

***Binocular
Vision
and Ocular
Motility***

SIXTH
EDITION

Binocular Vision and Ocular Motility

THEORY AND MANAGEMENT
OF STRABISMUS

Gunter K. von Noorden, MD

Emeritus Professor of Ophthalmology
Cullen Eye Institute
Baylor College of Medicine
Houston, Texas

Clinical Professor of Ophthalmology
University of South Florida College of Medicine
Tampa, Florida

Emilio C. Campos, MD

Professor of Ophthalmology
University of Bologna
Chief of Ophthalmology
S. Orsola-Malpighi Teaching Hospital
Bologna, Italy

M Mosby

A Harcourt Health Sciences Company

St. Louis London Philadelphia Sydney Toronto



A Harcourt Health Sciences Company

Editor-in-Chief: Richard Lampert
Acquisitions Editor: Kimberley Cox
Developmental Editor: Danielle Burke
Project Manager: Agnes Byrne
Production Manager: Peter Faber
Illustration Specialist: Lisa Lambert
Book Designer: Ellen Zanolle

Copyright © 2002, 1996, 1990, 1985, 1980, 1974 by Mosby, Inc.

All rights reserved. No part of this publication may be reproduced or transmitted in any form or by any means, electronic or mechanical, including photocopy, recording, or any information storage and retrieval system, without permission in writing from the publisher.

NOTICE

Ophthalmology is an ever-changing field. Standard safety precautions must be followed, but as new research and clinical experience broaden our knowledge, changes in treatment and drug therapy may become necessary or appropriate. Readers are advised to check the most current product information provided by the manufacturer of each drug to be administered to verify the recommended dose, the method and duration of administration, and contraindications. It is the responsibility of the treating physician, relying on experience and knowledge of the patient, to determine dosages and the best treatment for each individual patient. Neither the publisher nor the authors assume any liability for any injury and/or damage to persons or property arising from this publication.

Permission to photocopy or reproduce solely for internal or personal use is permitted for libraries or other users registered with the Copyright Clearance Center, provided that the base fee of \$4.00 per chapter plus \$.10 per page is paid directly to the Copyright Clearance Center, 222 Rosewood Drive, Danvers, Massachusetts 01923. This consent does not extend to other kinds of copying, such as copying for general distribution, for advertising or promotional purposes, for creating new collected works, or for resale.

Mosby, Inc.
A Harcourt Health Sciences Company
11830 Westline Industrial Drive
St. Louis, Missouri 63146

Printed in the United States of America.

Library of Congress Cataloging-in-Publication Data

Von Noorden, Gunter K., 1928–
Binocular vision and ocular motility : theory and management of strabismus / Gunter K. von Noorden, Emilio C. Campos.—6th ed.

p. cm.


Includes bibliographical references and index.

ISBN 0-323-01129-2

1. Strabismus. 2. Binocular vision. 3. Eye—Movements. I. Title.

RE771.V62 2001 616.7'62—dc21 2001042586

01 02 03 04 05 / 9 8 7 6 5 4 3 2 1



HERMANN MARTIN BURIAN
1906-1974

Preface to the Sixth Edition

A major change with this edition is the addition of co-author Dr. Emilio Campos, who is one of the leaders of European strabismology and widely respected for his scientific contributions. Dr. Campos has written a new chapter on Chemo-denervation and assisted me with the review and revision of this sixth edition. I selected Dr. Campos as a co-author because his scientific background is similar to mine. His mentor Bruno Bagolini was trained, as I was, by the late Hermann Burian, with whom I co-authored the first edition. Because of this common heritage we agree on all major issues discussed in this text. Whenever an occasional difference in opinions existed on minor subject matters both of our views were stated.

As in previous editions, new material was added and older text that had lost its relevance was deleted, except when it was of historical interest. *Binocular Vision and Ocular Motility* has become a major source of references to the older strabismus literature that is not retrievable through electronic search techniques. With this in mind, we have used a conservative approach in deleting older references so that they would remain available to the researcher and interested clinician.

We have endeavored to improve clarity in the text and tables, replaced several old figures with better examples, and added illustration of surgical techniques not covered in previous editions.

I feel deeply honored for having been asked by Dr. Gunter von Noorden to collaborate with him on the sixth edition of *Binocular Vision and Ocular Motility*, and I consider this recognition as one of the highlights of my career.

I hope that my input to this edition has not interfered with the homogeneity of this book and its original message.

Both Dr. von Noorden and I would appreciate any input from our readers that may help us to make future editions even more useful.

I would like to express my gratitude to my collaborators Drs. Costantino Schiavi and Costan-

The formerly voluminous chapter on sensory adaptation and stereopsis has been divided into three smaller chapters for easier access. Because sensorial anomalies in strabismus are only briefly dealt with in current texts, or receive at best spurious coverage in most teaching curricula for residents, the comprehensive discussion of this subject in this book appears to be fully justified.

The contributions and teaching of Hermann Burian remain apparent throughout this text but especially in Part One. We submit this volume not only as his legacy but also that of his teacher, Alfred Bielschowsky, who has influenced strabismology during the first half of the 20th century like no one else.

My thanks are due to Mrs. Louise Thomas, my faithful former secretary, for obtaining copies of articles from the local medical libraries and illustrations through the Baylor Department of Medical Illustrations, and to Mr. Mike Piorunski, librarian of the Friedenwald Library of the Wilmer Institute, for locating and verifying older references. Last, but not least, I thank my dear wife for her continued support and patience during the work on this edition.

The authors have no proprietary interest in any of the commercial products, drugs, or instruments mentioned in this book.

Gunter K. von Noorden

tino Bellusci, who have helped me in the preparation of clinical illustrations and surgical drawings. Many thanks also to Stefania Piaggi, C.O., for having located obscure references and for her help with the computer search of the literature.

I am grateful to all my collaborators and to those close to me for their patience during the preparation of the manuscript and ask their forgiveness for any lack of attention during this most stimulating but time-consuming venture.

Emilio C. Campos

Preface to the First Edition

He who is theoretic as well as practical is therefore doubly armed: able not only to prove the propriety of his design but equally so to carry it into execution.

VITRUVIUS

This volume is the product of the cooperative efforts of the two authors. Parts I and II were written by Burian, and Parts III and IV by von Noorden; however, both authors take full responsibility for the complete text.

In this work, our aim is to provide the practicing ophthalmologist as well as the budding one with the theoretic knowledge and practical know-how that will enable him to pursue the field of neuromuscular anomalies of the eyes in the manner set forth in the precept of Vitruvius.

The sound physiologic tradition of Hering, Helmholtz, Donders, Tschermak, Hofmann, and their schools forms the solid ground upon which was built the clinical work of Javal, Worth, Bielschowsky, Duane, Lancaster, and, more recently, Harms, Cüppers, Lyle, Bagolini, ourselves, and many others. Our purpose has been to convey this physiologic basis as concisely and simply as

possible, always with the practicing ophthalmologist in mind and wherever possible emphasizing its immediate clinical application. But much has happened in our field since the days of the old masters, and due consideration is given to the exciting and significant modern studies in the psychophysical and neurophysiologic areas as well as in the field of clinical management of strabismus. This volume is not a handbook or a system, however, and is not intended to be systematically or historically complete. We, therefore, have omitted many points that are to be found in reference works. Neither does this book supplant the *Atlas of Strabismus* by von Noorden and Maumenee, which continues to be a useful guide to the diagnostic aspects of strabismus.

The theoretic foundation has served us as a means to make the strictly clinical chapters both “theoretic and practical,” telling the ophthalmologist not only the “what and how” but also the “why.” We hope that the long hours of labor expended on this volume may be of real usefulness in the study of strabismus, particularly to the younger generation of ophthalmologists.

Hermann M. Burian
Gunter K. von Noorden

Contents

PART ONE

Physiology of the Sensorimotor Cooperation of the Eyes

1 General Introduction	3
The Eyes as a Sensorimotor Unit	3
The Tasks of the Motor System	3
Nature and Control of Ocular Movements	3
Voluntary and Involuntary Eye Movements	3
Cybernetic Control of the Eye Movements	4
Apparent Movement of the Environment	5
Empiricism and Nativism	5
2 Binocular Vision and Space Perception	7
Fusion, Diplopia, and the Law of Sensory Correspondence	7
Relative Subjective Visual Directions	7
Retinomotor Values	8
Common Relative Subjective Visual Directions	9
Retinal Correspondence	10
Sensory Fusion	10
Motor Fusion	11
Retinal Rivalry	11
Objective (Physical) and Subjective (Visual) Space	12
Discrepancies of Objective and Subjective Metrics	14
Distribution of Corresponding Retinal Elements	15
The Foveae as Corresponding Elements	15
The Horopter	16
Physiologic Diplopia	18
Clinical Significance	18
Suppression	19
Panum's Area of Single Binocular Vision	20
Fixation Disparity	21
Stereopsis	21
Physiologic Basis of Stereopsis	22
Local vs. Global Stereopsis	23
Stereopsis and Fusion	24
Stereoscopic Acuity	25
Monocular (Nonstereoscopic) Clues to Spatial Orientation	25
Interaction of Stereoscopic and Monocular Clues	27
Clinical Significance of Monocular Clues	27
Experimental Determination of the Longitudinal Horopter and the Criteria of Retinal Correspondence	28
Criterion of Single Vision	28
Apparent Frontal Plane Criterion	28
Criterion of Common Visual Directions	29
Criterion of Highest Stereoscopic Sensitivity	29
Egocentric (Absolute) Localization	29
Egocentric Localization and Convergence	29
Egocentric Localization and Proprioception	30
Clinical Significance of Relative and Egocentric Localization	31
Theories of Binocular Vision	31
Correspondence and Disparity	31
Neurophysiologic Theory of Binocular Vision and Stereopsis	31
Older Theories of Binocular Vision	33
Advantages of Binocular Vision	35
3 Summary of the Gross Anatomy of the Extraocular Muscles	38
Rectus Muscles	39
Muscle Pulleys	41
Oblique Muscles	42
Fascial System	44
Tenon's Capsule	44
Muscle Sheaths and Their Extensions	45
Ligament of Lockwood	47
Check Ligaments	47
Intracapsular Portion of the Muscle	47
Functional Role of the Fascial System	48
Developmental Anomalies of Extraocular Muscles and the Fascial System	48
Innervation of Extraocular Muscles	49
Blood Supply of Extraocular Muscles	49
4 Physiology of the Ocular Movements	52
Basic Kinematics	52
Translatory and Rotary Movements	52
Center of Rotation	52

Definitions of Terms and Action of Individual Muscles 52
 Further Considerations of Mechanics of Extraocular Muscles 56

The Fundamental Laws of Ocular Motility 59

Donders' and Listing's Laws 59
 Sherrington's Law of Reciprocal Innervation 63
 Hering's Law of Equal Innervation 64
 Experimental Studies of Integration of Ocular Movements by Muscle Transposition 67

Survey of Ocular Movements and Their Characteristics 67

Terminology of Ocular Movements 67
 Versions 68
 Vergences 71
 Characteristics of Version and Vergence Movements 76

Fixation and the Field of Fixation 79

Fixation 79
 Field of Fixation 79

5 The Near Vision Complex 85

Accommodation 85

Mechanism of Accommodation 85
 Units of Measurement of Accommodation and Definition of the Prism Diopter 86
 Sympathetic Innervation 86

Convergence 86

Units of Measurement of Convergence 87
 Components of Convergence 88

Pupillary Constriction 99

6 Histology and Physiology of the Extraocular Muscles 101

Structure and Function of the Extraocular Muscles 101

General Histologic Characteristics 101
 Nerve Supply 102
 Physiologic and Pharmacologic Properties 102
 Slow and Fast Twitch Fibers 103

Structural and Functional Correlations 107

Muscle Spindles and Palisade Endings in the Extraocular Muscles 109

Electromyography 109

Sources of Tonus of the Extraocular Muscles 111

7 Visual Acuity, Geometric Optical Effects of Spectacles, and Aniseikonia 114

Visual Acuity 114

Basic Physiologic Concepts 114
 Variables Affecting Visual Acuity 115

Geometric Optical Effects of Spectacles 118

Aniseikonia 119

PART TWO

Introduction to Neuromuscular Anomalies of the Eyes

8 Classification of Neuromuscular Anomalies of the Eyes 127

Heterophoria and Heterotropia 127
Relative and Absolute Position of Rest 128
Ocular Alignment 129
Direction of Deviation 129
Comitance and Incomitance 131
Constancy of Deviation 131
State of Vergence Systems 132
Type of Fixation 132
Time of Onset of Deviation 132
Paralytic Strabismus 132
 Paralysis and Paresis 132
 Muscles Affected 133
 Duration and Cause 133
 Seat of Lesion 133
Mechanical-Restrictive Strabismus 133
Orbital Strabismus 133

9 Etiology of Heterophoria and Heterotropia 134

Factors Responsible for the Manifestation of a Deviation 134
 Abnormalities of Fusion Mechanism 134
 Reflexologic Theories 137
Factors Causing the Underlying Deviation 138
 Mechanical (Muscular) Theories 138
 Structural Anomalies of Extraocular Muscles 139
 Role of Accommodation and Refraction in Comitant Strabismus 139
 Fixation Disparity 140
 Other Innervational (Neurologic) Factors in Comitant Strabismus 141
 Brain Damage 143
 Embryopathy 145
 Facial and Orbital Deformities 145
Genetics of Comitant Strabismus 145
 Summary 148
Concluding Remarks 148

10 Symptoms in Heterophoria and Heterotropia and the Psychological Effects of Strabismus 153

Asthenopia and Diplopia 153
Psychological Effects of Strabismus 156

11 Examination of the Patient—I Preliminaries 158

History 158
Assessment of Visual Acuity in Children 159

Estimation of Visual Acuity in Infants	159
Measurement of Visual Acuity in Preschool-Age Children	162
Measurement of Visual Acuity in School-Age Children and Adults	163
Refraction	163
Changes of Refraction with Age	165
12 Examination of the Patient—II	
Motor Signs in Heterophoria and Heterotropia	168
Inspection of the Eyes and Head Position	168
Inspection of the Lids and Lid Fissures	168
Position of the Globes—Angle Kappa	169
<i>Measurement of Angle Kappa</i>	171
<i>Size of Angle Kappa</i>	172
<i>Clinical Significance of Angle Kappa</i>	172
Observation of Head Position	173
Determination of Presence of a Deviation—Cover and Cover-Uncover Tests	174
Measurement of Deviation	176
Prism and Cover Test	177
<i>Physiologic Basis</i>	177
<i>Performance</i>	178
<i>Limitations</i>	181
<i>Prism and Cover Test in Diagnostic Positions of Gaze</i>	182
Measurement with the Major Amblyoscope	183
Corneal Reflection Tests	185
Photographic Methods	186
Brückner Test	187
Subjective Tests	187
<i>Diplopia Tests (Red-Glass Test and Others)</i>	187
<i>Haploscopic Tests</i>	190
Measurement of Cyclodeviations	194
<i>Qualitative Diagnosis Based on Position of Double Images</i>	194
<i>Maddox Double Rod Test</i>	194
<i>Bagolini Striated Glasses</i>	195
<i>Major Amblyoscope</i>	196
<i>Ophthalmoscopy and Fundus Photography</i>	196
<i>The New Cyclo Test</i>	198
<i>Scotometry</i>	198
<i>Determination of the Subjective Horizontal or Vertical</i>	198
Measurement of Dissociated Vertical Deviations	198
The Head Tilt Test	198
Examination of the Motor Cooperation of the Eyes	199
Ductions and Versions	199
<i>Elevation or Depression of the Adducted Eye (Upshoot or Downshoot in Adduction)</i>	201
Measurement of Vergences	202
<i>Measurement With Prisms</i>	202
<i>Measurement With a Major Amblyoscope</i>	206
<i>Fusional Movements Elicited by Peripheral Retinal Stimuli in Strabismus</i>	206
Near Point of Convergence	206
<i>Maintenance of Convergence</i>	207
13 Examination of the Patient—III	
Sensory Signs, Symptoms, and Binocular Adaptations in Strabismus	211
Confusion and Diplopia	212
Monocular Diplopia	213
Binocular Diplopia	214
Suppression	215
Mechanism and Seat	215
Clinical Features	216
Tests for Suppression	217
<i>Binocular Perimetry and Haploscopy</i>	217
<i>Prisms</i>	218
<i>The Four-Prism Diopter Base-Out Prism Test</i>	218
<i>Monocular Visual Acuity Measured Under Binocular Conditions</i>	219
<i>The Worth Four-Dot Test</i>	219
Suppressing Versus Ignoring a Double Image	220
Measurement of Depth of Suppression	221
Blind Spot Mechanism	221
Anomalous Correspondence	222
Basic Phenomenon and Mechanism	222
Tests	225
<i>Afterimage Test</i>	225
<i>Striated Glasses Test of Bagolini</i>	227
<i>Testing With the Major Amblyoscope</i>	228
<i>Diplopia Test</i>	230
<i>Testing With Projection Devices</i>	230
<i>Foveo-Foveal Test of Cüppers</i>	230
Evaluation of Tests	231
Neurophysiologic Basis	233
Suppression and Anomalous Correspondence	233
Development and Clinical Picture	234
<i>Development</i>	234
<i>Clinical Picture</i>	235
Quality of Binocular Vision in Anomalous Correspondence	239
Prevalence	239
Theories	240
Review and Summary	241
14 Examination of the Patient—IV	
Amblyopia	246
Prevalence, Social and Psychosocial Factors	246
Classification and Terminology	248
Strabismic Amblyopia	249
Anisometropic Amblyopia	250
Visual Deprivation Amblyopia (Amblyopia Ex Anopsia)	252
Idiopathic Amblyopia	253
Organic Amblyopia	253
Amblyopia Secondary to Nystagmus	254
Clinical Features of Strabismic Amblyopia	254
Fixation Preference	254
Visual Acuity	255
Fixation Pattern of the Amblyopic Eye	260
The Sensitive Period	268
Pathogenesis and Pathophysiology of Amblyopia	269
Psychophysical Studies	269
Higher Nervous Center Activities	277

Eye Movements in Amblyopia 279
 Electrophysiologic Studies 279
Amblyopia vs. Suppression 282
**Experimental Amblyopia in Animal Models
 and Histologic Abnormalities in Brains
 of Human Amblyopes 282**
The Essence of Amblyopia 286

15 Examination of the Patient—V
Depth Perception 298
Development of Stereopsis 298
Stereopsis and Strabismus 298
Testing for Stereopsis 299
 Major Amblyoscope or Stereoscope 299
 Stereogram 299
 Titmus Stereo Test 299
 Random-Dot Stereograms 301
 TNO Test 302
 Lang Test 303
 Two-Pencil Test 304

PART THREE

***Clinical Characteristics of
 Neuromuscular Anomalies of
 the Eye***

16 Esodeviations 311
Esophoria and Intermittent Esotropia 311
Etiology 311
Clinical Signs 311
Symptoms 312
Sensorial Adaptation 312
Diagnosis 312
Therapy 313
Accommodative Esotropia 314
 Refractive Accommodative Esotropia (Normal AC/A
 Ratio) 314
Definition 314
Etiology 314
Clinical Characteristics 316
Therapy 316
 Nonrefractive Accommodative Esotropia (High AC/A
 Ratio) 318
Definition 318
Clinical Characteristics 318
Therapy 318
 Hypoaccommodative Esotropia 319
Definition 319
Clinical Characteristics 319
Partially Accommodative Esotropia 319
Definition 319
Clinical Characteristics 320
Therapy 320
Nonaccommodative Esotropia 320
 Essential Infantile Esotropia 320
Definition 320
Terminology, Prevalence, Etiology 320

Differential Diagnosis 321
Clinical Characteristics 321
Therapy 329
 Nonaccommodative Convergence Excess Esotropia
 (Normal AC/A Ratio) 336
Definition 336
Clinical Characteristics 336
Treatment 336
 Acquired or Basic Esotropia 336
Definition 336
Clinical Characteristics 337
Therapy 337
 Esotropia in Myopia 338
 Acute Acquired Comitant Esotropia 338
*Acute Strabismus After Artificial Interruption of
 Fusion 338*
*Acute Esotropia Without Preceding Disruption of
 Fusion (Burian-Franceschetti Type) 339*
Acute Esotropia of Neurologic Origin 339

Microtropia 340
Historical Review 340
Current Concepts and Clinical Significance 342
Diagnosis 343
Therapy 344

Recurrent Esotropia 345
Secondary Esotropia 345
 Sensory Esotropia 345
Etiology and Clinical Characteristics 345
Therapy 346
 Consecutive Esotropia 347

Management of Surgical Overcorrections 347
Esotropia Associated with Vertical Deviations 348
Clinical Characteristics and Diagnosis 348
Therapy 349

17 Exodeviations 356
Classification and Etiology 356
Primary Exodeviations 358
Clinical Characteristics 358
Therapy 365
Surgical Treatment 367
Dissociated Exodeviations 372
Secondary Exodeviations 372
 Sensory Exotropia 372
 Consecutive Exotropia 372

18 Cyclovertical Deviations 377
Comitant Hyperdeviations 377
Etiology and Clinical Characteristics 377
Therapy 378
Dissociated Vertical Deviations 378
Terminology 378
Clinical Characteristics 378
Measurement 380
Etiology 381
Differential Diagnosis 383
Therapy 383
Dissociated Horizontal Deviations 385
**Elevation in Adduction (Strabismus
 Sursoadductorius) 385**

<i>Clinical Characteristics</i>	385		
<i>Etiology</i>	386		
<i>Therapy</i>	387		
Depression in Adduction (Strabismus Deorsoadductorius)	387		
Cyclodeviations	389		
<i>Diagnosis</i>	389		
<i>Clinical Characteristics</i>	389		
<i>Therapy</i>	391		
19 A and V Patterns	396		
Etiology	398		
Horizontal School	398		
Vertical School	399		
Oblique School	399		
Orbital Factors	399		
<i>Craniofacial Anomalies</i>	399		
<i>Heterotropia of Muscle Pulleys</i>	400		
Anomalies of Muscle Insertions and Cyclotorsion	401		
Conclusions	402		
Prevalence	404		
Clinical Findings and Diagnosis	404		
Treatment	406		
Indications for Surgery	406		
Surgical Methods	407		
<i>Surgery on the Horizontal Rectus Muscles</i>	407		
<i>Surgery on the Oblique Muscles</i>	407		
<i>Transposition of Horizontal or Vertical Rectus Muscles</i>	409		
<i>Slanting of the Horizontal Muscle Insertions</i>	410		
Choice of Surgical Procedure	410		
20 Paralytic Strabismus	414		
Diagnosis and Clinical Characteristics	414		
<i>Ductions and Versions</i>	415		
<i>Measurement of the Deviation</i>	415		
<i>Head Tilt Test</i>	416		
<i>Compensatory Anomalies of Head Position</i>	417		
<i>Sensory Anomalies</i>	421		
<i>Past-Pointing</i>	421		
<i>Electromyography</i>	422		
<i>Neurogenic Paralysis vs. Myogenic or Structural Restriction of Eye Movements</i>	422		
<i>Forced Duction Test</i>	423		
<i>Estimation of Generated Muscle Force</i>	425		
<i>Eye Movement Velocity</i>	426		
<i>Paralytic vs. Nonparalytic Strabismus</i>	427		
<i>Congenital vs. Acquired Paralysis</i>	427		
<i>Orbital Imaging Techniques</i>	429		
<i>Evaluation of Visual Impairment Caused by Diplopia</i>	429		
Paralysis of Individual Extraocular Muscles	429		
Cranial Nerve III Paralysis	430		
Cranial Nerve IV Paralysis	434		
Cranial Nerve VI Paralysis	439		
Skew Deviation	442		
Double Elevator Paralysis	442		
Double Depressor Paralysis	443		
Supranuclear and Internuclear Paralysis	444		
		Therapy of Paralytic Strabismus	444
		Nonsurgical Therapy	445
		Surgical Therapy	445
		Alternative Methods	451
21 Special Forms of Strabismus	458		
Retraction Syndrome (Duane Syndrome)	458		
Laterality and Sex Distribution	458		
Etiology	459		
Clinical Findings and Diagnosis	461		
Therapy	465		
Brown Syndrome	466		
Incidence, Laterality, and Heredity	466		
Associated Anomalies	467		
Natural History	467		
Etiology	467		
Diagnosis and Differential Diagnosis	470		
Therapy	470		
Adherence Syndrome	471		
Strabismus Fixus	471		
Clinical Findings and Etiology	471		
Therapy	472		
Strabismus in High Myopes	473		
Fibrosis of the Extraocular Muscles	474		
Graves' Endocrine Ophthalmopathy	476		
Etiology	476		
Diagnosis and Clinical Findings	476		
Therapy	478		
Acute Orbital Myositis	480		
Cyclic Heterotropia	480		
Clinical Findings and Etiology	480		
Therapy	482		
Acquired Motor Fusion Deficiency	482		
Fracture of the Orbital Floor	483		
Clinical Findings and Etiology	483		
Therapy	484		
Fracture of the Medial Orbital Wall	486		
Superior Oblique Myokymia	487		
Clinical Findings and Etiology	487		
Therapy	487		
Ocular Myasthenia Gravis	488		
Clinical Findings	488		
Diagnosis	488		
Therapy	489		
Chronic Progressive External Ophthalmoplegia (Ocular Myopathy of von Graefe)	489		
Clinical Findings and Etiology	489		
Therapy	490		
22 Anomalies of Convergence and Divergence	500		
Anomalies of Convergence	502		
Convergence Insufficiency	502		
Convergence Insufficiency Associated with Accommodative Insufficiency	503		
Convergence Paralysis	503		
Convergence Spasm	504		
Anomalies of Divergence	505		
Divergence Insufficiency	505		
Divergence Paralysis	505		

23 Nystagmus	508	26 Principles of Surgical Treatment .	566
Manifest Congenital Nystagmus	508	History and General Comments	566
Sensory and Motor Type	508	Choice of Operation	568
Clinical Characteristics	509	Motility Analysis	569
Compensatory Mechanisms	511	Symmetrical vs. Asymmetrical Operations	570
Latent and Manifest-Latent Congenital		Amount of Operation	571
Nystagmus	516	Prism Adaptation Test	572
Clinical Characteristics	516	Operations to Weaken the Action of a Muscle	573
Treatment	520	Operations to Strengthen the Action of a	
Medical Treatment	521	Muscle	579
Surgical Treatment	522	Combined Recession-Resection Operation	580
		Single vs. Multiple Procedures	580
		Preparation of Patient and Parents for Surgery	581
		Anesthesia	581
		General Anesthesia	581
		Local Anesthesia	582
		Instruments, Sutures, Needles	582
		Surgical Techniques	583
		Preparation of the Eye	583
		Fixation of the Globe	584
		Conjunctival Incision and Exposure of a Rectus	
		Muscle	584
		Recession of a Rectus Muscle	587
		Resection of a Rectus Muscle	588
		Adjustable Sutures	591
		Marginal Myotomy of a Rectus Muscle	597
		Myectomy of the Inferior Oblique Muscle	598
		Recession of the Inferior Oblique Muscle	600
		Tenectomy of the Superior Oblique Muscle	602
		Recession of the Superior Oblique Muscle	603
		Tucking of the Superior Oblique Muscle	603
		Anterior and Lateral Displacement of the Superior	
		Oblique Tendon for Excyclotropia (Harada-Ito	
		Procedure)	607
		Posterior Fixation Suture	609
		Muscle Transposition Procedures	612
		Recession of Conjunctiva and Tenon's Capsule	617
		Traction Sutures	617
		Use of Plastic Materials	618
		Complications	618
		Surgical Complications	618
		Complications of Anesthesia	619
		Postoperative Complications	620
		Overcorrections	623
		Postoperative Care	623
		Length of Hospitalization and Postoperative	
		Checkups	623
		Dressing	624
		Medication	624
		Index	633

PART FOUR

Principles of Therapy**24 Principles of Nonsurgical Treatment** 537**Optical Treatment** 537

Refractive Correction 537

Prisms 540

Pharmacologic Treatment 541

Miotics 541

Atropine 543

Chemodenervation 543

Orthoptics 543

Applications 543

Indications and Contraindications 544

Treatment of Amblyopia 545

Red Filter Treatment 550

Prisms 550

Penalization 550

Drugs 552

Pleoptics 552

CAM Treatment 553

Other Types of Treatment 553

Rationale for Treatment 553

25 Chemodenervation of Extraocular Muscles—Botulinum Toxin 559**Mechanisms of Action** 559**Injection Technique** 560**Indications** 561

Botox in Infantile Esotropia 561

Botox in Other Forms of Comitant Strabismus 562

Botox in Paralytic Strabismus 562

Botox in Endocrine Ophthalmopathy and Other
Ocular Motility Disturbances 563

Botox in Nystagmus 563

Other Ophthalmologic Indications 563

Alternatives to Botox for Chemodenervation 563

P A R T

one

***Physiology of the
Sensorimotor
Cooperation of
the Eyes***

General Introduction

The Eyes as a Sensorimotor Unit

The two human eyes with their adnexa and nervous system connections form an indivisible entity. This fact must always be kept in mind, but for the purpose of study a distinction between the sensory and the motor systems is necessary.

Light stimuli, having gone through the changes imposed on them by the refractive media, reach the peripheral organ of vision, the retina, and produce physical and chemical alterations in the retinal receptors. In turn, these alterations provoke in the retinal neurons physicochemical and electrical changes that are transmitted as impulses to the central nervous system. Eventually, visual sensations of form, spatial relationships, and color appear in our consciousness. This sequence of events may be called the *sensory* aspect of the visual process. The events in the sensory part of the visual system also precipitate a chain of responses in the *motor* system of the eyes, in the central and peripheral nervous arrangements, and in the inner and outer muscles of the eyes.

In this unitary sensorimotor system, the sensory system transmits and elaborates the information received about the outside world. The motor system has no independent significance and is entirely in the service of the sensory system, by which it is largely governed. Understanding of this system is essential for the interpretation of the neuromuscular anomalies of the eyes.

The Tasks of the Motor System

The tasks of the motor system are (1) to enlarge the field of view by transforming the field of vision into the field of fixation, (2) to bring the image of the object of attention onto the fovea and keep it there, and (3) to position the two eyes in such a way that they are properly aligned at all times, thereby ensuring the maintenance of single binocular vision.

Nature and Control of Ocular Movements

Voluntary and Involuntary Eye Movements

In agreement with a time-honored classification, a distinction is made between voluntary and involuntary eye movements. *Voluntary* simply implies that the movements are “willed” by the individual, presumably as a result of a chain of impulses that originate in the cortex. *Involuntary* eye movements are not willed by the individual and, indeed, occur without awareness. They are elicited mainly by stimuli arising from outside the body, for example, visual or auditory, or those arising from within the body, for example, vestibular. The former are referred to as *exteroceptive*, the latter as *interoceptive* stimuli.

When the illuminance of the retina changes, the pupil of the eye constricts or dilates. When we

tilt our head to one shoulder, the eyes make a parallel movement around their anteroposterior axes, so the vertical meridians of the retinas turn in the direction opposite that of the head. The eyes attempt to right themselves. Both these motor reactions are highly useful *unconditioned reflexes*. The central nervous system structures that mediate these reflexes are subcortical. The individual is not aware they are taking place.

When a light stimulus reaches the retinal periphery, the eye turns and causes the stimulus to impinge on the area of highest resolving power, the fovea. If a binocularly fixated object approaches the eyes, the visual axes converge to maintain fixation. If for some reason the proper alignment of the visual axes has been lost, corrective fusional movements occur and restore binocular fixation. All these movements are highly useful, and most of them are also reflexive, but there is a significant difference between them and reflex movements.

If a person is lost in thought or concentrating on an object of regard, another object approaching from one side may not be noticed—at times with regrettable results. One can voluntarily stop convergence or voluntarily overconverge. In inattentive states, one may fail to make fusional movements. All these movements, then, though basically reflexive, require the cooperation of the cerebral cortex, in particular a state of visual attention. Hofmann and Bielschowsky,⁸ who published their classic study on fusional movements in 1900, clearly noted the reflex nature of these movements, but were also aware that they did not come about without the concurrence of attention. They designated the fusional movements as *psycho-optical reflexes*. At the time Hofmann and Bielschowsky published their paper, Pavlov had just begun his work on conditioned reflexes, and his findings were not yet published. Today, reflex movements that require cooperation of the cerebral cortex are designated as *conditioned reflexes*.

In summary, all eye movements, insofar as they are not voluntary, are unconditioned or conditioned reflexes performed in the service of the sensory system of the eyes, specifically in the interest of clear, distinct vision and of binocular fixation.

Cybernetic Control of the Eye Movements

The concept of reflex activity, with the neuron as the unit of the anatomical and physiologic organi-

zation of the nervous system, for a long time has been the cornerstone of neurophysiology and neurology and, consequently, also that of the sensorimotor system of vision. Chavasse¹ introduced an extreme reflexologic view into the analysis of neuromuscular anomalies of the eyes. He extended the concept of unconditioned reflexes, in the manner of Pavlov's teaching on the higher nervous activity, to include the sensory visual responses. Chavasse's views are discussed in detail in later chapters.

Control of the eye movements thus was interpreted as resulting from exteroceptive and proprioceptive stimulations. More recently, a new way of thinking and a new vocabulary have been developing. Cybernetics and information theory, together with spectacular advances in electronic technology, have brought about a revolution that could not help have an influence on the interpretation of biological phenomena. The terminology of the engineer has taken on a strangely biological cast, and the terminology of the biologist is increasingly borrowing terms from the engineer. "Closed loops," "open loops," "feedback," and "servomechanisms" are words heard today as commonly from biologists as from engineers.

The information received from the retina may be designated as retinal error signal (the difference between the desired and received placement of the image) or as *outflow* feedback. Signals sent out from tension sensors in the extraocular muscles would then represent an *inflow* (proprioceptive) feedback. Inflow feedback is the common mechanism provided for in skeletal muscles, for example, the muscles of the limbs. Whether inflow from the extraocular muscles plays a role in oculomotor control or space perception is discussed in Chapter 2.

Ludvig,¹² one of the first to propose a cybernetic model for eye movements, stated that it is tempting to hypothesize that the retina provides the necessary feedback, since the visual environment is ordinarily heterogeneous; therefore, movements of the eyes bring about changes in the retinal and neural pattern even in the absence of any interoceptive sense. Ludvig pointed out, however, that control of the eye movements cannot be based on retinal feedback alone.¹² The temporal relations are such that entire large excursions of several degrees, so-called saccadic movements, may be initiated and completed by the eyes before there is time for any inflow or outflow

feedback to become effective. This reasoning may not apply to the much slower fusional movements.

According to Ludvigh's hypothesis¹² a definite innervation sequence always follows when the stimulus has a specific extrafoveal position. This is an important concept well described by Hofmann,⁷ who spoke of a *motor value* of the retinal elements proportional to the distance of the stimulated element from the fovea, whose retinomotor value is equal to zero (see Retinomotor Values in Chapter 2).

The cybernetic scheme proposed by Ludvigh¹² is a qualitative one. Later authors^{2, 5, 15-17} have worked out quantitative models for oculomotor control. It is not useful to discuss them in this book; interested readers are referred to the original publications.

Apparent Movement of the Environment

When the eyes make a saccadic movement, the image of the environment sweeps across the retina, yet no movement is perceived. This phenomenon has been explained by von Holst and Mittelstaedt,⁹ Ludvigh,¹¹ and others as follows.

The control system (the "space representation center" of Ludvigh¹²) is informed of the conjugate innervation sent to the extraocular muscles. If the movement is accurately performed, the information from retinal feedback coincides with the information about the conjugate innervation, and no movement is perceived; but if the two disagree, an apparent movement of the visual environment results.

This can be shown by a simple experiment: close the left eye and push your right eye nasalward with your finger. Images will now sweep across the retina, but since the control center knows of no active innervation to the right medial rectus muscle, the environment appears to make a jump to the right. Likewise, if an extraocular muscle (e.g., the right lateral rectus muscle) is paralyzed, an innervation impulse to abduct that eye will not be executed at all or, if any abduction occurs, the eye will not abduct fully. The control center is informed of the innervation, but the absence of the proper retinal feedback again causes an apparent movement of the environment to the right. This phenomenon is the basis of *past-pointing* in paralytic strabismus, which is discussed further in Chapter 20.

Empiricism and Nativism

Historically, there were two opposing schools of thought with regard to the origin and development of normal binocular vision and spatial orientation. One maintained that humans are born without binocularity or spatial orientation and that binocularity and spatial orientation are learned functions acquired by trial and error through experience and assisted by all the other senses, especially the kinesthetic sense. This is the theory of *empiricism*: that binocular vision depends on ontogenetic development. The other school held that binocular vision and spatial orientation are not learned functions but are given to humans with the anatomico-physiologic organization of his visual system, which is innate. This is the *nativistic* teaching: that binocular vision is acquired phylogenetically rather than ontogenetically.

The principal proponents of these two schools were Hering and Helmholtz who—with very little experimental evidence on either side—battled each other fiercely during the second half of the nineteenth century. The intensity of this battle is understandable, because it is not restricted to the question of the development of binocular vision; indeed it is a battle between two attitudes toward life and existence.

One may ask why philosophic ponderings on empiricism and nativism should be found in a book on strabismus. Surprising as it may seem, they are of basic importance in the management of strabismus since the prognosis and the attitude toward timing of treatment depend on this view. If one believes that binocular vision is a learned skill and if a functional cure is sought, one will have to operate very early in a child's life. Another ophthalmologist, more nativistically inclined, may believe that, given a normal sensorimotor anlage, early surgery is not absolutely essential, just as it is of no functional use if the anlage is not there.

There is no doubt that the anlage for normal binocular vision is present at birth. No evidence exists, for instance, that sensory fusion or stereopsis are "learned" processes any more than the perception of color—as distinct from color naming—is a learned process. Certain motor skills of the eyes are learned and improvable, as are all motor skills. The situation may be compared with that of a musician. "Innate" musical talent is necessary, but to be a pianist or violinist the motor skills of fingers and arms must be learned and continually reinforced through practice.

Animal research during the past three decades has actually provided support for both the nativistic and the empiricist schools of thought. The most direct evidence for the nativistic view came from the epochal work of Hubel and Wiesel,¹⁰ who showed with microelectrode recordings that visually inexperienced kittens have striate neurons with normal orientation sensitivity and a considerable number of neurons that are responsive to stimulation from either eye. In fact, electrophysiologic data from these kittens were strikingly similar to those obtained from adult cats. The same degree of complex functional differentiation of the visual cortex is present in visually immature baby monkeys.¹⁸ These findings support a nativistic view, according to which many connections responsible for the highly organized behavior of the striate cortex must be present at birth or within a few days of it. On the other hand, we have also learned from animal experiments that *the normal postnatal development of the visual system depends on normal visual experience* and that this development can be adversely modified by abnormal visual input. For instance, environmental factors are highly effective in tuning the spatial orientation of cortical neurons.⁶ Only brief disruptions of binocularity, produced by suturing the lid of one eye in a monkey¹⁴ or by creating artificial strabismus,³ suffice to decimate or even abolish binocular neurons in the striate cortex and thus the ability to see stereoscopically.⁴ Thus, normal visual experience is essential to preserve visual functions already present at birth and to promote their further development. The contradiction between empiricism and nativism, with all its philosophical and social implications, may well be only an apparent one as far as the visual system is concerned.¹³

REFERENCES

1. Chavasse FB: Worth's Squint or the Binocular Reflexes and Treatment of Strabismus. Philadelphia, P Blakiston's Son & Co, 1939.
2. Collins CC: The human oculomotor control system. In Lennerstrand G., Bach-y-Rita P, ed: Basic Mechanisms of Ocular Motility and Their Clinical Applications. New York, Pergamon Press, 1975, p 145.
3. Crawford ML, Noorden GK. The effects of short-term experimental strabismus on the visual system in *Macaca mulatta*. Invest Ophthalmol Vis Sci 18:496, 1979.
4. Crawford ML, Noorden GK, von Meharg LS, et al. Binocular neurons and binocular function in monkeys and children, Invest Ophthalmol Vis Sci 24:491, 1983.
5. Fender DH, Nye PW: An investigation of the mechanisms of eye movement control. Kybernetik 1 (July):81, 1961.
6. Hirsch HVB, Spinelli DN: Visual experience modifies distribution of horizontally and vertically oriented receptive fields in cats. Science 168:869, 1970.
7. Hofmann FB.: Die Lehre vom Raumsinn des Auges. In Axenfeld T, Elschnig A, eds: Graefe-Saemisch's Handbuch der gesamten Augenheilkunde, ed 2, vol 3. Berlin, Springer-Verlag, 1920-1923, p 208.
8. Hofmann FB, Bielschowsky A: Über die der Willkür entzogenen Fusionsbewegungen der Augen. Pflügers Arch 80:1, 1900.
9. Holst E von, Mittelstaedt E: Das Refferenzprinzip (Wechselwirkung zwischen Zentralnervensystem und Peripherie). Naturwissenschaften 37:464, 1950.
10. Hubel DH, Wiesel TN: Receptive fields of cells in striate cortex of very young, visually inexperienced kittens. J Neurophysiol 26:994, 1963.
11. Ludvig E: Possible role of proprioception in the extraocular muscles. Arch Ophthalmol 48:436, 1952.
12. Ludvig E: Control of ocular movements and visual interpretation of environment. Arch Ophthalmol 48:442, 1952.
13. Noorden GK von: Application of basic research data to clinical amblyopia. Ophthalmology 85:496, 1978.
14. Noorden GK von: Morphological and physiological changes in the monkey visual system after short-term lid suture. Invest Ophthalmol Vis Sci 17:762, 1978.
15. Robinson DA: Oculomotor control signals. In Lennerstrand G, Bach-y-Rita P, eds: Basic Mechanisms of Ocular Motility and Their Clinical Applications. New York, Pergamon Press, 1975, p 337.
16. Stark L, Kupfer C, Young LR: Physiology of the visual control system. NASA CR-283, Washington, DC, June 1965.
17. Sunderhauf A: Untersuchungen über die Regelung der Augenbewegungen. Klin Monatsbl Augenheilkd 136:837, 1960.
18. Wiesel TN, Hubel DH: Ordered arrangement of orientation columns in monkeys lacking visual experience. J Comp Neurol 158:301, 1974.

Binocular Vision and Space Perception

Without an understanding of the physiology of binocular vision it becomes difficult, if not impossible, to appreciate its anomalies. The reader is well advised to study this chapter thoroughly since important basic concepts and terminology used throughout the remainder of this book are introduced and defined. It is of historical interest that most of these concepts and terms have only been with us since the nineteenth century when they were introduced by three men who may be considered among the fathers of modern visual physiology: Johannes Müller, Hermann von Helmholtz, and Ewald Hering. The basic laws of binocular vision and spatial localization that were laid down by these giants of the past form the very foundation on which our current understanding of strabismus and its symptoms and sensory consequences is based.

Fusion, Diplopia, and the Law of Sensory Correspondence

Let us position an object at a convenient distance in front of an observer at eye level and in the midplane of the head. If the eyes are properly aligned and if the object is fixated binocularly, an image will be received on matching areas of the two retinas. If the eyes are functioning normally and equally, the two images will be the same in size, illuminance, and color. In spite of the presence of the two separate physical (retinal) images,

only one visual object is perceived by the observer. This phenomenon is so natural to us that the naive observer is not surprised by it; he is surprised only if he sees double. Yet the opposite—single binocular vision from two distinct retinal images—is the truly remarkable phenomenon that requires an explanation.

Relative Subjective Visual Directions

Whenever a retinal area is stimulated by light entering the eye, the stimulus is perceived not only as being of a certain brightness and color and of a certain form but also as always being localized in a certain direction in visual space. One cannot have a visual impression without seeing it somewhere. If the stimulated retinal area is located to the left of the fovea, it is seen in the right half of the field; if it is located to the right of the fovea, it is seen in the left half of the field.

The direction in which a visual object is localized is determined by the *directional*, or *spatial*, values of the stimulated retinal elements. These directional values (the local signs of Lotze) are an intrinsic property inherent to the retinal elements, as are all the properties that lead to sensations of brightness, color, and form of a percept.

That the directional values are intrinsic properties of the retinal elements and are not caused by the location of the light stimulus in external space or by some other properties of the light stimulus

can be shown by using inadequate stimuli. If the retina is stimulated mechanically (pressure) or electrically, the resulting sensation is localized in the same specific direction in which it would be localized if the retinal elements had been stimulated by light. For instance, if we apply finger pressure near the temporal canthus through the lids of one eye, we will become aware of a positive scotoma in the nasal periphery of that eye.

It must be made clear at this point that whenever *retinal elements*, *retinal points*, or *retinal areas* are spoken of in this book, they are to be understood in the sense in which Sherrington⁸⁵ used them. He defined these terms to mean “the retinocerebral apparatus engaged in elaborating a sensation in response to excitation of a unit area of retinal surface.” None of the “properties” spoken of “belong” to the retinal elements per se. Anatomical, physiological, biophysical, and biochemical arrangements and mechanisms within the retina give rise to excitations that ultimately result in what we know as “vision.” We “see” with our brain, not with our retina, but the first step in elaboration of information received by the eye takes place in the retina. Without the retina, there is no vision. Since it is vastly easier for us to visualize the retina than the totality of the retinocerebral apparatus, retinal terminology is adhered to throughout this book.

Each retinal element, then, localizes the stimulus as a visual percept in a specific direction, a visual direction, but this direction is not absolute. It is relative to the visual direction of the fovea. The fovea, the area of highest visual acuity, is also the carrier of the *principal visual direction* and the center to which the *secondary visual directions* of all other retinal elements relate. This relationship is stable, and this stability is what makes an orderly visual field possible. Since the localization of the secondary visual direction is not absolutely fixed in visual space but is fixed only as related to the visual direction of the fovea, its direction shifts together with the principal visual direction with changes in the position of the eye. Strictly speaking, visual directions are *subjective sensations* and cannot be drawn in a geometric construct. The objective correlates to visual directions for the use in such drawings are the *principal* and *secondary lines of directions*. A *line of direction* is defined as a line that connects an object point with its image on the retina. Helmholtz⁴⁴, vol. 1, p. 97 defined it (the direction ray) also as a line from the posterior nodal point to the retina. All

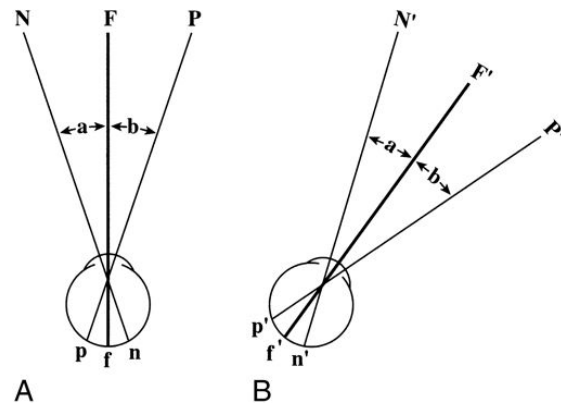


FIGURE 2-1. Relative lines of direction. A, Eye in straight-ahead position. F, principal line of direction; N and P, secondary lines of direction. B, Eye turned to right. The sheath of lines of directions shifts with the position of the eyes, but F' remains the principal line of direction and N' and P' remain the secondary lines of direction.

lines of direction therefore should meet in the anterior nodal point. For simplicity, the lines of direction are represented as straight lines in schematic drawings (Fig. 2-1).

Retinomotor Values

There is a further important result of this stable and orderly arrangement of the relative visual directions. The appearance of an object in the periphery of the visual field attracts attention, and the eye is turned toward the object so that it may be imaged on the fovea. The resulting eye movement, also called a *saccade*, is extraordinarily precise. It is initiated by a signal from the retinal periphery that transmits to the brain the visual direction, relative to the foveal visual direction, where the peripherally seen object has appeared. Corresponding impulses are then sent to the extraocular muscles to perform the necessary ocular rotation, mediated and controlled in a manner discussed in Chapter 4. This function of the retinal elements may be characterized by saying that they have a *retinomotor value*. This retinomotor value of the retinal elements increases from the center toward the periphery. The retinomotor value of the fovea itself is zero. Once an image is on the fovea, there is no incentive for ocular rotation. The fovea, then, in addition to its other functions, is also the *retinomotor center* or *retinomotor zero point*. The retinal organization described here has an important clinical application: it makes it possible to measure ocular deviations by means of the prism and cover test (see prism and cover test in Chapter 12).

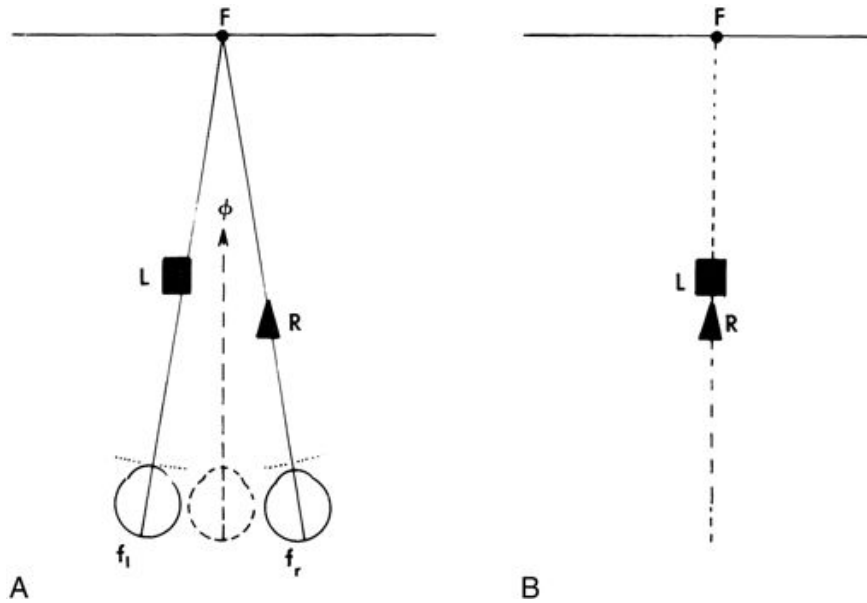


FIGURE 2-2. A, The fixation point, F, and the objects L and R all lie on the geometric lines of direction Ff_l and Ff_r of the two foveae. F, L, and R therefore are seen behind each other in subjective space in the common relative subjective visual direction of the two foveae, f , as shown in B. The imaginary “third” eye, the cyclopean eye, is indicated by dashed lines in A.

Common Relative Subjective Visual Directions

Thus far, only the single eye has been discussed. How do the relative subjective visual directions of the two eyes relate to each other?

Let a person with head erect fixate an object, F (Fig. 2-2), called the fixation point. Ff_l and Ff_r are the lines of direction of the two foveae and as such are of special importance. They are also called principal lines of direction or visual axes. Other synonyms are line of gaze, line of vision, and line of regard. If the two principal lines of direction intersect at the fixation point, it is said that there is binocular fixation. If only one principal line of direction goes through the fixation point, fixation is monocular.

As we have seen, F, fixated binocularly (see Fig. 2-2), is seen not in the direction of the principal line of direction of either eye but in a direction that more or less coincides with the median plane of the head. This holds true not only for the fixation point but also for any object point in the principal line of direction. L and R in Figure 2-2, which lie on the principal lines of direction of the left and right eyes, therefore will appear to be behind each other and in front of F, although all three are widely separated in physical space. All object points that simultaneously stimulate the two foveae appear in one and the same subjective visual direction. This direction belongs to both the

right and left foveae and therefore is called the common subjective visual direction of the foveae.

The two foveae have more than just a common visual direction; if an observer fixates F binocularly (Fig. 2-3), the object points, N and N', if properly positioned, will be seen behind each other, since the peripheral retinal points n_l and n_r have a common visual direction represented by b. What applied to n_l and n_r applies to all other retinal elements. Every retinal point or area has a partner

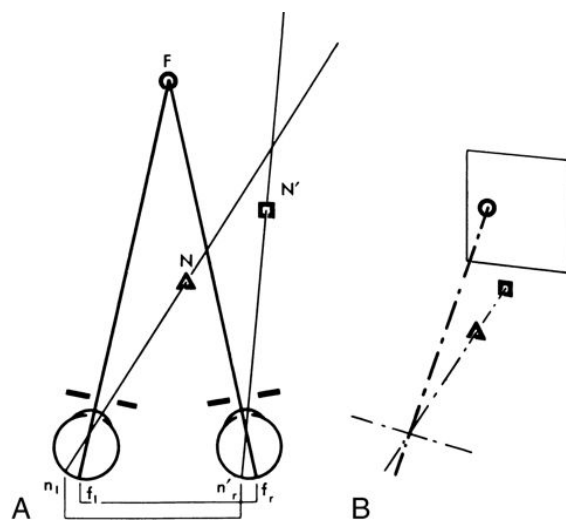


FIGURE 2-3. A, Stimulating corresponding retinal elements, objects N and N', are localized in visual space in the common relative subjective visual direction of n_l and n_r , and despite their horizontal separation are seen behind each other in B, subjective visual space. F, fixation point.

in the fellow retina with which it shares a common relative subjective visual direction.

Retinal Correspondence

Retinal elements of the two eyes that share a common subjective visual direction are called corresponding retinal points. All other retinal elements are noncorresponding or disparate with respect to a given retinal element in the fellow eye. This definition also may be stated in the following way: *corresponding retinal elements are those elements of the two retinas that give rise in binocular vision to the localization of sensations in one and the same subjective visual direction.* It does not matter whether a stimulus reaches the retinal element in one eye alone or its corresponding partner in the other eye alone or whether it reaches both simultaneously (see Figs. 2–2 and 2–3).

The common visual direction of the foveae is again of special importance. All visual directions, as has been seen, have a relative value in subjective space. The common subjective visual directions, too, have a fixed position relative only to the principal common visual direction. They determine the orientation of visual objects *relative to each other* with the principal visual direction as the direction of reference.

All common subjective visual directions can be represented in a drawing as intersecting at one point with the principal visual direction. Thus, they form a sheaf that is the subjective equivalent of the two physical eyes and may be thought of as the third central imaginary eye^{46, p. 348} or the binoculus, or *cyclopean eye*^{44, vol. 3, p. 258} (see Fig. 2–2). If the principal subjective visual direction lies in the median plane of the head, the physical correlate of the point of intersection of the visual directions, their origin, would be approximately in the area of the root of the nose (whence “cyclopean” eye).

Corresponding retinal elements arranged in horizontal and vertical rows provide the subjective vertical and horizontal meridians. Meridians that include the visual direction of the fovea are the principal corresponding horizontal and vertical meridians.

The existence of corresponding retinal elements with their common relative subjective visual directions is the essence of binocular vision. It may be called the *law of sensory correspondence* in analogy with the law of motor correspondence, which is discussed in Chapter 4.

The oneness of the directional sensory responses originating in each eye is impressively demonstrated by means of afterimages. If one creates an afterimage on the retina of one eye, it will appear in the binocular field of view in the common visual direction of the stimulated retinal area and in its nonstimulated partner in the other eye. It is difficult, indeed almost impossible, for the observer to judge which eye carries the afterimages. It will continue to be seen and localized in the same direction, whether the eyes are open or closed or whether the stimulated eye is closed and the other eye held open. In this latter situation some authors^{19, 55} have spoken of an *afterimage transfer*. This term is a misnomer as nothing is being transferred.⁴³

If a horizontal afterimage is formed in one eye by a strong horizontal light stimulus, leaving the fovea unstimulated, and if a similar vertical afterimage is created in the other eye, the resulting visual percept is an afterimage in the form of a cross with a gap in its center.^{10, 49, p. 158} The gap is seen because of the lack of stimulation in the foveae. The center of the horizontal and vertical afterimages is consequently a single spot localized in the principal common visual direction. The horizontal and vertical legs of the afterimages are oriented accordingly (Fig. 2–4). It is of great importance to understand clearly that *the appearance of the afterimage cross is independent of the position of the eyes.* Once a lasting stimulus, such as an afterimage, has been imparted, its localization in subjective space depends solely on the visual direction of the retinal elements involved. One may topically anesthetize one eye and move it passively with a forceps or push it in any direction with one’s finger—the cross remains a cross. No change in the relative localization of the vertical and horizontal afterimage will occur. The use of afterimages has an important place in the diagnosis of anomalous retinal correspondence (see Chapter 13). The principles underlying afterimage testing must be fully understood to guard against gross errors in interpretation.

Sensory Fusion

Sensory correspondence explains binocular single vision or sensory fusion. The term is defined as *the unification of visual excitations from corresponding retinal images into a single visual percept, a single visual image.* An object localized in one and the same visual direction by stimulation

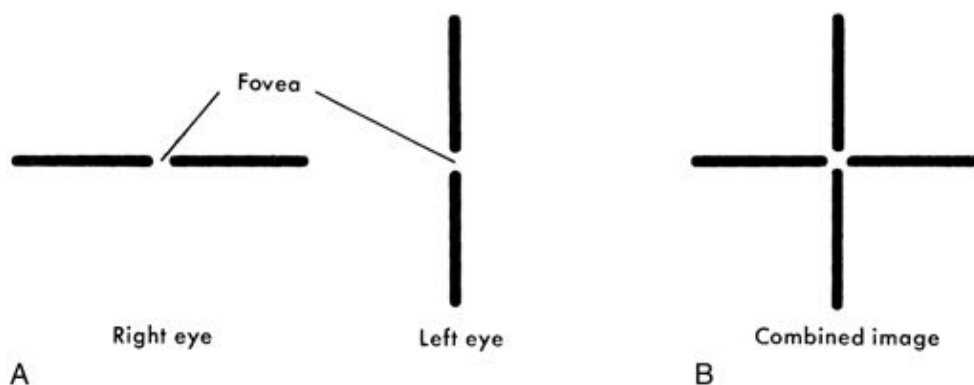


FIGURE 2-4. A, Afterimages produced in the right and left eye, respectively. The fovea is represented by the break in the afterimage. B, The combined binocular afterimage forms a cross. The two gaps appear single.

of the two retinas can only appear as one. An individual cannot see double with corresponding retinal elements. *Single vision is the hallmark of retinal correspondence.* Put otherwise, the stimulus to sensory fusion is the excitation of corresponding retinal elements.

Since both the central and peripheral parts of the retina contribute fusible material, it is misleading to equate sensory fusion with “central” fusion (as opposed to “peripheral” or motor fusion). Fusion, whether sensory or motor, is always a central process (i.e., it takes place in the visual centers of the brain).

For sensory fusion to occur, the images not only must be located on corresponding retinal areas but also must be sufficiently similar in size, brightness, and sharpness. Unequal images are a severe sensory obstacle to fusion. Obstacles to fusion may become important factors in the etiology of strabismus (see Chapter 9). Differences in color and contours may lead to retinal rivalry.

The simultaneous stimulation of noncorresponding or disparate retinal elements by an object point causes this point to be localized in two different subjective visual directions. An object point seen simultaneously in two directions appears double or in diplopia. *Double vision is the hallmark of retinal disparity.* Anyone with two normal eyes can readily be convinced of this fact by fixating binocularly an object point and then displacing one eye slightly by pressure from a finger. The object point, which appeared single before pressure was applied to the globe, is now seen in diplopia because it is no longer imaged on corresponding retinal areas. Qualifications that must be made about equating disparate retinal elements and diplopia are discussed on page 20. Paradoxical diplopia with ordinarily correspond-

ing elements in cases of strabismus is discussed in Chapter 13.

Motor Fusion

The term motor fusion refers to the ability to align the eyes in such a manner that sensory fusion can be maintained. The stimulus for these fusional eye movements is retinal disparity outside Panum’s area and the two eyes are moving in opposite directions (vergences; see Chapter 4). Unlike sensory fusion, which occurs between corresponding retinal elements in the fovea and the retinal periphery, *motor fusion is the exclusive function of the extrafoveal retinal periphery.* No stimulus for motor fusion exists when the images of a fixated visual object fall on the fovea of each eye.

Retinal Rivalry

When dissimilar contours are presented to corresponding retinal areas, fusion becomes impossible. Instead, retinal rivalry may be observed. This phenomenon, also termed binocular rivalry, must be clearly distinguished from local adaptation, or Troxler’s phenomenon.⁶⁷

If a person looks into a stereoscope at two dissimilar targets with overlapping nonfusible contours, first one contour, then the other will be seen, or mosaics of one and the other, but not both contours simultaneously. In Figure 2-5, taken from Panum,⁷⁸ each eye sees a set of oblique lines, one going from above left to below right, seen by the left eye, and another set going from above right to below left, seen by the right eye. When observed in a stereoscope, these lines are not seen as crossing lines but as a changing pattern of

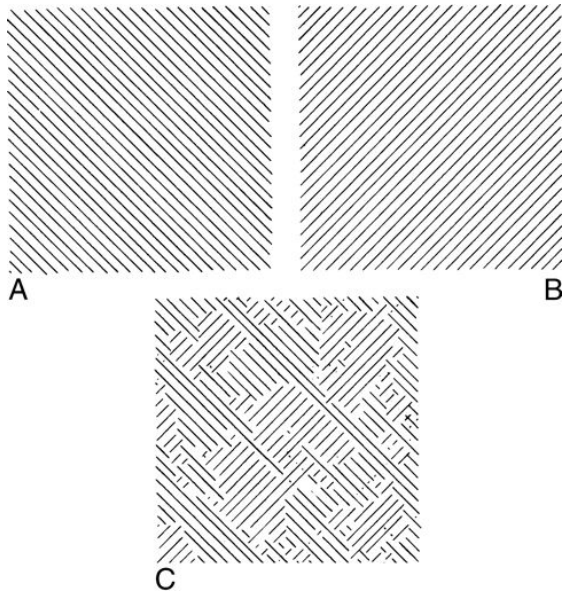


FIGURE 2-5. Rivalry pattern. *A*, Pattern seen by the left eye. *B*, Pattern seen by the right eye. *C*, Binocular impression. (From Panum PL. *Physiologische Untersuchungen über das Sehen mit zwei Augen*. Kiels. Germany, Schwerssche Buchhandlung, 1858, pp. 52 ff.)

patches of oblique lines going in one or the other direction.

Binocular rivalry may also be produced by uniform surfaces of different color (color rivalry) and unequal luminances of the two targets. Many combinations of contours, colors, and luminances have been studied exhaustively since the days of Panum,⁷⁸ Fechner,⁴¹ Helmholtz,⁴⁴ and Hering.⁴⁵ Review of the literature may be found in the reports of Hofmann,⁴⁹ Ogle,^{76, p. 409} and Levelt.⁶⁷

It is of interest that it takes a certain buildup of time (150 ms) before dissimilar visual input to the eyes causes binocular rivalry. Dichoptic stimuli were perceived as “fused” when presented for shorter periods.⁶³

The phenomenon of retinal rivalry is basic to binocular vision and may be explained as follows. Simultaneous excitation of corresponding retinal areas by dissimilar stimuli does not permit fusion; but since such excitations are localized in the same visual direction and since two objects localized in the same place give rise to conflict and confusion, one or the other is temporarily suppressed. Which of the two is suppressed more depends on the greater or lesser dominance of one eye rather than on the attention value of the visual object seen by each eye.¹⁷ In other words, it is the eye and not the stimulus that competes for dominance under a wide range of conditions. Stimulus rivalry occurs

only within a limited range of spatial and temporal parameters.⁵⁹

The extent to which true fusion or monocular alternation in the binocular field governs normal visual activity—in other words, the significance of the rivalry phenomena for the theory of binocular vision—is considered on page 31.

It is at once clear that rivalry phenomena, or rather their absence, must in some fashion be related to what is known as suppression in strabismic patients. Suppression is discussed in detail in Chapter 13. Here we state only that constant foveal suppression of one eye with cessation of rivalry leads to complete sensory dominance of the other eye, which is a major obstacle to binocular vision. Return of retinal rivalry is a requisite for reestablishment of binocular vision.

The retinal rivalry phenomenon has been explained in neurophysiologic terms by the presence of separate channels for the right and left eyes that compete for access to the visual cortex. A third binocular channel is activated only by fusible input.^{27, 102} Because of this competition and the inhibition elicited, only fragments of the image seen by each eye are transmitted to the striate cortex in the case of nonfusible binocular input. Competitive interaction occurs not only in the primary visual cortex¹⁴ but continues at several afferent levels of the visual pathway, well after the inputs to the two eyes have converged.⁶⁴

Objective (Physical) and Subjective (Visual) Space

Certain terminological differentiations made earlier in this chapter will not have escaped the notice of the attentive reader. For example, *location* of an object point in physical (objective) space was separated from its *localization* in visual (subjective) space. The (objective) lines of direction determine which retinal area will be stimulated; their (subjective) counterpart, the visual directions, determine the direction in which the object will be seen in visual space.

Clear distinctions between physical space and its subjective counterpart are essential both in thinking about spatial orientation and in the expression of that thinking. Failure to do so has been the source of much confusion and error in the description of normal and abnormal binocular vision. The naive observer gives little thought to vision. His thoughts are for the things he sees. He takes it for granted that he sees things as they are

and where they are. This instinctive approach is deeply ingrained in all of us, and we act in accordance with it in practical life. In fact, however, we do not see physical objects. What takes place is that energy in the form of light waves is absorbed by photosensitive receptors in the retina and is transformed into other forms of energy. Eventually this process leads in some manner to events occurring in our consciousness; we call this seeing. Thus, vision results from the active transformation of the excitations produced initially in our retinas by energy emanating from a narrow band within the electromagnetic spectrum. In consciousness this builds up our world of light, color, and spatial orientation.

This view of vision is not shared by everyone. Some maintain that events in certain parts of the brain are synonymous with vision and that what we experience in consciousness is an epiphenomenon. Others state that vision is nothing more than an overt response of the organism to stimulation, a form of behavior, but all concede that we do not see physical objects. What occurs in our brain are physicochemical and electrical events. What we experience in our consciousness are sense data. In joining one sense datum to other sense data derived from the same or from different receptor organs, we proceed from sensation to perception. Relating these sense data to past experience is enormously complex, and each new sense datum becomes either meaningful or not meaningful.

The sense datum is qualitatively different from and is not commensurate with the physical process to which it is correlated. This is immediately clear when speaking of colors. Neither radiant energy of 640 nm nor the processes evoked by this radiant energy in the retina, the optic nerve, or the brain cells is "red." Red is a sensation. It is not immediately clear that similar considerations apply to the perception of space. That they indeed do apply will be evident throughout this book.

The scientific or philosophical validity of the various concepts of the nature of sensation and perception and of "reality" will not be argued here. The question under consideration is not which view is "true" or "correct"—that is, verifiable—but which one gives the best description of the phenomena and is most likely to help in furthering the understanding and the advancement of clinical work. In this respect, the most useful view is that incorporated into the methodology termed *exact subjectivism* by Tschermak-Seysenegg.⁹⁴ This view recognizes objective and

subjective factors in vision, that *physical space*, of which we and our visual system are a part, and *subjective space* are built up from sense data.

The subjective space is private to each one of us. A color-normal person can understand but never experience how a color-blind person sees the world, nor can a color-blind person ever experience colors as a color-normal person does. Similarly, a person with a normal sensorimotor system of the eyes may be able to understand but can never experience certain phenomena that people with abnormal sensorimotor systems may experience in their subjective space (see Chapter 13).

The sensations of color and spatial localization are not anarchic, however. Certain physical processes are always correlated with certain sensations and perceptions. Known changes introduced into the environment produce regular changes in sensations and perceptions. These lawful relations allow us to make quantitative determinations. We have no yardstick for the sensation "red," and we have no yardstick for subjective space; but we can characterize them quantitatively by changes in the environment with which they are correlated.

Each stimulus has certain characteristics: luminance, wavelength, extent, and location in physical space. All these parameters, singly and combined, have an effect on the visual system; but how a colored object appears does not depend solely on the wavelength it emits or reflects but also on the state of the eye, particularly on the color to which it has been previously adapted. The brightness of a percept depends not only on the luminance of the stimulus but also on the state of the eye and its responsiveness. For instance, a stimulus that is below threshold for an eye adapted to bright light may appear very bright if the eye is adapted to darkness.

The ability of the eye to adapt to varying levels of illumination is involved also in one of the *constancy phenomena*. A white sheet of paper appears to be white not only at noon but also at twilight, although it reflects much more light into the eye at noon. The smaller amount of light is as effective in the dark-adapted eye as is the greater amount of light in the light-adapted eye. Up to a certain distance the size of a man remains constant as he walks away from us, although the retinal image grows smaller (size constancy). Eventually, however, he will appear smaller, and as he recedes farther he shrinks to a point and finally disappears altogether.

Most important, no stimulus is ever isolated. It

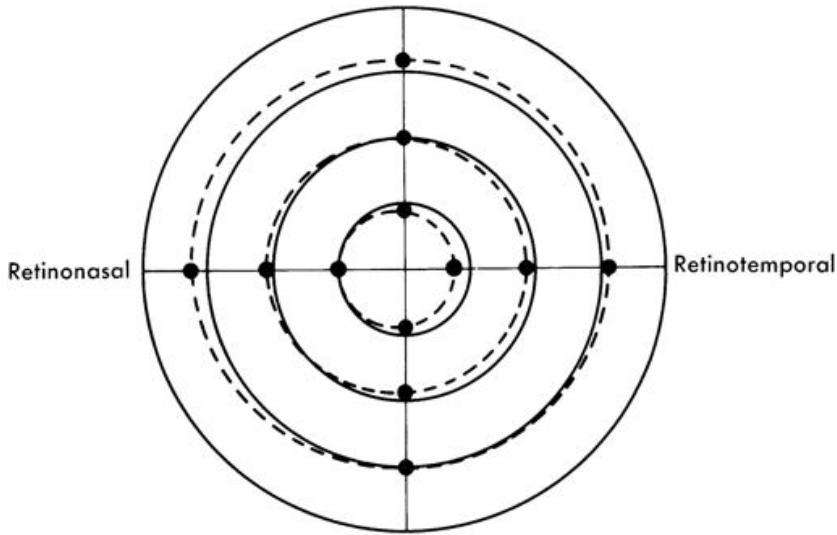


FIGURE 2-6. Retinal discrepancies. Subjective appearance of circles (broken lines) contrasts with objective circle (solid lines). (From Tschermak-Seysenegg A Von: Der exacte Subjectivismus in der neueren Sinnesphysiologie, ed 2, Vienna, Emil, Haim, 1932.)

has a surround, and this surround also has stimulus qualities. The effects of the surround, especially at the borders, lead to the phenomena of induction and physiologic contrast, which play a great role in visual discrimination and color vision.

Where a visual object is localized in subjective space relative to other objects does not depend on the position of that object in physical space. It depends on the visual direction of the retinal area

that it stimulates. An object may be located in physical space at any place. So long as it stimulates the foveae it is seen in their common subjective visual direction.

Discrepancies of Objective and Subjective Metrics

The difference between the metric of physical space and the metric of the eye is emphasized by

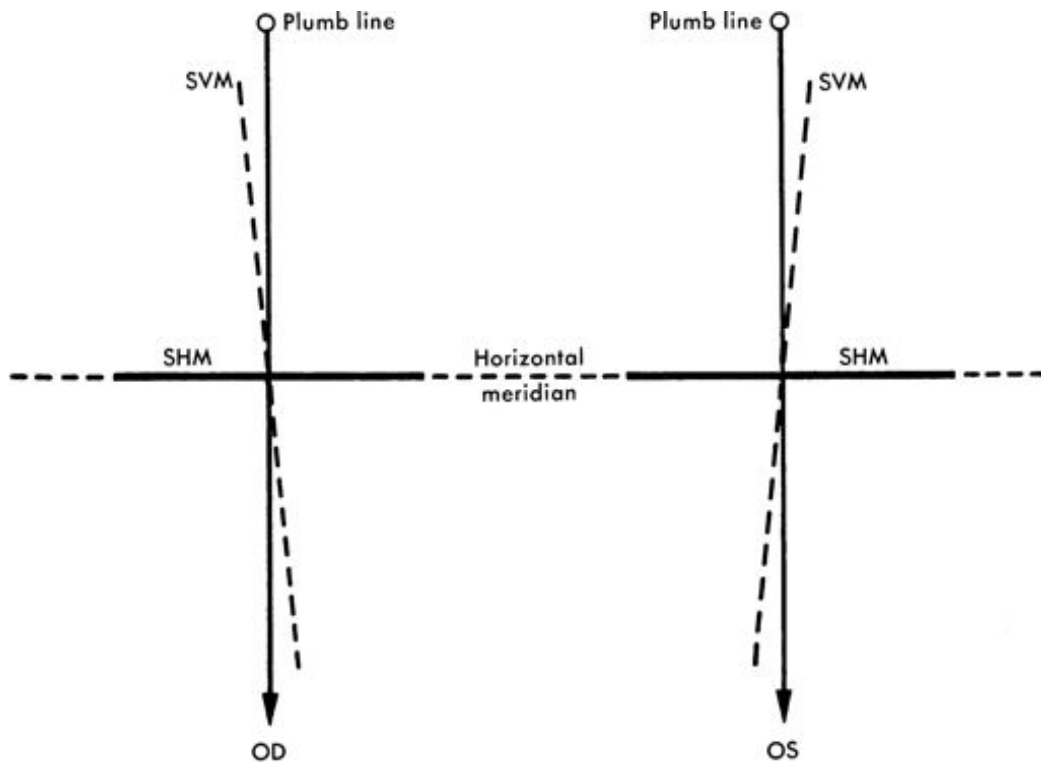


FIGURE 2-7. Discrepancies between subjective vertical meridian, SVM, and plumb line in the two eyes. No discrepancy exists between the subjective horizontal, SHM, and the objective horizontal meridians. (From Tschermak-Seysenegg A Von: Der exacte Subjectivismus in der neueren Sinnesphysiologie, ed. 2, Vienna, Emil Haim, 1932.)

the existence of so-called visual discrepancies. If one attempts to bisect a monocularly fixated line in an arrangement that excludes other visual clues from the field, a constant error is detected. The line is not divided into two objectively equal line segments. If placed horizontally, the line segment imaged on the nasal side of the retina, that is, the one appearing in the temporal half of the field, is larger than the temporally imaged retinonasal line segment. This is the famous partition experiment of Kundt, a German physicist of the mid nineteenth century.^{95, p. 137} The opposite phenomenon, described by Münsterberg,⁷³ occurs only rarely. Similarly, the lower line segment (imaged retino-superiorly) is shorter than the upper (retinoinferior) segment. In subjective space, therefore, the equivalent of a true circle fixated centrally is a somewhat irregular round figure, the smallest radius of which points outward. Accordingly, a subjectively true circle does not correspond to a true circle in physical space (Fig. 2-6). In general, the discrepancies in the two eyes are symmetrical. They compensate each other, and the partition of a line into two equal segments is more nearly correct in binocular fixation.

There are also directional discrepancies that result in a deviation of the subjective vertical from the objective vertical. A monocularly fixated plumb line shows a definite disclination with the top tilted templeward. This disclination is, as a rule, approximately symmetrical in the two eyes (Fig. 2-7). In general, the angle of disclination is not greater than 4° to 5° , but it has been reported in isolated cases to be as high as 14° .

The discrepancies described are evidence that the retinal elements that physically have the same eccentricity in the two eyes are not equivalent functionally. This is the basis of the Hering-Hillebrand horopter deviation (see p. 18).

Distribution of Corresponding Retinal Elements

The Foveae as Corresponding Elements

That the foveae have a common subjective visual direction is demonstrated by Hering's fundamental experiment,^{46, p. 343} which in its classic simplicity is reminiscent of a bygone day when basic discoveries in physiologic optics could be made with a candle, some cardboard, and a few strings and pulleys.

Place yourself in front of a closed window with an open view. Close the right eye and look for an outstanding, somewhat isolated object, say, a tree. Make an ink mark on the window pane at about the midline of your head that will cover a spot on the tree. Now close your left eye, open the right eye without moving your head, and fixate the ink spot. Observe what object it covers in the landscape, say, a chimney on a house. Open both eyes and fixate the ink spot binocularly. You will note that the chimney, the tree, and the ink spot appear in a line behind each other, approximately in the midline of your head. All those objects are seen in the common visual direction of the two foveae, even though they may actually be widely separated in physical space (Fig. 2-8). If you now place the point of a fine object (e.g., the tip of a pencil) between one eye and the ink spot, it will also appear in line with the objects seen outside

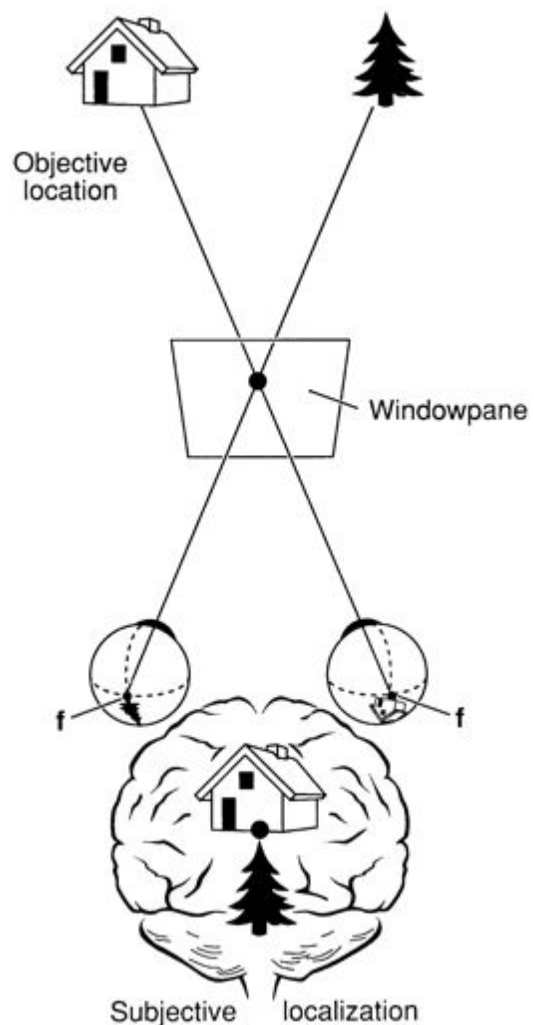


FIGURE 2-8. Hering's fundamental experiment. (Modified from Ogle KN: *Researches in Binocular Vision*. Philadelphia, WB Saunders, 1950.)

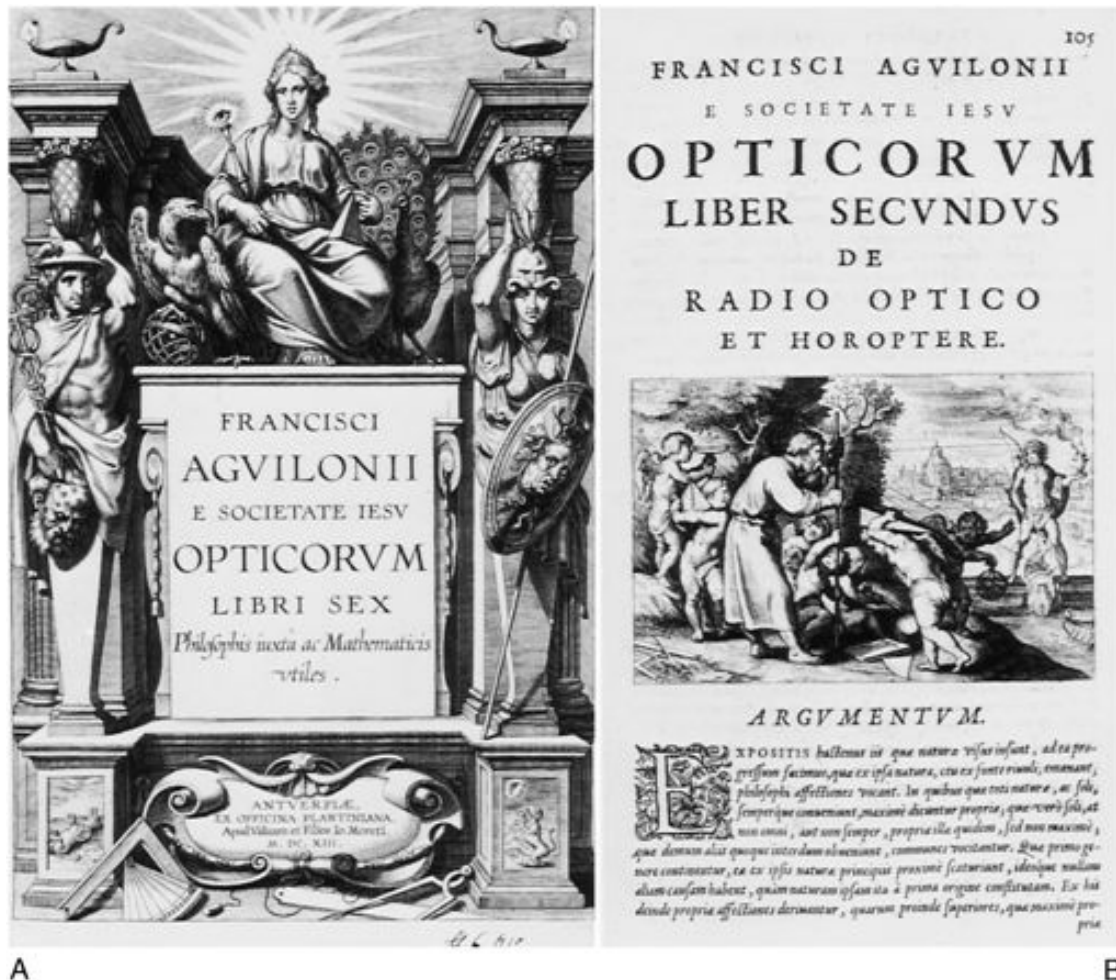


FIGURE 2-9. A, Title page of the volume by Francis Aguilonius, S.J., *Six Books on Optics Useful to Philosophers and Mathematicians*, published in Antwerp, 1613. B, First page of book II of Aguilonius' volume, which deals with the horopter $\times 30$.

the window. This simple experiment shows convincingly the discrepancies that may exist between subjective and objective physical space.

The Horopter

Determining the distribution of the corresponding retinal elements throughout the retina is less readily achieved. For a long time the idea prevailed that the distribution of the corresponding retinal elements was strictly geometric. If this were indeed true, then corresponding points would be retinal elements having the same horizontal and vertical distance from the fovea in the right and left halves of the retinas. The following mental experiment clarifies the concept. Place the two retinas one on the other so that the two foveae and the geometric horizontal and vertical meridians coincide. Imagine a needle placed through the two retinas anywhere within the area subserving the field of binocular vision. The needle should strike

corresponding points in the two retinas. On the assumption that this is in fact the case, the horopter was determined theoretically.

Horopter is a very old term, introduced in 1613 by Aguilonius¹ in his book on optics (Fig. 2-9) even though the basic concept of the horopter had been known since the times of Ptolemy.³⁶ In modern usage it is defined as the locus of all object points that are imaged on corresponding retinal elements at a given fixation distance.

The determination of the total horopter surface was approached mathematically by Helmholtz⁴⁴, vol. 3, pp. 460 ff, on the basis of assumptions about the geometric distribution of the corresponding retinal elements and about the position of the subjective vertical meridians. For our purpose, we need be concerned only with the horizontal distribution of corresponding retinal elements and to consider the longitudinal horopter curve. This is the line formed by the intersection of the visual plane (with head erect and eyes fixating a point straight

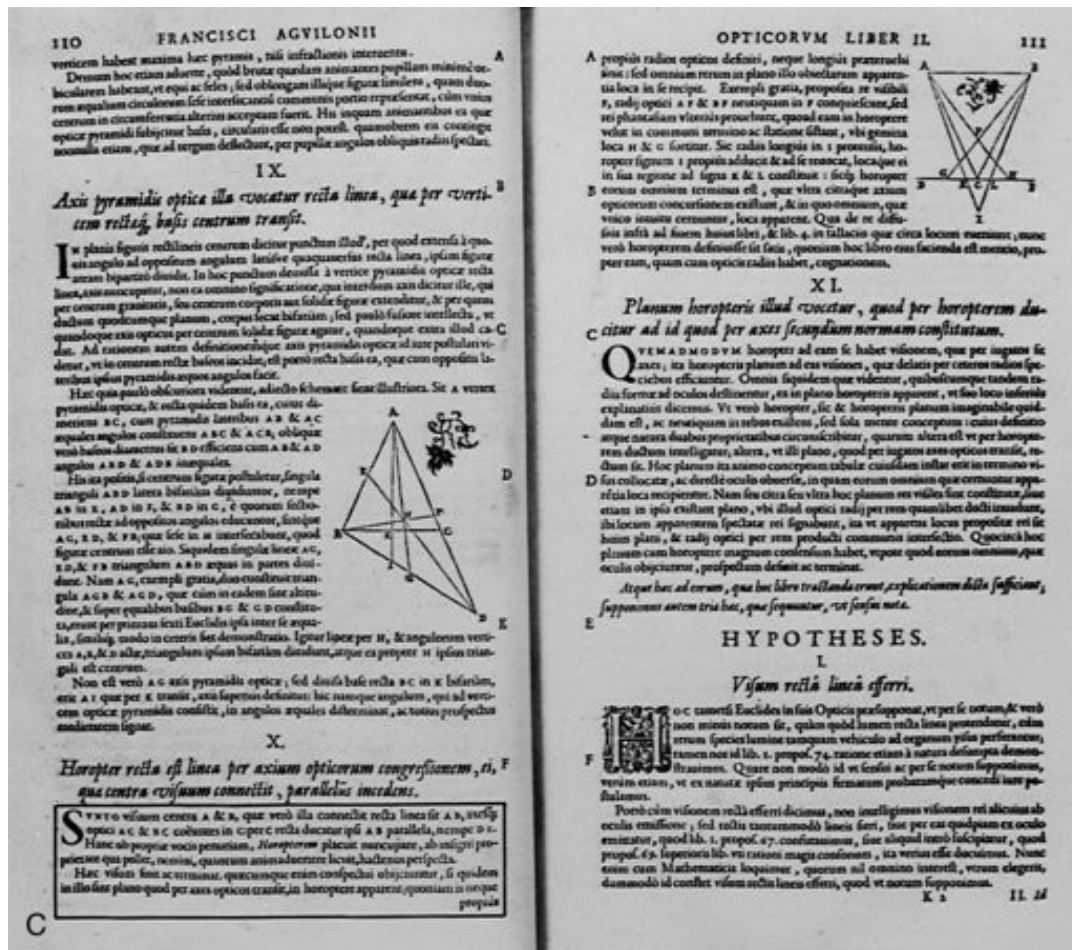


FIGURE 2-9 Continued. C, Pages 110 and 111 of the volume of Aguilonius in which he introduces the term *horopter* and defines it as the line that delimits and bounds binocular vision. The pertinent paragraph is indicated by a box. (From the copy of the book of Aguilonius at Dartmouth College's Baker Library. Courtesy Dartmouth College Photographic Service, Hanover, NH.)

ahead in symmetrical convergence) with the horopter surface.

The term *longitudinal horopter* is an inadequate translation of the German term *Längshoropter*. Boeder, in his 1952 translation of Tschermak-Seysenegg's *Einführung zur physiologischen Optik* (Introduction to Physiological Optics), suggested the term *horopter of horizontal correspondence*.⁹⁵ p. 134 This much better but somewhat cumbersome term has not found general acceptance. The term longitudinal horopter refers to the locus in space of object points imaged on "subjective longitudes" of the retina.

VIETH-MÜLLER CIRCLE. If corresponding points have a geometrically regular horizontal distance from the two retinas, the longitudinal horopter curve would be a circle passing through the center of rotation of the two eyes and the fixation point (Fig. 2-10). This would be true because of the theorem of inscribed circles any lines drawn from

two points on a circle to any other pair of points on its circumference include equal angles, as shown in the insert (see Fig. 2-10). This was first pointed out by Vieth⁹⁹ and later taken up by Müller,⁷² and this circle, which is the theoretical or mathematical horopter curve, is also known as the Vieth-Müller circle (see Fig. 2-10).

EMPIRICAL HOROPTER CURVE. By actual experimental determinations of the horopter curve, Hering^{45, 46} and his pupil Hillebrand⁴⁷ could show that the Vieth-Müller circle does not describe the longitudinal horopter. The empirical horopter curve is flatter than the Vieth-Müller circle (see Fig. 2-10). This means that the distribution of the elements that correspond to each other is not the same in the nasal and temporal parts of the two retinas (e.g., the right half of each retina). The characteristics of the horopter for each individual vary within certain limits; each person has his personal horopter.

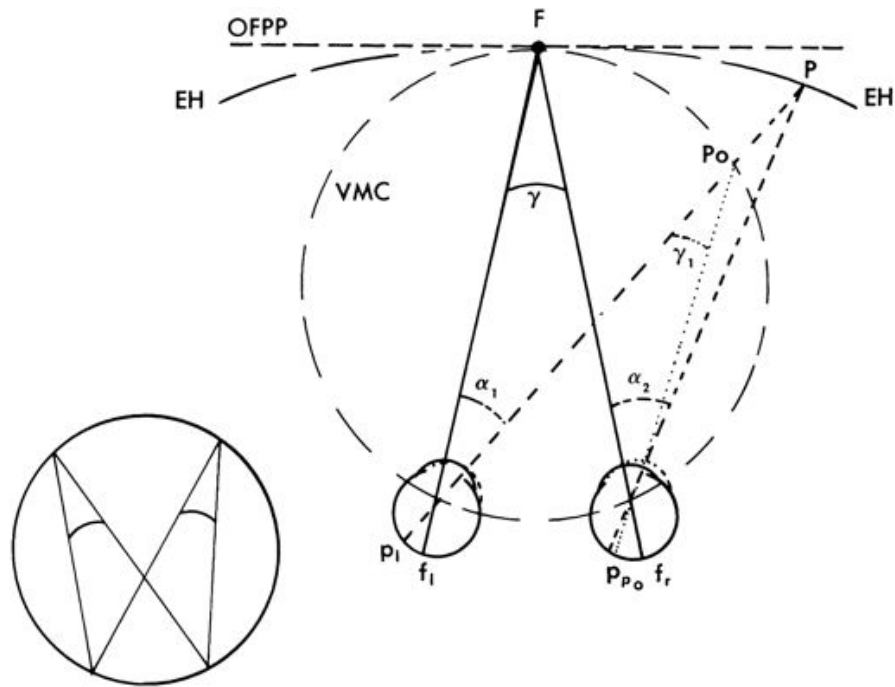


FIGURE 2-10. Vieth-Müller circle. VMC, empirical horopter; EH, objective frontoparallel plane; OFPP, fixation point; F, inset, law of inscribed circles. Object P on EH is seen singly, but object PO on VMC elicits double vision because of discrepancies between the empirical and theoretical horopter (see text).

The discrepancy between the theoretical horopter (the Vieth-Müller circle) and the empirically established horopter curve (the so-called Hering-Hillebrand horopter deviation) might be attributed to disturbing optical properties of the ocular media. However, Tschermak-Seysenegg⁹⁵ has shown conclusively that this is not the case.

A great deal of work has been expended on experimental studies of the horopter. Interested readers are referred to the books by Tschermak-Seysenegg⁹⁵ and Ogle.⁷⁵ Only the broad outlines of the information resulting from this work and the experimental techniques are discussed on page 28, but first other phenomena of binocular vision must be presented.

Physiologic Diplopia

All object points lying on the horopter curve stimulate corresponding retinal elements. By definition, all points on the horopter curve are seen singly. Also by definition, all points not lying on the horopter curve are imaged disparately and, with certain qualifications, are seen double. The diplopia elicited by object points off the horopter is called physiologic diplopia.

Physiologic diplopia can be readily demonstrated to anyone with normal binocular vision.

Hold a pencil at reading distance in front of your head in its midplane and select a conspicuous, somewhat isolated object on the wall in line with the pencil. Fixate the more distant object, and the pencil will be seen double. Shut alternately one eye and then the other. The contralateral double image of the pencil will disappear; that is, the image on the left will disappear if the right eye is shut, and the one on the right will disappear if the left eye is shut. In other words, when fixating a distant object, a nearer object is seen in crossed (heteronymous) diplopia. Crossed diplopia is explained by the fact that the nearer object is seen in temporal (crossed) disparity with reference to its fovea (or to a corresponding element in peripheral vision if the nearer object is located in the periphery of the visual field). This is shown in Figure 2-11, A.

If one now fixates the pencil binocularly it will be seen singly, but the more distant object doubles up. By again alternately closing each eye, one finds that the ipsilateral double image vanishes. There is uncrossed (homonymous) diplopia because the more distant object is imaged in nasal (uncrossed) disparity (Fig. 2-11, B).

Clinical Significance

Physiologic diplopia, a fundamental property of binocular vision, has a twofold clinical significance.

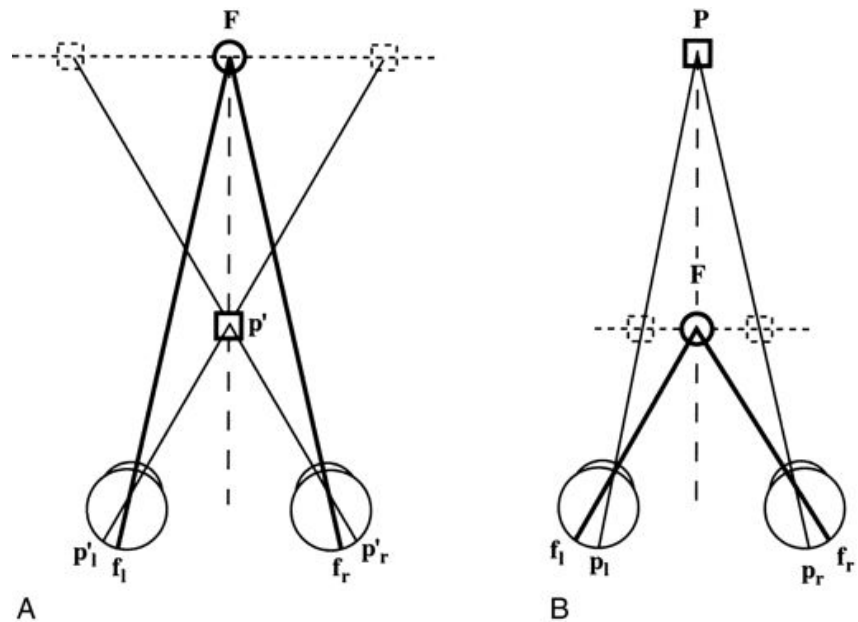


FIGURE 2-11. Physiologic diplopia. *A*, Crossed (heteronymous) diplopia of the object p' , closer than the fixation point F , imaged in temporal disparity. *B*, Uncrossed (homonymous) diplopia of the object P , more distant than the fixation point F and imaged in nasal disparity.

Occasionally a person accidentally will become aware of physiologic diplopia. Since double vision must appear as an abnormal situation, the individual likely will seek the help of an ophthalmologist. If the ophthalmologist cannot establish the presence of an acute paresis of an extraocular muscle or any of the other causes of diplopia mentioned in this book, one must conclude that all the patient has experienced is physiologic double vision. The ophthalmologist must attempt to explain to the patient that physiologic diplopia is a characteristic of normal binocular vision and evidence that the patient enjoys normal cooperation of the two eyes. This is not always easy. Apprehensive, neurotic patients may not accept the explanation and will reinforce the annoyance by constantly looking for a second image "that should not be there." Many patients have spent considerable amounts of money looking for an ophthalmologist who will finally rid them of their diplopia.

This is the undesirable clinical aspect of physiologic diplopia. The desirable use that can be made of physiologic diplopia is both diagnostic and therapeutic. In diagnosing binocular cooperation, the presence of physiologic diplopia indicates that the patient is capable of using both eyes in casual seeing and presumably does so. In orthoptic treatment of comitant strabismus, physiologic diplopia is an important tool (see Chapter 24).

Suppression

Physiologic diplopia is not just a trick produced in vision laboratories. It is a phenomenon inherent

to normal binocular vision. The question arises, why are we not always aware of diplopia?

From the first moment in which binocular vision is established, we become accustomed or conditioned to the arrangements provided for binocular seeing and hence to physiologic diplopia. We learn how to disregard it, and unless some abnormal process interferes we are never aware of diplopia.

If a patient acquires an acute lateral rectus paresis in one eye, the eye turns in. An object point fixated by the other eye is now imaged on a nasally disparate area in the deviated eye. Consequently, the patient experiences uncrossed diplopia. If he or she has acquired a medial rectus paralysis, the eye turns out and the fixation point is imaged in temporal disparity. The patient has crossed diplopia. These forms of diplopia in patients with acute paralytic strabismus are to be expected from what is known about physiologic diplopia and are a *normal* response of the sensory system to an abnormal motor situation.

As a rule, patients with comitant strabismus of early onset do not see double in spite of the relative deviation of the visual lines. Visual impressions that should be transmitted to the brain by one eye may be suppressed. The ability to disregard physiologic diplopia must be distinguished from suppression, an active, inhibitory mechanism. The former is a psychological, the latter a neurophysiologic process. The ability to selectively exclude certain unwanted visual impulses from entering consciousness (the ability to disregard or suppress them) is important in normal

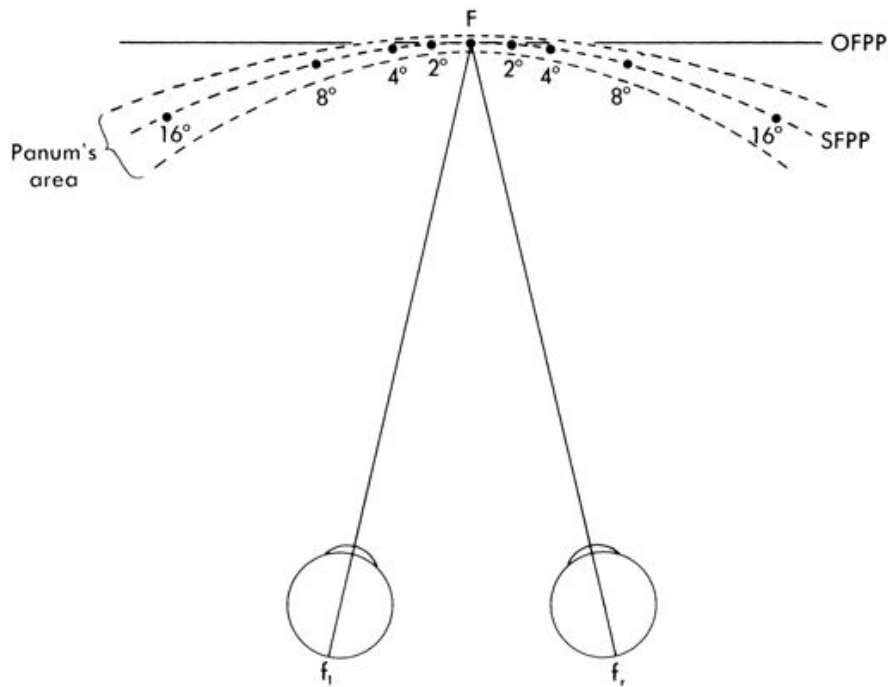


FIGURE 2-12. Panum's area as determined on the horopter instrument. F, fixation point; OFPP, objective frontoparallel plane; SFPP, subjective frontoparallel plane (horopter).

and abnormal vision and is given a good deal of attention in the clinical parts of this book.

Panum's Area of Single Binocular Vision

The statement has been made that object points lying on the horopter are seen singly, whereas points off the horopter are seen double. The first part of this statement always holds true; the second part needs qualification.

If under appropriate experimental conditions, one fixates a fixed vertical wire with a number of movable vertical wires arranged to each side of the fixation wire (p. 28), all wires are seen singly if they are placed on the horopter. If one of the wires seen in peripheral vision is moved, one will notice that this wire can be displaced a certain short distance, forward or backward, away from the horopter position without being seen double. Since the wires must be imaged on disparate retinal meridians as soon as they are displaced from the horopter, it follows that within a narrow band around the horopter stimulation of disparate retinal elements transmits the impression of single vision. Panum,⁷⁸ the Danish physiologist, first reported this phenomenon, and the region in front and back of the horopter in which single vision is present is known as Panum's area of single binocular

vision or Panum's fusional area (Fig. 2-12). Not only is single vision possible in Panum's area but visual objects are seen stereoscopically, that is, in depth.

According to classic views the horizontal extent of these areas is small at the center (6 to 10 minutes near the fovea) and increases toward the periphery (around 30 to 40 minutes at 12° from the fovea). The vertical extent has been variously assessed by different observers.^{75, p. 66} However, more recent research suggests that Panum's area is considerably larger. Moving random-dot stereograms, which are most effective in retaining fusion while the disparity is increased, have shown that disparities of as much as 2° to 3° can be fused.^{40, 54, 79}

The increase of Panum's area toward the periphery may be related to anatomical and physiologic differences known to exist between the monosynaptic foveal cone system and the rod and cone system of the periphery. It parallels the increase in size of the retinal receptive fields. Note also the ability of summation of the retinal periphery, an ability that is virtually absent in the fovea in the photopic state (see Chapter 13). The horizontal extent of Panum's area can be reduced to some degree by training.

The question is sometimes asked whether Panum's area is in (physical) space outside the eye or in the retina. This question is obviously mean-

ingless. This “area” represents the subjective response to a specific stimulus situation eliciting single visual impressions. The areas in physical space (location of object points and their images on the retinas) simply define operationally the regions within which binocular single vision may be obtained with stimulation of disparate retinal areas.

Fixation Disparity

A physiologic variant of normal binocular vision exists when a minute image displacement, rarely exceeding several minutes of arc of angle, occurs within Panum’s area while fusion is maintained. Although this phenomenon was demonstrated in earlier experiments,^{4, 50} Ogle and coworkers⁷⁷ were the ones who clarified the nature of this condition and coined the term *fixation disparity*.

Fixation disparity can be elicited experimentally by presenting in a haploscopic device visual targets that appear as mostly similar and some dissimilar markings to the eyes. Such an experimental arrangement, from a paper by Martens and Ogle,⁷⁰ is shown in Figure 2–13. The periphery of the screen, seen by each eye, containing identical visual information is fused. At the center of the screen two vertical test lines are arranged so that the lower one is seen only by the right eye and the upper one only by the left eye. The position of one of these lines can be varied so that during the test the lines can be adjusted until they appear aligned to the observer. The actual separation of the lines, expressed in minutes of arc of subtended

angle, is the fixation disparity. Whether fixation disparity is an interesting but clinically irrelevant laboratory finding or whether it represents the first step between orthophoria and microtropia is a matter of debate.³²

The use of the fixation disparity method to measure the accommodative convergence–accommodation (AC/A) ratio is described in Chapter 5, and its possible relationship to the etiology and pathophysiology of heterophoria is discussed in Chapter 9.

Stereopsis

When the experiment using fixation wires is performed to determine Panum’s area and the wires seen peripherally are moved backward and forward, they do not double up so long as they remain within Panum’s area of single binocular vision. As soon as they are moved out of the horopter position, however, they appear in front or in back of the fixation wire and are then seen stereoscopically. *Stereopsis* is defined as the relative ordering of visual objects in depth, that is, in the third dimension. This extraordinarily intriguing quality of the visual system requires a rather detailed analysis.

Relative localization in the third dimension in depth parallels that of visual objects in the horizontal and vertical dimensions. The ability to perceive relative depth allows one to localize the peripherally seen wires just alluded to in front or in back of the fixation wire, and it is this ability that permits one to perceive a cube as a solid.

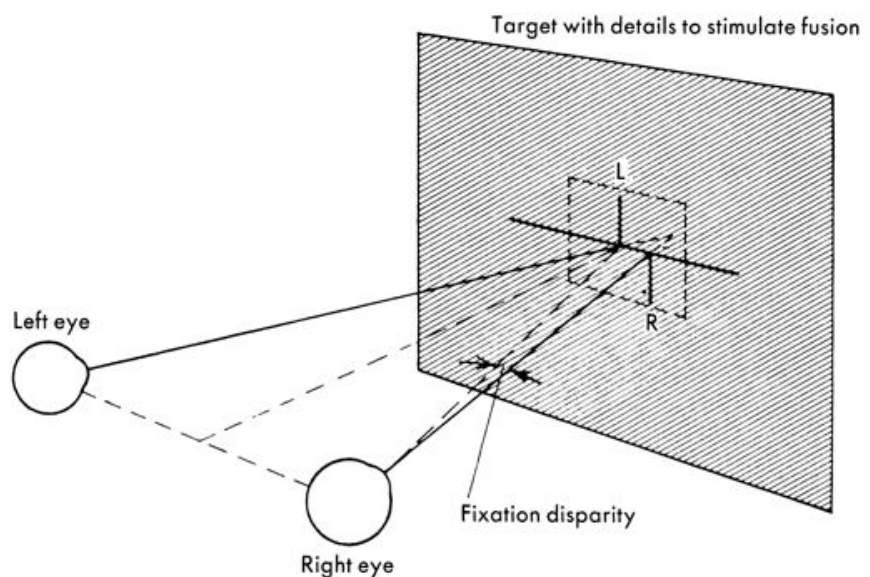


FIGURE 2–13. Testing arrangement to determine fixation disparity. (From Martens TG, Ogle KN: Observations on accommodative convergence, especially its non-linear relationships. *Am J Ophthalmol.* 47:455, 1959.)

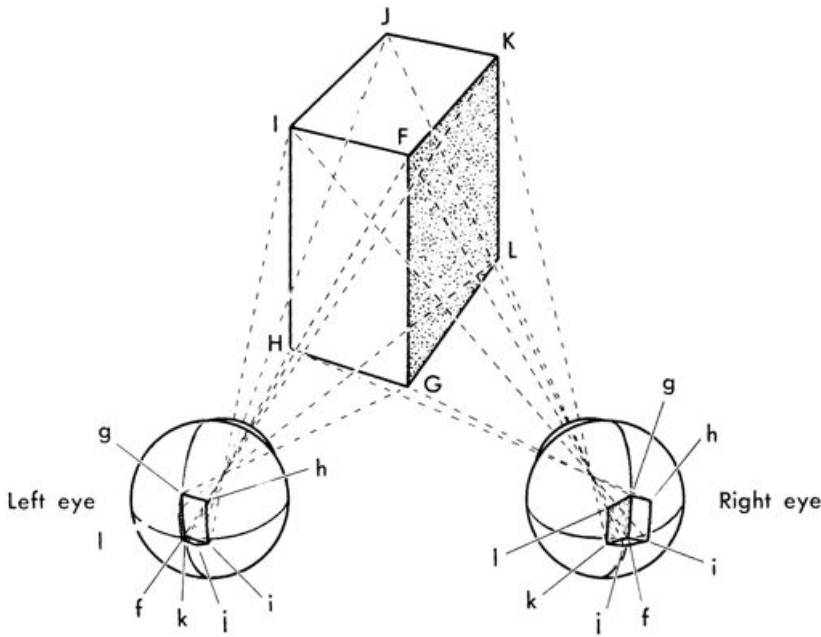


FIGURE 2-14. A solid object placed in the midline of the head creates slightly different or disparate retinal images, the fusion of which results in a three-dimensional sensation. The lowercase letters of the retinal image correspond to the uppercase letters of the object.

Physiologic Basis of Stereopsis

Wheatstone,¹⁰¹ by his invention of the stereoscope in 1838, was the first to recognize that stereopsis occurs when horizontally disparate retinal elements are stimulated simultaneously. The fusion of such disparate images results in a single visual impression perceived in depth, provided the fused image lies within Panum’s area of single binocular vision, which provides the physiologic basis of binocular depth perception. Vertical displacement produces no stereoscopic effect.

A solid object placed in the median plane of the head produces unequal images in the two eyes. Owing to the horizontal separation of the two eyes (the interpupillary distance), for geometric reasons each eye receives a slightly different image (Fig. 2-14), referred to as a parallax angle by physicists. The sensory fusion of the two unequal retinal images results in a three-dimensional percept.

The object producing slightly unequal images in the two eyes need not be a solid one. A stereoscopic effect can also be produced by two-dimensional pictures, some elements of which are imaged on corresponding retinal elements to give the frame of reference for the relative in-depth localization of other elements of figures constructed to provide horizontally disparate imagery. Such figures must be viewed separately but binocularly in a stereoscope or some haploscopic device (see Chapter 4). This is another example of a difference between physical and subjective space. Neither figure seen by each eye has depth; each

provides only the appropriate stimulus situation that, when elaborated by the visual system, produces a three-dimensional percept in visual space.

A simple example will make this clear. If one presents to each eye in a stereoscope or haploscope a set of three concentric circles, they will be fused into a single set of three flat concentric circles. Each circle is imaged on corresponding retinal elements. To ensure that each eye has indeed viewed the circles, a black dot, a so-called check mark, is placed to the left of the circles seen by the left eye and to the right of the circles seen by the right eye. In the fused image a dot will be seen on each side of the three circles (Fig. 2-15A).

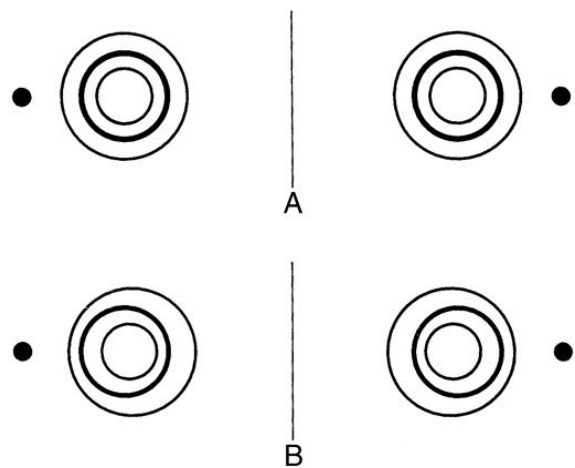


FIGURE 2-15. A, Two sets of concentric circles to be viewed in a stereoscope. B, Two sets of eccentric circles to be similarly viewed.

The circles may be drawn so that they are not concentric, but eccentric, by shifting the center of the two inner circles on the horizontal diameter of the outer circle (Fig. 2-15B). If viewed in a stereoscope, the outer circles imaged on corresponding retinal elements will be fused and serve the viewer as a frame of reference for the other two circles, which are also fused. However, they will appear in front or in back of the outer circle, depending on the direction in which their centers have been shifted. If they are displaced toward each other (i.e., toward the inner side of the circumference of the outer circles), they create a temporal disparity and therefore are seen in front of the outer circle. If they are displaced away from each other (toward the outer side of the large circles), they are imaged in nasal disparity and therefore are seen in back of the outer circle. The greater the displacement of the inner circles, the farther away from the outer circle they are localized. *The greater the depth effect, the greater the horizontal disparity.*

The inner circles are seen not only in depth relative to the outer circle in the fused image but they also appear concentric with it, although the image in each eye appears as eccentric circles. This most startling phenomenon of a shift in visual direction of the fused image is the very essence of stereopsis, and without it there is no stereopsis. It has implications for the clinical use of stereoscopic targets (see Chapter 15).

Stereopsis is a response to disparate stimulation of the retinal elements. It is this highest form of binocular cooperation that adds a new quality to vision, but it is not a "higher" form of fusion as is implied in the term *third degree of fusion*, used in the older literature to denote stereopsis.

The question arose whether the brain must compare the images formed on each retina before it can use the disparity of the visual input to convey the sense of depth. The answer to this question was provided by Julesz's invention⁵⁷ of *random-dot stereograms*. Random-dot stereograms, when monocularly inspected, convey no visual information other than random noise (Fig. 2-16); however, when binocularly fused by convergence or prisms, a square pattern appears in vivid depth above or below the level of the page. It follows that stereopsis does not depend on monocular clues to spatial orientation or shape recognition, since each monocularly viewed figure contains no information about the contour of the stereoscopic image. Binocularly imaged information is independent of the monocular information. Moreover, since the square is seen only because it is perceived in depth, monocular pattern recognition is not necessary for stereopsis. Julesz⁵⁸ concluded from a series of elegantly designed experiments that *form perception must occur after stereopsis* in the functional hierarchy of visual processing and not before, as was once assumed.

The principle on which random-dot stereograms is based is shown in Figure 2-17. The dot distributions seen by the right and left eyes are identical (0 and 1 squares) except for the central squares of each figure, which are shifted in a horizontal direction relative to each other (A and B squares). The retinal disparity of the central squares when both images are fused elicits stereopsis.

Local vs. Global Stereopsis

The rather startling finding that random-dot stereopsis is not preceded by form recognition directed



FIGURE 2-16. Random-dot stereogram. The central square will appear behind the plane of the page when the eyes overconverge and in front of the paper when they underconverge. (From Julesz B: *The Foundations of Cyclopean Perception*. Chicago, University of Chicago Press, 1971.)

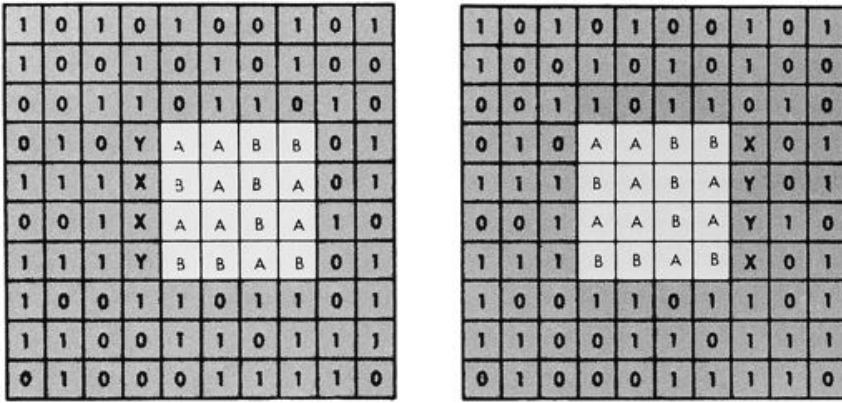


FIGURE 2-17. Principle of generating a random-dot stereogram. (From Julesz B: *The Foundations of Cyclopean Perception*, Chicago, University of Chicago Press, 1971.)

attention to the dot-by-dot or square-by-square matching process that must occur between the right and left stereogram to elicit stereopsis. Julesz⁵⁸ applied the term *local stereopsis* to this correlation and pointed out that the elements of a random-dot stereogram (i.e., black and white dots) may give rise to many false matches within Panum’s area since ambiguity exists about which elements in the two monocular fields are corresponding. There is less uncertainty about which parts of the drawing are seen by corresponding retinal elements in a classic stereogram (see Fig. 2-15). For random-dot stereopsis to occur the global neighborhood of each matching pair of dots or lines that provide the stimulus for stereopsis and, ultimately, for form recognition must be taken into account. This mechanism was termed *global stereopsis* by Julesz.⁵⁸

The clinician must ask how the recognition of stereopsis in a random-dot stereogram relates to stereopsis under casual conditions of seeing. It is disconcerting to learn, for instance, that 40% of 162 *normal* children aged 4 1/2 to 5 1/2 years were found to have random-dot stereopsis of less than 40 seconds of arc.⁵⁹ This finding casts doubt upon the value of random-dot testing in differentiating visually normal from abnormal subjects⁷ and draws attention to the fact that testing for random-dot stereopsis is not the same as testing for stereopsis under casual conditions of seeing. For instance, under ordinary visual conditions the recognition of form does not depend on intact stereopsis and the visual system is not challenged by the task of having to unscramble a seemingly meaningless pattern of black and white dots without the availability of nonstereoscopic clues to depth perception.

This should not distract from advantages of using tests that exclude contamination of testing

results by monocular clues and permit the objective testing of infants⁵ or experimental animals³¹ for stereopsis. Other clinical features of stereopsis testing are discussed in Chapter 15.

Stereopsis and Fusion

Although it is true that sensory fusion is essential for the highest degree of stereopsis, lower degrees of stereopsis may occur in the absence of sensory fusion and even in the presence of heterotropia. Examples are microtropia and small angle esotropia. Moreover, it has been shown experimentally that binocular depth discrimination may occur with diplopia.²⁰ For instance, if a peripherally seen wire is located to the left and at some distance in front of a binocularly fixated wire, as in a horopter apparatus (see p. 28), the peripheral wire appears in (physiologic) diplopia. One can now attempt to place a second peripheral wire, located in the right half of the field, in line with the left peripheral wire. The closer the left peripheral wire is to the centrally fixated wire, the more accurate is the setting of the wire on the right. The accuracy decreases with increasing distance from the central wire, and eventually the settings are made by pure chance, indicating that the wire on the right is no longer placed by the criterion of stereopsis; stereopsis has broken down. These observations are important for the theory of stereopsis. Whereas this experiment shows that sensory fusion of disparate retinal images is not absolutely essential for binocular depth discrimination, it must be emphasized that to obtain higher degrees of stereopsis the similar parts of a stereogram must be fused to obtain a frame of reference (see Fig. 2-17).

On the other hand, sensory fusion (i.e., the ability to unify images falling on corresponding retinal areas) in itself does not guarantee the pres-

ence of stereopsis. There are patients who readily fuse similar targets and who may have normal fusional amplitudes but who have no stereopsis. Such patients suppress selectively the disparately imaged elements of a stereogram seen by one eye. This behavior is of clinical importance and is discussed in Chapter 15.

Stereoscopic Acuity

The responsiveness to disparate stimulations has its limits. There is a minimal disparity beyond which no stereoscopic effect is produced. This limiting disparity characterizes a person's stereoscopic acuity.

Stereoscopic acuity depends on many factors and is influenced greatly by the method used in determining it. In refined laboratory examinations and with highly trained subjects, stereoscopic acuities as low as 2 to 7 seconds of arc have been found. There are no standardized clinical stereoscopic acuity tests comparable to visual acuity tests, and no results of mass examinations. Generally speaking, a threshold of 15 to 30 seconds obtained in clinical tests may be regarded as excellent.

It is clear that visual acuity has some relation to stereoscopic acuity. Stereoscopic acuity cannot be greater than the Vernier acuity of the stimulated retinal area. Stereoscopic acuity decreases, as does visual acuity, from the center to the periphery of the retina.²¹ However, despite this relationship, stereopsis is a function not linearly correlated with visual acuity. It has been shown, for instance, that reduction of visual acuity with neutral filters over one eye does not raise the stereoscopic threshold, even if the acuity was lowered to as low as 0.3. A further decrease in vision to 0.2 greatly increased the threshold and with a decrease in acuity of the covered eye to 0.1, stereopsis was absent.⁷¹ Colenbrander²⁸ quotes Holthuis as stating that in examining aviators he found that poor visual acuity was generally accompanied by reduced stereoscopic acuity but that there was no correlation between the two functions. On the other hand, spectacle blur decreases stereoacuity more than ordinary visual acuity.¹⁰⁰ Of special clinical interest is the fact that stereoacuity in patients with amblyopia may be better than what one would expect from their visual acuity.^{7, 26} This observation raises doubts about the value of stereoacuity testing being advocated by many as a foolproof visual screening method for preschool children.

Since there is a stereoscopic threshold, it follows that stereopsis cannot work beyond a certain critical distance. This distance has been computed somewhere between 125 and 200 m by various authors, depending on the threshold used for computation.

Monocular (Nonstereoscopic) Clues to Spatial Orientation

Stereopsis—the relative localization of visual objects in depth—can occur only in binocular vision and is based on a physiologic process derived from the organization of the sensory visual system. It is not acquired through experience and is unequivocal and inescapable.

Stereopsis is restricted to relatively short visual distances and is not the only means we have for spatial orientation. A second set of clues, the monocular or experiential clues, are important in our estimation of the relative distance of visual objects and are active in monocular as well as binocular vision. The importance of monocular clues in judging the relative distance between remote objects is perhaps best exemplified by an optical illusion known to every sailor and brought about by the paucity of such clues on the open sea: two ships approaching each other from opposite directions may appear to be dead set on a collision course when, in fact, they are separated by many hundreds of yards of water as they pass each other.

Monocular clues are the result of experience and are equivocal. Such clues are numerous, and descriptions of the most important ones follow.

MOTION PARALLAX. When one looks at two objects, one of which is closer than the other, and moves either the eyes or the head in a plane parallel to the plane of one of these objects, movement of the objects becomes apparent. The farther object appears to make a larger excursion than the near object. This behavior is learned by experience, and one makes much use of it in daily life, for instance, in sighting monocularly. If there are depressions or elevations in the fundus, one can observe the apparent movement of the retinal vessels by moving the head from side to side. The parallax movement of the more distant vessels gives a compelling picture of the different levels of the retina.

LINEAR PERSPECTIVE. Object points having a constant size appear to subtend smaller and

smaller angles as they recede from the subject. Railroad tracks, which are in fact parallel, seem to approach each other in the distance. Foreshortening of horizontal and vertical lines is one of the most powerful tools for creation of three-dimensional impressions on a two-dimensional surface (Fig. 2–18). Renaissance artists made exaggerated use of this “trick” to create depth in their paintings.

OVERLAY OF CONTOURS. Configurations in which contours are interposed on the contours of other configurations provide impelling distance clues. An object that interrupts the contours of another object is generally seen as being in front of the object with incomplete contours (Fig. 2–19); the second, farther object is also higher than the first one. This, too, is a clue made use of by early painters to indicate relative distances.

DISTRIBUTION OF HIGHLIGHTS AND SHADOWS. Highlights and shadows are among the most potent monocular clues. Since sunlight comes from above, we have learned that the position of shadows is helpful in determining elevations and



FIGURE 2–18. This photograph of an airport corridor shows the strong depth effect created by the apparently decreasing width of the ceiling lights and the decreasing height of the columns.

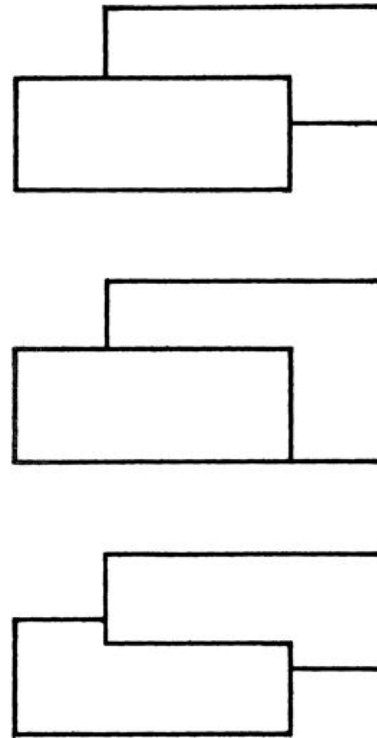


FIGURE 2–19. Effect of overlay of contours. The rectangle in incomplete outline generally seems farther back than the one that is complete. The incomplete rectangle is also higher, which adds to this impression.

depressions, that is, the relative depth, of objects. This phenomenon is impressively shown in Figure 2–20, taken from a paper by Burian²²; a piece of cloth, (Fig. 2–20C) is photographed by throwing light on it in such a way that horizontal threads in the tissue appear as ridges. In Figure 2–20D, the identical photograph has been turned 180° and the ridges appear as troughs.

The inversion can occur because nothing in our experience prevents it from happening. In Figure 2–20A and B, a photograph of a sculptured head is shown. Here the inversion of the print does not have the same effect. Some observers may note a general flattening in the inverted face, but a nose is a nose and can never be seen as a trough.

SIZE OF KNOWN OBJECTS. If the size of two objects is known, one can judge the relative distance of these objects by their apparent size. If an object known to be smaller appears to be larger than the other, we judge it to be nearer.

AERIAL PERSPECTIVE. Aerial perspective is the term used for the influence of the atmosphere on contrast conditions and colors of more distant objects. The bluish haze of more distant mountains is an example. Chinese painters are masters at

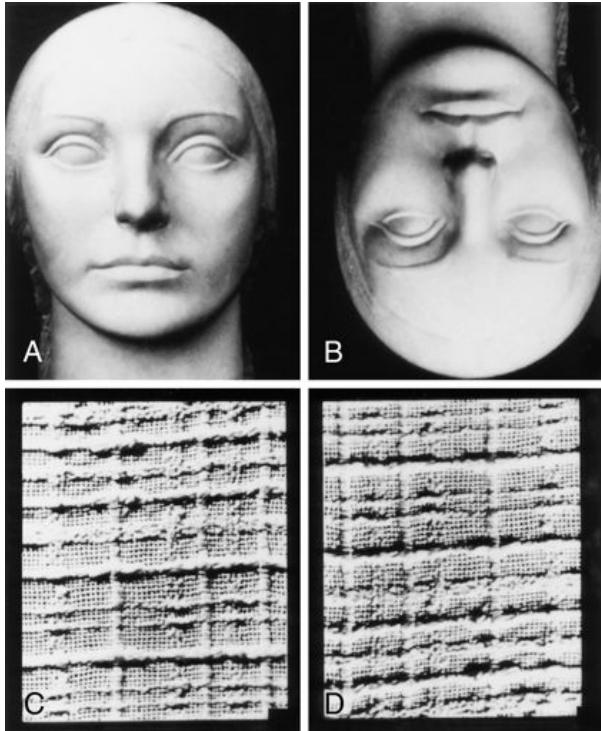


FIGURE 2-20. Effect of highlights and shadows. *A*, Sculpture of human head illuminated from above. *B*, Photograph *A* inverted. *C*, Piece of cloth illuminated from above. *D*, Photograph *C* inverted. (From Burian HM: The objective and subjective factors in visual perception. *J Assoc Med Illustrators* 9:4, 1957.)

creating extraordinary depth in landscapes by using subtle variations of shading.

NATURE OF MONOCULAR CLUES. The impression of three-dimensionality imparted by all these clues is a judgment, an interpretation, and implies that false judgments are possible; indeed, such is the case. It also implies that this impression depends on past experience, as does every judgment. The nature of the nonstereoscopic clues is that they are experiential and can be meaningful only when they are capable of being related to past experience.

Interaction of Stereoscopic and Monocular Clues

All this does not mean that nonstereoscopic monocular clues are less important in everyday life than stereoscopic clues. Normally the two function together, one enhancing the effect of the other, but this is not always the case. If one introduces into stereograms monocular clues that conflict with stereoscopic clues, fascinating observations can be made.

Not everyone reacts in the same fashion to such

stereograms. Some people are more responsive to disparate stimulation, that is, stereoscopic clues, whereas others respond more readily to monocular clues. These differences are caused both by physiologic peculiarities or actual abnormalities of the visual system and by past experience. A person stereoblind since infancy must rely exclusively on monocular clues and will flawlessly perform most ordinary tasks requiring depth discrimination, such as pouring milk into a glass or parallel parking. He or she will fail abysmally, however, when a higher degree of stereopsis becomes essential and monocular clues are no longer available, for instance, as occurs in the limited field of vision provided by an operating microscope.

Humans, then, have at their disposal two sets of clues for their orientation in space. By means of the monocular clues to spatial localization, interpretation of the depth relation of visual objects is achieved on the basis of experience. The clues provided by fusion of disparate retinal images afford the direct perception of this relation on the basis of intrinsic physiologic arrangements.

Clinical Significance of Monocular Clues

All this is of considerable clinical importance in patients with strabismus. For example, if there is doubt about whether a patient actually does see stereoscopically, misleading monocular clues introduced purposely into stereograms may provide the answer. Heavy black figures (as in the circles of Fig. 2-15) appear closer than lighter figures do to a person without stereopsis, even if the stereogram is so drawn that the black figures should appear in back of the lighter ones. Furthermore, if it is not known if a patient can see stereoscopically, again use the eccentric circles and ask the patient to state whether the inner circle seems to be closer to the right or left side of the outer circle. If the patient answers that it is closer to one side or the other, one can be sure that he or she does not see stereoscopically, since the circles would otherwise have to appear concentric. In addition, the patient's answer allows one to determine which eye the patient is suppressing. For example, if the two inner circles are displaced away from each other and the patient reports that the heavier circle is to the left in the outer circle, he or she is suppressing the right eye (see Fig. 2-15).

A patient with binocular vision but who has

recently lost one eye and is looking across a square will have no question that a lamppost is in front of a house. The continuous lines of the lamppost are interposed over the interrupted horizontal contours of the house. However, the patient may have considerable difficulty in pouring cream into a coffee cup and performing other tasks of visuomanual coordination. In time the patient may overcome these difficulties and become as skillful or almost as skillful as before the eye was lost. Fast-moving objects (such as a flying ball) may continue to give trouble, but as time passes monocular clues to depth perception may be used, even in near vision where formerly stereoscopic clues were relied on entirely.

Experimental Determination of the Longitudinal Horopter and the Criteria of Retinal Correspondence

In preceding discussions in this chapter, reference has been made repeatedly to wires placed in various positions relative to a binocularly and centrally fixated wire. Such an arrangement of wires is used in the determination of the empirical horopter.

The horopter apparatus (Fig. 2-21) is operated in the following manner. The observer's head is fixed in a headrest, and a suitable aperture excludes all extraneous elements from the observer's visual field. Tracks are provided that converge at a point below the middle of the observer's basal

line, that is, the line segment connecting the centers of rotation of the two eyes. In these tracks run carriers to which vertical wires are fastened. The observer fixates a vertical wire placed at a chosen near vision distance in the median plane. The position of the central wire remains unchanged. To each side of the fixation wire are situated movable wires that the observer sees at 1° , 2° , 3° , 4° , 6° , 8° , 12° , and so on in peripheral vision.

The purpose of the horopter apparatus is to determine the distribution of corresponding retinal elements. Therefore the patient must be assigned a task in which the peripherally seen wires are arranged so that they stimulate corresponding retinal elements. The patient must strictly fixate the central wire, which may be equipped for this purpose with a small bead. A number of possible criteria of correspondence can now be evaluated.

Criterion of Single Vision

Double vision with corresponding retinal points is impossible. One could instruct an observer to set the peripheral wires in the horopter apparatus so that they would all appear singly. This is not a reliable criterion for correspondence because of Panum's area of single binocular vision.

Apparent Frontal Plane Criterion

As we have also seen, stereopsis depends on disparate stimulation. Simultaneous stimulation of corresponding retinal elements does not produce a three-dimensional effect. *The stereoscopic value*

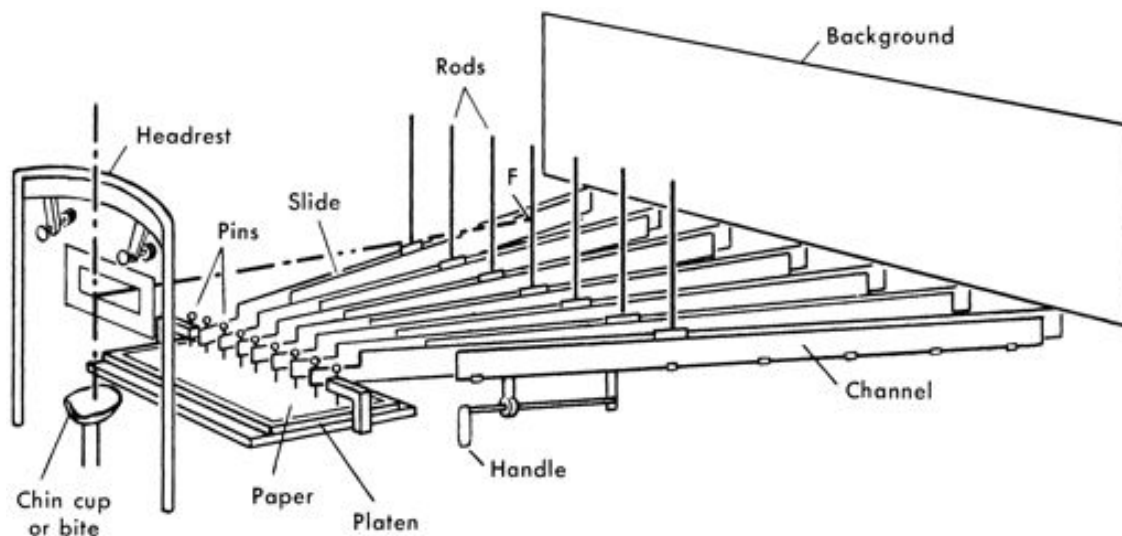


FIGURE 2-21. Horopter apparatus. (From Ogle KN: *Researches in Binocular Vision*. Philadelphia, WB Saunders, 1950.)

of corresponding retinal elements is zero. Therefore, if an observer is asked to place all peripheral wires in such a manner that they appear in a plane parallel with his or her forehead, the subjective frontoparallel plane, all wires presumably stimulate corresponding retinal elements and their position determines the observer's horopter.

For near vision distances, this horopter curve does not coincide with the objective frontoparallel plane. It is a curve that is slightly convex to the observer but has less of a curvature than the Vieth-Müller circle (see Fig. 2-10). At times it is amusing to see a naive observer's astonishment when it is shown that he or she has set the horopter wires in a curve. The observer is so sure they are in a plane!

Criterion of Common Visual Directions

The criterion of frontoparallel appearance is convenient and easy to use. This method is sufficiently reliable so that it has been used in almost all horopter studies, but it is indirect. In principle, the most reliable criterion would be direct determination of the common visual directions, which can be done with a special arrangement of the horopter wires.

If one of the peripheral wires is partially occluded so that, for example, its upper part is seen by one eye and its lower part by the other, the line will be seen as continuous only when it comes to lie on corresponding meridians in the two retinas. This method presents considerable practical difficulty, mainly because the reduction in fusible material in the field makes it difficult to maintain the proper positioning of the eyes.

Criterion of Highest Stereoscopic Sensitivity

Although the stereoscopic value of corresponding retinal elements is zero, stereoscopic sensitivity is highest in the immediate vicinity of corresponding retinal elements. This means that the smallest changes in the position in front of or behind the peripherally seen wires are detected near the horopter curve. By determining this position, an approximation of the observer's horopter curve can be obtained. This procedure is tedious and does not approximate the horopter curve as well as the much simpler determination of the subjective frontoparallel plane.

Egocentric (Absolute) Localization

Thus far this chapter has dealt with localization of visual objects relative to each other in the three dimensions. We must now turn to the absolute and egocentric localization of visual objects, that is, to their orientation with respect to a coordinate system that has its origin in physical space (absolute localization), especially that part of physical space occupied by a person's body (egocentric localization).

The physical coordinates for egocentric localization are the median plane of the body (vertical in an upright position of the body, perpendicular to the baseline at its center), the horizontal plane of the body (containing the baseline and the two principal lines of direction), and the frontal plane of the body (containing the baseline, which is perpendicular to the median and the horizontal plane). Subjective planes correspond to these physical planes: the subjective median plane transmits the impression "straight-ahead"; the subjective horizontal (visual) plane transmits the impression "at eye level"; and the subjective frontal plane transmits the impression "at a distance from me." In general, these subjective equivalents do not coincide with their physical counterparts.

Hering⁴⁶, p. 417 made the assumption that they did coincide since it happened to be true for him, and accordingly he placed the origin of the egocentric coordinate system at the root of the nose. It need not be there. If a person has a markedly dominant eye, the absolute position of the common visual direction of the foveae (and therefore of the subjective median plane and the "straight-ahead" position) may not be in the objective median plane but may be shifted toward the side of the dominant eye. Recent data suggest that the reference point for visual localization lies between the midpoint of the interocular axis and the line of sight of the dominant eye.⁸⁴

Egocentric Localization and Convergence

Of special interest is in-depth egocentric localization. How do we judge the distance of an object from us? Many factors cooperate in this function. The size of the retinal image could be one, since the retinal image of an object is smaller the farther it is from the eye. For objects of known size (e.g., a man) and relatively short distances, this clue is

of limited value because of the size-constancy phenomenon. Accommodation may provide another clue. Convergence is generally assumed to be the most potent clue.

A simple experiment will demonstrate this point convincingly. Hold up one thumb in front of you at arm's length and look at a window or door at the end of the room. Then converge your eyes on your thumb and the distant objects will seem to shrink and to move closer. This is a compelling phenomenon that is not only of theoretical but also of practical clinical significance in patients with intermittent exotropia (see Chapter 17).

It was postulated in the older literature that an awareness of the impulses required to bring or keep the eyes in a particular position was at the origin of our perception of absolute distance. This theory is not satisfactory, and Tschermak-Seysenegg^{95, p. 219} replaced it with the theory of an indirect sensory function of the ocular muscles. It makes the following assumption: Afferent nerve fibers respond to the active tonus of ocular muscles, but not to passive relaxation. However, there is no consciousness of the tension of single muscles or of the eye posture as such. The simple, preexisting sensation of the straight-ahead position or the equally high position is related to a certain complicated tonus distribution of the oculomotor apparatus and, therefore, to a complex of afferent excitation.

This somewhat awkwardly put explanation is, in fact, an anticipation of the way in which modern models describe control of eye movements and awareness of absolute depth. It contains the concept of "space representation" and of negative and, indeed, parametric feedback.

Egocentric Localization and Proprioception

As mentioned earlier in this chapter, there are two sources of information from which the brain may determine eye position and receive spatial orientation clues: visual input from the retina, (*outflow*) and proprioceptive information from the extraocular muscles (*inflow*). While there can be little doubt that efferent outflow is the dominant mechanism in supplying the most necessary spatial information to the brain, there is mounting evidence that proprioceptive inflow may also play a role. The human extraocular muscle is certainly adequately equipped to provide proprioceptive input: there are abundant muscle spindles, Golgi tendon,

and palisade endings located at the musculotendinous junction (see Chapter 6). Skavenski⁸⁶ was first to show in a carefully designed experiment that the human oculomotor system is capable of processing nonvisual inflow information. His subjects were able to correct for passively applied loads to the eyes with appropriate eye movements in the dark. Experiments in cats^{42, 69, 93} strongly suggested that the ophthalmic branch of the trigeminal nerve carries proprioceptive afferents. That the same may hold true for humans was suggested by Campos and coworkers²⁵ who described faulty egocentric localization in patients with herpes zoster ophthalmicus. Gauthier and coworkers⁴² (see also Bridgeman and Stark¹⁸) showed that passive deviation of one eye caused faulty localization of objects seen by the other eye in the direction of the passive movement, suggesting the utilization of inflow information for egocentric localization.

Lewis and Zee⁶⁵ reported that proprioceptive afference may influence egocentric localization in the absence of normal oculomotor innervation in a patient with trigeminal-oculomotor synkinesis. Lewis and coworkers⁶⁶ showed also that proprioceptive deafferentation of the extraocular muscles did not influence the accuracy of pointing and concluded that inflow provides sufficient information about orbital eye position for correct egocentric localization.

Mechanical vibration of the inferior rectus muscle to each eye simultaneously and under monocular and binocular conditions caused an illusionary movement of a red light presented in total darkness and induced past-pointing.⁹⁷ This visual illusion could also be elicited by vibration of the horizontal rectus muscles and cannot be attributed to retinal motion of the image of the fixated target.⁹⁶ Lennerstrand and coworkers⁶² showed that vibratory activation of the muscle spindles in extraocular muscle affects eye position and these signals are processed differently in normals and in exotropic patients.

Steinbach and Smith⁹¹ found surprisingly accurate egocentric localization in patients after strabismus surgery who had been deprived of visual input until the time of the experiment. According to these authors, this information can only be derived from inflow (see also Dengis and coworkers^{33, 34}). Myotomy of a muscle had a greater effect in deafferenting proprioception than a recession, presumably because of greater destruction of the palisade endings by the former procedure.⁹² How-

ever, Bock and Kommerell¹⁶ could not duplicate Steinbach's finding and Campos and coworkers²⁴ were unable to correlate pointing errors after strabismus surgery with a particular surgical procedure. They did, however, show changes in egocentric localization after exerting stretch on an extraocular muscle.²³

While some of these data are contradictory there is little doubt that inflow signals are available to the visual system. However, it is not clear how they are used by the brain and correlated with outflow information under casual conditions of seeing when visual input is abundantly available. Skavenski and coworkers⁸⁷ showed that when inflow and outflow signals conflict, the outflow signal is, as one may expect, the stronger one. It has been proposed that inflow acts as a long-term calibrator and is involved in maintaining the stability and conjugacy of gaze⁸⁹ and of smooth pursuit movement.³⁵ For reviews, see Steinbach^{88, 90} and Lennerstrand.^{60, 61}

Clinical Significance of Relative and Egocentric Localization

One need not go into experimental evaluations of egocentric localization, but emphasis must be placed on making a clear distinction between relative and absolute (egocentric) localization because relative and egocentric localization may be independently affected in certain forms of strabismus. Confusion between the two forms of subjective localization leads to misinterpretations of the observed phenomena. For instance, a patient with an acute paralysis of an extraocular muscle will past-point (see Chapter 20), which is evidence of abnormal egocentric localization, but will have normal relative localization (the double images are localized according to the laws of physiologic diplopia). A patient with comitant strabismus does not, as a rule, past-point, although exceptions do occur,^{3, 93, 94} but rather may experience abnormal relative localization; that is, the patient does not localize the double images according to the law of physiologic diplopia (anomalous retinal correspondence; see Chapter 13).

Theories of Binocular Vision

Correspondence and Disparity

According to the theory of binocular vision presented in this chapter, sensory binocular coopera-

tion is based on a system of correspondence and disparity.

A given retinal element in one retina shares a common subjective visual direction with an element in the other retina. These corresponding elements form the framework or zero system of binocular vision. When stimulated simultaneously by one object point, they transmit single visual impressions that have no depth quality. When stimulated simultaneously by two object points that differ in character, binocular rivalry results. When disparate elements are stimulated by one object point, diplopia is experienced. However, if the horizontal disparity remains within the limits of Panum's area, a single visual impression is elicited that has the quality of relative depth or stereopsis. The fused component, that is, the singly appearing, disparately imaged component of the stimulus or target, is seen not only in depth but also in the subjective visual direction of the relative retinal element to which the stimulus is disparate.

The perceived depth increases with increasing disparity. With further increase in disparity, diplopia eventually occurs. Although stereopsis generally occurs with fusion, it is still possible up to a point to experience a true stereoscopic effect from double images.^{20; 76, p. 281} However, increasing disparity causes the quality of stereopsis to decrease until finally there is no longer any binocular stereoscopic effect. There is, then, no sharp delineation between fusion with full stereopsis and diplopia without stereopsis, but only a gradual transition. This is consistent with many other biological processes, especially visual ones, none of which change abruptly from function to nonfunction.

One can think of each retinal element as being the center of attraction of a retinal unit, the attraction diminishing as the distance from the element increases. In considering this simile, keep in mind that (1) the retinal units are overlapping, and (2) the stimulation of neighboring units may result in inhibitory stimulation of surrounding units.

Neurophysiologic Theory of Binocular Vision and Stereopsis

The correspondence theory has been built on the basis of overwhelming evidence from psychophysical data. Direct physiologic evidence for it has emerged from the work of Hubel and Wiesel.⁵¹⁻⁵³ These authors have given us insight into

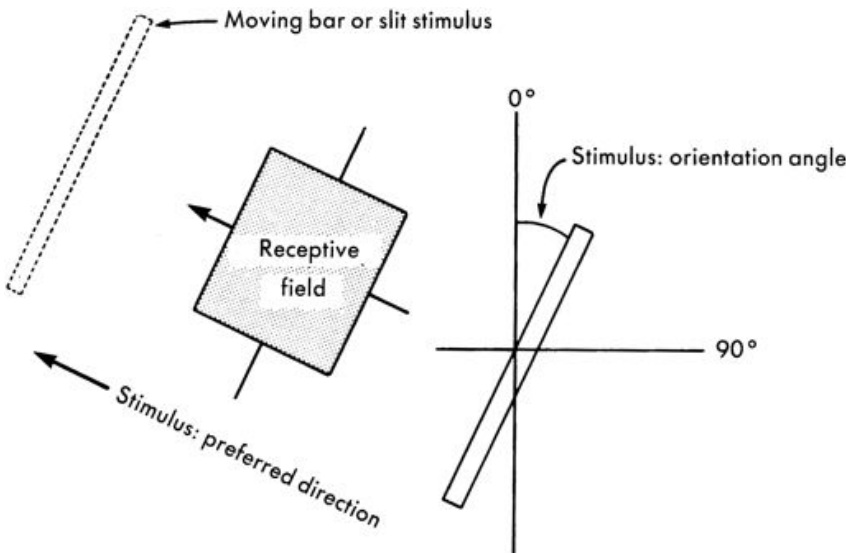


FIGURE 2-22. Receptive fields dependency on preferred direction and orientation of the stimulus. (Modified from Bishop P: Vertical disparity, egocentric distance and stereoscopic depth consistency: A new interpretation. Proc R Soc Lond B Biol Sci 237:1289, 1989.)

how visual stimuli from the retina to the visual cortex are modified and coded. In their microelectrode studies of single-cell responses in the striate cortex of the cat, they have found that roughly 80% of the neurons could be driven from either eye. However, only 25% of these binocularly driven cells are stimulated equally well from each eye; the remaining 75% represent graded degrees of influence from the right or left eye. Ten percent of the cells are driven exclusively from the right or left eye. Cells that can be driven by stimulation of either eye have receptive fields of nearly equal size and in approximately corresponding positions in the visual field. The *receptive field* of a visual neuron is defined as that part of the visual field that can influence the firing of that cell.⁵² The activity of most striate neurons is maximal to movement of a linear slit of light in front of the eye when the slit has a particular orientation and preferred direction of movement (Fig. 2-22).

Similar experiments in monkeys yielded comparable data^{8, 29} (Fig. 2-23). That this dominance in distribution of cortical neurons is easily upset when animals are reared with experimental strabismus, anisometropia, or form vision deprivation by lid suture is discussed in Chapter 14.

A reasonable assumption is that neurons in the striate cortex responding equally well to successive stimulation, and especially those in which the response can be maximized with simultaneous stimulation, are somehow involved with binocular visual processing. Indeed, Hubel and Wiesel⁵² showed response summation or inhibition, depending on the alignment or misalignment of the stimulus on the receptive field, concluding that

summation occurs whenever corresponding parts of the receptive field are stimulated.

The discovery of disparity-sensitive binocular cells in the striate cortex had to await the arrival of precise receptive field mapping techniques that excluded all eye movements during the experiment. The chronological sequence of a series of classic experiments that led to the discovery of the neurophysiologic mechanisms of stereopsis was reviewed by Bishop and Pettigrew.¹³ Barlow, Blakemore, and Pettigrew⁹ were the first to describe horizontal disparity sensitivity of binocular striate neurons in the cat and proposed that these cells may be responsible for stereopsis. Hubel and Wie-

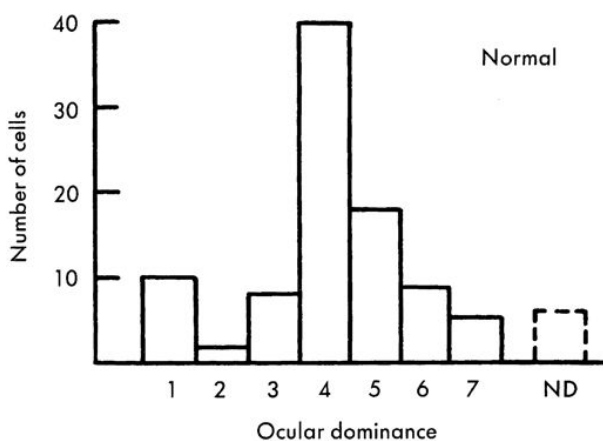


FIGURE 2-23. Dominance distribution of striate neurons from two normally reared monkeys. Categories 1 and 7 contain neurons driven only through the left or right eye. The remaining categories represent greater degrees of binocular influence with neurons in 4 being equally influenced by both eyes. (From Crawford MLJ, Blake R, Cool SJ, Noorden GK von: Physiological consequences of unilateral and bilateral eye closure in macaque monkeys: Some further observations. Brain Res 84:150, 1975.)

sel⁵³ identified cells described as being sensitive to binocular depth in area 18 of the macaque cortex. Poggio and coworkers⁸⁰⁻⁸³ discovered in rhesus monkeys neurons in cortical areas 17 and 18 that responded to dynamic random-dot stereograms containing no depth clues other than disparity. They identified two functional sets of stereoscopic neurons, one tuned excitatory and the other inhibitory. These cells responded differently, depending on whether visual objects were on, in front of, or behind the horopter.⁸³ Bishop^{11, 12} proposed that binocularly activated cortical cells may not only be selective for horizontal but for vertical stimulus disparities as well. However, in monkeys the horizontal disparities are appreciably greater than the vertical disparities and in humans vertical disparity produces no measurable stereoscopic effect.

Crawford and coworkers^{29, 30} showed in behavioral and electrophysiologic experiments that infant monkeys with a severely reduced binocular striate neuron population after a period of experimental strabismus become stereoblind (Fig. 2-24). Once binocular neurons are lost they do not recover, even with extensive binocular visual experience.³⁰ This may explain the markedly reduced stereoacuity in spite of early surgery in children with essential infantile esotropia (see Chapter 16) and emphasizes the extraordinary vulnerability of the primate binocular system to abnormal visual experience. Thus, stereopsis has been unequivocally linked with the so-called binocular cells in the striate cortex, and there has been good agreement between psychophysical data collected

from humans and neurophysiologic research in cats and primates.^{30, 31}

Whether binocular striate cells subserve functions other than stereopsis is not known. The response summation depending on stimulus alignment observed in animal experiments suggests that binocular cells may also be involved in the fusion process. On the other hand, the clinician knows that sensory fusion may occur in the absence of stereopsis. The cortical centers for sensory and motor fusion are yet to be identified.

Older Theories of Binocular Vision

Older theories of binocular vision still espoused in the second half of this century are mostly of historical interest now. However, familiarity with these concepts is indispensable for understanding the older literature.

ALTERNATION THEORY OF BINOCULAR VISION. *Sensory fusion* has been defined as the perceptual unification of the images received in corresponding locations in the two retinas. This definition is supported by the experience of single vision, which is quite compelling, but it is not necessarily the correct description of the process. Since 1760, when Du Tour³⁹ claimed that rivalry phenomena gave evidence that the binocular visual field is composed of a mosaic of monocularly perceived patches, this theory has had many adherents. Verhoeff,⁹⁸ in his replacement theory of binocular vision, assumed that corresponding retinal units were represented separately in the brain

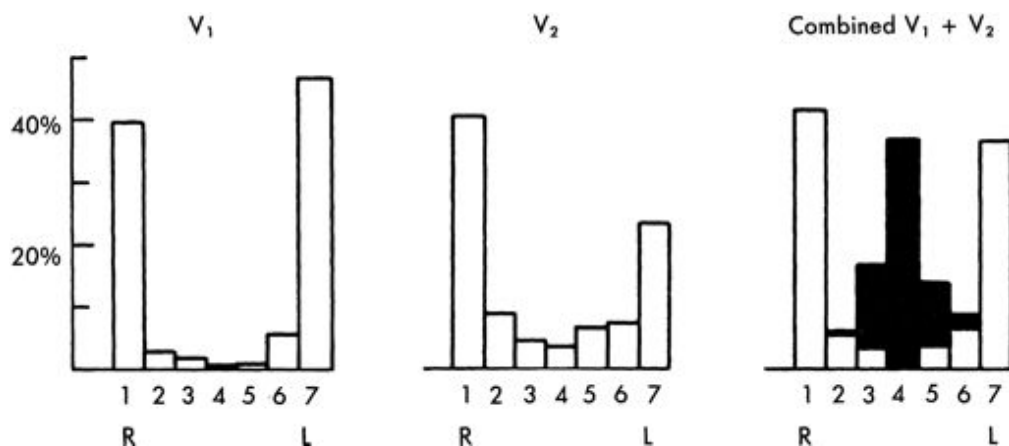


FIGURE 2-24. Stereoblind monkeys ($N = 3$) had most cortical cells controlled exclusively by one eye or the other (categories 1 and 7) with only 13% ($N = 276$) binocular innervation in cortex layers V_1 and 30% ($N = 108$) in V_2 . The black bars represent the missing binocularly innervated neurons ordinarily found in control monkeys. (From Crawford MLJ, Smith EL, Harwerth RS, Noorden GK von: Stereoblind monkeys have few binocular neurons. *Invest Ophthalmol Vis Sci* 25:779, 1984.)

but that each one of every pair was represented in consciousness by the same single unit. This conscious unit would receive the stimulus from only one retinal unit at a time; the other was excluded. Asher⁶ attempted to show that in binocular stimulation one pair of corresponding elements always suppressed the other. Hochberg⁴⁸ presented a similar view. Levelt,⁶⁷ although inclined toward the same view, did not share this all-or-none assumption. He believed that it is better to think of different levels of dominance of the eyes for each point of the visual field.

The “mosaicist” concept of the binocular visual field is supported by all its adherents with essentially the same evidence, largely based on the phenomena of rivalry. They fail, however, to explain many phenomena of binocular vision, particularly stereopsis. Also, as Linksz⁶⁸, p. 846 argued, the motor responses to the relative displacement of similar and dissimilar targets in a haploscope could not be as different as they are if alternate suppression were the basis of single binocular vision. Experiments in cats and monkeys have shown that when receptive fields from corresponding points of the retina are superimposed in the plane of an optimal stimulus, firing is markedly facilitated. When these fields are out of register, they mutually inhibit one another.⁷⁴ Moreover, “moderate summation” of responses from cortical neurons in macaques have been described following simultaneous stimulation of both eyes.^{8, 53} These findings do not support the alternation theory of binocular vision.

PROJECTION THEORY OF BINOCULAR VISION.

A theory that has now been largely abandoned is the projection theory, which contends that visual stimuli are exteriorized along the lines of direction. If a person fixates binocularly, a “bicentric” projection is supposed to occur that places the impression of each eye at the point of intersection of the lines of projection.

This theory is untenable for many reasons. It fails to explain even such fundamental observations as physiologic diplopia, not to mention the discrepancies between stimulus distribution and perception, and breaks down completely when interpretation of the sensory phenomena observed in strabismus is attempted (see Chapter 13). The basic reason for the inadequacy of the projection theory is that the distinction between physical and subjective space is disregarded and it attempts to reduce localization to a dioptic-geometric scheme.

Alexander Duane,^{36–38} among American ophthalmologists, has most clearly presented the projection theory, but he modified it to meet some obvious objections. According to Duane, in both monocular and binocular vision the visual impressions are projected or referred to a definite position in physical space outside the body. There is, however, an essential difference between monocular and binocular “projection.” In monocular vision each eye “projects with reference to its own axis” and in binocular vision with reference to the midline or “bivisual axis.” In other words, “binocular projection” may be conceived as performed by a single cyclopean “binoculus.” Duane states that the change from monocular to binocular vision is proved by the fact that in physiologic diplopia the double images are not “projected” to the plane of the fixation point but to the plane in which the object lies, which is seen double. Thus, Duane showed that physiologic diplopia cannot be explained by the projection theory and accepted the concept of the cyclopean eye. Nevertheless, he considered the projection theory to be valid.

It would not be necessary to go into the projection theory in such detail if it were not for the fact that it continues to crop up in the literature, at least in the terminology. For example, one still encounters such statements as “the functional scotoma in strabismus projected into space for the purpose of solving diplopia.” *The term projection should be altogether avoided in connection with visual orientation.*

The projection theory, as espoused by Duane,³⁸ is also responsible for binocular vision being described in terms of “oculocentric localization” from each eye and for anomalous correspondence still being termed “anomalous projection” by some modern authors. Alperr² states that “The stimulus for stereopsis is a disparity in the oculocentric localization of a given object in the field of one eye with respect to its oculocentric localization in the field of the other eye.” This gives—at least terminologically—an independence to each eye that it does not possess. Even less acceptable is “disparity of egocentric localization of the center of the visual fields of the two eyes” as the stimulus to motor fusion. Neither eye has an “egocenter.” Only the subject has an egocenter to which the egocentric localization of visual objects is referred. The persistent confusion between relative and absolute (egocentric) localization has caused many misunderstandings in the ophthalmic literature.

THEORY OF ISOMORPHISM. Linksz⁶⁸, pp. 380 ff. developed a theory of binocular vision based on a rigid retinocortical relationship. He believed that fusion is based on neuroanatomical features, which bring excitations from the two retinas into close proximity within the visual cortex. Those from corresponding elements are “consummated” in Gennari’s stripe, which he considers to be the anatomical counterpart of the horopter plane in objective space and of the nuclear plane in subjective space. “Nuclear plane” denotes the counterpart in subjective space of the horopter surface in physical space. The term is derived from the German *Kernpunkt* (nuclear point, the subjective correlate of the fixation point) and *Kernfläche* (nuclear plane, the subjective correlate of the objective frontal plane). Objects nearer to or farther from the fixation point stimulate disparate retinal elements, and the resultant excitations converge in front of or behind Gennari’s stripe in strict conformity with the distribution of objects in space. In this way the sensation of stereopsis is created. The point-to-point relationship between retina and cortex and strict conformity or isomorphism between the distribution of objects in space and cortical events form the basis of spatial orientation. Subjective visual directions as a property of the retinal elements do not exist. Retinal correspondence cannot change. There can be no “assimilation of visual directions” in stereopsis. Anomalous correspondence in patients with strabismus (see Chapter 13) has been misinterpreted.

Linksz extensively elaborated his fascinating intellectual theory. There is, however, no evidence for the physiologic rigidity of the retinocortical relationship or the convergence of the pathways on which it is based.

Advantages of Binocular Vision

The current tendency is to overemphasize stereopsis as the only important reason for having binocular vision. For instance, Bishop¹¹ stated that “with the exception of stereopsis, seeing with both eyes is marginally, if any, better than seeing with one—absolute threshold, differential threshold, and visual acuity being about the same.” Indeed, binocular summation experiments show no monocular-binocular differences or at best give only equivocal results.¹⁵ On the other hand, there are certain advantages to having binocular vision in

addition to stereopsis that are not readily appreciated by the nonclinician.

Parents of strabismic children whose eyes have been aligned surgically will often volunteer the information that the child’s visuomotor skills have suddenly and vastly improved. This improvement does not seem to depend on the presence of stereopsis. It is noted as long as gross binocular vision on the basis of normal or abnormal retinal correspondence is reestablished. Jones and Lee⁵⁶ substantiated this clinical observation by evaluating human binocular and monocular performance through a variety of exteroceptive and visuomotor tasks. The results indicated that binocular concordant information provides better exteroception of form and color and better appreciation of the dynamic relationship of the body to the environment, thereby facilitating control of manipulation, reaching, and balance. Also, the advantages of an intact binocular field of vision, which is larger than a monocular field, and of central visual field overlap become obvious as soon as the function of one eye becomes impaired by a disease process.

REFERENCES

1. Aguilonius F: *Francisci Aguilonii e Societate Jesu opti-
corum libri sex. Philosophis iuxta ac mathematicis
utilis, Antwerpiae, 1613, ex Officina Plantiniana, Apud
Viduam et Filios Jo Moreti.*
2. Alpern M: Movements of the eyes. In Davson H, ed: *The
Eye*, vol 3. New York, Academic Press, 1962, p 98 ff.
3. Ambrose P, Noorden GK von: Pastpointing in comitant
strabismus. *Arch Ophthalmol* 94:1896, 1976.
4. Ames A, Gliddon GH: Ocular measurements. *Trans Sect
Ophthalmol AMA* June 1928, p 102.
5. Archer SM, Helveston EM, Miller KK, Ellis FD: Stere-
opsis in normal infants and infants with congenital eso-
tropia. *Am J Ophthalmol* 101:591, 1986.
6. Asher H: Suppression theory of binocular vision. *Br J
Ophthalmol* 37:37, 1953.
7. Avilla C, Noorden GK von: Limitation of the TNO ran-
dom dot stereo test for visual screening. *Am Orthopt J*
31:87, 1981.
8. Baker FH, Grigg D, Noorden GK von: Effects of visual
deprivation and strabismus on the response of neurons in
the visual cortex of the monkey, including studies on the
striate and prestriate cortex in the normal animal. *Brain
Res* 66:185, 1974.
9. Barlow HB, Blakemore C, Pettigrew JD: The normal
mechanisms of binocular depth discrimination. *J Physiol
(Lond)* 193:327, 1967.
10. Bielschowsky A: Application of the after-image test in
the investigation of squint. *Arch Ophthalmol* 17:408,
1937.
11. Bishop P: Vertical disparity, egocentric distance and ste-
reoscopic depth constancy: A new interpretation. *Proc R
Soc Lond B Biol Sci* 237:1289, 1989.
12. Bishop PO: Neurophysiology of binocular single vision
and stereopsis. In Jung R, ed: *Handbook of Sensory
Physiology*, vol 7/3A. Berlin, Springer-Verlag, 1973, p
255.

13. Bishop PO, Pettigrew JD: Neural mechanisms of binocular vision. *Vision Res* 26:1587, 1986.
14. Blake R: A neural theory of binocular rivalry. *Psychol Rev* 96:145, 1989.
15. Blake R, Fox R: The psychophysical inquiry into binocular summation. *Perspect Psychophysiol* 14:161, 1973.
16. Bock O, Kommerell G: Visual localization after strabismus surgery is compatible with the "outflow" theory. *Vision Res* 21:1825, 1986.
17. Breedijk MA, Hoogesteger MF: Physiological suppression and attention. *Doc Ophthalmol* 72:399, 1989.
18. Bridgeman B, Stark L: Ocular proprioception and efference copy in registering visual direction. *Vision Res* 31:1903, 1991.
19. Brock FW, Givner T: Fixation anomalies in strabismus. *Arch Ophthalmol* 47:775, 1952.
20. Burian HM: Studien über zweiäugiges Tiefsehen bei örtlicher Ablendung. *Graefes Arch Clin Exp Ophthalmol* 136:172, 1936.
21. Burian HM: Stereopsis. *Doc Ophthalmol* 5-6:169, 1951.
22. Burian HM: The objective and subjective factors in visual perception. *J Assoc Med Illustrators* 9:4, 1957.
23. Campos E, Bolzani R, Schiavi C, et al: Further evidence for the role of proprioception in space perception. *Doc Ophthalmol* 72:155, 1989.
24. Campos EC: Extraocular muscle proprioception and visual functions: Clinical aspects. In Lennerstrand G, Noorden GK von, Campos EC, eds: *Strabismus and Amblyopia*. London, Macmillan, 1988, p 337.
25. Campos EC, Chiesi C, Bolzani R: Abnormal spatial localization in patients with herpes zoster ophthalmicus. *Arch Ophthalmol* 104:1176, 1986.
26. Campos EC, Enoch JM: Amount of aniseikonia compatible with fine binocular vision: Some old and new concepts. *J Pediatr Ophthalmol Strabismus* 17:44, 1980.
27. Cogan AI: Human binocular interaction: Towards a neural model. *Vision Res* 27:2139, 1988.
28. Colenbrander MC: The limits of stereoscopic vision. *Ophthalmologica* 115:363, 1948.
29. Crawford ML, Blake R, Cool SJ, Noorden GK von: Physiological consequences of unilateral and bilateral eye closure in macaque monkeys: Some further observations. *Brain Res* 84:150, 1975.
30. Crawford ML, Smith EL, Harwerth RS, Noorden GK von: Stereoblind monkeys have few binocular neurons. *Invest Ophthalmol Vis Sci* 25:779, 1984.
31. Crawford ML, Noorden GK von, Mehaig LS, et al: Binocular neurons and binocular function in monkeys and children. *Invest Ophthalmol Vis Sci* 24:491, 1983.
32. Crone RA.: From orthophoria to microtropia. *Br Orthoptics J* 26:45, 1969.
33. Dengis CA, Steinbach MJ, Kraft SP: Registererd eye positions: Short- and long-term effects of botulinum toxin injected into eye muscle. *Exp Brain Res* 119:475, 1998.
34. Dengis CA, Steinbach MJ, Ono H, et al: Ego-center location in children with strabismus: In the median plane and unchanged by surgery. *Invest Ophthalmol Vis Sci* 34:2990, 1993.
35. Donkelaar P van, Gauthier GM, Blouin J, Vercher J-L: The role of ocular muscle proprioception during modification of smooth pursuit output. *Vision Res* 37:769, 1997.
36. Duane A: Projection and double vision: Some new viewpoints. *Arch Ophthalmol* 54:233, 1925.
37. Duane A: Binocular vision and projection. *Arch Ophthalmol* 5:734, 1931.
38. Duane A: Diplopia and other disorders of binocular projection. *Arch Ophthalmol* 7:187, 1932.
39. Du Tour: Pourquoi un objet sur lequel nous fixons les yeux, parait-il unique? *Mem Savants Etrang* 3:514, 4:449, 5:677, 1760; quoted in Helmholtz H von: In Southhall PC, ed: *Helmholtz's Treatise on Physiological Optics*. English translation from 3rd German edition, Ithaca, NY, Optical Society of America, 1924, Quoted from reprint, New York, Dover Publications Vol 3, 1962, p 486.
40. Erkelens CJ, Collewijn H: Eye movements and stereopsis during dichoptic viewing of moving random-dot stereograms. *Vision Res* 25:1689, 1985.
41. Fechner G Th: Über einige Verhältnisse des binokularen Sehens. *Abhandlungen Sächs Ges Wiss* 7:337, 1861.
42. Gauthier GM, Nommay D, Vercher JL: Ocular muscle proprioception and visual localization of targets in man. *Brain* 113:1857, 1990.
43. Hansen AK: "After-image transfer test" in anomalous retinal correspondence. *Arch Ophthalmol* 52:369, 1954.
44. Helmholtz H von: In Southhall PC, ed: *Helmholtz's Treatise on Physiological Optics*. English translation from 3rd German edition, Ithaca, NY, Optical Society of America, 1924, Quoted from reprint, New York, Dover Publications, 1962.
45. Hering E: Beiträge zur Physiologie, vol 3. Leipzig, Wilhelm Engelmann, 1864, p 182.
46. Hering E: Der Raumsinn and die Bewegungen des Auges. In Hermann L, ed: *Handbuch der Physiologie*, vol 3. Leipzig, FCW Vogel, 1879.
47. Hillebrand F: *Lehre von den Gesichtsempfindungen*. Vienna, Springer-Verlag, 1929.
48. Hochberg J: A theory of the binocular cyclopean field: On the possibility of simulated stereopsis. *Percept Mot Skills* 19:685, 1964.
49. Hofmann FB: Die Lehre vom Raumsinn des Auges. In Axenfeld T, Elschnig A, eds: *Graefe-Saemisch's Handbuch der gesamten Augenheilkunde*, ed 2, vol 3. Berlin, Springer-Verlag, 1920-1923, p 245.
50. Hofmann FB, Bielschowsky A: Über die der Willkür entzogenen Fusionsbewegungen der Augen. *Archiv für die gesamte Physiologie* 80:1, 1900.
51. Hubel DH, Wiesel TN: Receptive fields of single neurons in the cat's striate cortex. *J Physiol (Lond)* 148:574, 1959.
52. Hubel DN, Wiesel TN: Receptive fields, binocular interaction and functional architecture in the cat's visual cortex. *J Physiol (Lond)* 160:106, 1962.
53. Hubel DH, Wiesel TN: Stereoscopic vision in macaque monkey: Cells sensitive to binocular depth in area 18 of the macaque monkey cortex. *Nature* 225:41, 1970.
54. Hyson MT, Julesz B, Fender DH: Eye movements and neural remapping during fusion of misaligned random-dot stereograms. *J Opt Soc Am A* 73:1665, 1983.
55. Jaffe NS: Anomalous projection. *Am J Ophthalmol* 36:829, 1953.
56. Jones RK, Lee DN: Why two eyes are better than one: The two views of binocular vision. *J Exp Psychol Hum Percept. Perform* 7:30, 1981.
57. Julesz B: Binocular depth perception of computer-generated patterns. *Bell Syst Tech J* 39:1125, 1960.
58. Julesz B: *The Foundations of Cyclopean Perception*. Chicago, University of Chicago Press, 1971.
59. Lee SH, Blake R: Rival ideas about binocular rivalry. *Vision Res* 39:1447, 1999.
60. Lennerstrand G: Motor and sensory functions of normal and strabismic extraocular muscle. In Lennerstrand G, Noorden GK von, Campos E, eds: *Strabismus and Amblyopia*. London, Macmillan, 1988, p 47.
61. Lennerstrand G, Tian S, Han Y: Functional properties of human eye muscles. Motor and sensory adaptation in strabismus. In Lennerstrand G, Ygge J, eds: *Advances in Strabismus Research: Basic and Clinical Aspects*. Wenner-Gren International Symposium Series. London, Portland Press, 2000, p 3.
62. Lennerstrand G, Tian S, Han Y: Effects of eye muscle

- proprioceptive activation on eye position in normal and exotropic subjects. *Graefes Arch Clin Exp Ophthalmol* 235:93, 1997.
63. Leonards U, Sireteanu R: Interocular suppression in normal and amblyopic subjects: The effect of unilateral attenuation with neutral density filters. *Perception Psychophys* 54:65, 1993.
 64. Leopold DA, Logothetis NK: Activity changes in early visual cortex reflect monkey's percepts during binocular rivalry. *Nature* 379:549, 1996.
 65. Lewis RF, Zee DS: Abnormal spatial localization with trigeminal-oculomotor synkinesis. Evidence for a proprioceptive effect. *Brain* 116:1105, 1993.
 66. Lewis RF, Gaymard BM, Tamargo RJ: Efference copy provides eye position information required for visually guided reaching. *J Neurophysiol* 80:1605, 1998.
 67. Levelt WJM: *On Binocular Rivalry*. Soesterberg, Netherlands, Institute for Perception RVD-TNO, 1965.
 68. Linksz A: Physiology of the eye. In Linksz A: *Vision*, vol 2. New York, Grune & Stratton, 1952.
 69. Maffei L, Fiorentini A: Electrophysiological and behavioral evidence for the role of oculomotor proprioception on visual functions of the cat. *Doc Ophthalmol* 58:97, 1984.
 70. Martens TG, Ogle KN: Observations on accommodative convergence, especially its nonlinear relationships. *Am J Ophthalmol* 47:455, 1959.
 71. Matsubayashi A: Visual space perception. In Graham CH, ed: *Vision and Visual Perception*. New York, John Wiley & Sons, 1965, p 527.
 72. Müller J: *Zur vergleichenden Physiologie des Gesichtsinnes des Menschen und der Thiere nebst einen Versuch über die Bewegungen der Augen and über den menschlichen Blick*. Leipzig, C Knobloch, 1826, p 173.
 73. Münsterberg H: *Das Augenmass*. *Beitr Exp Psychol* 2:125, 1880.
 74. Nikara T, Bishop PO, Pettigrew JD: Analysis of retinal correspondence by studying receptive fields of binocular single units in cat striate cortex. *Exp Brain Res* 6:353, 1968.
 75. Ogle KN: *Researches in Binocular Vision*. Philadelphia, WB Saunders, 1950.
 76. Ogle KN: The optical space-sense. In Davson H, ed: *The Eye*, vol 4. New York, Academic Press, 1962.
 77. Ogle KN, Martens TG, Dyer JA: Oculomotor Imbalance in Binocular Vision and Fixation Disparity. Philadelphia, Lea & Febiger, 1967, p 292.
 78. Panum PL: *Physiologische Untersuchungen über das Sehen mit zwei Augen*. Kiel Schwerssche Buchhandlung, 1858, p 52 ff.
 79. Piantanida TP: Stereo-hysteresis revisited. *Vision Res* 26:431, 1986.
 80. Poggio GF, Fischer B: Binocular interaction and depth sensitivity in striate cortical neurons of behaving rhesus monkey. *J Neurophysiol* 40:1392, 1977.
 81. Poggio GF, Poggio T: The analysis of stereopsis. *Annu Rev Neurosci* 7:379, 1984.
 82. Poggio GF, Talbot WH: Mechanisms of static and dynamic stereopsis in foveal cortex of rhesus monkey. *J Physiol (Lond)* 315:469, 1981.
 83. Poggio GF, Gonzales F, Krause F: Stereoscopic mechanism in monkey visual cortex: Binocular correlation and disparity selectivity. *J Neurosci* 8:4531, 1988.
 84. Porac C, Coren S: Sighting dominance and egocentric localization. *Vision Res* 26:1709, 1986.
 85. Sherrington CS: *The Integrative Action of the Nervous System*. New York, Charles Scribner's Sons, 1906. Reprint, New Haven, Yale University Press, 1947, p 375.
 86. Skavenski AA: Inflow as a source of extraretinal eye position information. *Vision Res* 12:221, 1972.
 87. Skavenski AA, Haddad G, Steinman RM: The extraretinal signal for the visual perception of direction. *Percept Psychophysiol* 11:287, 1972.
 88. Steinbach MJ: Minireview: Proprioceptive knowledge of eye position. *Vision Res* 27:1737, 1987.
 89. Steinbach MJ: Discussion. In Lennerstrand G, Noorden GK von, Campos EC, eds: *Strabismus and Amblyopia*. London, Macmillan, 1988, p 393.
 90. Steinbach MJ: The palisade ending: An afferent source for eye position information. In Lennerstrand G, Ygge J, eds: *Advances in Strabismus Research: Basic and Clinical Aspects*. Wenner-Gren International Symposium Series. London, Portland Press, 2000, p 33.
 91. Steinbach MJ, Smith DR: Spatial localization after strabismus surgery evidence for inflow. *Science* 213:1407, 1981.
 92. Steinbach MJ, Kirschner EL, Arstikaitis MJ: Recession vs. marginal myotomy surgery for strabismus: Effects on spatial localization. *Invest Ophthalmol Vis Sci* 28:1870, 1987.
 93. Swan KC: False projection in comitant strabismus. *Arch Ophthalmol* 73:189, 1965.
 94. Tschermak-Seysenegg A von: *Der exacte Subjektivismus in der neueren Sinnesphysiologie*, ed 2. Vienna, Emil Haim, 1932.
 95. Tschermak-Seysenegg A von: *Introduction to Physiological Optics*. Translated by Boeder P, Springfield IL, Charles C Thomas, 1952.
 96. Velay JL, Bouquerel A: A Motor and perceptual responses to horizontal and vertical eye vibration in humans. *Vision Res* 37:2631, 1997.
 97. Velay JL, Roll R, Lennerstrand G, Roll JP: Eye proprioception and visual localization in humans: Influence of ocular dominance and visual context. *Vision Res* 34:2169, 1994.
 98. Verhoeff FH: A new theory of binocular vision. *Arch Ophthalmol* 13:152, 1935.
 99. Vieth GUA: Über die Richtung der Augen. *Gilberts Ann* 58:233, 1818. Quoted in Helmholtz H von: In Southall PC, ed: *Helmholtz's treatise on physiological optics*. English translation from 3rd German edition, Ithaca, NY, Optical Society of America, 1921. Quoted from reprint, New York, Dover Publications, vol. 3, 1962, p 486.
 100. Westheimer G, McKee SP: Stereoscopic acuity with defocused and spatially filtered retinal images. *J Opt Soc Am A* 70:772, 1980.
 101. Wheatstone C: Contributions to the physiology of vision. Part the first. On some remarkable and hitherto unobserved phenomena of binocular vision. *Philos. Trans R Soc Lond B Biol Sci* 128:371, 1838.
 102. Wolfe JM, Blake R: Monocular and binocular processes in human vision. In Rose D, Dobson V eds: *Models of the Visual Cortex*, New York, John Wiley & Sons, 1985, p 192.

Summary of the Gross Anatomy of the Extraocular Muscles

Descriptions of the gross anatomy of the extraocular muscles can be found readily in standard texts, notably Wolffe's *Anatomy of the Eye*, now in its 8th edition,³ Duke-Elder and Wybar,¹² Whitnall,³⁸ and Fink,¹⁴ to mention only a few. This chapter consists of a brief survey of the gross anatomy of these muscles, which is indispensable for the understanding of how they function in normal and abnormal states.

In humans there are three pairs of extraocular muscles in each orbit: a pair of horizontal rectus muscles, a pair of vertical rectus muscles, and a pair of oblique muscles. The four rectus muscles come from the depth of the orbit and are attached to the sclera anterior to the equator near the cornea. The two oblique muscles approach the globe from in front, at the medial side of the orbit, and continue obliquely and laterally to insert on the sclera posterior to the equator on the temporal part of the globe. Contraction of the rectus muscles pulls the globe backward and nasalward, and contraction of the oblique muscles pulls the globe forward and nasalward. The two directions of pull form an angle of 100° to 110° , open toward the nasal side (Fig. 3-1). On the whole, therefore, a pull nasalward is exerted by the tonus of these muscles that must be balanced by the tension of the temporal part of Tenon's capsule and by the soft tissues nasal to the globe. The backward pull of the rectus muscles is only partly offset by the

forward pull of the oblique muscles in a ratio of 1:5.5 relative to the axis YY' of the globe (see Fig. 3-1) and only in a ratio of 1:12 relative to the axis of the orbit (or the direction of pull of

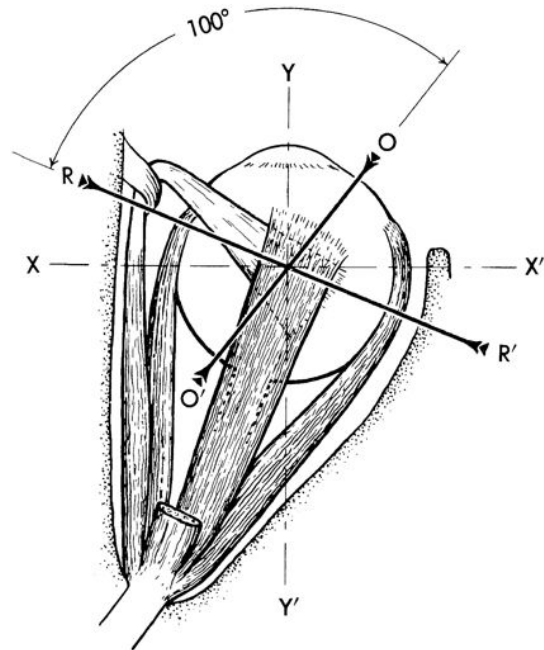


FIGURE 3-1. Relation of the eyes to the pull of the horizontal rectus and oblique muscles, right eye. (Modified from Zoth O: *Augenbewegungen und Gesichtswahrnehmungen*. In Nagel W, ed: *Handbuch der Physiologie des Menschen*, vol 3. Braunschweig, Friedr Vieweg & Sohn, 1905, p 296.)

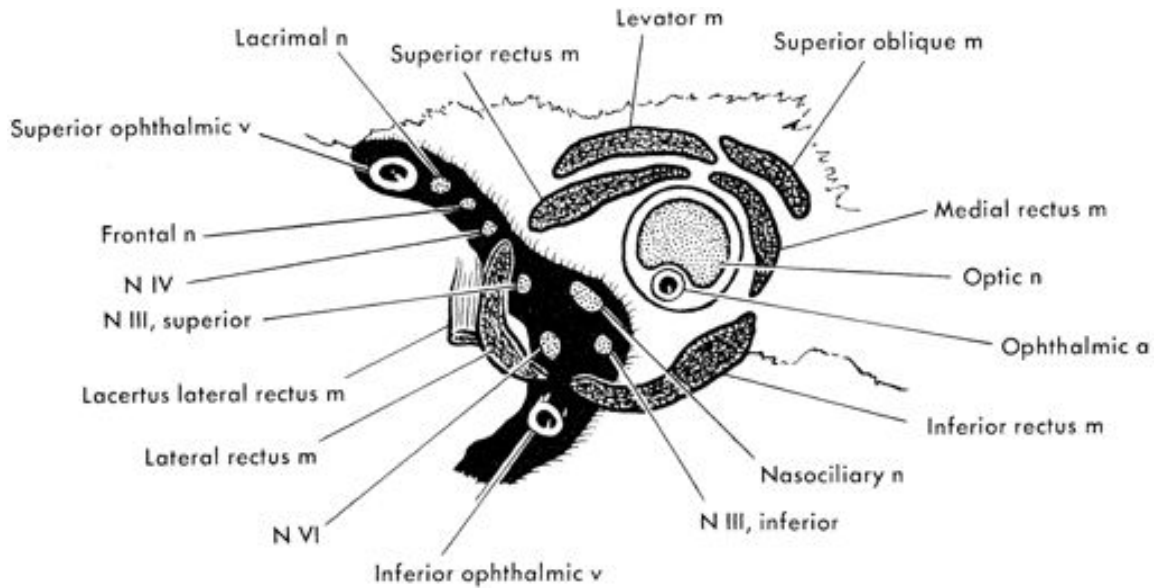


FIGURE 3-2. Posterior aspect of orbit showing topographic relationship of muscle origins in the annulus of Zinn. N, cranial nerve.

the rectus muscles). Here again, Tenon's capsule, fastened to the orbital rim and the retrobulbar tissue, must provide the necessary balance.³⁹

Rectus Muscles

The rectus muscles are more or less flat narrow bands that attach themselves with broad, thin tendons to the globe. There are four of these muscles: the *medial* (internal), the *lateral* (external), the *superior*, and the *inferior*.

The extraocular muscles have delightful synonyms in the old anatomical texts, some of which we cannot refrain from quoting: *medial rectus* (bibitorius, the drinking, because the eyes are crossed while looking at the bottom of the cup); *lateral rectus* (indignatorius, the angry); *superior rectus* (superbus, the proud; pius, the pious, because the upward turning of the eyes expresses devotion); *inferior rectus* (humilis, the humble). The *superior oblique* is also known as patheticus (the pathetic).²⁶ Powell³¹ called the oblique muscles *amatorii, quod sint velut in amore duces et furtivum oculorum jactus promoveant* (for they are as leaders in love and promote furtive glances of the eyes).

The *origins* of the rectus muscles, the superior oblique muscle, and the levator muscle of the upper lid are at the tip of the orbital pyramid. There the origins of the muscles are arranged in a more or less circular fashion (the *annulus of Zinn*), surrounding the optic canal and in part the supe-

rior orbital fissure (Fig. 3-2). Through this oval opening created by the origins of the muscles, the optic nerve, the ophthalmic artery, and parts of cranial nerves III and VI enter the *muscle cone* formed by the body of the rectus muscles.

The interlocking of muscle and tendon fibers at the site of origin creates an extremely strong anchoring of the extraocular muscles. Avulsion of a muscle at the origin is rare even in cases where traction or trauma is sufficiently severe to cause avulsion of the optic nerve.³³ Attachments exist between the origins of the medial and superior recti and the dura of the optic nerve. This explains the pain occurring on eye movements in patients with optic neuritis.³³

The medial and lateral rectus muscles follow the corresponding walls of the orbit for a good part of their course, and the inferior rectus muscle remains in contact with the orbital floor for only about half its length. The superior rectus muscle is separated from the roof of the orbit by the levator muscle of the upper lid.

If the rectus muscles were to continue their course in their original direction, they would not touch the globe; but about 10 mm posterior to the equator, the muscle paths curve toward the globe rather abruptly and eventually insert on the sclera at varying distances from the corneal limbus. The reason for this change in course is musculo-orbital tissue connections (the muscle pulleys; see below). Charpy,⁵ quoting Motais,²⁸ describes how recurrent fibers may detach themselves from the bulbar side of the rectus muscles near their inser-

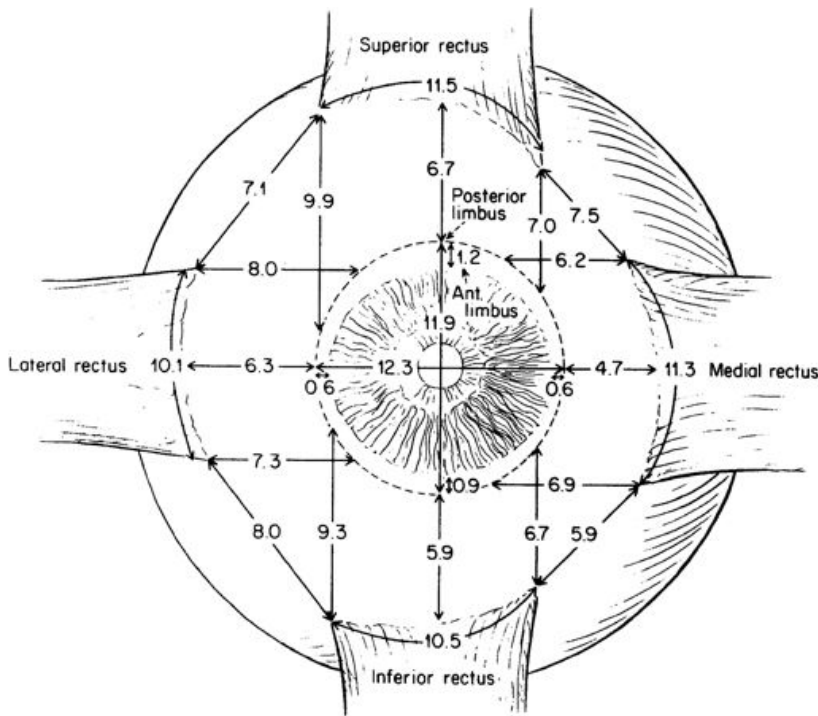


FIGURE 3-3. Insertions of rectus muscles. Average measurements are in millimeters. (Data from Apt L: An anatomical evaluation of rectus muscle insertions. *Trans Am Ophthalmol Soc* 78:365, 1980.)

tion, attaching themselves to the sclera 1 to 5 mm behind the insertions. Scobee³² called these attachments *footplates* and attributed considerable importance to them in the etiology of esotropia (see Chapter 9).

Because the insertions of the rectus muscles are not equidistant from the corneal limbus, they do not lie on a circle that is concentric with it but rather on a spiral (the *spiral of Tillaux*). The insertion of the medial rectus muscle is closest to the corneal limbus, followed by the inferior, lateral, and superior rectus insertions, with the superior rectus insertion being the most distant (Fig. 3-3).

The lines of insertion are generally not straight, but are more or less curved and sometimes even wavy. The straightest ones are the insertions of the medial and lateral rectus muscles, but these too are often slightly convex toward the corneal limbus. Fuchs¹⁵ found in 50 cadaver eyes that in half the cases the horizontal meridian cut the insertions symmetrically. For the rest of the cases, up to two thirds of the width of the tendon of the medial rectus muscle was above the horizontal meridian and that of the lateral rectus muscle was below it. Fuchs found also that the insertion line of these muscles was perpendicular to the horizontal meridian in less than half the eyes. In the others the insertion lines ran obliquely up and in, in the case of the medial rectus, and up and out, in the case of the lateral rectus.

The lines of insertion of the superior and infe-

rior rectus muscles are markedly convex toward the corneal limbus and run obliquely upward and laterally. The rounded, temporal ends of their insertions therefore are more distant from the corneal limbus than their nasal ends. The amount of obliquity varies in different eyes but is usually marked and, according to Fuchs,¹⁵ is usually of the same degree for the two muscles of the same eye. The lines of insertion are cut asymmetrically by the vertical meridian. The greater part of the tendon (two thirds of its width according to Fuchs) of the superior rectus lies temporal to the meridian. In one third of the eyes, Fuchs found that the meridian bisected the inferior rectus tendon; otherwise, the larger segment of the insertion line was found to lie lateral to it.

The normal distance between muscle insertion and limbus is of importance during operations and reoperations on the extraocular muscles. Data based on measurements taken by Apt¹ from cadaver eyes of adult subjects (mean age, 60.3 years) are shown in Figure 3-3 and Table 3-1. The *anterior limbus* was defined by Apt as the transition from clear cornea to gray and the *posterior limbus* as the transition from gray cornea to white sclera. While the means are similar to those of another recent study,²³ the range of variations between data reported elsewhere in the literature is remarkable.^{15, 16, 22, 24, 35} The experienced surgeon is aware how often differences of several millimeters from the norms shown in Figure 3-3 can be found.

TABLE 3-1. Distance from Limbus to Rectus Muscle Insertions

	Mean \pm SD (mm)	Range (mm)
Medial rectus insertion		
Anterior limbus to midpoint of insertion	5.3 \pm 0.7	3.6–7.0
Posterior limbus to midpoint of insertion	4.7 \pm 0.6	3.0–6.4
Inferior rectus insertion		
Anterior limbus to midpoint of insertion	6.8 \pm 0.8	4.8–8.5
Posterior limbus to midpoint of insertion	5.9 \pm 0.8	3.9–7.6
Lateral rectus insertion		
Anterior limbus to midpoint of insertion	6.9 \pm 0.7	5.4–8.5
Posterior limbus to midpoint of insertion	6.3 \pm 0.6	4.8–7.9
Superior rectus insertion		
Anterior limbus to midpoint of insertion	7.9 \pm 0.6	6.2–9.2
Posterior limbus to midpoint of insertion	6.7 \pm 0.6	5.0–8.0

From Apt L: An anatomical evaluation of rectus muscle insertions. *Trans Am Ophthalmol Soc* 78:365, 1980.

Since a topographic correlation exists between the location of the tendon insertion and the ora serrata and since the distance of the ora from the limbus depends on the anteroposterior diameter of the globe,^{36, 37} the distance of the tendon from the limbus may be influenced by age and axial refractive errors of the eye.¹⁵ If these variations in the location of the insertion are not taken into account (see Table 3-1), the value of geometric calculations in predicting the results of surgery on the action of the extraocular muscles is limited. For instance, the effect of a 4-mm muscle recession will vary significantly with the distance of the anatomical insertion from the limbus. These considerations apply especially when considering the effect of muscle surgery in infants. Table 3-2 shows a substantial difference in mean anatomical data obtained from adult and newborn eyes. According to Souza-Dias and coworkers,³⁵ age differ-

ences in the distance between limbus and insertion can be neglected in strabismus operations in children older than 6 months. In view of the fact that the longitudinal growth of the eye is not completed by that age, we take a more conservative view and would put the age at which adult dosages of strabismus surgery may be applied at 2 years and older.

The length of the rectus muscles exclusive of tendon is fairly constant, but there are variations between the width of the insertion and the length of tendon of the different muscles (Table 3-3). Other anatomical data of importance to the kinematics of the eye are discussed in Chapter 4.

Muscle Pulleys

Modern imaging techniques such as computed tomography (CT) scanning³⁴ and magnetic resonance imaging (MRI)^{6, 10, 27} have revealed that the paths of the rectus muscles remain fixed relative to the orbital wall during excursions of the globe and even after large surgical transpositions.^{7, 8} Only the anterior aspect of the muscle moves with the globe relative to the orbit, as it must on account of its scleral attachment. In other words, there is no sideslip of the rectus muscles in relation to the orbital walls when the eye moves from primary into secondary gaze positions (Fig. 3-4). Demer and coworkers¹⁰ suspected from these findings that there must be musculo-orbital coupling through tissue connections that constrain the muscle paths during rotations of the globe. Subsequent studies with high-resolution MRI confirmed this notion by demonstrating retroequatorial inflections of the rectus muscle paths^{6, 10} (Fig. 3-5). Gross dissection of orbits and histologic and histo-

TABLE 3-2. Comparative Measurements of Medial and Lateral Rectus Muscles in Adults* and Newborns†

	Medial Rectus Muscle	Lateral Rectus Muscle
Length	37.7 (28)‡	36.3 (31.6)
Width	10.4 (7.9)	9.6 (6.9)
Distance from limbus (middle of insertion)	5.7 (3.9)	7.5 (4.8)

*Data from Lang J, Horn T, Eichen U von den: Über die äusseren Augenmuskeln und ihre Ansatzzonen. *Gegenbaurs Morphol Jahrb* 126:817, 1980.

†Data Weiss L: Über das Wachstum des menschlichen Auges und über die Veränderungen der Muskelinsertionen am wachsenden Auge. *Anat Hefte* 25 (pt 1):191, 1897; Schneller F: Anatomisch-physiologische Untersuchungen über die Augenmuskeln Neugeborener. *Graefes Arch Clin Exp Ophthalmol* 47:178, 1899.

‡Measurements from newborn in parentheses.

TABLE 3-3. Means and Range (in parentheses) of Measurements of Rectus Muscles (mm)*

	Medial Rectus Muscle	Inferior Rectus Muscle	Lateral Rectus Muscle	Superior Rectus Muscle
Length†	37.7 (32.0–44.5)	37.0 (33.0–42.5)	36.3 (27.0–42.0)	37.3 (31.0–45.0)
Length of tendon	3.0 (1.0–7.0)	4.7 (3.0–7.0)	7.2 (4.0–11.0)	4.3 (2.0–6.0)
Width of tendon	10.4 (8.0–13.0)	8.6 (7.0–12.0)	9.6 (8.0–13.0)	10.4 (7.0–12.0)

From Lang J, Horn T, Eichen U von den: Über die äusseren Augenmuskeln und ihre Ansatzzonen. Gegenbaurs Morphol Jahrb 126:817, 1980.

*Data from right eye.

†Exclusive of tendon.

chemical studies^{10, 30} showed that these inflections are caused by musculo-orbital tissue connections in the form of fibroelastic sleeves that consist of smooth muscle, collagen, and elastin. During contraction the muscles travel through these sleeves which act as *pulleys* by restraining the muscle paths. The *orbital layer* of the rectus muscle inserts directly on the pulley, whereas the *global layer* continues anteriorly to insert into the sclera.

These pulleys are located in a coronal plane anterior to the muscle bellies and about 5 to 6 mm posterior to the equator. They are compliant rather than rigid, receive rich innervation involving numerous neurotransmitters in humans and monkeys,^{9, 11} and change their positions as a function of gaze direction. For instance, the pulleys of the horizontal rectus muscle move posteriorly during muscle contraction.⁸ This adjustability of pulley positions and the different insertion sites of the global and orbital layers of extraocular muscles may play a major but still undefined role in ocular kinematics.^{8, 9, 30}

The demonstration of muscle pulleys is incom-

patible with the classic view according to which the direction of pull of a rectus muscle is determined by its functional insertion at the point of tangency with the globe and its origin at the annulus of Zinn.¹⁰ Actually, the functional origin of a rectus muscle is located at its pulley. It follows that atypical location of a pulley (see Chapter 19) or pathologic conditions that may influence pulley function may cause certain forms of strabismus. Moreover, the finding of stability of the muscle paths during excursions of the globe through muscle pulleys may change our concepts about the function of the rectus muscles in tertiary gaze. Further reference to the muscle pulleys is made in the appropriate sections of this book.

Oblique Muscles

From its origin above and medial to the optic foramen, the *superior oblique muscle* courses anteriorly in a line parallel with the upper part of the medial wall of the orbit, reaching the trochlea at the angle between the superior and medial wall.

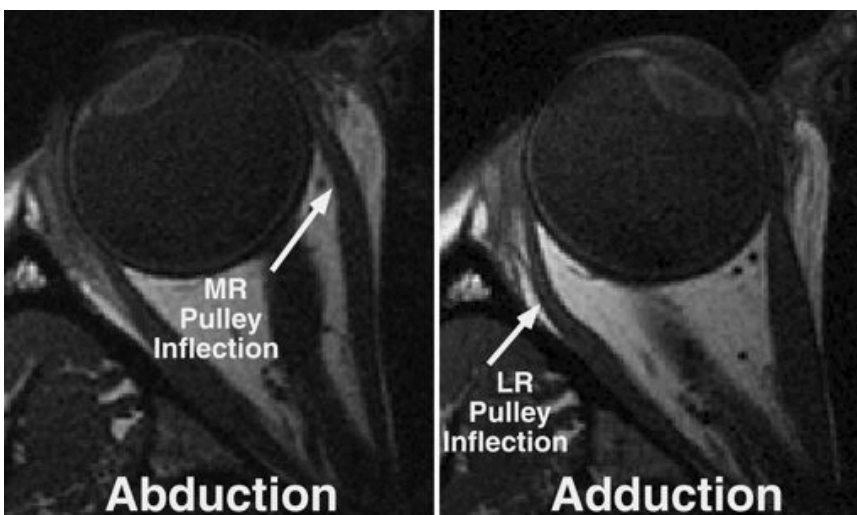


FIGURE 3-4. Two-mm-thick, 320- μ m resolution axial MRI scan of a normal left orbit showing the inflection of the horizontal rectus muscles as they pass through their respective pulleys during abduction and adduction. MR, medial rectus; LR; lateral rectus. (From Demer JL: Orbital connective tissue in binocular alignment and strabismus. In Lennerstrand G, Ygge J, eds: *Advances in Strabismus*, Proceedings of International Symposium at the Wenner-Gren Center, Stockholm, June 1999. London, Portland Press, 2000, p 17.)

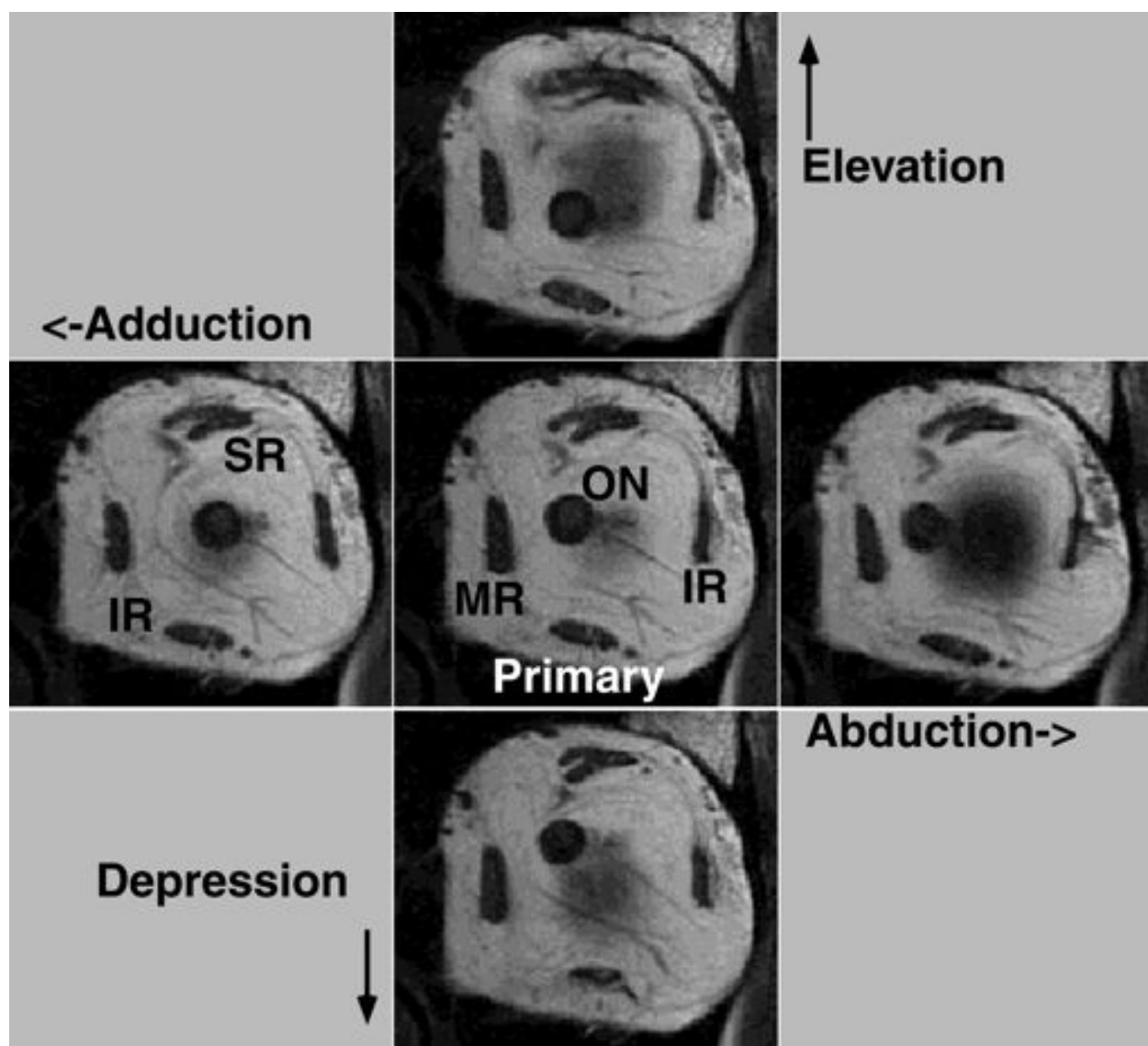


FIGURE 3-5. Two-mm-thick, 320- μm resolution axial MRI scan of normal left orbit in primary and secondary gaze positions, showing near constancy of the positions of the rectus muscles posterior to the pulleys. IR, inferior rectus; SR, superior rectus; MR, medial rectus; LR, lateral rectus; ON, optic nerve. Note stability of the coronal sections of the rectus muscles but movement of the section of the optic nerve in secondary gaze positions. (Courtesy of Dr. J.L. Demer, Los Angeles.)

The trochlea is a tube 4 to 6 mm long formed in its medial aspect by bone (the trochlear fossa of the frontal bone). The rest of the circumference is composed of connective tissue that may contain cartilaginous or bony elements. After passing the trochlea, the superior oblique muscle turns in laterodorsally, forming an angle of about 54° with the *pretrochlear* or direct portion of the muscle.

A fibrillar, vascular sheath surrounds the intra-trochlear superior oblique tendon. This portion of the tendon consists of discrete fibers with few interfibrillar connections, as reported by Helveston and coworkers.²¹ Each fiber of the tendon moves through the trochlea in a sliding, telescoping fashion with the central fibers undergoing maximal

and the peripheral fibers the least excursion. The total travel of the central fibers appears to be 8 mm in either direction.²⁰

Helveston and coworkers²¹ also described a bursa-like structure lying between the trochlear “saddle” and the vascular sheath of the superior oblique tendon and postulated that pathologic alterations of the bursa may be a factor in the etiology of Brown syndrome (see Chapter 21).

At about the distal third of the direct portion (10 mm behind the trochlea), the muscle becomes tendinous and remains tendinous in its entire *post-trochlear* or reflected part. The tendon passes under the superior rectus muscle, fans out, and merges laterally with the sclera to the vertical

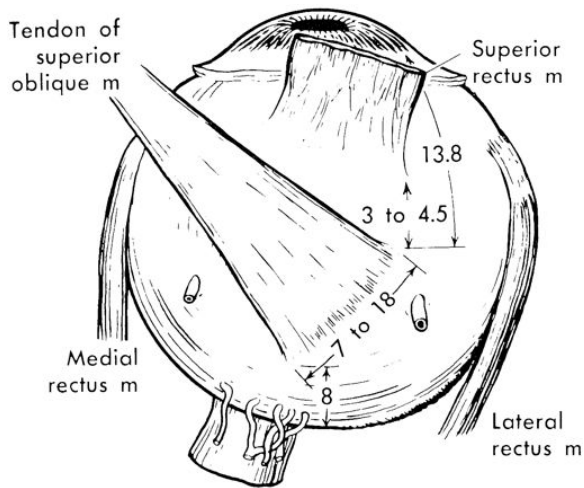


FIGURE 3-6. Relationships of tendons of superior oblique muscle. Measurements are in millimeters. (Modified from Fink WH: *Surgery of the Vertical Muscles of the Eyes*, ed 2. Springfield, IL, Charles C Thomas, 1962.)

meridian, forming a concave curved line toward the trochlea (Fig. 3-6). The anterior end of the insertion lies 3.0 to 4.5 mm behind the lateral end of the insertion of the superior rectus muscle and 13.8 mm behind the corneal limbus. The posterior end of the insertion lies 13.6 mm behind the medial end of the insertion of the superior rectus muscle and 18.8 mm behind the corneal limbus. The width of the insertion of the superior oblique muscle varies greatly (from 7 to 18 mm, Fink¹⁴) but is 11 mm on average. The medial end of the insertion lies about 8 mm from the posterior pole of the globe. Near its insertion the posterior border of the muscle is related to the superior vortex vein.

The length of the direct part of the superior oblique muscle is about 40 mm and that of the reflected tendon is about 19.5 mm. *From a physiologic and kinematic standpoint, the trochlea is the origin of the muscle.*

The *inferior oblique muscle* is the shortest of all the eye muscles, being only 37 mm long. It arises in the anteroinferior angle of the bony orbit in a shallow depression in the orbital plate of the maxilla near the lateral edge of the entrance into the nasolacrimal canal. The origin is readily located by drawing a perpendicular line from the supraorbital notch to the lower orbital margin.

The muscle continues from its origin backward, upward, and laterally, passing between the floor of the orbit and the inferior rectus muscle. It inserts by a short tendon (1 to 2 mm) in the posterior and external aspect of the sclera. The width of the insertion varies widely (5 to 14 mm, Fink¹⁴) and may be around 9 mm on average. The

insertion forms a curved concave line toward the origin of the muscle. Its anterior margin is about 10 mm behind the lower edge of the insertion of the lateral rectus muscle; its posterior end is 1 mm below and 1 to 2 mm in front of the macula (Fig. 3-7). Near its insertion the posterior border of the muscle is related to the inferior vortex vein.

Unlike the other extraocular muscles, especially the superior obliques, which have both muscular and tendinous components, the inferior oblique is almost wholly muscular. It forms an angle of about 51° with the vertical plane of the globe.

Fascial System

Tenon's Capsule

The eyeball is suspended within the orbit by a system of fasciae. The way in which this is achieved represents an ideal solution to the problem of suspending a spheroid body in a cone-shaped cavity. The bulk of the system is made up of Tenon's capsule, which is a condensation of fibrous tissue that covers the eyeball from the entrance of the optic nerve to near the corneal limbus, where it is firmly fused with the conjunctiva. Except for this area of fusion, the two structures are separated by the *subconjunctival space*. Tenon's capsule is also separated from the sclera. Between the two is the *episcleral space (Tenon's space)*, which can be readily injected (Fig. 3-8). On its outer aspect the capsule is intimately related to the orbital reticular tissue. Its posterior edge is

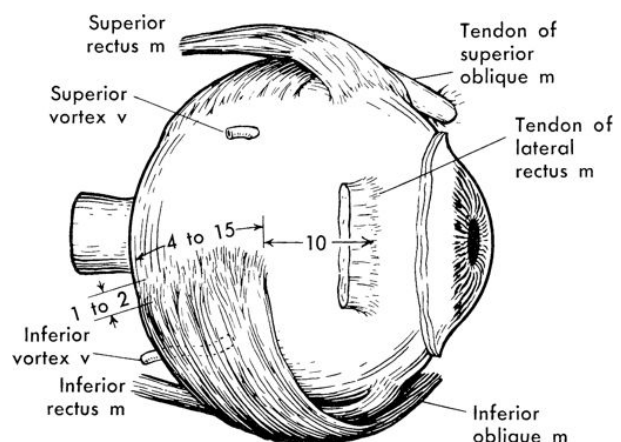


FIGURE 3-7. Course of inferior oblique muscle and the relationships of its tendon. Measurements are in millimeters. (Modified from Fink WH: *Surgery of the Vertical Muscles of the Eyes*, ed 2. Springfield, IL, Charles C Thomas, 1962.)

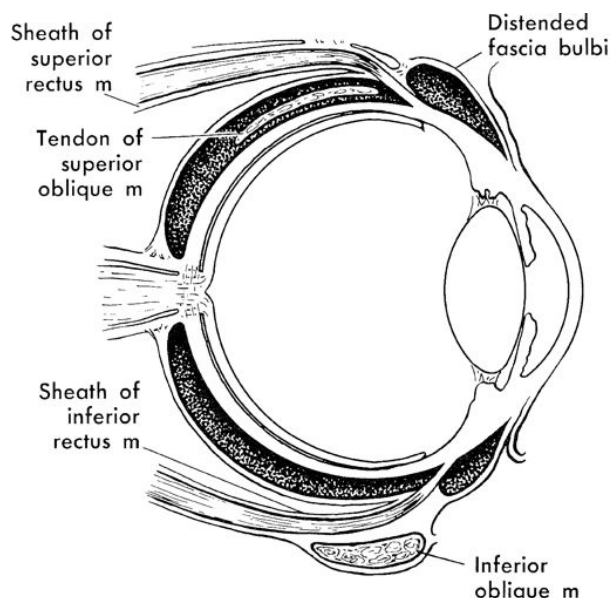


FIGURE 3-8. Tenon's space shown by injection with India ink. (Modified from Charpy A: *Muscles et capsule de Tenon*. In Poirier P, Charpy A, eds: *Traité d'anatomie humaine*, new ed, vol 5/2. Paris, Masson, 1912, p 539.)

not clearly delineated; it is thin and more or less continuous with the meshwork of the orbital fat.

If the globe is enucleated, one can see the *anterior orifice* of Tenon's capsule, the borders of which were attached to the sclera before enucleation; the *posterior orifice*, which is fused with the sheaths of the optic nerve; and the smooth inner surface with the slits of entry for the extraocular muscles. The openings for the vortex veins are small and not readily visualized (Fig. 3-9).

Muscle Sheaths and Their Extensions

The extrinsic ocular muscles pierce Tenon's capsule, enter the subcapsular space, and insert into

the sclera. Therefore, one can distinguish an *extracapsular* and an *intracapsular portion* of each muscle.

In their extracapsular portions, the extrinsic eye muscles are enveloped by a *muscle sheath*. This sheath is a reflection of Tenon's capsule and runs backward from the entrance of the muscles into the subcapsular space for a distance of 10 to 12 mm. At the lower aspect of the entrance, Tenon's capsule is reduplicated. At the upper aspect, it continues forward as a single membrane (Fig. 3-10). The muscle sheaths of the four rectus muscles are connected by a formation known as the *intermuscular membrane*, which closely relates these muscles to each other (Fig. 3-11). In addition, there are numerous extensions from all the sheaths of the extraocular muscles, which form an intricate system of fibrous attachments interconnecting the muscles, attaching them to the orbit, supporting the globe, and checking the ocular movements. These will now be described in their essential features.

The *fascial sheath of the superior rectus muscle* closely adheres in its anterior external surface to the undersurface of the sheath of the levator muscle of the upper lid. In front of the equator the sheath of the superior rectus muscle also sends a separate extension obliquely forward that widens and ends on the lower surface of the levator muscle. The fusion of the two muscles accounts for the cooperation of upper lid and globe in elevation of the eye, a fact that must be kept in mind when surgical procedures on the superior rectus muscle are being considered.

The *fascial sheath of the inferior rectus muscle* divides anteriorly into two layers: an upper one, which becomes part of Tenon's capsule, and a

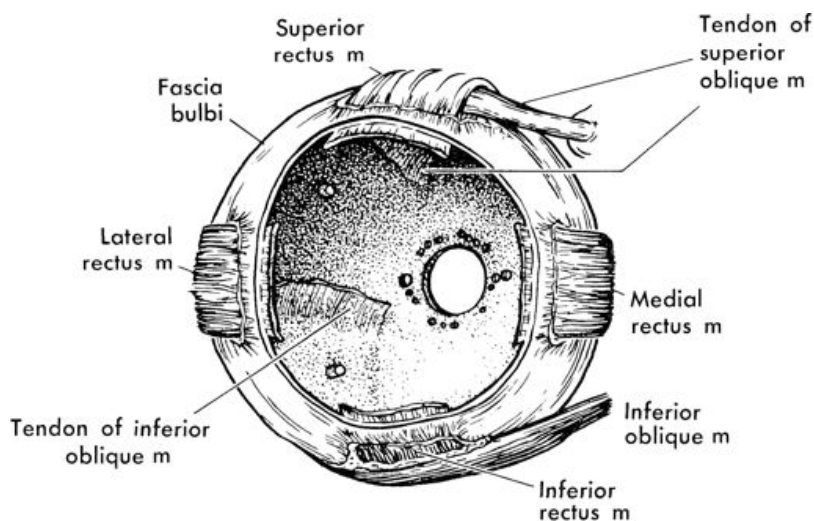


FIGURE 3-9. Anterior and posterior orifice of Tenon's capsule shown after enucleation of the globe. (Modified from Charpy A: *Muscles et capsule de Tenon*. In Poirier P, Charpy A, eds: *Traité d'anatomie humaine*, new ed, vol 5/2. Paris, Masson, 1912, p 539.)

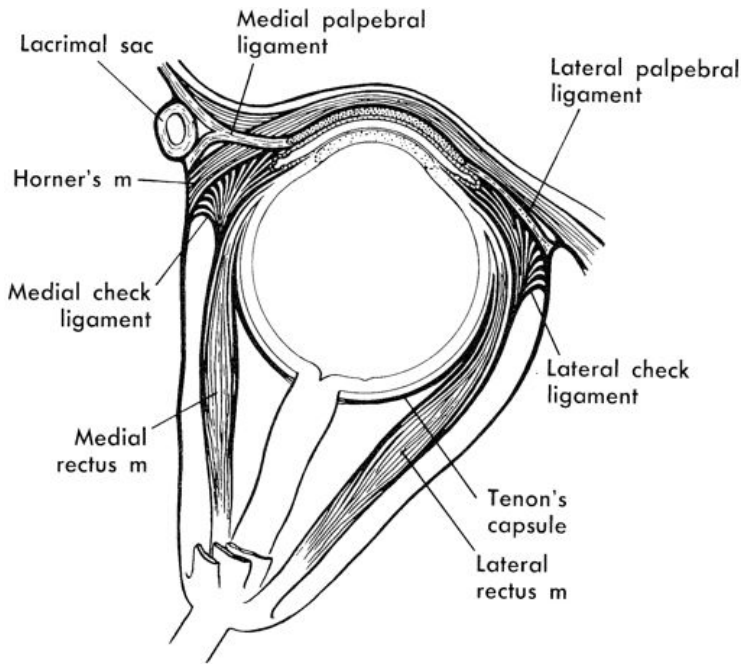


FIGURE 3-10. Check ligaments of medial and lateral rectus muscles. Reduplication of Tenon's capsule, forming the muscle sheath of the rectus muscles.

lower one, which is about 12 mm long and ends in the fibrous tissue between the tarsus of the lower lid and the orbicularis muscle (Figs. 3-11 and 3-12). This lower portion forms part of Lockwood's ligament.

The *fascial sheath of the reflected tendon of the superior oblique muscle* consists of two layers of strong connective tissue (Fig. 3-13). The two layers are 2 to 3 mm thick, so the tendon and its sheath have a diameter of about 5 to 6 mm. The potential space between the sheath and the tendon is continuous with the episcleral space. Material injected into Tenon's space therefore may penetrate into the space between tendon and sheath.² Many attachments extend from the sheath of the

superior oblique muscle to other areas: to the sheath of the levator muscle, to the sheath of the superior rectus muscle, to the conjoined sheath of these two muscles, and to Tenon's capsule, behind, above, and laterally. The numerous fine fibrils that connect the inner surface of the sheath to the tendon are an important feature (see Fig. 3-13). Some authors^{19, 29} have rejected the idea of the superior oblique tendon having a separate sheath and favor the view that what appears to be sheath are actually reflections of anterior and posterior Tenon's capsule. This concept is of interest in connection with the etiology of Brown syndrome.

The *fascial sheath of the inferior oblique muscle* covers the entire muscle. It is rather thin at the

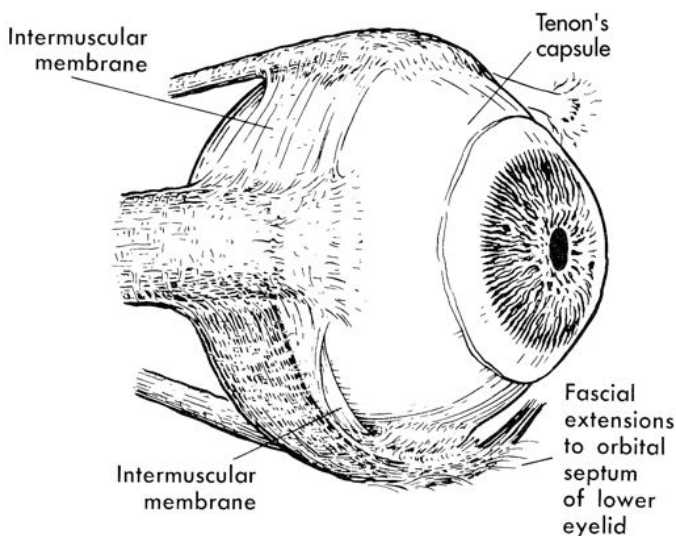


FIGURE 3-11. Intermuscular membranes and fascial extensions of the superior, lateral, and inferior rectus muscles (right eye).

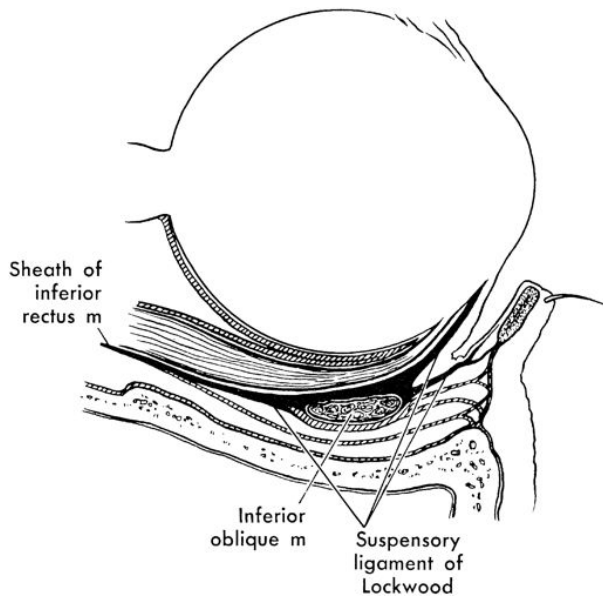


FIGURE 3-12. Fascial sheath of the inferior rectus muscle and Lockwood's ligament.

origin but thickens as the muscle continues laterally and develops into a rather dense membrane where it passes under the inferior rectus muscle. At this point, the sheath of the inferior oblique muscle fuses with the sheath of the inferior rectus muscle (see Fig. 3-12). This fusion may be quite firm and complete or so loose that the two muscles may be relatively independent of each other. Near the insertion of the muscle the sheath of the inferior oblique muscle also sends extensions to the sheath of the lateral rectus muscle and to the sheath of the optic nerve.

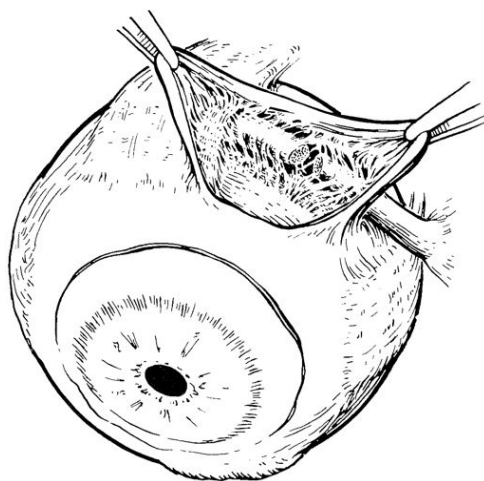


FIGURE 3-13. Fascial sheath of the reflected tendon of the superior oblique muscle. (Modified from Berke RN: Tenotomy of the superior oblique for hypertropia [preliminary report]. *Trans Am Ophthalmol Soc* 44:304, 1946.)

Ligament of Lockwood

The blending of the sheaths of the inferior oblique and inferior rectus muscles and the extensions that go from there upward on each side to the sheaths of the medial and lateral rectus muscles form a suspending hammock, which supports the eyeball. This part of the fascial system has been termed the *suspensory ligament of Lockwood*. Extensions of fibrous bands to the tarsal plate of the lower lid, the orbital septum, and the periosteum of the floor of the orbit also form part of Lockwood's ligament (see Fig. 3-12).

Check Ligaments

The medial and lateral rectus muscles possess well-developed fibrous membranes that extend from the outer aspect of the muscles to the corresponding orbital wall.

The check ligament of the *lateral rectus muscle* appears in horizontal sections as a triangle, the apex of which is at the point where the sheath of the muscle pierces Tenon's capsule. From there it goes forward and slightly laterally, fanning out to attach to the zygomatic tubercle, the posterior aspect of the lateral palpebral ligament, and the lateral conjunctival fornix (see Fig. 3-10).

The check ligament of the *medial rectus muscle* extends from the sheath of the muscle, attaching to the lacrimal bone behind the posterior lacrimal crest and to the orbital septum behind. It is triangular and unites at its superior border with a strong extension from the sheath of the levator muscle and a weaker extension from the sheath of the superior rectus muscle. The inferior border is fused to extensions from the inferior oblique and inferior rectus muscle sheaths.

The other extraocular muscles do not have clearly distinct check ligaments such as those of the medial and lateral rectus muscles. However, the various extensions of the muscle sheaths to the sheaths of other muscles, the orbital wall, and Tenon's capsule undoubtedly fulfill the task of checking the action of these muscles. Actually, it has been said (with considerable truth) by Duke-Elder,^{12, p. 451} who quotes Dwight,¹³ that the complexities of Tenon's capsule are limited only by the perverted ingenuity of those who describe it.

Intracapsular Portion of the Muscle

The muscles move freely through the openings in Tenon's capsule. In the intracapsular portion,

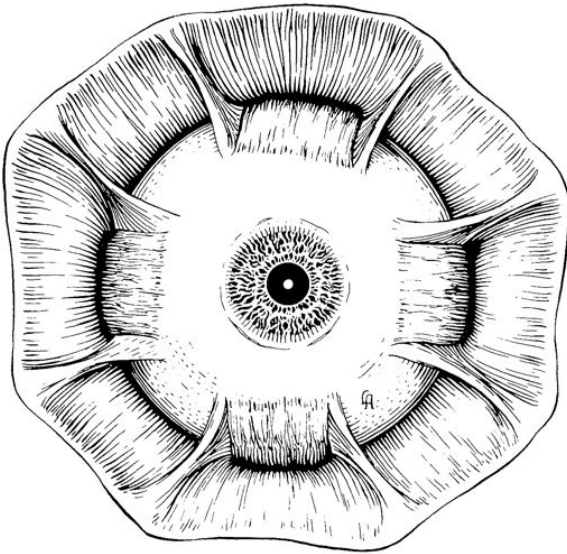


FIGURE 3–14. The falciform folds of Guérin, one on each side of the rectus muscles. (Modified from Guérin G: *Mémoire sur la myotomie oculaire par la méthode sous-conjonctivale*. Gazette Med Paris, 1842.)

which for the rectus muscles is 7 to 10 mm in length, they have no sheath but are covered by episcleral tissue fused with the perimysium. This tissue expands laterally, going along the muscle on each side, from the entry of the muscle into the subcapsular space to the insertion. Posteriorly, this tissue attaches to the capsule and laterally to the sclera. At the tendon this tissue becomes rather dense and appears to serve to fixate the tendon, forming the *falciform folds* of Guérin¹⁷ or *adminicula* of Merkel^{25, 26} (Fig. 3–14). Merkel and Kallius remarked that these structures make it difficult to determine accurately the width of the insertions.

Functional Role of the Fascial System

Aside from its role in connecting the globe with the orbit and of supporting and protecting it, the main task of Tenon's capsule is to serve as a cavity within which the eyeball may move. Helmholtz¹⁸ compared the movements of the eyeball in Tenon's capsule to the movements of the head of the femur in the cotyloid fossa. However, Tenon's capsule does not have the anatomical characteristics of synovial tissue, nor is it a serous membrane.

The complicated system of fasciae and ligaments is of considerable importance in the control of the eye movements. It prevents or reduces retractions of the globe, as well as movements in the direction of action of the muscle pull. Thus, the position of the center of rotation of the eyeball

remains fairly constant in relation to the orbital pyramid (see Chapter 4). Also, owing particularly to the action of the check ligaments, the eye movements become smooth and dampened. As the muscles contract, their action is graduated by the elasticity of their check systems, which limits the action of the contracting muscle and reduces the effect of relaxation of the opposing muscles (see Sherrington's law, Chapter 4, p. 63). This ensures smooth rotations and lessens the shaking up of the contents of the globe when the eyes suddenly stop or change the direction of their movement.

Developmental Anomalies of Extraocular Muscles and the Fascial System

Gross developmental anomalies of the extraocular muscles are infrequent. The cases recorded in the literature are grouped together and reported with great completeness by Duke-Elder^{12, p. 979} Many of these reports are fascinating, but it would serve no useful purpose to discuss them in this book. Unless the anomaly is extreme, such as the total absence of a muscle, it is not likely to have a major effect on the coordination of the eye movements or on the relative position of the eyes, since even the experimental transposition of various extraocular muscles does not permanently destroy this coordination.

Patients with congenital absence of a muscle present with the clinical picture of complete paralysis (see Chapter 20). There may be no preoperative clues to alert the surgeon that the apparently paralyzed muscle is absent. Consequently, the surgeon must be prepared to use alternative surgical approaches if a muscle cannot be located at the time of the operation.

Anomalies of the fascial system are more common than those of the muscles, and it is probable that they have functionally, and therefore clinically, a more profound effect on the ocular motility. These anomalies act as a check to active and passive movements of the globe in certain directions, although the muscles that should produce the active movement may be quite normal anatomically and functionally. To this group belong a number of clinical entities, such as the various forms of strabismus fixus and the superior oblique tendon sheath syndrome of Brown,⁴ which are discussed in Chapter 21.

Innervation of Extraocular Muscles

The medial, superior, and inferior rectus muscles and the inferior oblique muscle are all innervated by cranial nerve III, the oculomotor nerve. The branches enter their respective muscles from the bulbar side. The branches intended for the medial rectus muscle enter its belly 15 mm from the origin of the muscle; those for the inferior rectus muscle enter at the junction of the posterior and middle third of the belly; and those for the inferior oblique muscle enter just after the muscle passes lateral to the inferior rectus muscle. All these branches are innervated by the inferior division of cranial nerve III.

The branches for the superior rectus muscle originate from the upper division of the oculomotor nerve and enter the muscle at the junction of the posterior and middle thirds (Fig. 3-15). The lateral rectus muscle is innervated by cranial nerve VI, the abducens nerve, which enters the muscle 15 mm from its origin on the bulbar side (see Fig. 3-15).

The superior oblique muscle differs from the other five extraocular muscles in that cranial nerve IV, the trochlear nerve, which innervates it, enters

the muscle from the outer (orbital) surface near the lateral border after crossing over from the medial side. The nerve divides into three or four branches. The most anterior branch enters the belly at the juncture of the posterior and middle third of the muscle and the most posterior at about 8 mm from its origin (see Fig. 3-15).

Sensory organs have been described in the extraocular muscles. They presumably provide a more or less defined stretch effect. Although the innervation of these organs has not been followed in humans, it is likely to take the route of the ophthalmic division of the trigeminal nerve.

Blood Supply of Extraocular Muscles

All extraocular muscles are supplied by the lateral and medial muscular branches of the ophthalmic artery. The lateral branch supplies the lateral and superior rectus muscles, the levator muscle of the upper lid, and the superior oblique muscle. The medial branch, the larger of the two, supplies the inferior and medial rectus muscles and the inferior oblique muscle. The inferior rectus muscle and the inferior oblique muscle also receive a branch

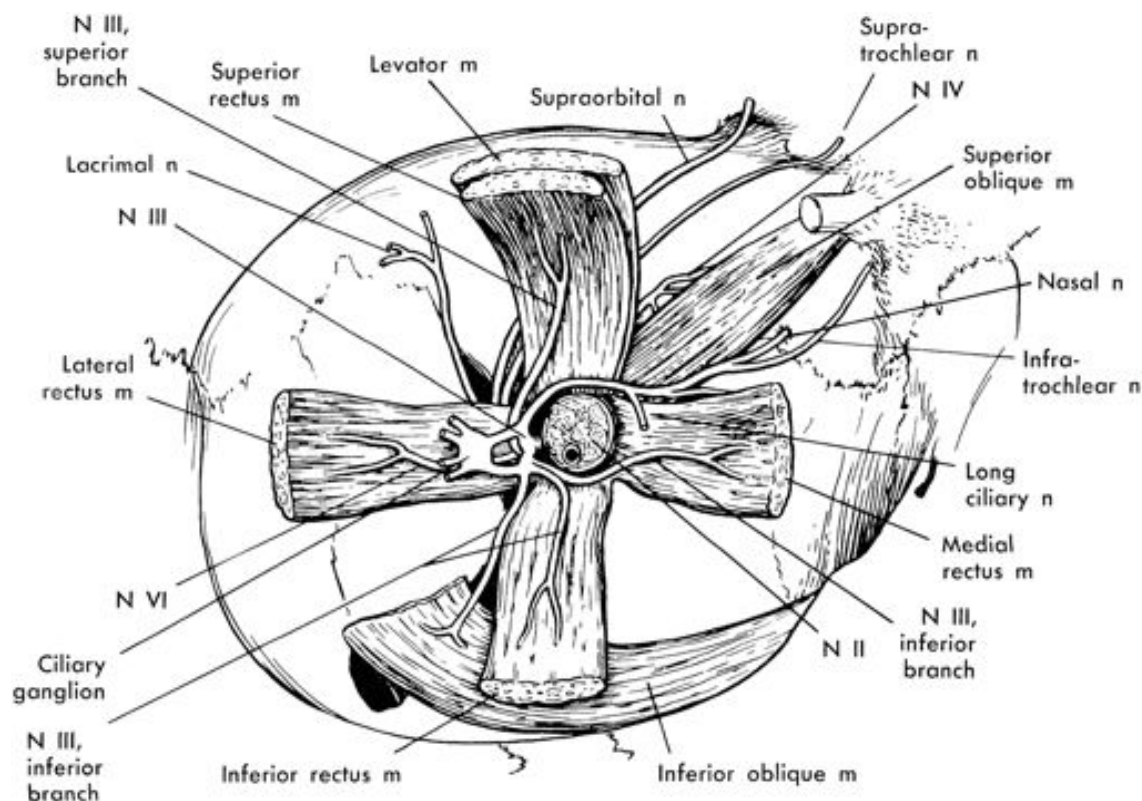


FIGURE 3-15. Innervation of the extraocular muscles. N, cranial nerve.

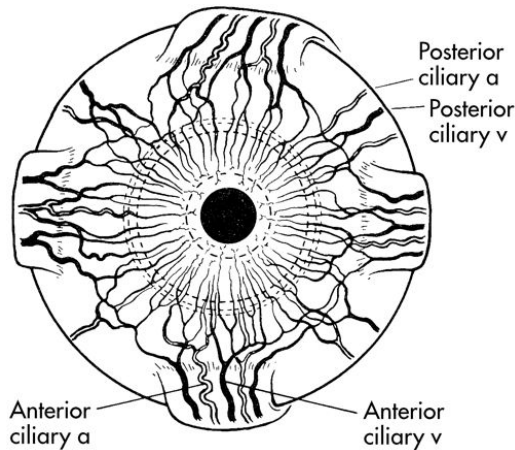


FIGURE 3-16. The anterior ciliary arteries. (From Last RJ: *Wolff's Anatomy of the Eye and Orbit*, ed 6. Philadelphia, HK Lewis, 1968.)

from the infraorbital artery, and the medial rectus muscle receives a branch from the lacrimal artery.

The arteries to the four rectus muscles give rise to the anterior ciliary arteries. Two arteries emerge from each tendon, except for the lateral rectus muscle, which has only one. There are exceptions to this rule, however, as any muscle surgeon can readily confirm. Variations in the number of anterior ciliary arteries supplied by each muscle become clinically relevant with regard to the anterior segment blood supply when disinserting more than two rectus muscle tendons during muscle surgery (see Chapter 26).

The anterior ciliary arteries pass to the episclera, give branches to the sclera, limbus, and conjunctiva, and pierce the sclera not far from the corneoscleral limbus (Fig. 3-16). These perforating branches cross the suprachoroidal space to terminate in the anterior part of the ciliary body. Here they anastomose with the lateral and medial long ciliary arteries to form the major arterial circle of the iris.

The veins from the extraocular muscles correspond to the arteries and empty into the superior and inferior orbital veins, respectively.

REFERENCES

1. Apt L: An anatomical evaluation of rectus muscle insertions. *Trans Am Ophthalmol Soc* 78:365, 1980.
2. Berke RN: Tenotomy of the superior oblique for hyperopia (preliminary report). *Trans Am Ophthalmol Soc* 44:304, 1946.
3. Bron AJ, Tripathi RC: *Wolff's Anatomy of the Eye and Orbit*, ed 8. London, Chapman & Hall, 1997.
4. Brown HW: Congenital structural muscle anomalies. In Allen, JH, ed: *Strabismus Ophthalmic Symposium I*. St Louis, Mosby-Year Book, 1950, p 205.
5. Charpy A: Muscles et capsule de Tenon. In Poirier P, Charpy A, eds: *Traité d'anatomie humaine*, new ed vol 5/2. Paris, Masson, 1912, p 539.
6. Clark RA, Miller JM, Demer JL: Location and stability of rectus muscle pulleys. Muscle paths as function of gaze. *Invest Ophthalmol Vis Sci* 38:227, 1997.
7. Clark RA, Rosenbaum AL, Demer JL: Magnetic resonance imaging after surgical transposition defines the anteroposterior location of the rectus muscle pulleys. *J AAPOS* 3:9, 1999.
8. Demer JL, Miller JM, Poukens V: Surgical implications of the rectus extraocular muscle pulleys. *Pediatr Ophthalmol Strabismus* 33:208, 1996.
9. Demer JL, Oh SY, Poukens V: Evidence for active control of rectus extraocular muscle pulleys. *Invest Ophthalmol Vis Sci* 41:1280, 2000.
10. Demer JL, Miller JM, Poukens V, et al: Evidence for fibromuscular pulleys of the recti extraocular muscles. *Invest Ophthalmol Vis Sci* 36:1125, 1995.
11. Demer JL, Pukens V, Miller JM, Mircevych P: Innervation of extraocular pulley smooth muscle in monkeys and humans. *Invest Ophthalmol Vis Sci* 38:1774, 1997.
12. Duke-Elder S, Wybar KC: *The Anatomy of the Visual System. System of Ophthalmology*, vol 2. St Louis, Mosby-Year Book, 1961.
13. Dwight T: The anatomy of the orbit and the appendages of the eye. In Norris WF, Oliver CA, eds: *System of Diseases of the Eye*, vol 1. Philadelphia, JB Lippincott, 1897, p 99.
14. Fink WH: *Surgery of the Vertical Muscles of the Eyes*, ed 2. Springfield, IL, Charles C Thomas, 1962.
15. Fuchs E: Beiträge zur normalen Anatomie des Augapfels. *Graefes Arch Ophthalmol* 30(4):1, 1894.
16. Gat L: Einige Beiträge zur Topographie des Ansatzes der vier geraden Augenmuskeln. *Ophthalmologica* 14:43, 1947.
17. Guérin G: Mémoire sur la myotomie oculaire par la méthode sous-conjonctivale. *Gazette Med Paris*, 1842.
18. Helmholtz H von: In Southall PC, ed: *Helmholtz's Treatise on Physiological Optics*. English translation from the 3rd German edition, Ithaca, NY, Optical Society of America, 1924. Quoted from reprint, New York, Dover Publications, vol 3, 1962, p 38.
19. Helveston EM: Brown syndrome: Anatomic considerations and pathophysiology. *Am Orthoptics J* 43:31, 1993.
20. Helveston EM: The influence of superior oblique anatomy on function and treatment. *Binocular Vision Strabismus Q*:14:16, 1999.
21. Helveston EM, Merriam WW, Ellis FD, et al: The trochlea: A study of the anatomy and physiology. *Ophthalmology* 89:124, 1982.
22. Howe L: Insertion of the ocular muscles. *Trans Am Ophthalmol Soc* 9:668, 1902.
23. Lang J, Horn T, Eichen U von den: Über die äusseren Augenmuskeln und ihre Ansatzzonen. *Gegenbaurs Morphol Jahrb* 126:817, 1980.
24. Last RJ: *Wolff's Anatomy of the Eye and Orbit*, ed 6. Philadelphia, HK Lewis & Co, 1968.
25. Merkel F: Makroskopische Anatomie. In Graefe A, Saemisch Th, eds: *Handbuch der gesammten Augenheilkunde*, ed 1, vol 1. Leipzig, Wilhelm Engelmann, 1874, p 56. [See also Merkel and Kallius.^{27, p 73}]
26. Merkel F, Kallius E: Makroskopische Anatomie des Auges. In Graefe A, Saemisch Th, eds: *Handbuch der gesammten Augenheilkunde*, ed 2, vol 1. Leipzig, Wilhelm Engelmann, 1910, p 65 n.
27. Miller JM: Functional anatomy of human rectus muscles. *Vision Res* 29:223, 1989.
28. Motais E: L'appareil moteur de l'oeuil de l'homme et des vertébrés. Déductions physiologiques et chirurgicales (strabisme). Paris, A. Delahaye & E. Lecrosnier, 1887.

29. Parks MM: The superior oblique tendon—33rd Doyne Memorial Lecture. *Trans Ophthalmol Soc UK* 97:288, 1977.
30. Porter JD, Pukens V, Baker RS, et al: Structure function correlations in the human medial rectus extraocular muscle pulleys. *Invest Ophthalmol Vis Sci* 37:468, 1996.
31. Powell T: *Elementa opticae*. London, F. Griswold, 1651 p 18. [About this exceedingly rare book and its author, see Burian HM: A text for the times of Cromwell. *Dartmouth Coll Libr Bull* 4:19, 1943.]
32. Scobee RC: Anatomic factors in the etiology of strabismus. *Am J Ophthalmol* 31:781, 1948.
33. Sevel P: The origins and insertions of the extraocular muscles: Development, histologic features, and clinical significance. *Trans Am Ophthalmol Soc* 84:488, 1986.
34. Simonsz HJ, Harting F, de Waal BJ, et al: Sideways displacement and curved path of recti eye muscles. *Arch Ophthalmol* 103:124, 1985.
35. Souza-Dias C, Prieto-Diaz J, Uesugui CF: Topographical aspects of the insertions of the extraocular muscles. *J Pediatr Ophthalmol Strabismus* 23:183, 1986.
36. Stangl R, Mühlendyck H, Kraus-Mackiw E: Muskelansatz-Limbusdistanz und Sehnenlänge der Musculi recti in Abhängigkeit von der Bulbusgrösse bzw. vom Altern. In Kommerell G, ed: *Augenbewegungsstörungen: Neurophysiologie und Klinik*. JF Bergmann, Munich, 1978, p 33.
37. Thiel HL: Zur topographischen und histologischen Situation der Ora serrata. *Graefes Arch Clin Exp Ophthalmol* 156:590, 1955.
38. Whitnall SE: *The Anatomy of the Human Orbit and Accessory Organs of Vision*, ed 2. New York, Humphrey Milford, 1932.
39. Zoth O: Augenbewegungen und Gesichtswahrnehmungen. In Nagel W, ed: *Handbuch der Physiologie des Menschen*, vol 3. Braunschweig, Friedrich Vieweg & Sohn, 1905, p 296.

Physiology of the Ocular Movements

Basic Kinematics

Translatory and Rotary Movements

The eye movements, as mechanical events, are subject to the general laws of kinematics. Although a detailed knowledge of this subject is not required for the understanding of the clinical facts, a few basic concepts must be discussed.

Any movement of a freely suspended spheroid body can be reduced to a combination of one or more of the following six movements. This body can move sideways, up or down, and forward or backward (*translatory movements*), or it can rotate around a vertical, horizontal, or anteroposterior axis (*rotary movements*). If a translatory movement takes place, the center of the body moves with it. In a pure rotary movement the center would not shift its position; it would have zero velocity.

Center of Rotation

The eye performs rotary movements around a center of rotation within the globe. This center of rotation has been assumed to be fixed, but newer experiments indicate that this is not the case. The center of rotation of the eye does not have zero velocity; it moves in a semicircle in the plane of rotation. Thus, even seemingly simple eye movements are complex.

However, from a practical standpoint the translatory movements may be disregarded. In primary

position the center of rotation is located about 13.5 mm (in myopes, 14.5 mm) behind the apex of the cornea on the line of sight, which places it 1.3 mm behind the equatorial plane. For practical purposes, one may assume that a line connecting the middle of the lateral orbital margins goes through the center of rotation of the two eyes if they are emmetropic or not highly ametropic and have normally developed orbital fat.

Definitions of Terms and Action of Individual Muscles

The action of an individual muscle is controlled by the direction of its pull to the three axes around which the globe rotates.

Before we consider what movement an eye would make if all but one of the six eye muscles were paralyzed, certain definitions having to do with these movements must be introduced.

DUCTION MOVEMENTS. Since the eyeball has an essentially fixed center of rotation, the globe has three, not six, degrees of freedom. It can rotate around one of three axes, all going through the center of rotation. One of these is the anteroposterior or sagittal axis (y-axis), coincident with the line of sight (or line of fixation). The other two are perpendicular to the line of sight; one is vertical (z-axis), and the other is horizontal (x-axis). The vertical and the horizontal axes are assumed to lie in the equatorial plane, or *Listing's plane*, which is defined as a plane fixed in the orbit

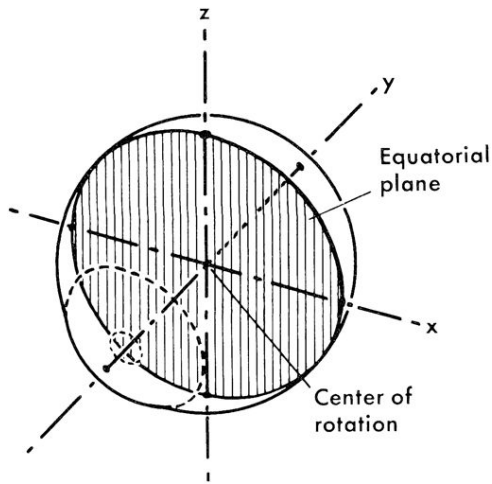


FIGURE 4-1. Axes of rotation, center of rotation, and equatorial plane.

that passes through the center of rotation and the equator of the globe when the eye is in primary position (Fig. 4-1).

The rotations of the single eye are termed *duction movements* (Fig. 4-2). Rotations around the vertical axis (horizontal excursions of the globe) are called *adduction* (movement nasalward) and *abduction* (movement templeward). Rotations around the horizontal axis (vertical excursions of the globe) are termed *elevation* or *sursumduction* (movement upward) and *depression* or *deorsumduction* (movement downward). These four movements are the *cardinal movements of the eye*. A combination of the horizontal and vertical excursions moves the globe into various oblique positions in the directions up and right, up and left, down and right, and down and left. These oblique movements occur around axes lying obliquely in the equatorial plane.

Rotations around the anteroposterior axis of the globe, known as *cycloductions*, rotate the upper pole of the cornea templeward (*excycloduction*) or nasalward (*incycloduction*).

POSITIONS OF THE GLOBE. The *primary position* is assumed by the eye when one is looking

straight ahead with body and head erect. For clinical purposes this is a satisfactory description. A more stringent kinematic definition of the primary position is given elsewhere in this chapter. The adducted, abducted, elevated, or depressed positions of the globe are designated as *secondary positions*. The oblique positions of the eye are termed *tertiary positions* (Fig. 4-3).

TERMS RELATED TO THE MECHANICS OF MUSCLES. The point at which the center of the muscle or of its tendon first touches the globe is the *tangential point*. A tangent to the globe at this point indicates the direction of pull of that muscle. The position of this point changes when the muscle contracts or relaxes and the globe rotates (Fig. 4-4).

The *arc of contact* is the arc formed between the tangential point and the center of the insertion of the muscle on the sclera. Since the position of the tangential point is variable, the arc of contact changes in length as the muscle contracts. It is longest when the muscle is relaxed and its antagonist contracted and shortest when the muscle is contracted and its antagonist relaxed.

The *muscle plane* is determined by the tangent to the globe at the tangential point and the center of rotation. In general, it is the plane determined by the centers of origin and insertion and the center of rotation (see Fig. 4-4).

These traditional concepts of arc of contact and muscle plane and their effects on ocular kinematics are based on straight-line, two-dimensional models of orbital anatomy. They do not take into account the recently discovered *muscle pulleys* and their effect on the linearity of the muscle paths of the rectus muscles.²³ We expect that some of these concepts will need to be modified when the function of muscle pulleys, which have been discussed in the preceding chapter, becomes better known.

An *axis of rotation*, which is perpendicular to the muscle plane erected in the center of rotation,

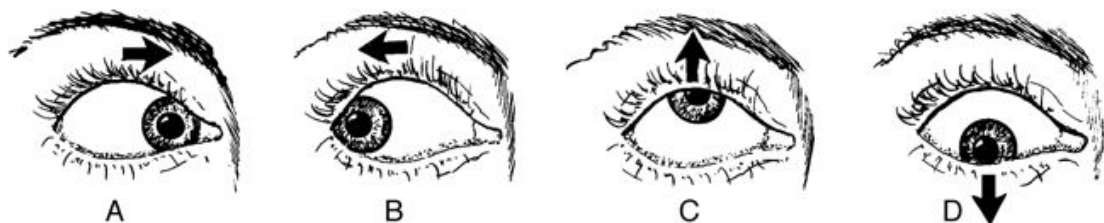


FIGURE 4-2. Ductions. Secondary positions, right eye. A, Adduction. B, Abduction. C, Sursumduction (elevation). D, Deorsumduction (depression).

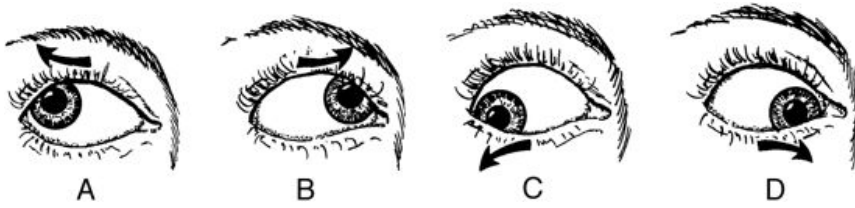


FIGURE 4-3. Some tertiary positions, right eye. *A*, Gaze up and right. *B*, Gaze up and left. *C*, Gaze down and right. *D*, Gaze down and left.

corresponds to each muscle plane. The muscle plane describes the direction of pull of the muscle and determines the axis around which the eye would rotate if the particular individual muscle were to make an isolated contraction (see Fig. 4-4).

HORIZONTAL RECTUS MUSCLES. In the case of the horizontal rectus muscles the action is quite simple. One might assume at first that these muscles share a common muscle plane that is horizontal in primary position and contains the line of sight. Their axis of rotation coincides in primary position with the z-axis of the system. As a result, the contraction of one of the horizontal rectus muscles produces a pure rotation around the vertical axis: the lateral rectus abducts the line of gaze, and the medial rectus adducts the line of gaze (Table 4-1 and see Fig. 4-2).

In general, with the contraction of these muscles, there is neither a vertical component nor a cycloduction. However, in positions of elevation and depression the action of these muscles has a component of elevation and depression, which explains upshoot and downshoot of the adducted eye in certain patients with Duane's syndrome (see Chapter 21).

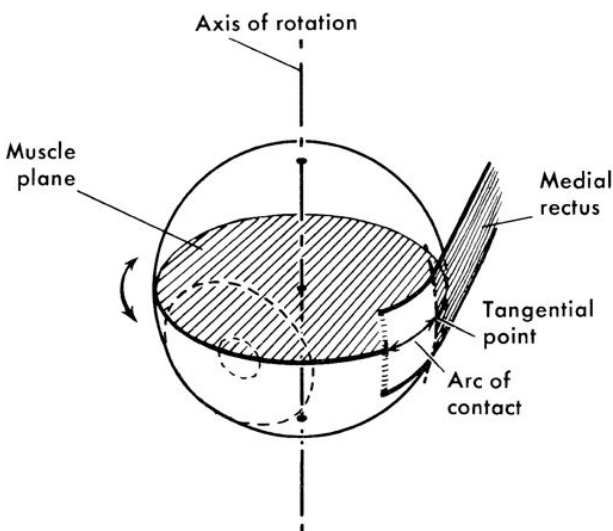


FIGURE 4-4. Schematic presentation of muscle plane, medial rectus, axis of rotation, tangential point, and arc of contact.

VERTICAL RECTUS MUSCLES. In primary position the plane of the vertical rectus muscles does not include one of the axes of the coordinate system. Therefore, their action is more complicated than that of the horizontal rectus muscles.

The planes of the *superior* and *inferior rectus muscles* are assumed to coincide, which is sufficient approximation for clinical purposes. This common muscle plane in primary position forms an acute angle of about 23° with the y-axis (the median plane of the eye). The axis of rotation of these muscles therefore does not coincide with the x-axis in the equatorial plane of the globe but forms an angle of 23° with it (Fig. 4-5 A).

Accordingly, when the eye is in primary position, the *superior rectus muscle* not only *elevates* the globe but also *adducts* it and rotates it around the anteroposterior y-axis, causing *incycloduction* (see Table 4-1). If the globe is abducted, its axis of rotation more and more approaches the x-axis; when it is abducted 23° , the two coincide. At that moment the superior rectus muscle becomes a pure elevator, and its action no longer has a cycloducting component. The elevating action of the superior rectus muscle is maximal in abducted positions of the eye.

The opposite effect applies to incycloduction. The more the globe is adducted, the greater the incycloduction effect. If the globe could be adducted 67° , the superior rectus would produce pure incycloduction. Since the globe cannot adduct that far, there is some elevating component to the action of the superior rectus, even in adduction.

What has been said about the superior rectus applies analogously to the *inferior rectus muscle*; but since the inferior rectus is attached to the globe from below, it *depresses* the globe (maximally in abduction) and has a slight *adducting* action. It causes *excycloduction* of the eye, maximal in adduction and equal in amount for a given position of the globe to the incycloduction effect of the superior rectus muscle (see Table 4-1).

The secondary action of the vertical rectus muscles as adductors was studied in detail in the rhesus monkey by Chamberlain.²⁰ When he made a tenotomy excision of the vertical rectus muscles,

TABLE 4-1. Action of the Extraocular Muscles from the Primary Position

Muscle*	Primary	Secondary	Tertiary
Medial rectus	Adduction	—	—
Lateral rectus	Abduction	—	—
Inferior rectus	Depression	Excycloduction	Adduction
Superior rectus	Elevation	Incycloduction	Adduction
Inferior oblique	Excycloduction	Elevation	Abduction
Superior oblique	Incycloduction	Depression	Abduction

*The superior muscles are incycloductors; the inferior muscles, excycloductors. The vertical rectus muscles are adductors; the oblique muscles, abductors.

no limitation of adduction was found. When he made a tenotomy excision of the medial rectus muscle, the animal could not adduct its eyes beyond the midline. The vertical rectus muscles were not effective enough as secondary adductors to move the eye nasalward so long as the lateral rectus muscle was intact; but if the lateral rectus muscle was also tenotomized, a small amplitude of adduction from the straight-ahead position was noted.

In contrast to Chamberlain's findings, Gordon⁴⁴ measured marked restriction of adduction in six human eyes, later to be enucleated, on which he performed free tenotomies or myectomies of both vertical rectus muscles. This restriction persisted until the action of the vertical rectus muscles was restored.

OBLIQUE MUSCLES. The assumption that the two oblique muscles share a common plane is less justified for these muscles than for the vertical rectus muscles. However, both muscle planes go in a direction from the anteromedial aspect of

the globe to the posterolateral aspect. Therefore, neither muscle plane coincides with the median plane of the globe, nor does the axis of rotation coincide with the x-axis. The muscle plane of the superior oblique muscle forms an angle of about 54° with the median plane and that of the inferior oblique muscle, and angle of 51°. Because of the large angles formed in primary position, the oblique muscles mainly produce cyclorotation.

In primary position the *superior oblique muscle* causes *incycloduction* and *depression* of the eye and also acts as an *abductor* (see Table 4-1). When the globe is adducted, the angle between the median plane of the eye and the muscle plane is reduced and the superior oblique muscle acts more and more as a depressor. With an adduction of 54°, the superior oblique would be a pure depressor. The angle between the median plane of the globe and the muscle plane increases with abduction of the eye. The superior oblique increasingly produces incycloduction, and with 36° of abduction its action is one of pure incycloduction.

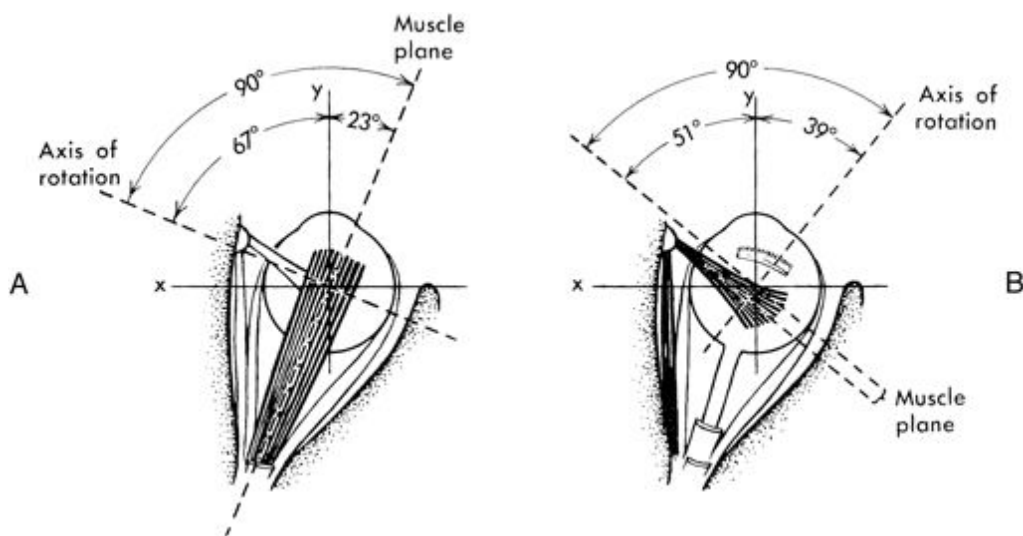


FIGURE 4-5. A, Relationship of muscle plane of vertical rectus muscles to x- and y-axes. B, Relationship of muscle plane of oblique muscles to x- and y-axes.

The maximum action of the superior oblique muscle as a depressor is in adduction; the maximum incycloduction occurs in abduction (Fig. 4-5B).

Analogous considerations apply to the *inferior oblique muscle*. In primary position its contraction causes *excycloduction*, *elevation*, and *abduction* of the globe (see Table 4-1). Its action as an elevator is greatest in adduction (maximum at 51°), and its action as an excyclorotator is greatest in abduction (maximum at 39°).

Chamberlain²⁰ also studied the secondary abducting action of the oblique muscles in the rhesus monkey and found behavior analogous to the secondary adduction of the vertical rectus muscles. When both horizontal rotators were intact, sectioning both oblique muscles did not affect abduction. When only the lateral rectus muscle was cut, no abduction could be performed unless the medial rectus muscle was also tenotomized, in which case moderate abduction was noted.

Further Considerations of Mechanics of Extraocular Muscles

The anatomical data about the extraocular muscles given in Chapter 3 allow certain general conclusions about the mechanics of these muscles. They are long and slender with an average cross-section ratio of 1:10 to their length. This design enables them to move a relatively small mass with considerable speed.

The effectiveness of a mover in rotating a sphere depends on the position of its attachment to the sphere in relation to the sphere's center and on its mass. The farther anteriorly from the center it is attached and the greater its mass, the greater its effectiveness. On both counts the medial rectus is the most favored muscle: its insertion is nearest to the corneal limbus and it is the heaviest.

The amplitude of the excursions that the globe can achieve as a result of the action of a muscle is determined theoretically by the maximum shortening the muscle is capable of achieving. This maximum depends on the length of the arc of contact of the muscle on the globe. Table 4-2 lists the average results of the measurements of the arcs of contact of the various muscles as determined by Volkmann¹³¹ on cadaver eyes. In this table, taken from Zoth,¹⁴¹ column I shows the length of the arc of contact; L, the length of the muscle without its tendon (note the difference between these data and those from a later study shown in Table 3-2; and Q, the theoretical maximum of shortening of

TABLE 4-2. Arc of Contact of Muscles and Excursions of Globe

Muscle	I (mm)	L (mm)	I/L	Q	Q'
Medial rectus	6.33	40.8	0.15	29°31'	50°
Inferior rectus	9.83	40.0	0.24	41°43'	45°
Lateral rectus	13.25	40.6	0.32	60°43'	50°
Superior rectus	8.92	41.8	0.21	41°48'	45°

Modified from Zoth O: Augenbewegungen und Gesichtswahrnehmungen. In Nagel W, ed: *Handbuch der Physiologie des Menschen*, vol 3. Braunschweig, Friedrich Vieweg & Sohn, 1905, p 299.

the muscle in degrees obtained from I. These data are based on the assumption that the eye is a sphere with its center of rotation in the center. Column I/L, which shows the ratio between arc of contact and the length of the muscle, expresses the theoretical maximum of contraction of the muscle. Finally, Q' indicates the maximal rotations actually achieved by the living eye in the nasal, downward, temporal, and upward directions.

Comparison of the figures for Q and Q' shows that for the lateral rectus muscles Q exceeds Q'. This means that theoretically the mechanical conditions are such that the lateral rectus muscle is amply able to abduct the eye fully when acting alone. The other muscles, the most striking being the medial rectus muscle, have a theoretical deficit of excursion when working alone.

In trying to account for this deficit, Zoth¹⁴¹ made the point that Volkmann's measurements of the arc of contact on cadaver eyes may not apply strictly to living eyes because the positions of the eyes in the two conditions generally do not agree (see Chapter 12). He also pointed out that Volkmann assumed the center of rotation to be in the center of the globe when, in fact, it lies behind it. Last, he mentioned the auxiliary actions of other muscles that may assist the prime mover when the globe reaches more extreme positions.

Another problem arises from the question of how the muscles, when contracting, maintain their plane of pull. If the effective origins and insertions are indeed pointlike, as is assumed in determining some of the mechanical factors of the muscle action, the axes or rotations and therefore the plane of pull of the extraocular muscles would be subject to considerable variation during contraction of a muscle. According to Helmholtz,⁵⁰ the wide, fanlike insertion of the muscles largely reduces this possibility. In connection with the ques-

tion of maintaining the more or less constant plane of pull of the muscles, consideration must also be given to the all-or-nothing law of muscular contraction, discussed in Chapter 6.

Using Volkmann's measurements of the effective origins and insertions of the extraocular muscles as his basis, Boeder¹⁰⁻¹² analyzed mathematically and graphically the action of the individual muscles and their cooperation. From his graphs, Boeder reached some important and original conclusions about cooperation of the muscles of the two eyes. The medial and lateral rectus muscles cancel the abducting and adducting action of the elevators and depressors when the eyes elevate or depress the globe from positions of abduction or adduction. The superior and inferior rectus muscles contribute more than the oblique muscles to elevation and depression of the globe throughout the entire range of adduction and abduction. It is not correct therefore to say that the vertical rectus muscles function primarily in abduction and the oblique muscles in adduction. Boeder also challenged the assumption that the vertical rectus muscles of one eye are functionally linked with the oblique muscles of the other eye. Rather, he stated that his analysis demonstrated that the pair of elevators of one eye work as a unit with the pair of elevators of the other eye and that the two pairs of depressors are similarly linked.

Boeder's theory on the cooperative action of the extraocular muscles is given in Figure 4-6. The state of muscular contraction in a field of fixation ranging from 30° abduction to 30° adduction and from 30° depression to 30° elevation for each of the extraocular muscles is illustrated in this figure. The heavily numbered lines are the loci of normal eye positions in which each muscle is contracted as many millimeters as the negative numbers indicate. The broken numbered lines are the loci of those normal eye positions for which the muscle is extended as many millimeters as the positive numbers indicate. Using this number, the contractive state of all six muscles can be determined for any position of gaze. For instance, the contractive state of all muscles (in millimeters) in 20° adduction and 30° elevation is lateral rectus 2.0; medial rectus, -4.7; superior rectus, -6.2; inferior oblique, -4.3; inferior rectus, 3.6; superior oblique, -5.3.

Clearly, on the basis of these calculations and contrary to conventional views, the superior rectus muscle must contract more than the inferior oblique muscle to elevate the adducted eye. The

same principle applies to the action of the superior oblique muscle in adduction. For instance, to attain a position of 20° adduction and 30° depression, the inferior rectus muscle must contract 6.3 mm and the superior oblique, only 3.0 mm. Robinson,¹¹⁴ on the basis of quantitative analysis of extraocular muscle cooperation, reached similar conclusions regarding the major role of the vertical rectus muscles as elevators and depressors, not only in abduction but also in adduction, and the validity of his model has been confirmed by Clement.²⁴

For a given contraction of the superior or inferior oblique muscle, Jampel⁵⁹ found in experiments on monkeys and observations in humans that the angle of cyclotorsion remains the same throughout the whole range of horizontal movements.

Boeder's theory is supported by several clinical observations. First, elevation or depression in adduction is unimpaired after myectomy of an overacting inferior oblique muscle or tenectomy of an overacting superior oblique tendon. Second, on examination of the ductions, the vertical lag in the field of action of a paralytic oblique muscle will appear to be less pronounced than when a vertical rectus muscle is paralytic. Finally, we have observed perfectly normal depression of each adducted eye in patients with surgically proven congenital absence of the superior oblique muscle. It would be of interest to verify electromyographically this departure from the classic concepts with respect to the yoking of vertical rectus and oblique muscles.

Recent studies of human volunteers have been concerned with the position of the rectus muscles in different gaze positions. Using computed tomography (CT) scans¹²³ or magnetic resonance imaging (MRI),⁸² it has been shown that vertical movement of the horizontal rectus muscles in elevation and depression (sideslip) or horizontal movement of the vertical rectus muscles in adduction and depression is minimal and that the muscle planes are relatively fixed in the orbit. These observations confirm Helmholtz⁴⁹ who stated, "it is to be noted that all ocular muscles have a rather broad insertion with fibers fanning out a little. The consequence is that even if the eye has rotated considerably from the primary position, the axes of rotation of the individual muscles do not significantly change their position in space." Boeder,¹¹ recognizing the significance of Helmholtz's statement, pointed out that the effective

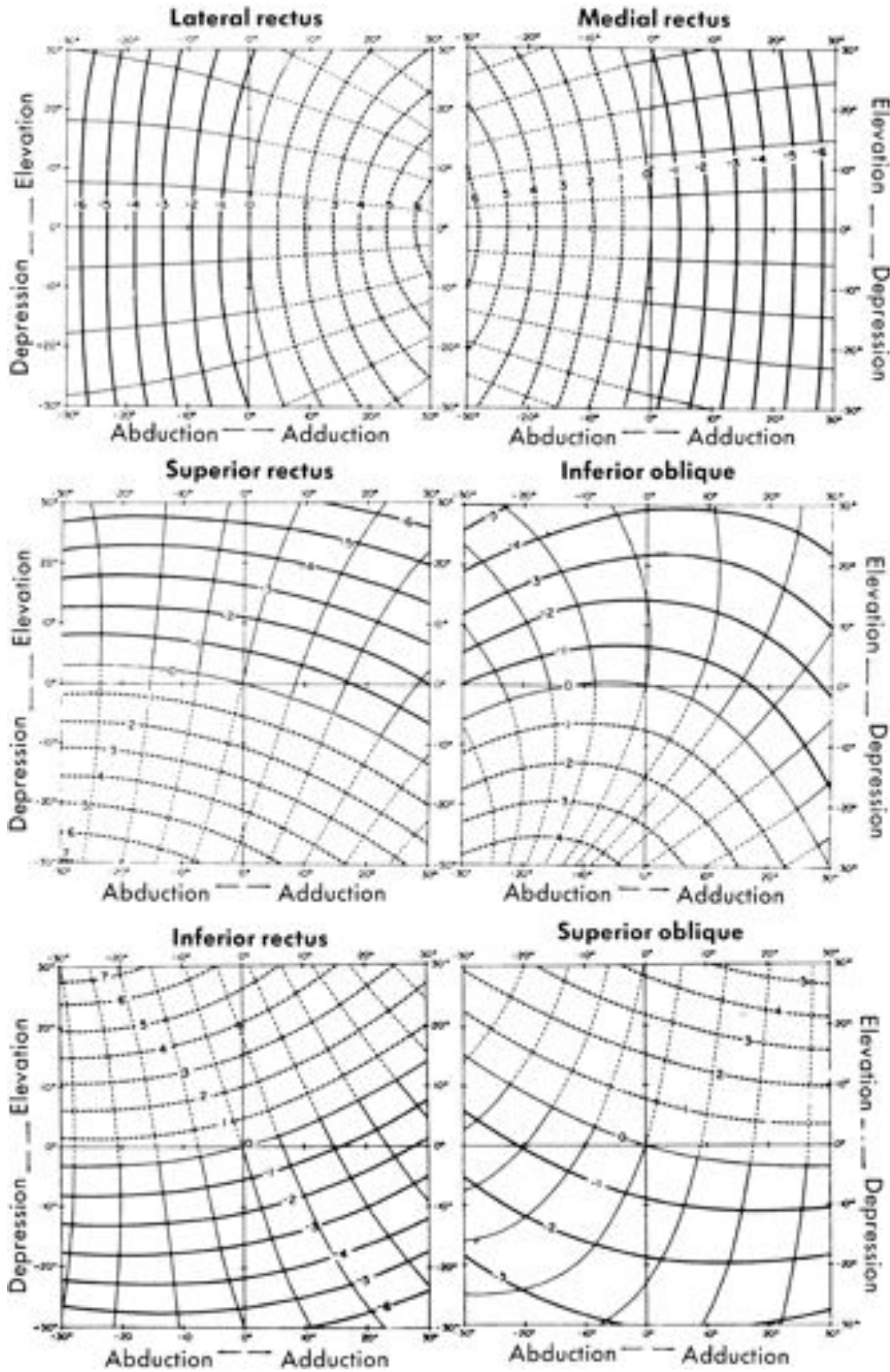


FIGURE 4-6. Boeder's theory on the cooperative action of the extraocular muscles. For explanation, see text. (From Boeder P: Cooperative acting of extraocular muscle. *Br J Ophthalmol* 46:397, 1962.)

insertion moves away from the center to the peripheral part of the insertion as the eye moves away from the primary position. Boeder also realized that this displacement of the effective inser-

tion and, consequently, the displacement of the muscle plane, is restricted. Thus, the in vivo studies^{82, 123} are not in contradiction with Boeder's view of muscle action. Nor are they incompatible

with the assumption that the horizontal recti augment elevation with the eye elevated and depression with the eye depressed and that the vertical recti have similar horizontal effects with respect to the adducted or abducted eye. No sideslip of the recti in relationship to the orbital walls is necessary to accomplish these tasks, which are based on a change in the relationship between the effective muscle insertion and the center of rotation of the globe (bridle effect). The validity of this concept has been well documented in patients with Duane's syndrome (see Chapter 21). As pointed out by Simonsz and coworkers,¹²³ it is important to distinguish between sideways displacement of the muscle relative to the bony orbit and sideslip of the muscle over the globe. Indeed, for the muscle plane to be relatively fixed in the orbit, muscle slip over the globe is unavoidable.

Robinson^{108, 111, 113, 115} and Robinson and coworkers¹¹⁶ applied engineering principles to the study of the mechanism of the various eye movements. The results of these complex investigations were summarized as follows by Breinin in his Gifford lecture.¹⁶

1. The eye is driven impulsively in a saccade by a brief burst of force much larger than that needed to hold the eye in its new position.
2. The role of the mass of the eyeball is negligible in determining the timing of the saccade.
3. There is no active checking. The eyeball is decelerated by the highly viscous nature of the orbital supporting structures.
4. Larger saccades are achieved by increasing the duration of the excess force applied, since the intensity of the force, although large, is limited. In engineering terms, this movement is termed *frequency compensation* (or neural preemphasis).
5. Smooth pursuit movements are markedly different from saccadic movements and exhibit quite different mechanical parameters.
6. Vergence movements, on the other hand, show a slow rise of tension compared with other movements. The time course of vergence movements suggests the presence of different neuromuscular control mechanisms and leads to the implication of the slow fiber system.

In an extension of this work, Robinson¹¹⁵ calculated the force, length, innervation, and unit action vector of each muscle and described how its force

is distributed to act horizontally, vertically, and in torsion. From this model, certain predictions may become possible with respect to the effect of muscle surgery. Clinical trials are under way in several centers to test the application of Robinson's work.

The Fundamental Laws of Ocular Motility

Donders' and Listing's Laws

DONDERS' LAW. In the preceding description of the actions of individual muscles, each muscle is regarded as an independent mover. Such a description is of necessity analytic and is indispensable to the diagnosis of paralyzes of individual extraocular muscles or groups of muscles. However, this description should not create the impression that an extraocular muscle can ever act alone. This is not so, and the effect of the combined action of the extraocular muscles with regard to the kinematics of the single eye must now be considered. This is also an abstraction, because the muscles of the two eyes are always simultaneously innervated, as is discussed later.

The eyeball has three degrees of freedom of rotation. However, one freedom, the rotation around the anteroposterior axis, the line of sight, is severely restricted. If unrestricted rotations around the line of sight were permitted to the globe, the cardinal rotations and their combinations could be associated with an infinite number of cyclorotations. If this were the case, great difficulties in spatial orientation would arise. Indeed, such random cyclorotations do not occur.

Donders³⁴ expressed this theory in 1848 by stating that *to each position of the line of sight belongs a definite orientation of the horizontal and vertical retinal meridians relative to the coordinates of space*. Orientation depends solely on the amount of elevation or depression and lateral rotation of the globe. The orientation of the retinal meridians pertaining to a particular position of the globe is achieved irrespective of the path the eye has taken to reach that position. After returning to its initial (primary) position, the retinal meridian is oriented exactly as it was before the movement was initiated. This is known as Donders' law.

To repeat, this law implies that only one orientation of the retinal meridians is permissible with each position of the eyes. This one and only one orientation does not allow for the infinite number

of other orientations around the line of sight that could exist if the freedom of cyclorotations were unrestricted.

LISTING'S LAW. Listing⁷³ did not add anything essentially new to Donders' law, but he and those after him, Helmholtz⁵⁰ especially, elaborated in considerable detail on the geometry and mathematics of the ocular rotations. Listing suggested that each movement of the eye from the primary position to any other position involves a rotation around a single axis lying in the equatorial plane, also called Listing's plane. This plane was defined earlier as being fixed in the orbit and passing through the center of rotation of the eye and its equator, when the eye is in primary position. The axis is perpendicular to the plane that contains the initial and final positions of the line of sight.

Listing's law implies that all eye movements from the primary position are true to the meridians and occur without "torsion" or cyclorotation with respect to the primary position. This law is obviously true for movements around the horizontal and vertical axes in the equatorial plane. It can be proved also for movements into tertiary positions elicited by means of the classic afterimage method. With this method the subject's eye is placed in the primary position with respect to the center of a plane (or preferably a bowl to avoid perspective distortions) on which a number of meridians are drawn. To the center of the bowl is fastened a rotatable disk carrying a cross, usually of red paper, which produces a good afterimage (Fig. 4-7). The cross is placed so that one arm

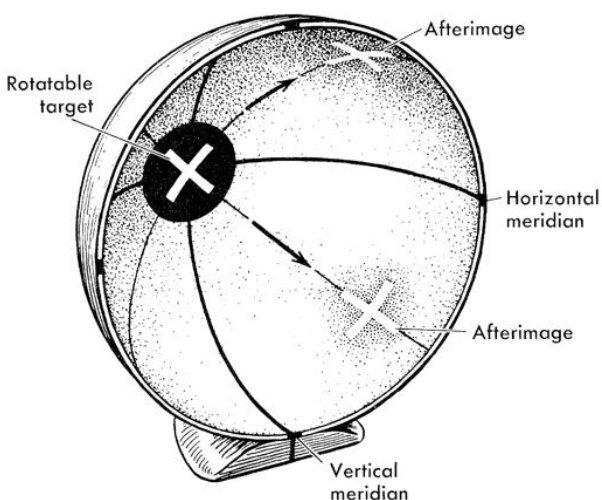


FIGURE 4-7. Bowl with inscribed meridians and movable disk carrying a cross to produce afterimage to show that eye movements from primary position are true to meridians.

coincides with one of the meridians; when an afterimage has been imprinted on the retina, the eye is moved along that meridian. The subject will then find that the arms of the cross have remained true to the meridian, indicating that no cyclorotation has occurred during the ocular movement (see Fig. 4-7). This phenomenon is what is required by Donders' law, but since the movement is along meridians, the arms of the cross must make an angle with respect to the objective vertical (see Fig. 4-7). The amount of this angle depends on the eccentricity of the tertiary position on the meridian.

The distinction between this geometric angular deviation (sometimes called "false torsion" or "pseudotorsion") and the cyclorotation-free movement, according to Listing's law, has caused untold confusion, much of which is a result of the varied and often inappropriate terminology used by different authors. To avoid confusion, the term *cyclorotation* for actual rotations of the globe around the line of sight would appear to be unequivocal and in good agreement with the terms *cycloduction* and *cyclovergence*, for example, introduced by Lancaster.⁷⁰ Its acceptance is advocated.

There is no single term for the discrepancy between the vertical corneal meridian and the objective vertical. In English the term most frequently applied is *false torsion*. However, Duke-Elder³⁵ uses the term *torsion* for it. These are not good terms. There is no torsion in the sense of cyclorotation, and there is nothing false about the very real phenomenon. In the German terminology, distinction is made between wheel rotation (*Raddrehung*, Helmholtz⁵⁰) for "false" cyclorotation and rolling (*Rollung*, Hering⁵¹) for "true" cyclorotation. A term used by Tschermak-Seysenegg^{129, 130} is *kinematic inclination* (in Boeder's translation of Tschermak-Seysenegg) *Tertiärneigung* or *inclination in tertiary position*. This neutral descriptive term, characterizing the geometric nature of the phenomenon, would seem to be perfectly clear, and its general acceptance would go far in clarifying Listing's law.

Determination of the position of the vertical corneal meridians may be used to objectively assess the angle formed between the vertical retinal meridian and the objective vertical. When the eye is brought into primary position, some outstanding features on conjunctiva or iris are noted and the corneal meridians are marked in some manner. The eye then is allowed to assume a tertiary posi-

tion, and the vertical corneal meridian is related mechanically or photographically to the objective vertical.

Plotting the blind spot has also been used in physiologic studies^{42, 81} and in clinical studies to determine cyclorotations in patients with A and V patterns of fixation (see Chapter 19).^{74, 134} Listing's law also implies a stringent kinematic definition of the primary position of the eyes, since it is out of this position that the eye performs cyclorotation-free movements. In the experiments discussed, this is the primary position to which reference has been made.

To bring the eye into the kinematic primary position for laboratory purposes, the best method to use is the needle-coincidence test (Helmholtz⁵⁰), in which a needle directed toward the eye is placed at the fixation point. The head and eye of the observer are then placed so that the needle appears as a point. The sides of the needle should not be seen by the observer. When this is achieved, the needle and the line of sight coincide, and the eye is in the kinematic primary position (Fig. 4-8).

Boeder¹¹ has challenged the requirement of Listing's law that the movement must start from the kinematic primary position. He analyzed such rotations into a series of segments, each of them occurring along a circle through the occipital point (a direction circle of Helmholtz) and about the axis of that circle. At the end of each component rotation, the corneal meridians would be oriented as expected (according to Listing's law), as if the rotation had started from the kinematic primary position. In analyzing this theory, one should remember that when the eye follows a straight line that is not a meridian starting from a tertiary

position, this line appears to rotate in a manner indicative of a cyclorotation of the eye.

Ferman and coworkers^{40, 41} reinvestigated the validity of Listing's law by recording horizontal, vertical, and cyclorotational eye movements under static and dynamic conditions with the scleral coil technique. This modification of Robinson's suction contact lens¹⁰⁸ technique to record eye movements with the patient's head in a revolving magnetic field has replaced older recording techniques in terms of accuracy. Van Rijn and van den Berg¹⁰³ concluded that Listing's law, while qualitatively valid, specifies cyclorotations only approximately.

SIGNIFICANCE OF LISTING'S LAW. Moses⁸⁵ believed the differentiation between "true" and "false" torsion to be merely verbal. He thought it fair to say that "when the vertical meridian of the eye was no longer vertical, the eye had torted, no matter by what mechanism this had occurred." Here again, one encounters a semantic problem. Moses does not specify what he means by "torted," nor does he indicate the reference frame in respect to which the vertical meridian of the eye is "torted." Boeder¹⁰ has clearly pointed out that one should always refer the position of the vertical meridian of the eye to either the kinematic primary position or the objective vertical.

Alpern^{3, p. 20} stated that the only advantage in describing the rotations of the eye in terms of Listing's system was that it was more parsimonious. If one uses the Helmholtz or Fick system of coordinates to describe the movement, at least three degrees of freedom and a cyclorotation around the line of sight are required to explain the position assumed by the eye in a tertiary position. Listing's system of axes requires only two degrees of freedom and does not require a cyclorotation. From a purely geometric standpoint this is true, but only from an abstract geometric standpoint. The physiologist and the ophthalmologist are interested in knowing which system the eye follows and whether the eye makes cyclorotations in its movement from the kinematic primary to tertiary positions. This is important from the sensory standpoint.

If the eye, starting from a tertiary position, follows with sufficient speed any straight line that is not a meridian, a rotation of that line will be noted by the observer. This rotation indicates that a cyclorotation of the eye has occurred. A movement of the eye along the meridians avoids this, and Hering⁵² has therefore spoken of Listing's law as the law of avoidance of apparent movement.

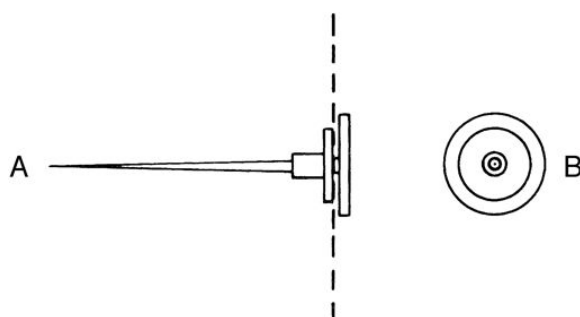


FIGURE 4-8. Needle coincidence device. A, Side view. B, View seen by observer when his or her eye is in the kinematic primary position. (From Tschermak-Seysenegg A von: *Methodik des optischen Raumsinnes und der Augenbewegungen*. In Abderhalden E, ed: *Handbuch der biologischen Arbeitsmethoden*, vol 5. Berlin, Urban & Schwarzenberg, 1937, p 1141.)

Meissner⁸¹ called it the law of easiest spatial orientation. Helmholtz⁵⁰ believed that by following Listing's law the spatial impressions are best brought into harmony with those of the nonmoving eye so that "fixed objects are perceived as fixed."

CYCLOROTATIONS AND LISTING'S LAW. Although Listing's law implies that under specified conditions the eye does not make cyclorotations, the eyes in certain circumstances do make cyclorotations. Cyclorotations (cycloductions and cycloversions) occur with postural changes of head and body and are required in binocular vision in the form of cyclovergences to compensate for incorrect orientations of the vertical meridians of the two eyes.

Early studies of ocular motility had already shown that there were certain deviations from Listing's law. Some eyes, especially myopic eyes, do not have a clear-cut kinematic primary position. In some individuals this position tends to change with time. In distance vision there is more disclination (tipping temporally at the top) in elevation and less disclination in depression of the principal retinal meridians relative to the primary position. Near vision (convergence) induces an excyclorotation that becomes greater the more the eyes converge (Fig. 4-9). This cyclorotation increases with elevation of gaze and decreases with depression of gaze for a given degree of convergence.¹⁴¹ All this has been interpreted as a break-

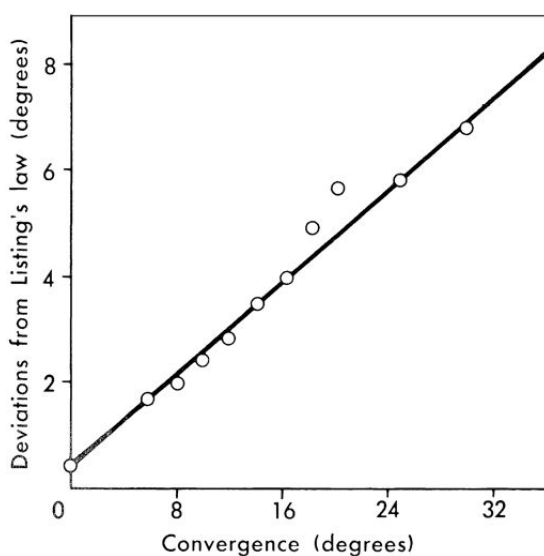


FIGURE 4-9. Cyclorotation in convergence. Data after Landolt. (From Alpern M: *Movements of the eyes*. In Davson H, ed: *The Eye*, vol 3. New York, Academic Press, 1962.)

down of Listing's law. Tschermak-Seysenegg¹³⁰ made the point, based on experimental and mechanical considerations, that this was not a breakdown of Listing's law but that the cyclorotations were superimposed on the cyclorotation-free movements. This also explained, according to Tschermak-Seysenegg, the reason for four rather than two vertical muscles. For cycloduction-free movements, only one elevator and one depressor would suffice. However, since cyclorotations must occur, provisions must be made for their execution.

Each single elevator (or depressor) can cooperate with the other elevator (or depressor) of the same eye (the superior or inferior rectus with the inferior or superior oblique) in executing a cyclorotation-free elevation (or depression). Each elevator (or depressor) can also cooperate with the adjacent muscle (superior rectus with superior oblique, inferior rectus with inferior oblique) in an elevation-free cyclorotation movement. This splitting of the vertical muscles into four individual muscles is the most economical way to satisfy both the requirement for cyclorotation-free movements and the need for cyclorotations.

How can the constancy of cyclorotation according to Listing's law be explained? A neural control mechanism has been suggested that is capable of maintaining a given degree of cyclorotation for each gaze position.⁸⁷ Apparent violations of Listing's law during sleep^{87, 126} in near vision^{62, 83, 84, 103} and elicited by the vestibulo-orbital reflex²⁶ are in accord with this concept. Guyton⁴⁶ demonstrated the complexity of the interplay between vertical and cyclorotational innervation by eliciting vertical eye movements in normal subjects and patients with superior oblique paralysis in whom cycloductions were experimentally induced or cyclofusion was challenged. Westheimer and Blair¹³⁶ suggested that the orientation specificity of certain cortical neurons may be involved in maintaining the geometric constancy of the horizontal and vertical retinal meridians. However, Demer and coworkers²⁹ pointed out that a complex neural substrate for Listing's law need not be invoked since the violations of the law cited above are of small magnitude and may simply constitute neural noise. The authors proposed that the pulleys of the four rectus muscles (see p. 41) and the drumhead-like suspension of the globe by Tenon's fascia provide a passive orbital mechanism sufficient to explain Listing's law.

Sherrington's Law of Reciprocal Innervation

AGONIST, ANTAGONIST, AND YOKE MUSCLES. As a rule, every contraction of a muscle brings about a movement. Considered as the mover producing that movement, the muscle is called an *agonist*. A movement in the direction opposite that produced by the agonist is caused by its *antagonist*. Thus, the medial rectus muscle adducts the globe, and the lateral rectus muscle abducts it. The medial and lateral rectus muscles are antagonists.

Two muscles moving an eye in the same direction are *synergists*. The superior oblique muscle and the inferior rectus muscle are both depressors of the eye. As such they are synergists. However, the superior oblique muscle causes an incyclorotation and the inferior rectus muscle, an excyclorotation. In respect to cyclorotation, they are antagonists.

Synergistic muscles in the two eyes—muscles that cause the two eyes to move in the same direction—are known as *yoke* muscles. Some readers may not be familiar with the word “yoke.” In fact, in correcting examination papers and even in the ophthalmic literature we have seen this word not infrequently misspelled “yolk.” The reader who grew up in an urban society or in a country where draft animals have been replaced by agricultural machines may not know that yoke refers to a “wooden bar or frame by which two draft animals (e.g., oxen) are joined at the head or necks for working together.”¹³³ When one yoked animal moves in a certain direction, so must the other, and the same applies to the cooperation between a pair of yoke muscles. In passing we note that although there are words for yoke in many languages, this vivid and didactically useful allegory in explaining the functional linkage between the extraocular muscles of the two eyes is to our knowledge limited to the English ophthalmic literature (see also Chapter 20).

The right medial rectus and the left lateral rectus muscles cause levoversion of the eyes. They are yoke muscles. As pointed out earlier in this chapter, a pair of muscles in one eye can be yoked with a pair in the other eye. For instance, the elevators of one eye (superior rectus and inferior oblique muscles) are yoked as a unit to the elevators of the fellow eye, and the two pairs of depressors are similarly yoked. Thus, antagonistic muscles act on the same eye, and yoke muscles

act on both eyes. Yoking may change according to the different type of eye movements. For instance, the medial rectus muscle of one eye is yoked with the lateral rectus muscle of the other eye in lateroversion, but the medial rectus muscles in both eyes are yoked during convergence.

The term *contralateral antagonist*, used in connection with so-called inhibitional palsy (see Chapter 20), is contradictory and should be avoided. This term refers to the *antagonist of the yoke muscle*. For example, a patient with paralysis of the right superior oblique muscle who habitually fixates with the right eye will have an apparent paresis of the left superior rectus muscle. The explanation for this is that in the fixating eye the innervation of the pairs of elevators (superior rectus and inferior oblique muscles) is below normal because of loss of the opposing action of the paralyzed superior oblique muscle. Thus, in accordance with Hering's law (see p. 64), equally diminished innervation will flow to the elevators of the left eye and the left eye does not elevate fully. Elevation will become normal, however, when the left eye takes up fixation.

SHERRINGTON'S LAW. Whenever an agonist receives an impulse to contract, an equivalent inhibitory impulse is sent to its antagonist, which relaxes and actually lengthens. This is *Sherrington's law of reciprocal innervation*,¹²¹ which implies that the state of tension in the agonist exerts a regulatory influence on the state of tension in the antagonist and vice versa. The finely graded interplay between opposing eye muscles makes movements of the globe smooth and steady. Whether there are actually active centrifugal inhibitory neural impulses flowing to the antagonist as the agonist contracts or whether there is merely an absence of innervation is not clear. Sherrington's law applies to all striated muscles of the body and is not limited to the extraocular muscles.

The basic mechanism underlying agonistic and antagonistic muscle action was clearly understood by Descartes^{22, 30} more than 250 years before Sherrington's classic experiment^{121, 122} in which he demonstrated reciprocal innervation of the extraocular muscles. When Sherrington severed cranial nerves III and IV intracranially on one side (e.g., on the right), a paralysis occurred in all the extraocular muscles except the lateral rectus muscle, which was innervated by cranial nerve VI. The right globe was now in divergent position. After allowing time for the motor nerves to the extraoc-

ular muscles to degenerate, Sherrington electrically stimulated the right cortical area, eliciting a conjugate deviation of the eyes to the left. The left eye turned all the way to the left, but the right eye moved only to the midline. This behavior of the right eye gave evidence that the original divergent position was the result of a contraction of the right lateral rectus muscle, which was unopposed by the tonus of its antagonistic right medial rectus muscle. When a levoversion impulse was induced, the reciprocal innervation to the right lateral rectus muscle caused it to relax to the point where the globe could return to the midline.

The validity of Sherrington's law of reciprocal innervation now has been established in intact human eyes by means of *electromyography*. Figure 4–10 demonstrates electrical silence in the left lateral rectus muscle with the eyes in extreme dextroversion and in the right medial rectus in extreme levoversion. A comparable result is achieved when recordings are made from horizontal rectus muscles during calorically induced nystagmus.

Reciprocal innervation is physiologically and clinically important. It explains why strabismus occurs following paralysis of an extraocular muscle. Reciprocal innervation must be considered when surgery on the extraocular muscles is performed. Co-contraction of antagonistic muscles instead of relaxation of the antagonist, for instance, as demonstrated by electromyography in the retraction syndrome (see Chapter 20), is said to be always abnormal in eye muscles, although it does occur in skeletal muscles. Some clinical applications of Sherrington's law are shown in Figure 4–11.

Hering's Law of Equal Innervation

Isolated innervations to an extraocular muscle of the eye do not occur, nor can the muscles from one eye alone be innervated. Impulses to perform an eye movement are always integrated, and all ocular movements are associated. Dissociated ocular movements are seen only in pathologic states. Whenever an impulse for the performance of an eye movement is sent out, corresponding muscles of each eye receive equal innervations to contract or relax. This is the basic *law of equal innervation*, also called the *law of motor correspondence* of the eyes, first proposed by Hering,⁵¹ who placed it parallel to the law of sensory correspondence (see Chapter 2). Hering's law explains *primary* and *secondary deviations* in paralytic strabismus (see Chapter 20). Hering's law applies only to extraocular muscles. There are no muscles in the body that are functionally interrelated as are the pairs of yoke muscles of the eye.

When Hering⁵¹ formulated his law in 1868, reference was made only to voluntary eye movements. Involuntary eye movements were little known or considered at that time. Many textbooks still state that Hering's law is valid only for voluntary version movements. Actually, it applies to all normal eye movements, including vergences. However, it must be emphasized that one of the eyes need not make an observable movement. Because under certain circumstances one eye seemingly moves alone does not invalidate Hering's law.

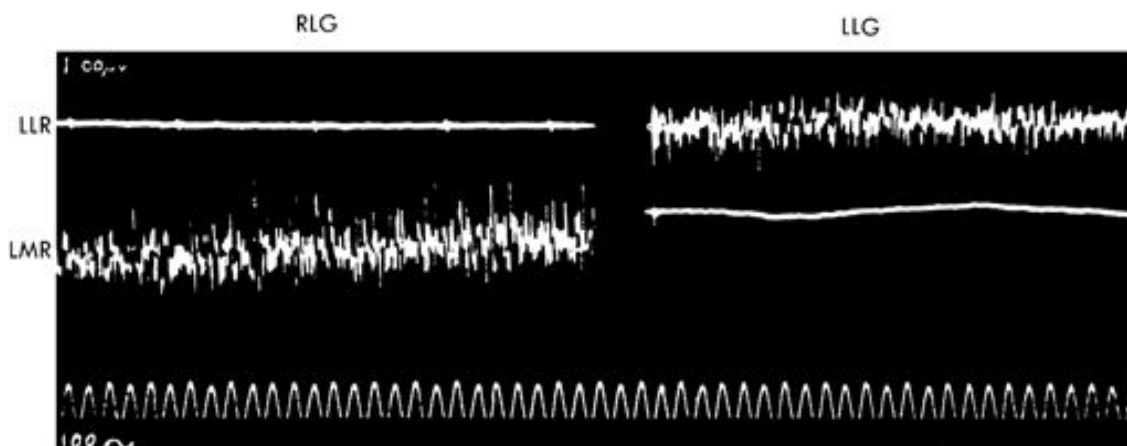


FIGURE 4–10. Electromyographic evidence for reciprocal innervation of extraocular muscles. Upper tracing from left lateral rectus muscle (LLR); lower tracing from left medial rectus muscle (LMR). In extreme right lateral gaze (RLG) the LLR is electrically silent and the LMR is electrically active. In extreme left lateral gaze (LLG) the LMR is electrically silent and the LLR is electrically active. (Courtesy of Dr. Goodwin M. Breinin.)

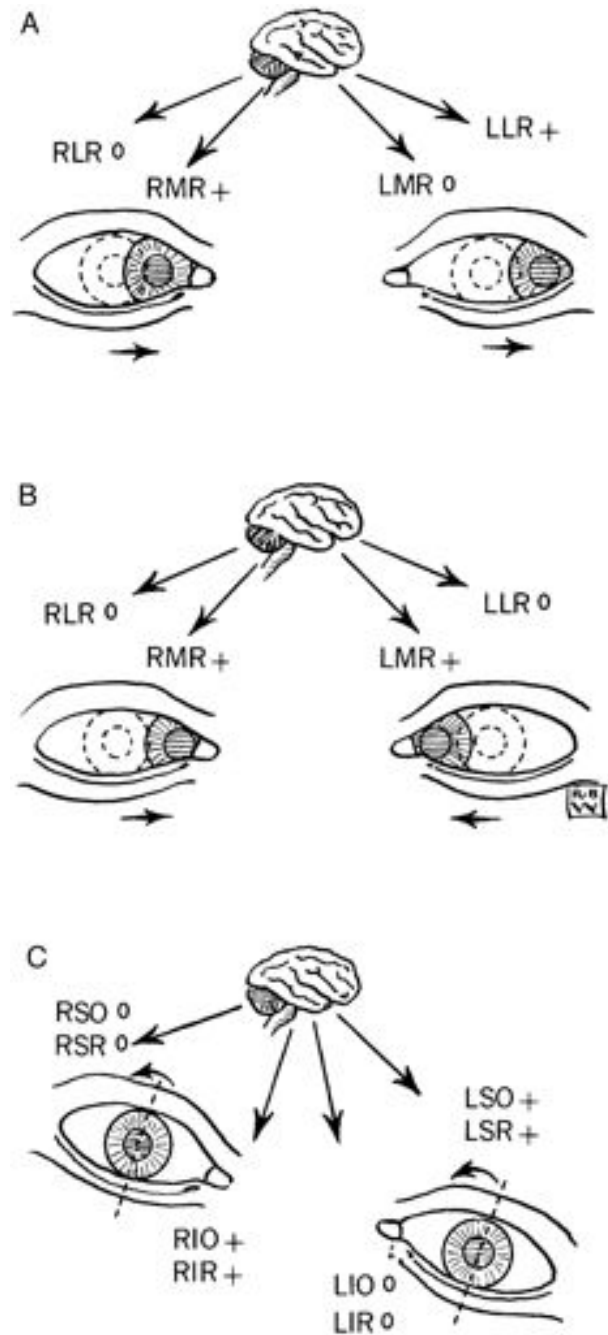


FIGURE 4-11. Sherrington's law of reciprocal innervation. *A*, On leversion, increased contraction (+) of the right medial rectus (RMR) and left lateral rectus (LLR) is accompanied by decreased tonus (0) of the antagonistic right lateral (RLR) and left medial rectus (LMR) muscles. *B*, Increased activity of both medial rectus muscles and decreased tonus of both lateral rectus muscles during convergence. *C*, Contraction and relaxation of opposing muscle groups on dextrocycloversion when the head is tilted to the left shoulder. RSO, right superior oblique; RSR, right superior rectus; LSO, left superior oblique; LSR, left superior rectus; RIO, right inferior oblique; RIR, right inferior rectus; LLO, left inferior oblique; LIR, left inferior rectus. (From Noorden GK von: Atlas of Strabismus, ed 4. St. Louis, Mosby-Year Book, 1983.)

ASYMMETRICAL CONVERGENCE AND HERING'S LAW. Asymmetrical convergence has been cited as an example that disproves Hering's law, since it appeared that unequal innervations could be sent to the two eyes. This is not the case. Assume that a person fixates an object point, F, at 2 m distance. A second object point, P, is placed to the right of the left visual line at 40 cm from the eyes. The position of P is such that fixation on P requires asymmetrical convergence (Fig. 4-12A). The left eye makes a smaller movement than the right eye, which is evident from the geometry of this drawing. In Figure 4-12A, the

right eye would have to move through the angle FPCr and the left eye through the angle FPCl. If P lies on the line of sight of the left eye (Fig. 4-12B), that eye would not have to make a movement. One would think that in this case the only thing necessary to achieve binocular fixation of P would be an adduction movement of the right eye. Gross observation seems to indicate that this is indeed the case: the right eye makes a movement to the left, whereas the left eye appears to remain essentially stationary. Similarly, if a patient with intermittent exotropia (see Chapter 17) binocularly fixates a distant object and fusion breaks, only one

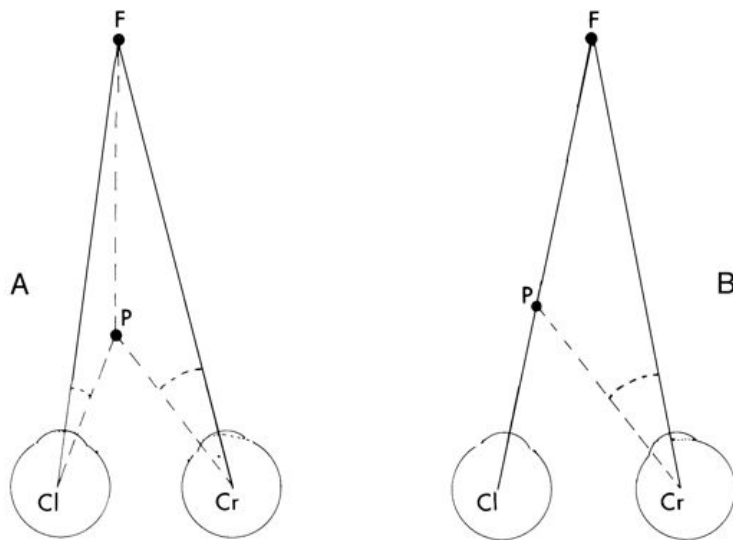


FIGURE 4-12. *A*, Asymmetrical convergence. F, fixation point; P, nearer fixation point, asymmetrically placed; Cl and Cr, left and right center of rotation. *B*, Asymmetrical fixation point. P, on line of fixation of left eye.

eye appears to move outward; or if a base-in prism is dropped in front of one eye of a person who binocularly fixates an object, only an inward movement of that eye will be noted, followed by an outward movement on removal of the prism.

Hering⁵² himself interpreted the unequal movements of the two eyes as an interplay between versions and vergence impulses. If the nearer object is to the left, a levoversion impulse strong enough to bring the visual line of the right eye to P (see Fig. 4-12A) must be given. If only a levoversion impulse were to be given, the left eye would lose fixation on P. If only a convergence impulse were given, neither eye would achieve fixation on P. What actually happens, according to Hering, is that the levoversion impulse is partially canceled in the left eye by a convergence impulse (or completely if P is on the line of sight to the left eye; see Fig. 4-12B), whereas the two are additive in the right eye. Thus, binocular fixation of P is achieved. Similarly, a lateroversion impulse, imparted by placing a prism base-out in front of one eye, is offset by a convergence impulse.

Which mechanism controls the motor responses of the eyes in asymmetrical convergence? Hering^{53, p. 524} believed innervations for versions and vergences were sent to the horizontal eye muscles and were balanced out peripherally. He observed fine movements of the stationary eye and suggested that these arose from the different velocities of the two movements induced by the opposing impulses. He even auscultated the muscles and heard increased muscle noise in the stationary eye.⁵⁴

Alpern,^{3, p. 93} in his attempt to verify Hering's

law of equal innervation, confirmed Hering's predictions and findings by *electro-oculography*, a method of recording ocular movements that makes use of the standing potential of the eyes. The recording is done from skin electrodes, one to each side of the eye. Changes in potential between these electrodes, induced by a shift in position of the eye and therefore of the relation between the electrical field of the eye and the electrodes, are used to indicate direction, amplitude, and velocity of ocular movements. Alpern placed a prism base-out in front of the right eye of an observer and made electro-oculographic recordings from the two eyes. Figure 4-13, taken from Alpern's work, shows that sudden placement of the prism before the right eye causes both eyes to move. The movement consists of two phases, the first phase having the velocity characteristics of a rapid version movement and the second phase, the velocity characteristics of a slow vergence movement. Electro-oculographic recordings also showed that both eyes move when the eyes assume an asymmetrical convergence position.⁴ With a photographic technique using light reflections from the cornea, Westheimer and Mitchell¹³⁷ found that movements requiring asymmetrical convergence consisted of two parts, a saccadic movement and a vergence movement. On the other hand, Enright³⁸ showed that under certain conditions smooth, slow and "saccade-free" asymmetrical convergence movements can be elicited, which is in apparent contradiction to Hering's law.

Electromyographic studies gave conflicting results. Tamler and coworkers¹²⁷ found that when an object was moved slowly and smoothly along the line of sight toward an eye, there was an increment

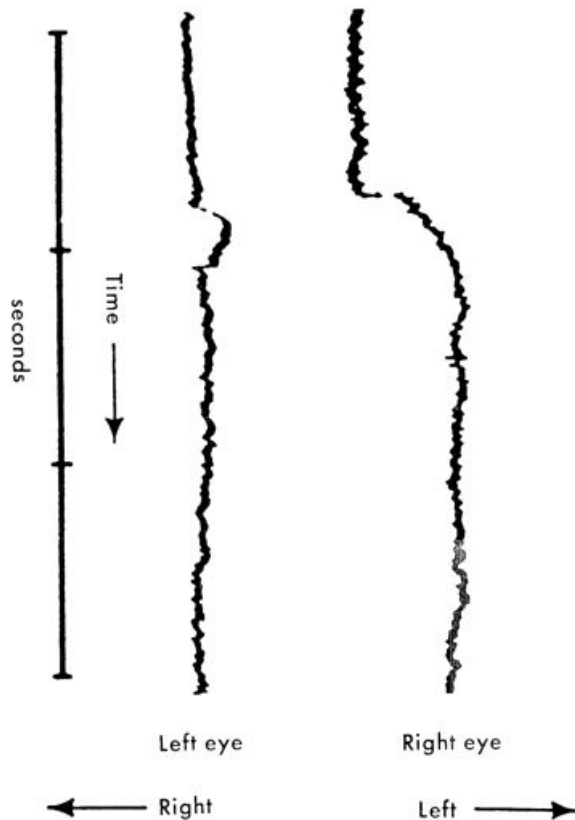


FIGURE 4-13. Electro-oculographic record of eye positions when a small prism base-out is placed in front of the right eye. Note the slow vergence movement of the right eye and saccadic movement of the left eye. (From Alpern M: *Movements of the eyes*. In Davson H, ed: *The Eye*. vol 3. New York, Academic Press, 1962.)

of the electrical activity of the medial rectus muscle of the other eye with a corresponding decrement in the antagonistic lateral rectus muscle. In the stationary eye there was at the same time an increment in electrical activity of both the medial and lateral rectus muscles. The authors concluded that this co-contraction of the two horizontal muscles guaranteed the immobility of the eye and confirmed Hering's view of a peripheral adjustment of opposing version and vergence innervations. Breinin,¹⁵ and later Blodi and Van Allen⁹ noted no change in the electrical activity of the horizontal muscles of the stationary eye. In contrast to Hering,⁵¹ Breinin¹⁵ concluded that "there is integrated in the brain all forms of vergences and versions. These are added together, and what emerges into the final common pathway is the vector resultant. This is a simple reciprocity mechanism in which there is never any co-contraction."

Alpern³, p. 94 tried to reconcile the findings of these authors by stating that differences have to be expected, depending on whether asymmetrical

convergence was achieved by a jump from one fixation point to the other or by a pursuit movement. However, it would appear that both Tamler and coworkers¹²⁷ and Blodi and Van Allen⁹ used pursuit movements.

Some clinical applications of Hering's law of equal innervation are shown in Figure 4-14.

Experimental Studies of Integration of Ocular Movements by Muscle Transposition

There is ample physiologic and clinical evidence for the integration and coordination of the ocular movements under normal conditions. That this coordination can be maintained or reestablished after transposition of various extraocular muscles has been shown in a number of experimental investigations in monkeys, cats, and dogs. Surprisingly, normal excursion of the globe and coordinated eye movements were affected only insignificantly or not at all after these manipulations.^{71, 72, 77, 79, 94, 132}

The mechanism of recovery of coordination of the extraocular muscle action after switching their insertions in combination with excising a muscle partially or completely is by no means clear. Certainly one tends to question the validity of purely mechanical explanations and to look to the nervous system for an explanation of the effects of the transpositions. Marina,⁷⁸ who was a neurologist, did indeed conclude from his experiments that there was no fixity in the relation of the pathways in the brain stem and extended this view to a general theory. On the other hand, Watrous and Olmsted¹³² made the significant observation that after transposition of extraocular muscles, the reflex responses of these muscles were in no way different from those of muscles on which surgery had not been performed. They showed this by enucleating the globe and attaching the muscles to recording devices and inducing nystagmus by caloric stimulations or rotations of the body. Thus, the question of the effect of transposition of the extraocular muscles remains a challenge, especially in view of the increasing use of muscle transpositions in human patients (see Chapter 25).

Survey of Ocular Movements and Their Characteristics

Terminology of Ocular Movements

The classification and terminology of ocular movements has been a source of considerable con-

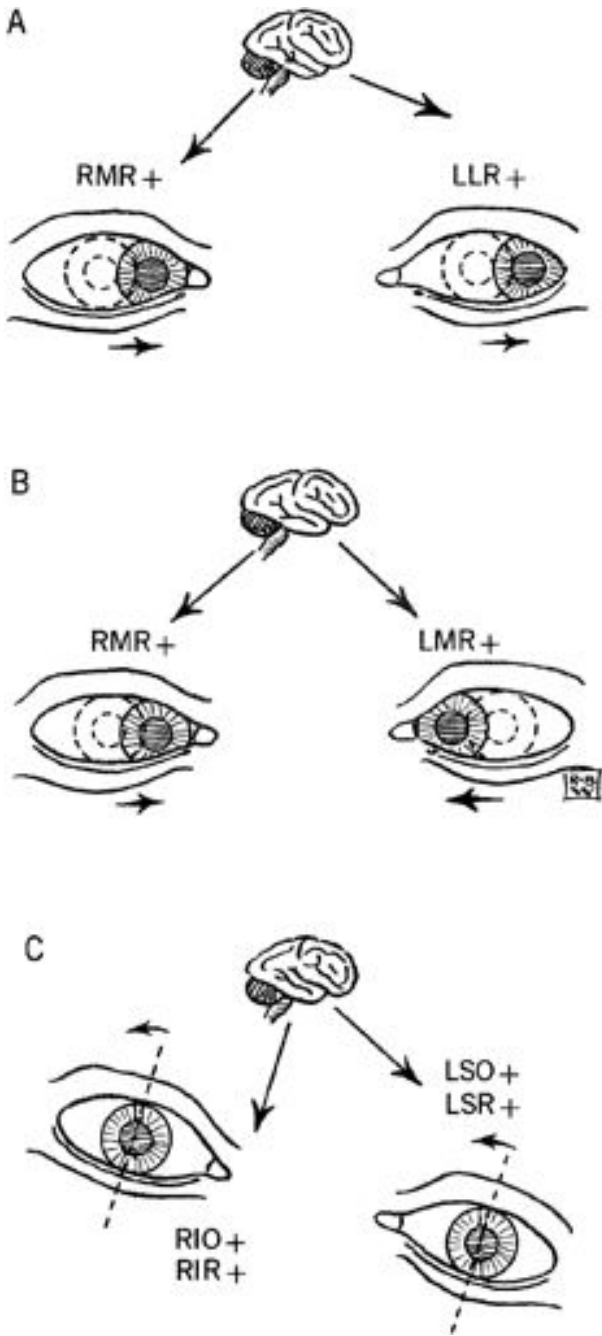


FIGURE 4-14. Hering's law of equal innervation. *A*, During leversion the right medial rectus and the left lateral rectus muscles receive an equal and simultaneous flow of innervation. *B*, During convergence the right and left medial rectus muscles receive equal and simultaneous innervation. *C*, When the head is tilted to the left, the muscle groups controlling excycloduction of the right eye and incycloduction of the left eye receive equal and simultaneous innervation. However, inclination of the head is only partially compensated for by wheel rotations of the eyes. (From Noorden GK von: Atlas of Strabismus, ed 4. St. Louis, Mosby-Year Book, 1983, p 21.)

fusion. It is to Lancaster's^{69, 70} credit that unified and basically simple terminology is now almost universally accepted (Table 4-3).

UNIOCULAR MOVEMENTS. All uniuocular rotations are termed *ductions*. The various duction movements introduced in this chapter are summarized in Table 4-3 and illustrated in Figure 4-2. Prism vergences should never be called ductions.

BINOCULAR MOVEMENTS. Synchronous simultaneous movements of the two eyes in the same direction are called *versions*. Synchronous simultaneous movements of the two eyes in opposite

directions are called *vergences*. Versions are fast and vergences are slow eye movements. The various versions and vergences are listed in Table 4-3.

Versions

The versions fulfill the first two tasks assigned to the motor system of the eyes (see Chapter 1): to enlarge the field of view and to bring the object of attention onto the fovea. Versions are either voluntary or involuntary. They are voluntary if the subject moves the eyes of his or her own volition.

TABLE 4-3. Terminology of Ocular Movements

Monocular Movements (ductions)	Binocular Movements	
	Versions	Vergences
Adduction	Dextroversion	Convergence
Abduction	Levoversion	Divergence
Sursumduction (elevation)	Sursumversion (elevation)	Right sursumvergence* (left deorsumvergence)
Deorsumduction (depression)	Deorsumversion (depression)	Right deorsumvergence† (left sursumvergence)
Incycloduction	Dextrocycloversion	Incyclovergence
Excycloduction	Levocycloversion	Excyclovergence

*Positive vertical divergence (in the terminology of Hering, used by Bielschowsky, and others).

†Negative vertical divergence (in the terminology of Hering, used by Bielschowsky and others).

Involuntary versions are semireflex movements in response to optical, acoustic, or other stimuli.

Optical stimuli that reach the retinal periphery and attract the attention of the observer elicit *saccadic eye movements*. The purpose of a saccade is to place the image on the fovea and to keep it there as long as it attracts attention. *Smooth pursuit* or *following movements* are made when tracking a moving object. Thus, the function of the saccadic eye movement system is to correct the position error between target and fovea, and the function of the pursuit system is to match eye velocity to target velocity. Other examples of fast saccadic eye movements are random movements that occur in response to a command (*command movements*), eye movements occurring during the fast phase of optokinetic or vestibular nystagmus, during sleep (*rapid eye movements, REMs*), and correcting saccades during fast pursuit movements.⁹³ Even during fixation of a stationary object the eyes are never completely still. A normal observer will make small saccadic eye movements of a few minutes of arc and will be unconscious of doing so (miniature eye movements, microsaccades: see p. 79). In monocular vision, saccadic and pursuit movements are a form of duction.

The saccadic and pursuit systems have different characteristics with respect to latency and velocity and together with the vergence and vestibular systems make up four oculomotor subsystems. These systems have different neural controls but a final common path.¹¹⁴ A comprehensive review of the saccadic, pursuit, and vestibulo-optic systems exceeds the scope of this text and can be found in Robinson's chapter¹¹⁰ on eye movement control.

HORIZONTAL VERSIONS. From what has been said in the preceding discussions in this chapter, the manner in which these rotations evolve should

be evident. For each direction there is a prime mover that contracts actively. The antagonist receives inhibitory impulses. The vertical rectus and the oblique muscles stabilize the movement by maintaining or adjusting their tonus to prevent vertical deviations of the line of sight and to avoid cyclorotations. As the prime mover contracts and its arc of contact shortens, it is assisted by the adducting or abducting action of the other muscles. The movement of the globe is restricted and controlled by the elastic forces of Tenon's capsule and the check ligaments and, to a degree, by the elastic pull of the antagonist.

VERTICAL AND OBLIQUE VERSIONS. Similar considerations apply to the oblique versions, but such a situation is complicated by the existence of two elevators and two depressors. The classic description of the function and whole range of action of these muscles has been described elsewhere in this chapter. It has been pointed out (see p. 57) that this classic view of yoking between oblique muscles and the contralateral vertical rectus muscles has been challenged by Boeder.^{10, 11} The muscles less engaged in performing the vertical rotations stabilize the line of sight. The horizontal rectus muscles bring the eyes to the required lateral or medial position. They also assist in extreme positions of elevation and depression.

A point of practical importance in connection with the A and V patterns of strabismus (see Chapter 19) is the relative increase in divergence of the lines of sight in elevation and the relative decrease of divergence in depression. The change in relative position of the visual axes must not be confused with the previously mentioned change in relative position of the primary vertical meridians of the retinas as a result of the cyclorotation occurring on elevation or depression.

The divergence of the two visual lines in elevation was interpreted by Helmholtz⁵⁰ as a learned association since the eyes are normally elevated in distance fixation and depressed in near vision. Hering,⁵³ on the contrary, explained it as a result solely of mechanical factors in the relationship of the elevator and depressor muscles, since there was no change in accommodation for a given convergence position when the eyes were elevated or depressed. Payne and von Noorden⁹⁸ confirmed this observation. Such a change in accommodation would have to occur if there were an active change in innervation of the horizontal muscles in elevation or depression.

CYCLOVERSIONS. Cycloversions are restricted in amplitude but can be artificially produced with appropriate haploscopic targets.^{46, 105} Naturally occurring cycloversions are postural reflexes. They arise from stimuli in the neck muscles and the inner ear. The influence of body posture on eye movements and eye position is much greater in lower vertebrates than in humans, but even in humans there are certain effects that are of clinical importance. This is true in particular for the influence of the inner ear.

The semicircular canals with their endolymph are recognized as the peripheral organs of the sense of equilibrium. Stimulations set up by a current of endolymph generated in the semicircular canals, which arise with every change in the position of the head or body, are among the important sources of tonus of the extraocular muscles. The changes in relative tonus within the eye muscles are such that each labyrinth tends to pull each eye toward its side, but since the effect of the two labyrinths is equal and antagonistic, no change in the position of the eyes takes place when the head is erect and straight. However, with every change of head and body position, a change in tonic tension of the extraocular muscles occurs that prevents the eyes from following the rotations of the head. In humans this causes a rotation of the eyes to the left when the head is turned to the right and a rotation of the eyes to the right when the head is turned to the left (Fig. 4–15A and B). When the head is lifted, the eyes go down; when the head is lowered, the eyes go up. This is the *oculocephalic reflex* (doll's head phenomenon, *oculovestibular reflex*, *Puppenkopffänomen*¹¹⁸; Fig. 4–15C and D), which is important to test for the intactness of the oculomotor nuclei in patients with supranuclear paralysis of gaze or in distin-

guishing true paresis from pseudoparesis of the lateral rectus muscle in young children (see Chapter 20).

Cycloversions that occur on tilting of the head to one shoulder are of considerable clinical importance. When the head is tilted toward the right shoulder, the right superior rectus and oblique muscles and the left inferior rectus and oblique muscles cooperate in producing a levocycloversion; when the head is tilted toward the left shoulder (see Fig. 4–14), the left superior rectus and oblique muscles and the right inferior rectus and oblique muscles produce a dextrocycloversion movement. In other words, the upper muscles of the eye on the side toward which the head is tilted and the lower muscles of the opposite eye receive active impulses to contract with corresponding relaxation of their antagonists.

This reflex originates from the otoliths and, as is true of all eye movements controlled by the inner ear, is a static reflex. In humans, its original goal of keeping the retinal meridians properly oriented in space is no longer achieved. The eyes of humans compensate only to a small extent for the tilting of the head to one shoulder. A quick tilting of the head may result in a cyclorotation of as much as 20°, but this is transitory.⁸⁶ The eyes immediately stabilize at a lesser degree of excursion, which is maintained as long as the head remains tilted. This cycloversion is subject to great individual variations. A cycloversion produced by a head tilt of 60° may range from a minimum of 4° in some persons to 16° in others, with an average of 8°.⁸ Though of little physiologic significance, the phenomenon is of considerable clinical value in the diagnosis of paresis or paralysis of the cyclovertical muscles, especially the superior oblique muscle. Its application is known as the head tilting test of Bielschowsky (see Chapters 12 and 20).

Javal⁶⁰ was the first to describe the cycloversion that occurs on tilting the head to one shoulder. Javal, who had a considerable amount of astigmatism, noted a decrease in visual acuity when he tilted his head. He correctly attributed this decrease to a cycloversion of his eyes, which caused the axis of his astigmatism to change relative to the correction in his glasses. This historical vignette is an example of how a keen observer with a fine analytic mind can make important discoveries with the simplest of means. Van Rijn¹⁰² and Van Rijn and coworkers,¹⁰⁵ by using Collewijn's modification of Robinson's search coil



FIGURE 4-15. A, Levoversion with the head turned to the right. B, Dextroversion with the head turned to the left. C, Depression of the eyes with the chin elevated. D, Elevation of the eyes with the chin depressed.

technique for the recording of eye movements, showed that cycloversions may also be elicited optically and, unlike cyclovergences, are rapid responses without a phase lag. From the same laboratory comes a report according to which cyclovergences are more stable during fixation than are cyclotorsions.¹⁰⁶ Although cyclorotations as a rule are thought to be purely reflexive, that is, without indication of voluntary control, Balliet and Nakayama⁷ showed that human subjects can be trained to make large cyclorotary eye movements at will.

Vergences

The vergences fulfill the second of the two tasks assigned to the motor system of the eyes (see

Chapter 1). They align the eyes in such a way as to ensure and maintain binocular fixation and binocular vision. Since, by definition, they are movements of the two eyes in opposite directions, they are also known as *disjunctive movements*.

If prisms of appropriate power are placed horizontally or vertically in front of the eyes of an observer with normal binocular cooperation, he may see double for a brief moment but will immediately regain binocularity. After the removal of the prisms the observer may again experience diplopia, but single vision is promptly reestablished. The eyes move toward the apex of the prisms (Fig. 4-16). If the prisms are placed base-out (tempeward) in front of the eyes, they must con-

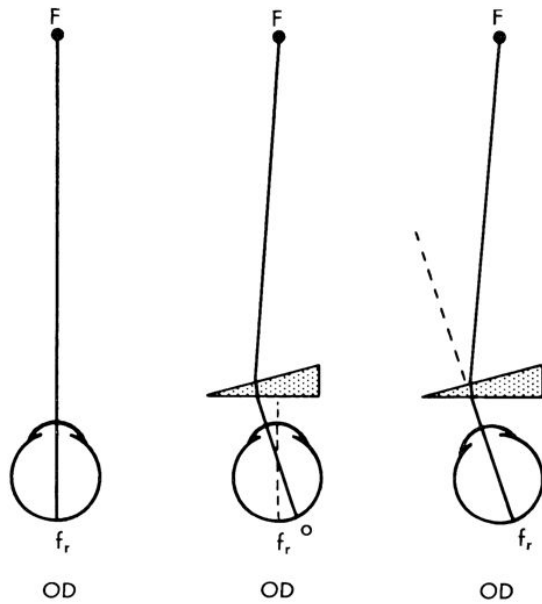


FIGURE 4-16. Diagram showing that the eye turns toward the apex of a prism. F, fixation point; f_r , right fovea; o, position of image of fixation point when prism is first placed in front of the eye.

verge to restore binocularity; if the prisms are placed base-in (nasalward), the eyes must diverge. If the prisms are placed base-up in front of one eye and base-down in front of the other eye, the eyes must perform a vertical vergence movement. Under conditions of casual seeing, convergence occurs when an object approaches the eyes and divergence occurs when an object recedes. As has been pointed out in this chapter, eye muscles cooperate differently in vergences than in versions. For example, in a levoversion movement the left lateral and right medial rectus muscles receive impulses to actively contract, whereas in convergence both medial rectus muscles contract.

Vergence movements serve not only to bring the eyes into proper alignment but also to maintain this alignment. If a person has a deviation of the visual axes, a *heterophoria* (see Chapter 8), compensatory vergence impulses adjust the tonus of the extraocular muscles to ensure proper relative positioning of the eyes. Thus, vergence impulses are sent out and vergence movements are made in the interest of fusion. The particular type of vergences discussed thus far are also referred to as *fusional movements*. These movements represent the motor aspect of fusion, in contrast to the sensory unification of the retinal images discussed in Chapter 2.

Vergence is a generic term intended to cover all disjunctive movements of the eyes: the fusional movements elicited by disparate stimulation, and

the horizontal disjunctive movements not so elicited but connected with accommodation and pupillary constriction (see Chapter 5). These movements are performed also in the interest of single binocular vision.

All fusional movements, with the exception of convergence, which can also be voluntarily produced, are *psycho-optical reflexes* (see Chapter 1). The stimulus eliciting the reflex is disparate retinal imagery. When a retinal image that falls on corresponding retinal elements is shifted so as to fall on disparate retinal elements (as is the case with approaching or receding objects or when prisms are placed before the eyes), the eyes move to correct their relative position and again bring the images on corresponding retinal areas. This avoids diplopia caused by disparate retinal imagery and ensures bifoveal fixation. However, to produce fusional movements, the disparity must exceed the size of Panum's area (see Chapter 2); otherwise sensory fusion without motor fusion will take place. The size of Panum's area represents the lower limit of the disparity that will elicit fusional movements.

There is also an upper limit that, when exceeded, will not result in vergences. These two limits determine the *amplitude of motor fusion*, which is usually greatest for convergence movements and smallest for vertical vergence movements (see Chapter 12). In normal subjects the amplitudes vary considerably from individual to individual. They vary with the state of alertness, that is, whether the subject is tired or rested or under the influence of a toxic agent. They depend on the type of visual activity prior to the measurement, the procedure by which the amplitudes are measured, and to a large extent on the state of the individual's neuromuscular apparatus. Horizontal and vertical fusional amplitudes are determined by prisms or with some haploscopic device.

HAPLOSCOPY. Haploscopic devices are of fundamental importance for the study of the sensorimotor cooperation of the eyes. The so-called major amblyoscopes, widely used in orthoptic practice (see Chapter 12), all derive from the laboratory instrument originally conceived by Hering. In haploscopy, the visual fields of the two eyes are differentiated and a separate target is presented to each eye. Hering's original instrument⁵¹ was designed primarily for studying the relationship between accommodation and convergence (Fig. 4-17).

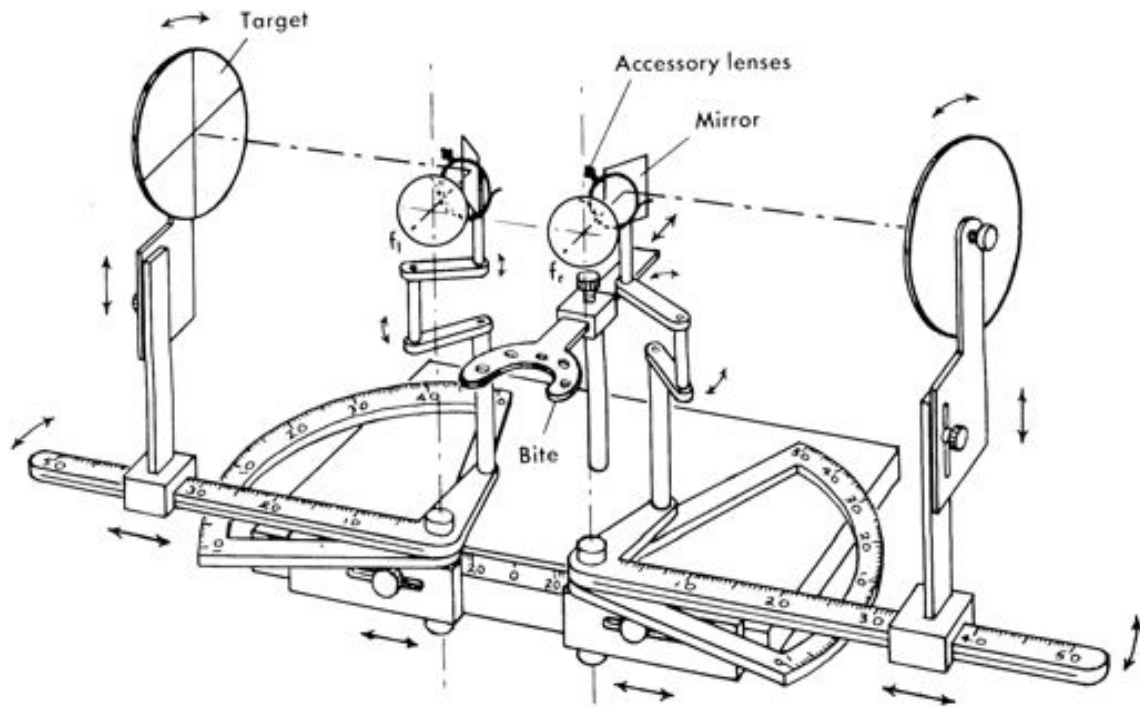


FIGURE 4-17. A haploscope.

The head is fixed with an appropriate head- and chinrest provided with a bite-board. Two movable arms, one for each eye, are adjusted below the center of rotation of each eye so that the arm can be freely rotated around that point. Each arm carries a mirror set at 45° to the line of vision and a target placed on the arm to be seen by the eye. Horizontal, vertical, and cyclorotatory displacements of the stimuli can be made. The stimulus to accommodation is varied by placing the targets at different distances from the eyes along the arm. Numerous modifications of Hering's original design have been made and consist primarily of improvements and refinements in the adjustment of the interocular separation and in the movements of the targets in their plane. More compact, so-called major amblyoscopes of which there are a number of models, have been designed for orthoptic practice. These and other similar devices are particularly suited for measurement of the amplitude of the vergences. It is to be noted that the major amblyscope is the only instrument available in a clinical setting for the accurate measurement of cyclofusional amplitudes.

STEREOSCOPES. Stereoscopes also make use of the haploscopic principle, but they lack the flexibility of the haploscope of Hering. This is also true for the anaglyph system in which the visual fields of the two eyes are differentiated by means of complementary colors. For example, a

red lens is placed in front of the right eye and a green lens in front of the left eye. Targets with red and green outlines, matching the color of the filters, are then presented. Instead of differentiating the two visual fields by colored filters, polarized material may be used. Color differentiation is used in testing patients with the Hess screen; polarized material is used in some tests for stereopsis (see Chapter 12). The flexibility of the red-green and polarized tests—and for that matter of any haploscopic system—is enhanced by using projection devices, as in Lancaster's red-green test⁹¹ (see Chapter 12) and in the studies on peripheral fusion by Burian.¹⁸

PHASE DIFFERENCE HAPLOSCOPY. A more recent form of projection haploscope is that of Aulhorn,⁶ which uses a new principle of differentiating the two visual fields. A sector disk rotates in front of each eye at a speed above fusion frequency and with a phase difference of 90° between the two. One projector for each eye also is equipped with a sector disk in phase with the disk in front of the corresponding eye. In this way the projected image (but only the image produced by its own projector) is seen continuously by each eye (Fig. 4-18). The same degree of differentiation of the two visual fields can also be achieved with synchronized liquid crystal shutters.

ROLE OF RETINAL PERIPHERY IN MOTOR FUSION. As pointed out in the preceding discussion,

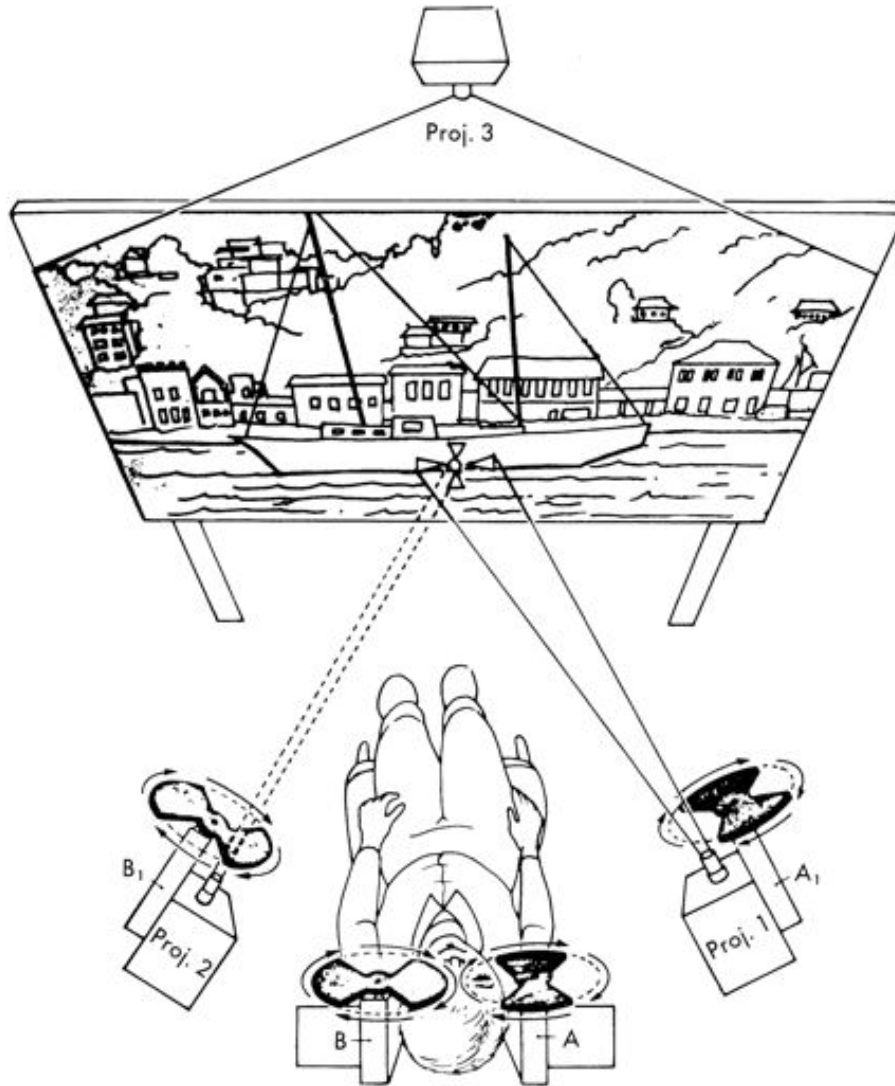


FIGURE 4-18. Phase difference haploscope of Aulhorn. The rotating segmented disks, A and A₁ and B and B₁, are synchronized and 90° out of phase. The cross, projected by projector 1, is seen only by the right eye, the circle only by the left eye. Projector 3 provides fusional background seen by both eyes. (From Noorden GK von: The etiology and pathogenesis of fixation anomalies in strabismus. *Trans Am Ophthalmol Soc* 67:698, 1969.)

the amplitude of vergences depends on many factors, one of which is the amount of fusible material in the binocular field of vision. If there is no fusible material, as when the eyes are presented with dissimilar haploscopic targets, no fusional movements are elicited. If the targets are similar, the amount of vergence that can be induced is a function of the size of the targets. In casual seeing, the whole surface of the two retinas is exposed to similar stimuli and the conditions for motor fusion should be optimal.

Clearly, the retinal periphery is a powerful factor in production of fusional movements. In view of its great extent, compared with the extent of the retinal center, it should be possible to produce a relative deviation of the lines of sight by

applying peripherally located fusional stimuli in an otherwise empty binocular visual field. This has proved to be the case.

Burian¹⁸ investigated with a projection haploscope the role of the retinal periphery in the production of fusional movements. Identical targets were superimposed on retinal areas of varying sizes and varying degrees of eccentricity, and the amplitudes of fusion obtained by these stimuli were tested. As expected, fusional movements could be elicited by peripherally placed disparate stimuli, and the hypothesis was confirmed that such stimuli appropriately placed and of adequate strength could break up central fusion, even if the observer paid close attention to the centrally fixed object and disregarded entirely the peripheral stimulus.

The significance of the finding is evident. It points out that, in addition to its function in twilight vision and perception of motion, *the retinal periphery makes an important contribution to stabilization of relative position of the eyes*. The importance of peripheral fusional stimuli is most obvious in cyclofusion. Since the vertical retinal meridians are not parallel but diverge or converge at the top, a cyclovergence movement may be required to make the vertical meridians parallel and maintain fusion. Even though cyclofusion may also occur on a sensory basis the strong influence of peripheral retinal stimulation on the motor component of cyclofusion must be emphasized.¹²⁵

Movements around the line of sight cannot be produced, or only with difficulty, by stimuli lying near or in the line of sight. They come about readily with stimuli extending toward the periphery of the retina. The situation can be best understood if the eye is likened to a wheel provided with a long rod (the visual line) fixed to its center. To rotate the wheel by holding the rod at its end is much less effective than to rotate it by its rim or its spokes. It is impossible to stop the rotation of the wheel by holding on to the end of the rod if a force is applied to the rim or to the spokes.

An interesting parallel to this simile is rotary optokinetic nystagmus. Kestenbaum⁶⁴ believed that there was no evidence for a prevalence of the retinal periphery over the retinal center in eliciting optokinetic nystagmus, except for its rotary form. Rotary optokinetic nystagmus is primarily, if not exclusively, produced by stimulation of the retinal periphery. Winkelman¹³⁸ studied the influence of parameters of the stimulus on effectiveness of the peripheral fusional targets in breaking central fusion. He found that location, size, and brightness of the target affected the required exposure time, but could demonstrate no absolute minimal time of exposure that would produce peripheral fusion. He also noted that the effect was strongest when the target was brightest, the area large, and the distance from the fovea small.

Since Burian's¹⁸ initial study of the role of peripheral stimuli for motor fusion, this concept has become generally accepted. The term *peripheral fusion* is now used universally but very little additional experimental work (see Lyle and Foley⁷⁶ and Nauheim⁸⁸) has been done on the subject.

CONVERGENCE. It has been pointed out repeatedly that among the vergences only convergence

may be voluntary. As a rule, no other vergence movements can be initiated or stopped voluntarily. The reflex moiety of convergence is complex, since it is a response to a variety of stimuli. Convergence is an essential part of the near vision complex and is discussed in detail in Chapter 5.

DIVERGENCE. The nature of divergence has been much discussed in the past, and its very existence as a separate function has been questioned. The concept proposed and held by many authors was that divergence movements are not an active function but simply the return of the globes to a more parallel position by elastic forces when convergence impulses were relaxed (e.g., see Scobee and Green¹²⁰).

The ability of the eyes to diverge their axes beyond parallelism in distance fixation and the existence of clinical entities such as divergence paralysis speak clearly in favor of an active divergence process controlled by separate central nervous system arrangements. These matters are discussed further in Chapters 5 and 22.

VERTICAL VERGENCES AND CYCLOFUSIONAL MOVEMENTS. Vertical vergences and cyclofusional movements (sursum- and deorsumvergence and cyclovergence) may be induced artificially with haploscopic devices²⁵ or by optically induced cyclodisparity.¹⁰² Under casual conditions of seeing they exist only as compensatory adjustments of muscle tonus to correct the relative position of the eyes in the presence of a hyperphoria or cyclotropia (see Chapter 18). Nothing is known about the central representation of these movements, but since they are active movements, some central nervous system arrangements are required to ensure proper impulse distribution to the extraocular muscles.

Enright³⁷ reported that disparity-induced vergence movements are associated with cycloverversions. A vertical vergence movement induced by vertical prisms (1.5° to 3.0°) was accompanied by a cycloverversion with the downward moving eye incycloducting and the upward moving eye excycloducting. Enright concluded from this observation that the oblique muscles must be largely responsible for vertical vergence movements. Other investigators have confirmed these findings and drawn similar conclusions.^{21, 47, 104}

We do not doubt that vertical vergences are accompanied by a cycloverversion, that is, excyclo-duction of the elevating and incyclo-duction of the depressing eye, and that such torsional movements

of the globe can only be produced by contraction of the superior, and inferior oblique muscles. However, we find it difficult to envision these muscles as the principal motors of vertical vergence movements. Excycloduction of the elevating and incycloduction of the depressing eye can also be explained by a more powerful torsional action of the oblique muscles that overrides the less powerful torsional effect of the vertical rectus muscles in the opposite direction (incycloduction of the elevating and excycloduction of the depressing eye) while both cyclovertical muscle pairs contract in unison in elevating and depressing the eye.⁸⁹ Moreover, since the vertical effect of oblique muscle contraction in adduction is practically negligible, a vertical vergence mechanism based exclusively on oblique muscle contraction, as envisioned by Enright³⁷ and others,^{21, 47, 104} would function only in primary position and not be of much use in lateral gaze. This controversial issue is further discussed in Chapter 18 in connection with dissociated vertical deviations.

Kertesz and Jones⁶³ initially questioned the presence of cyclovergences (see also Krekling⁶⁷), arguing that cyclofusion is a purely sensory process without a motor component. Crone and Everhard-Halm,²⁷ however, could show convincingly that subjective and objective measurements were in exact agreement and that motor cyclofusion does occur when the proper stimuli are used. More recent publications by Sullivan and Kertesz¹²⁵ agree with this point.

There has been discussion about whether cyclovergence occurs not only under experimental conditions but also in casual seeing, for instance, to permit fusion in the presence of cyclophoria. Such cyclofusional movements have been demonstrated in patients with superior oblique paresis^{55, 66} and by cyclovergence movements induced by the appearance and disappearance of a background pattern.⁶⁸ However, these movements are slow, of low amplitude, and their significance in compensating for a manifest cyclodeviation is not clear. These findings do not invalidate the concept that cyclofusion occurs predominantly on a sensory basis.⁹¹

Characteristics of Version and Vergence Movements

OPTOKINETIC AND OPTOSTATIC MECHANISMS. The two general functions of the oculorotary system (see Chapter 1) may be defined as

optokinetic and *optostatic*. The optokinetic function requires that the eyes perform certain motions with the greatest possible speed and accuracy, which is accomplished by version movements. Virtually all of them result from quick, tetanic contractions of the extraocular muscles. The optostatic function, which regulates the position of the eyes relative to each other and to the coordinates of space, is subserved by the vergence movements (and the cycloversions on tilting the head to one shoulder), which are produced by slow, tonic changes in the state of the muscles.

The remarkable thing about the oculorotary system is that these two contradictory functions are performed by the same muscles more or less at the same time. The histologic and physiologic arrangements that make this dual function possible are fascinating (see Chapter 6). That they are performed at the same time is evident from the clinical fact that versions are superimposed on the compensatory innervations (vergence impulses) required to maintain the proper alignment of the eyes. A person with heterophoria or even with intermittent heterotropia (see Chapter 8) apparently performs versions just as a person without a significant latent deviation of the lines of sight. The simultaneity of version and vergence impulses and the muscular response to these impulses is clearly seen in asymmetrical convergence. Rashbass and Westheimer⁹⁹ have made a special point of the independence of the two types of movement.

TEMPORAL CHARACTERISTICS OF VERSIONS (SACCADES) AND VERGENCES. Versions and vergences share certain temporal characteristics: their latencies are about 120 to 200 ms, and in general their speed is a function of the amplitude of the movement; the greater the amplitude, the greater the speed. The similarity ends there.

VERSIONS ARE EXTRAORDINARILY FAST MOVEMENTS. Their angular velocity has been measured by numerous investigators^{13, 17, 33, 44, 45, 56, 67, 105, 127} and ranges from 30° to 700°/s with a latency of 200 ms.²⁸ Here it will suffice to give the figures of Hyde⁵⁸ for saccades of 15° to 90°, reproduced in Figure 4–19. The curves in Figure 4–19 also show that the eyes accelerated sharply early in the movement, reached a maximum velocity, and then decelerated gradually. For example, for a 60° saccade, 49 ms was spent in reaching the peak velocity and 93 ms was used in completing the movement. The time required to reach the

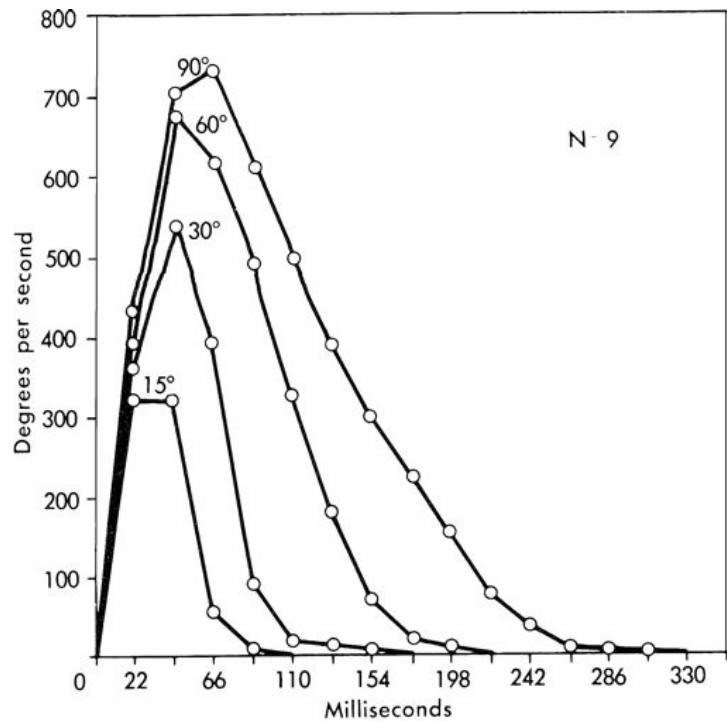


FIGURE 4-19. Time course of 15° to 90° saccades. (From Hyde JE: Some characteristics of voluntary ocular movements in the horizontal plane. *Am J Ophthalmol* 48:85, 1959.)

peak velocity was relatively independent of the amplitude of the saccade, whereas the time spent in deceleration was linearly related to it (Fig. 4-20). The impression is gained that the movements are performed in such a manner as to mini-

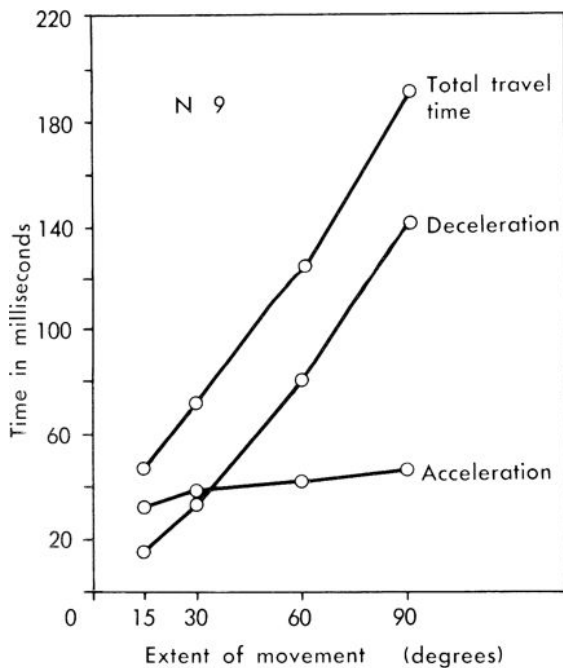


FIGURE 4-20. Relationship between total travel time, acceleration, deceleration, and the extent of the movement of a saccade. (From Hyde JE: Some characteristics of voluntary ocular movements in the horizontal plane. *Am J Ophthalmol* 48:85, 1959.)

mize an overshoot. In contrast to Hyde, Westheimer¹³⁵ found the peak velocity to be reached almost halfway through the movement so that acceleration and deceleration were essentially symmetrical. The diagnostic significance of increased saccadic latency is mentioned in Chapter 20.

Deceleration of the eye to zero velocity at completion of a saccade is associated with momentary activation of antagonistic muscles.¹²⁴ Saccades normally fall short of a target, and correction of the eye position occurs with a secondary corrective saccade. The purpose of this strategy is not entirely clear. Postsaccadic drifts can be observed in patients with internuclear ophthalmoplegia and myasthenia gravis.¹⁰⁹

VERGENCES ARE MUCH SLOWER MOVEMENTS THAN VERSIONS.

For lateral fusional movements of 5.5° their maximum velocity is given as 21.43°/s by Westheimer and Mitchell.¹³⁷ Alpern and Ellen⁴ found the maximum velocity for an accommodative vergence movement (see Chapter 5) of 6.6° to be 20.2°/s. Accordingly, the duration of the movement is also much longer. The total travel time for a 15° saccade is less than 50 ms (see Fig. 4-19) and thus 10 times less than a vergence movement of only 1.5° (Fig. 4-21), which takes 325 ms (500 ms minus the latency of 160 ms) to execute. That the vergences are very

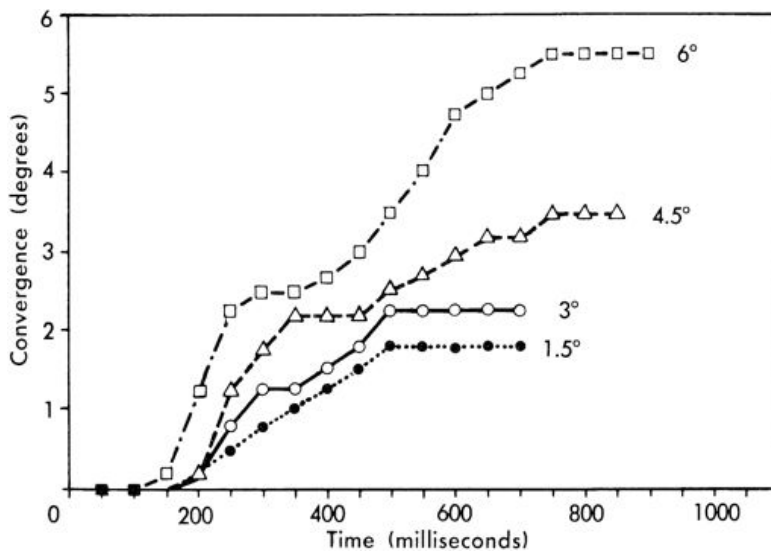


FIGURE 4-21. Duration of convergence movements for various degrees of convergence (From Westheimer G, Mitchell AM: Eye movement responses to convergence stimuli. *Arch Ophthalmol* 55: 848, 1956.)

slow movements compared with the versions has long been known. Dodge³² gave 40 ms for saccades but 400 to 1000 ms for vergences. Brecher¹⁴ stated that fusional movements are completed in 1 to 2 seconds.

In addition to these fundamental differences between versions and vergences there are dissimilarities between convergence and divergence. Time to peak velocity was twice as high and all temporally related components, including latency, were shorter for convergence than for divergence.⁵⁷ This suggests differences in neural processing for convergence and divergence.

AFTEREFFECTS OF VERGENCE IMPULSES. The differences in the temporal characteristics of version and vergence movements clearly establish the difference in the nature of these two types of eye movements. While the fusional vergence response to retinal disparity is slower than a version movement, it is considerably faster than yet another type of fusional vergence impulse that may persist for hours or even days. This type of fusional vergence is not disrupted by covering one eye momentarily. Thus, one may distinguish between a *fast and slow fusional vergence system*.^{25, 118} The slow vergence system is of considerable importance in the clinical determination of the relative position of the eyes and of the amplitudes of the vergences. Whenever a vergence impulse is sent out, it takes an appreciable length of time for its effect to become established. The effect of the impulse does not cease immediately after the stimulus has been removed but persists longer, depending on the intensity and duration of the preceding vergence impulse. This was already known

to Panum,⁹⁶ who stated that the simple maintenance of convergence caused a shift of the fusion-free (heterophoric) position toward esophoria. The aftereffect of induced vergences has been noted by all subsequent investigators concerned with fusional movements. Taylor and coworkers¹²⁸ demonstrated that this aftereffect is not limited to horizontal vergences but applies to cyclovergence as well.

It has also been observed that duration of the aftereffect can be shortened by a fusional movement in another direction. The aftereffect of fusional vergence determines the sequence of testing amplitudes of convergence and divergence (p. 202), may influence the result of the alternating cover test, and has led to the use of short-term unocular occlusion during examination of certain types of exotropias (Chapter 17).

The temporal characteristics of vergence movements impose certain precautions for measurement of fusional amplitudes and heterophorias. The rate of change in disparity must be sufficiently slow to allow fusional movements to occur. If the rate is too fast, the fusional amplitude will be small. The effect of different rates of changes in disparity has been demonstrated quantitatively by Ellerbrock.³⁶ *Vergences of opposite sign should not be measured in sequence* (e.g., divergence after convergence). *Heterophoria measurements should not follow immediately after vergence measurements*.² These and other practical matters are discussed in Chapter 12. It is probable that the so-called eating-up of prisms during the prism adaptation test is caused by the slow vergence system (see Chapter 25).

Fixation and the Field of Fixation

Fixation

The term *fixation* is used to indicate the seemingly steady maintenance of the image of the object of attention on the fovea. If one eye alone fixates, one speaks of *uniocular (monocular) fixation*; if both eyes simultaneously fixate an object point, fixation is *binocular* or *bifoveal*. The term “bifixation” is used by Parks⁹⁷ and his school as opposed to “monofixation” to connote normal vs. deficient foveal functioning under binocular conditions. We find this terminology confusing and do not advocate it since fixation may remain bifoveal despite organic or reversible loss of function of one fovea (suppression; see Chapter 13) under binocular conditions. Moreover, it could also erroneously imply alternation of fixation.

During fixation, afferent sensory input from the retina is used to elicit appropriate efferent signals to the extraocular muscles to maintain eye position. Thus fixation is a well-integrated sensorimotor process that is essentially immature at birth and is acquired in the first 6 months of life, paralleling the anatomical maturation of the central fovea.

According to Kestenbaum,⁶⁵ the following conditions must be present for fixation to occur: (1) good foveal function; (2) the object to be fixated must have distinct contours (a homogeneous area does not elicit a fixation reflex); and (3) the object to be fixated must have attention value. To this we add a fourth condition: the sense of directness of vision associated with foveal but not with peripheral retinal stimulation.⁸⁹

The steadiness of the eye in fixating an object is only apparent. “Steady” fixation is the result of a complex motor act to which several minute involuntary movements contribute and is comparable to the hardly perceptible motions of a soldier standing strictly at attention.

The existence of involuntary movements during fixation was noted very early by Jurin,⁶¹ and Helmholtz,⁵⁰ but their quantitative evaluation had to await development of adequate experimental methods, consisting either of photographic recordings of a beam of light reflected from a mirror attached to the eye,^{1, 80, 95, 100} of direct photography,⁴⁸ or of photoelectric methods.⁷⁵

EYE MOVEMENTS DURING FIXATION. Because of their small magnitude, eye movements during

fixation are also referred to as *micro* or *miniature eye movements*. Carpenter¹⁹ distinguished between tremor, drift, and microsaccades. *Tremor* is present when the amplitude of fixation tremor is on the order of the diameter of the smallest cone. Estimates range from 5 to 50 seconds.^{31, 100, 140} Binocular recordings of the tremor indicate that it is uncorrelated (disjunctive) between the two eyes. *Drift*, compared to tremor, is larger and slower. Amplitudes are 2 to 5 minutes and, as in tremor, the direction of drifts is apparently uncorrelated between the two eyes.¹⁰¹ Whether drifts are related to the position of the target in relation to the fovea is a matter of dispute. *Microsaccades* range in amplitude from 1 to 23 seconds, and it is possible they correct (like macrosaccades) for slippage of the visual target off the fovea. Indeed, similarities exist between velocity characteristics of microsaccades and macrosaccades.¹⁴² It is difficult to judge from available data to what extent miniature eye movements owe their characteristics to experimental artifacts. It is also difficult to judge what their role is, if any, during fixation and with regard to the visual acuity function. We return to this issue in Chapter 7.

Field of Fixation

The *field of vision* delineates the area within which, for a given fixation distance, form, brightness, or color may be perceived without moving the eye or the head. The *field of fixation* is the area within which central fixation is possible by moving the eye but not the head. The *practical field of fixation* is the field of fixation achieved by moving both the eyes and the head, as in casual seeing.

MONOCULAR AND BINOCULAR FIELD OF FIXATION. The monocular field of fixation is best determined by imprinting an afterimage on the fovea and having the observer follow an object on a perimeter arm or, in distance vision, by having the observer follow an object moved behind a pane of glass. When the subject is no longer able to make the object and the afterimage coincide, the limit of the field of fixation is reached. These limits depend on the configuration of structures surrounding the eyes and on the refraction of the globe. Individual differences are large, and the data given vary considerably. However, there is agreement in the older literature that the field of fixation is largest in gaze downward (54°), fol-

TABLE 4-4. Monocular and Binocular Field of Fixation

	Monocular Field of Fixation		Binocular Field of Fixation	
	Left Eye	Right Eye	Left Eye	Right Eye
Elevation	41°	42°	28°	28°
Depression	45°	45°	45°	45°
Abduction	39°	45°	20°	21°
Adduction	48°	44°	35°	34°

Modified from Asher W: Monokulares und binokulares Blickfeld eines Myopischen. Graefes Arch Clin Exp Ophthalmol 47:318, 1899.

lowed by the limits for inward (46°), outward (42°), and upward (34°) gaze. The figures in parentheses are the means of all the determinations by various authors listed by Hofmann.⁵⁶ The limits of the binocular field of fixation are more restricted than those of the monocular field. The data obtained by Asher,⁵ who was a myope, for his monocular and binocular fields are given in Table 4-4 and are reproduced in Figure 4-22. Yamashiro¹³⁹ studied the limits of ocular excursions in a large number of normal eyes (200 eyes of 100 normal Japanese subjects). He found large individual differences. The rank order for the mean values of the different versions was adduction → abduction → depression → elevation. Yamashiro also noted an interesting age dependence of the maximum values, with a significant decrease starting at the sixth decade (Table 4-5). There was no sex difference, nor did the values for the dominant eye differ significantly from those for the nondominant eye. The binocular field of fixation is of special importance to the clinician concerned with neuromuscular anomalies of the eyes. In clinical practice it is often determined with a perimeter^{39, 76} (see Chapter 12).

THE PRACTICAL FIELD OF FIXATION. The field of fixation, as well as the field of vision, is consid-

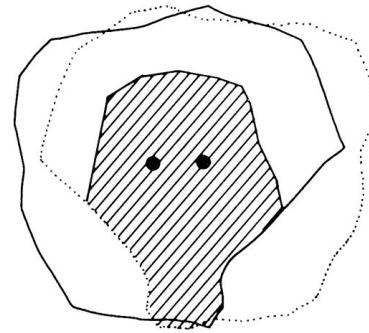


FIGURE 4-22. Monocular and binocular fields of fixation. Dotted line, limit of monocular field of right eye. Solid line, limit of monocular field of left eye. Barred area, binocular field of fixation. (Modified from Asher W: Monokulares und binokulares Blickfeld eines Myopischen. Graefes Arch Clin Exp Ophthalmol 47:318, 1899.)

erably enlarged if, in addition to eye movements, head movements are permitted. The field of fixation thus determined has been termed the *practical field of fixation* by von Rötth.¹¹⁷ Normally, the full extent of the field of fixation permitted by eye movements is not used. In fact, the eyes make very small rotations; the rest of the required movement is supplied by head movements. A stiff neck makes one painfully aware of the limitation of the field of fixation, and the constant, extensive turning of the head to either side by the spectators at a tennis match is often amusing to those watching telecasts of a match.

Ritzmann¹⁰⁷ long ago noted that head movements occur even with very small movements of the eyes and are subject to considerable individual variations, being greater the larger the excursion and differing in amount in the various directions of gaze. He found that in elevation only about one third of the excursion was done by the eyes, whereas in depression head movements hardly participated in the movements.

In an extensive study on 600 subjects, Fischer⁴³ showed that *head movements account for most of the field of fixation in the horizontal direction.* He

TABLE 4-5. Maximal Limits of Field of Fixation and Age

Age (yr)	Right Eye				Left Eye			
	Adduction	Abduction	Depression	Elevation	Adduction	Abduction	Depression	Elevation
10-19 (n = 24)	58°	54°	51°	44°	60°	53°	51°	43°
20-29 (n = 33)	57°	54°	51°	42°	59°	52°	50°	41°
30-39 (n = 13)	57°	52°	49°	42°	59°	52°	49°	41°
40-49 (n = 17)	57°	53°	49°	41°	58°	52°	49°	41°
50+ (n = 13)	54°	52°	46°	39°	55°	43°	43°	39°

Modified from Yamashiro M: Objective measurement of the monocular and binocular movements. Jpn J Ophthalmol 1:130, 1957.

also found marked individual differences, but on average the ocular rotations did not exceed 6° to 8° to either side; the maximum he found was 12° . This applied both to distance fixation and to close work. In reading, the amount of head movement depended on the material read, whether reading was done silently or aloud, and on the experience (age) of the reader. The more difficult the material, the more head movements were used. This was also true for reading out loud. Comparing age groups, Fischer found maximum eye movements to be 6° in 11-year-old children and 10° in 20-year-old persons.

According to Fischer⁴³ and others, eye movements, in general, precede head movements. He, as well as von Rötth,¹¹⁷ explained head movements in the horizontal direction as reflex movements elicited by and aimed at the avoidance of asymmetrical convergence. Another significant observation made by Fischer was that aphakic patients or other high ametropes provided with spectacle corrections never made eye movements greater than 6° when reading. This was attributable to the optical properties of the correcting lenses (see Chapter 7). Nowadays aphakic glasses are being replaced by contact lenses or intraocular lenses. On the other hand, an increasing use is made of glasses with progressive lenses. The optical zone of these lenses is quite limited. Patients who wear glasses with progressive (or even bifocal) lenses make eye movements that are even smaller than those of aphakic patients and do not exceed more than 2° to 3° (Campos, unpublished observation).

It is of clinical significance that in ordinary use the eyes make remarkably small rotations. Thus all considerations of the mechanical effects of extraocular muscles at 20° , 30° , or 40° from the straight-ahead position deal with specific nonphysiologic situations that have little meaning with respect to casual use of the eyes. It also points out that manifest strabismus in eye positions beyond 20° from the primary position will often not bother a patient. An important exception exists when the patient has special occupational visual needs. Diplopia in the periphery of the field of vision of, say, a construction worker, may present a handicap and occupational risk to the patient. This must be recognized when establishing the extent of a disability resulting from a decrease in the size of the field of binocular vision (see Chapter 4). Last, the relatively limited size of the practical fields of fixation means that it should be helpful to a patient with a paralysis of a muscle if its action could be

improved to where it would allow the eye to turn at least 12° to 15° toward the primary position.

REFERENCES

1. Adler FH, Fliegelman M: Influence of fixation on visual acuity. *Arch Ophthalmol* 12:475, 1934.
2. Alpern M: The aftereffect of lateral duction testing on subsequent phoria movements. *Am J Optom* 23:442, 1946.
3. Alpern M: Movements of the eyes. In Davson H, ed: *The Eye*, vol 3. New York, Academic Press, 1962.
4. Alpern M, Ellen P: A quantitative analysis of the horizontal movement of the eyes in the experiment of Johannes Mueller. I. Method and results. *Am J Ophthalmol* 42 (4, pt 2):289, 1956.
5. Asher W: Monokulares und binokulares Blickfeld eines Myopischen. *Graefes Arch Clin Exp Ophthalmol* 47:318, 1899.
6. Aulhorn E: Phasendifferenz-Haploskopie. Eine neue Methode zur Trennung der optischen Eindrücke beider Augen. *Klin Monatsbl Augenheilkd* 148:540, 1966.
7. Balliet R, Nakayama K: Training of voluntary torsion. *Invest Ophthalmol Vis Sci* 71:303, 1978.
8. Bárány R: Quoted in Hofmann FB: Die Lehre vom Raumsinn. In Axenfeld T, Elschmig A, eds: *Graefe-Saemisch's Handbuch der gesamten Augenheilkunde*, ed 2, vol 3. Berlin, Springer-Verlag, 1925.
9. Blodi FC, Van Allen MW: Electromyography of the extraocular muscles in fusional movements. *Am J Ophthalmol* 44 (4, pt 2):136, 1957.
10. Boeder P: An analysis of the general type of ocular rotations. *Arch Ophthalmol* 57:200, 1957.
11. Boeder P: The cooperation of the extraocular muscles. *Am J Ophthalmol* 51:469, 1961.
12. Boeder P: Cooperative action of extraocular muscle. *Br J Ophthalmol* 46:397, 1962.
13. Boghen D, Troost BT, Daroff RB, et al: Velocity characteristics of normal human saccades. *Invest Ophthalmol* 13:619, 1974.
14. Brecher GA: Quantitative studies of binocular fusion. *Am J Ophthalmol* 38 (1, pt 2):134, 1954.
15. Breinin GM: The nature of vergence revealed by electromyography. *Arch Ophthalmol* 54:407, 1955.
16. Breinin GM: The structure and function of the extraocular muscle. An appraisal of the duality concept. The Gifford Memorial Lecture. *Am J Ophthalmol* 72:1, 1971.
17. Brückner A: Über die Anfangsgeschwindigkeit der Augenbewegungen. *Pflügers Arch* 90:73, 1902.
18. Burian HM: Fusional movements. Role of peripheral fusion stimuli. *Arch Ophthalmol* 21:485, 1939.
19. Carpenter RH: *Movement of the Eyes*. London, Pion, 1977, p 97.
20. Chamberlain WP Jr: Ocular motility in the horizontal plane: An experimental study of the primary and secondary horizontal rotators in the rhesus monkey. *Trans Am Ophthalmol Soc* 52:751, 1954.
21. Cheeseman EW, Guyton DL: Vertical fusional vergence. The key to dissociated vertical deviation. *Arch Ophthalmol* 117:1188, 1999.
22. Ciuffreda KJ, Stark L: Descartes' law of reciprocal innervation. *Am J Physiol Opt* 52:663, 1975.
23. Clark RA, Isenberg SJ, Rosenbaum AL, et al: Posterior fixation sutures: A revised mechanical explanation for the fadenoperation based on rectus extraocular muscle pulleys. *Am J Ophthalmol* 128:702, 1999.
24. Clement RA: Computer simulation of extraocular muscle cooperation: An evaluation. *Ophthalmol Physiol Opt* 2:107, 1982.

25. Cooper J: Clinical implications of vergence adaptation. *Optom Vis Sci* 69:300, 1992.
26. Crawford JD, Vilis T: Axis of eye rotation and Listing's law during rotation of the head. *J Neurophysiol* 65:407, 1991.
27. Crone RA, Everhard-Halm Y: Optically induced eye torsion. I. Fusional cyclovergence. *Graefes Arch Clin Exp Ophthalmol* 195:231, 1975.
28. Dell'Osso LF, Daroff RB: Eye movement characteristics and recording techniques. In Duane T, ed: *Clinical Ophthalmology*, vol 2. Hagerstown, MD, Harper & Row, 1978, p 1.
29. Demer JL, Miller JL, Poukens V, et al: Evidence for fibromuscular pulleys of the recti muscles. *Invest Ophthalmol Vis Sci* 36:1125, 1995.
30. Descartes R: *Treatise of Man*. French text with translation and commentary by Hall TS. Cambridge, Harvard University Press, 1972, pp 23–29.
31. Ditchburn RW: Eye movements in relation to retinal action. *Opt Acta (Lond)* 1:171, 1955.
32. Dodge R: Five types of eye movements in the horizontal meridian plane of the field of regard. *Am J Physiol* 8:307, 1903.
33. Dodge R, Cline TS: The angle velocity of eye movements. *Psychol Rev* 8:145, 1901.
34. Donders FC: Beitrag zur Lehre von den Bewegungen des menschlichen Auges. *Holland Beitr Anat Physiol Wiss* 1:104, 384, 1848.
35. Duke-Elder S: *Text-book of Ophthalmology*, vol 1. St Louis, Mosby-Year Book, 1932/1996, p 599.
36. Ellerbrock V: Experimental investigation of vertical fusional movements. *Am J Optom* 26:337, 1949.
37. Enright JT: Unexpected role of the oblique muscles in the human vertical fusional reflex. *J Physiol* 451:279, 1992.
38. Enright JT: Slow-velocity asymmetrical convergence: A decisive failure of "Hering's law." *Vision Res* 36:3667, 1996.
39. Feibel RM, Roper-Hall G: Evaluation of the field of binocular single vision in incomitant strabismus. *Am J Ophthalmol* 78:800, 1974.
40. Ferman L, Collewijn H, Berg AV van den: A direct test of Listing's law—I: Human ocular torsion measured in static tertiary position. *Vision Res* 27:929, 1987.
41. Ferman L, Collewijn H, Berg AV van den: A direct test of Listing's law—II: Human ocular torsion measured under dynamic conditions. *Vision Res* 27:939, 1987.
42. Fick A: Neue Versuche über die Augenstellung. *Mole-schotts Untersuchungen* 5:193, 1858.
43. Fischer FP: Über die Verwendung von Kopfbewegungen beim Umhersehen. I und II. Mitteilung. *Graefes Arch Clin Exp Ophthalmol* 115:49, 1925.
44. Gordon OE: A study of primary and auxiliary ocular rotations. *Trans Am Acad Ophthalmol Otolaryngol* 58:553, 1954.
45. Guillery H: Über die Schnelligkeit der Augenbewegungen. *Pflügers Arch* 73:87, 1898.
46. Guyton D: Ocular torsion: Sensorimotor principles. *Graefes Arch Clin Exp Ophthalmol* 226:241, 1988.
47. Guyton DL, Cheeseman EW Jr, Ellis FJ, et al: Dissociated vertical deviation: An exaggerated normal eye movement used to damp cyclovertical latent nystagmus. *Trans Am Ophthalmol Soc* 96:389, 1998.
48. Harbridge H, Thomson C: Methods of investigating eye movements. *Br J Ophthalmol* 32:581, 1948.
49. Helmholtz H von: *Handbuch der physiologischen Optik*. Hamburg, ed 3, vol 3. L Voss, 1910, p 47. Cited in Boeder P: The cooperation of the extraocular muscles. *Am J Ophthalmol* 51:469, 1961.
50. Helmholtz H von: In Southall JPC, ed: *Helmholtz's Treatise on Physiological Optics*. Translation from the 3rd German edition, Ithaca, NY, Optical Society of America, 1924. Quoted from reprint, New York, 1962, Dover Publications, vol 3. 1962, p 44.
51. Hering E: *Die Lehre vom binocularen Sehen*. Leipzig, Wilhelm Engelmann, 1868.
52. Hering E: Über die Rollung des Auges um die Gesichtslinie. *Graefes Arch Clin Exp Ophthalmol* 15(4):1, 1869.
53. Hering E: Der Raumsinn and die Bewegungen der Augen. In Hermann L, ed: *Handbuch der Physiologie*, vol 3. Leipzig, FCW Vogel, 1879, p 343.
54. Hering E: Über Muskelgeräusche des Auges. *Sitzungsbericht Wien Akad Wiss* 79 (pt 3):173, 1879.
55. Herzau V, Joos-Kratsch E: Objective and subjective evaluation of cyclovergence and cyclofusion. *Doc Ophthalmol* 58:85, 1984.
56. Hofmann FB: Die Lehre vom Raumsinn. In Axenfeld, Th, Elschnig A, eds: *Graefe-Saemisch's Handbuch der gesamten Augenheilkunde*, ed 2, vol 3. Berlin, Springer-Verlag, 1925.
57. Hung GK, Zhu H, Ciuffreda KJ: Convergence and divergence exhibit different response characteristics to symmetric stimuli. *Vision Res* 37:1197, 1997.
58. Hyde JE: Some characteristics of voluntary ocular movements in the horizontal plane. *Am J Ophthalmol* 48:85, 1959.
59. Jampel RS: The fundamental principle of the action of the oblique muscle. *Am J Ophthalmol* 69:623, 1970.
60. Javal E: *Manuel théorique et pratique du strabisme*. Paris, Masson, 1896.
61. Jurin J: *Essay on distinct and indistinct vision*. In Smith's *Optics*. Cambridge, Cambridge University Press, 1738.
62. Kapoula Z, Bernotas M, Haslwanter T: Listing's plane rotation with convergence: Role of disparity, accommodation and depth perception. *Exp Brain Res* 126:175, 1999.
63. Kertesz AE, Jones RW: Human cyclofusional response. *Vision Res* 10:891, 1970.
64. Kestenbaum A: Zum Mechanismus der Fixation (eine experimentelle Studie). *Z Augenheilkd* 57:557, 1925.
65. Kestenbaum A: *Clinical Methods of Neuroophthalmologic Examination*. New York, Grune & Stratton, 1961.
66. Kolling G: Möglichkeiten und Grenzen der Messung von Zyklodeviation unter besonderer Berücksichtigung des Deviometers nach Cüppers. *Klin Monatsbl Augenheilkd* 178:89, 1981.
67. Krekling S: Comments on cyclofusional eye movements. *Graefes Arch Clin Exp Ophthalmol* 188:231, 1973.
68. Lamansky S: Bestimmung der Winkelgeschwindigkeit der Blickbewegung respektive Augenbewegung. *Pflügers Arch* 2:418, 1869.
69. Lancaster WB: Detecting, measuring, plotting and interpreting ocular deviations. *Trans Section Ophthalmol AMA* 1939.
70. Lancaster WB: Terminology in ocular motility and allied subjects. *Am J Ophthalmol* 26:122, 1943.
71. Leinfelder PJ, Black NM Jr: Experimental transposition of extraocular muscles in monkeys. *Am J Ophthalmol* 24:1115, 1941.
72. Leinfelder PJ, Black NM Jr: Experimental transposition of extraocular muscles in monkeys. Role of superior oblique. *Am J Ophthalmol* 25:974, 1942.
73. Listing JB: Cited in Ruete CG Th: *Lehrbuch der Ophthalmologie für Aerzte and Studierende*, ed 2, vol 1. Braunschweig, Germany, Friedrich Vieweg & Sohn, 1855, 37 ff.
74. Locke JC: Heterotropia of the blind spot in ocular vertical muscle imbalance. *Trans Am Ophthalmol Soc* 65:306, 1967.
75. Lord MP, Wright WD: Eye movements during monocular fixation. *Nature* 162:25, 1948.

76. Lyle TK, Foley J: Subnormal binocular vision with special reference to peripheral vision. *Br J Ophthalmol* 39:474, 1955.
77. Marina A: Die Theorie über den Mechanismus der assoziierten Konvergenz – und Seitenbewegungen studiert auf Grundlage der experimentellen Forschungsergebnisse mittels Augenmuskeltransplantationen an Affen. *Dtsch Z Nervenheilkd* 44:138, 1912.
78. Marina A: Die Relationen des Palaencephalons sind nicht fix. *Neurol Centralbl* 34:338, 1915.
79. Marina A, Cofler A: Über die Kontraktion des Sphinkter iridis bei der Konvergenz und Seitenbewegungen der Bulbi *Dtsch Z. Nervenheilkd* 24:274, 1903.
80. Marx E, Trendelenburg W: Über die Genauigkeit der Einstellung des Auges beim Fixieren. *Z Sinnesphysiol* 45:87, 1911.
81. Meissner G: Über die Bewegungen des Auges, nach neuen Versuchen. *Z Rationelle Med Ser 3* 8:1, 1860.
82. Miller J: Functional anatomy of normal human rectus muscle. *Vision Res* 29:223, 1989.
83. Mok D, Ro A, Cadera JD, et al: Rotation of Listing's plane during vergence. *Vision Res* 32:2055, 1992.
84. Minken AWH, Gisbergen van JAM: Three-dimensional analysis of vergence movements at various levels of elevation. *Exp Brain Res* 101:331, 1994.
85. Moses RA: Torsion of the eye on oblique gaze. *Arch Ophthalmol* 44:136, 1950.
86. Mulder: Über parallele Rollbewegungen der Augen. *Graefes Arch Clin Exp Ophthalmol* 21:68, 1875.
87. Nakayama K: Kinematics of normal and strabismic eyes. In Schor CM, Ciuffreda K, eds: *Vergence Eye Movements: Basic and Clinical Aspects*. Boston, Butterworth, 1983, p 543.
88. Nauheim JS: A preliminary investigation of retinal locus as a factor in fusion. *Arch Ophthalmol* 58:122, 1957.
89. Noorden GK von: The etiology and pathogenesis of fixation anomalies in strabismus. *Trans Am Ophthalmol Soc* 67:698, 1969.
90. Noorden GK von: *Atlas of Strabismus*, ed 4. St Louis, Mosby-Year Book, 1983.
91. Noorden GK von: Clinical and theoretical aspects of cyclotropia. *J Pediatr Ophthalmol Strabismus* 21:126, 1984.
92. Noorden GK von: In discussion of Guyton DL, Cheeseman EW Jr, Ellis FJ, et al: Dissociated vertical deviation: An exaggerated normal eye movement used to damp cyclovertical latent nystagmus. *Trans Am Ophthalmol Soc* 96:389, 1998.
93. Noorden GK von, Mackensen G: Pursuit movements of normal and amblyopic eyes: An electroophthalmographic study. I. Physiology of pursuit movements. *Am J Ophthalmol* 53:325, 1962.
94. Olmsted JMD, Margutti M, Yanagisawa K: Adaptation to transposition of eye muscles. *Am J Physiol* 116:245, 1936.
95. Orchansky J: Eine Methode die Augenbewegungen direkt zu untersuchen (Ophthalmographie). *Zentralbl Physiol* 12:785, 1898.
96. Panum PL: *Physiologische Untersuchungen über das Sehen mit zwei Augen*. Kiel, Schwesche Buchhandlung, 1858, p 18.
97. Parks MM: *Ocular Motility and Strabismus*. Hagerstown, MD, Harper & Row, 1975, p 82.
98. Payne JW, Noorden GK von: The ratio of accommodative convergence to accommodation in strabismus with A and V patterns. *Arch Ophthalmol* 77:26, 1967.
99. Rashbass C, Westheimer G: Independence of conjugate and disjunctive eye movements. *J Physiol (Lond)* 159:361, 1961.
100. Ratliff F, Riggs LA: Involuntary motions of the eye during monocular fixation. *J Exp Psychol* 46:687, 1950.
101. Riggs LA, Ratcliff F: Visual acuity and the normal tremor of the eyes. *Science* 114:17, 1951.
102. Rijn LJ van: *Torsional Eye Movements in Humans*. Doctoral dissertation, University of Rotterdam, 1994.
103. Rijn LJ van, Berg AV van den: Binocular eye orientation during fixation: Listing's law extended to include eye vergence. *Vision Res* 33:691, 1993.
104. Rijn LJ van, Collewijn H: Eye torsion associated with disparity-induced vertical vergence in humans. *Vision Res* 34:2307, 1994.
105. Rijn LJ van, Steen J van der, Collewijn H: Visually induced cyclovergence and cyclovergence. *Vision Res* 32:1875, 1992.
106. Rijn LJ van, Steen J van der, Collewijn H: Instability of ocular torsion during fixation: Cyclovergence is more stable than cyclovergence. *Vision Res* 34:1077, 1994.
107. Ritzmann E: Über die Verwendung von Kopfbewegungen bei den gewöhnlichen Blickbewegungen. *Graefes Arch Clin Exp Ophthalmol* 21:131, 1875.
108. Robinson D: A method measuring eye movement using a scleral search coil in a magnetic field. *IEEE Trans Biomed Eng* 10:137, 1963.
109. Robinson D: The functional behavior of the peripheral oculomotor apparatus: A review. In Kommerell G, ed: *Disorders of Ocular Motility*. Munich, JF Bergmann, 1978, p 43.
110. Robinson D: Control of eye movements. In Brooks VB, ed: *Handbook of Physiology*, vol 2, pt 2, The Nervous System. Baltimore, Williams & Wilkins, 1981, p 1275.
111. Robinson DA: The mechanics of human saccadic eye movements. *J Physiol (Lond)* 174:245, 1964.
112. Robinson DA: The mechanics of human smooth pursuit eye movement. *J Physiol (Lond)* 180:569, 1965.
113. Robinson DA: The mechanics of human vergence movement. *J Pediatr Ophthalmol* 3:31, 1966.
114. Robinson DA: Eye movement control in primates. *Science* 161:1219, 1968.
115. Robinson DA: A quantitative analysis of extraocular muscle cooperation and squint. *Invest Ophthalmol* 14:801, 1975.
116. Robinson DA, O'Meara DM, Scott AB, et al: Mechanical components of human eye movements. *J Appl Physiol* 26:548, 1969.
117. Rötth A von: Über das praktische Blickfeld. *Graefes Arch Clin Exp Ophthalmol* 115:314, 1925.
118. Schor CM: The relationship between fusional vergence eye movements and fixation disparity. *Vision Res* 19:1359, 1992.
119. Schuster ME (1920), cited by Bielschowsky A: *Die Lähmungen der Augemuskeln*. Springer-Verlag, Berlin, 1932, p 315.
120. Scobee RG, Green EL: A center for ocular divergence: Does it exist? *Am J Ophthalmol* 29:422, 1946.
121. Sherrington CS: Experimental note on two movements of the eyes. *J Physiol (Lond)* 17:27, 1894.
122. Sherrington CS: *The Integration of the Nervous System*. New York, Charles Scribner's Sons, 1906.
123. Simonsz HJ, Harting F, Waal BJ de, et al: Sideways displacement and curved path of recti eye muscles. *Arch Ophthalmol* 103:124, 1985.
124. Sindermann F, Geiselman B, Fischler M: Single motor unit activity in extraocular muscles in man during fixation and saccades. *Electroencephalogr Clin Neurophysiol* 45:64, 1978.
125. Sullivan MJ, Kertesz AE: Peripheral stimulation and human cyclofusional response. *Invest Ophthalmol Vis Sci* 18:1287, 1979.
126. Suzuki Y, Hepp K, Henn V: Listing's law during sleep. *Soc Neurosci Abstracts* 21:1198, 1995.
127. Tamler E, Jampolsky A, Marg E: An electromyographic

- study of asymmetric convergence. *Am J Ophthalmol* 46 (5, pt 2):174, 1958.
128. Taylor MJ, Roberts DC, Zee DS: Effect of sustained cyclovergence on eye alignment: Rapid torsional phoria adaptation. *Invest Ophthalmol Vis Sci* 41:1076, 2000.
 129. Tschermak-Seysenegg A von: Methodik des optischen Raumsinnes und der Augenbewegungen. In Abderhalden E, ed: *Handbuch der biologischen Arbeitsmethoden*, vol 5. Berlin, Urban & Schwarzenberg, 1937, p 1141.
 130. Tschermak-Seysenegg A von: *Introduction to Physiological Optics*. Translated by Boeder P. Springfield, IL, Charles C Thomas, 1952 p 234.
 131. Volkmann AW: Zur Mechanik der Augenmuskeln. *Ber Sächs Ges Wiss Math Naturwissenschaften Klasse* 21:28, 1869.
 132. Watrous WG, Olmsted JMD: Reflex studies after muscle transplantations. *Am J Physiol* 132:607, 1941.
 133. Webster's Ninth New Collegiate Dictionary. Springfield, MA, Merriam-Webster, 1983.
 134. Weiss JB: Ectopies et pseudoectopies maculaires par rotation. *Bull Mem Soc Fr Ophthalmol* 79:329, 1966.
 135. Westheimer G: Mechanism of saccadic movements. *Arch Ophthalmol* 52:710, 1954.
 136. Westheimer G, Blair SM: Mapping the visual sensory onto the visual motor system. *Invest Ophthalmol* 11:490, 1972.
 137. Westheimer G, Mitchell AM: Eye movement responses to convergence stimuli. *Arch Ophthalmol* 55:848, 1956.
 138. Winkelman JE: Peripheral fusion. *Arch Ophthalmol* 45:425, 1951.
 139. Yamashiro M: Objective measurement of the monocular and binocular movements. *Jpn J Ophthalmol* 1:130, 1957.
 140. Yarbus AL: *Movement of the Eyes and Vision*. New York, Plenum Press, 1967, p 103.
 141. Zoth O: Augenbewegungen und Gesichtswahrnehmungen. In Nagel W, ed: *Handbuch der Physiologie des Menschen*, vol 3. Braunschweig, Friedrich Vieweg & Sohn 1905, p 299.
 142. Zuber BL, Stark L: Microsaccades and the velocity-amplitude relationship for saccadic eye movements. *Science* 150:1459, 1965.

The Near Vision Complex

When an observer transfers binocular fixation from an object at one fixation distance to one at another fixation distance, changes in the refractive power of the eyes and in the relative position of the visual axes are required to maintain sharply defined retinal images and to preserve binocular fixation. Thus when an observer binocularly fixates an object situated in his or her median (sagittal) plane at a certain distance (say, 6 m) and when the object then approaches the observer's head, the eyes must increase their refractive power more and more to produce a continuously well-focused image of the approaching object on the retinas. At the same time, the angle formed between the visual axes must grow increasingly larger to allow the object's images to remain on the two foveae. The opposite process takes place when an object recedes from near fixation. Refraction and the position of the visual axes also change if the change in fixation distance is discontinuous, as in a jumplike change from one fixation distance to another.

The process by which the refractive power of the eyes is altered to ensure a clear retinal image is known as *accommodation*. The change in the relative position of the visual axes is called *convergence* when the angle formed by the visual axes increases and *divergence* when this angle decreases. In addition, with fixation at near vision, *pupillary constriction* occurs.

The association of accommodation, convergence, and pupillary constriction during fixation at near may be termed the *near vision complex*. This triad of events is not a true reflex but rather

a synkinesis, that is, an association of different functions elicited by nearness of the observed object. Each of these functions can be dissociated from one another.

Accommodation

A detailed discussion of the process of accommodation and the mechanisms that have been proposed is outside the scope of this book. Fundamentals will be discussed only to help the understanding and investigation of neuromuscular anomalies of the eyes.

Mechanism of Accommodation

There is no disagreement that a change in the shape of the lens—an increase or decrease in curvature and thickness of its central parts that produces an increase or decrease in the dioptic power of the eye—is the basic mechanism underlying accommodation. Nor is there any disagreement that this change in the shape of the lens is caused by a contraction of the ciliary muscle. Whether this contraction produces loosening of the zonular fibers²³ or tightening with forward pull on the choroid and increased intravitreal pressure, affecting the periphery of the lens,⁵³ or some other more complex effects, is not essential to this discussion. It is sufficient to know only that the change in shape of the lens, resulting from a contraction of the ciliary muscle, represents the peripheral mechanism of accommodation set in

motion by a central mechanism of accommodation, which in turn responds to a stimulus to accommodation.

The stimulus to accommodation is the blurred retinal image. The afferent pathway is represented by the visual pathway up to area 17 and continues to area 19. The ciliary muscle is innervated by cranial nerve III, with the majority of the fibers being relayed through the ciliary ganglion from the midline nucleus (Edinger-Westphal) of the oculomotor complex. The projection of area 19 to the midbrain oculomotor complex is by way of the internal corticotectal tract, but no details of the supranuclear connections are known. Jampel²⁷ succeeded in increasing refraction in both eyes of the macaque accompanied by convergence and in some cases pupillary constriction by unilateral faradic stimulation of area 19.

Units of Measurement of Accommodation and Definition of the Prism Diopter

Accommodation is measured in *diopeters* (D), that is, in terms of the reciprocal of the fixation distance. Thus if the fixation distance is 1 m, the accommodation is said to be 1D; if 1/2 m, 2D; if 1/3 m, 3D; and so forth. There is a near fixation distance inside which the eyes cannot effectively accommodate. This limiting distance is termed the *near point of accommodation* (NPA). It is assumed that at optical infinity no accommodation is exerted by emmetropic or corrected ametropic eyes. This distance is termed the *far point of accommodation* (FPA). The range from infinity to the near point of accommodation is the *range of accommodation*. The distance of the near point—and therefore the range of accommodation—is a function of advancing age. The standard curve describing this relationship was established by Duane in 1912 and revised in 1922 on the basis of 4200 cases¹² (Fig. 5–1). During the second, third, and fourth decades, the loss of accommodation is gradual (on average, 2.0D in the second decade and 2.9D in the fourth decade). It is very rapid in the fifth decade and after that asymptotically reaches a minimum. In measuring the NPA in older children and teenagers we have found that the average values determined by Duane are about 1.5D higher than the average values in our clinic population.³⁷

Sympathetic Innervation

In all probability there is also a sympathetic innervation of the ciliary muscle so that instillation

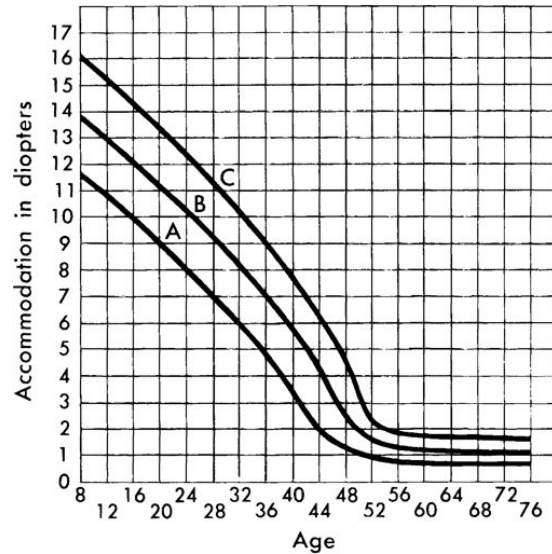


FIGURE 5–1. Duane's standard curve of accommodation in diopters in relation to age. A, lowest values; B, average values; C, highest values. (From Duane A: Studies in monocular and binocular accommodation with their clinical applications. *Am J Ophthalmol* 5:865, 1922.)

of sympathicomimetic drugs in humans or stimulation of the cervical sympathetic ganglion in animals may increase hypermetropia. One cannot be sure whether this effect is the result of vasoconstriction with reduction in the mass of the ciliary body and increased tension of the zonular fibers and flattening of the lens. There also may be a direct effect on the ciliary muscle. In any event, the effect is small compared with the positive accommodation resulting from parasympathetic impulses.

Convergence

As stated in Chapter 4, convergence is a disjunctive (vergence) movement that produces an increase in the angle formed by the visual axes, ordinarily through simultaneous, synchronous adduction of each eye. The result is a convergent position of the visual axes. The term *convergence* is applied equally to the movement of the eyes, to the convergent position they assume through this movement, and by implication to the innervational pattern required to maintain the convergent position. A terminological differentiation would be desirable for clarity's sake, but one does not exist at present. In general the meaning of the word "convergence" is readily understood from the context in which it is used, and it will be used in this volume without the cumbersome qualifying

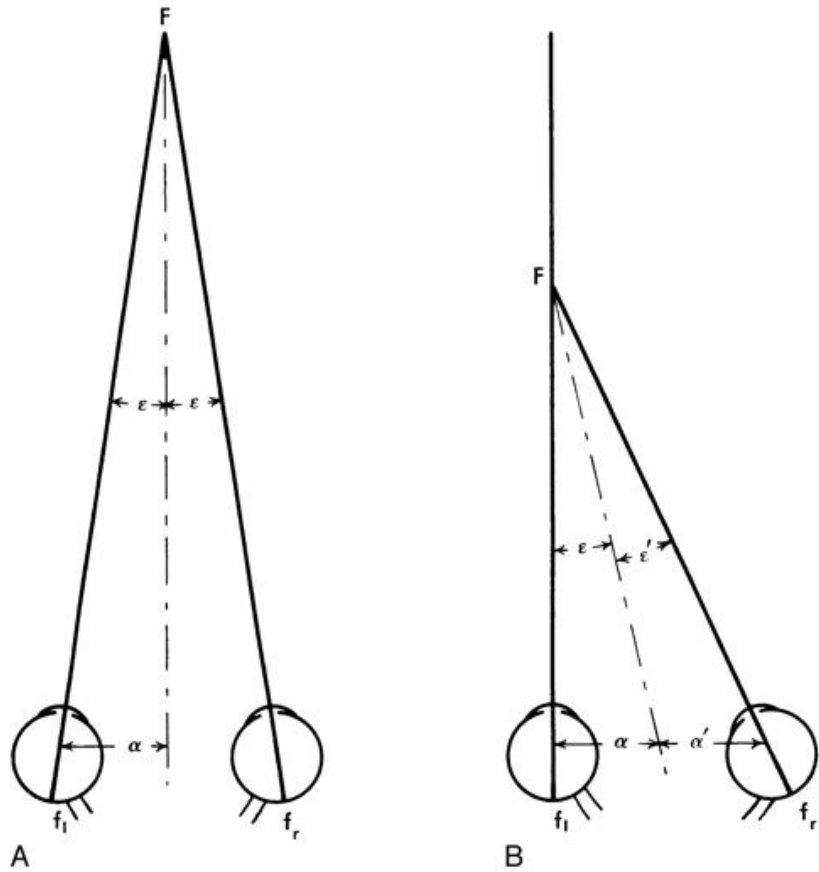


FIGURE 5-2. A, Symmetrical convergence of the visual lines; α equals one half the interpupillary distance. B, Asymmetrical convergence of the visual lines.

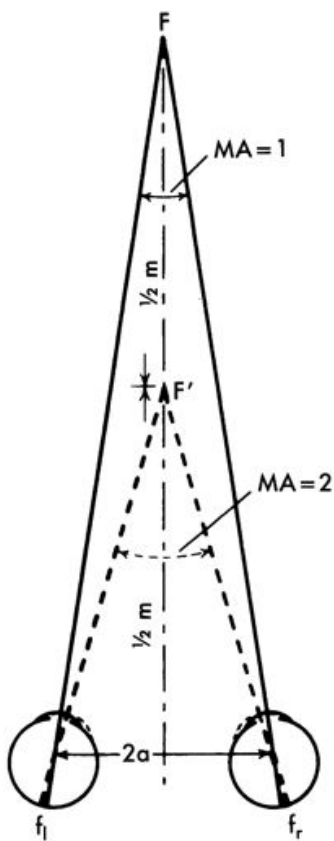


FIGURE 5-3. Definition of meter angle (MA). The visual lines converge 1 MA at 1 m fixation distance, F, and 2 MA at 1/2 m fixation distance, F'.

words “movement” or “position,” except for the sake of clarity.

If the fixated object is situated in the median (sagittal) plane of the head, equal angles are formed between each visual axis and a line erected perpendicular at the midpoint of a line connecting the centers of rotation of the eyes (*symmetrical convergence*, Fig. 5-2A.) If the fixation point lies to the right or left of the median plane, the angles differ (*asymmetrical convergence*, Fig. 5-2B.)

The nearest point on which the eyes can converge is the *near point of convergence* (NPC). As a rule, it is much closer to the eyes than the NPA and in general does not change with age. In clinical practice an NPC of 10 cm is considered adequate. The proper clinical determination of the NPC and its value in assessing neuromuscular anomalies of the eyes are discussed in Chapter 12.

Units of Measurement of Convergence

The unit for the measurement of convergence is the *meter angle* (MA), introduced by Nagel.³⁵ This unit is numerically the reciprocal of the fixation distance in meters; that is, it is formed in analogy to the diopter (Fig. 5-3).

The MA is defined as the amount of convergence required for each eye to fixate an object located at 1 m from the eyes in the median plane. Thus if the fixation distance is 1 m, an emmetropic subject must converge 1 MA and accommodate 1D; if the fixation distance is 1/2 m, the MA equals 2 and the accommodation required is 2D; if the fixation distance is 2 m, the MA equals 1/2 and the required accommodation is 1/2D; and so on. The MA is a convenient unit since it relates convergence numerically to accommodation, but the values are precise only if the reference points for the two functions are identical. This usually is not the case, since accommodation is ordinarily specified from the spectacle plane and convergence from the center of rotation of the eyes.

Also, we are accustomed to thinking of convergence in terms of the angle formed between the two visual axes rather than the amount of vergence of each eye, which is the most convenient and common usage, particularly for clinical purposes. The amount of vergence of both eyes may be designated as the large MA to distinguish it from the small MA of Nagel.³⁵

The large MA is a relative unit and is the same in every person. The absolute or actual amount of convergence is greater the larger the interocular separation. Consequently, for identical MAs the absolute amount of convergence varies for different individuals.

If the interocular separation, $2a$, and the fixation distance, d , are known, the angle (half the angle of symmetrical convergence) can be found by the formula $\tan \epsilon = 2a/d$ (see Fig. 5-3).

The *prism diopter* is the unit of measurement of an ophthalmic prism, and in clinical usage convergence is described in terms of prism diopters. A prism is defined as having the power of 1 prism diopter (Δ) when it displaces the visual axis, referred to the center of rotation, by 1 cm at a distance of 1 m (Fig. 5-4), and 1Δ is equivalent to 0.57° of arc. Since prisms or their equivalents are used to measure vergences and the relative position of the eyes, the term prism diopter has acquired a broader meaning and also is used clinically to specify vergences and ocular deviations.

The angle of 2ϵ of symmetrical convergence is found by multiplying $1/d$ (the MA of convergence) in meters by the interocular distance in centimeters. Thus if a person converges at 1 m and has an interocular separation of 6.5 cm, the convergence this person must exert is 6.5Δ . If an object is fixated at a distance of 1/3 m, there must

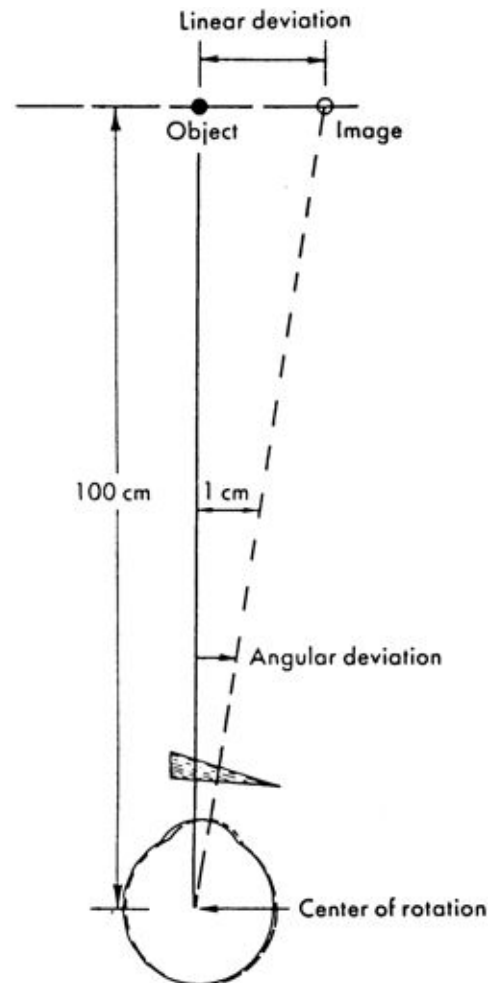


FIGURE 5-4. Diagram demonstrating definition of prism diopter.

be a convergence of 19.5Δ . This is known as a person's *convergence requirement* for the given fixation distance.

Strictly speaking, one should specify the interocular separation as the distance between the centers of rotation. For clinical purposes the term *interpupillary distance* is sufficient. To the distance d , measured habitually from the spectacle plane, approximately 0.027 m should be added to account for the distance from the spectacle plane to the center of rotation. In common clinical usage, this may be safely disregarded.

Components of Convergence

VOLUNTARY CONVERGENCE. Convergence is the only vergence movement that also may be voluntary, which means that convergence may be exerted without an external stimulus to converge. However, in the ordinary use of the eyes, conver-

gence is a reflex, as are all other vergence movements.

Jampolsky²⁸ denied the existence of voluntary convergence and believed it to be a “trick” when someone converges the eyes seemingly at will. In his opinion such a person is making an accommodative effort even without a fixation object and converges accordingly. Jampolsky based this view on his observation that with alleged voluntary convergence a pupillary constriction is always present.

It is difficult to prove that voluntary convergence can be independent of accommodation and pupillary constriction is not absolute proof for the presence of an “accommodative effort.” Moreover, voluntary accommodation with one eye occluded does not necessarily trigger the change of vergence usually associated with accommodation.³² Many people are capable of maintaining the convergent position of their eyes even when the fixation object has been removed. Since this obviates the need for accommodation, the maintenance of convergence is thought to be achieved by voluntary convergence. Whether or not this is correct, to evaluate a patient’s ability to maintain convergence is helpful in forming a judgment about the quality of overall convergence function (Chapter 12). In a clinical setting, voluntary convergence is occasionally used by children to gain the attention of or cause anxiety in their parents. Indeed, we have on more than one occasion examined children with a history of intermittent crossing of the eyes who had discovered the trick of voluntarily convergence.

Reflex convergence may be divided into a number of components³⁰: tonic convergence, accommodative convergence, fusional convergence, and proximal convergence.

TONIC CONVERGENCE. The anatomical position of rest of the eyes (see Chapter 8) is generally believed to be one of divergence. To bring the eyes from this position into the physiologic position of rest, the only position that one can define operationally in awake and conscious subjects is tonic convergence. Tonic convergence presumably is brought about by the tonus of the extraocular muscles. Extraocular muscles are never without electrical activity when the eyes are at rest in the intact, awake human. The sources of tonus of the extraocular muscles are discussed also on page 11.

In the absence of quantitative data on the absolute position of rest, it is impossible to make

quantitative statements about tonic convergence. However, it would appear that tonic convergence in the visually adult person remains rather stable throughout life, as judged by the stability of the “fusion-free” position.⁴⁰

The apparent increase of tonic convergence after sustained periods of fixation appears to be the result of prolonged decay of fusional vergence rather than a change in the level of tonic innervation of the extraocular muscles.⁴⁴

Jampolsky²⁸ questioned the existence of tonic convergence or tonic divergence—that is, the existence of any convergence or divergence mechanism that is not set into motion by retinal stimuli (see also Chapter 22). For example, he pointed out that in death and before rigor mortis the eyes commonly are only slightly divergent or even straight. This is not directly comparable to the situation in which a live person fixates at a distance. Others have made positive observations in favor of the existence of tonic convergence. Cohen and Alpern⁹ among others, in studying the effect of ethanol on the accommodative convergence–accommodation (AC/A) ratio, have shown that ethanol increases convergence at distance; that is, it produces an increase in tonic convergence. Jampel²⁷ produced convergence movements without pupillary responses by stimulating certain areas of the central nervous system. Jampolsky²⁸ was not convinced that tonic convergence can be produced by these experiments because of the possibility that the electric current may have stimulated a broader area than that intended. Be that as it may, the evidence appears to favor the existence of tonic convergence. Moreover, we believe that a *nonaccommodative convergence excess type of esotropia* (see Chapter 16), that is, an esotropia greater at near than at distance fixation, in a patient with a normal or abnormally low AC/A ratio can only be explained on the basis of excessive tonic convergence.³⁹ The relentless recurrence of certain types of comitant esotropia despite repeated maximal surgery has also been blamed on excessive tonic convergence.³⁸ From a clinical point of view the mechanism of tonic convergence is a useful and necessary concept even though nothing is known about the source and trigger mechanism of such innervation.

ACCOMMODATIVE CONVERGENCE AND THE AC/A RATIO. When a person exerts a certain amount of accommodation, a determined amount of convergence is elicited. Convergence so elicited

is called accommodative convergence. The reverse would seem to hold true also; for example, forced convergence with ophthalmic prisms may cause changes in accommodation.¹⁴ However, these changes in accommodation have no clinical importance.

The synkinesis between accommodation and convergence has important physiologic effects on binocular vision in near fixation, and an understanding of this role is essential in the study of comitant strabismus.

It is reasonable to assume that the basic convergence requirement is fulfilled through accommodative convergence. Tonic and fusional convergence have their own functions, and proximal convergence is a supplementary one. Therefore a normal, emmetropic person should be expected to exert 1 MA of convergence for each diopter of accommodation (or its equivalent in prism diopters), but this is not the case. Each individual responds to a unit stimulus of accommodation with a specific amount of convergence that may be greater or smaller than is called for by the convergence requirement. The convergence response of an individual to a unit stimulus of accommodation may be expressed by his or her AC/A ratio. This ratio, which has the dimensions [Δ/D], is a measure of the responsiveness of a person's convergence function to a unit of stimulus of accommodation. The concept of a ratio between accommodation and convergence was first clearly defined by Fry¹⁸ who later with Haines²⁰ introduced the abbreviation, AC/A ratio.

METHODS FOR DETERMINATION OF THE AC/A RATIO

Heterophoria Method. This method consists of measuring the deviation in distance fixation (optical infinity) with full correction of a refractive error, if one is present, on the assumption that no accommodation is exerted under these circumstances. The deviation then is measured at near-vision distance (33 cm or 3D) on the assumption that the convergence exerted is caused wholly by the accommodation-convergence synkinesis. The AC/A ratio is obtained from the equation

$$AC/A = PD + \frac{\Delta_n - \Delta_o}{D}$$

where PD is the interpupillary distance (in centimeters), Δ_n and Δ_o the deviations near and at distance, and D the fixation distance at near in diopters. This equation is explained by the fact that the convergence requirement equals the inter-

pupillary distance multiplied by the fixation distance in diopters and that the change in deviation from distance to near fixation equals $\Delta_n - \Delta_o$. Note also should be made of the fact that the sign conventionally is as follows: esodeviations are considered to be positive (+) and exodeviations to be negative (-).

To give an example:

$$PD = 6.0 \text{ cm}, \Delta_n = 8^\Delta X \text{ at } 3D, \Delta_o = 2^\Delta X$$

$$AC/A = 6.0 + \frac{-8 - (-2)}{3} = 4^\Delta/D$$

The AC/A ratio equals 4^Δ of accommodative convergence for each diopter of accommodation.

A simple comparison of the deviation in distance and near fixation is commonly used in clinical practice to estimate the AC/A ratio. If the two measurements are equal, the AC/A ratio is said to be normal.⁴¹ If the near measurements in an esotropic patient are greater by 10^Δ or more, the AC/A ratio is said to be abnormally high.

Caution is necessary when making such a determination. The difference between the deviation in distance and near fixation is of great practical importance in assessing the degree of comitant strabismus in patients with esotropia or exotropia. The use of the term *normal* or *excessive AC/A ratio* should be avoided, however, unless the ratio has been actually determined by using equation (1) or by some other method. If a patient has an esodeviation of 30^Δ for distance and for near fixation (e.g., at 33 cm) and a PD of 5.7 cm, his or her AC/A ratio would be

$$5.7 + \frac{30 - 30}{3} = 5.7^\Delta/D$$

The AC/A ratio is equal to the interpupillary distance. Theoretically, the expected "ideal" AC/A ratio is when the convergence requirement is fulfilled by accommodative convergence. If the term *normal* is understood in a statistical sense, however, one would say that the AC/A ratio of this patient is close to the upper limit of the distribution of a population with a normal sensorimotor system. In such a population the mean of the AC/A ratio is somewhat over half the interpupillary distance. If a patient has an esotropia of 30^Δ in distance fixation and 36^Δ when fixating at 33 cm (which is not considered to be a clinically significant difference) and again an interpupillary distance of 5.7 cm, the AC/A ratio would be

$$5.7 + \frac{36 - 30}{3} = 7.7^\Delta/D$$

This figure is outside the normal range and by all counts a high AC/A ratio. *These considerations must be kept in mind by those who determine the AC/A ratio by comparing distance and near deviations.*

An additional caveat regarding the heterophoria method concerns those patients who have an abnormal near-distance relationship of their esotropia that is unrelated to a high AC/A ratio (nonaccommodative excess). Von Noorden and Avilla³⁶ showed that the AC/A ratio as determined with the gradient method is actually normal or may be subnormal in such patients and that reliance on the heterophoria method will miss the correct diagnosis of this entity.

Gradient Method. Another method of determining the AC/A ratio which is preferred by us over other methods is the so-called gradient method. Here the change in the stimulus to accommodation is produced by means of *ophthalmic lenses*, not by a change in viewing distance. For a given fixation distance, minus lenses placed before the eyes increase the requirement for accommodation and plus lenses relax accommodation. It is assumed that $-1D$ lenses produce an equivalent of $1D$ of accommodation, whereas $+1D$ lenses relax accommodation by $1D$, and that the accommodative response to the lenses (and therefore the accommodative convergence produced) is linear within a certain range. For a given fixation distance the AC/A ratio inferred from the effect of ophthalmic lenses may be readily ascertained from the simple formula

$$AC/A = \frac{\Delta_1 - \Delta_0}{D}$$

where Δ_0 is the original deviation, Δ_1 the deviation with the lens, and D the power of the lens. If the original deviation for a given fixation distance was an exodeviation of 2Δ , and if $-2D$ lenses induced an esodeviation of 8Δ , the AC/A ratio would be

$$\frac{8 - (-2)}{2} = 5\Delta/D$$

The AC/A ratio computed by the heterophoria method is usually larger than the one obtained by the gradient method, mainly because of the effect of proximal convergence. It is held, therefore, that only the gradient method gives a true estimate of the AC/A ratio,^{40, p 121ff; 48} but it is necessary that more than two points be determined.

First, one cannot be sure of the limits within which the AC/A ratio is linear. Alpern and coworkers³ showed linearity over the intermediate stimulus levels ($+1$ to $5D$) in prepresbyopic subjects but nonlinearity at the lower and higher stimulus levels.

Second, the deviations of the ocular axes are subject to considerable random variation in magnitude. By determining a greater number of points and drawing the best-fitting line through them, one can lessen the effect of the random variations on the computed AC/A ratio. Table 5-1 shows the way in which Sloan and coworkers recorded their data. In Figure 5-5 the data from this table are plotted in a graph. The slope of the best-fitting line, $s = 3.9$, is a measure of the AC/A ratio.

TABLE 5-1. Illustrative Data on Accommodation-Convergence Relationship

Dioptric Power of Added Spheres	Diopters of Accommodation Required for Clear Image at 33 cm	Lateral Phoria at 33 cm in Prism Diopters	Equivalent Convergence in Prism Diopters (PD = 6.4 cm)	Supplementary Observations
+4.0	-1.0	18X	1.5	Target details blurred
+3.0	0	18X	1.5	Target details clear
+2.0	1.0	17X	2.5	
+1.0	2.0	12X	7.5	
0	3.0	9X	10.5	Passes bar-reading test
-1.0	4.0	5X	14.5	
-2.0	5.0	1X	18.5	
-3.0	6.0	2E	21.5	Passes bar-reading test
-4.0	7.0	7E	26.5	
-5.0	8.0	11E	30.5	
-6.0	9.0	14E	34.5	
-6.5	9.5	21E	41.5	Target details clear with effort
-7.5	10.5	29E	49.5	Target details blurred

*Normal subject, age 26, interpupillary distance 6.4 cm, exophoria of 0.5Δ at 20 ft.

X, exophoria; E, esophoria.

Modified from Sloan L, Sears ML, Jablonski MD: Convergence-accommodation relationships. Arch Ophthalmol 63:283, 1960.

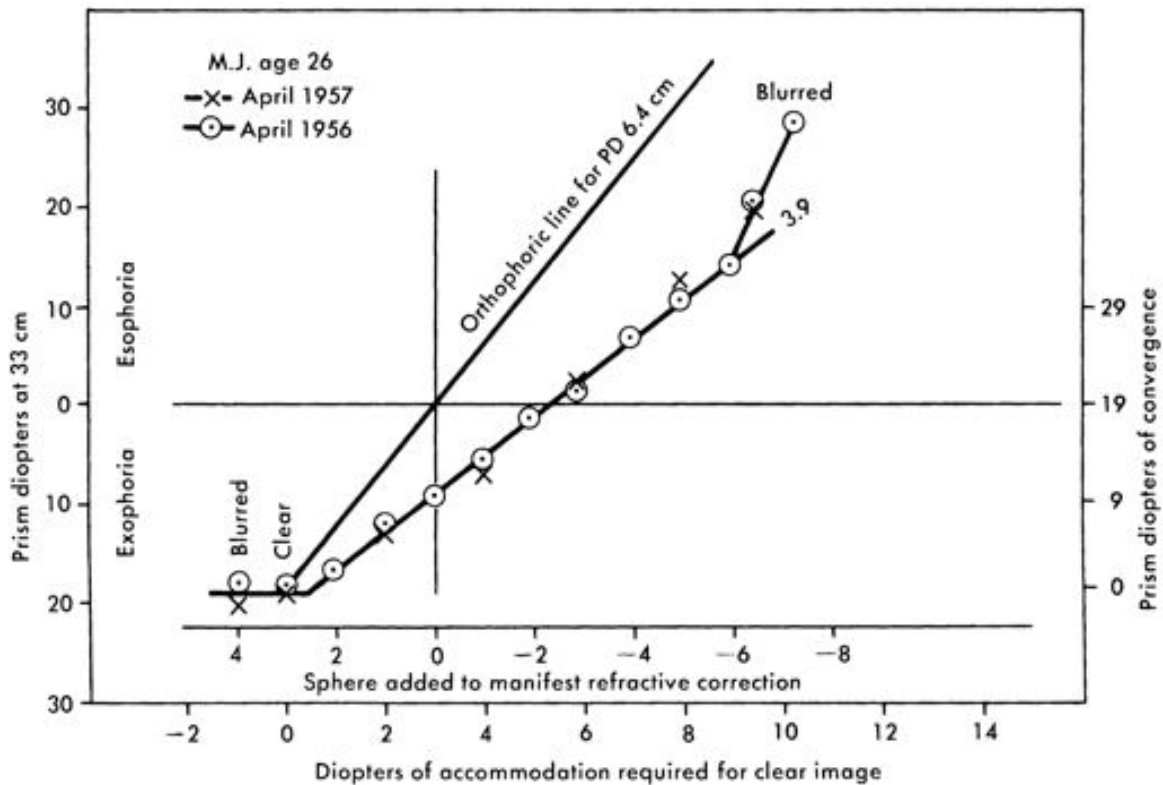


FIGURE 5-5. Graph showing the accommodative convergence–accommodation (ratio) data given in Table 5-1. PD, prism diopter. (From Sloan L, Sears ML, Jablonski MD: Convergence-accommodation relationships. *Arch Ophthalmol* 63:283, 1960.)

For clinical purposes it suffices to measure the deviation with the eyes in primary position at a fixation distance of 33 cm and the patient fully corrected and then to repeat these measurements after the addition of +3.00D and -3.00D lenses.

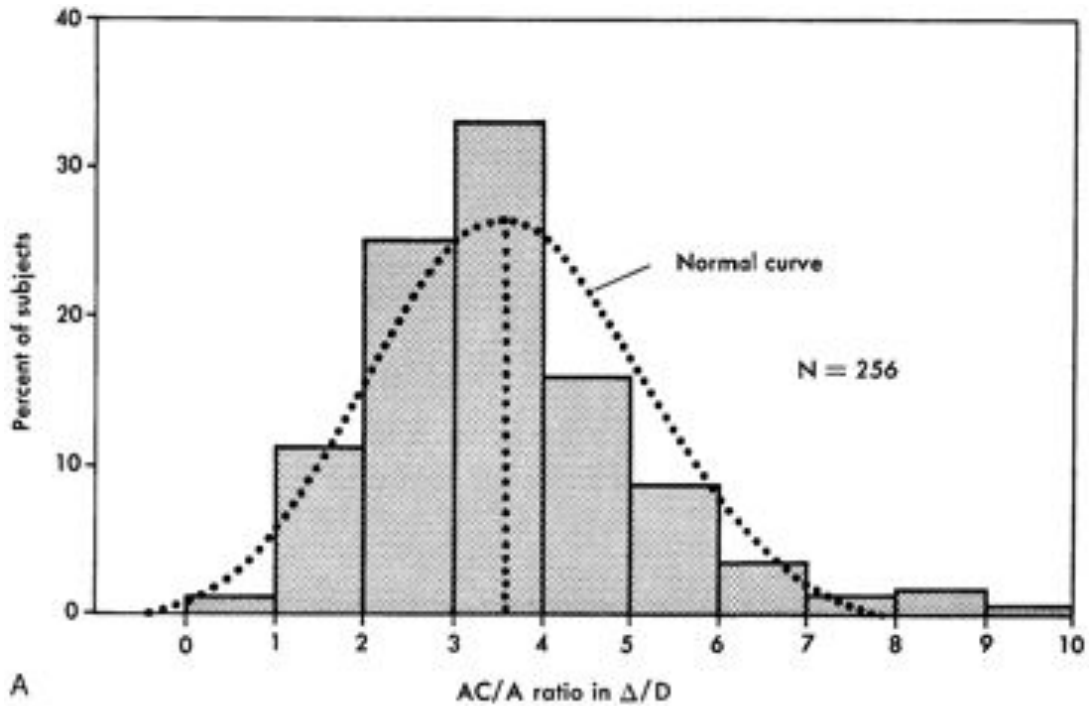
Fixation Disparity Method. The fixation disparity method has been used extensively by Ogle and coworkers⁴⁰ to obtain the AC/A ratio. The AC/A ratio is indirectly derived from this technique. Ogle and coworkers determined in one set of data the changes in fixation disparity induced by forced convergence using prisms and in a second set of data the changes induced by altering the accommodative stimulus with lenses. From these two sets of data they determined the stimuli for convergence and accommodation that gave the same fixation disparity. These results agreed with those obtained by means of direct determination of the AC/A ratio. The authors pointed out that the value of their method is the fact that it is binocular test.⁴⁰ However, because of its complexity, the test has found little application in clinical work.

Haplosopic Method. Another laboratory method which must be mentioned makes use of haplosopic arrangements (p. 72). In fact, the

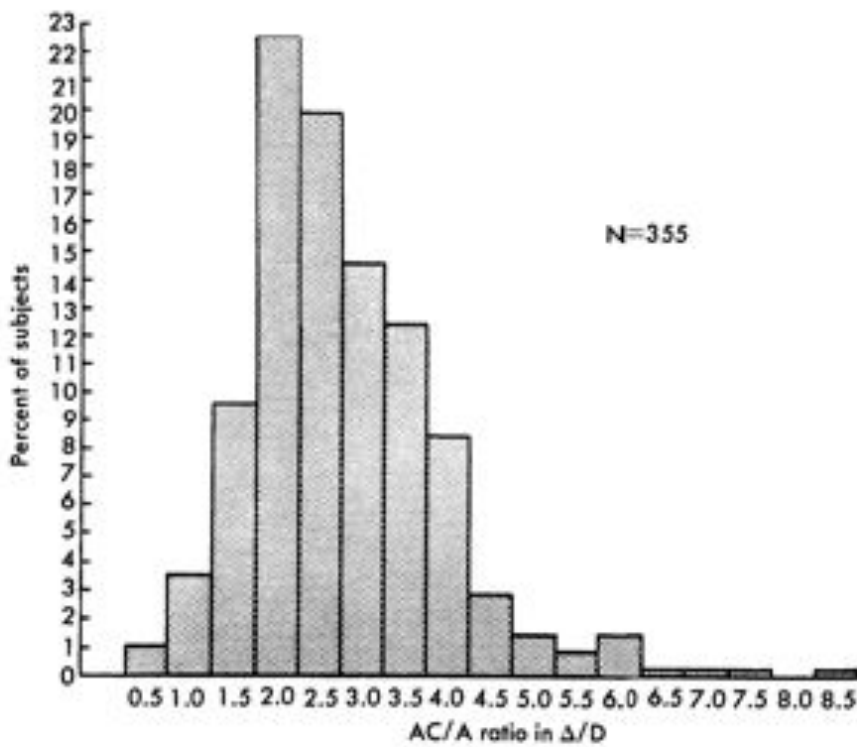
haploscope was originally invented for study of the accommodation-convergence relationship and is ideally suited for the purpose.

Normal Range of the AC/A Ratio. Quantitative studies on persons with normal sensorimotor systems have shown that in the vast majority of people the AC/A ratio does not fulfill the convergence requirement. The normal range of the AC/A ratio is between 3 and 5. Values above 5 are considered to denote excessive accommodative convergence and values under 3, an insufficiency.⁴⁶ Figure 5-6A shows the frequency distribution in 256 subjects studied by Ogle and coworkers⁴⁰ with the fixation disparity method. Franceschetti and Burian,¹⁶ using a gradient method (Fig. 5-6B), found a somewhat different distribution in 355 subjects of a random population.

THE ACCOMMODATION-CONVERGENCE RELATIONSHIP: ACQUIRED OR INNATE? From the clinical standpoint the most important questions are whether the AC/A ratio is a stable function, constant throughout life, and whether it can be manipulated by glasses, drugs, surgery, or orthoptic treatment. The answers depend to some extent on whether one believes the AC/A ratio to



A



B

FIGURE 5-6. Distribution of accommodative convergence–accommodation (AC/A) ratios in a normal population (Δ/D). (A from Ogle KN, Martens TG, Dyer JA: Oculomotor Imbalance in Binocular Vision and Fixation Disparity. Philadelphia, Lea & Febiger, 1967; B from Franceschetti AT, Burian HM: Gradient accommodative convergence–accommodative ratio in families with and without esotropia. Am J Ophthalmol 70:558, 1970.)

be an acquired (learned) or an intrinsic association.

The view of Helmholtz,²⁴ that the association between accommodation and convergence devel-

ops early in life as a result of constantly repeated, simultaneous use of related degrees of the two functions—in other words, that it is a *learned association*—has been accepted and elaborated on

by many workers. An acquired association implies a certain degree of independence in the relationship of the two functions; that is, one function can change to some degree without a change in the other. This elastic relationship is expressed in the classic teaching of Donders¹¹ and many others of a “relative” accommodation and “relative” convergence (p. 97). In the earlier orthoptic literature the treatment for accommodative esotropia therefore was spoken of as aimed at the “dissociation” of the two functions. Judge and Miles²⁹ showed that by increasing the interpupillary distance with periscope glasses the coupling between convergence and accommodation can be challenged and undergo adaptive modification. The clinical significance of this finding must be explored. Hainline and coworkers²² showed that infants under 1 year of age had appropriate convergence for targets at various distances. However, accommodation lagged behind convergence in development.

Any change in the stimulus to accommodation that can be shown to lead to a change in convergence or that accommodation can be changed by forced convergence would favor an innate and stable relationship between the two types of convergence. If it could be shown that any change in the stimulus to accommodate causes a change in convergence and, conversely, that accommodation is altered by prismatically induced convergence, this would favor an innate and stable relationship between these two functions. Such a situation was found by Ames and Gliddon⁴ and by Morgan.³³ Furthermore, if the association is learned, one would not expect it to exist in patients who have had strabismus throughout most or all of their lives. Hofstetter²⁵ found, however, that strabismic patients have the same pattern of the accommodation-convergence relationship as that in random samples of nonstrabismic populations. Hofstetter²⁶ also, by analysis of variance of this relationship in 30 pairs of identical twins, noted that there was a greater difference between families than between members of the same family. This would point to some genetic factors. Franceschetti and Burian,¹⁶ in comparing the AC/A ratio of a random population with that of members of families with an esotropic propositus, also found a significant difference in their average AC/A ratio and percentile distribution, which indicates that the AC/A ratio is a factor in the inheritance of esotropia.

The effect of age is of interest as well in this connection. From the evidence in the literature the

AC/A ratio appears stable up to the presbyopic age and even beyond, although Alpern^{2, p. 130} found a slight decline with age. Fry¹⁹ described for his own eyes an increase in the AC/A ratio during the 20 years from his 30th to 50th year. An increase in early presbyopia would not be too surprising and might well be attributed to an increase in impulse to accommodation, somewhat similar to that required with cycloplegia. This view is in agreement with that of Breinin and Chin,⁷ who demonstrated in a longitudinal study that the stimulus AC/A ratio remained essentially unchanged from age 16 through 52 but increased significantly beginning with the prepresbyopic age through early presbyopia (see also Fincham¹³).

A stable, genetically determined relationship between accommodation and convergence, based on fixed central nervous system arrangements, presupposes that excitations in these regions of the central nervous system by a stimulus to accommodation elicits simultaneous impulses to the extraocular muscles. Martens and Ogle,³¹ among others, found that within the range of response to ophthalmic lenses—that is, within the limits in which neither diplopia nor excessive blurring was induced by these lenses—the responses were indeed linear in 90% of 250 subjects examined. When a nonlinearity with plus lenses was found, it was attributed to a failure to relax accommodation rather than to a nonlinearity of the AC/A ratio itself.

STIMULUS AND RESPONSE AC/A RATIO. To obtain an understanding of the relationship between accommodation and convergence, one must keep in mind the elements involved in the process. These elements are (1) the change in stimulus to accommodation, (2) the peripheral and central nervous system mechanisms that elicit and transmit the impulses and provide the motor impulses to the inner and outer muscles of the eyes, and (3) the effector organs that provide the responses (the change in refraction of the eye and the change in position of the globe). These factors must be briefly analyzed.

So far in this discussion of AC/A ratio determination, the degree of convergence achieved has been related to the stimulus to accommodation (the dioptric power of the lenses used or the change in viewing distance). This relationship has been termed the *stimulus AC/A ratio* by Alpern and coworkers.³ In laboratory studies one can arrange a haploscopic device so that the stimulus to accommodation, the response to the stimulus (the

change in refraction of the eyes), and the change in position of the eyes can be determined simultaneously. With such an arrangement, one can relate the change in convergence to the stimulus to accommodation as well as to the accommodative response. The AC/A ratio related to the accommodative response has been termed the *response AC/A ratio*. This ratio differs from but parallels the stimulus AC/A ratio reported by Alpern and coworkers³ and by Ripps and coworkers.⁴³ Alpern and coworkers³ stated that the response AC/A ratio could be predicted with reasonable accuracy by multiplying the stimulus AC/A ratio by a factor of 1.08. In other words, the response AC/A ratio exceeds the stimulus AC/A ratio by about 8%. Presumably, this applies only to nonpresbyopic adults.

From the clinical standpoint, to determine the response AC/A ratio is impractical and unnecessary. The clinician must be concerned with the stimulus AC/A ratio. Various investigators have shown that the convergence response is generally linear and the stimulus is in the range within which the observers can respond. However, it is evident that a given stimulus to accommodation need not always elicit the required amount of change in refraction of the eye (the accommodative response), for example, in presbyopic patients. Although the impulses to accommodation sent out by the central nervous system may be adequate, or even excessive, and may result in adequate contraction of the ciliary muscle, the accommodative response will not be linear with the stimulus because of hardening of the crystalline lens. In cycloplegia the accommodative response may be too low or altogether absent because of a lack of response of the ciliary muscle. Nevertheless, in presbyopia there is a convergence response linear to the stimulus^{40, p. 151} and in partial cycloplegia even an excessive convergence response.

The reason one should use the stimulus AC/A ratio for clinical purposes is, then, that the accommodative convergence response does not depend on the accommodation response as such but rather on what is known in clinical terminology as the greater or lesser "effort of accommodation," which means the greater or lesser impulse to accommodation elicited by the stimulus. This is not an appropriate term. It cannot be defined or quantified operationally. The physiologist does not like it. Nevertheless, it has a certain usefulness to the clinician. When anomalies are present that require

a greater stimulation to accommodation, the associated convergence will be greater accordingly. Examples include uncorrected hypermetropia and inadequate ciliary muscle response such as cycloplegia. Conversely, if a lesser stimulus is necessary to achieve sharp retinal imagery, as in uncorrected myopia or with a spasm of the ciliary muscle, less innervation will be sent out to the ciliary muscle, and, accordingly, to the extraocular muscles.

CHANGES IN THE AC/A RATIO WITH GLASSES, DRUGS, SURGERY, AND ORTHOPTICS. Both accommodation and convergence have a central and a peripheral mechanism. The definition given for the AC/A ratio as a measure of responsiveness of the convergence mechanism to a unit of accommodation refers to the central mechanism. Theoretically, this is undoubtedly permissible, since the wide range of AC/A ratios clearly cannot be attributed to differences in the peripheral mechanisms of either accommodation or convergence. Methods of measuring the "accommodative effort" or the convergence responsiveness are not available.⁶ One can only determine the change in vergence induced by a unit stimulus to accommodation (or by the refractive change produced by such a stimulus, as in the response AC/A ratio). This, then, is the *operational definition of the AC/A ratio*.

Such an operational definition is most needed since it is possible to bring about changes in vergence through various manipulations of the peripheral mechanisms of accommodation and convergence. However, when evaluating neuromuscular anomalies of the eyes, one should keep in mind that a central mechanism—the so-called accommodative effort—in the last analysis controls the AC/A ratio.

This is quite clear in the case of *spectacles lenses*. No one has claimed that spectacles lenses change the AC/A ratio. If, for instance, a patient has an esodeviation of 15^Δ for distance and a refractive error of +3D in both eyes (OU) and if the deviation is caused solely by accommodative convergence, correction of the refractive error will reduce the deviation at distance to zero. What happens is that if the patient's eyes are not corrected by glasses, hypermetropia will be overcome by accommodation. There is an AC/A ratio of 5^Δ/D and therefore the patient develops an esodeviation of 15^Δ in distance fixation. With correction, the need for accommodation at distance is zero and consequently there is no deviation. The AC/A

ratio has not changed; only the need to accommodate has been removed. On the other hand, von Noorden and Avilla³⁶ reported a gradual decrease of esotropia at near fixation without change of the angle at distance in a group of children wearing bifocals. This observation must be interpreted to the effect that the AC/A ratio has changed.

The situation is seemingly more complex when it comes to the effect of topically applied *miotics*. For example, if one uses a parasympathomimetic drug, such as echothiophate iodide (Phospholine Iodide), clinical experience shows that the deviation has decreased insofar as it is caused by accommodative convergence. Ripps and coworkers⁴³ demonstrated that since this drug is a cholinesterase inhibitor, it enhances the effect of acetylcholine on the ciliary muscle. There is a facilitation of impulse transmission at the neuromuscular junction, which means that this drug lessens the impulse required to obtain a unit contraction of the ciliary muscle; therefore the AC/A ratio should be reduced as defined operationally, and in fact this is the case. The AC/A ratio obtained by the gradient method is considerably smaller when the eyes are under the influence of diisopropyl fluorophosphate (DFP)⁴⁸ or echothiophate iodide⁴³ than when the eyes are in their natural state. This effect can be verified in every patient in whom these drugs are effective, as in the following example.

CASE 5-1. A female patient, born 9-19-62, had a left esotropia from birth.

Treatment with glasses was started at 9 months of age. 3-4-65: Recession left medial rectus 4 mm, myectomy left inferior oblique. 9-14-66: Refraction and visual acuity +6.00 sph. + 1.50 ax 30° = 6/6; OS + 6.75 sph. + 1.00 ax 175° = 6/8. 10-11-67: s RX more than 70^Δ ET for distance and near, c̄ Rx 22^Δ ET with 5^Δ left hypertropia (LHT); 16^Δ ET' with 8^Δ-LHT'. AC/A ratio = 10^Δ/D (gradient method). Placed on 0.125% echothiophate iodide in 5% phenylephrine (Neo-Synephrine), one drop to each eye every night. 11-9-67: 14^Δ ET with 3^Δ LHT; 8^Δ ET' with 6^Δ LHT'. AC/A ratio = 4^Δ/D (gradient method).

Since the mechanism is a peripheral one, residing in the effectors, whether one wishes to say that the AC/A ratio has changed or to think in terms of a change in response of the effector, which calls for a reduced “accommodative effort,” is a matter of definition. There is a certain parallel to the effect of glasses. Glasses change

the input—the stimulus to accommodation. Drugs change the state of the effectors.

Tour⁵² expressed the thought that parasympathomimetic drugs affect the pupil. The greater depth of focus of an eye with a narrow pupil would reduce the need to accommodate and, hence, reduce the “accommodative effort.” If this were true, these drugs would act, as do spectacles lenses, by reducing the input. That this is not the case was shown by Ripps and coworkers.⁴³

The effect on the AC/A ratio of weakening the action of the medial rectus muscles surgically is explained by a change in the relationship between muscular contraction and the resulting rotation of the eyes.^{41, 45} Although parasympathomimetic drugs increase the sensitivity of the ciliary muscle to stimulation, operations on the medial rectus muscles reduce their mechanical effectiveness. In both cases the change is in the effector system, with this difference: when the drug is discontinued, the AC/A ratio generally returns to its original value. With *surgery* the change is lasting.⁴⁶ There is no reason to assume that the central linkage of accommodation and convergence has been affected by topically applied miotics or by surgery.

The whole concept presented in this chapter is supported by the effect of cycloplegic agents on the AC/A ratio. The clinician knows that patients with accommodative esotropia (see Chapter 16) may have a larger deviation in incomplete cycloplegia than without cycloplegia, as reported by Maddox.³⁰ Christoferson and Ogle,⁸ in studying the effect of cycloplegia on the AC/A ratio, related the magnitude of this ratio to the NPA. Figure 5-7 shows the data from a patient in whom the AC/A ratio increased from 2.4^Δ/D before cycloplegia to 20^Δ/D 1 hour after instillation of 2% homatropine hydrobromide drops. Twenty-four hours after the instillation, the AC/A ratio had returned to its initial value.

Interpretation of these findings is as follows. In cycloplegia a change in stimulus to accommodation results in a stronger impulse to the ciliary muscle than without cycloplegia and consequently to the extraocular muscles. A more or less unsuccessful effort is made to clear the retinal image. Remarkably, the relationship between stimulus to accommodation and convergence response remains linear even under those circumstances.

Cycloplegic agents, then, though acting directly on the peripheral mechanisms of accommodation, have an indirect effect on the central nervous

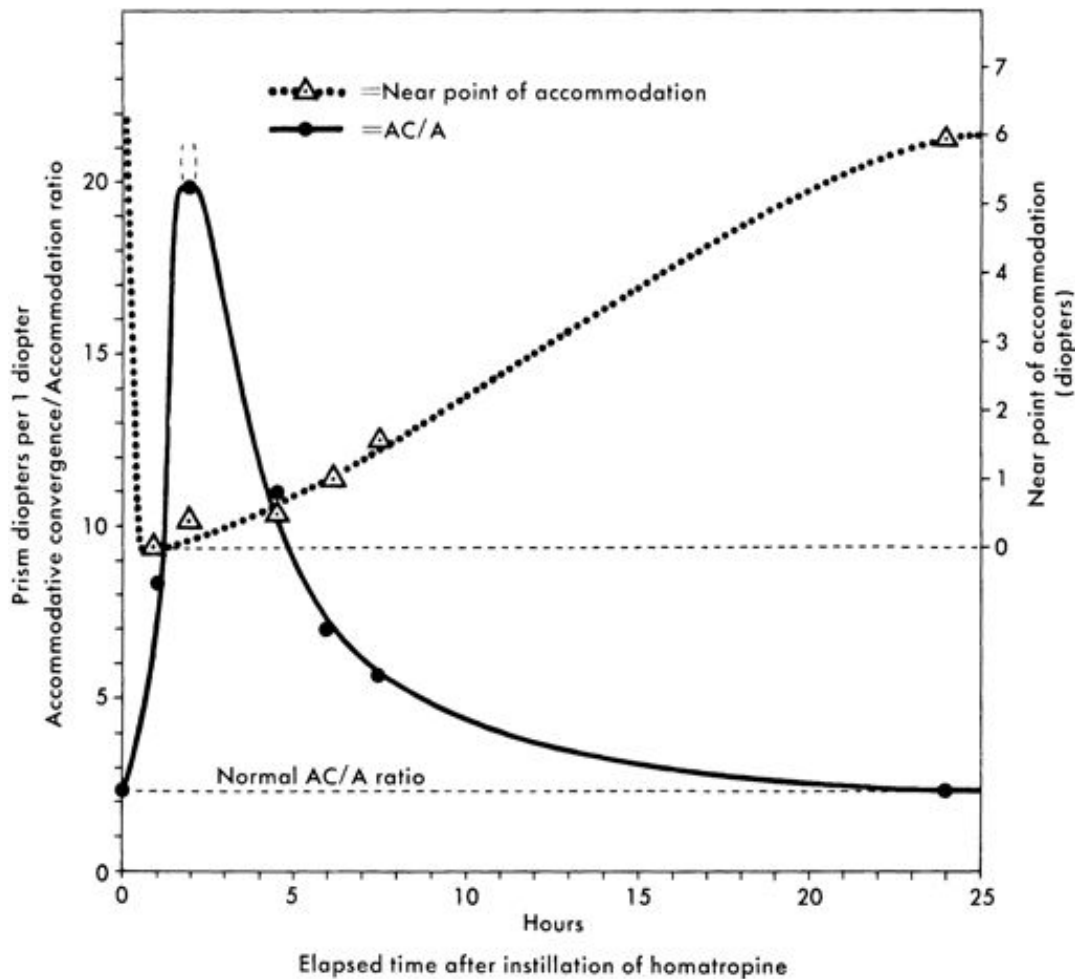


FIGURE 5-7. Effect of instillation of homatropine on the accommodative convergence–accommodation (AC/A) ratio, showing the marked increase in the AC/A ratio and corresponding reduction in the near point of accommodation and their return to normal within 20 to 25 hours. (From Christoferson KW, Ogle KN: The effect of homatropine on the accommodation–convergence association. *Arch Ophthalmol* 55:779, 1956.)

system control of the accommodation–convergence synkinesis, eliciting a greater “accommodative” effort.

A direct effect of drugs on the central nervous system, which influences the AC/A ratio, though in the opposite sense, is known to exist. Powell,⁴² Colson,¹⁰ Adler¹ and others have shown an increase in blood alcohol levels to be associated with an increase in esophoria at distance, an increase in exophoria at 33 cm (a more remote NPC), and some effect on fusional movements. Ethanol appeared not only to increase tonic convergence but also to reduce the AC/A ratio.⁹

Last, a word must be said about the effect of orthoptic exercises on the AC/A ratio. Most authors agree that such exercises do not change the AC/A ratio but Flom¹⁵ reported that in patients with exophoria, orthoptic exercises induced a nominal but only temporary increase in the AC/A ratio.

“RELATIVE” CONVERGENCE AND “RELATIVE” ACCOMMODATION. The observation that, within limits, one can force convergence by the use of prisms without blurring the fixated object and, conversely, that one can change accommodation by means of lenses without causing diplopia suggested to Donders¹¹ and his followers that there is an elastic relationship between accommodation and convergence. The limits within which convergence and accommodation could be changed without producing blurring or diplopia were termed the “amplitude of relative convergence” and the “amplitude of relative accommodation.” This teaching has prevailed until recently, but it has now been shown that every change in accommodative stimulus produces a change in convergence. The limits within which single vision is possible with changes in accommodative stimulus depend not on an elastic relationship between accommodation and convergence but on the availability of

fusional amplitudes that enable one to cope with the change in the position of the eyes. This concept is of basic importance for the understanding of binocular cooperation and of the neuromuscular anomalies of the eyes.

FUSIONAL CONVERGENCE. Accommodative convergence provides for gross adjustment of the position of the eyes, but when acting alone it rarely if ever provides binocular fixation. As stated on page 92, the AC/A ratio is too low in the majority of people, relative to the convergence requirement, leaving a divergence of the visual axes at near fixation. In some people the AC/A ratio is too large, causing excessive convergence of the visual axes and esodeviation in near fixation. The fine adjustment of the visual axes necessary for binocular fixation is obtained by *fusional vergence movements*. Fusional convergence does not differ in its general characteristics from other fusional movements. It is involuntary, and the stimulus for it is disparate retinal imagery.

PROXIMAL CONVERGENCE. A common experience in clinical testing of a patient's deviation is that esodeviations measured on a major amblyoscope are generally larger than those detected by the prism and cover test.^{5, 17, 50} This difference is present despite the fact that the major amblyoscope is arranged so that the targets are set at optical infinity. Furthermore, when the esodeviation of a patient who wears full correction is determined at near, one should expect to find the deviation to be equal to that in distance vision when lenses equivalent to the fixation distance at near are placed in front of the eyes. Under these conditions the need for accommodation has been obviated. One may find, however, that even then the deviation is larger at near than at distance. There are two explanations for this situation. The glasses worn by the patient may not have fully corrected the refractive error; or if it was definitely established that correct glasses were worn, the difference may be attributable to proximal convergence.

Proximal convergence is induced by the awareness of nearness of an object. This may be either an object at near vision distance or one that, while situated at near vision distance, has been optically placed at infinity, as in a major amblyoscope.

The actual amount contributed by proximal convergence to fulfill the convergence requirement has been variously estimated. Morgan³³ examined 413 subjects and estimated the mean to be 3.5^Δ.

An inverse relationship between proximal convergence and observation distance has been noted.^{21, 47} Wick and Bedell⁵⁴ measured the magnitude and velocity of proximal convergence and found that the peak velocities averaged to be substantially faster than the velocities of comparably sized fusional or accommodative convergence responses. These authors suggest that proximal convergence may, in fact, play a greater part in contributing to the near vergence response than traditionally assumed.

Ogle and coworkers^{40, p. 131} determined the AC/A ratio with the heterophoria method (R_d). They established a ratio PC/D, proximal convergence over distance, by the formula $PC/D = R_d - R_L$, where R_L stands for the AC/A ratio determined by the gradient method. They then found the proximal convergence of 28 subjects to have a mean value of 2.25^Δ, with a spread of -3.12^{Δ} to 7.25^Δ. It is difficult to interpret the meaning of the negative values.

SUMMARY. In the foregoing pages, following the lead of Maddox,³⁰ we subdivided convergence into a number of subclasses; however, we must emphasize that this is an artificial separation. In reality, there are certain central nervous system arrangements, the details of which are little known, that control impulses to the nuclei of the third cranial nerve and to the medial rectus muscles so that simultaneous adduction of the globes occurs, which we call convergence. These centers are probably located in the midbrain but have numerous connections with various cortical, subcortical, and peripheral retinal areas. As a result, convergence movements (or changes in convergent positions) can be elicited in many different ways: through stimuli arising in the cortex (tonic and proximal convergence); through the "accommodative effort" elicited by retinal stimuli by means of cortical areas 17 and 19 (accommodative convergence); and through convergence elicited by disparate retinal stimuli, again through the primary visual cortical areas and beyond (fusional convergence). One must not assume that the central arrangements for convergence distinguish between the various sources of impulses received. The central arrangements for convergence respond or do not respond to the stimuli reaching them and transmit them to the nuclei of cranial nerve III.

Although for analytic reasons, both physiologic and clinical, it is necessary to separate the various sources of convergence movements; do not forget that convergence is a unitary process.

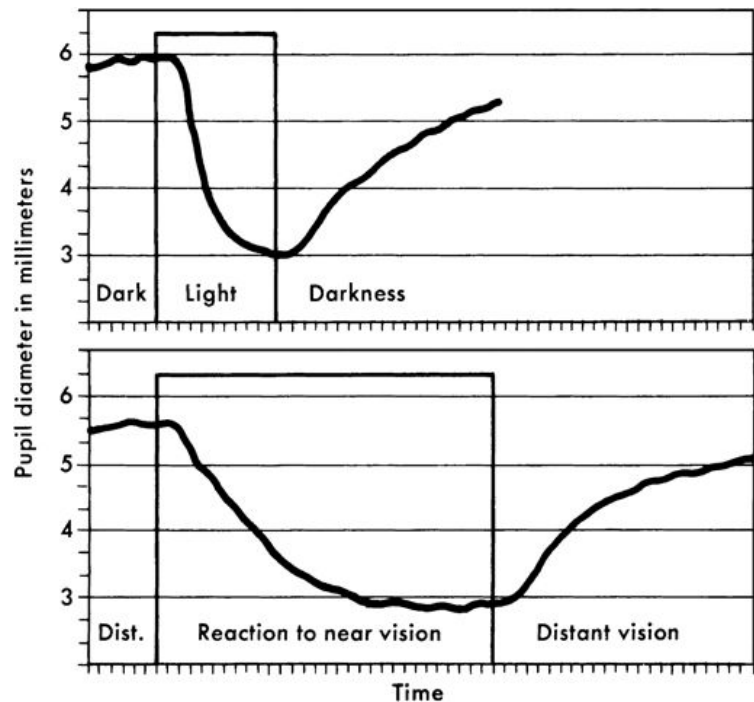


FIGURE 5-8. Graph showing the difference in temporal characteristics of light and near reaction of the pupil.

Pupillary Constriction

When changing fixation from a distant to a near object, in addition to accommodation and convergence, the pupils constrict. This reaction of the pupils differs from that which occurs with a change in retinal illuminance. It is slower (tonic) in nature and is maintained as long as the near fixation distance is maintained. When fixation is shifted to a more distant object, the pupils slowly dilate after a relatively long latency time of about 0.5 second. The time it takes to regain the original pupil size is roughly 10 times longer than the values of other pupil reactions.⁵⁵ In contrast to this slow, maintained constriction, a change in retinal illuminance causes speedier constriction, which is not maintained. If the retinal illuminance remains constant, the pupils return to their physiologic width corresponding to the level of illuminance (Fig. 5-8).

Pupillary constriction, although occurring in association with convergence and accommodation, does not depend on either one.⁵¹ Discussion continues whether, for instance, it is possible to have miosis with convergence of the visual axes while eliminating accommodation with plus lenses in front of each eye. Likewise, miosis occurs at near fixation in patients with uncorrected myopia and advanced presbyopia.⁵¹

On the other hand, recent work has shown that under rigorous alignment conditions accommoda-

tion may occur without pupillary constriction.⁴⁹ Myers and Stark³⁴ showed that the addition of a near stimulus reduces the latency of vergence eye movements and of accommodation more than pupillary latency. They concluded from these findings that the dual interaction between vergence and accommodation on the one hand and miosis on the other may be asymmetrical rather than symmetrical as previously assumed.

Constriction of the pupil at near fixation will be equal in both eyes even though vision in one eye may be impaired.

REFERENCES

1. Adler FH: Effect of anoxia on heterophoria and its analogy with convergent comitant strabismus. *Arch Ophthalmol* 34:227, 1945.
2. Alpern M: Movements of the eyes. In Davson H, ed: *The Eye*, vol 3. New York, Academic Press, 1962.
3. Alpern M, Kincaid WM, Lubeck MJ: Vergence and accommodation. III. Proposed definitions of AC/A ratios. *Am J Ophthalmol* 48 (1, pt 2): 141, 1959.
4. Ames A Jr, Gliddon GH: Ocular measurements. *Trans Section Ophthalmol AMA* 1928, p 102.
5. Bagolini B: Ricerche sul comportamento della "convergenza prossimale" in soggetti strabici e normali (rilievi mediante determinazione al sinottoforo e con prismi). *Boll Ocul* 40:461, 1961.
6. Breinin GM: Personal communication, 1962.
7. Breinin GM, Chin NB: Accommodation, convergence and aging. *Doc Ophthalmol* 34:109, 1973.
8. Christoferson KW, Ogle KN: The effect of homatropine on the accommodation-convergence association. *Arch Ophthalmol* 55:779, 1956.
9. Cohen MM, Alpern M: Vergence and accommodation. VI. The influence of ethanol on the AC/A ratio. *Arch Ophthalmol* 81:518, 1969.

10. Colson ZW: The effect of alcohol on vision. An experimental investigation. *JAMA* 115:1525, 1940.
11. Donders FC: On the Anomalies of Accommodation and Refraction of the Eye with a Preliminary Essay on Physiological Dioptrics. London, New Sydenham Society, 1864, p 110 *ff.*
12. Duane A: Studies in monocular and binocular accommodation with their clinical applications. *Am J Ophthalmol* 5:865, 1922.
13. Fincham EF: The proportion of ciliary muscular force required for accommodation. *J Physiol (Lond)* 128:99, 1955.
14. Fincham EF, Walton J: The reciprocal actions of accommodation and convergence. *J Physiol (Lond)* 135:488, 1957.
15. Flom MC: On the relationship of accommodation and accommodative convergence. III. Effect of orthoptics. *Am J Optom* 37:619, 1960.
16. Franceschetti AT, Burian HM: Gradient accommodative convergence–accommodative ratio in families with and without esotropia. *Am J Ophthalmol* 70:558, 1970.
17. Franceschetti AT, Burian HM: Proximal convergence. An evaluation by comparison of major amblyoscope and alternate prism and cover test measurements and by AC/A ratio determinations. In *Strabismus '69. Transactions of the Consilium Europaeum Strabismi Studio Deditum Congress (London, 1969)*. St Louis, Mosby–Year Book, 1970, p 125.
18. Fry GA: Further experiments on the accommodation convergence relationship. *Am J Optom* 16:125, 1939.
19. Fry GA: The effect of age on the AC/A ratio. *Am J Optom* 36:299, 1959.
20. Fry GA, Haines HF: Tait's analysis of the accommodative-convergence relationship. *Am J Optom*. 17:393, 1940.
21. Guzzinati GC: Osservazioni sulla convergenza prossimale. *Ann Ottalmol Clin Ocul* 79:475, 1953.
22. Hainline L, Ridell P, Grose-Fifer J, et al: Development of accommodation and convergence in infancy. *Behav Brain Res* 49:33, 1992.
23. Helmholtz H von: Über die Accommodation des Auges. *Graefes Arch Clin Exp Ophthalmol* 1 (pt 2): 1, 1855.
24. Helmholtz H von: Helmholtz's treatise on physiological optics. In Southall JP, ed: Translation from 3rd German edition, Ithaca, NY, Optical Society of America. 1924, Reprint, New York, Dover Publications, Vol 3, 1962, p 55 *ff.*
25. Hofstetter HW: Accommodative convergence in squinters. *Am. J Optom* 25:417, 1946.
26. Hofstetter HW: Accommodative convergence in identical twins. *Am J Optom* 25:480, 1946.
27. Jampel RS: Representation of the near response on the cerebral cortex of the macaque. *Am J Ophthalmol* 48 (5, pt 2): 573, 1959.
28. Jampolsky A: Ocular divergence mechanisms. *Trans Am Ophthalmol Soc* 68:730, 1970.
29. Judge SJ, Miles FA: Changes in the coupling between accommodation and vergence eye movements induced in human subjects by altering the effective interocular separation. *Perception* 14:617, 1985.
30. Maddox EC: *Clinical Use of Prisms, and Decentering of Lenses*. Bristol, England, John Wright & Sons, 1893.
31. Martens TG, Ogle KN: Observations on accommodative convergence, especially its nonlinear relationships. *Am J Ophthalmol* 47 (1, pt 2): 453, 1959.
32. McLin LN, Schor CM: Voluntary effort as a stimulus to accommodation and convergence. *Invest Ophthalmol Vis Sci* 29:1739, 1988.
33. Morgan MW Jr: Relationship between accommodation and convergence. *Arch Ophthalmol* 47:745, 1952.
34. Myers GA, Stark L: Topology of the near response triad. *Ophthalmic Physiol Opt* 10:175, 1990.
35. Nagel A: Die Anomalien der Refraction und Accommodation des Auges. In Graefe A, Saemisch Th, eds: *Handbuch der gesammten Augenheilkunde*, vol 6. Leipzig, Wilhelm Engelmann, 1880, p 478 *ff.*
36. Noorden GK von, Avilla CW: Nonaccommodative excess. *Am J Ophthalmol* 101:70, 1986.
37. Noorden GK von, Jenkins R: Accommodative amplitude in children wearing bifocals. In Lennerstrand G, ed: Update on strabismus and pediatric ophthalmology. In Proceedings of the Seventh Meeting of the International Strabismology Association and 20th Meeting of the American Association of Pediatric Ophthalmology and Strabismus, Boca Raton, FL, CRC Press, 1995, p 201.
38. Noorden GK von, Muñoz M: Recurrent esotropia. *J Pediatr Ophthalmol Strabismus* 25:275, 1988.
39. Noorden GK von, Morris J, Edelman P: Efficacy of bifocals in the treatment of accommodative esotropia. *Am Ophthalmol* 85:830, 1978.
40. Ogle KN, Martens TG, Dyer JA: *Oculomotor Imbalance in Binocular Vision and Fixation Disparity*. Philadelphia, Lea & Febiger, 1967.
41. Parks MM: Abnormal accommodative convergence in squint. *Arch Ophthalmol* 59:364, 1958.
42. Powell WH Jr: Ocular manifestations of alcohol and consideration of individual variations in seven cases studied. *J Aviat Med.* 9:97, 1938.
43. Ripps H, Chin NB, Siegel TM, et al: The effect of pupil size on accommodation, convergence, and the AC/A ratio. *Invest Ophthalmol* 1:127, 1962.
44. Rosenfield M: Tonic vergence and vergence adaptation. *Optom Vis Sci* 74:303, 1997.
45. Sears M, Guber D: The change in the stimulus AC/A ratio after surgery. *Am J Ophthalmol* 64:872, 1967.
46. Semmlow J, Putteman A, Vercher JL, et al: Surgical modification of the AC/A ratio and the binocular alignment ("phoria") at distance; its influence on accommodative esotropia: A study of 21 cases, *Binocu Vis Strabismus Q* 15:121, 2000.
47. Shapero M, Levi M: The variation of proximal convergence with change in distance. *Am J Optom* 30:403, 1953.
48. Sloan L, Sears ML, Jablonski MD: Convergence-accommodation relationships. *Arch Ophthalmol* 63:283, 1960.
49. Stakenburg M: Accommodation without pupillary constriction. *Vision Res* 31:267, 1991.
50. Thompson DA: Measurements with cover test. *Am Orthoptics J* 2:47, 1952.
51. Thompson HS: The pupil. In Moses RA, ed: *Adler's Physiology of the Eye*, ed 7. St Louis, Mosby–Year Book, 1982, p 326.
52. Tour RL: Nonsurgical treatment of convergent strabismus. *Calif Med* 90:429, 1959.
53. Tscherning MH: *Optique physiologique*. Paris, Carrée et Naud, 1898.
54. Wick B, Bedell H: Magnitude and velocity of proximal vergence. *Invest Ophthalmol Vis Sci* 30:755, 1989.
55. Wildt GJ van der: The pupil response to an accommodation stimulus and to a light stimulus. In Dodt E, Schrader KE, eds: *Normal and Disturbed Pupillary Movements*. Munich, JF. Bergmann, 1973.

Histology and Physiology of the Extraocular Muscles

As described in Chapter 4, the extraocular muscles perform two functions: optostatic and optokinetic. The optostatic function requires that the muscles maintain a state of postural tonicity; the optokinetic function requires that quick, tetanic contractions be performed. These two contradictory functions are served by two different sets of muscles in the skeletal muscle system. Eye muscles, however, are equipped to perform both functions simultaneously. It is important to learn what mechanisms enable them to do so.

In principle the type of response by extraocular muscles would be controlled either by the central nervous system or by peripheral mechanisms residing in the extraocular muscles or by both. We have only sketchy information of the finer details of the central nervous system control of tonic and saccadic extraocular movements, but we have gained a little more insight into the structural differentiation and physiologic and pharmacologic responses of the extraocular muscles. The structure of the extraocular muscles and its possible relation to their function will be discussed first.

In general, two types of striated muscles are distinguished in the skeletal muscle system: (1) “red” or dark muscles composed of fibers of small diameter and rich in sarcoplasm and (2) pale or “white” muscles with fibers of greater diameter and scanty sarcoplasm. Red muscles contract more slowly and are kept in a state of tonic contracture

by fewer impulses per second than are white muscles, which contract more quickly. Red muscles relax more slowly than white muscles, and their metabolism increases much less during contraction than that of white muscles. Consequently, red muscles do not tire as easily as white muscles. Red muscles are more continuously active and serve the function of postural activity; white muscles are muscles of locomotion and quick activity.

Structure and Function of the Extraocular Muscles

General Histologic Characteristics

The histologic structure of eye muscles, which perform the functions of both red and white muscles, differs in many respects from that of other striated muscles. Extraocular muscles contain fibers of varying diameters. In general they are the finest fibers found in any striated muscles. They vary in diameter from 9 μm to 17 μm , with fibers as fine as 3 μm having been seen,⁷² but these muscles also contain coarse fibers up to 50 μm in width. One can appreciate the fineness of fibers of extraocular muscles if their diameters are compared with those of fibers of the gluteus maximus (90 μm to 100 μm).

It was once believed that each muscle fiber

runs through the entire length of the extraocular muscle. If this were true, one would expect to find the same number of fibers in sections taken from the central or peripheral part of the muscle. This view has not been shown to be valid. Fiber counts from the central portion of the muscle have been consistently higher (44% to 72%) than those taken from the proximal or distal portions.^{2, 57} These findings indicate that many fibers must originate and terminate between the origin and the insertion of the muscle, suggesting that an interconnection network of muscle fibers must exist. Indeed, cholinesterase-positive “myomyous” junctions have been described in eye muscles of various species, including humans.⁵³

The extraocular muscles can be divided into two distinct portions. One portion is a peripheral orbital layer along the muscle surface and faces the orbit, which contains thin fibers with many mitochondria. This layer encloses a second portion, the central or bulbar layer, close to the globe, which consists of thicker muscle fibers with variable mitochondrial content. Both zones are distinctly separated from each other, sometimes by an internal perimysium, and their existence has been confirmed by numerous investigators.^{20, 39, 42, 53} High-resolution magnetic resonance imaging (MRI) and orbital dissections have shown that the rectus muscles insert in a bifid fashion: the global layer terminates at the myotendinous scleral insertion, whereas the orbital layer branches off further posteriorly to insert at the pulley (see p. 41) of each muscle.²⁶

Elastic tissue is unusually abundant in extraocular muscles of adults, so much so that it has been described as elastic bands.⁶⁶ The elastic fibers are thick and are arranged parallel with the muscle fibers. These longitudinal fibers are interconnected by transverse elastic fibers that form a rather dense network around the muscle fibers. In neonates, elastic fibers are present only in the perimysium. Schiefferdecker⁶⁶ therefore believed that the elastic fibers grow from the perimysium into the endomysium. He also thought that the abundance of elastic tissue was a factor in fine regulation of eye movements. Duke-Elder²⁹ agreed with this view. However, Eisler³³ believed it to be a secondary, mechanical phenomenon produced by frequent small pulls on the extraocular muscles.

Nerve Supply

In Chapter 4, it was mentioned that the nerve supply to extraocular muscles is extraordinarily

rich. The motor nerves are very thick, owing to the large number of fibers they contain. The ratio of nerve fibers to muscle fibers is nearly 1:12 in extraocular muscles, whereas in skeletal muscles it may be as high as 1:125.⁵⁷ The possibility that this rich nerve supply is partly responsible for fine regulation of eye movements cannot be overlooked.

The abundance of nerve fibers has led to the conclusion that the all-or-nothing law, or *law of isobolia*, applies to eye muscles.⁴⁵ According to this general principle of neuromuscular physiology, individual muscle fibers always respond with a maximum contraction to every supraliminal stimulus. The amount of total contraction of a muscle depends on the number of fibers taking part in a contraction.

Extraocular muscles also are provided with a number of different types of nerve endings. Woolard⁷⁶ recognized three types: (1) ordinary single motor end plates associated with coarser muscle fibers; (2) multiple grapelike nerve endings, especially around the tendons, which are believed to be sensory in nature; and (3) very fine, nonmedullated fibers ending in the thinner muscle fibers. Newer studies of these different nerve endings are reported in the following discussion.

Physiologic and Pharmacologic Properties

The physiologic and pharmacologic properties of extraocular muscles correspond to the many unusual histologic features of these muscles. Rehms⁶⁰ stated that eye muscles require and receive more oxygen than other skeletal muscles. Björk⁸ showed by means of electromyography (see p. 109) that responses of extraocular muscles in humans are considerably lower in amplitude (20 to 150 μ V), of much shorter duration (1 and 2 ms), and much higher in frequency (up to 150 cps) than those of peripheral skeletal muscles, in which the amplitude is 100 to 3000 μ V; the duration, 5 to 10 ms; and the frequency only up to 50 cps. Björk attributed these differences to the low nerve fiber-to-muscle fiber ratio of the motor units in extraocular muscles.

Extraocular muscles contract much more quickly than other voluntary muscles. Contraction times obtained from experiments on cats were: soleus muscle, 100 ms; gastrocnemius muscle, 40 ms; and medial rectus muscle, 8 ms.^{23, 27} The great speed of contraction of extraocular muscles is in

keeping with the requirements of saccadic eye movements and with what is known of the structure and innervation of extraocular muscles. It is all the more striking when contrasted with another observation.

Duke-Elder and Duke-Elder³⁰ demonstrated that the extrinsic muscles of eyes of cats contract under the influence of acetylcholine. Acetylcholine produces a strong contraction of smooth muscles in invertebrates and of some skeletal muscles in lower vertebrates, but has slight, if any, effect on skeletal muscles of mammals. Only denervated muscles of mammals or embryonic mammalian muscles react strongly to acetylcholine. In the lower vertebrates the differences in reaction to acetylcholine are indicative of the nature of muscles. The more quickly a muscle acts, the less it is apt to respond to acetylcholine; the more its action is one of postural tonicity, the more strongly it will respond to acetylcholine.

Since the discovery that a dual motor system of slow and fast fibers exists in extraocular muscles, experiments have shown that acetylcholine, choline, and nicotine cause slow and tonic contraction of slow fibers, whereas fast fibers respond with a fast twitch. The response of extraocular muscles to neuromuscular blocking agents is of clinical interest, since these drugs are often used during general anesthesia.

Slow and Fast Twitch Fibers

Customarily, one thinks of voluntary striated muscles as being characterized by fibers that respond to a single stimulus applied to their nerve with an ungraded fast twitch, followed by speedy relaxation, and accompanied by propagated electrical activity. Repetitive stimuli of relatively high frequency are required to maintain a tetanic contraction of these fibers. In contrast, smooth and other slowly contractile muscle systems do not react to a single stimulus applied to their nerve, but they do respond with a slow, maintained graded contraction to a few repetitive stimuli, unaccompanied by electrical activity. There are also pharmacologic differences between these two systems, which, in general, are present in spatially unrelated muscle groups.

Sommerkamp,⁶⁹ in his pharmacologic studies with acetylcholine, intimated the existence of a slow contractile system in striated muscles of amphibians, which produced a rapid twitch of the sartorius muscle of the frog but a slow maintained

contraction of the rectus abdominis muscle. Within iliofibularis muscle of the frog, Sommerkamp was able to separate a group of fibers that responded to acetylcholine by a twitch and a second group of fibers (the "tonus bundle") in which acetylcholine produced a slow, tonic contraction.

Anatomical studies by Krüger⁴³ and his school uncovered the structural basis for fast and slow fiber systems in striated muscles. He stated that the system giving twitch responses had a *Fibrillenstruktur*, and the system responsible for the slow contractions had a *Felderstruktur*. In the course of time, the two systems have been demonstrated in skeletal muscles of amphibians, reptiles, and birds, but not of mammals. Although Krüger believed that he had found the two systems also in mammalian muscles, most workers agree with Hess³⁷ that *these two systems occur in mammals only in extraocular muscles*, where they have been found in the rabbit,⁴² guinea pig,³⁶ cat,^{18, 38} monkey,^{19, 57} and human.^{10, 28}

The *Fibrillenstruktur* type of the fast fiber system is characterized anatomically by small, well-defined myofibrils, each surrounded by abundant sarcoplasm and having an even, punctate appearance as seen with the light microscope (Fig. 6-1A). Light microscopic and electron microscopic examinations show a well-developed sarcoplasmic reticulum, a regular tubular (T) system in each sarcomere, a straight Z line, and a well-marked M line or thickening of the filaments in the middle of the A band. The nuclei of the fibers are usually located peripherally and are only infrequently centrally located (Figs. 6-2 and 6-3A).

In contrast, slow fibrils of the *Felderstruktur* type are clumped together in a more or less fibrillar-appearing mass of myofilaments with large, partially fused fibrils in scant sarcoplasm (Fig. 6-1B). The sarcoplasmic reticulum is poorly developed; the T system is absent or consists of aberrant elements; the Z line follows a zigzag course; and the M line is absent. Mayr⁵³ considers the presence or absence of the M band as a distinguishing sign between the two fiber types unreliable. The nuclei are located centrally or slightly eccentrically (Fig. 6-3B). The *Felderstruktur* systems stain more deeply than the *Fibrillenstruktur* systems. Peachey⁵⁹ subdivided fiber types according to their electron microscopic characteristics into five groups, and similar classifications have been suggested by others.^{2, 53} Miller⁵⁴ drew attention to the microstructural changes that extraocular muscles undergo with advancing age.

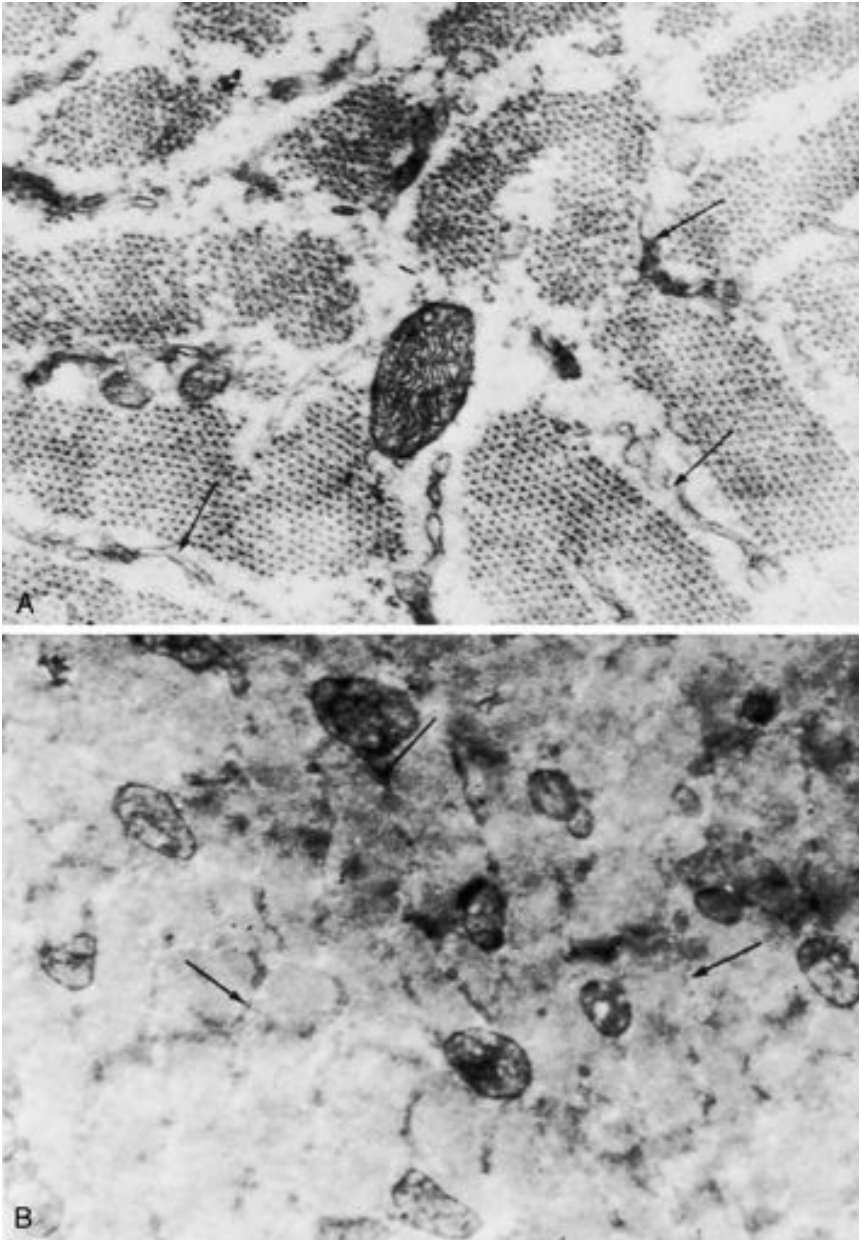


FIGURE 6-1. Transverse section of human inferior oblique muscle. Electron micrographs. *A*, *Fibrillenstruktur* fiber. Numerous elements of sarcoplasmic reticulum (arrows) (X36,000). *B*, *Felderstruktur* fiber. Scattered mitochondria and elements of sarcoplasmic reticulum (arrows) lie in the indistinct mass of myofilaments (X18,00). (From Brandt DE, Leeson CR: Structural differences of fast and slow fibers in human extraocular muscle. *Am J Ophthalmol* 62:478, 1996.)

Fibrillenstruktur fibers are innervated by thick, heavily myelinated nerves joining the muscle fiber with single, typical motor and so-called *en plaque* end plates (Fig. 6-4), showing junctional folds and numerous synaptic vesicles in the terminal axon. Unlike typical skeletal muscle, *Felderstruktur* fibers are innervated by multiple grapelike nerve terminals, so-called *en grappe* endings, derived from efferent nerves of small diameter arranged linearly or in loose collections and scattered throughout the muscle from origin to insertion (see Fig. 6-4). According to Cheng and Breinin,¹⁸ the synaptic membrane of these terminals has only a few rudimentary invaginations and the terminal axon contains granular as well as agranular synaptic vesicles.

With the exception of extraocular muscles, single fibers are innervated by multiple endplates in only two other muscles, the tensor tympani and the stapedius.³⁴ The presence of multiple endplates indicates that the fiber is innervated by either multiple branches from the same nerve or by input from more than one nerve fiber. Although polyneuronal innervation occurs in several types of vertebrate muscles, Bach-y-Rita and Lennerstrand⁷ were not able to demonstrate this function in the extraocular muscles of cats. Lennerstrand⁴⁶ distinguished further between multiple innervated fibers that conduct and those that do not conduct action potentials, but his hypothesis has not been universally accepted.^{15, 53}

The percentage of multiple innervated muscle

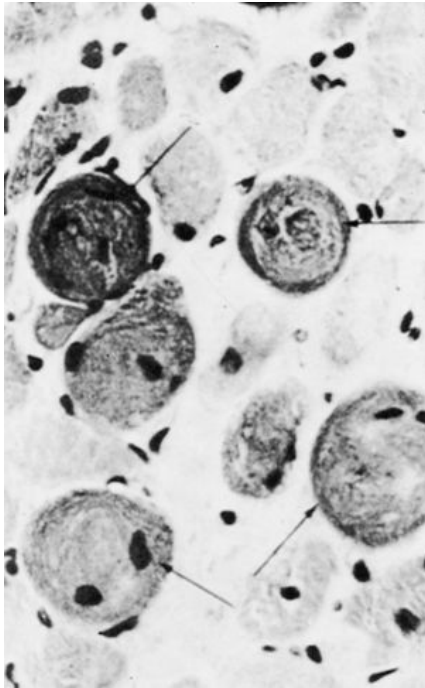


FIGURE 6-2. Transverse section of human inferior oblique muscle showing *Fibrillenstruktur* (arrows) and *Felderstruktur* fibers. (Light micrograph; X400.) Note that the *Felderstruktur* fibers take a much deeper stain. (From Brandt DE, Leeson CR: Structural differences of fast and slow fibers in human extraocular muscle. *Am J Ophthalmol* 62:478, 1996.)

fibers is higher in the orbital region than in the central zone of extraocular muscles and varies with the species.⁵³ However, the fact that both types of fibers are present in the two zones is of considerable importance when attempting to

correlate the structure of the extraocular muscles with their function.

The electron microscopic differences between the fibrillar and field type of fibers emphasize the differences in their functions: the fibrillar type is fast fibers and the field type is slow fibers. The presence of the T system and the abundance of sarcoplasmic reticulum may serve to transmit excitatory impulses with greater rapidity; the large concentration of mitochondria between the fibrils may be related to the considerable oxidative requirements associated with twitch contractions. The virtual absence of the T system and the sparse sarcoplasmic reticulum and mitochondrial concentration may be evidence for the slow, tonic contraction of the field type of fiber structures and their lesser demand for oxidative metabolism. The experimental work of Asmussen and Kiessling⁴ has shown that fast twitch fibers respond to denervation with atrophy and slow twitch fibers with hypertrophy.

Pharmacologic studies of the behavior of extraocular muscles are of particular interest. Kern⁴² showed that the superior rectus muscle of the rabbit consists of two layers, an upper thin layer made up of *Felderstruktur* fibers, and a lower layer, the bulk of the muscle, composed of *Fibrillenstruktur* fibers. Kern was able to separate the two muscle strips. When those of the *Felderstruktur* type were exposed to a low dose of acetylcholine (0.5 $\mu\text{g}/\text{mL}$), a tonic contraction of about 80 mg lasting for more than 6 minutes developed. In contrast, one fifth of the *Fibrillen-*

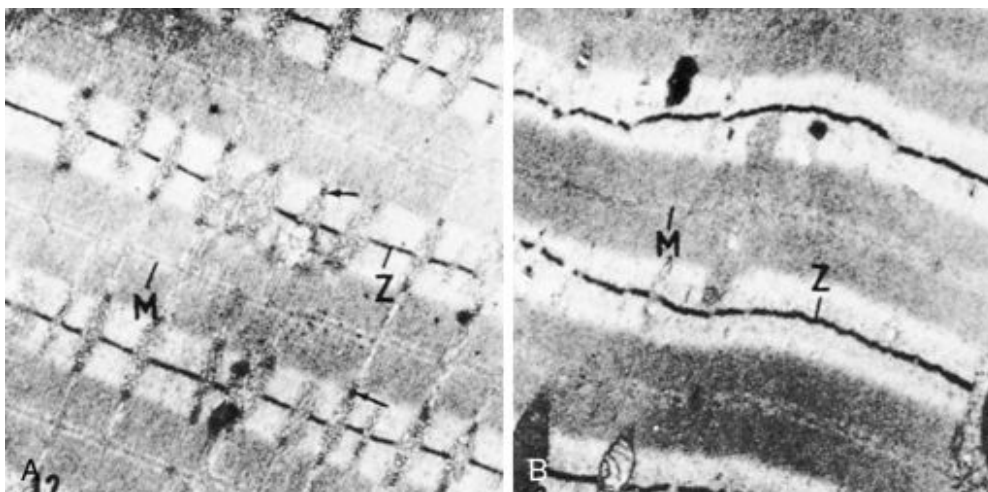


FIGURE 6-3. Longitudinal sections through superior oblique muscle of cat. Electron micrographs. *A*, Fast twitch fiber. Separation of fibrils by sarcoplasmic reticulum; straight M and Z lines; regularly occurring T system (arrows) (X16,000). *B*, Slow twitch fiber. Poor separation of fibrils; sparse sarcoplasmic reticulum; M and Z lines wavy; absent tubular system (X16,000). (From Hess A: The structure of vertebrate slow and fast twitch muscle fibers. *Invest Ophthalmol* 6:217, 1967.)

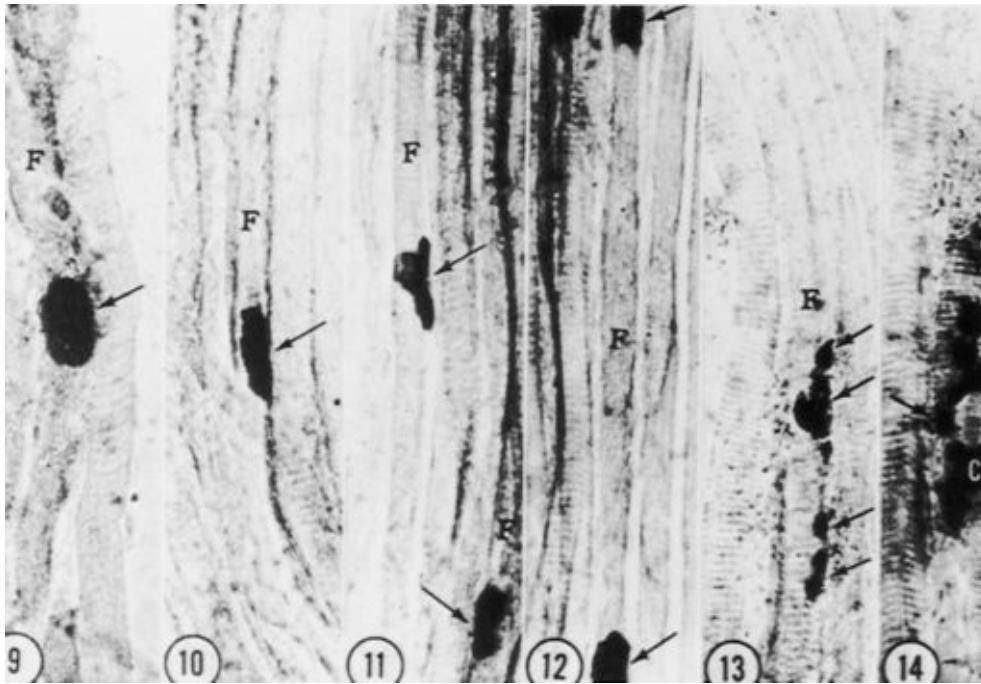


FIGURE 6-4. Simple *en plaque* endings common in muscle fibers (F) of *Fibrillenstruktur* type, 9 to 11. Rare finding of two *en plaque* endings on one muscle fiber, 12. *En grappe* nerve endings commonly found on *Felderstruktur* fibers, 13, 14. (From Dietert SE: The demonstration of different types of muscle fibers in human extraocular muscle by electron microscopy and cholinesterase staining. *Invest Ophthalmol* 4:51, 1965.)

struktur strips did not respond at all to acetylcholine, and only a small response rise in tension was noted in the remaining preparations (Fig. 6-5). This minimal response may be explained by some

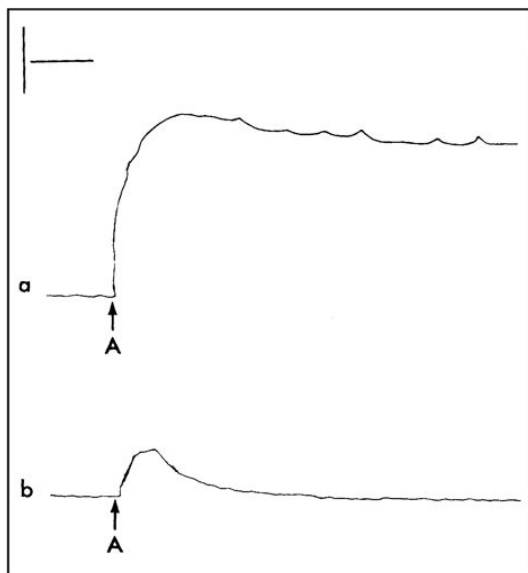


FIGURE 6-5. Response of rabbit's superior rectus muscle to acetylcholine (A). a, response of muscle strip comprising only *Felderstruktur* fibers; b, response of *Fibrillenstruktur* fibers. Calibration 20 mg/min. (From Kern R: A comparative pharmacologic histologic study of slow- and fast-twitch fibers in the superior rectus muscle of the rabbit. *Invest Ophthalmol* 4:901, 1965.)

admixture of slow fibers to the preparation. Increased concentrations of acetylcholine (0.1 to 1.0 $\mu\text{g/mL}$) induced faster and higher rises in both types of preparations. The responses of the *Fibrillenstruktur* strips were proportionately lower than those of the *Felderstruktur* strips and returned rapidly to the baseline level, whereas tensions of the latter strips remained elevated for longer than 10 minutes and returned to the baseline level after the drug was washed out.

The presence of two different fiber systems, a slow and a fast system, was confirmed by Katz and Eakins⁴⁰ in experiments with succinylcholine and other depolarizing agents. These authors found that the initial effect of succinylcholine on the superior rectus muscle of cats was to increase the baseline tension without an effect on the twitch response. The greater the dose of succinylcholine, the greater the rise of the baseline tension. Eventually the twitch response became depressed, and with a dosage of 128 $\mu\text{g/kg}$ of succinylcholine it was abolished (Fig. 6-6). The anterior tibial muscle did not respond with a rise in baseline tension, but its twitch response was abolished with much lower doses of the drug than in the superior rectus muscle.

Katz and Eakins believed that responses of extraocular muscles to succinylcholine and other

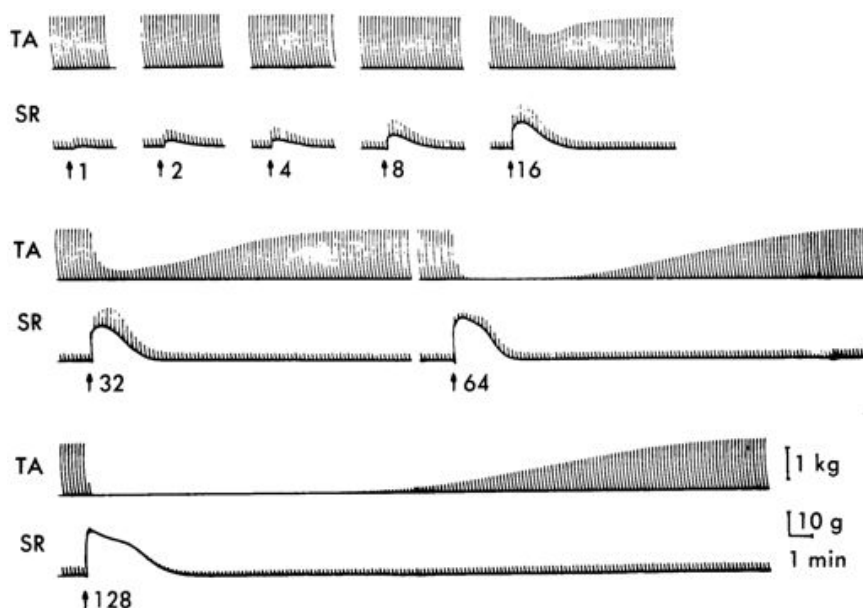


FIGURE 6-6. Response of the superior rectus muscle (SR) and the anterior tibial muscle (TA) of the cat to succinylcholine. (From Katz RL, Eakins KE: Pharmacological studies of extraocular muscles. Invest Ophthalmol 6:261, 1967.)

depolarizing agents found in their experiment are explained by the presence of two neuromuscular systems: the increase in baseline tension is attributable to the tonic (slow) system, and the decrease in twitch response is attributable to the twitch (fast) system.⁴⁰

Although there is abundant ultrastructural and pharmacologic evidence to support the notion of two principal fiber types (slow and fast twitch) in the human extraocular muscle, several authors have proposed classifications that are based on as many as five to six fiber types.^{2, 3, 53} These classifications take into account a much wider range of structural and contractile features for each fiber type than the older studies cited above.

Some reservations may be in order to distinguish muscle fibers exclusively on the basis of their electron microscopic characteristics, since it has been shown that fibers may change back and forth from *Felderstruktur* to *Fibrillenstruktur* along their length.^{25, 58} Brooke and Kaiser¹⁴ introduced a histochemical classification based on the

presence of slightly different isoforms of myosin in various types of slow and fast twitch fibers and more recent research has distinguished fiber types on the basis of immunohistochemical studies, using various antimyosin antibodies.^{62, 65, 75}

The main features distinguishing skeletal from extraocular muscle are summarized in Table 6-1 and the various characteristics of slow and fast fiber types are shown in Table 6-2. The reader is referred to several recent reviews for more detailed information.^{3, 13, 46, 61}

Structural and Functional Correlations

Inferring a correlation between fast fibers and fast eye movements (saccades) and slow fibers and

TABLE 6-1. Comparison of Skeletal and Extraocular Muscle

	Ocular	Skeletal
Fiber diameter	9–17 μm	90–100 μm (gluteus maximus)
Ratio of nerve to muscle fiber	1:1–17	Up to 1:300
Contraction time	Fast	Slow
Acetylcholine sensitivity	High	Low or absent

TABLE 6-2. Characteristics of Slow and Fast Twitch Fibers in Extraocular Muscles

Slow Twitch	Fast Twitch
Thin motor nerve fibers	Thick motor nerve fibers
Multiply innervated (en grappe)	Singly innervated (en plaque)
Large, poorly delineated muscle fibrils (<i>Felderstruktur</i>)	Small, well-delineated muscle fibrils (<i>Fibrillenstruktur</i>)
No conduction of action potential	Conduction of action potential
Slow, sustained contraction (tonic)	Fast contraction (phasic)
Predominantly in orbital layer	Predominantly in central (bulbar) layer

slow eye movements (vergences) is tempting. If this were so, then two separate neural pathways would exist, one for the saccadic and the other for the tonic function, each with its own separate supranuclear component and subnuclei in the oculomotor complex.

Miller⁵⁶ found the outer part of extraocular muscles of rhesus monkeys to consist of fibers with small cells having the histochemical and electromyographic characteristics of red muscles. The central part of these muscles consisted of fibers with large cells having the characteristics of white muscles. An intermediate area between the outer and central zones was made up of a mixture of large and small cells. Miller attributed slow eye movements to the outer red part of the fibers and faster eye movements to the central white part.⁵⁶

However, these notions were dispelled by the findings of Keller and Robinson,⁴¹ which are incompatible with the existence of two muscular systems, one for saccadic and one for tonic function. These authors induced saccadic, pursuit, and vergence movements in alert, unanesthetized monkeys while simultaneously recording the electric responses from cells of the abducens nucleus by means of microelectrodes. All investigated cells responded to all movements; no cells responded selectively. Keller and Robinson concluded that there was a *single common pathway for saccadic, pursuit, and vergence movements*.⁴¹ The undeniable differences in muscle fiber types then would have to be correlated with some other functional differences in the oculomotor system. For example, Keller and Robinson found fibers with a discharge frequency of 150 spikes per second with the eye in primary position, that is, during the entire time the animal was awake. As Björk⁸ had already determined from electromyographic studies, this amounts to an intensity and duration far in excess of that required from other muscle systems. On the other hand, units in which the threshold lies lateral to the primary position are recruited into activity for only brief periods of lateral gaze or during lateral saccades. Their role of intermittent activity is not unlike that of other skeletal muscles. Keller and Robinson conclude that it would be remarkable if such large differences in synaptic transmission and muscle metabolism were not reflected in morphologic differences. This observation by Keller and Robinson might well explain the presence of twitch fibers with different physiologic responses,⁴¹ but one fails to

see how it could account for the difference between fast and slow fibers.

Scott and Collins⁶⁷ and Collins²¹ recorded from slow and fast fibers in the orbital and central layers of human extraocular muscles to analyze their contribution to various types of eye movements. During fixation in different eye positions, the fast fibers are inactive outside the field of action of the muscle. As the muscle approaches its maximal field of action, their activity begins to increase. Conversely, slow fibers are active even in extreme positions of gaze outside the field of action of the muscle. Their activity increases nonlinearly as the eye begins to fixate more and more in the field of action of the muscle. This innervational pattern is similar during slow following movements; however, during fast saccades, both slow and fast fibers are activated maximally during the first phase of the saccades, then begin to decay logarithmically to their new equilibrium with a time constant of about half the duration of the saccade. The work of these investigators leaves little doubt that both slow and fast fibers contribute to tonic and phasic activity but not necessarily simultaneously in the case of tonic activity. Scott and Collins suggested that various muscle fiber types are functionally differentiated by the amount of work they do rather than by the type of eye movement to which they contribute.⁶⁷

One may hope that future work will permit application of laboratory findings in extraocular muscles to the clinical study of strabismus. Extraocular muscles contain different types of muscle fibrils with intricate ultramicroscopic structures and fibers with highly differentiated nerve endings. They are surely there to subservise specific functional needs. This seems more probable when one considers that even such anatomically and embryologically closely related muscles as the levator of the upper lid in humans²⁸ and the retractor bulbi in the rabbit⁴² do not share the peculiarities of extraocular muscles.

There is justification in comparing the action of extraocular muscles with the action of flexor muscles of amphibians. Flexor muscles of frogs contain tonic bundles required for the amplexus. Kuffler and Vaughan Williams⁴⁴ established that slow and fast fibers in these muscles are synergistic, that the state of tension of slow fibers is directly related to stimulus frequency, and that any amount of slow fiber tension could collapse instantly by superimposition of a single twitch

contraction. A comparable phenomenon may take place in extraocular muscles.

Regardless of what future studies may uncover, the uniqueness of the structure and function of extraocular muscles remains unquestionable.²⁸ These muscles have many structural and therefore functional features that are present in some skeletal muscle systems and absent in others which enable them to carry out their complex and highly specialized tasks.

The effect of the autonomous nervous system on extraocular muscles is uncertain because morphologic, pharmacologic, and electrophysiologic studies have produced contradictory results.^{1, 11, 12, 28, 30, 31, 44, 62, 75, 76} *There is no convincing evidence for sympathetic innervation of extraocular muscles.*

Muscle Spindles and Palisade Endings in the Extraocular Muscles

Groups of fine cross-striated fibers with centrally located nuclei surrounded by a thin, torpedo-shaped capsule are found in all skeletal muscles. These so-called muscle spindles are proprioceptive sensory organs. Since publication of the studies by Daniel,²⁴ Cooper and Daniel,²² and others, there is no doubt that human extraocular muscles also contain muscle spindles. The density of these spindles is about the same as in skeletal muscle⁵¹ and their presence is not, as had originally been assumed, age-related.⁹ Whether extraocular muscle spindles are capable of providing proprioceptive information is a subject of debate. In view of distinct histologic differences from spindles found in skeletal muscles,^{51, 63, 64} Ruskell doubts this capacity.⁶⁴ On the other hand, passive stretching of an extraocular muscle causes changes in ocular alignment and lack of pointing accuracy³⁵ and visual illusions can be elicited by muscle vibration.^{73, 74} Lennerstrand and coworkers⁴⁹ reported that vibration-induced eye movements differed in normal and exotropic subjects. Most current research seems to indicate that there may indeed be sensory feedback from muscle spindles even though the role of this inflow under casual conditions of seeing is by no means clear (see also p. 30).

Another possible source of proprioceptive input is the palisade endings, which have been described in the tendinous insertion of human extraocular

muscle.^{61, 68} Lewis and Zee⁵⁰ believe that the tendon organs rather than the muscle spindles are providing feedback as to the position of the eye,⁵² a view that is also shared by Steinbach and Smith⁷¹ and by Richmond and coworkers.⁶¹

The peripheral and central pathways of extraocular muscle proprioception have been defined by Manni and Bortolami,⁵² who showed, on the basis of histologic and electrophysiologic studies, that the perikarya of first-order neurons are located in the semilunar ganglion. Whereas the peripheral nerve process innervates the muscle spindle, the central nerve processes terminate in the ipsilateral portion of the spinal trigeminal nucleus and in the main sensory trigeminal nucleus. Second-order neurons have been identified in these nuclei and project on the cerebellum and the mesodiencephalic areas. These data refer to animal studies and there is no information yet on the route of centripetal information from the extraocular muscles in humans.

The functional significance of the muscle spindles, palisade endings, and other proprioceptive sensors is discussed in Chapter 2. For additional reviews of current theories, see Bach-y-Rita,^{5, 6} Lennerstrand,^{47, 48} and Steinbach.⁷⁰

Electromyography

Electrical responses have been recorded from extraocular muscles of animal eyes for many years. Following Björk's study⁸ of electromyography of human eyes in 1952 and subsequent elaboration by a number of researchers, important contributions have been made toward understanding of the function of extraocular muscles in normal and pathologic states. Basically, electromyography consists of oscilloscopic recording of suitably amplified electrical activities of a muscle. Monopolar or bipolar electrodes are inserted into the muscle to record the current. The electrodes are placed extracellularly. This basic technique may be highly refined by use of various electronic components for integration, analysis, and storage of responses.

Extraocular muscles are especially interesting to those engaged in electromyographic studies because of their low nerve fiber-to-muscle fiber ratio. The *anatomical motor unit* consists of the neuron cell body, its axon, and the muscle fibers innervated by that axon. All these fibers discharge synchronously when the axon is stimulated. The integrated voltage of this discharge constitutes the

electric motor unit. Since only a few fibers of an extraocular muscle are innervated by one axon, electromyography comes close to recording the electrical activity of a single anatomical motor neuron in such a muscle.

Electromyography has proved to be of value in assessing paretic and pseudoparetic conditions of extraocular muscles, in myopathies, and in elucidating the pathophysiology of the retraction syndrome (see Chapter 21). *No specific abnormalities are revealed in patients with comitant strabismus.*⁸ Great difficulties are encountered in quantifying electromyograms.¹² The smallest movement distinguishable by means of ocular electromyography is about 5°. All this puts limitations on the use of electromyography in studying the physiology of the motor functions of the eyes. It should be noted that the applicability of electromyography is, for technical reasons, limited. The introduction of electrodes into the muscles is easy only for rectus muscles, although some discomfort is always part of this procedure. The insertion of electrodes into the oblique muscle is far more difficult. Generally, no more than two muscles in each eye can be studied simultaneously. Multichannel recordings have recently been obtained after insertion of electrodes into the muscles during surgical procedures. The recordings were performed days after surgery and without discomfort to the patient, after which the electrodes simply pulled out of the muscle.¹⁷ This approach may hopefully provide better information on electrical activity of the extraocular muscles.

Despite these limitations electromyography has resulted in important contributions to the kinesiology of extraocular muscles. In essence, electromyographic studies have given incontrovertible proof for certain basic facts that were known, or assumed to be known, from physiologic or clinical experience. The contributions of electromyography to the anomalies of ocular movements are discussed in the appropriate place in various chapters dealing with these anomalies.

Electromyographically, there is no “rest” of the extraocular muscles (and no “position of rest” of the eyes). In primary position and with the eyes grossly fixed, extraocular muscles are never electrically silent but manifest a tonic activity. Complete inactivity of electrical discharge in extraocular muscles is encountered only in deep sleep or deep anesthesia.

When a muscle rotates an eye into its field of action, there is an increment of electrical activity accompanied by graded inhibition of the activity of the direct antagonist (Sherrington’s law of reciprocal innervation). Similarly, in extreme gaze to the right, the left medial rectus fires maximally while the left lateral rectus is electrically silent. The opposite is true in extreme gaze to the left (Fig. 6–7). Figure 6–7 also shows that in a waking person a muscle may be electrically silent only when in extreme positions out of its field of action. Whenever an eye diverges, an increment in the electrical activity occurs in the lateral rectus muscle. For the electromyographic behavior of extra-



FIGURE 6–7. Simultaneous electromyograms of the four rectus muscles. Note the graded increase in electrical activity in the right medial (RMR) and left lateral rectus (LLR) muscles with corresponding decrease in activity all the way to zero in the right lateral (RLR) and left medial rectus (LMR) muscles as the eyes perform a levoversion movement. With return to the primary position the RLR and LMR resume their activity and increase it in the ensuing dextroversion while the activity in the RMR and LLR decreases. (Courtesy of Prof. Alfred Huber, Zurich.)

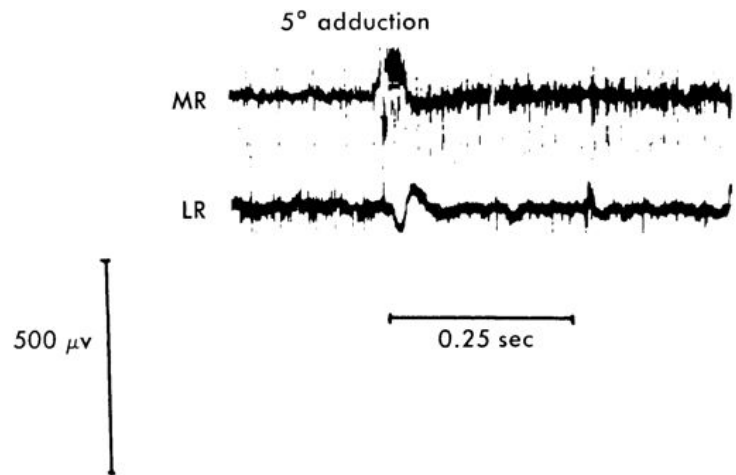


FIGURE 6–8. Electromyogram of saccadic movement showing saccadic burst in the agonistic medial rectus muscle. (Courtesy of Dr. James E. Miller, St. Louis.)

ocular muscles in vergences and a discussion surrounding it, see Chapter 4.

Saccadic movements differ from vergence movements in their innervational pattern. Miller⁵⁵ found that they are initiated by a sudden burst of motor unit activity of the agonist with corresponding inhibition in the antagonist (Fig. 6–8). The duration of the initial burst is proportional to the extent of the movement (30 ms for a 2.5° movement to 150 ms for a 40° movement).

This initial burst is followed immediately by an orderly series of uniformly firing motor units. The firing rate of the motor unit depends on the angular displacement from primary position. Large movements (15° to 20°) cause a second or third saccadic burst representing efforts to overcome a lag in fixation. These findings are in accord with those made by optical and electro-oculographic recordings of eye movements.

Sources of Tonus of the Extraocular Muscles

The presence of fast and slow fibers in extraocular muscles and their electrophysiologic characteristics and pharmacologic properties provide evidence for some of the peripheral mechanisms that contribute to the tonus of these muscles. This exciting new knowledge must not obscure the fact that the tonus of extraocular muscles is basically regulated by neural influences.

Neurophysiologists have established that there are differences in the frequency of firing of motor neurons innervating slow and fast muscles in the hind limbs of cats and other experimental animals. Buller and coworkers¹⁶ stated that the shorter

afterpolarization of motor neurons supplying fast muscles³² permits fast frequency of firing and is appropriately related to the contraction time of muscles. As a consequence, motor neurons with larger afterhyperpolarization have frequencies of discharge appropriate to the slow muscles they innervate. Buller and coworkers also made the observation in cross-union experiments that when a nerve from a fast motor neuron is made to innervate a slow muscle, the muscle is transformed into a fast muscle; slow or tonic motor neurons, similarly transferred, convert fast muscles into slow.¹⁶ No corresponding observations exist for extraocular muscles or other muscles innervated by cranial nerves.

Irrespective of peripheral mechanisms, the most important source of tonus of extraocular muscles is reflex in origin. A certain tonus within the central nervous system is kept up by stimuli from sensory sources. Light itself is a powerful source of tonus. In adult humans, reflex tonus from neck muscles appears to be of minor importance. All the more important are reflexes resulting from vestibular stimulations. These stimulations to a large degree control the position of the eyes in space. They are active when the head is erect, and they also regulate the position of the eyes with every movement of the head.

In humans, with their highly developed binocular vision, however, the most powerful tonic impulses flow from the process of vision. Psycho-optical reflexes have superseded in importance such unconditioned reflexes as those that arise from proprioception and the vestibular system. In uniocular and binocular vision, these impulses produce the fixation reflex. In binocular vision, disparate stimulation elicits fusional movements

and maintains the proper relative position of the eyes.

REFERENCES

- Alpern M, Wolter JR: The relation of horizontal saccadic and vergence movements. *Arch Ophthalmol* 56:685, 1956.
- Alvarado J, Van Horn C: Muscle cell types of the cat inferior oblique. In Lennerstrand G, Bach-y-Rita P, eds: *Basic Mechanisms of Ocular Motility and Their Clinical Implications*. New York, Pergamon Press, 1975, p 15.
- Asmussen G: Functional morphology and physiology of the eye muscles. In Kaufmann H, ed: *Transactions of the 16th Meeting of the European Strabismological Association*, Giessen, Germany, Sept 18, 1987, p 11.
- Asmussen G, Kiessling A: Hypertrophy and atrophy of mammalian extraocular muscle fibres following denervation. *Experientia* 31:1186, 1975.
- Bach-y-Rita P: Neurophysiology of eye movements. In Bach-y-Rita P, Collins CC, eds: *Control of the Eye Movements*. New York, Academic Press, 1971, p 7.
- Bach-y-Rita P: Structural-functional correlations in eye muscle fibers. In Lennerstrand G., Bach-y-Rita P, eds: *Basic Mechanisms of Ocular Motility and Their Clinical Implications*. New York, Pergamon Press, 1975, p 91.
- Bach-y-Rita P, Lennerstrand G: Absence of polyneuronal innervation in cat extraocular muscles. *J Physiol* 244:613, 1975.
- Björk A: Electrical activity of human extrinsic eye muscles. *Experientia* 8:226, 1952.
- Blumer R, Lukas JR, Aigner M, et al: Fine structural analysis of extraocular muscle spindles of a two-year-old infant. *Invest Ophthalmol Vis Sci* 40:55, 1999.
- Brandt DE, Leeson CR: Structural differences of fast and slow fibers in human extraocular muscle. *Am J Ophthalmol* 62:478, 1966.
- Brecher GA, Mitchell WG: Studies on the role of the sympathetic nervous stimulations in extraocular muscle movements. *Am J Ophthalmol* 44(4, pt 2):144, 1957.
- Breinin GM: *The Electrophysiology of Extraocular Muscle, with Special Reference to Electromyography*. Toronto, University of Toronto Press, 1962.
- Breinin GM: The structure and function of extraocular muscle—an appraisal of the duality concept. The Gifford Memorial Lecture. *Am J Ophthalmol* 72:1, 1971.
- Brooke MH, Kaiser KK: Muscle fiber types: how many and what kind? *Arch Neurol* 23:369, 1970.
- Browne JS: The contractile properties of slow muscle fibers in cat extraocular muscles. *J Gen Physiol* 49:1177, 1966.
- Buller AJ, Eccles JC, Eccles RM: Interactions between motoneurons and muscle in respect to the characteristic speeds of their responses. *J Physiol (Lond)* 150:417, 1960.
- Campos EC, Bolzani R, Schiavi C, et al: Technique of simultaneous recording of EMG from various extraocular muscles under EOG control. *Graefes Arch Clin Exp Ophthalmol* 233:371, 1995.
- Cheng K, Breinin GM: Fine structure of nerve endings in extraocular muscle. *Arch Ophthalmol* 74:822, 1965.
- Cheng K, Breinin GM: A comparison of the fine structure of extraocular and interosseous muscles in the monkey. *Invest Ophthalmol* 5:535, 1966.
- Chiarandini DJ: Activation of two types of fibers in rat extraocular muscles. *J Physiol (Lond)* 259:299, 1976.
- Collins CC: The human oculomotor control. In Lennerstrand G, Bach-y-Rita P, eds: *Basic Mechanisms of Ocular Motility and Their Clinical Implications*. New York, Pergamon Press, 1975, p 15.
- Cooper S, Daniel PM: Muscle spindles in human extrinsic eye muscles. *Brain* 72:1, 1949.
- Cooper S, Eccles JC: The isometric responses of mammalian muscles. *J Physiol (Lond)* 69:377, 1930.
- Daniel P: Spiral nerve endings in the extrinsic eye muscles of man. *J Anat* 80:189, 1946.
- Davidowitz J, Chiarandini DJ, Philips G, et al: Morphological variation along multiply innervated fibers of rat extraocular muscles. In Lennerstrand G, Zee DS, Keller EL, eds: *Functional Basis of Ocular Motility Disorders*. Oxford, Pergamon Press, 1982, p 17.
- Demer JL, Oh SY, Poukens V: Evidence of active control of rectus extraocular muscle pulleys. *Invest Ophthalmol Vis Sci* 131:448, 2000.
- Denny-Brown D: The histological features of striped muscle in relation to its functional activity. *Proc R Soc Lond B Biol Sci* 104:252, 1929.
- Dietert SE: The demonstration of different types of muscle fibers in human extraocular muscle by electron microscopy and cholinesterase staining. *Invest Ophthalmol* 4:51, 1965.
- Duke-Elder S: *Textbook of Ophthalmology*, vol 1. St Louis, Mosby-Year Book, 1946, p 171.
- Duke-Elder S, Duke-Elder PM: The contraction of the extrinsic muscles of the eyes by choline and nicotine. *Proc R Soc Lond B Biol Sci* 107:332, 1930.
- Eakins KE, Katz RL: The role of the autonomic nervous system in extraocular muscle function. *Invest Ophthalmol* 6:253, 1967.
- Eccles JC, Eccles RM, Lundberg A: The action potentials of the alpha motoneurons supplying fast and slow muscles. *J Physiol (Lond)* 142:275, 1958.
- Eisler P: *Die Anatomie des menschlichen Auges*. In Schieck F, Brückner A, eds: *Kurzes Handbuch der Ophthalmologie*, vol 1. Berlin, Springer-Verlag, 1930, p 208.
- Ferdinand VS, Hess A: The occurrence, structure, and innervation of slow and twitch muscle fibres in the tensor tympani and stapedius of the cat. *J Physiol (Lond)* 200:547, 1969.
- Han Y, Lennerstrand G: Eye movements in normal subjects induced by vibratory activation of neck muscle proprioceptors. *Acta Ophthalmol Scand* 73:414, 1995.
- Hess A: The structure of slow and fast extrafusar muscle fibers in the extraocular muscles and their nerve endings in guinea pigs. *J Cell Physiol* 58:63, 1961.
- Hess A: The structure of vertebrate slow and twitch muscle fibers. *Invest Ophthalmol* 6:217, 1967.
- Hess A, Pilar G: Slow fibres in the extraocular muscles of the cat. *J Physiol (Lond)* 169:780, 1963.
- Kato T: *Ueber histologische Untersuchungen der Augenmuskeln von Menschen und Säugetieren*. *Okajimas Folia Anat Jpn* 16:131, 1938.
- Katz RL, Eakins KE: Pharmacological studies of extraocular muscles. *Invest Ophthalmol* 6:261, 1967.
- Keller EL, Robinson DA: Abducens unit behavior in the monkey during vergence movements. *Vision Res* 12:369, 1972.
- Kern R: A comparative pharmacologic histologic study of slow and fast-twitch fibers in the superior rectus muscle of the rabbit. *Invest Ophthalmol* 4:901, 1965.
- Krüger P: *Die Innervation der tetanischen und tonischen Fasern der quergestreiften Skelettmuskulatur der Wirbeltiere*. *Anat Anz*. 97:169, 1949.
- Kuffler SW, Vaughan Williams EM: Properties of the "slow" skeletal muscle fibers of the frog. *J Physiol (Lond)* 121:318, 1953.
- Lancaster WB: The "all-or-nothing" principle of nerve conduction and muscle contraction applied to eyes. *Trans Section Ophthalmol AMA* 1923, p 107.
- Lennerstrand G: Motor units in eye muscles. In Lennerstrand G, Bach-y-Rita P, eds: *Basic Mechanisms of Ocular Motility and Their Clinical Implications*. New York, Pergamon Press, 1975, p 119.

47. Lennerstrand G: Motor and sensory functions of normal and strabismic extraocular muscle. In Lennerstrand G, Noorden GK von, Campos E, eds: *Strabismus and Amblyopia. Experimental Basis for Advances in Clinical Management*. London, Macmillan, 1988, p 47.
48. Lennerstrand G, Tian S, Hang Y: Functional properties of human eye muscles. Motor and sensory adaptations to strabismus. In Lennerstrand G, Ygge J, eds: *Advances in Strabismus Research. Basic and Clinical Aspects*. Wenner-Gren International Symposium Series. London, Portland Press, 2000, p 3.
49. Lennerstrand G, Tian S, Han Y: Effects of eye proprioceptive activation on eye position in normal and exotropic subjects. *Graefes Arch Clin Exp Ophthalmol* 235:63, 1997.
50. Lewis RF, Zee DS: Abnormal spatial localization with trigeminal-oculomotor synkinesis. *Brain* 116:1105, 1993.
51. Lukas JR, Aigner M, Blumer R, et al: Number and distribution of neuromuscular spindles in human extraocular muscles. *Invest Ophthalmol Vis Sci* 35:4317, 1994.
52. Manni E, Bortolami R: Proprioception in eye muscles. In Zee DS, Keller EL, eds: *Functional Basis of Ocular Motility Disorders*. New York, Pergamon Press, 1982, p 55.
53. Mayr R: Funktionelle Morphologie der Augenmuskeln. In Kommerell G, ed: *Augenbewegungsstörungen. Neurophysiologie und Klinik*. Munich, JF Bergmann, 1978, p 1.
54. Müller J: Aging changes in extraocular muscles. In Lennerstrand G, Bach-y-Rita P, eds: *Basic Mechanisms of Ocular Motility and Their Clinical Implications*. New York, Pergamon Press, 1975, p 47.
55. Miller JE: Electromyographic pattern of saccadic eye movements. *Am J Ophthalmol* 46 (pt 2):183, 1958.
56. Miller JE: Cellular organization of rhesus extraocular muscle. *Invest Ophthalmol* 6:18, 1967.
57. Mühlendyck H: Die Grösse der motorischen Einheiten der unterschiedlich innervierten Augenmuskelfasern. In Kommerell G, ed: *Augenbewegungsstörungen. Neurophysiologie und Klinik*. Munich, JF Bergmann, 1978, p 17.
58. Pachter BR: Fiber composition of the superior rectus extraocular muscle of the Rhesus monkey. *J Morphol* 174:237, 1982.
59. Peachey L: The structure of the extraocular muscle fibers of mammals. In Bach-y-Rita P, Collins C, Hyde J, eds: *The Control of Eye Movements*. New York, Academic Press, 1971, p 47.
60. Rehms J: Contribution a l'étude des muscles privilégiés quant à l'oxygène disponible. *Arch Int Pharmacol* 8:203, 1901.
61. Richmond FJ, Johnston WS, Baker RS, et al: Palisade endings in human extraocular muscles. *Invest Ophthalmol Vis Sci* 25:471, 1984.
62. Rowleron AM: Fibre types in extraocular muscles. In Kaufmann H, ed: *Transactions of the 16th Meeting of the European Strabismological Association*, Giessen, Germany, Sept 18, 1987, p 19.
63. Ruskell GL: The fine structure of human extraocular muscle spindles and their potential proprioceptive capacity. *J Anat* 167:199, 1989.
64. Ruskell GL: Extraocular muscle proprioceptors and proprioception. *Prog Retina Eye Res* 18:269, 1999.
65. Sartore S, Mascarello F, Rowleron A, et al: Fibre types in extraocular muscle: A new myosin isoform in the fast fibres. *J Muscle Res Cell Motil* 8:161, 1987.
66. Schiefferdecker P, quoted by Eisler P: *Die Anatomie des menschlichen Auges*. In Schieck F, Brückner A, eds: *Kurzes Handbuch der Ophthalmologie*, vol 1. Berlin, Springer-Verlag, 1930.
67. Scott AB, Collins CC: Division of labor in human extraocular muscle. *Arch Ophthalmol* 90:319, 1973.
68. Sodi A, Corsi M, Faussone-Pellegrini MS, et al: Fine structure of the receptors of the myotendinous junction of human extraocular muscles. *Histol Histopathol* 3:103, 1988.
69. Sommerkamp H: Das Substrat der Dauerverkürzung am Froschmuskel. *Arch Exp Pathol Pharmacol* 128:99, 1928.
70. Steinbach MJ: The palisade ending: An afferent source for eye position in humans. In Lennerstrand G, Ygge J, eds: *Advances in Strabismus Research. Basic and Clinical Aspects*. Wenner-Gren International Symposium Series. London, Portland Press, 2000, p 4.
71. Steinbach MJ, Smith DR: Spatial localization after strabismus surgery: Evidence of inflow. *Science* 212:1407, 1981.
72. Sunderland S: A preliminary note on the presence of neuromuscular spindles in the extrinsic ocular muscles in man. *Anat Rec* 103:561, 1949.
73. Velay JL, Allin F, Bouquerel A: Motor and perceptual responses to horizontal and vertical eye vibration in humans. *Vision Res* 37:2631, 1997.
74. Velay JL, Roll R, Lennerstrand G, et al: Eye proprioception and visual localization in humans: Influence of ocular dominance and visual context. *Vision Res* 34:2169, 1994.
75. Wiczorek DF, Periasamy M, Butler-Browne GS, et al: Co-expression of multiple myosin heavy chain genes, in addition to a tissue-specific one, in extraocular musculature. *J Cell Biol* 101:618, 1985.
76. Woollard HH: The innervation of the ocular muscles and the mesencephalic root of the fifth nerve. *Trans Ophthalmol Soc UK* 57:84, 1937.

Visual Acuity, Geometric Optical Effects of Spectacles, and Aniseikonia

Visual Acuity

Basic Physiologic Concepts

Before discussing the clinical assessment of visual acuity in Chapter 11, certain theoretical considerations are in order. Visual acuity is a highly complex function that consists of (1) the minimum visible, (2) the minimum separable (hyperacuity), and (3) the minimum resolvable (ordinary visual acuity).

The *minimum visible* is concerned with detection of the presence or absence of a visual stimulus. Its threshold value is only 1 second of arc; however, Westheimer³⁹ pointed out that the minimum visible is a brightness rather than a spatial-visual threshold function.

The *minimum separable* concerns the judgment of the location of a visual target, usually relative to another element of the same target. The best-known example is Vernier acuity, that is, the ability to detect minimal differences in the horizontal alignment of two vertical lines. The threshold of the minimum separable in normal observers is only 2 to 10 seconds of arc.⁴⁰ In view of this extraordinary sensitivity, the term *hyperacuity*, frequently used as a synonym for the minimum separable, seems appropriate.

More familiar to the clinician and therefore occasionally referred to as “ordinary visual acuity” is the *minimum resolvable*, that is, the ability to determine the presence of or to distinguish between more than one identifying feature in a visible target.³⁹ The threshold of the minimum resolvable is between 30 seconds and 1 minute of arc.

When one tests visual acuity with Snellen letters or number charts, picture charts, Landolt rings, or the illiterate E, the patient is asked to name the test objects or to specify a critical part of them. All these tests are designed to present an object or a series of objects with a critical dimension of 1 minute of arc when viewed from a standard distance (generally 6 m or 20 ft). Patients unable to recognize these objects at the standard distance are tested with increasingly larger objects that have a critical dimension of 1 minute of arc at greater distances (e.g., from 12 m, 15 m, or 60 m). An eye with substandard vision is then said to have a visual acuity of 6/12, 6/15, or 6/60. Many people have better than standard vision in at least one eye, for example, a vision of 6/4.5 or 6/3, which indicates that they are able to recognize objects which from the standard distance have critical dimensions smaller than 1 minute of arc. It is better therefore not to speak of 6/6 vision

as normal but rather as *standard vision*. Also, recognition improves when the subject is allowed to use both eyes. Binocular visual acuity, as determined in clinical tests, is better than monocular visual acuity. The reasons for this are complex and not well understood.

The recognition task is highly involved and undoubtedly is composed of resolution and localization, without which there could be no recognition. Recognition and naming are higher visual functions that bring into effect other variables, such as the ease with which certain numbers or letters are recognized. The picture charts used for the visual screening of preliterate or illiterate patients have to be designed by keeping cultural and geographic differences in mind. Once, while visiting a visual screening station in a remote part of Central Africa one of us (GKvN) observed children and adults staring in frustration at preliterate test charts used by the health workers and depicting objects familiar to every child in the United States, such as birthday cakes, Christmas trees, and houses, none of which were known by those to be screened. Clearly, the objects to be depicted have to be familiar to be identified. On the other hand, identification of a familiar object becomes possible even if only parts thereof are seen because higher integration functions defined as gestalt are involved in the recognition process. Ideally, stimuli should be used which are void of any meaning, such as Landolt Cs or illiterate Es.

The basis for the resolving power of the eye is generally assumed to be the structure of the retinal mosaic. It is not necessary to consider whether the dimensions of the retinal mosaic or the optical aberrations of the eye are the limiting factor of visual acuity and how higher visual acuities, such as those obtained by the Vernier method, come about. The reader is only reminded that the cones are thinnest and most densely packed in the rod-free area of the fovea, which has a diameter of about 1.7° , and that the cones in that area, each of which has a separate nerve fiber, have an average width of 2.5μ . These facts are recalled because the thought has been expressed that some of the properties of the fovea of amblyopic eyes might be accounted for by the encroachment of rods into the cone-free area.

Variables Affecting Visual Acuity

Numerous variables affect visual acuity, but only some of them will be discussed here. For a more complete discussion, see that of Westheimer.⁴⁰

RETINAL ECCENTRICITY. That visual acuity depends on the location of the retinal stimulus and decreases sharply with an increase in distance of the image of an object from the center of the fovea is well-known. Some quantitative information on this subject must be given since it has an important bearing on the clinical and theoretical aspects of amblyopia (eccentric fixation) (see Chapter 14).

The most frequently quoted work is that of Wertheim,³⁸ whose number for the decrease in visual acuity in the horizontal meridian (Fig. 7-1) is the one generally reproduced. The number shows that visual acuity is reduced to 6/12 at 2.5° and to 6/30 at 10° on the nasal side of the fovea. On the temporal side visual acuity decreases somewhat more rapidly. Of special importance is Wertheim's observation that it decreases more sharply below and, especially, above the fovea, so that lines connecting points of equal visual acuity are elliptic, paralleling the outer margins of the visual field. Later studies have given more detailed information about reduction in visual acuity in the region from the center to 10° from the fovea²⁶ (Figs. 7-2 and 7-3). Peripheral visual acuity declines with advancing age.¹⁴

A decrease in visual acuity from the center to the periphery must be related in some way to the retinal mosaic. Ludvigh's data²⁶ (see Fig. 7-3) indicate that the visual acuity curve does not parallel linear or areal density of cones from center to periphery. Weymouth⁴² made the intriguing and reasonable suggestion that the resolving power of a retinal area depends not on the number of cones present but on the number of perceptual units in that area. It is generally believed that the number of receptors connected by a single fiber to the brain defines the extent of a sensory unit.³¹ The ganglion cells are the cells of origin of the optic nerve fibers. Weymouth, who proposed that the density of ganglion cells rather than that of the cones should be related to the minimal angle of resolution, showed that this minimal angle of resolution, the reciprocal of visual acuity, was linearly related to the distance from the fovea. He also found a linear relationship between the density of the ganglion cells and their distance from the fovea.

LUMINANCE AND STATE OF ADAPTATION. The effect of luminance on visual acuity has been well summarized by Riggs,³³ who stated that visual acuity is poor at scotopic levels where parafoveal or peripheral rod receptors predominate. As the

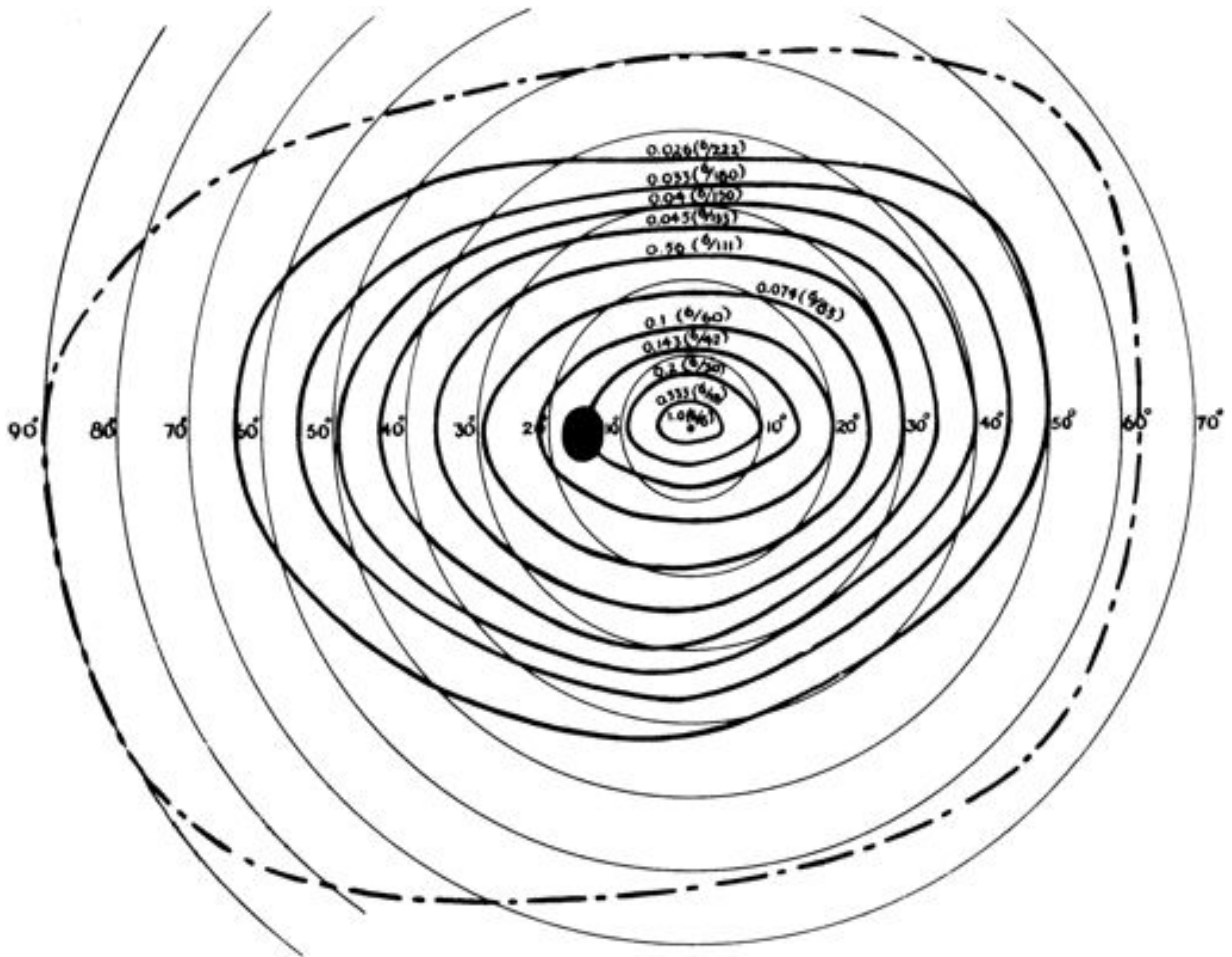


FIGURE 7-1. Visual acuity of the retinal periphery. Continuous black lines indicate points of equal visual acuity. Note that the gradient of visual acuity is steepest in the upper half of the retina. The decline in acuity with eccentricity is least on the temporal side. The broken line indicates the peripheral limits of the visual field. (Data from Wertheim T: *Über die indirekte Sehschärfe*. *Z Psychol Physiol Sinnesor* 7:172, 1894; modified from Hofmann FB: *Die Lehre vom Raumsinn*. In Axenfeld T, Elschnig A, eds: *Graefe-Saemisch Handbuch der gesamten Augenheilkunde*, ed 3, vol 3. Berlin, Springer-Verlag, 1925.)

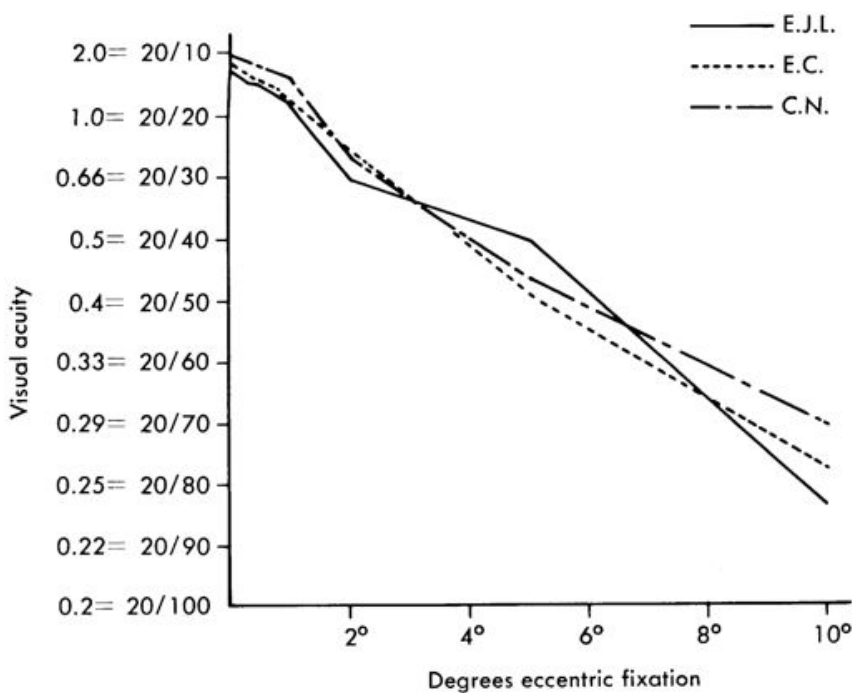


FIGURE 7-2. Decrease in visual acuity for three subjects from the fovea to 10° eccentrically. (From Ludvig E: *Extrafoveal visual acuity as measured with Snellen test letters*. *Arch Ophthalmol* 25:469, 1941.)

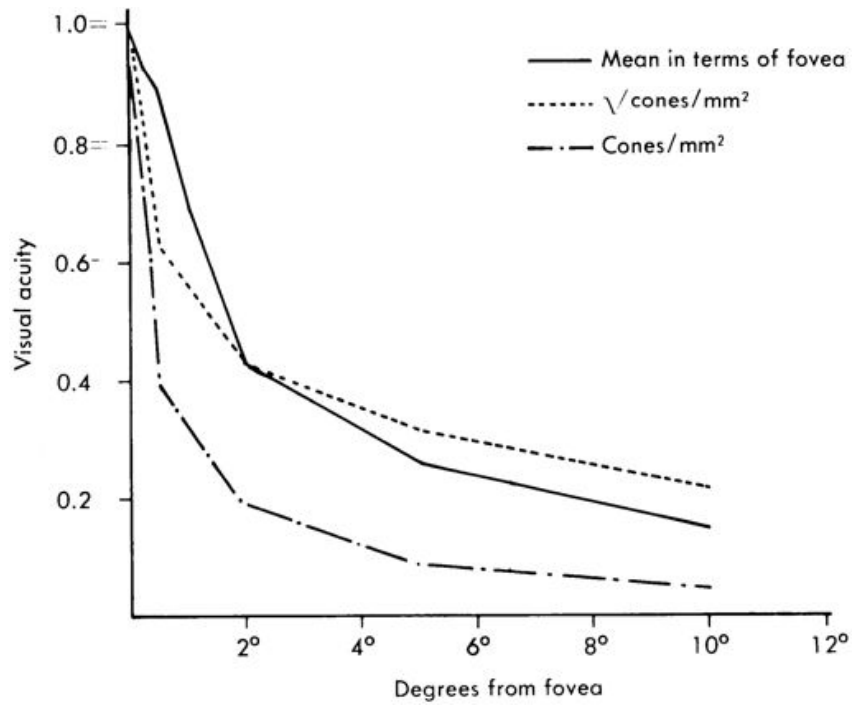


FIGURE 7-3. Data indicating that the decrease in visual acuity from the fovea to 10° eccentrically (*solid line*) does not parallel the linear (*broken line*) or areal (*dotted line*) density of the cones. (From Ludwig E: Extrafoveal visual acuity as measured with Snellen test letters. Arch Ophthalmol 25:469, 1941.)

level of intensity is raised, thresholds of the cone receptors are exceeded and acuity rises steeply. With a further increase in intensity, this maximum acuity is maintained over a wide range of increas-

ing intensities. This is, in fact, a description of the classic curve of König for the relation between visual acuity and intensity, which uses objects on a white background (Fig. 7-4).

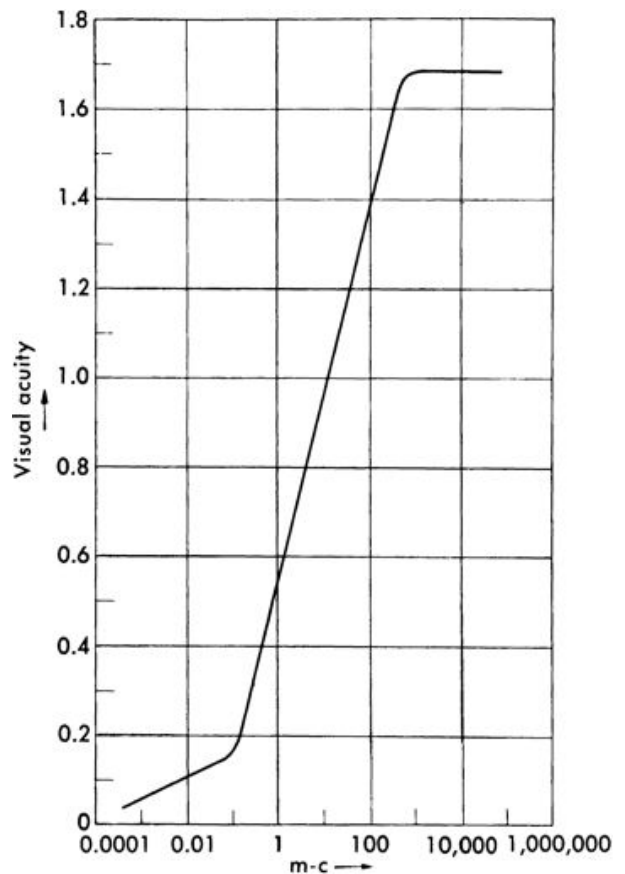


FIGURE 7-4. Curve of König showing relationship of visual acuity and luminance. The ordinate is in meter candles (m · c).

The pupil size is also involved in the effect of luminance on visual acuity. A large pupil allows more light to enter the eye but increases the effect of the optical aberrations. These aberrations are minimized with a small pupil, but a very narrow pupil reduces visual acuity by markedly reducing retinal illuminance and by increasing the effect of light diffraction. Generally speaking, visual acuity is optimal with an intermediate-size pupil of about 2 mm, but the optimal size varies with conditions of luminance, size of test object, and other factors.

CONTRAST. In the discussion of contrast effects, two concepts must be differentiated. The *objective or photometric contrast* refers to differences in luminance of adjacent fields or objects. The *subjective or physiologic contrast* refers to such subjective phenomena as the change in apparent brightness of objects of a given luminance, which depends on the luminance of the surround. In general, the visual acuity decreases with reduction in objective contrast, this effect being more pronounced the smaller the test object.

The effect of subjective contrast is of greatest importance for vision. The borderline between a bright and dark surface produces a blurred, unfocused retinal image caused by the optical aberrations of the eye and the veiling effect of stray light. These effects are offset by subjective contrast. The image of a white field appears whiter, the image of a dark field darker, and the borderline sharp when the two border on each other. Tschermak-Seysenegg³⁷ stated that without the subjective contrast phenomenon one would be unable to read. Ludvig,²⁷ showed that with low degrees of contrast, visual acuity varies markedly; but at high contrast levels, relatively great changes in photometric contrasts have little effect on visual acuity.

The mechanisms underlying subjective contrast have been and continue to be a matter of controversy. Helmholtz,²¹ and others after him thought of contrast as dependent on a judgment of relative brightness, thus making it the result of highest nervous system activity. Hering²² considered contrast to be a physiologic change in sensation in the sense that the sensation of brightness depends on the interplay between the illuminances of a given retinal area and its surround. The electrophysiologic findings of Hartline²⁰ on the lateral inhibition in the *Limulus* eye and of Kuffler²⁵ on retinal receptor fields, as well as the psychophysical studies by Harms and Aulhorn,¹⁹ established that sensitivity to each side of adjacent fields of different retinal illuminance is reduced, pointing

to the physiologic mechanisms that may underlie subjective contrast.

EYE MOVEMENTS. The eyes are never completely motionless, even with a strenuous effort at steady fixation (see Chapter 4). These miniature fixation movements may have the effect of blurring or “smearing” the retinal image, just as the motion of an object or of a camera may produce a blurred photographic picture. They also may have the opposite effect of enhancing the neuronal activity on which visual acuity depends by allowing retinal receptors to scan the contours of an object.³³

Riggs and coworkers³⁴ showed that there is no evidence to prove that eye movements serve to improve visual acuity. Ratliff³² determined the instantaneous value of visual acuity by presenting a grating test object for 75 ms and simultaneously recording the eye movements for an interval beginning before the test exposure and ending after it. The involuntary drifts of the visual axis were clearly a hindrance, and the rapid tremors were detrimental to visual acuity. No evidence was found that scanning the retinal image contributed to visual resolution, as has been postulated by some investigators.^{3, 43}

Whether miniature eye movements have evolved to counteract image fading (Troxler effect)²³ or whether they are simply the expression of random noise in the eye movement control system is not clear.¹³

CONTOUR INTERACTION. Visual acuity can be reduced by the spatial arrangement of additional contours in the field of vision in amblyopic patients (see Chapter 14). Flom and coworkers¹⁸ investigated this phenomenon in normal subjects and pointed out that it is related to the size of the receptive field associated with the retinal region used to fixate the target. Contour interaction is not limited to ordinary visual acuity but also interferes with Vernier acuity⁴¹ and stereoacuity.¹² It is highly exaggerated in amblyopia where it causes the crowding phenomenon (see Chapter 14). Thus the spacing of optotypes on acuity charts must not be left to chance, in which case visual acuity will differ depending on which chart has been used. Rather, the spacing between letters and lines should be related to the letter size.

Geometric-Optical Effects of Spectacles

Whenever eyeglasses are worn, a series of far-reaching visual changes are introduced. These ef-

fects are discussed extensively in treatises dealing with the geometric optics of spectacles (e.g., see Erggelet¹⁶ and Ogle³⁰).

To begin with, spectacles have a profound effect on the neuromuscular mechanism of the eyes through their influence on accommodation. The region within which the spectacles wearer must accommodate, as well as the range of accommodation, is affected. For example, a young uncorrected hypermetrope of 4D will have to accommodate by that amount to see clearly at infinity and correspondingly more for near fixation. If a full correction is worn, the person does not have to accommodate for infinity. On the other hand, an uncorrected myope of 4D can do close work at 25 cm without using accommodation. If the correction is worn, close work requires accommodation.

The association between accommodation and convergence is discussed fully in Chapter 5. It is clear from what is known about this association that the excessive convergence that the uncorrected hypermetrope must overcome is automatically relaxed when the refractive error is corrected. In contrast, the refractive correction that the myope wears stimulates convergence. These factors form the basis of treatment of certain forms of strabismus by spectacles.

Furthermore, spectacles lenses, which change the direction in which object points appear in indirect vision, cause changes in perspective and the perception of space. These changes are particularly evident to the spectacles wearer with a high refractive correction, for instance, after cataract extraction. They are minimized by the use of contact lenses.¹¹

Spectacles change the size of the retinal image in emmetropic eyes and the blurred image in uncorrected ametropic eyes. For geometric-optical reasons, these changes in size occur only if the patient has a refractive ametropia. If the ametropia is axial in origin, a correcting lens placed into the anterior focal plane of the eye produces an image equal in size to that of the emmetropic eye. This is known as Knapp's rule.^{29, p. 264} This rule has been interpreted to the effect that contact lens correction of an anisometropia caused by an axial ametropia may actually induce aniseikonia, whereas correction with a spectacles lens will not. This does not necessarily hold true in all clinical situations. While the geometric-optical basis of Knapp's rule is correct, it has been shown that aniseikonia may occur after spectacles correction in spite of the axial nature of anisomy-

opia.^{4, 9, 24, 35, 36} The reason for this is a reduction of retinal receptor density caused by stretching of the posterior pole in high myopia that causes perceptual micropsia despite equal size of the retinal images (*basic aniseikonia*).

The effect of spectacles lenses on measuring the angle of strabismus is discussed in Chapter 12.

Aniseikonia

There is one effect produced by spectacles to which the wearer does not always readily adapt and which may cause great difficulties. Whenever refractive ametropias in the two eyes of a person are different (i.e., when there is an anisometropia), the corrected retinal images of the two eyes, and consequently the two visual images, differ in size. This condition has been termed *aniseikonia*, literally meaning unequal imagery.

Aniseikonia resulting from a corrected refractive anisometropia may be termed *refractive aniseikonia*. However, this condition may also exist in patients with an equal ametropia in the two eyes or who may have no ametropia at all. This type of image size difference may be termed *basic aniseikonia*. In this case, the aniseikonia is presumably a result of a difference in the distribution of the retinal elements, or rather their spatial values, in the two eyes. Examples of basic aniseikonia were mentioned previously and are also provided by patients with epiretinal membranes and vitreomacular compression that may cause aniseikonia from separation or compression of photoreceptors.^{6, 15}

The incongruities of the retinal images may be of different types. The image size may differ or may be the same in all meridians (*overall size difference*), or one of the two images may be larger only in the horizontal or vertical meridian (*meridional size difference*). The images may differ in oblique meridians (*oblique meridional size difference*), or they may be *asymmetrically* different in the two eyes (e.g., larger on the temporal side in one eye than on the nasal side). Finally, there may be *irregular differences*, as in a patient with a healed retinal detachment, and two or more of the listed image size differences may be simultaneously present.

In this book we consider aniseikonia only to the extent that it has a bearing on fusion and spatial orientation. Easy and comfortable fusion of the two retinal images demands that they be as

equal as possible in brightness, form, and size. When aniseikonia is present, the last requirement is not fulfilled. Thus, *aniseikonia may be an obstacle to fusion*. The mechanism of this obstacle is the rivalry set up between foveal and peripheral fusion (see Chapter 4). If the centers of the images are fused, the peripheral margins are not; if the peripheral margins are fused, the centers are disparately imaged. If the aniseikonia is very small, the difficulty is negligible. If the aniseikonia is very large, say, size differences of 5% or more, the patient as a rule will suppress part of the image of one eye, thus eliminating symptoms. This must be done at the expense of normal binocular vision. Not all patients are able to suppress equally well. This is especially true if the aniseikonia is of relatively moderate amount, say, between 0.75% and 2.5%; then the compulsion to fuse often prevails, with resulting subjective symptoms. On the other hand, suppression may be strong enough to cause a deviation of the visual lines, a strabismus. Bielschowsky⁸ described a most perplexing case of horror fusionis (see Chapter 13) which responded to a complex correction with iseikonic lenses.

Aniseikonia also has an effect on spatial localization. If a patient has an image size difference in the horizontal meridian, the image of one eye is larger in that meridian; in other words, there is a horizontal disparity of the retinal images. Fusion of horizontally disparate images produces a stereoscopic effect (see Chapter 2). One should therefore expect a stereoscopic effect, a spatial distortion, when aniseikonia is present in the horizontal meridian. Indeed, such a spatial distortion can always be found and is readily explained on a geometric basis.

Assume that the visual lines of a normal observer intersect in symmetrical convergence at point F on a plane on which there are two points, P and N , seen in peripheral vision (Fig. 7-5). If the image of the observer's right eye is now magnified in the horizontal meridian by an appropriate lens, all horizontal distances on the plane are magnified and PFN is increased to $P'F'N'$ for the right eye. This means that the object point P , originally imaged on the retinal point p_r in the right eye, now stimulates the more temporally located point p'_r . The image of the point N is displaced in the right eye from n_r to n'_r . No change in the image size of the left eye has occurred. If the horizontal disparity between the two eyes that has been created is not too large, sensory

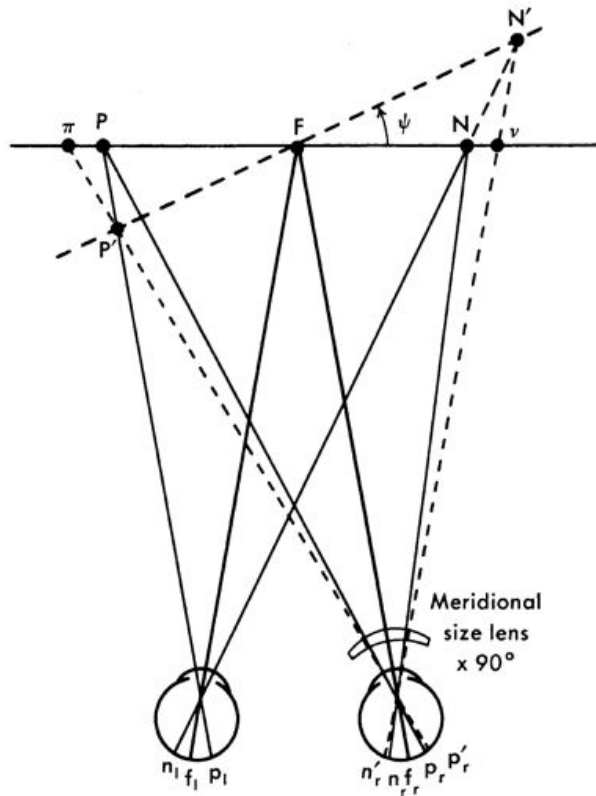


Figure 7-5. Tipping of a frontoparallel plane around a fixation point when the image of the right eye is magnified horizontally by a meridional-size lens placed at axis 90°. (From Burian HM: Influence of prolonged wearing of meridional size lenses on spatial localization. Arch Ophthalmol 30:645, 1943.)

fusion of the horizontally disparate retinal images will occur and must create a stereoscopic effect. Object P will appear to have advanced to point P' and object point N to have receded to N' , since only points situated objectively at P' and N' could fulfill the conditions of stimulating simultaneously the retinal elements p_l and p'_r , and n_l and n'_r . The impression is created that the plane has rotated around the fixation point F . In general, objects in the half of the visual field pertaining to the eye with the relatively larger retinal image in the horizontal meridian appear farther away than the fixation point, whereas those in the half of the visual field pertaining to the eye with the relatively smaller retinal image appear to be closer.

Vertical and oblique meridional aniseikonic errors also produce typical distortions of space. All those stereoscopic effects are quantitative, and the empirical data are in good agreement with the theory, so much so that a clinical instrument for the measurement of aniseikonia was designed (space eikonometer) based on these stereoscopic effects. For clinical purposes, especially in strabis-

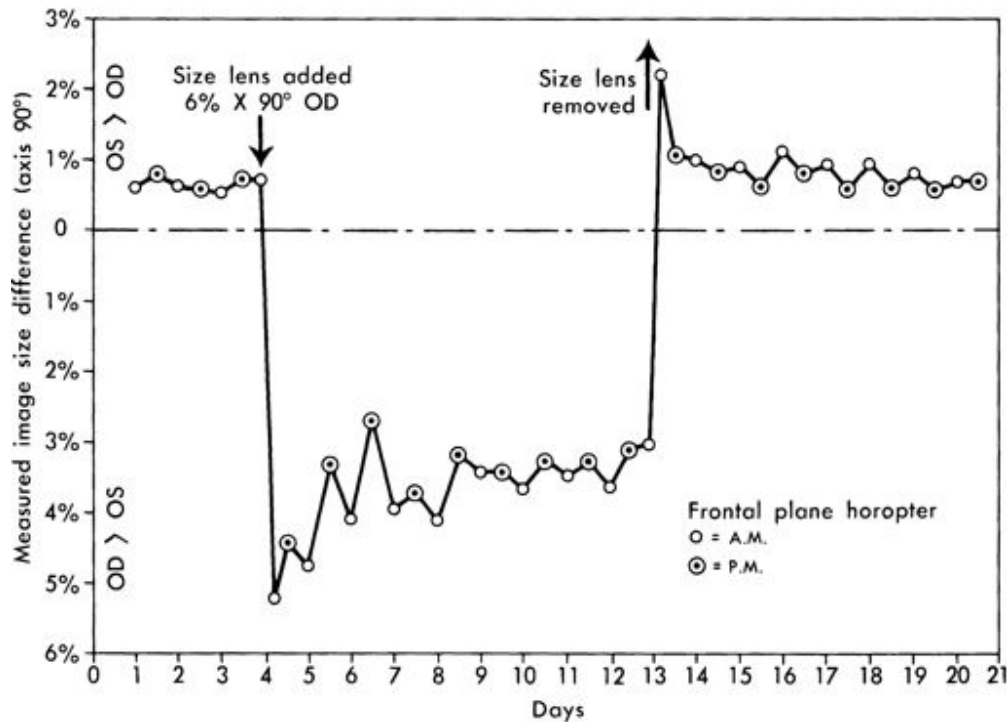


FIGURE 7-6. Data showing that prolonged wearing of a meridional-size lens has only minimal adapting effect on the frontal plane horopter. (From Burian HM: Influence of prolonged wearing of meridional size lenses on spatial localization. *Arch Ophthalmol* 30:645, 1943.)

mic patients, aniseikonia is determined with Aulhorn's phase difference haploscope (see Chapter 4). Awaya and coworkers⁵ developed a simple and useful "new aniseikonia test"* that is based on image separation with red and green spectacles. In comparing this test with the eikonometer, McCormack and coworkers²⁸ found that the Awaya test may underestimate the degree of aniseikonia (see also Yoshida and coworkers⁴⁴). Another new test,† combining the features of the Aulhorn phase difference haploscope (see Chapter 4) with those of the Awaya test was introduced by Esser¹⁷ and also has the advantage of permitting aniseikonia measurements in the presence of manifest strabismus. Unfortunately, neither of these instruments is available in most clinical settings.

Why do patients with corrections for anisotropia generally not complain about spatial distortions? The answer is that many patients will report that during the first day or two of wearing a new correction they experience various changes in the appearance of their surroundings; for example, the floor may appear to have slanted to one side, or it may have seemed to slant up or down in front of

them. These distortions are caused by aniseikonia. However, after a short while the distortions disappear. By what mechanism do they disappear? The first thought is that the aniseikonia may have been compensated for by some physiologic mechanism. This is not the case. Burian¹⁰ demonstrated in an experimental study, using the subjective frontoparallel plane in the horopter apparatus as a criterion, that the amount of aniseikonia measured was changed by only a fraction after the phenomenologic adaptation had taken place, regardless of how long the adaptation had lasted (Fig. 7-6).

What actually happens is that there are two general classes of clues to spatial orientation: the *binocular stereoscopic clues* and the *uniocular experiential clues* (see Chapter 2) Only the stereoscopic clues can be affected by aniseikonia, for they alone depend on the disparity of retinal images. The experiential clues remain unaffected. If stereoscopic perception is changed suddenly in such a way as to convey an incorrect impression of the surroundings, for instance, by a pair of new spectacles, stereoscopic clues will at first dominate and the environment will appear distorted. In time, however, uniocular clues—born from experience and active also in binocular vision—make themselves felt and gradually dominate stereoscopic clues. One learns how to disregard or suppress

*Distributor for Western Hemisphere: Binocular, PO Box 3727, Dillon, CO 80435; Phone or fax USA (970) 262-0753; e-mail: perxbvq@colorado.net; Website: BinocularVision.com

†Oculus, Inc., P.O. Box 1007, Woodinville, WA 98072-1007

stereoscopic clues, and under the influence of unioocular clues the surroundings resume their normal appearance.

This brief discussion of some of the basic concepts of aniseikonia in a book on the neuromuscular anomalies of the eyes is justified because it enlarges insight into the binocular function. Since aniseikonia is an obstacle to fusion it could be a factor in the etiology of certain types of comitant strabismus (see Chapter 9). The response of normal observers to artificially induced aniseikonia under certain experimental conditions, as well as the responses of naturally aniseikonic patients to the same experimental situations, also gives an inkling of some of the important adaptive mechanisms in patients with neuromuscular anomalies of the eyes (see Chapter 13).

The treatment of aniseikonia has become almost a lost art since the Dartmouth Eye Institute closed its doors in 1947. Most of what is known about aniseikonia today is based on the work of such Dartmouth notables as *Ames*, *Lancaster* (who coined the term), *Linksz*, *Ogle*, *Burian*, and *Boeder*. Although the clinical significance of aniseikonia as a cause of asthenopia was undoubtedly overemphasized in those days, recent interest in aniseikonia has surged since the advent of kerato-refractive surgery and the optic calculation of intraocular lens implants. A discussion of the clinical management of aniseikonia exceeds the purpose of this text and the reader is referred to other sources.^{1, 2, 7.}

REFERENCES

- Achiron LR, Witkin NS, Ervin AM, et al: The effect of relative spectacle magnification on aniseikonia. *J Am Optom Assoc* 69:591, 1998.
- Achiron LR, Witkin N, Primo S, et al: Contemporary management of aniseikonia. *Surv Ophthalmol* 41:321, 1997.
- Adler FH, Fliegelman M: Influence of fixation on visual acuity. *Arch Ophthalmol* 12:475, 1934.
- Awaya S, Noorden GK von: Aniseikonia measurement by phase difference haploscopy in myopic anisometropia and unilateral aphakia (with special reference to Knapp's Law and comparison between correction with spectacle lenses and contact lenses). *Binocular Vision Strabismus Q* 14:223, 1999.
- Awaya S, Sugawara M, Horibe F, et al: The "new aniseikonia test" and its clinical application. *Acta Soc Ophthalmol Jpn* 86:217, 1982.
- Benegas NM, Egbert J, Engel WK, et al: Diplopia secondary to aniseikonia associated with macular disease. *Arch Ophthalmol* 117:896, 1999.
- Brown RM, Enoch JM: Combined rules of the thumb in aniseikonia prescriptions. *Am J Ophthalmol* 69:118, 1970.
- Bielschowsky A: Congenital and acquired defects of fusion. *Am J Ophthalmol* 18:925, 1935.
- Bradley A, Rabin A, Freeman RD: Nonoptical determinants of aniseikonia. *Invest Ophthalmol Vis Sci* 24:507, 1983.
- Burian HM: Influence of prolonged wearing of meridional size lenses on spatial localization. *Arch Ophthalmol* 30:645, 1943.
- Burian HM: Optics: Fusion in unilateral aphakia. In *Contact Lens Symposium*. *Trans Am Acad Ophthalmol Otolaryngol* 66:285, 1962.
- Butler T, Westheimer G: Interference with stereoscopic acuity: Spatial, temporal, and disparity tuning. *Vision Res* 18:1387, 1978.
- Carpenter RH: *Movement of the Eyes*. London, Pion, 1977, p 260.
- Collins MJ, Brown B, Bowman KL: Peripheral visual acuity and age. *Ophthalmic Physiol Opt* 9:314, 1989.
- Enoch JM, Schwartz A, Chang D, et al: Aniseikonia, metamorphopsia and perceived entoptic pattern: Some effects of a macular epiretinal membrane, and the subsequent spontaneous separation of the membrane. *Ophthalmic Physiol Opt* 15:339, 1995.
- Eggelet H: *Brillenlehre*. In Schieck F, Brückner A, eds: *Kurzes Handbuch der Ophthalmologie*, vol 2. Berlin, Springer-Verlag, 1932, p. 745.
- Esser J: A new simple test for quantitative determination of near aniseikonia. *Klin Monatsbl Augenheilkd* 198:228, 1991.
- Flom MC, Weymouth FW, Kahneman D: Visual resolution and contour interaction. *J Opt Soc Am* 53:1026, 1963.
- Harms IH, Aulhorn E: Studien über den Grenzkontrast. I. Mitteilung. Ein neues Grenzphänomen. *Graefes Arch Ophthalmol* 121:400, 1958.
- Hartline HK: Inhibition of activity of visual receptors by illuminating nearby retinal areas in the *Limulus* eye. *Fed Proc* 8:69, 1949.
- Helmholtz H von: In Southall JPC, ed: *Helmholtz's treatise on physiological optics*. Translation from the 3rd German edition, Ithaca, NY, Optical Society of America, 1924, Dover reprint, New York, Dover Publications, vol 4, 1962, p. 9.
- Hering E: Zur Lehre vom Lichtsinn. Über successive Lichtinduction. *Sitzungsbericht Kaiserl Akad Wiss Wien Math Natl. Kl* 66:(pt 3)5, 1872.
- Keeseey UT: Effects of involuntary eye movements on visual acuity. *J Ophthalmol Soc Am* 50:769, 1960.
- Kramer P, Shipman S, Bennet G, et al: A study of aniseikonia and Knapp's law using a projection space eikonometer. *Binocular Vision Strabismus Q* 14:197, 1999.
- Kuffler SW: Discharge patterns and functional organization of mammalian retina. *J Neurophysiol* 16:37, 1953.
- Ludvigh E: Extrafoveal visual acuity as measured with Snellen letters. *Am J Ophthalmol* 24:303, 1941.
- Ludvigh E: Effect of reduced contrast on visual acuity as measured with Snellen test letters. *Arch Ophthalmol* 25:469, 1941.
- McCormack G, Peli E, Stone P: Differences in tests of aniseikonia. *Invest Ophthalmol Vis Sci* 33:2063, 1992.
- Ogle KN: *Researches in Binocular Vision*. Philadelphia, WB Saunders, 1950.
- Ogle KN: *Optics*. An Introduction for Ophthalmologists. Springfield, IL, Charles C Thomas, 1961.
- Polyak SL: *The Retina*. Chicago, University of Chicago Press, 1941.
- Ratliff F: The role of physiologic nystagmus in monocular acuity. *J Exp Psychol* 43:163, 1952.
- Riggs LA: Visual acuity. In Graham CH, ed: *Vision and Visual Perception*. New York, John Wiley & Sons, 1965, p 321.
- Riggs LA, Ratliff F, Cornsweet JC, et al: The disappearance of steadily fixated visual test objects. *J Opt Soc Am* 43:495, 1953.

35. Romano PE: An exception to Knapp's law; unilateral axial high myopia. *Binocular Vision Strabismus Q* 1:166, 1985.
36. Romano PE, Noorden GK von: Knapp's law and unilateral high axial myopia. *Binocular Vision Strabismus Q* 14:215, 1999.
37. Tschermak-Seysenegg A von: *Introduction to Physiological Optics*. Translated by Boeder P. Springfield, IL, Charles C Thomas, 1952.
38. Wertheim, T: Über die indirekte Sehschärfe. *Z Psychol Physiol Sinnesorgane* 7:172, 1894.
39. Westheimer G: The spatial sense of the eye. Proctor lecture. *Invest Ophthalmol Vis Sci* 18:893, 1979.
40. Westheimer G: Visual acuity. In Moses R, ed: *Adler's Physiology of The eye*, ed 7. St Louis, Mosby-Year Book, 1982, p 540.
41. Westheimer G, Hauske G: Temporal and spatial interference with Vernier acuity. *Vision Res* 15:1137, 1975.
42. Weymouth FW: Visual sensory units and the minimal angle of resolution. *Am J Ophthalmol* 46:(1, pt 2)102, 1958.
43. Weymouth FW, Andersen EE, Averill HL: Retinal mean local sign: A new view of the relation of the retinal mosaic to visual perception. *Am J Physiol* 63:410, 1923.
44. Yoshida M, Sato M, Awaya S: Evaluation of the clinical usefulness of the New Aniseikonia Tests (in Japanese). *Nippon Ganka Gakkai Zasshi* 101(Sept):718, 1997.

P A R T

two

***Introduction to
Neuromuscular
Anomalies of
the Eyes***

Classification of Neuromuscular Anomalies of the Eyes

A deviation of the visual axes relative to each other is the most common sign in all neuromuscular anomalies of the eyes except for supranuclear affections. All neuromuscular anomalies of the eyes therefore are classified primarily on the basis of the properties and characteristics of the deviation, its direction, origin, temporal behavior, and various modifications imposed on it by the sensory system.

Heterophoria and Heterotropia

Proper alignment of the eyes is guaranteed by a normally functioning sensory and motor fusion mechanism. If sensory fusion is artificially suspended by excluding one eye from participating in vision, motor fusion is “frustrated,” as Chavasse⁴ put it, and a measurable relative deviation of the visual axes will appear in most patients. When the obstacle to sensory fusion is removed, motor fusion in most patients will return the visual axes to their proper relative positions. The relative deviations thus elicited are called *heterophorias*, a very useful term introduced by Stevens.²³ Since heterophorias become evident only when normal cooperation of the eyes is disrupted, they may be defined as *deviations kept latent by the fusion mechanism*. Figure 8–1 shows the effect of fusion

in controlling a large esodeviation that becomes manifest when fusion is disrupted with the translucent occluder of Spielmann.²¹

In the absence of a properly functioning fusion mechanism, a more or less obvious deviation of one of the visual lines will be present. Such deviations, termed *heterotropias*, are *manifest deviations not kept in check by fusion*. The term heterophoria and related terms were formed from the Greek words *heteros*, “other,” “different from,” and *phora*, “bringing,” “carrying” (compare *pherein*, to bear, carry, a word from which so many medical and scientific words have been coined).¹⁹ *Phora* does not mean a tendency, even less so the word *phoro* from which Stevens states he derived his term. Stevens’ original definition of “heterophoria as a tendency of the visual lines to turn away from parallelism,” copied to this day in many texts, does not properly describe the phenomenon, as Lancaster¹¹ pointed out.

In accordance with the foregoing definitions, all neuromuscular anomalies of the eyes can be separated into two main classes: latent deviations (heterophorias) and manifest deviations (heterotropias). Manifest deviations are known also by the generic name of *strabismus*, or *squint*.

According to Hirschberg⁸ the word *strabismus* originates from the Greek. Hippocrates used the word *streblos*, “turned,” “twisted,” when he talked about strabismic subjects and the word is

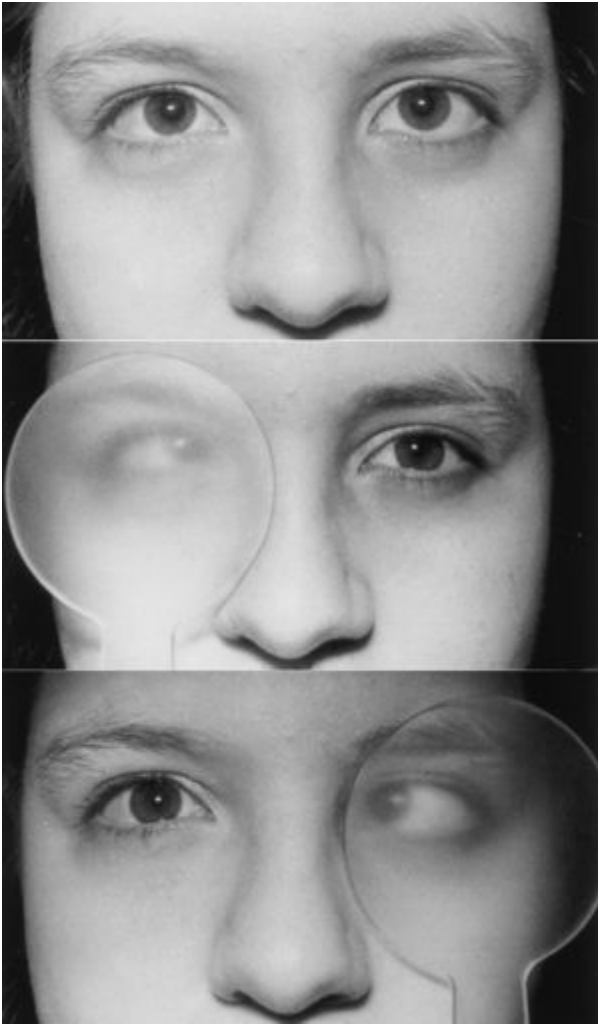


FIGURE 8-1. Manifestation of esotropia after disruption of fusion with a translucent occluder.

derived from the verb *strephein*, “to twist,” “to turn.”¹⁴ The Romans simply adopted the term *strabismus* into their language from whence it entered medical terminology. The proper Latin expressions were *paetus* and *luscus* which originally meant “one-eyed.” Neither of these terms or their derivatives are used in English but *luscus* survived in the French verb *loucher*, “to squint.” Whether the name of the famous Greek historian and geographer Strabo (“the squinter,” 66 BC–AD 24) had anything to do with the origin of *strabismus*, as has occasionally been claimed, is unlikely since Hippocrates had used the word 400 years earlier. Perhaps Strabo had strabismus and thereby got his name.

Relative and Absolute Position of Rest

The position assumed by the visual axes when fusion is suspended has been termed the *relative*

position of rest of the eyes.^{1, 2} This is an unfortunate term because ocular muscles are never “at rest” in a living, conscious person. It is known today from electromyographic evidence (see Chapter 6) that electrical activity is continuous in extraocular muscles when the eyes are steadily fixating. Indeed, even when fusion is interrupted, the deviation of the visual axes is not a passive but an active process, as shown by the increment and corresponding decrement in electrical activity of certain extraocular muscles. Long before electrophysiologic evidence became available, it was obvious that the eyes are never truly at rest in a waking person. Maintenance of the primary position, fixation, and proper alignment of the visual axes all require the presence of an actively supported tonus and a continuous shift in tonus of extraocular muscles (see p. 111). A differentiation was made therefore between the *relative, functional, or physiologic position of rest* assumed by the eyes when fusion was suspended and the *absolute position of rest* assumed by the eyes in death before the onset of rigor mortis,¹⁵ and in deep anesthesia. The absolute position of rest has also been termed *anatomical* or *static* because it is determined solely by anatomical and other mechanical factors.^{7, 10, 11} Spielmann²² introduced the term *fixation-free position* to describe the position of the eyes in the dark or when both eyes are covered with semiopaque occluders. This position is identical to what Lancaster¹¹ called, less descriptively, the *static position*.

The term *relative position of rest* is an unnecessary one. Since binocular vision and fusion are not active when the vision of one eye is obstructed, it is best to say the particular position that the eyes assume under those conditions is the *fusion-free position*.⁹ Synonymous terms are the *heterophoric position* and the *dissociated position*.⁴

The absolute or anatomical position of the eyes in death is generally one of slight divergence and elevation,^{4, 7, 16} yet it does not attain the divergent angle of the orbital axes.⁵ The eyes may also be aligned in death.⁵ The position of the eyes in death is determined by the absence of nervous impulses to extraocular muscles. Curare or curare-like substances, which inhibit transmission at the neuromuscular junction, can be used to artificially reproduce this situation in normal subjects. Toselli²⁴ did this and found that the eyes assumed a position of 8° to 12° of divergence and 3° to 6° of elevation, which is comparable to the position assumed by the eyes in general anesthesia. Using a linear mea-

surement, Meyers¹⁷ determined the position of the eyes of 37 patients under general anesthesia who were undergoing some type of general surgery. The state of ocular alignment had been previously tested. She found a significant degree of divergence in all patients who had been exophoric before being given anesthesia, as well as in one third of patients with esophoria. The eyes of most (65%) esophoric patients were parallel within the limits of accuracy of the method; a convergent position was seen only in some patients with esotropia. The position of the eyes in patients with strabismus who are under general anesthesia is considered of importance by some surgeons in deciding how much surgery to do. This matter is considered further in the discussion of principles of surgery on extraocular muscles (see Chapter 26).

Ocular Alignment

Ideally, the fusion-free position of the eyes should be such that the visual lines are parallel in distance fixation and have the proper convergence in near vision. This ideal, termed *orthophoria*, is infrequently realized; it is only approached more or less closely. Whenever fusion is suspended by some means, there is usually a deviation of the visual axes even though it may be too small to be measured by ordinary clinical means.

Orthophoria therefore is not a normal condition in the majority of people free from ocular symptoms. Consequently, many clinicians consider a certain amount of heterophoria to be normal. Moses,¹⁸ for example, stated that 1^Δ to 2^Δ of esophoria or 1^Δ to 4^Δ of exophoria in distance fixation should be considered physiologic. He went on to say that hyperphoria of 1^Δ of either eye nearly always produces symptoms; hence, only 0.5^Δ of hyperphoria can be considered to be within the physiologic range. These values are selected on the basis of clinical significance. A clinically significant finding is one that may produce symptoms and may require treatment. It should be noted that the clinical significance of heterophorias depends not so much on their absolute values as on correlated findings, for example, the fusional amplitudes (see Chapter 4).

For a description of a complete alignment of the visual axes with the object of regard and thus of a desirable endstage of strabismus therapy, the term *orthotropia* appears most suitable. *Ortho-*

tropia is present when the cover test is negative upon covering either eye in the absence of amblyopia. The latter qualification is necessary to exclude patients with amblyopia and eccentric fixation in whom the cover test may also be negative but in whom the visual axis of the amblyopic eye is *not* aligned with the object of regard (see Chapter 14). In Greek, *orthos* means “straight” or “correct” and, according to Lang,¹³ *tropos* means “turn” but also “direction.” Thus orthotropia conveys the notion of a correct direction or position of the eyes. Another acceptable term is *orthoposition*,³ the position of the eyes in which the visual axes intersect at the fixation point under the influence of fusion. Both orthotropia and orthoposition may be used interchangeably to describe binocular alignment on a fixation target. The term *orthophoria* is not a good one since, as mentioned above, orthophoria is the exception and heterophoria is the rule in normal binocular vision.¹ The terms *straight-appearing eyes* or *straight eyes*, which all too often seem to escape editorial scrutiny in the contemporary American literature, are to be avoided. They lack precision in describing the functional state of the patient since they encompass a whole spectrum of conditions that includes orthotropia, heterophoria of varying degrees and clinical significance, and even microtropia and heterotropia with a small angle.

Direction of Deviation

There are a variety of heterophoric or heterotropic deviations (Fig. 8–2). If the visual axes converge, the condition is called *esophoria* or *esotropia*, and if they diverge it is known as *exophoria* or *exotropia*. *Hyperphoria* or *hypertropia* occurs if one visual line is higher than the other. It is present on the right if the right visual line is higher than that on the left and on the left if the left visual line is higher than that on the right.

One may also speak of a left hypophoria or hypotropia when the right visual line is the higher one and of a right hypophoria or hypotropia when the left visual line is the higher one. Since deviations of the visual lines are relative, the terms *hypophoria* and *hypotropia* may appear to be superfluous, but they are useful, especially in heterotropias, to indicate which eye is fixating. Thus right hypertropia indicates that the (lower) left eye is the one fixating, whereas left hypotropia indicates that the (higher) right eye is fixating. For

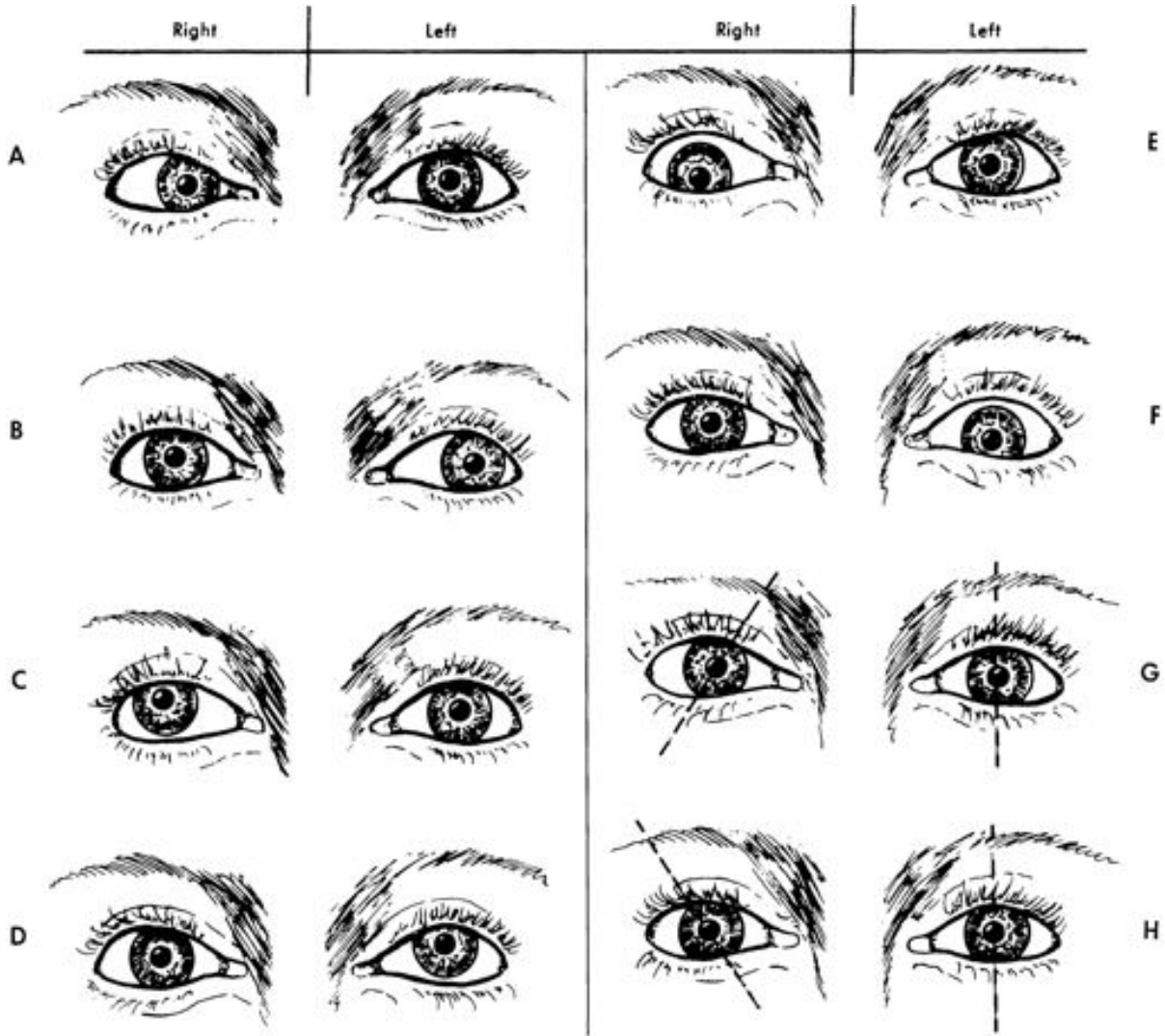


FIGURE 8-2. Classification by direction of deviation. *A*, Right esotropia. *B*, Left exotropia. *C*, Right hypertropia associated with small exotropia. *D*, Left hypertropia. *E*, Right hypotropia. *F*, Left hypotropia. *G*, Right incyclotropia. *H*, Right excyclotropia.

the vertical heterophorias or heterotropias, Bielschowsky² also used the terms *positive* (right hyper-) or *negative* (left hyper-) *vertical divergence* (or *deviation*) in his American publications. These terms are still in common usage in German ophthalmology.

A misalignment of one or both eyes around the sagittal axis produces clockwise or counterclockwise rotations of the globe (*cyclotropia*). Since the direction of the deviation must be defined in each eye, the terms *right* or *left* excyclotropia or incyclotropia are used. Cyclodeviations are mostly manifest; hence, differentiation between *cyclophoria* and *cyclotropia* is difficult to justify on clinical grounds (see Chapter 18).

As already stated, deviations of the visual axes also frequently are referred to by the time-honored names of *strabismus* and *squint*. An esotropia is

then a convergent strabismus; an exotropia, a divergent strabismus; a hypertropia, a vertical strabismus; and a cyclotropia, a torsional strabismus.

The terms *convergent* and *divergent strabismus*, which are widely used in the continental European literature, have not become popular in this country. This is rather fortunate since convergent and divergent could easily be misunderstood to mean that the convergence or divergence mechanism is implicated. Although this may well be so in some forms of horizontal strabismus, it certainly does not hold true for others. In American usage the term *strabismus* generally is understood to be synonymous with heterotropia. In British and continental European usage, the word includes both heterotropias and heterophorias. To differentiate between the two, the expressions *manifest strabismus* and *latent strabismus* are used. To encompass

both the heterophoric and heterotropic forms, such terms as *esodeviation* and *exodeviation* are appropriate.

A person may manifest a heterophoric or heterotropic deviation that combines two or more of the various directions mentioned. He or she may then have an *esohyperdeviation*, an *exohyperdeviation*, or a *cyclovertical deviation*.

Comitance and Incomitance

Strabismus may occur in one of two major forms: it is either *comitant* or *incomitant*. In comitant strabismus, the deviation is, within physiologic limits and for a given fixation distance, the same in all directions of gaze. In incomitant strabismus, one or more extraocular muscles show signs of underaction or paralysis. The deviation therefore varies in different directions of gaze but is larger when the eyes are turned in the direction of action of the underacting or paralytic muscle. Further differentiation between these two forms of strabismus is discussed in Chapter 20.

The term *comitant* originally had the form *concomitant*, derived from the late Latin *concomitor*, meaning “I attend,” “I accompany,” which implies that despite the deviation, one eye accompanies the other in all its excursions (compare the German *Begleitschielen*, concomitant squint). Duane⁶ suggested *comitant*, a form which is universally accepted in the American literature and not without linguistic justification.

We speak of *incomitance* when the angle of deviation changes in different positions of gaze. Incomitance may be caused by innervational factors (paralytic strabismus) or mechanical-restrictive factors.

Constancy of Deviation

A manifest deviation need not be present at all times. In some patients the fusion mechanism is

inadequate to keep the eyes properly aligned under any circumstances. One then speaks of a *constant deviation* (constant strabismus, constant esotropia, constant exotropia). In other patients the fusion mechanism functions well in some but not in all circumstances. The deviation then is manifest only at certain times, when the patient awakes from a nap or is tired, ill, under stress, or in particular test situations. An *intermittent deviation* (intermittent strabismus, intermittent esotropia, intermittent exotropia) is then said to be present. Even though variations may exist between different teaching hospitals, the symbols listed in Table 8-1 are fairly uniformly used for abbreviation of strabismus forms in charts and orthoptic records.

Some patients display a heterophoric deviation for one fixation distance and a heterotropic deviation for another fixation distance (e.g., esotropic in near vision but esophoric in distance vision). Patients with a paralyzed muscle may be heterotropic in one direction of gaze but heterophoric in the opposite direction. Also, patients with an A or V pattern of fixation (see Chapter 19) may be heterotropic in the position of maximum deviation and heterophoric in the position of minimum deviation. In British usage,^{15, p. 94} following the lead of Chavasse,⁴ this behavior is termed *periodic strabismus*, meaning that during the period when the eyes are in a certain position a manifest strabismus occurs. The term is not well chosen, since the word “periodic” generally refers to divisions of time. In these cases the essence is not the time during which a certain position of the eyes is assumed, nor is there any periodicity. It is the position of the fixation object in space that determines the sensorimotor response.

Cases of *cyclic heterotropia* (see Chapter 21) represent an interesting variant of the intermittent type of deviation. In these patients a manifest deviation appears at regular intervals (e.g., every other day). At the time when the eyes appear to be straight, no latent deviation comparable in amount to the manifest deviation can be measured.

TABLE 8-1. Common Abbreviations

	Heterophoria		Heterotropia		Intermittent	
	Near	Distance	Near	Distance	Near	Distance
Esodeviation	E'	E	ET'	ET	E(T)'	E(T)
Exodeviation	X'	X	XT'	XT	X(T)'	X(T)
Right hyperdeviation	RH'	RH	RHT'	RHT	RH(T)'	RH(T)
Left hyperdeviation	LH'	LH	LHT'	LHT	LH(T)'	LH(T)

By classifying these patients with the general group of intermittent strabismus, we do not imply that the mechanism is the same as that in ordinary intermittent esotropia or exotropia.

State of Vergence Systems

The role of *accommodative convergence* in determining the relative position of the visual axes has been discussed in Chapter 5. Its role in the etiology of esotropia and in the clinical picture of heterotropias is examined in later chapters (see Chapters 9 and 16). In this chapter mention will be made only that a further classification distinguishes *accommodative esotropia* from *nonaccommodative esotropia*. In accommodative esotropia the act of accommodation has a major influence on the deviation, whereas in nonaccommodative esotropia it does not.

Convergence is more active in near fixation and divergence in distance fixation. On this basis Duane⁶ developed his classification of the comitant motor anomalies. If an esodeviation is greater at near than at distance, one may speak of a *convergence excess type*; if an exodeviation is greater at near than at distance fixation, then it is referred to as a *convergence insufficiency type*. If an exodeviation is greater at distance than at near, there is a *divergence excess type*; if an esodeviation is greater at distance than at near, there is a *divergence insufficiency type*. We find this classification useful provided it is clearly understood that this terminology is to be used only in a descriptive sense, that is, without etiologic implications. This classification is described in more detail in Chapter 17.

Type of Fixation

The use made of the eyes for fixation is another important criterion for classifying heterotropias. One distinguishes *unilateral* heterotropias (e.g., right esotropia or exotropia), in which the patient habitually uses one eye for fixation, from *alternating* heterotropias, in which the patient fixates with either eye. A whole spectrum of fixation habits exists, ranging from extreme unilaterality to free random alternation. The term *nonalternating strabismus* is preferable to “unilateral strabismus.” Unilateral is the contrary of bilateral. It would seem inappropriate to define an alternating hetero-

tropia as “bilateral strabismus.” The latter term should be reserved for those rare cases in which both eyes are deviated from the primary position (e.g., skew deviations, myogenic or mechanical strabismus).

The term *monofixation* introduced by Parks²⁰ to describe what Lang¹² referred to as microstrabismus or microtropia (see Chapter 16) is somewhat ambiguous. It implies that only one eye is fixating. However, that is also the case in other forms of strabismus. Monofixation could also be interpreted as lack of alternation.

Time of Onset of Deviation

A deviation noted at birth or in the first months of life is termed *congenital (connatal)*. Because the onset is difficult to document at that age (see Chapter 16), the term congenital has been replaced by or is used synonymously with *infantile*, which includes all forms of strabismus with an onset during the first 6 months of life. If the deviation arises after that age, it is called *acquired*. A variant of the acquired form is *acute esotropia* (see Chapter 16). These forms are also spoken of as *primary heterotropia*. The meaning of the term *secondary heterotropia* is not quite uniform. In general it refers to a deviation that results from some known cause such as a sight-impairing disease or trauma of one eye (*sensory heterotropia*), or after surgical overcorrection (*consecutive heterotropia*). Occasionally an esotropic eye may change spontaneously into an exodeviation, in which case the term *consecutive deviation* is also used.

Paralytic Strabismus

Paralysis and Paresis

If the action of a muscle or a group of muscles is completely abolished, this condition is a *paralysis* or *palsy*; if the action of the muscle or muscles is impaired but not abolished, this is a *paresis*. It is not always possible to distinguish on clinical grounds between paresis and paralysis since an apparently paralysed muscle may occasionally regain some function after surgery or Botox (botulinum toxin, type A) injection of its antagonist. Inability to move an eye in a certain gaze direction does not automatically imply that the muscle involved is paralyzed, as mechanical factors may

also impede ocular motility. In that case the term *paralysis*, which should be limited to an innervational cause of restricted motility, is inappropriate.

Muscles Affected

The terms *N III*, *N IV*, and *N VI* paralysis refer to paralyzes of muscles supplied by those cranial nerves. If all extraocular muscles supplied by the third cranial nerve are paralyzed, the paralysis is termed a *complete oculomotor palsy*; if one or more extraocular muscles are spared, the oculomotor palsy is *partial*. If all extraocular muscles are paralyzed, the condition is called an *external ophthalmoplegia*. If the intrinsic ocular muscles are paralytic, one speaks of an *internal ophthalmoplegia*. If both the extrinsic and intrinsic ocular muscles are affected, then *complete ophthalmoplegia* occurs.

Duration and Cause

The characteristics of a paralytic strabismus vary with time (see Chapter 20). One must therefore separate the cases of paralytic strabismus according to duration of the condition and time of onset. In these cases, as in comitant heterotropias, the paralysis may be *congenital* or *acquired*. Acquired paralytic strabismus, in turn, is acute or gradual, and may be caused by trauma, infection, inflammation, vascular conditions, tumors, or degenerative processes.

Seat of Lesion

Depending on the seat of the lesion, neurogenic paralyzes of extraocular muscles may be *supranuclear*, *nuclear*, or *infranuclear* in origin. Myogenic paralyzes result from diseased states of the muscles themselves.

Mechanical-Restrictive Strabismus

Structural alteration of the muscle itself or of its antagonist may limit its ability to function normally. In that case we speak of *mechanical* (also structural or restrictive) strabismus as opposed to *innervational strabismus*.

Orbital Strabismus

Any ocular misalignment caused by anomalies of the orbit or of the face (craniofacial dysostoses, plagiocephaly, hydrocephalus, heterotopia of muscle pulleys, and so forth) may be referred to as *orbital strabismus*.

REFERENCES

1. Bielschowsky A: Über die Ruhelage der Augen, vol 66. Bericht 39. Versammlung ophthalmologische Gesellschaft, Heidelberg. Wiesbaden, JF Bergmann, 1913, p 67 ff.
2. Bielschowsky A: Lectures on Motor Anomalies. Hanover, NH, Dartmouth College Publications, 1943/1956.
3. Bredemeyer HG, Bullock K: Orthoptics: Theory and Practice. St Louis, Mosby-Year Book, 1968, p 86.
4. Chavasse FB: Worth's Squint or the Binocular Reflexes and the Treatment of Strabismus, ed 7. Philadelphia, P Blakiston's Sons, 1939.
5. Cogan DG: Neurology of the Ocular Muscles, ed 2. Springfield, IL, Charles C Thomas, 1956, p 20.
6. Duane A: A new classification of the motor anomalies of the eyes based upon physiological principles, together with their symptoms, diagnosis and treatment, reprinted from Ann Ophthalmol Otolaryngol October 1896, and edited by White JW, nd.
7. Hansen Grut E: A contribution of the pathogenesis of concomitant squinting. Trans Ophthalmol Soc UK 10:1, 1890.
8. Hirschberg J: The History of Ophthalmology, vol 1. Translated by Blodi FC. Bonn, Wayenborgh, 1982, p 110.
9. Hofmann FB: Die Lehre vom Raumsinn. In Axenfeld Th, Elschmig A, eds: Graefe-Saemisch's Handbuch der gesamten Augenheilkunde, ed 2, vol 3. Berlin, Springer-Verlag, 1925, p 392.
10. Lagleyze P: Du strabisme. Paris, J Rousset, 1913.
11. Lancaster WB: "Terminology," with extended comments on the position of rest and fixation. In Allen JH, ed: Strabismus Ophthalmic Symposium I. St Louis, Mosby-Year Book, 1950.
12. Lang J: Micotropia. Arch Ophthalmol 81:758, 1969.
13. Lang J: Strabologische Terminologie II und Informatik. Klin Monatsbl Augenheilkd 186:231, 1985.
14. Lang J: Personal communication, Sept 8, 1999.
15. Lyle TK, Wybar KC: Lyle and Jackson's Practical Orthoptics in the Treatment of Squint (and Other Anomalies of Binocular Vision), ed. 5. Springfield, IL, Charles C Thomas, 1967.
16. Majoros J: Totenstarre der Augen. Graefes Arch Clin Exp Ophthalmol 134:112, 1935.
17. Meyers MP: The position of eyes in general anesthesia. Am J Ophthalmol 34:174, 1951.
18. Moses RA: Adler's Physiology of the Eye: Clinical Application, ed 5. St. Louis, Mosby-Year Book, 1970, p 201.
19. Nybakken OE: Greek and Latin in Scientific Terminology. Ames, IA, Iowa State College Press, 1959.
20. Parks MM: The monofixation syndrome. Trans Am Ophthalmol Soc 67:609, 1969.
21. Spielmann A: A translucent occluder for studying eye positions under unilateral and bilateral cover test, Am Orthoptics J 36:65, 1986.
22. Spielmann A: Les strabismes. De l'analyse clinique à la synthèse chirurgicale, ed 2. Paris, Masson, 1991, p 10.
23. Stevens GT: A system of terms relating to the conditions of the ocular muscles known as "insufficiencies." NY Med J 44:624, 1886.
24. Toselli C: Ricerche sulla posizione assoluta di riposo degli occhi in individui curarizzati. Boll Ocul 32:333, 1953.

Etiology of Heterophoria and Heterotropia

In heterophoria there is a relative deviation of the visual axes held in check by the fusion mechanism, whereas in heterotropia there is a manifest deviation of the visual axes. The relative position of the visual axes is determined by the equilibrium or disequilibrium of forces that keep the eyes properly aligned and of forces that disrupt this alignment. Clearly, the fusion mechanism and its anomalies are involved in some manner in producing comitant heterotropias. To understand the etiology of neuromuscular anomalies of the eyes, therefore, one should also gain an insight into other factors that determine the relative position of the visual axes.

First, there are *anatomical factors*, which consist of orientation, size, and shape of the orbits; size and shape of the globes; volume and viscosity of the retrobulbar tissue; functioning of the eye muscles as determined by their insertion, length, elasticity, and structure; and anatomical arrangement and condition of fasciae, ligaments, and pulleys of the orbit.

Second, there are *innervational factors*, that is, all the nervous impulses that reach the eyes. These factors include the co-movements of extraocular muscles with intrinsic ocular muscles, psych-optical reflexes (fixation reflex, fusional impulses), influences of the static apparatus on extraocular muscles and their tonus (endolymph, vestibular system, reflexes from neck muscles), and influences of the several nuclear and supranuclear areas that govern ocular motility.

Factors Responsible for the Manifestation of a Deviation

Abnormalities of Fusion Mechanism

DEFECT OF MOTOR FUSION IN INFANTILE ESOTROPIA. Motor fusion in patients with heterophoria is adequate to maintain a proper alignment of the eyes. This does not mean that patients with a heterophoria necessarily have normal sensory fusion. In those with higher degrees of heterophoria, suppression and a high stereoscopic threshold may be present, but motor responses are sufficient to keep the eyes aligned. In heterotropia this is not the case. These circumstances have led to a theory of the etiology of strabismus developed by Worth in 1903 in his famous book on squint.¹⁵⁶ His theory was that the essential cause of squint is a defect of the fusion faculty^{156, p. 55} and indeed is a congenital total absence of the fusion faculty.^{156, p. 61} Worth did not make a distinction between sensory and motor fusion.

Worth's theory has had an enormous influence on the thinking about strabismus, especially about essential infantile esotropia, but objections to it have been raised. In fact, Chavasse,²⁴ in editing the seventh edition of Worth's *Squint*, went so far as to say

We need no longer vainly genuflect before the fireless altar of "defect of the fusion faculty"; anymore than we need be content to regard lameness (with which strabismus has so much in common) as a defect of the

walking faculty [p. 2] . . . To many it will be a relief to see the exposure . . . of “congenital defect of fusion faculty” as a superstition which may have had its uses in the past [p. viii].

The comparison with lameness limps, as do most comparisons. Lameness may result from many causes, among them a defect in the “walking faculty,” that is, incoordination of the impulses to muscle, as in tabetic ataxia, or from paralysis of a muscle with contracture of the antagonist. In most instances, however, lameness has little in common with comitant strabismus.

To assess what Worth meant, one must reread what he wrote. He stated that when the fusion faculty is inadequate “the eyes are in a state of unstable equilibrium, ready to squint either inwards or outwards on slight provocation.”^{156, p. 55} Precipitating factors may be hypermetropia, anisometropia, motor anomalies, specific fevers, violent mental disturbances, injury during birth, occlusion, and hereditary factors. In other words, Worth makes no claims other than that the factors that lead to a latent deviation become manifest in the absence of a proper fusion mechanism. By general agreement, this is how heterophoria and heterotropia are defined.

One must admit that Worth’s proof for his concept of a *congenital* weakness of the fusion faculty^{156, p. 61} is not conclusive. He cited the example of a young patient with alternating esotropia and normal vision in each eye, no refractive error, and no detectable motor anomalies. Hypermetropia and mechanical elements therefore are excluded as etiologic factors. When tested with the amblyoscope, the patient suppressed the image from one eye and no amount of exercise enabled him to fuse the two images. The esotropia, Worth reasoned, must be the result of a congenital total absence of the fusion faculty when, in fact, this patient’s inability to fuse probably resulted from a well-established suppression mechanism rather than from a primary fusion defect. Indeed, considering that Worth, as stated above, did not make a distinction between sensory and motor fusion, one could conceive here that the original problem was in the motor fusion mechanism and that suppression took place as a consequence of the loss of ocular alignment. Another finding difficult to reconcile with a primary sensory fusion defect is the observation that some patients with essential infantile esotropia show a remarkably high degree of sensorimotor binocular cooperation (*subnormal binocular vision*)¹¹⁰ after surgical alignment of the eyes (see Chapter 16).

Modern psychophysical research in infants^{5, 134} has made it possible to add to the rather ancient theory of Worth. It has become evident that motor and sensory components of binocular vision such as visual acuity,⁶⁶ contrast sensitivity,^{8, 11} stereopsis,^{7, 68} and retinal disparity sensitivity (vergences)⁶⁷ are incompletely developed at birth (see also Chapter 11). The infantile visual system appears especially vulnerable to destabilization during this state of visual immaturity. The absence of a strong vergence control mechanism in the presence of a weak sensory input may explain the high prevalence of transient esotropias or exotropias in infants that later develop normal binocular vision.^{54, 109} With maturation of motor fusion, stabilization of ocular alignment occurs. However, if development of motor fusion is delayed or if motor fusion (i.e., the vergence system) is primarily defective, perhaps from genetically determined factors, esotropia may develop under the influence of a variety of strabismogenic causes.¹¹⁰ These may include excessive tonic convergence, hypermetropia, anisometropia, anomalies of the neural integrator for vergence movements, and other factors still unknown. Held,⁶⁷ who proposed a similar working hypothesis for the etiology of essential infantile esotropia (see also Helveston⁶⁹), points out that this theory, while speculative, has the advantage of being testable with available methods. Further reference to this theory is made in Chapter 16.

SENSORY OBSTACLES TO FUSION. Observations in older patients leave no doubt that interference with fusion may precipitate a manifest deviation in predisposed patients. The interference may be of peripheral or central origin and produce sensory or motor obstacles to fusion. Among the peripheral sensory obstacles are conditions that materially reduce the vision in one eye or the patching of either eye. A result of patching is well illustrated by the following example.

CASE 9-1.

A 14-year-old boy had a large chalazion of the right lower lid. After removal of the chalazion, he wore a bandage over the eye for 2 days. When the bandage was taken off he complained of diplopia. He now had an alternating esotropia of 40°. The visual acuity was 6/6 in each eye and a hypermetropia of +5.0 sphere D was present OU. He was given the refractive correction which he had never worn before and

fit-over base-out prisms that restored single binocular vision. The strength of the prisms was reduced every 2 or 3 days. After 2 weeks the manifest deviation had entirely disappeared, but an esophoria remained for distance of about 20^Δ, with correction. Both with and without correction, the boy had excellent fusional amplitudes and full stereopsis. The patient refused to wear his refractive correction. Since his vision was excellent, he had no symptoms and the glasses were in his way. Throughout 2 years of observation the condition remained unchanged. It should be added that the boy's older brother had been operated on for esotropia.

In essence, Case 9-1 demonstrates that a peripheral sensory obstacle, in this instance brief occlusion of one eye, is capable of precipitating a large manifest deviation when ordinarily a well-functioning fusion mechanism would prevent such an anomaly. A similar problem may also be caused by centrally acting factors, as shown by the following cases.

CASE 9-2.

A 17-year-old girl was thrown from her bicycle when it struck a tree. She sustained bruises and was somewhat dazed, but there were no serious injuries. As soon as she recovered from the initial shock, she noted diplopia. Examination on the day of the accident revealed standard visual acuity in each eye with her correction for myopia, no sign of a paresis or paralysis of an extraocular muscle, and an alternating exotropia of 18^Δ for distance. Single vision could be readily obtained with prisms. After a few days, spontaneous single binocular vision with good amplitudes and stereopsis was reestablished, but an exophoria of 15^Δ was evident on dissociation of the eyes.

CASE 9-3.

A 72-year-old woman began seeing double during an attack of pneumonia 10 years before being examined and had seen double thereafter. According to the ophthalmologist whom she consulted at the time and others who saw her subsequently, there was no evidence of a paralysis of an extraocular muscle. Examination revealed standard visual acuity in both eyes, a minimal refractive error (+0.25 sphere D OU), an alternating esotropia of 20^Δ without any sign of an inveterate paralysis, and good fusional amplitudes and stereopsis on the synoptophore. An operation was performed that relieved

the patient of the diplopia. Two years later she had an esophoria of 2^Δ for distance and 8^Δ of exophoria for near, with correction. Binocular cooperation was normal.

Cases 9-2 and 9-3 are examples of transient or permanent impairment of the fusion mechanism from traumatic or toxic causes. Toxic causes also may be the precipitating factors in heterotropias of childhood, although it is difficult to prove this point. In a significant number of cases it can be established only by the history. Parents are known to be prone to attribute an ocular deviation in their children to an incidental cause—a fall or disease. Yet, knowing how severe the toxic effect of diseases such as measles or whooping cough may be on the central nervous system, it is not unreasonable to formulate the hypothesis that these conditions may precipitate heterotropia in some children. This question will be brought up again in the discussion of the etiologic role of brain damage (see p. 141).

A more permanent interference with the fusion mechanism may cause *sensory heterotropia* in children and adults. There is controversy in the older literature at what age eso- or exotropia develops when there is visual loss in one eye as a consequence of, say, a congenital or traumatic cataract. We found that eso- and exotropia occur with equal frequency when the onset of unilateral visual loss occurs between birth and 5 years of age.¹³³ After that age, sensory exotropia predominates, and both sensory eso- and exotropia may be accompanied by a dissociated vertical deviation.^{15, 89} The reason a blind eye becomes esotropic in some patients and exotropic in others is not clear. Jampolsky⁷⁷ postulated that tonic divergence triggered by blurred peripheral and macular images in one eye relative to the other eye causes the eye with poor vision to diverge. This theory does not explain the mechanism of sensory esotropia. Other authors have blamed the degree of loss of visual acuity¹⁸ or the type of underlying refractive error^{24, p. 172} for the direction of the deviation. However, we were unable to establish a correlation between these factors and the occurrence of sensory esotropia or exotropia.¹³³

COMITANT STRABISMUS AS A RESULT OF HORROR FUSIONIS AND DIPLOPIAPHOBIA.

Horror fusionis is a term used by Bielschowsky^{16, p. 72} for a specific phenomenon—avoidance of bifoveal stimulation. Historically, this subject

was dealt with first by von Graefe in 1854,⁶⁰ when he introduced the term “reluctance to see singly” (*Widerwillen gegen Einfachsehen*) and was later mentioned by Javal who, in 1896, spoke of “repulsion of images.”⁷⁹ The term *horror fusionis* should not be loosely applied to other forms of absent or deficient sensory fusion. The phenomenon can be observed when images presented to the eyes are moved slowly toward each other by means of a haploscopic arrangement or rotary prisms. One eye maintains fixation while the image in the fellow eye is moved across the retina closer to the fovea. The distance between the two images is gradually reduced until the image in each eye is close to or on the fovea. At that moment the two images separate more widely, and no amount of manipulation of the devices brings about a superposition of the two foveal images. The patient rejects bifoveal stimulation whenever it is attempted. Bielschowsky^{16, p. 72} ascribed the change in distance of the double images to variations in the deviation. He thought that two images localized in the same direction without being fused caused a feeling of discomfort that the patient instinctively endeavored to avoid by changing the angle of squint. Bielschowsky^{16, p. 73} also believed that horror fusionis might be caused by defective development of sensory connections in the visual cortex.

There is little doubt that horror fusionis is caused by a change in the angle of strabismus, and in our experience the condition is quite rare except when elicited artificially. For instance, many orthoptists are acquainted with what they call “chasing,” that is, the continual increase in deviation in tests with a major amblyoscope whenever the stimulus in the deviated eye is placed on or near the fovea in the deviated eye. This phenomenon could also be attributed to some sort of anomalous disparity-induced vergence mechanism and be identical or at least similar to the “eating up” of prisms.²¹

Avoidance or active rejection of bifoveal stimulation may not be achieved solely by changes in the deviation. Bielschowsky's definition of horror fusionis may be enlarged by including deepening of suppression and changes in the mode of localization whenever bifoveal stimulations are attempted. The clinical aspects of horror fusionis were discussed in a monograph by Hamburger.⁶⁴

The possibility has been mentioned in the older literature that this aversion to bifoveal stimulation conceivably is an etiologic factor in strabismus.

Horror fusionis would then belong to the group of etiologic factors that produce what has been called a *purposive strabismus*,^{24, p. 125} comparable to the *diplopiaphobia* of van der Hoeve.¹⁵⁰ Van der Hoeve reasoned that if a child did not have a strong fusion mechanism, the result would be double vision. Because diplopia is most disturbing, the child would soon instinctively find it less annoying if one eye were turned so as to bring the image of the fixated object on a more peripheral retinal area of low visual acuity. As a result, the child would acquire a constant strabismus, having followed an active separatist policy, as Chavasse^{24, p. 125} so colorfully described it. A similar active policy may arise from a horror fusionis, but the likelihood of this being the case is remote.

Reflexologic Theories

The concept of fusion does not mean the same to all authors. To some, fusion is preformed anatomically and physiologically as a constitutional characteristic of the individual. To others, fusion is acquired by usage. To those who hold this latter view, the concept of a congenitally defective or absent fusion mechanism is not acceptable. To Chavasse,^{24, p. 80} fusion was an overt motor response of the eyes based on conditioned reflexes and as such was acquired by usage. Sensory fusion, distinct from motor fusion, was not recognized by him. Chavasse believed that peripheral or central interference with development of binocular reflexes causes an anomaly of these reflexes, expressed in a relative deviation of the visual axes. If the interference lasts beyond the plastic stage in development of a child, proper reflexes can no longer be acquired by therapy. Nonsurgical, orthoptic treatment aimed at restoration of binocular vision is useless once the child is no longer in the plastic stage. This type of reasoning has widespread appeal. One may hear it said, for example, that a functional cure was achieved because of late onset of the deviation and that the child had an opportunity to gain binocular experience.

Another strongly reflexologic view was championed by Keiner,⁸¹ who believed the causative factor in strabismus to be a disturbance of the optomotor reflexes, following the teaching of Zeman.¹⁵⁷ Keiner stated that optomotor reflexes determine relative position of the eyes in the course of postnatal development. He recognized a monocular duction reflex grafted on the proprioceptive

reflex pathway, a binocular reflex for versions grafted on the vestibular reflex pathway, and a convergence reflex also grafted on the proprioceptive reflex pathway. According to Zeeman and Keiner, the position of the eyes in the orbit during fetal life depends on stimuli originating chiefly in the proprioceptive and enteroceptive fields and the labyrinths. With birth comes light—a powerful conditioning stimulus that determines the function of the foveae and the cooperation of the homonymous halves of the retinas through development of optomotor reflexes. After a short transitional period (during which the eyes of all infants have only dissociated movements), the optomotor reflexes supersede older subcortical reflexes and soon take precedence in determination of the position of the eyes in space (binocular reflexes) or in the orbit (monocular reflexes). The directing and coupling process, initiated by optomotor reflexes, eventually leads to full motor and sensory coordination of the eyes; in the infant, eyes change from a state of dissociation to a state of association. The abnormal position of eyes in convergent strabismus is a consequence of abnormal development of optomotor reflexes and consists of a predominance of monocular adduction reflexes over those for conjugate movements and abduction.

Keiner⁸¹ concluded from his studies that all neonates are potential squinters and that this universal disposition is offset in the first 18 months of life unless interfered with by endogenous or exogenous factors. Keiner thought that the cause for disturbance of development of optomotor reflexes might be a delay in the process of myelination of pathways, a possibility that had been alluded to as early as 1897 by Steffan.¹³⁹ These thoughts are not entirely at odds with our current thinking on the etiology of infantile esotropia according to which a delay in the development of motor fusion, which could conceivably be caused by a delay in the myelination of the pathways for vergences may be responsible for this condition (see p. 135) Lang⁹² also blames a delay of myelination or difficulties in coordination between ocular and vestibular influences on a nasal fixation bias which in turn causes infantile esotropia.

Factors Causing the Underlying Deviation

Mechanical (Muscular) Theories

At the beginning of scientific ophthalmology, the first theories were that mechanical or muscular

malfunction caused comitant strabismus. They superseded earlier physiologically oriented theories, which were largely speculative and even fantastic. The mechanical theories arose largely because of the development around 1840 of an operative procedure for successfully correcting horizontal deviations. Since deviations could be corrected by mechanical means, it seemed reasonable to assume that mechanical factors were responsible for them. These mechanical factors were held responsible for anomalies affecting the action of antagonistic muscles due to disproportions in their structure, length, cross section (mass), and elasticity, or to anomalies of the insertions. Structural anomalies of the orbits and orbital tissues were also taken into consideration.

In subsequent years the foremost exponents of the muscular theory of the etiology of comitant strabismus have been Scobee¹³¹ and Nordlöw.^{113, 114} Scobee was of the opinion that in 90% of patients with heterotropia there is an underlying anatomical cause for the deviation. He observed anomalies of the check ligaments that consisted of thickening, fusion, and posterior extension on the muscles and supernumerary muscle slips and footplates on otherwise normal-appearing insertions. These footplates were described as attaching the muscle to the globe anywhere from 2 to 7 mm behind its insertion. They corresponded in all probability to structures described much earlier by Motais¹⁰⁰ (see p. 40). Scobee pointed out that the effect of these anomalies was to prevent relaxation of the antagonist of the affected muscle, and he believed that existence of the anomalies had a bearing on the type of operation to be performed. Since anatomical anomalies cannot be detected during preoperative examination of the patient, Scobee suggested that the decision about the type of operative procedure should be made while the patient is on the operating table following a forced duction test by which the passive mobility of the globes can be determined.¹³¹ It is of interest that the concept of etiologic significance of primary structural alterations in the extraocular muscles of strabismic patients is upheld by contemporary authors. Domenici and coworkers⁴³ described alterations of both contractile structures and mitochondria, more pronounced at the scleral myotendinous junction than in the actual muscle belly, in patients with infantile esotropia. Corsi and coworkers²⁹ reported on alterations of extraocular muscle proprioceptors in this patient group.

In most patients it is impossible during an

office examination to establish the presence or absence of anatomical abnormalities, but certain important facts can be uncovered about functioning of the muscles. In many patients with heterotropia, varying degrees of excessive or defective excursions of the globe can be observed. The extent to which the eyes are capable of rotating is important not only in determining the best operative approach but also has a bearing on the etiology of strabismus.

The first to take into account the behavior of the rotations, that is, the extent and position of the monocular and binocular field of fixation in strabismus, was von Graefe.⁶¹ He stated that in comitant strabismus the amplitudes of the excursions were normal in extent but that their midpoint was displaced nasalward in esotropia and templeward in exotropia. In this von Graefe saw support for his muscular theory of strabismus. According to this theory strabismus is caused by disproportion in the mean length of the different extraocular muscles. Landolt⁹¹ also emphasized the importance of determining the amplitude of the horizontal excursions, but he⁹⁰ and other supporters of the accommodative theory of strabismus believed that displacement of the excursions was secondary, occurred gradually under the influence of convergence and accommodation, and resulted eventually in contractures of the muscles.

The most exhaustive studies of the horizontal excursions were made by Hesse⁷² and by Nordl w.¹¹³ Hesse confirmed von Graefe's theory⁶¹ regarding the horizontal excursions in esotropia and exotropia and found that in 70% of the cases there was agreement between the displacement and the angle of squint within the limits of error of the method (5°). Hesse did not evaluate his material from the point of view of etiology. He was interested in the changes in position of the midpoint of the excursions following operative procedures.

Nordl w,¹¹³ on the other hand, undertook his painstaking study with special regard for the etiology of comitant esotropia. He investigated statistically the visual acuity, refraction, angle of squint, horizontal excursions, fusional amplitudes, retinal correspondence, and depth perception in a group of normal subjects and in a group of squinters. Nordl w found in the normal subjects no statistically significant difference in horizontal excursions between the right and left eyes or between adults and children. For each subject there was good agreement between the heterophoric position

and displacement of the midpoint of horizontal excursion of the eyes. Nordl w considered this displacement to be an expression of the heterophoric position. A nasal displacement of horizontal excursions of normal amplitude could only be explained on the basis of mechanical factors. Nordl w concluded from his study that at the time of onset of a constant esotropia mechanical factors are present that produce a strabismus even if the fusion mechanism is normal. In constant strabismus the refractive factor plays a subordinate role.

One of the main arguments of Scobee¹³¹ and Nordl w¹¹⁴ in favor of mechanical (muscular), possibly hereditary, causes of strabismus is the frequency with which onset of esotropia occurred at birth or in early infancy. Curiously, this same observation convinced Keiner that mechanical factors could not be held responsible. The diametrically opposed inferences drawn by these authors from the same premise would indicate that there is no conclusive evidence for either theory.

Structural Anomalies of Extraocular Muscles

A discussion of mechanical theories would be incomplete without reference to the fact that congenital or acquired anomalies of extraocular muscles or adjacent orbital structures may cause strabismus. Among these anomalies are acquired myopathies, acquired and congenital fibrosis, fractures of the orbital bones, Brown syndrome, and many others that are discussed in detail in the appropriate chapters of this book. Systemic diseases such as sarcoidosis^{28, 137} or tumor metastases^{13, 59} may affect extraocular muscle and produce manifest strabismus.

Congenital absence (agenesis) or anomalous insertion of one or several extraocular muscles is described in Chapter 3. This anomaly, often unsuspected by the ophthalmologist during preoperative evaluation of the patient, may not become apparent until the time of surgery and a swift decision may then be required by the surgeon regarding alternative surgical approaches. If muscle surgery is contemplated in a patient with Crouzon's disease, agenesis or anomalous insertion of extraocular muscles must always be suspected because these variations are very prevalent in such cases.^{40, 136}

Role of Accommodation and Refraction in Comitant Strabismus

When Donders⁴⁴ discovered the close relationship between accommodation and convergence, he also

provided the means for understanding a frequent cause of heterotropia. This relationship was treated in detail in Chapter 5. The reader will recall that whenever a given amount of accommodation is exerted, a well-defined amount of convergence (called *accommodative convergence*) is coupled with it. An excessive amount of accommodation, required to clear the retinal image at a given fixation distance, generates an excessive amount of accommodative convergence. This occurs, for example, in the uncorrected hypermetrope. Accordingly, one generally finds an esophoria present in uncorrected hypermetropes and an exophoria in uncorrected myopes; however, neither excessive nor deficient convergence impulses *in themselves* lead to esotropia or exotropia. The vast majority of people have adequate motor fusion and therefore are not heterotropic; but if the fusional amplitudes are inadequate or if the fusion mechanism is impaired by some sensory obstacle, the eyes may deviate. Once fusion has broken down, all other etiologic factors (mechanical and innervational as well as accommodative) gain free rein and a heterotropia is established. At first it may be intermittent, but in time it will become constant.

Refractive errors, through their effect on accommodation, are without doubt one of the prime causes of misalignment of the eyes. Removal of the deviation by corrective lenses in one third of the patients with comitant esotropia is simple and direct evidence for this.

To be sure, Donders's theory⁴⁴ since its inception has found critics who demonstrated that there are esotropes who are emmetropic or even myopic and exotropes who are hypermetropic. Other critics have pointed out that there is no correlation between the amount of the refractive error and the size of the deviation. All this is quite true, but it does not affect the soundness of Donders's theory. First of all, there is a group of patients who have an esotropia that is not accommodative in origin to which Donders's theory does not apply, but there remain two thirds to whom it does apply. Furthermore, the amount of deviation induced by accommodation depends on the individual's responsiveness, that is, his or her accommodative convergence/accommodation (AC/A) ratio (see Chapter 5). If the AC/A ratio is high or very high, large deviations will occur regardless of the refractive error. Also, patients with moderate hypermetropic errors (2D to 3D) frequently have a high AC/A ratio, whereas patients with high

hypermetropia (5D or more) frequently have a low AC/A ratio.¹¹²

All these matters must be understood to evaluate Donders's theory in the somewhat expanded form presented in this chapter. Solidly based on physiologic facts and clinical observations, his remains the best-substantiated theory of the cause of certain types of strabismus (see also Chapter 16).

Fixation Disparity

The possibility that a relationship exists between fixation disparity (p. 21) and heterophoria was suggested many years ago by Ames and Gliddon⁴ who used the term "retinal slip" to describe what is now known as *fixation disparity*. They found fixation disparity associated with heterophorias, but exceptions were observed in patients with exophoria or esophoria in whom disparity was not noted.

Jampolsky and coworkers⁷⁸ investigated the possibility of quantitatively expressing the relationship between fixation disparity and heterophoria. They found that while the direction and magnitude of the disparity in esodeviations correlated well with the direction and magnitude of the heterophoria, such a relationship could not be established for exophorias. In fact, in many patients, exophoria was associated with esodisparity.

Crone³⁰⁻³³ also implied a close relationship between fixation disparity and heterophorias. Using the technique of Ogle and coworkers¹¹⁵ he demonstrated that esodisparity is present in patients with esophoria and exodisparity with exophoria. However, using an experimental method that interferes only minimally with the condition of casual seeing (phase difference haploscopy), Palmer and von Noorden¹¹⁷ showed that small degrees of heterophoria do not necessarily produce fixation disparity and that fixation disparity does not necessarily sustain heterophoria.

The possible role of fixation disparity in the etiology of heterophorias is far from being settled. Convincing data are lacking that indicate a consistent qualitative and quantitative relationship between fixation disparity and heterophorias in all directions of gaze as well as the absence of fixation disparity in orthophoric subjects. Far-reaching and in our opinion often unsupported conclusions have been drawn with respect to the etiology of heterophoria from an experimental situation in which the fusible material in the central or periph-

eral field of vision of an observer was artificially reduced or in which fixation disparity was artificially provoked by stressing motor fusion with prisms or lens-induced vergences. The available evidence is insufficient to establish that fixation disparity is anything more than a physiologic variant of normal binocular vision. This should not distract from the value of lens-induced fixation disparity as a laboratory method for determination of the AC/A ratio (see Chapter 5).

Other Innervational (Neurologic) Factors in Comitant Strabismus

Innervational causes have been implicated in the etiology and pathogenesis of strabismus ever since the inception of scientific ophthalmology. They were recognized in general terms as early as 1855 by Mackenzie,⁹⁸ who stated that

The cause of strabismus should be sought elsewhere than in the muscles of the eyes, elsewhere than in the retina; that is to say in the brain and nerves, organs which preside over the association of acts of the muscles of the eyes.

Donders's theory suggests that a specific innervational mechanism exists for esotropia. Adler³ found that one third of the patients with comitant esotropia fit Donders's theory and fell into the purely accommodative class. In another third the accommodative element was more or less prominent. The nonaccommodative element in this latter group and in the remaining one third, in whom no contributing accommodative element is found, requires an explanation. It is to these patients that musculomechanical interpretations of the deviation have been applied by some workers. Others also have alleged innervational causes for the nonaccommodative factor of the deviation.

PARETIC ELEMENTS. Snellen¹³⁵ held that nonaccommodative comitant heterotropia in all cases should be considered paralytic in origin in the absence of a better explanation of its pathogenesis. Since Snellen, several investigators have concurred with his opinion.

Paresis of an extraocular muscle may lead to paralytic strabismus. With diminution of the paresis, the paralytic strabismus tends to acquire characteristics of a comitant strabismus, and this is known as *spread of comitance* (see Chapter 18). There is no doubt that a certain number of cases of strabismus that are connatal or appear in early infancy are indeed paretic in origin because of a

paresis of a horizontal rectus muscle. However, one should not unduly stretch this hypothesis to cover all cases of infantile nonaccommodative strabismus.

A vertical deviation also may reasonably be assumed to be the immediate cause of a horizontal strabismus. A paresis or paralysis of a vertically acting muscle is a gross obstacle to fusion, and one almost invariably finds that in an adult with acquired paralysis of such a muscle a horizontal deviation is also present because the preexisting heterophoria has become manifest.

ANOMALIES OF THE BRAINSTEM. The intriguing possibility has been raised that infantile strabismus may be caused by a congenital defect in neural wiring of the brain stem that could impede the function of recently discovered integrating systems.⁹⁵ These systems include the nucleus prepositus and interneurons of the abducens nucleus which connect the pontine horizontal gaze center with the motor neuron of the medial rectus muscles. The nucleus prepositus receives visual input as well as information on eye position and movement. It acts as an interface between the vestibular nuclei and the cerebellum. Although there is no evidence to implicate the nucleus prepositus, it could be functionally capable of initiating events that lead to ocular misalignment.¹⁰

ANOMALIES OF CONVERGENCE AND DIVERGENCE. An excess of convergence or divergence innervation from anomalies of the subcortical centers and pathways for convergence and divergence have been implicated as a cause of strabismus by prominent authors of the past.^{1, 118} The clinically useful classification of horizontal strabismus into convergence and divergence excess and insufficiency by Duane⁴⁵ (see Chapter 8) has similar connotations. The high probability cannot be denied that certain forms of esotropia, for instance, hyperaccommodative, hypoaccommodative, and nonaccommodative convergence excess (see Chapter 16), or the nystagmus compensation syndrome (see Chapter 23), are caused by an excess of convergence or that divergence insufficiency (see Chapter 22) is caused by a lack of divergence innervation. However, there is little to support the notion that other forms of esotropia or exotropia are caused by similar mechanisms. For this reason, as well as to avoid any false etiologic implications, we believe that the terms *esotropia* and *exotropia* employed in English are preferable to *convergent*

or *divergent strabismus*, as used in the European literature.

VESTIBULAR SYSTEM. Doden⁴¹ studied spontaneous nystagmus and optokinetic and postrotary vestibular nystagmus and found abnormalities in about 40% of patients with comitant strabismus. Salman and von Noorden¹²⁷ reported abnormal responses to caloric stimulation in children with dissociated vertical deviations, congenital esotropia, or both. These anomalies consisted of postcaloric nystagmus of irregular amplitude and frequency, vestibular hyperexcitability, and irregular eye movements with the eyes closed and at rest. According to Doden, a primary disturbance in optomotor coordination exists in these children. He sought the cause of the primary motor incoordination in children with genetically determined or acquired abnormalities and found birth injuries to be predominant among the acquired abnormalities. A normally developed sensory system can compensate for the deficiency of motor coordination. When accessory factors (hypermetropia, reduced fusion ability caused by general weakness of the patient, and anatomical anomalies) are present, a manifest deviation develops.

Hoyt⁷⁵ reevaluated the vestibular system in strabismic children by studying the vestibulo-ocular response in congenital esotropia. He described this response to be consistently abnormal in these patients, which is in contrast to the normal response obtained from children with the nystagmus blockage syndrome (see Chapter 23). However, these findings do not necessarily indicate that dysfunction of the vestibular system is a primary cause of infantile esotropia.

Safran and coworkers¹²⁶ described an "ocular tilt reaction," which occurs in a number of clinical conditions that are believed to be related to alterations in the otolithic or vertical semicircular canal pathway, or both. This type of strabismus shows a prominent vertical component associated with a change in the perception of verticality, conjugate cyclotorsion of the eyes, and a head tilt.

ANOMALIES OF THE VISUAL PATHWAYS. In normal subjects optokinetic nystagmus is elicited with equal facility, regardless of whether the optokinetic targets move in a nasotemporal or temporonasal direction. In esotropes, patients with dissociated vertical deviations, and occasionally in exotropes, the optokinetically elicited pursuit movement is either absent or abnormal when the stimulus moves in a temporal direction (optoki-

netic asymmetry.^{36, 103, 143-152} This finding has been interpreted as being indicative of anomalies involving the visual motion processing centers of the primary and extrastriate cortex, which, in turn, are responsible for the strabismus.^{144, 147} We¹¹¹ and others¹³² have proposed a different mechanism and suggested that this asymmetry, which is a normal finding in visually immature infants,^{6, 108} is the consequence of disruption of normal binocular vision early in life, rather than the manifestation of a primary structural anomaly of the brain. The absence of normal binocular input during infancy disrupts maturation of the visual pathways, and the immature stage of the optokinetic response, with its nasotemporal asymmetry, persists. This view is supported by the establishment of a direct relationship between the presence of optokinetic asymmetry and the age at which the strabismus becomes manifest³⁶ (see also Chapter 16). Another reason we think that optokinetic asymmetry is the consequence of strabismus rather than the manifestation of a primary anomaly of the motion-processing ability is the finding that this asymmetry also occurs in nonstrabismic children who lose sight in one eye prior to the sixth month of life.⁶³

Kommerell⁸⁵ suspects a common mechanism for the optokinetic asymmetry and manifest-latent nystagmus in patients with infantile esotropia (see Chapter 16). He believes that cortical binocularity is impaired in such patients, either because of a primary defect or as a consequence of the esotropia. Reduced binocularity prevents signal transmission from the visual cortex to the brain stem as evidenced by maldevelopment of slip control of the retinal image. This slip explains the defective optokinetic response to monocularly viewed and temporally directed visual targets. This asymmetry is also evident in the latent nystagmus with a tonic preponderance directed nasalward with reference to the fixating eye. The adduction preference of the fixating eye is said to be due to a superimposed gaze innervation with the purpose of dampening the nystagmus. However, the question remains open why manifest-latent nystagmus occurs only in some patients with infantile esotropia, whereas optokinetic asymmetry is a consistent feature of this condition.

The demonstration of abnormal visually evoked responses (VERs) by some authors⁵¹ (unconfirmed by others¹⁰²) have added further to speculations that some patients with strabismus have structural anomalies of the brain. This notion has gained additional support because of the association of

optokinetic asymmetry and strabismus with misdirection of the retinogeniculate pathways in patients with albinism.^{27, 38} However, some persons with albinism have the capacity for binocular visual processing, as well as for fusion and global stereopsis, despite misrouted temporal retinal fibers.

Tychsen¹⁴⁵ described marked reduction of the connections between neighboring cortical dominance columns in macaque monkeys with a naturally occurring esotropia that resembled human infantile esotropia in many respects. He believes that these changes may actually be the cause of the motor signs of infantile strabismus. However, he also deems it possible that these anomalies are purely secondary and the result of abnormal binocular experience during visual infancy. *There are no convincing data at this time to link primary structural anomalies of the brain with the etiology of essential infantile esotropia.*

Lang⁹² believes that manifest-latent nystagmus and infantile esotropia have a common etiologic denominator. He stated that the nystagmus is driven by a functional preponderance of the nasal half of the retina because of prematurity, birth trauma, or from "other causes." This functional nasal preponderance of the retinas is said to be reminiscent of a phylogenetically and ontogenetically older visual system with uncrossed fibers. It causes children to take up fixation with either eye in nasally eccentric areas shortly after birth. During the first few months the fixation area then moves toward the foveola but the tendency for the image to drift nasalward persists, causing latent nystagmus during monocular viewing. In discussing this theory Kommerell⁸⁵ pointed out that it is difficult to explain why the slow drifts of the nystagmus are toward the allegedly functionally superior nasal half of the retina when the opposite (a fast corrective saccade) should actually be expected. To this we add our concern about the difficulties involved in determining nasally eccentric fixation reliably in an infant. The observations that infantile esotropia is rarely present at birth (see Chapter 16) but typically develops during the first trimester is also difficult to reconcile with this hypothesis. The pronounced nasotemporal asymmetry of differential light threshold in patients with infantile esotropia (see Herzau and Starc⁷⁰), favoring the temporal hemifield, must be considered as a consequence of abnormal visual experience early in life rather than as a evidence

for a primary functional preponderance of the nasal retina.

Brain Damage

Doden⁴¹ suggested that the etiology of strabismus should be clearly distinguished from its pathogenesis, that is, from mechanisms immediately responsible for this anomaly. In his view, disturbance of the optomotor coordination is the pathogenetic factor, whereas birth injuries and other endogenous or exogenous influences are etiologic factors.

This theory, then, relates strabismus to brain damage. With regard to brain damage there are two opposing camps. Bielschowsky^{16, p. 59} did not think enuresis and left-handedness were more frequent in strabismic than in nonstrabismic children. This opinion was based on a study by his pupil Lippmann,⁹⁷ who made a detailed analysis in 2086 cases of "stigmata of degeneration" and laterality in their significance for strabismus. On the other hand, Lessel⁹⁶ (see also Firth⁴⁹), who reported in more recent studies an increased prevalence of left-handed and ambidextrous persons in an esotropic population, felt that brain asymmetry or anomalous wiring of the visual system may be the cause of esotropia in some patients. Burian and coworkers,²⁰ in studying the higher visual functions in patients with amblyopia, and Burian,¹⁹ in investigating the relation of eyedness and handedness in amblyopic patients, did not find evidence that these patients belonged in the class of brain-damaged persons. A recent review¹²³ of studies conducted between 1934 and 1986 showed that the average percentage of right-handedness in the strabismic population was 73.8% and of right-eyedness, 46.9%. Both of these percentages are considerably lower than in the general population and the author of this review offered the hypothesis that reduced right dominance in the strabismic population may result from dysfunction of the otoliths or their higher brain stem pathways, or of both.¹²³

One could cite the high prevalence of strabismus associated with mental retardation and especially with Down syndrome to make a point for brain damage as a contributing factor to the etiology of strabismus. Fisher⁵⁰ reported a prevalence of 22% of mental retardation associated with *infantile esotropia* without indicating, however, how many of the retarded children had Down syndrome. According to other authors the prevalence

of strabismus in Down syndrome ranges between 21%¹⁴ and 57%.²²

Vontobel¹⁵³ pointed to the high prevalence of hypermetropia in Down syndrome, compared with the frequency of hypermetropia among institutionalized mentally defective patients.⁸⁷ The same point was made by other authors who emphasized that inhibition of growth of the eye, to which they ascribed the hypermetropia, is in accordance with the generalized inhibition of growth in children with Down syndrome. The high incidence of hypermetropia in brain-damaged children and in educationally subnormal children has also been emphasized by other authors.^{48, 57, 80} In contrast to these findings, Caputo and coworkers²² found an about equal distribution of hypermetropia and myopia in 187 patients with Down syndrome.

Unger¹⁴⁹ believed that a general motor retardation, found in a large number of strabismic children, was the most convincing expression of early brain damage and that this damage was mainly attributable to exogenous causes. Prominent among these causes were birth injuries following complicated births, in which he reported 45% of 300 patients as being strabismic. A high incidence of strabismus among children who had sustained a birth trauma was also reported by other authors.^{65, 71, 125, 130, 142}

In marked contrast to these data are the figures of Richter,^{124, p. 72} who found among 542 mothers of strabismic children only 5.9% with a history of abnormalities of pregnancy and 9.4% with a history of complicated deliveries. In a control series of 53 mothers of children without strabismus who were seen for external eye diseases or ocular injuries, the corresponding figures were 7.5% and 11.7%, respectively. Richter concluded that the frequency of exogenous factors to which strabismus might be attributed is no greater in these children than in nonsquinting children.

Gardiner and Joseph⁵⁸ reported an interesting association between congenital heart lesions and eye defects. Of 85 children, all over 6 years of age, examined by these authors, 12 (14%) had strabismus. It is significant that of the cyanotic group (tetralogy of Fallot) 24% were so affected, whereas in the noncyanotic group only 12% were heterotropic. In any event, the frequency of strabismus in this population is four to six times higher than in the general population. It is difficult not to attribute to this nonhereditary factor a causative role in the appearance of the strabismus.

In further support of the etiologic role of brain

damage as a cause of certain forms of nonhereditary strabismus is the high prevalence of strabismus in children with cerebral palsy and premature birth. Numerous studies, quoted in a review by Hiles and coworkers,⁷³ cite the prevalence of strabismus in patients with cerebral palsy as ranging from 15% to 62%, with a 44% average in the 1953–1965 surveys. Esotropia occurred about three times more often than exotropia in these patients. A peculiar fluctuation between esotropia and exotropia, which is not seen in the neurologically “normal” strabismic population, may appear in these children and must be taken into consideration when planning surgical therapy.¹²⁸

Gallo and Lennerstrand⁵⁵ reported a prevalence of strabismus of 9.9% in 528 premature children as compared with a prevalence of 2.1% in 1047 full-term children. Excluding those with severe regressed retinopathy of prematurity (ROP) and reduced visual acuity, the prevalence was 8.5% and 11%.^{56, 82} Esotropia occurred about twice as frequently as exotropia, and the prevalence of refractive errors and of nystagmus was also higher than in normal subjects.⁵⁶ Including children with retinopathy increased the prevalence to 14.7% in the first year of life in another study of 3030 premature infants enrolled in the Multicenter Trial of Cryotherapy for Retinopathy of Prematurity.¹⁷ There was a correlation between the seat and stage of ROP, which indicates that the strabismus was sensory in some patients and thus only indirectly related to ROP. A high prevalence (20.7%) of strabismus in children with very low birth weight was also noted by Pott and coworkers.¹²¹ However, the *infantile esotropia* syndrome occurred in only 1.9% of this group, which is not more frequent than what has been reported in normal children and indicates that brain damage does not play an important role in this particular condition. These findings are in contrast with another study in which infantile esotropia occurred more frequently in children with low birth weight and prematurity than in normal controls.¹⁰⁵

Brain injuries also may affect the centers for motor fusion and cause strabismus. Such patients become incapable of single binocular vision for any length of time. After momentary superimposition of the double images, the eyes will begin to drift into a position of small angle esotropia or exotropia and diplopia will occur. Fusional amplitudes are severely reduced or absent altogether. Jaensch⁷⁶ first described this condition in 1935, and several other studies were published later.^{42, 122, 138}

We have found this disorder in patients who had suffered head trauma, usually followed by periods of unconsciousness, and refer to it as *post-traumatic fusion deficiency*.⁹ The clinical features of this condition are discussed in Chapter 22.

The common association of latent and manifest-latent nystagmus and *infantile esotropia* (see Chapters 16 and 23) may also be interpreted as evidence for primary brain dysfunction. However, Kommerell⁸⁴ pointed out that latent nystagmus and optokinetic asymmetry may occur also as a consequence of strabismus⁸⁵ and the occurrence of manifest-latent nystagmus is not limited to esotropic patients.

As discussed, there is sufficient evidence that strabismus occurs with increased frequency in a population afflicted with brain damage. However, care must be taken to not imply to parents that children with strabismus who are apparently normal in all other respects are “brain-damaged.” This may evoke unfounded parental anxiety or guilt feelings. Unless more becomes known about the nature of the disturbance causing the strabismus in Down syndrome, mental retardation, or prematurity, it suffices to mention the frequent association of these conditions with strabismus.

Embryopathy

In view of the high prevalence of ocular and systemic malformations associated with Duane’s syndrome (see Chapter 21) it has been surmised for some time^{34, 86} that certain forms of strabismus may be caused by a teratogen. This theory has found firm support in the findings of a high prevalence of Duane’s syndrome in *thalidomide embryopathy*.^{104, 141} Since this entity may also be associated with Möbius syndrome, isolated lateral rectus palsy, or horizontal gaze paresis, Miller¹⁰⁴ suggested that certain forms of incomitant horizontal strabismus may result from a developmental disturbance beginning early in the fourth week of gestation and extending over the next 4 to 5 days.

In a recent multidisciplinary and multi-institutional study²⁵ the risk factors for esotropia and exotropia were examined in a cohort of 39,227 children, followed from gestation to the age of 7 years. The incidence of esotropia was 3% and of exotropia 1.2%. Maternal *cigarette smoking* during pregnancy and low birth weight were independent and important risk factors for both esotropia and exotropia. There was a clear correlation be-

tween the number of cigarettes smoked per day and the risk of developing horizontal strabismus. The types of strabismus (e.g., accommodative vs. nonaccommodative, infantile vs. late acquired strabismus) were not further identified and the etiologic connection remains unclear at this time.

A high prevalence of strabismus in children afflicted by the *fetal alcohol syndrome* has also been noted.^{23, 140}

Facial and Orbital Deformities

The common association of horizontal or cyclovertical strabismus with craniofacial dysostoses (oxycephaly, Crouzon’s disease, plagiocephaly)⁶² or the association of certain forms of A- or V-pattern types of strabismus with anomalies of the lid fissures clearly implicates anomalies of the bony orbit in the pathogenesis of certain forms of strabismus. The role of desagittalization of the oblique muscles in patients with plagiocephaly and hydrocephalus causes dysfunction of the oblique muscles and may result in cyclovertical strabismus (see Chapter 19). Rotation of the entire orbit along with the globe or *heterotopia of muscle pulleys* (see Chapter 3) will change the action of the extraocular muscles as will be discussed in connection with apparent dysfunctions of the oblique muscles (see Chapter 18) and A- and V-pattern strabismus (see Chapter 19). Orbital lesions, for example, fibrous dysplasia,¹⁰⁶ may push on the globe, restrict ocular motility, and cause strabismus. Enlargement of the globe itself in high myopia will limit rotation of the eye because its posterior pole collides with the orbital walls or the paths of some muscles has been altered³⁷ (see Chapter 21).

Genetics of Comitant Strabismus

Every ophthalmologist is aware that strabismus often affects more than one member of a family. This observation goes back to antiquity. Indeed, Hippocrates wrote: “We know that bald persons descend from bald persons; blue-eyed persons from blue-eyed persons, and squinting children from squinting parents”⁷⁴ An amusing though quite chauvinistic account of how the causes of congenital strabismus were viewed over 400 years ago is found in the first printed textbook of oph-

thalmology published in 1583 by G. Bartisch¹² (Fig. 9–1).

The incidence of hereditary strabismus in a strabismic population has been estimated as 30% to 70%. In spite of the seemingly obvious hereditary nature of strabismus and the vast literature on the subject, fully reported in the volumes of François,⁵³ Waardenburg,¹⁵⁴, p. 1009 and Klein and Franceschetti,⁸³ the mode of inheritance is by no means clear because of the nature and frequency of the condition and the methods used to study the pattern of its inheritance. Almost without exception, writers on the subject have attempted to find the mode of inheritance of manifest deviation.

There is no reason to believe that the manifest deviation as such is heritable. What very likely is heritable is the condition underlying the deviation,

the cause of the “disease” strabismus, which, depending on circumstances, may or may not lead to a manifest deviation.

To be sure, it is impossible to look for the cause of strabismus, as there is no single cause for all forms. We know that a variety of causes, singly or combined, may lead to a deviation, manifest or otherwise. Mechanical (musculofascial) anomalies, paretic factors, anomalies in the version system and in the systems for convergence or divergence connected or not connected with the function of accommodation and refraction of the eyes, other anomalies in the optomotor system, and anomalies in the sensory system are all more or less well-documented factors in the cause of strabismus.

In spite of these and many other factors identi-

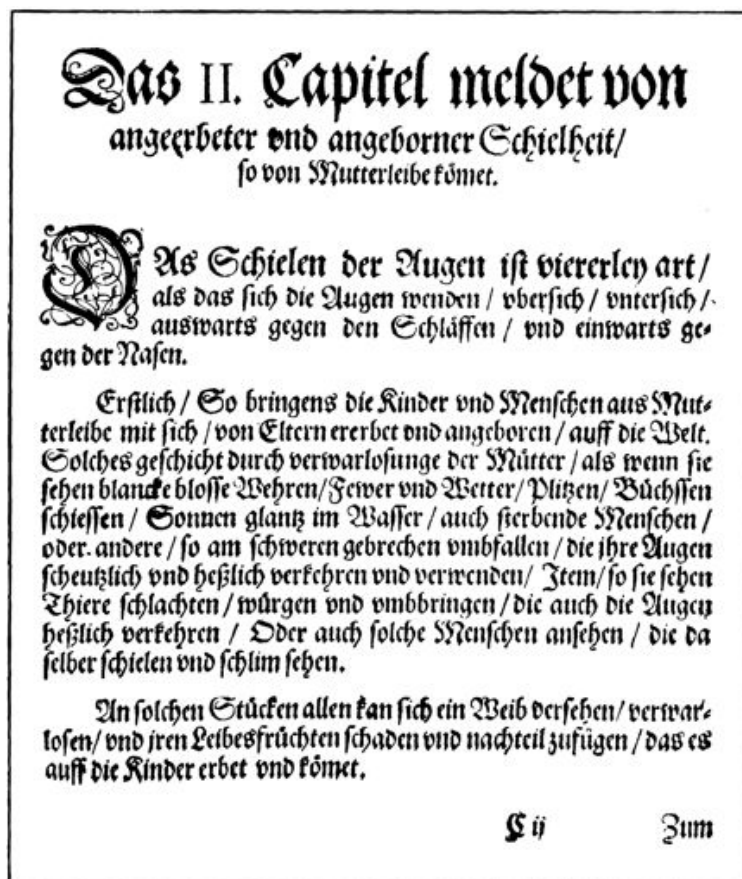

FIGURE 9–1. “The second chapter describes inherited and congenital strabismus/as it is passed on from the mother’s womb. There are many forms of strabismus/as the eyes may turn/upward/downward/outward toward the temples/and inward toward the nose. First/it is passed on to children and people from their mother’s womb/inherited from the parents and inborn. Such may be caused by negligence of the mothers/as when they look at shining armor/fire and storm/lightning/gunfire/the sun reflecting in water/also at dying people/or others/collapsing from severe infirmity/who twist and contort their eyes in a hideous manner/likewise/when they watch the slaughter of animals/choked and killed/who will also contort their eyes in agony/or look at people who are squinting themselves and don’t see well. Through all this carelessness/a woman will become slovenly/cause damage to the fruit of her womb/so that it is then passed on to the children.” (Author’s translation from Bartisch G: Augendienst (Oftalmoleia). Dresden, 1583, p 14. Facsimile reprint, London, Dawsons of Pall Mall, 1966.)

fied as causing strabismus, this etiologic heterogeneity is mostly neglected by geneticists. Probably as a result of this neglect, there is a wide diversity in the reported mode of inheritance. Some authors concluded from their studies that strabismus was *recessively* transmitted,^{26, 35, 132} whereas others stressed the *dominant* mode of inheritance.^{53, 54, p. 1014}

Dufier and coworkers⁴⁶ studied the inheritance in 195 unselected patients with strabismus, separating them into alternating strabismus without amblyopia (presumably esotropia), alternating strabismus with amblyopia, and accommodative strabismus with a high AC/A ratio. This family study and the complex segregation studies show that the hypothesis of *dominant autosomal* inheritance with *incomplete penetrance* is the most probable of the three types.

Maumenee and coworkers¹⁰¹ studied pedigrees of probands with *infantile esotropia* and the absence of significant degrees of hypermetropia. These authors employed the method of segregation analysis for best fit to different models of mendelian inheritance. A best fit was obtained with a model of codominant inheritance, with a high probability of being affected for homozygotes carrying a relatively common allele. Since standard errors from this analysis are large, the transmission probability for this codominant model differs significantly from mendelian expectations. This suggests the existence of etiologic heterogeneity among the 173 families studied by Maumenee and coworkers, which could have resulted from a major admixture of autosomal recessive, some dominant, and even some nongenetic cases.

Twin studies are of value in investigations of the genetics of strabismus as in all other heritable condition.⁹⁴ Here the concordance of the trait in monozygotic twins as opposed to dizygotic twins

is of particular importance, since a prevalence of the former would indicate the heritable nature of the trait under consideration. Waardenburg^{154, p. 1018} did indeed find such a prevalence in monozygotic twins, as did Richter,^{124, p. 38} and de Vries and Houtman,³⁹ whereas Weekers and coworkers¹⁵⁵ and François⁵³ did not (Table 9-1). Indeed, Weekers and coworkers concluded that, strictly speaking, strabismus (i.e., the manifest deviation) is not genetic. They stated that it is a facultative complication of an ametropia, which alone is genetically determined.¹⁵⁵ This is in marked contrast to Waardenburg's opinion^{154, p. 1017} that both hypermetropia and esotropia are separately inherited and to Lang's⁹³ finding that 10 of 24 monozygotic twins had *essential infantile esotropia*, a condition which we know to be independent of ametropia.

Richter^{124, p. 75} found no evidence for autosomal recessive inheritance of strabismus and cautioned about the assumption of autosomal dominant inheritance with incomplete penetrance. Instead, a multifactorial system of inheritance was held responsible for the fact that fewer members in kindred of the proband exhibited the trait than would be expected. She considers the assumption unproven that sensory anomalies in strabismic patients are the consequence of the abnormal relative position of the eyes. She claims that these sensory anomalies (anomalous correspondence, amblyopia) are inherited traits. This view is supported only by the frequency of their appearance in strabismic families and has no support other than the opposite view held strongly by even such enthusiastic geneticists as Waardenburg.^{154, p. 1014} Clearly, the enormous amount of work expended by Richter has still not brought us nearer to the solution of the problem.

To demonstrate how widely some authors may differ in their opinions, even when reached on the basis of very similar material, the conclusions

TABLE 9-1. Twin Studies in the Investigation of the Genetics of Strabismus

Study	Monozygotic Twins		Dizygotic Twins	
	Concordant	Discordant	Concordant	Discordant
Waardenburg ¹⁵⁴	11	0	4	13
Weekers et al. ¹⁵⁵	3	4	6	2
François ⁵³	2	4	—	—
Richter ¹²⁴	11	1	7	20
de Vries and Houtman ³⁹	8	9	—	—
Lang ⁹³	8	4	—	—
Totals	43	22	17	35

drawn by Schlossman and Priestley¹²⁹ from a rather large group of patients are quoted:

Hyperopia alone was not the cause of convergent squint. Hyperactivity of the center of convergence, defective fusion faculty and obvious anatomic malformation, although important, were not major inherited factors except in a small percentage of the families. . . . There are probably two types of inheritance: (a) a defect in the ectoderm involving the nerve tissues, and (b) a defect in the mesoderm, involving such structures as muscles, check ligaments and fascial attachments. Anisometropia is a relatively unimportant factor in the etiology of familial esotropia. Amblyopia and abnormal retinal correspondence are not inherited. By use of the a priori method, it was found that the data fit a 3:1 ratio, indicating a recessive inheritance for both esotropia and exotropia. There was a certain lack of penetrance in both the families with convergent and the families with divergent strabismus. Convergence is dominant over divergence. About 1 of every 4 persons is a carrier of the gene for strabismus.^{129, p. 20}

In a study of 32 patients with Williams syndrome (mental retardation, short stature, aortic stenosis, "elfin" facies, and associated ocular anomalies) Esswein and von Noorden⁴⁷ found a prevalence of strabismus of 78% (25 of 32 patients) which, with the exception of two patients, consisted of *infantile esotropia*. Others have reported that patients with Williams syndrome without measurable strabismus may have a primary microtropia.¹¹⁶ This extraordinarily high association of Williams syndrome with *infantile esotropia*, unmatched by any other medical condition known to us, strongly suggests a genetic linkage between the two diseases.

Summary

The study of the literature of genetics in strabismus¹¹⁹ gives an impression of considerable confusion. One cannot help but feel that most workers in the field have looked in the wrong place, taking certain motor and sensory manifestations (deviation, amblyopia, and anomalous correspondence) to be the trait that is inherited rather than the underlying condition to which these traits are owed. Richter^{124, p. 70} believed that these conditions are not accessible to measurement. This view can be challenged. There are functions that can be quantitatively characterized and their distribution in strabismic and nonstrabismic families established. In relation to the deviation, such functions are the AC/A ratio,¹⁰⁰ optomotor responses (e.g., fusional amplitudes,⁹⁹ but also responses of the optovestibular system), and, in the families of

patients with an A or V pattern of fixation, the configuration of the lids and structures around the eyes. Instead of looking for an inheritance pattern of amblyopia and anomalous correspondence, one should investigate quantitatively retinal rivalry, the readiness to suppress, and other similar functions. One could even conceive of an ophthalmologist well versed in biochemistry who would test the hypothesis of Keiner,⁸¹ that a heritable metabolic factor is at the root of the presumed retardation of myelination of the visual system.

Most of the work on the genetics of strabismus was done 30 or more years ago. With the advent of molecular biology and in view of the rapid advances in gene identification in recent years, it is hoped that strabismus once again catches the interest of geneticists so that the pattern of inheritance can be firmly established. The frequent association between Williams syndrome and infantile esotropia⁴⁷ (19 of 32 patients) mentioned earlier in this chapter should provide fertile ground for further investigation with modern methods of genetic research.

Accurate knowledge of the inheritance of strabismus (in the broadest sense, not in the sense of the deviation as such) would be of utmost practical use. Suppositions would no longer have to be relied on to answer the question of whether sensory anomalies are cause or sequelae. Such information might help to explain why certain patients do and others do not respond to treatment.

The frequent occurrence of sensorimotor anomalies in the pedigrees of strabismic probands¹²⁰ obliges the conscientious ophthalmologist to insist on an examination of all siblings of a strabismic child to rule out the presence of neurosensory anomalies of the eyes. Such anomalies may be subtle and thus may have escaped the attention of parents. Abrahamson and coworkers² identified a positive family history of strabismus and hypermetropia in excess of +3.00D as risk factors for the development of strabismus. Children with these characteristics were four to six times more likely to develop strabismus than normal controls.

Concluding Remarks

In strabismus, the deviation, even if comitant, is caused by a variety of etiologic factors. Each author lays the greatest stress on those factors that he or she finds most appealing on the basis of theoretical concepts, personal clinical experience,

or individual research direction. A unitary theory of the pathogenesis of strabismus is then developed in terms of mechanical anomalies or innate paralysis and the admission that accommodation, refraction, or other innervational factors may also play a role is made almost grudgingly. The evidence that a normal sensorimotor mechanism can overcome remarkably severe anatomical and mechanical obstacles is neglected. Others to whom strabismus is a purely innervational anomaly consider it naive to allow mechanical factors to be involved. From some writings the impression is gained that nervous impulses act almost in a vacuum. To those who attribute a preponderant role to the fusion mechanism or to toxic influences, both mechanical and refractive elements are secondary, if they are acknowledged at all. And so it is with all other theories.

As has been pointed out repeatedly in this chapter, all elements listed contribute in varying degrees to the appearance of a deviation. Some authors have recognized this, and their number is increasing. Foremost among them was Bielschowsky,^{16, p. 51} who distinguished two groups of causes of comitant strabismus—static causes and anomalies of the sensorimotor system. Van der Hoeve¹⁵¹ also stated explicitly that strabismus is neither a purely static nor a purely sensorimotor or psychic problem but a combination of all of them. Many modern authors have expressed themselves in a similar vein.

For the practicing ophthalmologist the truth, in an academic sense, about the etiology of strabismic deviations is of small importance. However, it is necessary to be well acquainted with the multiplicity of causes that may lead to a deviation, for a rational treatment is possible only if the cause is understood.

REFERENCES

1. Abrahamson M, Fabian G, Sjöstrand J: Refraction changes in children developing convergent or divergent strabismus. *Br J Ophthalmol* 76:723, 1992.
2. Abrahamson M, Magnusson G, Sjöstrand J: Inheritance of strabismus and the gain of using heredity to determine populations at risk of developing strabismus. *Acta Ophthalmol Scand* 77:653, 1999.
3. Adler FH: Pathologic physiology of convergent strabismus. Motor aspects of the non-accommodational type. *Arch Ophthalmol* 33:362, 1945.
4. Ames A, Gliddon GH: Ocular measurements. *Trans Section Ophthalmol AMA* 1928, p 102.
5. Aslin RN: Development of binocular fixation in human infants. *J Exp Child Psychol* 23:133, 1977.
6. Atkinson J: Development of optokinetic nystagmus in the human infant and monkey infant. In Freeman RD, ed: *Developmental Neurobiology of Vision*. New York, Plenum Press, 1979, p 277.
7. Atkinson J, Braddick O: Stereoscopic discrimination in infants. *Perception* 5:29, 1976.
8. Atkinson J, Braddick O, Moar K: Development of contrast sensitivity over the first 3 months of life in the human infant. *Vision Res* 17:1037, 1977.
9. Avilla CW, Noorden GK von: Post-traumatic fusion deficiency. In Ravault A, Lenk M, eds: *Transactions of Fifth International Orthoptic Congress, Lyon, France, LIPS, 1984*, p 143.
10. Baker R: Role of brainstem circuits in the etiology of strabismus. In Lennerstrand G, Noorden GK von, Campos EC, eds: *Strabismus and Amblyopia. Experimental Basis for Advancement in Clinical Management*. London, Macmillan, 1988, p 75.
11. Banks MS, Salapatek P: Acuity and contrast sensitivity in 1-, 2- and 3-month-old human infants. *Invest Ophthalmol Vis Sci* 17:361, 1978.
12. Bartisch G: *Augendienst (Oftalmoleia)*. Dresden, 1583, p 14. [Facsimile reprint, London, Dawsons of Pall Mall, 1966.]
13. Bedford PD, Daniel PM: Discrete carcinomatous metastasis in the extrinsic ocular muscles. *Am J Ophthalmol* 49:723, 1960.
14. Berk AT, Saatci AO, Ercal MD, et al: Ocular findings in 55 patients with Down's syndrome. *Ophthalmic Genet* 17:15, 1996.
15. Bielschowsky A: Über die relative Ruhelage der Augen, vol 66. In *Proceedings of the 39th Meeting of the Ophthalmology Society, Heidelberg*. Wiesbaden, Germany, JF Bergmann, 1913, p 67.
16. Bielschowsky A: *Lectures on Motor Anomalies*. Hanover, NH, Dartmouth College Publications, 1943/1956, p 51 ff.
17. Bremer DL, Palmer EA, Fellows RR, et al: Strabismus in premature infants in the first year of life. Cryotherapy for Retinopathy of Prematurity Cooperative Group. *Arch Ophthalmol* 116:329, 1998.
18. Broendstrup P: The squinting position of weak-sighted eyes. *Acta Ophthalmol* 20:386, 1944.
19. Burian HM: Handedness, eyedness and refractive error in relation to strabismic amblyopia. *Wiss Z Univ Leipzig Math Naturwissenschaften R* 18:236, 1969.
20. Burian HM, Benton AL, Lipsius RC: Visual cognitive functions in patients with strabismic amblyopia. *Arch Ophthalmol* 68:786, 1962.
21. Campos EC, Catellani T: Further evidence for the fusional nature of the compensation (or "eating up") of prisms in concomitant strabismus. *Int Ophthalmol* 1:57, 1979.
22. Caputo AR, Wagner RS, Reynolds DR, et al: Down syndrome: Clinical review of ocular features. *Clin Pediatr (Phila)* 28:355, 1989.
23. Chan T, Howell R, O'Keefe M, et al: Ocular manifestations in fetal alcohol syndrome. *Br J Ophthalmol* 75:524, 1991.
24. Chavasse FB: *Worth's Squint or the Binocular Reflexes and the Treatment of Strabismus*, ed 7. Philadelphia, P Blakiston's, 1939.
25. Chew E, Remaley NA, Tamboli A, et al: Risk factors for esotropia and exotropia. *Arch Ophthalmol* 112:1349, 1994.
26. Claussen W, Bauer J: Beiträge und Gedanken zur Lehre von der Vererbung des Strabismus. *Z Augenheilkd* 50:313, 1913.
27. Collewijn H, Apkarian P, Spekrijse H: The oculomotor behavior of human albinos. *Brain* 108:1, 1985.
28. Cornblath WT, Elner V, Rolfe M: Extraocular muscle involvement in sarcoidosis. *Ophthalmology* 100:501, 1993.

29. Corsi M, Sodi A, Salvi G, et al: Morphological study of extraocular muscle proprioceptor alterations in congenital strabismus. *Ophthalmologica* 200:154, 1990.
30. Crone RA: Heterophoria. I. The role of microanomalous correspondence. *Graefes Arch Clin Exp Ophthalmol* 177:52, 1969.
31. Crone RA: Heterophoria. II. Fusion and convergence. *Graefes Arch Clin Exp Ophthalmol* 177:66, 1969.
32. Crone RA: From orthophoria to microtropia. *Br Orthoptics J* 26:45, 1969.
33. Crone RA: A new theory about heterophoria. *Ophthalmologica* 162:199, 1971.
34. Cross HE, Pfaffenbach DD: Duane's retraction syndrome and associated congenital malformations. *Am J Ophthalmol* 73:442, 1972.
35. Crzellitzer A: Wie vererbt sich Schielen? *Klin Monatsbl Augenheilkd* 69:519, 1922.
36. Demer JL, Noorden GK von: Optokinetic asymmetry in esotropia. *J Pediatr Ophthalmol Strabismus* 25:286, 1988.
37. Demer JL, Noorden GK von: High myopia as an unusual cause of restrictive motility disturbance. *Surv Ophthalmol* 33:281, 1989.
38. Demer JL, Zee DS: Vestibulo-ocular and opto-kinetic deficits in albinos with congenital nystagmus. *Invest Ophthalmol Vis Sci* 25:739, 1984.
39. de Vries B, Houtman WA: Squint in monozygotic twins. *Doc Ophthalmol* 46:305, 1979.
40. Diamond GR, Katovitz JA, Uhllocker LA, et al: Variations in extraocular muscle number and structure in craniofacial dysostosis. *Am J Ophthalmol* 90:416, 1980.
41. Doden W: Zur Entstehung des Begleitschielens. *Bericht Dtsch Ophthalmol Ges* 61:294, 1958.
42. Doden W, Bunge H: Fusionsstörungen nach Schädelhirntraumen. *Klin Monatsbl Augenheilkd* 146:845, 1965.
43. Domenici LL, Corsi M, Mencucci R, et al: Extraocular muscles in congenital strabismus: Muscle fiber and nerve ending ultrastructure according to different regions. *Ophthalmologica* 205:29, 1992.
44. Donders FC: On the Anomalies of Accommodation and Refraction of the Eye. Translated by Moore WD. London, New Sydenham Society, 1864.
45. Duane A: A new classification of the motor anomalies of the eyes based upon physiological principles, together with their symptoms, diagnosis and treatment. Reprinted from *Ann Ophthalmol Otolaryngol* 5 (October):969–1008, 1896, and edited by JW White.
46. Dufier JL, Briard ML, Bonaiti C, et al: Inheritance in the etiology of congenital squint. *Ophthalmologica* 179:225, 1979.
47. Esswein Kapp MB, Noorden GK von: Strabismus in Williams syndrome. *Am J Ophthalmol* 119:355, 1995.
48. Fantl EW, Perlstein MA: Ocular refractive characteristics in cerebral palsy. *Am J Dis Child* 102:36, 1961.
49. Firth AY: Handedness in strabismus. Etiological implications. *Acta Ophthalmol Scand* 73:486, 1995.
50. Fisher N: The relationship between esotropia and neurological dysfunction. *J Pediatr Ophthalmol Strabismus* 11:184, 1974.
51. Fitzgerald BA, Billson FA: Evidence of abnormal optic nerve fiber projection in patients with dissociated vertical deviation (DVD). In Ravault AP, Lenk M, eds: Transactions of the Fifth International Orthoptic Congress, Lyon, France, 1984, LIPS, p 161.
52. Fledelius H: Prematurity and the eye. *Acta Ophthalmol* 128:3, 1976.
53. François J: Heredity in Ophthalmology. St Louis, Mosby-Year Book, 1961, p 255.
54. Friedrich D, Decker W de: Prospective study of the development of strabismus during the first 6 months of life. In Lenk-Schäfer M, ed: Transactions of Sixth International Orthoptic Congress, Harrogate, England, 1987, p 21.
55. Gallo JE, Lennerstrand G: A population-based study of ocular abnormalities in premature children aged 5 to 10 years. *Am J Ophthalmol* 11:539, 1991.
56. Gallo JE, Holmström G, Kugelberg U, et al: Regressed retinopathy of prematurity and its sequelae in children aged 5–10 years. *Br J Ophthalmol* 75:527, 1991.
57. Gardiner PA: Refractive errors and cerebral palsy. In Smith VH, ed: Visual Disorders and Cerebral Palsy, London, Spastics Society, William Heinemann, 1962, p 44.
58. Gardiner PA, Joseph M: Eye defects in children with congenital heart lesions: A preliminary study. *Dev Med Child Neurol* 10:42, 1968.
59. Goldberg SH, Kennedy RE, Metz HS, et al: Strabismus caused by melanoma metastatic to an extraocular muscle. *Ann Ophthalmol* 22:467, 1990.
60. Graefe A von: Ueber Doppelsehen nach Schieloperationen und Incongruenz der Netzhäute. *Arch Ophthalmol* 1:117, 1854.
61. Graefe A von: Beiträge zur Lehre vom Schielen und von der Schieloperation. Erste Abhandlung. *Arch Ophthalmol* 3:177, 1857.
62. Greaves B, Walker J, Wybar K: Disorders of ocular motility in craniofacial dysostosis. *J R Soc Med* 72:21, 1979.
63. Gross S, Esswein MB, Noorden GK von. Asymmetric optokinetic nystagmus and pursuit in monocular patient (abstract). *Invest Ophthalmol Vis Sci* 35:1829, 1994.
64. Hamburger FA: Horror fusionis. Seine Bedeutung für Theorie und Praxis der Schielbehandlung. Bücherei des Augenarztes, vol 54. Stuttgart, F. Enke Verlag, 1970.
65. Heinonen O: Das Geburtstrauma als Ursache des Schielens. *Acta Ophthalmol* 25:19, 1947.
66. Held R: Development of acuity in infants with normal and anomalous visual experience. In Aslin RN, Alberts JR, Peterson MD, eds: Development of Perception, vol 2. New York, Academic Press, 1981, p 279.
67. Held R: Normal visual development and its deviations. In Lennerstrand G, Noorden GK von, Campos E, eds: Strabismus and Amblyopia. Experimental Basis for Advances in Clinical Management. London, Macmillan, 1988, p 247.
68. Held R, Birch EE, Gwiazda J: Stereoacuity of human infants. *Proc Natl Acad Sci U S A* 77:5572, 1980.
69. Helveston EM: Frank Costenbader Lecture—the origins of congenital esotropia. *J Pediatr Ophthalmol Strabismus* 30:215, 1993.
70. Herzau V, Starc S: Does early onset strabismus inhibit the development of the uncrossed optic pathway? In Lennerstrand G: Advances in Strabismology. Proceedings of the Eighth Meeting of the International Strabismological Association, Maastricht, Sept 1–12, 1998. Buren, The Netherlands, Aeolus Press, 1999, p 57.
71. Hess JH, Mohr GJ, Barthelme PF: Quoted by Heinonen O: Das Geburtstrauma als Ursache des Scheilens. *Acta Ophthalmol* 25:19, 1947.
72. Hesse R: Über Augenbewegung und Schielen. *Graefes Arch Clin Exp Ophthalmol* 128:145, 1932.
73. Hiles DA, Wallar PH, MacFarlane F: Current concepts in the management of strabismus in children with cerebral palsy. *Ann Ophthalmol* 7:789, 1975.
74. Hirschberg J: The History of Ophthalmology, vol 1. Translated by Blodi FC. Bonn, Wayenbergh, 1982, p 110.
75. Hoyt CS: Abnormalities of the vestibuloocular response in congenital esotropia. *Am J Ophthalmol* 93:704, 1982.
76. Jaensch PA: Fusionsstörungen nach Gehirnerschütterung. *Klin Monatsbl Augenheilkd* 94:470, 1935.
77. Jampolsky A: Ocular divergence mechanisms. *Trans Am Ophthalmol Soc* 68:730, 1970.

78. Jampolsky A, Flom B, Fried A: Fixation disparity in relation to heterophoria. *Am J Ophthalmol* 43:97, 1957.
79. Javal E: Manuel théorique et pratique du strabisme. Paris, Masson, 1896, p 255.
80. Jevons NA: Ocular defects and intelligence, quoted by Gardiner PA, Joseph M: Eye defects in children with congenital heart lesions: A preliminary study. *Dev Med Child Neurol* 10:42, 1968.
81. Keiner GB: New Viewpoints on the Origin of Squint. The Hague, Martinus Nijhoff, 1951.
82. Keith CG, Kitchen WH: Ocular morbidity in infants with very low birth weight. *Br J Ophthalmol* 67:302, 1983.
83. Klein D, Franceschetti A: Missbildungen und Krankheiten des Auges. In Becker PE, ed: *Humangenetik, ein kurzes Handbuch in fünf Bänden*. Stuttgart; George Thieme Verlag, 1964.
84. Kommerell G: Ocular motor phenomena in infantile strabismus. In Lennerstrand GK, Noorden GK von, Campos E, eds: *Strabismus and Amblyopia. Experimental Basis for Advances in Clinical Management*. London, Macmillan, 1988, p 99.
85. Kommerell G: The relationship between infantile strabismus and latent nystagmus. *Eye* 10:274, 1996
86. Krüger KE: Beitrag zur Ätiologie des Stilling-Türk-Duane syndromes. *Acta Ophthalmol* 47:415, 1969.
87. Kurz H: Über die Refraktion bei Schwachsinnigen. Ein weiterer Beitrag zur Refraktionsfrage. *Graefes Arch Ophthalmol* 118:500, 1927.
88. Kushner BJ: Strabismus and amblyopia associated with regressed retinopathy of prematurity. *Arch Ophthalmol* 100:256, 1982.
89. Kutluk S, Avilla C, Noorden GK von: The prevalence of dissociated vertical deviation in patients with sensory heterotropia. *Am J Ophthalmol* 119:744, 1995.
90. Landolt E: Etude sur les mouvements des yeux á l'état normal et á l'état pathologique. *Arch Ophthalmol* 1:636, 1881.
91. Landolt E: Untersuchung der Augenbewegungen. In Graefe A von, Saemisch Th, eds: *Handbuch der gesamten Augenheilkunde*, ed 2. Leipzig, Wilhelm Engelmann, 1904, p 739.
92. Lang J: A new hypothesis on latent nystagmus and on the congenital squint syndrome. *Doc Ophthalmol* 32:83, 1982.
93. Lang J: Genetische Aspekte bei der Esotropie einiger Zwillinge. *Klin Monatsbl Augenheilkd* 196:275, 1990.
94. Lanthony P, Ithier N, Picard MP: Les jumeaux strabiques. *J Fr Orthoptique* 9:93, 1977.
95. Lennerstrand G: Central motor control in concomitant strabismus. *Graefes Arch Clin Exp Ophthalmol* 226:172, 1988.
96. Lessel S: Handedness and esotropia. *Arch Ophthalmol* 104:1492, 1986.
97. Lippmann D: Die Entartungszeichen und die Überwertigkeit einer Körperhälfte in ihrer Bedeutung für das Schielen. *Klin Monatsbl Augenheilkd* 92:370, 1934.
98. Mackenzie W: A Practical Treatise on the Diseases of the Eye. To Which Is Prefixed an Anatomical Introduction Explanatory of a Horizontal Section of the Human Eyeball by Thomas Wharton Jones. With Notes and Additions by Addinell Hewson. Philadelphia, Blanchard & Lea, 1855.
99. Mash AJ, Hegmann JP, Spivey BE: Genetic analysis of vergence measures in populations with varying incidences of strabismus. *Am J Ophthalmol* 79:978, 1975.
100. Mash AJ, Hegmann JP, Spivey BE: Genetic analysis of cover test measures and AC/A ratio in human populations with varying incidences of strabismus. *Br J Ophthalmol* 59:380, 1975.
101. Maumenee IH, Alston A, Mets MB, et al: Inheritance of congenital esotropia. *Trans Am Ophthalmol Soc* 84:85, 1985.
102. McCormack GL: Electrophysiological evidence for normal optic nerve fiber projections in normally pigmented squinters. *Invest Ophthalmol Vis Sci* 14:931, 1975.
103. Mein J: The asymmetrical optokinetic response. *Br Orthoptics J* 40:1, 1983.
104. Miller M: Thalidomide embryopathy: A model for the study of congenital incomitant horizontal strabismus. *Trans Am Ophthalmol Soc* 89:623, 1991.
105. Mohny BG, Erie JC, Hodge D, et al: Congenital esotropia in Olmsted County, Minnesota. *Ophthalmology* 105:864, 1998.
106. Moore AT, Bunic JR, Munro IR: Fibrous dysplasia of the orbit in childhood. Clinical features and management. *Ophthalmology* 92:12, 1985.
107. Motais E: L'appareil moteur de l'oeil de l'homme et des vertébrés. Déductions physiologiques et chirurgicales (strabisme). Paris, A. Delahaye & E. Le Crosnier, 1887.
108. Naegale JR, Held R: The postnatal development of monocular optokinetic nystagmus in infants. *Vision Res* 22:341, 1982.
109. Nixon RB, Helveston EM, Miller K, et al: Incidence of strabismus in neonates. *Am J Ophthalmol* 100:798, 1985.
110. Noorden GK von: A reassessment of infantile esotropia (XLIV Edward Jackson Memorial Lecture). *Am J Ophthalmol* 105:1, 1988.
111. Noorden GK von: Current concepts of infantile esotropia (The William Bowman Lecture). *Eye* 2:243, 1988.
112. Noorden GK von, Avilla CW: Accommodative convergence in hypermetropia. *Am J Ophthalmol* 110:287, 1990.
113. Nordlöw W: Über den Entstehungsmechanismus und die Frühoperation des Einwärtsschielens. *Acta Ophthalmol Scand* 23:97, 1945.
114. Nordlöw W: Age distribution at the onset of esotropia. *Br J Ophthalmol* 37:593, 1953.
115. Ogle KN, Mussey F, Prangen A. de H: Fixation disparity and fusional processes in binocular single vision. *Am J Ophthalmol* 32:1069, 1949.
116. Olitsky SE, Sadler LS, Reynolds JD: Subnormal binocular vision in the Williams syndrome. *J Pediatr Ophthalmol Strabismus* 34:58, 1997.
117. Palmer EA, Noorden GK von: The relationship between fixation disparity and heterophoria. *Am J Ophthalmol* 86:172, 1978.
118. Parinaud H: Le strabisme et son traitement. Paris, Gaston Doin & Cie, 1899, p 88.
119. Paul TO, Hardage LK: The heritability of strabismus. *Ophthalmic Genet* 15:1, 1994.
120. Podgor MJ, Remaley NA, Chew E: Associations between siblings for esotropia and exotropia. *Arch Ophthalmol* 114:739, 1996.
121. Pott JWR, Sprunger DT, Helveston EM: Infantile esotropia in very low birth weight (VLBW) children. *Strabismus* 7:97, 1999.
122. Pratt-Johnson JA: Central disruption of fusional amplitude. *Br J Ophthalmol* 57:347, 1973.
123. Previc FH: Abnormal motoric laterality in strabismus and a hypothesis concerning its neurological origins. *Int J Neurosci* 68:19, 1993.
124. Richter S: Untersuchungen über die Heredität des Strabismus concomitans. *Abhandlungen aus dem Gebiete der Augenheilkunde*, vol 23, Leipzig, VEB Georg Thieme, 1967.
125. Rydberg, quoted by Heinonen O: Das Geburtstrauma als Ursache des Schielens. *Acta Ophthalmol* 25:19, 1947.
126. Safran AB, Hausler R, Issoua D, et al: Strabismes induits par des lésions vestibulaires périphériques. *Klin Monatsbl Augenheilkd* 200:418, 1992.

127. Salman SD, Noorden GK von: Induced vestibular nystagmus in strabismic patients. *Ann Otol Rhinol Laryngol* 79:352, 1970.
128. Seaber JH, Chandler AC: A five-year study of patients with cerebral palsy and strabismus. In Moore S, Mein J, Stockbridge L, eds: *Orthoptics: Past, Present, Future: Transactions of Third International Orthoptic Congress*, New York, 1976, Stratton Intercontinental Medical Book, p 271.
129. Schlossman A, Priestley BS: Role of heredity in etiology and treatment of strabismus. *Arch Ophthalmol* 47:1, 1952.
130. Schoberlein, quoted by Heinonen O: Das Geburtstrauma als Ursache des Schielens. *Acta Ophthalmol* 25:19, 1947.
131. Scobee RG: Anatomic factors in the etiology of heterotropia. *Am J Ophthalmol* 31:781, 1948.
132. Shawkat FS, Harris CM, Taylor DS, et al: The optokinetic response differences between congenital profound and nonprofound unilateral visual deprivation. *Ophthalmology* 102:1615, 1995.
133. Sidikaro Y, Noorden GK von: Observations in sensory heterotropia. *J Pediatr Ophthalmol Strabismus* 19:12, 1982.
134. Slater AM, Findlay JM: Binocular fixation in the newborn baby. *J Exp Child Psychol* 20:248, 1975.
135. Snellen H Jr: Die Ursache des Strabismus convergens concomitans. *Arch Ophthalmol* 84:433, 1913.
136. Snir M, Gilad E, Ben-Sira I: An unusual extraocular muscle anomaly in a patient with Crouzon's disease. *Br J Ophthalmol* 66:253, 1982.
137. Stannard K, Spalton DJ: Sarcoidosis with infiltration of the external ocular muscles. *Br J Ophthalmol* 69:562, 1989.
138. Stanworth A: Defects of ocular movement and fusion after head injury. *Br J Ophthalmol* 58:266, 1974.
139. Steffan Ph: Erfahrungen und Studien über Strabismus. *Arch Augenheilkd* 35:200, 1897.
140. Strömland K, Hellstrom A: Fetal alcohol syndrome—an ophthalmological and socioeducational prospective study. *Pediatrics* 97:845, 1996.
141. Strömland K, Miller M: Thalidomide embryopathy: Revisited 27 years later. *Acta Ophthalmol* 71:238, 1993.
142. Tischer, quoted by Unger L: Begleitschielen und frühkindlicher Hirnschaden. *Klin Monatsbl Augenheilkd* 130:642, 1957.
143. Tsutsui J, Fukai S: Human strabismic cases suggestive of asymmetric projection of the visual pathway. In Reinecke RD, ed: *Strabismus*. New York, Grune & Stratton, 1978, p 79.
144. Tychsens L: Visual cortex maldevelopment as a cause of esotropic strabismus (letter). *Arch Ophthalmol* 105:457, 1987.
145. Tychsens L: Infantile esotropia: current management, Rosenbaum A, Santiago AP, eds: In *Clinical Strabismus Management: Principles and Surgical Techniques*. Philadelphia, WB Saunders, 1999, p 117.
146. Tychsens L, Lisberger SG: Maldevelopment of visual motion processing in humans who had strabismus with an onset in infancy. *J Neurosci* 6:2495, 1986.
147. Tychsens L, Lisberger SG: Visual motion processing for the initiation of smooth-pursuit eye movements in humans. *J Neurophysiol* 56:953, 1986.
148. Tychsens L, Hurtig RR, Scott WE: Pursuit is impaired but the vestibulo-ocular reflex is normal in infantile strabismus. *Arch Ophthalmol* 103:536, 1985.
149. Unger L: Begleitschielen und frühkindlicher Hirnschaden. *Klin Monatsbl Augenheilkd* 130:642, 1957.
150. Van der Hoeve J: Über Augenmuskelwirkung und Schielen. *Klin Monatsbl Augenheilkd* 69:620, 1922.
151. Van der Hoeve J: Operationen an den Augenmuskel. In Axenfeld T, Elschnig A, eds: *Graefe-Saemisch's Handbuch des gesamten Augenheilkunde*, ed 3, vol 2. Berlin, Springer-Verlag, 1928, p 1594.
152. van Hof-van Duin J, Mohn G: Monocular and binocular optokinetic nystagmus in humans with defective stereopsis. *Invest Ophthalmol Vis Sci* 27:574, 1986.
153. Vontobel W: Über Linsen und Hornhautuntersuchungen an mongoloiden Idioten. *Graefes Arch Ophthalmol* 130:325, 1933.
154. Waardenburg PJ: Functional disorders of the outer eye muscles. In Waardenburg PJ, Franceschetti A, Klein D, eds: *Genetics and Ophthalmology*, vol 2. Assen, The Netherlands, Royal Van Gorcum, 1963, p 1009; also Springfield, IL, Charles C Thomas, 1968.
155. Weekers R, Moureau P, Hacourt J, et al: Contribution à l'étiologie du strabisme concomitant et de l'amblyopie par étude de jumeaux un iet bivitellins. *Bull Soc Belge Ophthalmol*, 2:146, 1956.
156. Worth C: *Squint, Its Causes, Pathology and Treatment*, ed 6. London, Baillière, Tindall & Cox, 1929.
157. Zeeman WP: Conservative treatment of strabismus. *Doc Ophthalmol* 7/8:527, 1954.

Symptoms in Heterophoria and Heterotropia and the Psychological Effects of Strabismus

Asthenopia and Diplopia

Persons can overcome a heterophoria, provided there is no interference with fusion, by maintaining a tonus distribution in the extraocular muscles so that their visual axes are parallel for distance and are properly directed in near vision. Under certain circumstances, this task may be too difficult and may cause subjective symptoms consisting of discomfort of varying degree and location, so-called asthenopic symptoms, or diplopia.

Patients always relate the symptoms to use of their eyes and to so-called eyestrain. Complaints range from redness and a feeling of heaviness, dryness, and soreness of the eyes, to pain in and around the eyes, frontal and occipital headaches, and even gastric symptoms and nervous exhaustion. The eyes are easily fatigued, and such patients often have an aversion to reading and studying. Typically, these complaints tend to be less severe or to disappear altogether when patients do not use their eyes in close work. Close work also is easier when the patient is rested or when one eye is closed.

Virtually everyone has a heterophoria, but comparatively few people experience symptoms. The appearance of symptoms depends on the state of the sensorimotor system, the use made of the eyes, and the general well-being of a person. The absolute amount of the heterophoric deviation is not the most important factor; what matters is the presence or absence of a discrepancy between the deviation and amplitudes of motor fusion. If the amplitudes are inadequate to cope comfortably with the deviation, asthenopic symptoms may arise.

Vertical deviations are especially likely to cause symptoms, since the vertical fusional amplitudes generally are limited, although one encounters remarkable exceptions (see Chapter 20). Even if the amplitudes are adequate, patients will sometimes develop asthenopic symptoms or even diplopia following a debilitating disease. For example, after severe pneumonia, when they begin to read they will often state that the disease has “affected their eyes.” What actually has happened is that their general level of energy is too low to allow them to overcome their heterophoria with the same ease as when they were in normal health. In these cases symptoms usually are transient.

Asthenopic symptoms are less frequent in distance vision than in near vision, because there is less strain on the sensorimotor system. However, it can be distressing to watch moving objects in the distance, such as in movies, on television, or from fast-moving cars, or at a ball game, since maintenance of fusion in such circumstances is difficult and may produce stress.

Asthenopic symptoms are much more common when doing close work requiring sustained fixation, often for hours, at the same visual distance. It does not allow for roving gaze in the same manner as distance fixation. Maintenance of proper alignment of the eyes may represent a considerable strain on the sensorimotor system of the eyes. This is why asthenopic symptoms tend to occur during the last years of high school or college or in professional work requiring prolonged close application, but rarely, if ever, in preschool children.

Not all asthenopic symptoms are caused by neuromuscular anomalies. If they are, the condition is termed *muscular asthenopia*, but often they are caused by uncorrected refractive errors, including aniseikonia (see Chapter 7). One speaks then of *refractive asthenopia*. One cannot always be sure whether a patient's complaints are the result of muscular or refractive asthenopia, as shown in the following case.

CASE 10-1

In the course of a routine ophthalmic examination of a freshman class of nurses, a 19-year-old woman reported that she had experienced severe eyestrain on close work during the last 2 years in high school. She had worked hard and was a good student. She had never had an eye examination. The globes were normal in all respects. Vision was 6/6 in each eye. The refraction revealed OU + 2.75 + 0.25 cyl ax 90°. There was an exophoria of 20^Δ for distance and 25^Δ for near, with large amplitudes and full stereopsis. The patient was told that she should wear glasses but that these might make her symptoms worse. She was given the glasses and was immediately symptom-free. During a follow-up period of 3 years, the symptoms did not return. Clearly, this was a case of refractive asthenopia, not of muscular asthenopia, as was anticipated.

Another cause of asthenopia, frequently overlooked in children of school age, is caused by *accommodative insufficiency*.^{2, 4} This condition may occur without an obvious cause, possibly on

a congenital basis or as a sequela to head trauma. We have also observed transient accommodative insufficiency in a 12-year-old child who had been bitten by a poisonous spider. It is advisable to check the near point of accommodation routinely in all asthenopic patients who are old enough to give reliable responses.

Whenever the ophthalmologist finds it difficult to decide whether a patient's asthenopia is caused by muscular or refractive factors, it is advisable to have the patient wear an occlusive patch over one eye for several days. If this *patch test* relieves the symptoms, asthenopia is most likely caused by muscular factors. The decision-making process⁷ involved in interpreting the results of the patch test is summarized in Figure 10-1.

To prevent asthenopic symptoms and diplopia, humans have a built-in mechanism—suppression. By suppressing the images from one eye, at least regionally, asthenopic symptoms may be greatly reduced or altogether done away with. Suppression is most active in patients with heterotropia. Heterotropic patients therefore only rarely complain of such symptoms; if they do, such symptoms are most likely to be accommodative. Nor is diplopia common in untreated patients with comitant heterotropia. Not all people suppress equally well. Patients with a well-functioning sensory system and a strong compulsion to fusion do not readily suppress, but they may have to pay for their excellent binocularity with asthenopic symptoms. A child with a large exophoria and without any symptoms may develop an exotropia in later life or stay exophoric and develop symptoms of eyestrain with sustained close work. Which of the two paths the patient will follow depends on the state of the sensorimotor system.

Diplopia in its various manifestations is discussed further in Chapter 13.

Asthenopic symptoms, regardless of their cause, may be misinterpreted as a sign of neurotic tendencies. There is little doubt that some patients complaining about asthenopia are truly neurotic, have a fixation about their eyes, exaggerate their suffering, have a fear of blindness, or crave attention; but the ophthalmologist is quite wrong to attribute all asthenopic symptoms to neurosis. We feel defeated if we cannot find a physical cause for a patient's complaints and should always ask ourselves the cause and effect in such patients—do they complain because of their constant eyestrain, or do they complain of eyestrain because they are disturbed in some other way?

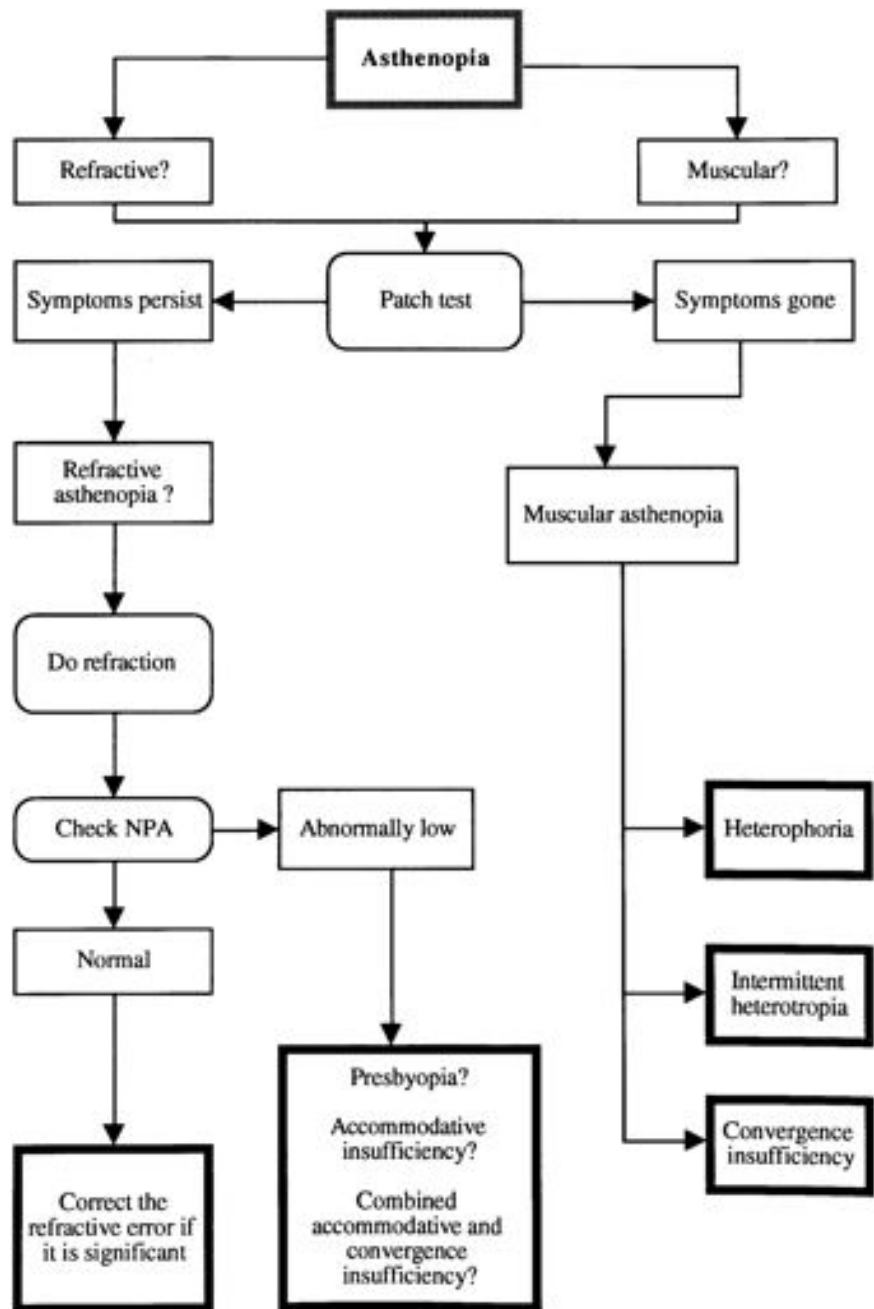


FIGURE 10-1. The differential diagnosis of asthenopia based on the patch test. NPA, near point of accommodation. (Modified from Noorden GK von, Helveston EM. *Strabismus: A Decision-Making Approach*. St Louis, Mosby-Year Book, 1994, p 132.)

How a patient deals with diplopia depends very much on his or her personality. A perfectionist knows that the second image should not be there, that it is wrong, and that it is a flaw. The continual search for that second image reinforces the patient's disturbance. A more relaxed person will acknowledge the presence of two images, but usually will take it in stride. Such patients have learned how to distinguish the double image from the "real" image, act accordingly, and by disregarding it and not allowing it to disturb them, learn how to live with it.

We have encountered on several occasions patients who complained about intermittent diplopia

and, on examination, were found to have essentially normal ocular motility. Further questioning established that they had become aware of physiologic diplopia. How Walter B. Lancaster dealt with this problem was often recounted with great relish by the late Hermann Burian.

A faculty colleague at Dartmouth College once consulted Dr. Lancaster with the following complaint: Whenever he looked out of his window to contemplate a beautiful old tree outside, a curtain string hanging from his window was seen double. After the eye examination showed nothing abnormal, Dr. Lancaster explained to the patient the phenomenon of physiologic diplopia. This was apparently to no avail since the patient kept returning to his office with the same com-

plaint. Finally, Dr. Lancaster's patience ran out; he scribbled something on a prescription blank, put it into an envelope and told the patient not to open it until he had left the office. He had written, "Go to a hardware store, buy a pair of scissors, and cut the damned string off!"

That pathologic diplopia may lead to severely neurotic behavior is illustrated by the following case.

CASE 10-2

A 32-year-old schoolteacher had experienced strabismus since infancy and had several surgical eye corrections performed during childhood. Wanting to regain normal binocular vision, he had read extensively about strabismus in public libraries. He underwent intensive orthoptic antisuppression therapy until finally he could use both eyes together, which resulted in constant double vision. Examination showed normal visual acuity in each eye, a minimal deviation that varied between esotropia and exotropia, and diplopia, which, according to the underlying deviation, varied between uncrossed and crossed localization of the images. Since he had no motor fusion, the patient was unable to superimpose the double images for longer than a few seconds. The patient requested to have one eye surgically removed because he was no longer able to work as a teacher as a result of the double vision. I suggested an occluding contact lens instead. The patient would not hear of this solution and consulted a colleague in another city who sent the patient to a psychiatrist. When I met this colleague several years later, I asked how our mutual patient was doing. He replied, "He no longer complains about diplopia; but then, since he began seeing his psychiatrist, he has stopped speaking altogether."

Psychological Effects of Strabismus

The psychological effects of strabismus on the patient and, in the case of a child, on the parents should not be underestimated. Superstition and folklore that label a squinter as being "shifty-eyed," "evil-eyed," and "not to be trusted" and "apt to lie" are still strong in our allegedly enlightened world, especially in rural areas. The words for strabismus or squint have distinctly negative connotations in some other languages. For instance, the German word for squint is *schielen*, from the Greek *skollós*, "crooked," "dishonest" (see also *scoliosis*). An older and etymologically closely related German adjective is *scheel*, "be-

grudging," "envious," or *scheelsichtig*, "strabismic." To this day, the expression to look *mit scheelem Blick* is equivalent to looking at something "enviously" or "begrudgingly." In Yiddish the expression for strabismus is *krimme Augen*. *Krim* (or *krum*) also means crooked and is used for describing dishonest business. The French verb to squint is *loucher* and to this day a shady business deal is referred to as *une affaire louche*.

Cosmetically, strabismus is unacceptable in most societies; thus growing up with crossed eyes and looking different from other children, as well as being exposed to teasing and harassment from playmates, cannot help but have a negative impact on self-esteem and personality development in children afflicted with this condition. This was not always so. For instance, in the Inca culture esotropia was considered a sign of beauty and a small ball of beeswax was dangled before a baby's eyes to force the eyes into convergence. Many pictures of the ancient sun god show the eyes in a position of esotropia.

Strabismus not only may have a negative psychosocial impact on a child but may also affect the parent-child relationship. Many parents develop anxieties and guilt feelings about their child's eye condition, and further conflicts are caused by the parents' response to what others will think of their child's strabismus. These psychological problems and anxieties of the parents may be compounded by their participation in decisions regarding medical and surgical treatment of their child.¹

That the psychosocial consequences of strabismus are not limited to childhood but occur in teenagers and adults as well was shown by Satterfield and coworkers,¹¹ who studied the psychosocial implications of growing up with a noticeable strabismus. This study showed that strabismus has an adverse effect on the afflicted person's livelihood, self-image, ability to obtain work, interpersonal relationships, schooling, work, and sports activity throughout life.

The negative experiences of an ophthalmologist³ who was afflicted with strabismus during childhood are interesting reading in this respect and confirm Satterfield's findings.

Olitzky and coworkers⁸ studied the effect on college students of computer-modified photographs in which the same person was shown with orthotropia, esotropia, and exotropia. Negative social and occupational prejudices were evoked by the photographs showing strabismus and it is reasonable to assume that such bias would have been

even more pronounced if the group surveyed had included a more diverse section of the general population.¹⁰

The many functional benefits derived from surgical correction of strabismus are reflected in a list of recent publications compiled by Kushner.⁹

The psychosocial effects of strabismus must also be considered in connection with the indications for its surgical correction^{5, 6, 12} (see also Chapter 26).

REFERENCES

1. Beckwith MD: Stress and strabismus. In Pearlman JT, Adams GI, Sloan SH, eds: *Psychiatric Problems in Ophthalmology*. Springfield, IL, Charles C Thomas, 1977, p 84.
2. Boschi A, Bergmans J, Moulart E, et al: Accommodation insufficiency in children (in French). *Bull Soc Belge Ophthalmol* 239:51, 1990.
3. Burden AL: The stigma of strabismus: An ophthalmologist's perspective (letter). *Arch Ophthalmol* 112:302, 1994.
4. Chrousos GA, O'Neill JF, Lueth BD, et al: Accommodation deficiency in healthy young individuals. *J Pediatr Ophthalmol Strabismus* 25:176, 1988.
5. Helveston EM: The value of strabismus surgery. *Ophthalmic Surg* 21:311, 1990.
6. Keltner J: Strabismus surgery in adults (editorial). *Arch Ophthalmol* 112:599, 1994.
7. Noorden GK von, Helveston EM: *Strabismus: A Decision-Making Approach*. St Louis, Mosby-Year Book, 1954, p 132.
8. Olitsky SE, Sudesh S, Graziano A, et al: The negative psychosocial impact of strabismus in the adult. *J AAPOS* 3:209, 1999.
9. Kushner BJ: Functional benefits of strabismus surgery. *Binoc Vision Strabismus Q* 16:11, 2001.
10. Rosenbaum AL: Adult strabismus surgery: The rehabilitation of a disability. *J AAPOS* 3:193, 1999.
11. Satterfield D, Keltner JL, Morrison TL: Psychosocial aspects of strabismus study. *Arch Ophthalmol* 111:1100, 1993.
12. Small RG: Functional vs. cosmetic ophthalmologic defects. *Arch Ophthalmol* 109:1194, 1991.

Examination of the Patient—I

PRELIMINARIES

History

A carefully obtained history, beginning with the *family history*, is essential in treating a patient with neuromuscular anomalies of the eyes. One should ask not only about grandparents, parents, and siblings but also about more distant relatives (uncles, aunts, cousins). The questions should not be restricted to actual turning of the eyes. An effort should also be made to find out whether a large number of relatives wear strong glasses. We have found the question of whether a relative has or had a “lazy eye” of little help since that term means different things to different people and thus the answers may be misleading. While the ophthalmologist may use this term to explain amblyopia to the patient or the parents, the layperson will use it for any number of ocular anomalies, which may include amblyopia but also any form of latent or manifest strabismus, refractive errors, or other types of visual deficits.

Next, the *personal history* of the patient should be obtained, beginning with the mother’s pregnancy and the events at birth. Factors such as prematurity and birth weight, unusual length of labor, abnormal position, and use of instruments should be documented. The extent to which these factors contribute to the etiology of strabismus is

not always clear. However, this information may provide information regarding the physical and mental maturation and general health of a patient. The questions must be asked skillfully and gently so as not to cause guilt feelings in the mother or to imply that a mistake was made in the delivery room.

An attempt should be made to establish the age at which the position of the patient’s eyes was first noted to be abnormal. It is especially valuable to know the opinion of the parents as to which eye deviates and whether it is always the same eye that is turned. When this question is asked, it is not unusual for the mother of a child with an obvious esotropia of the left eye to state that the right eye deviates. “The right eye?” one asks. “Look at the child.” “Sure, the right eye,” says the mother and points her finger toward the child’s left eye.

It is also important to learn whether the deviation was constant or intermittent at first and whether it becomes worse when the child is tired or ill, more obvious in distance fixation or in near vision, and worse or better when the patient is visually attentive or daydreaming. The existence of a cyclic pattern of strabismus (see Chapter 21) should always be remembered when taking the history.

Certain manifestations are often volunteered by the parents. For instance, they may report that their child closes one eye in bright light, which is a phenomenon often but not exclusively associated with an intermittent deviation (see Chapter 17). The parents should be asked whether convulsions, disease, or trauma preceded onset of the deviation. Then ask about development of the child (motor, speech), health, motor behavior patterns, handedness, general behavior anomalies such as enuresis, and last but very important, about any treatment for the strabismus (glasses, patching, exercises, operations) that the patient may have had. In adults and in all patients in whom onset of the deviation is acute, one should determine whether diplopia is present if the patient does not voluntarily report this symptom. If so, ascertain whether diplopia is present at all times when both eyes are open or whether it occurs more often or is more marked in distance vision or in near vision.

The term *double vision* does not necessarily have the same meaning for every patient as it does for the ophthalmologist (p. 153). Careful questioning may reveal that the patient is bothered by blurring of vision or a partial overlay of contours rather than by actual image separation. Demonstration of true diplopia by holding a prism before one eye of the patient may save time otherwise wasted by looking for a nonexistent motility problem. In patients with no obvious ocular deviation, complaints about double vision should immediately alert the physician to the possibility of monocular diplopia. Retesting with a cover held first before one eye and then before the other eye will quickly establish whether diplopia is monocular or binocular.

All histories must be evaluated critically; at times they are of doubtful value. Occasionally, baby pictures of the patient are useful in substantiating the parents' claim about the time of onset of the deviation. The accuracy of observation of some people is low and their memory short. Parents often do not care to admit that their child may have a defect, especially if the defect is familial on the side of the reporting parent. They may overstress the seriousness of an accident or illness and look for a cause of a condition that actually preexisted. Nevertheless, when talking with a seemingly reliable mother, the ophthalmologist will do well not to take her report too lightly. More often than not she is right. For example, if a mother is quite sure that her child's eyes are misaligned only occasionally, for instance, after

school or when daydreaming, and if the ophthalmologist is unable to find a deviation during the first examination, it is unwise to dismiss the patient with the advice that nothing is wrong. Quite likely the ophthalmologist will find a deviation at one of the next examinations.

Taking the history need not consume a long time, but however long it takes, it is time usefully spent. From the history the more experienced ophthalmologist often can arrive at a presumptive diagnosis, which is particularly helpful in very young, uncooperative patients on whom it may not be possible to perform a detailed examination at the first visit. Busy ophthalmologists may have a lay assistant or orthoptist take the history. However, ideally, this task should not be delegated to another, for this first encounter with a patient and his or her family provides a unique opportunity to follow and evaluate certain leads and to establish communication and a basis for trust between the physician and the patient or parents. Moreover, during this initial discussion the patient may be casually observed for evidence of the type of strabismus (unilateral or alternating), the preferred eye, an anomalous head posture, and so on. This is often helpful in young children who may become intimidated and uncooperative once the actual examination starts.

Assessment of Visual Acuity in Children

Testing the vision of patients with neuromuscular anomalies of the eyes is not merely a matter of having them read a chart. It is a more complex procedure because of the youth of many of these patients and because of certain characteristics of visual acuity (see Chapter 7), especially in amblyopia (see Chapter 14).

Estimation of Visual Acuity in Infants

Although knowledge of the actual visual acuity in normal infants and its development in early childhood is important, the ophthalmologist treating an infant who manifests a heterotropia is more concerned with the acuity of one eye relative to that of the other rather than with absolute visual acuity levels in each eye. It must be known whether amblyopia is present in one eye. Such a finding is important, and luckily it can be readily

established in most instances by mere observation of the patient. If by history and observation one eye is always deviated and if the infant objects more strenuously to covering one eye than the other, the assumption of amblyopia must be made, provided the fundus examination was normal, and immediate treatment is mandatory. The importance of establishing fixation preference in diagnosing amblyopia is discussed further in Chapter 14.

The growing awareness of the sensitivity of immature visual systems to abnormal stimulation,^{3, 26, 42, 43, 60} the need to treat amblyopia early in life, and the prevention of visual deprivation amblyopia by overtreatment have stimulated development of quantitative methods to estimate visual acuity in infants. Three such methods (optokinetic nystagmus, preferential looking, and evoked cortical potentials) are now available. While few pediatric ophthalmologists use these methods routinely in an office environment, these techniques have added to our knowledge of the development of visual acuity in infants. For a summary of the developmental aspects of visual acuity testing in infants and a comparison of the different methods available, the reader is referred to recent reviews.^{6, 12, 13, 20, 21, 47, 57}

OPTOKINETIC NYSTAGMUS. Optokinetic nystagmus has been used for a long time to determine visual acuity objectively. Nystagmus is elicited by passing a succession of black and white stripes through the patient's field of vision. The visual angle subtended by the smallest stripe width that

still elicits an eye movement (*minimum separable*, p. 114) is a measure of visual acuity. The only cooperation required is that the subject be awake and hold both eyes open.

Gorman and coworkers²² were the first to use this method of acuity testing in newborns. Other investigators refined the method¹¹ and extended its use to older infants.^{17, 19, 31} These data varied considerably, undoubtedly because of methodological differences in stimulus parameters and response determination; however, one can reasonably conclude from these studies that optokinetic nystagmus acuity is at least 6/120 in the newborn and improves fairly rapidly during the first few months of life. Dobson and Teller¹³ offered valuable suggestions about how to standardize the testing procedure and response evaluation of this method. Since it has been reported that optokinetic responses can be elicited in the presence of cortical blindness,⁵⁹ this test must be interpreted cautiously since subcortical mechanisms may be involved. Moreover, a negative response may be due to lack of attention to the optokinetic stimulus and to a delayed maturation of the motor pathways involved with the response.^{9, 16}

PREFERENTIAL LOOKING. This technique is based on the fact that an infant's attention is more attracted by patterned stimuli than by a homogeneous surface.^{4, 18} Consequently, if offered the choice between a patterned stimulus (e.g., black and white stripes) and a homogeneous background, an infant will prefer to look at the pat-



FIGURE 11-1. Testing of an infant's acuity with forced-choice preferential looking. The observer is hidden behind the screen and monitors through a peephole the direction of eye or head movements in response to the appearance of the striped stimulus. (From Teller DY, Movshon JA: Visual development. *Vision Res* 26:1483, 1986.)

terned stimulus as long as the pattern is above the visual acuity threshold.

This technique, originally described by Fantz,¹⁸ was further developed by Dobson and Teller and their coworkers^{14, 55} to exclude observer bias. During the test, an observer is hidden behind a screen on which a visually homogeneous surface on one side of the screen is alternated randomly with black and white stripes on the other side. The baby faces the screen, and the observer records the direction of head or eye movements in response to the appearance of the striped stimulus (Fig. 11-1).

Gwiazda and coworkers²³ further modified the preferential looking method and Jacobson and coworkers²⁸ reported its effectiveness in monitoring the visual acuity of the occluded eye in infants undergoing treatment for amblyopia. Most studies have shown that this method of acuity testing is especially suitable for infants up to 4 months of age. Older infants are too easily distracted. Visual acuities determined with this method range from approximately 6/240 in the newborn to 6/60 at 3 months and 6/6 at 36 months of age³⁷ (Fig. 11-2). It is generally assumed that foveal immaturity contributes to the lower neonatal visual acuity, although it may not be its exclusive cause.²⁵ To adapt the time-consuming, forced-choice preferen-

tial looking procedure to a clinical setting, McDonald and coworkers³⁹ introduced acuity cards (Teller Acuity Cards, Vistech, Inc., Dayton, OH) containing grating patterns of various spatial frequencies. An observer watches an infant's eye and head movements in response to repeated presentations of these cards at a 38 cm fixation distance. This method has undergone extensive clinical testing (for a review of the literature, see Dobson¹²) and has been accepted by some pediatric ophthalmologists as an office procedure for estimating visual acuity in infants. It must be realized, however, that grating acuity testing cannot automatically be equated with acuity testing based on recognition tasks, such as naming pictures or Snellen letters. In normal children, grating acuity is better than recognition acuity,^{38, 58} and this difference is exaggerated in children with amblyopia.^{15, 30, 36, 44, 48} Thus children with strabismic amblyopia and other forms of visual impairment may have their visual acuity underestimated, which limits the value of the Teller Acuity Card Test in clinical practice.^{8, 32, 46} As a visual screening method the Teller cards yield a high rate of false-positive results.⁵³

The improved performance on spatial discrimination vs. recognition tasks suggests that different

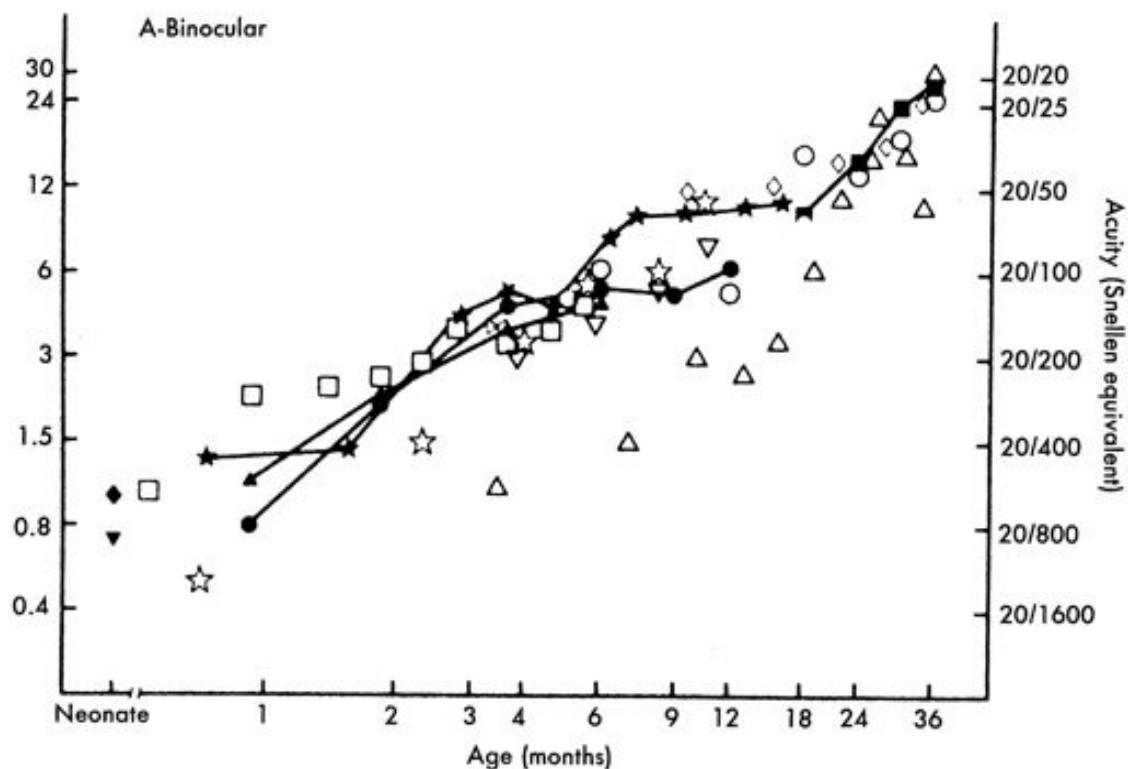


FIGURE 11-2. Compilation of behavioral data from different studies showing the development of binocular grating acuity in humans over the first 5 postnatal years. (From Teller DY, Movshon JA: Visual development. *Vision Res* 26:1483, 1986.)

neural processing mechanisms in the brain are addressed by either test. For this reason caution is advised in listing Snellen acuity equivalents when displaying grating acuity data, a practice that has become widespread in psychophysical literature (see Fig. 11–2). Such comparisons, though of some value for quick orientation, must be considered approximations rather than true equivalence. Examiner bias, accuracy of measurement, and failure to detect myopia are listed as additional limitations of this method.¹² Held and coworkers^{5, 24} applied the principle of preferential looking to assessing stereoacuity in infants and concluded that the mean age at which stereopsis could first be demonstrated was 16 weeks. By the mean age of 21 weeks, stereoacuity was 1 minute of arc or better. Thus, in comparison with visual acuity, development of stereopsis is quite rapid.

VISUALLY EVOKED POTENTIALS. A variety of stimuli and recording methods using cortical potentials have been used to assess visual acuity in infants. Marg and coworkers,³⁵ using square wave gratings alternated with a homogeneous field to produce transient visually evoked potentials (VEPs), demonstrated visual acuity of 6/120 at 1 month of age, which rapidly reached standard adult acuity by 6 months of age. Sokol⁵¹ recorded steady-state VEPs produced by alternating checkerboards and reported visual acuity values to be slightly below those obtained by Marg. VEP Vernier acuity remains strikingly immature throughout the first year of life, similar to behavioral Vernier acuity.⁴⁹ However, most VEP studies suggest that the infant visual system matures to allow detection of 6/6 targets by at least 1 year of age or possibly earlier.

The discrepancy between estimated acuity values established by the optokinetic nystagmus and preferential looking techniques and those obtained using VEPs by 6 months of age (Table 11–1) must be noted. However, Sokol and Moskovitz⁵² showed that when VEP latency rather than ampli-

tude is used to estimate acuity, there is a significant correlation between electrophysiologic and behavioral data, and Katsumi and coworkers²⁹ reported a good correlation with preferential looking when “spatial frequency sweep pattern visual evoked responses” were used.

Minor differences between the results of different testing methods notwithstanding, psychophysical and electrophysiologic research during recent years has established that visual acuity in infants develops much more rapidly than once thought, that an infant’s visual capacities are surprisingly rather well established shortly after birth, and that adult levels are reached at approximately 2 to 3 years of age.

While the information provided by these tests cannot be accurate, it has been extremely useful for collecting information on the maturation of visual functions.^{9, 16, 56} Clinically, the tests may establish whether the responses from the two eyes differ. They are also useful for the follow-up of patients with bilateral reduction of visual acuity to chart progression of the condition.

Measurement of Visual Acuity in Preschool-Age Children

Reliable visual acuity measurements cannot be obtained until children are old enough to cooperate with tests that are based on recognition, such as *illiterate Es* in a linear arrangement. This usually occurs between the ages of 2½ and 3 years. The child is given a cutout of an E and asked to match this E with isolated Es of varying sizes. The first attempt is not always successful. One may then instruct the mother to teach the child the E game at home. The mother may be provided with two Es cut out of cardboard, one for the child to hold and another for the mother to show to the child. When the child is ready for it, a visual acuity chart consisting of Es oriented in various directions may be used. The advantage of

TABLE 11–1. Estimated Visual Acuity at Different Ages

Method	1 mo	2 mo	6 mo	Age at Which 6/6 Achieved
Optokinetic nystagmus	6/120	6/60	6/30	20–30 mo
Preferential looking	6/120	6/60	6/30	24–36 mo
Visually evoked potentials	6/120	6/60	6/6–6/12	6–12 mo

Modified from Dobson V, Teller D: Visual acuity in human infants. A review and comparison of behavioral and electro-physiological studies. *Vision Res* 18:1469, 1978.

presenting the Es in a linear arrangement on a test chart over isolated optotypes held before the child when screening for amblyopia is discussed in Chapter 14. Many children have no difficulty in showing whether the E points up or down but become confused when the E points to the right or left. This has nothing to do with vision as such, but with difficulties in orientation. If a child repeatedly has a perfect score with the Es pointing up or down, we tend to give less weight to the errors in pointing right or left. To a preschool child the E is meaningless, even if it is spoken of by the examiner as an animal with three legs. Sjögren has replaced the E with the isolated figure of a hand, and in some children this works better than Es.

When the child is able to verbalize but not old enough to indicate directions reliably, visual acuity charts showing pictures rather than symbols, such as the illiterate E, may be used. Many such charts have been devised and one should be chosen that presents pictures of objects with which the child is likely to be familiar. We have found the Allen Preschool Vision Test, which presents pictures of objects familiar to most children in the Western Hemisphere in an isolated form, especially useful for this purpose (Fig. 11-3).

Measurement of Visual Acuity in School-Age Children and Adults

When testing children of school age and adults, the ophthalmologist may employ any of the sys-

tems (charts, projection devices) used routinely in the examination of patients.

Latent nystagmus that becomes manifest when one eye is covered (see Chapter 23) may cause reduced vision of the exposed eye. In such cases it becomes necessary to resort to blurring of one eye with plus lenses of sufficient power to reduce the vision but not strong enough to provoke a nystagmus. In school-age children and adults, vision should be tested also at near. This can be done with Snellen charts, reduced photographically for near vision distance, or by reading charts.

Refraction

An essential and hardly preliminary part of the examination is determination of the refractive error of a patient with neuromuscular anomalies of the eyes. One must always strive to obtain as complete and accurate an estimate of the refractive error as possible.

Cycloplegic refraction should be carried out in every patient with strabismus, but procedures adopted by different ophthalmologists may vary. The statement has been made repeatedly that 1% cyclopentolate is less effective as a cycloplegic agent than 1% atropine sulfate in hypermetropic, esotropic, and normal children.^{27, 45, 54} Others believe that cyclopentolate applied in the examiner's office one to three times at 5-minute intervals is sufficient to produce good cycloplegia.



FIGURE 11-3. The Allen Preschool Vision Test. (Courtesy of Ophthalmix, La Grange, IL.)

In most patients we induce cycloplegia in the office. We use two instillations of 1% cyclopentolate for white patients and one drop of 5% homatropine hydrobromide for non-whites. Since 1% cyclopentolate may cause a transient increase in blood pressure in infants, we use a 0.5% solution for this age group and add a drop of 2.5% phenylephrine hydrochloride (Neo-Synephrine Hydrochloride) if mydriasis is unsatisfactory.

We have found two simple tricks to be amazingly helpful in overcoming the unpleasantness associated with application of eye drops in children. The first is to maintain the plastic bottle containing the medication at body temperature by carrying it in a shirt or coat pocket. The stinging sensation of the cycloplegic agent is less severe than when the drops are instilled at room temperature. Second, one drop applied to the back of the patient's or mother's hand to show that the "medicine" does not burn will help to alleviate the child's apprehension.

In non-white children under 3 years of age and in those in whom accommodation remains active despite repeated instillation of cyclopentolate and homatropine, we prescribe 1% atropine sulfate solution, one drop to be instilled in each eye morning and night for 3 days. On the fourth day, the day of the examination, one drop is to be given in each eye 1 hour before the appointment time. This dosage may be excessive in view of a recent study according to which the additional cycloplegic effect of 3-day atropinization vs. two single instillations followed by refraction 90 minutes later was only 0.5D.²

A printed instruction sheet is handed to the parents, which, in addition to the dosage, describes the signs of atropine toxicity and the warning to discontinue the drug if the child seems sensitive to it. By having the mother apply the drops at home, the physician is relieved of one aspect of the examination that is unpleasant to many children, who may become apprehensive or uncooperative on future office visits.

To properly instill atropine solution at home the child should be recumbent. The drops are placed on the conjunctiva of the lower lid, which must be somewhat pulled away from the eye and held away from it for a few seconds to avoid the fluid being squeezed out by the lids. The canaliculi should be compressed for 30 seconds to reduce absorption of the atropine through the nasal mucosa. The dropper must not be brought into contact with the conjunctiva, but also must not be

held too high lest there be some unpleasantness from the impact of the falling drop. Although one drop is prescribed, the mother is advised that she may use a second drop if the first one lands mostly on the cheek. In spite of careful instruction, not all mothers are successful in applying the drops, which is why some ophthalmologists prefer the use of atropine sulfate in an ointment. This somewhat messy method has the disadvantage that the dosage is difficult to control, and the child may receive an unnecessarily large amount of atropine, which, after all, is a very potent alkaloid.

Even the best and most complete cycloplegic refraction does not guarantee that one can successfully perform retinoscopy on a child. Some children are too restless or obstreperous and cannot be persuaded to cooperate. An assistant may immobilize them by holding or bundling them,⁴¹ but these procedures are crude and rather frightening to the child. We have found it helpful to ask the mother to withhold the feeding bottle from an infant until we are ready to start the examination. Most infants are oblivious to their surroundings while feeding, and this provides an excellent opportunity to perform retinoscopy and ophthalmoscopy on an otherwise uncooperative patient. After all, nothing is gained by letting the mother feed her child in the waiting room, so that by the time the physician is ready the infant is sound asleep and reacts with anger and irritation to all attempts to arouse it.

A *fundus examination* is an integral part of the refractive procedure but, unfortunately, it is not always done or is not properly done. We have seen a number of children who had suffered weeks and months of useless occlusion of the better eye because it was thought that the fellow eye was amblyopic but in whom a fundus examination showed a dense macular scar or an atrophy of the optic nerve.

In some patients, an examination and refraction under general anesthesia cannot be avoided. This method permits a thorough inspection of the fundus. In many such instances the size of the deviation and the type of strabismus are such that previous examinations had already indicated the need for an operation. In that case and when the refractive error is found to be insignificant the surgeon may then proceed with the operation as planned, thus saving the child another general anesthesia. On the other hand, if the refractive error is significant, the surgeon should postpone surgery and prescribe glasses as a first step.

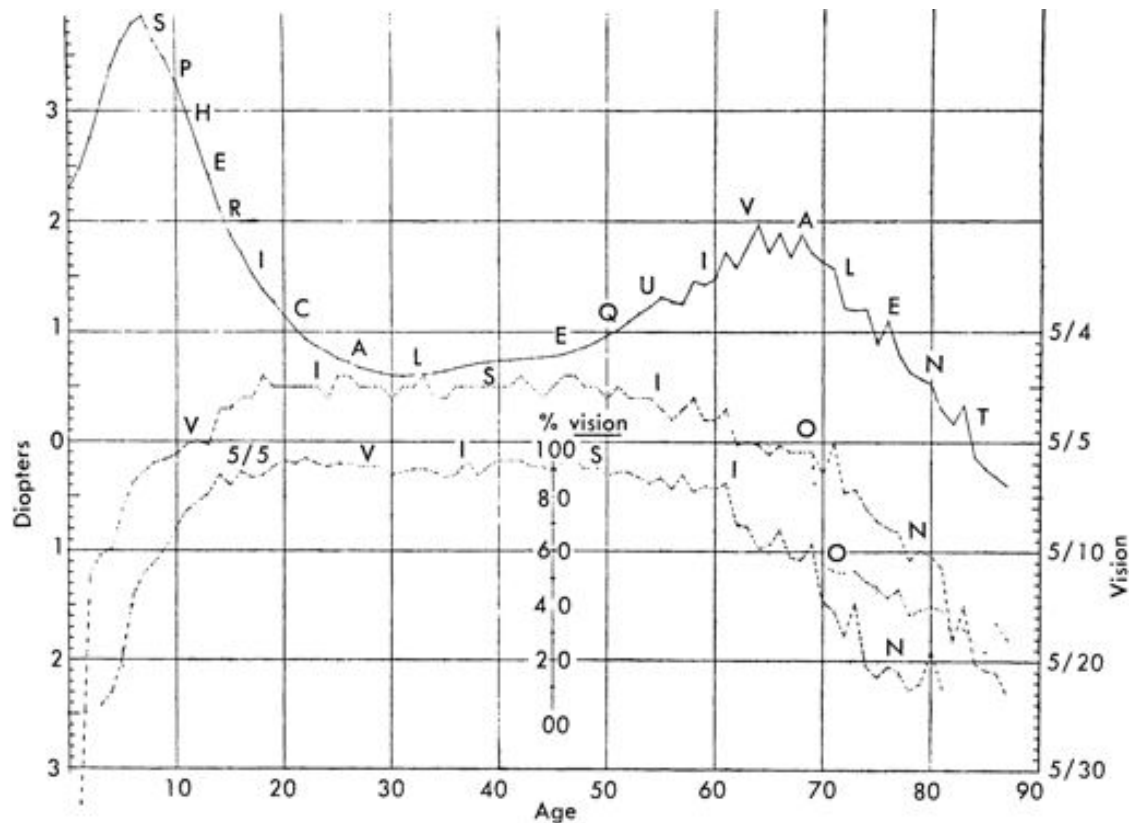


FIGURE 11-4. Relationship between spherical equivalent of refractive error and age (solid line in upper part of graph), based on 35,570 refractions. (Data from Slataper FJ: Age norms of refraction and vision. *Arch Ophthalmol* 43:466, 1950.)

Changes of Refraction with Age

Refraction of neonates and changes of refraction with age need be mentioned only briefly. The opinion, widely held in the past and also recently implied by some authors, that all neonates are hypermetropic and that those few with a congenital stable myopia have an error ranging from plano to 12.0D or more is erroneous. Cook and Glasscock,¹⁰ who performed retinoscopy on 1000 neonates, found 749 to be hypermetropic and 251 to be myopic. Mohindra and Held⁴⁰ followed 400 patients from birth to 5 years of age, and their results showed newborns to be relatively myopic. As they grew older, the myopic spheric equivalent refraction declined and the infants became emmetropic at about 6 months of age and hypermetropic thereafter. This process of "emmetropization" is said to be delayed in the nonfixating eye of strabismic children.^{33, 34} According to Abrahamson and coworkers¹ a hypermetropic refractive error tends to increase with time in esotropia and remains stationary in exotropia.

Another misconception is that the hypermetropia of neonates and infants decreases from birth. Brown⁷ has shown that hypermetropia tends to

increase up to about 7 years of age, at which time it begins to decrease. The data of Slataper,⁵⁰ based on 38,570 refractions (see Fig. 11-4), clearly show this trend and Ingram and Bar²⁶ reported similar findings in 145 children between the ages of 1 and 3½ years.

REFERENCES

1. Abrahamson M, Fabian G, Sjöstrand J: Refraction changes in children developing convergent or divergent strabismus. *Br J Ophthalmol* 76:723, 1992.
2. Auffahrt G, Hunold W: Cycloplegic refraction in children: Single-dose atropinization versus three-day atropinization. *Doc Ophthalmol* 80:353, 1992.
3. Baker FH, Grigg P, Noorden GK von: Effect of visual deprivation and strabismus on the response of neurons in the visual cortex of the monkey, including studies on the striate and prestriate cortex in the normal animal. *Brain Res* 66:185, 1974.
4. Berlyne DE: The influence of the albedo and complexity of stimuli on visual functions in the human infant. *Br J Psychol* 49:315, 1958.
5. Birch E, Shimojo S, Held R: Preferential-looking assessment of fusion and stereopsis in infants aged 1-6 months. *Invest Ophthalmol Vis Sci* 26:366, 1985.
6. Boothe RG, Dobson V, Teller DY: Postnatal development of vision in human and nonhuman primates. *Annu Rev Neurosci* 8:495, 1985.
7. Brown EV: Net average yearly change in refraction of atropinized eyes from birth to beyond middle age. *Arch Ophthalmol* 19:719, 1938.

8. Campos EC: Amblyopia revisited: Evidence for the heterogeneity of the syndrome. *Int Ophthalmol* 13:327, 1989.
9. Campos EC, Chiesi C: Critical analysis of visual function evaluating techniques in newborn babies. *Int Ophthalmol* 8:25, 1985.
10. Cook RC, Glasscock RE: Refractive and ocular findings in the newborn. *Am J Ophthalmol* 34:1407, 1951.
11. Dayton GO Jr, Jones MH, Ain P, et al: Developmental study of coordinated eye movements in man. I. Visual acuity in the newborn human: A study based on induced optokinetic nystagmus recorded by electro-oculography. *Arch Ophthalmol* 71:865, 1964.
12. Dobson V: Visual acuity testing in human infants: From laboratory to clinic. In Simons K, ed: *Early Visual Development, Normal and Abnormal*. New York, Oxford University Press, 1993, p 318.
13. Dobson V, Teller D: Visual acuity in human infants: A review and comparison of behavioral and electro-physiological studies. *Vision Res* 18:1469, 1978.
14. Dobson V, Teller D, Lee CP, et al: A behavioral method for efficient screening of visual acuity in young infants. I. Preliminary laboratory development. *Invest Ophthalmol Vis Sci* 17:1142, 1978.
15. Ellis GS, Hartmann EE, Love A, et al: Teller Acuity Cards versus clinical judgment in the diagnosis of amblyopia with strabismus. *Ophthalmology* 96:788, 1988.
16. Enoch JM, Campos EC: Helping the aphakic neonate to see. *Int Ophthalmol* 8:237, 1985.
17. Enoch JM, Rabinowicz IM: Early surgery and visual correction of an infant born with unilateral eye lens opacity. *Doc Ophthalmol* 41:371, 1976.
18. Fantz R: Pattern vision in young infants. *Psychol Rec* 8:43, 1958.
19. Fantz RL, Ordy JM, Udelf M: Maturation of pattern vision in infants during the first six months. *J Comp Physiol Psychol* 55:907, 1962.
20. Friendly DS, Jaafar MS, Morillo DL: A comparative study of grating and recognition visual acuity testing in children with anisometric amblyopia without strabismus. *Am J Ophthalmol* 110:293, 1990.
21. Fulton AB, Hansen RM, Mayer DL, et al: Clinical examination of infant visual status. In Simons K, ed: *Early Visual Development, Normal and Abnormal*. New York, Oxford University Press, 1993, p 309.
22. Gorman JJ, Cogar DG, Gellis SS: An apparatus for grading the visual acuity of infants on the basis of optokinetic nystagmus. *Pediatrics* 19:1088, 1957.
23. Gwiazda J, Brill S, Held R: New methods for testing infant vision. *Sightsaving Rev* 49:61, 1979.
24. Held R, Birch E, Gwiazda J: Stereoacuity in human infants. *Proc Natl Acad Sci U S A* 77:5572, 1980.
25. Hendrickson AE: Primate foveal development: A microcosmos of current questions in neurobiology. *Invest Ophthalmol Vis Sci* 35:3129, 1994.
26. Hubel DH, Wiesel TN: Binocular interaction in striate cortex of kittens reared with artificial squint. *J Neurophysiol* 28:1041, 1965.
27. Ingram RM, Barr A: Refraction of 1-year-old children after cycloplegia with 1% cyclopentolate: Comparison with findings after atropinization. *Br J Ophthalmol* 63:348, 1979.
28. Jacobson SG, Mohindra I, Held R: Visual acuity of infants with ocular diseases. *Am J Ophthalmol* 93:198, 1982.
29. Katsumi O, Denno S, Arai M, et al: Comparison of preferential looking acuity and pattern reversal evoked response acuity in pediatric patients. *Graefes Arch Clin Exp Ophthalmol* 235:684, 1997.
30. Katz B, Sireteanu R: The Teller Acuity Card Test: A useful method for the clinical routine? *Clin Vis Sci* 5:307, 1990.
31. Kiff AD, Lepard C: Visual responses in premature infants. Use of optokinetic nystagmus to estimate visual development. *Arch Ophthalmol* 75:631, 1966.
32. Kushner GJ, Lucchese NJ, Morton GV: Grating acuity with Teller cards compared to Snellen acuity in literate patients. *Arch Ophthalmol* 113:485, 1995.
33. Leffertstra LJ: Vergleichende Untersuchungen auf unterschiedliche Refraktionsänderungen beider Augen bei Patienten mit Strabismus convergens. *Klin Monatsbl Augenheilkd* 170:74, 1977.
34. Lepard CW: Comparative changes in the error of refraction between fixing and amblyopic eyes during growth and development. *Am J Ophthalmol* 80:485, 1975.
35. Marg E, Freeman DN, Peltzman P, et al: Visual acuity development in human infants: Evoked potential measurements. *Invest Ophthalmol* 15:150, 1976.
36. Mayer DL: Acuity of amblyopic children for small field gratings and recognition stimuli. *Invest Ophthalmol Vis Sci* 27:1148, 1986.
37. Mayer DL, Beiser AS, Warner AF, et al: Monocular acuity norms for the Teller Acuity Cards between ages one month and four years. *Invest Ophthalmol Vis Sci* 36:671, 1995.
38. Mayer L, Fulton A, Rodier D: Grating and recognition acuities of pediatric patients. *Ophthalmology* 91:947, 1984.
39. McDonald M, Dobson V, Sebris S, et al: The acuity card procedure: A rapid test of infant acuity. *Invest Ophthalmol Vis Sci* 26:1158, 1985.
40. Mohindra I, Held R: Refractions in humans from birth to 5 years. *Doc Ophthalmol* 28:19, 1981.
41. Morgan AL, Arstikaitis M: Examination of children. In *Ophthalmologic Staff of the Hospital for Sick Children, Toronto, eds: The Eye in Childhood*. St Louis, Mosby-Year Book, 1967, p 17.
42. Noorden GK von: Klinische Aspekte der Deprivationsamblyopie. *Klin Monatsbl Augenheilkd* 173:464, 1978.
43. Noorden GK von, Crawford ML: The sensitive period. *Trans Ophthalmol Soc U K* 99:442, 1980.
44. Parks MM, Wheeler MB: Concomitant esodeviation. In Duane TD, Jaeger EA, eds: *Clinical Ophthalmology. Ocular Motility and Strabismus*, vol 1. Philadelphia, JB Lippincott, 1988, p. 2.
45. Rosenbaum AL, Bateman JB, Bremer DL, et al: Cycloplegic refraction in esotropic children: Cyclopentolate versus atropine. *Ophthalmology* 88:1031, 1981.
46. Rydberg A: Assessment of visual acuity in adult patients with strabismic amblyopia. *Acta Ophthalmol Scand* 75:611, 1997.
47. Dobson V: Visual acuity testing in infants: from laboratory to clinic. In: Simons K, ed: *Early Visual Development, Normal and Abnormal*. New York, Oxford University Press, 1993, p 318.
48. Sireteanu R, Fronius M, Katz B: A perspective on psychophysical testing in children. *Eye* 4:794, 1990.
49. Skoczinski AM, Norcia A: Development of VEP vernier acuity and grating acuity in human infants. *Invest Ophthalmol Vis Sci* 40:2411, 1999.
50. Slataper FJ: Age norms of refraction and vision. *Arch Ophthalmol* 43:466, 1950.
51. Sokol S: Measurement of infant visual acuity from pattern reversal evoked potentials. *Vision Res* 18:33, 1978.
52. Sokol S, Moskowitz A: Comparison of pattern VEPs and preferential-looking behavior in 3-month-old infants. *Invest Ophthalmol Vis Sci* 26:359, 1985.
53. Spierer A, Royzman Z, Chetrit A, et al: Vision screening of preverbal children with Teller Acuity Cards. *Ophthalmology* 849:106, 1999.
54. Stolovitch C, Loewenstein A, Nehmet P, et al: The use of cyclopentolate versus atropine cycloplegia in esotropic Caucasian children. *Binocular Vision Q* 7:93, 1992.
55. Teller DY: The forced choice preferential looking proce-

- dure. A psychophysical technique for use with human infants. *Infant Behav Dev* 2:135, 1979.
56. Teller DY: First glances: The vision of infants (Friedenwald Lecture). *Invest Ophthalmol Vis Sci* 38:2183, 1997.
57. Teller DY, Movshon JA: Visual development. *Vision Res* 26:1483, 1986.
58. Tomlinson E, Martinez D: The measurement of visual acuity: Comparison of Teller Acuity Cards with Snellen and MBL results. *Am Orthoptics J* 38:130, 1988.
59. Van Hof-van Duin J, Mohn G: Optokinetic and spontaneous nystagmus in children with neurological disorders. *Behav Brain Res* 10:163, 1983.
60. Wiesel TH, Hubel DH: Effects of visual deprivation on morphology and physiology of cells in the cat's lateral geniculate body. *J Neurophysiol* 26:978, 1963.

Examination of the Patient—II

MOTOR SIGNS IN HETEROPHORIA AND HETEROTROPIA

Inspection of the Eyes and Head Position

Inspection of the Lids and Lid Fissures

When examining the eyes, attention should be given to the lid fissures, their width, and their direction, by means of an imaginary line connecting the inner and outer canthus. If the two lid fissures are different in width, the possibility of *ptosis* or *pseudoptosis* of the upper lid with the narrow lid fissure must be considered and the two conditions differentiated.

A weakness of elevation of one eye will cause the lid fissure to be narrower than that of the unaffected eye. The patient may have true *ptosis* of the upper lid, especially if the superior rectus muscle is involved. However, the lid may only appear to be *ptotic* as a result of narrowness of the lid fissure caused by the *hypotropic* position of the globe (Fig. 12–1A). This is known as *pseudoptosis* and can be established by having the patient fixate with the affected eye (Fig. 12–1B). If *pseudoptosis* is present, the lids will open to their normal width. The lids of the unaffected eye will widen abnormally as the elevators of that eye

receive excessive innervation according to Hering's law (see p. 64), and the left globe moves into a *hypertropic* position.

To correct a *pseudoptosis*, the only requirement is that the eyes be brought to the same level by operating on the appropriate extraocular muscles. Any operation on the levator muscle of an eye with *pseudoptosis* is a serious mistake. One should also ascertain whether the width of one lid fissure changes when the patient moves the eyes to the right or left, as in *retraction syndrome* (see Chapter 21), when the jaw is moved, or when the patient speaks or chews, as occurs in the jaw-winking phenomenon of *Marcus Gunn*.

In infants the *epicanthus* frequently is more or less pronounced with a semilunar fold of skin running downward at the side of the nose and its concavity directed toward the inner canthus.³⁹ The *epicanthus* varies considerably in width and may approach and obscure the inner canthus, which may create the appearance of *esotropia* when none is present (Fig. 12–2A). This is a common cause of *pseudostrabismus*. In time, the bridge of the nose develops, and in whites the *epicanthal* fold normally disappears. The examiner may demonstrate to anxious parents that *pseudostrabismus* disappears by lifting the skin from the nasal bridge

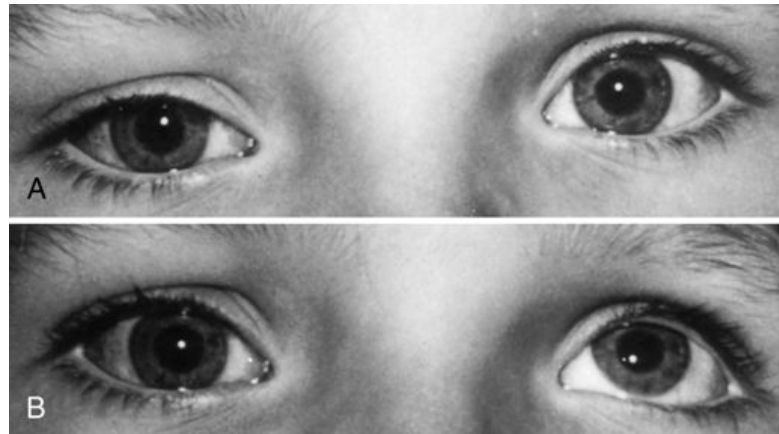

FIGURE 12-1. Pseudoptosis in a patient with right hypotropia caused by a paretic right superior rectus muscle and secondary left hypertropia. *A*, Patient fixating with left eye; apparent ptosis of right upper lid. *B*, Patient fixating with right eye; lid fissure wide open. Left hypertropia.

(Fig. 12-2*B*). Mongoloid and antimongoloid positions of the lid fissures are occasionally observed in patients with the *A* and *V* patterns of strabismus (see Chapter 19) and should alert one to the presence of such patterns.

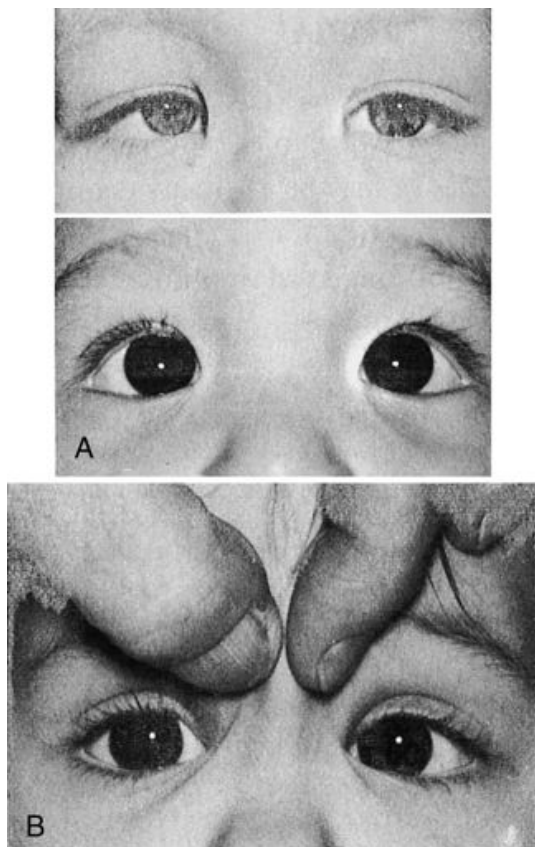


FIGURE 12-2. Pseudostrabismus. *A*, A prominent epicanthus may obscure some or all of the usually visible nasal aspects of the globe, thus giving the false impression that esotropia is present. *B*, For explanation, see text. (From Noorden GK von: *Atlas of Strabismus*, ed. 4. St Louis, Mosby-Year Book, 1983, p 29.)

Position of the Globes—Angle Kappa

The best means of estimating the relative position of the eyes is to have the patient fixate a penlight at near vision and then at distance while the light is held so that reflections from the cornea can be obtained. If reflected images from the two corneas appear centered under both conditions, one can assume that the eyes are properly aligned in distance and near fixation. Estimation of the angle of strabismus by fixation on a light should be used only when examining uncooperative patients or infants too young to sustain fixation of an accommodative target at near, since *the state of accommodation is uncontrolled with this method*.

Unusually narrow or unusually wide *interpupillary distances* should be noted. Narrow ones may create the impression that an esotropia is present. Of course, actual heterotropias may coexist with abnormal interpupillary distances.

Facial asymmetries also may create the impression that a hypertropia is present. In such instances the lid fissure and the whole eye may appear to be higher on one side than the other. However, further examination will reveal that, contrary to the impression given by the patient's appearance, there is no hypertropia, or a hyperphoria may actually be present in the eye opposite the one thought to be involved.

Gross manifest deviations in primary position are readily detected by inspection. However, small deviations may escape detection, or the presence of a deviation may erroneously be assumed to exist because of the presence of a large *angle kappa*. An angle kappa is caused by failure of the *pupillary and visual axes* of the eye to coincide

(Fig. 12-3). The pupillary axis is the line passing through the center of the apparent pupil perpendicular to the cornea. The visual axis (or the *line of sight*) connects the fovea with the fixation point.⁷⁴ The angle kappa is formed at the intersection of these two axes at the center of the entrance pupil. The angle kappa has also been referred to as the *angle lambda* in the older literature.^{48; 53, p.80} The visual axis does not always coincide with the *optical axis* (defined as the line connecting the optical centers of cornea and lens) with which it forms the *angle alpha* at the nodal point and the *angle gamma* at the center or rotation of the eye. All these angles are geometric constructions (Fig. 12-4), and only the angle kappa can actually be measured and is of practical importance.

As a rule, the pupillary axis touches the posterior pole of the globe slightly nasal and inferior to the fovea. As a result, when an eye fixates a penlight, the reflection from the cornea will not be centered but will be located in a position slightly nasal to the center. This is termed a *positive angle kappa* (Fig. 12-5). The student may find it helpful to remember “positive to nose.” A sufficiently large positive angle kappa may simulate an exodeviation and produce pseudostrabismus. An existing exodeviation will look worse than it actually is, or it may mask all or part of an esodeviation.

If the fovea’s position is nasal to the point at which the optical axis cuts the globe’s posterior

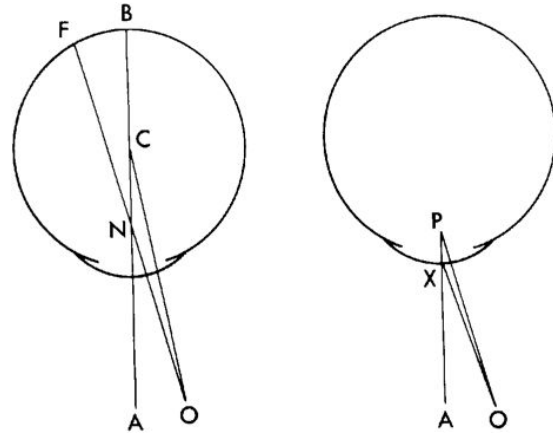


FIGURE 12-4. Definition of angles. C, center of rotation; F, fovea; N, nodal point; O, point of fixation; P, center of pupil; X, point of cornea that lies in the central pupillary line; AB, optical axis; AP, central pupillary line; OC, fixation axis; OF, visual axis; angle ONA, angle alpha; angle OCA, angle gamma; angle OPA, angle kappa; angle OXA, angle kappa, as measured clinically. Angle lambda not defined. (From Lyle TK, Wybar KC: Lyle and Jackson’s Practical Orthoptics in the Treatment of Squint [and Other Anomalies of Binocular Vision], ed 5. Springfield, IL, Charles C Thomas, 1967.)

pole, the corneal reflection of a light fixated by that eye will appear to lie on the temporal side of the pupillary center. In this case the term *negative angle kappa* is used. A negative angle kappa may simulate an esodeviation and again produce a pseudostrabismus, may make an existing esotropia look worse than it actually is, or may mask all or part of an exodeviation. Pseudoesotropia second-

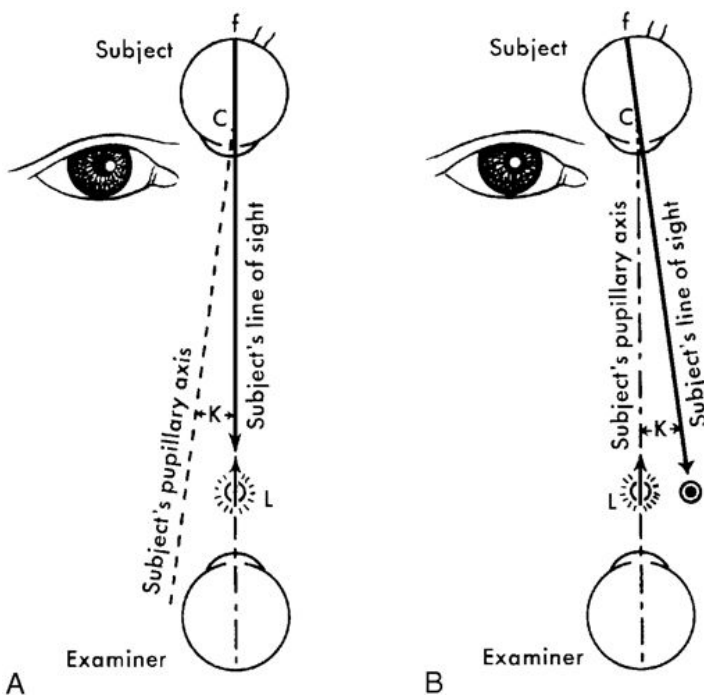


FIGURE 12-3. Angle kappa. A, When the observer places his or her eye in line with the light located on the subject’s line of sight, the reflection of that light appears displaced nasalward on the cornea. B, When the examiner brings his or her eye and the light into line with the patient’s pupillary axis, the reflection of the light appears centered.

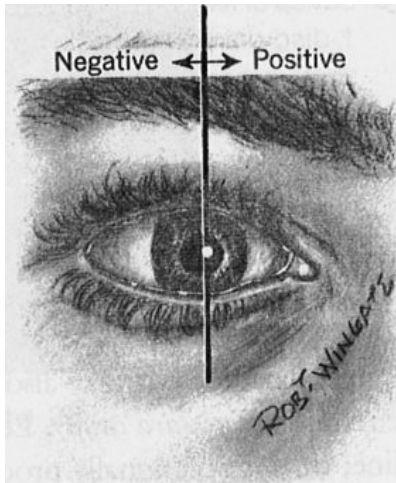


FIGURE 12-5. The angle kappa. The angle is called positive when the light reflex is displaced nasalward and negative when it is displaced templeward. (From Noorden GK von: Atlas of Strabismus, ed 4. St Louis, Mosby-Year Book, 1983, p 33.)

ary to nasal displacement of the fovea may be caused by high myopia. A negative angle kappa is less common than a positive angle kappa, but it is not correct to say that a negative angle kappa is always pathologic.^{28; 104, p.290} This statement, which has been repeated in many texts, especially orthoptic texts, gives the wrong impression. Fundus examination does not always reveal visible anomalies when a negative angle kappa is present.

However, because of traction of the retina in cases of retinopathy of prematurity, a true pathologic ectopia of the macula is accompanied by a positive angle kappa. The macula is pulled in the temporal direction, causing pseudoexotropia (Fig. 12-6). Other causes of ectopic macula include scarring from *Toxocara canis* retinitis or congenital retinal folds. The condition may be bilateral and may occur in siblings.⁴³

A vertical angle kappa, simulating a hyperdeviation, is usually (but not always¹¹) caused by superior or inferior displacement of the macula from a retinal scar.

Measurement of Angle Kappa

For clinical purposes it suffices to observe the position of the corneal light reflection while the patient fixates monocularly on a penlight. To avoid parallax, the examiner's eye must be aligned with the fixation light. A more accurate determination of the angle formed between the visual and pupillary axes can be made by observing catoptric (Purkinje) images using, for example, Tscherning's ophthalmophacometer,¹²² which consists of a telescope on a graduated arc provided with suitable lights. With the visual axis of the subject coincident with the axis of the telescope, the Purkinje images are displaced sideways or vertically,

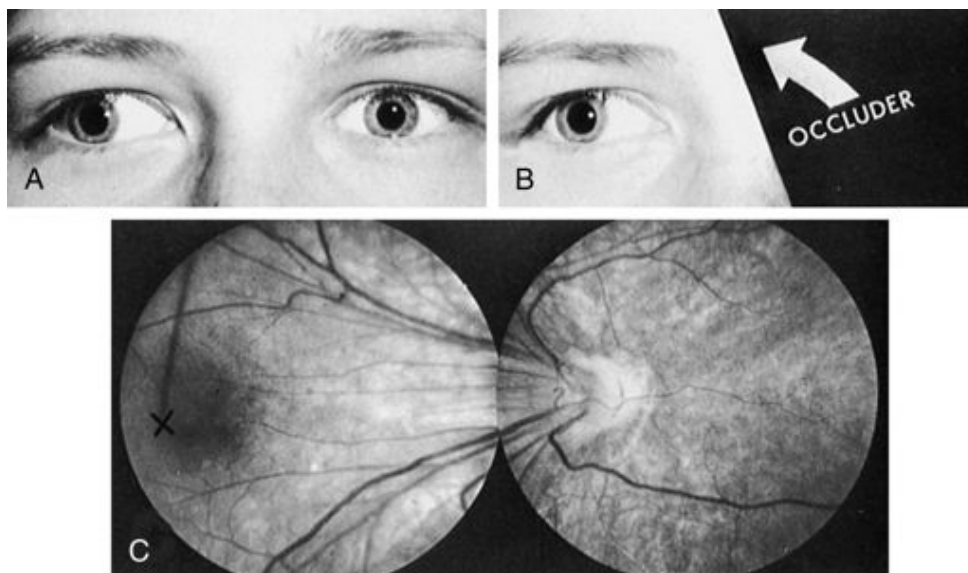


FIGURE 12-6. Pseudostrabismus caused by ectopic macula. *A*, The patient appears to have a large right exotropia (XT). The Hirschberg test showed an XT of 20° to 25°. *B*, No shift of OD occurs when OS is covered. *C*, Fundus photographs reveal an ectopic macula. The tip of the fixation target (X) indicates the position of the fovea, which is displaced several disk diameters templeward. The retinal blood vessels are pulled over templeward. This patient had been born prematurely and for several weeks was kept in an incubator with high oxygen concentration. (From Noorden GK von: Atlas of Strabismus, ed 4. St Louis, Mosby-Year Book, 1983, p 35.)

depending on the orientation of the phacometer. Fixation on a small object moved along a graduated arc brings the Purkinje images into the center of the pupil, and the optical axis is now coincident with the telescope's axis. The angle kappa is measured by determining the distance in degrees by which the fixation object has to be moved along the arc. This elegant and accurate instrument is no longer available and has been replaced by less precise but clinically useful methods.

Shifting of fixation and therefore of the visual line is used to measure the angle with a major amblyoscope. A special slide, bearing a horizontal row of letters and numbers separated by intervals of 1° or 2° , is inserted into one arm of the major amblyoscope. The patient is asked to fixate the zero, and the position of the corneal light reflection is observed. The patient shifts fixation to each of the letters or numbers in turn until the light reflection is centered on the cornea, which gives the angle kappa in degrees. The angle is positive for the right eye if fixation has to be shifted to the numbers (left), negative if it has to be shifted to the letters (right), and vice versa for the left eye (Fig. 12-7).

The angle kappa also may be measured clinically using a procedure similar to Tscherning's laboratory method. A seated patient's head is adjusted in front of a perimeter arc. One eye is occluded, and with the other eye the patient fixates the central fixation mark on the arc. The examiner closes one of the patient's eyes and places a small penlight or ophthalmoscope light firmly under the lower lid of the open eye. The patient first places his or her head and the light in line with the visual axis and observes the reflection from the cornea. If this reflection is not centered, the patient's head is moved with the light until centering is achieved. At this point the light coincides with the optical axis. If the patient has to move the light to the left for the right eye (temporally in relation to the patient) or to the right for the left eye, the angle

kappa is positive. In contrast, when using the major amblyoscope test, which is based on a different principle, the patient must turn the right eye to the left to compensate for a positive angle.

Size of Angle Kappa

Donders³⁵ found a positive angle kappa that varied from 3.5° to 6.0° with an average of 5.082° in emmetropic eyes and from 6.0° to 9.0° with an average of 7.55° in hypermetropic eyes. In myopic eyes the angle kappa was generally smaller, averaging around 2.0° , and may even be negative.³³ Donders's findings that emmetropes and hypermetropes tend to have a larger angle kappa than myopes was confirmed in a more recent study by Giovanni and coworkers⁴⁹ (Table 12-1). Although mean values reported by these authors are smaller than those of Donders, they are in line with an average angle kappa of 2.6° as measured by Franceschetti and Burian⁴⁶ in a random population of 334 subjects.

Clinical Significance of Angle Kappa

Since it may simulate, conceal,* or exaggerate a deviation, the angle kappa must be considered to obtain the best estimate of the actual deviation in patients in whom this determination is made by the corneal reflection test. When the deviation has been so determined because of low visual acuity in one eye, an operation to improve the patient's appearance is usually indicated. In such cases it is best to disregard the angle kappa and its measurements. Cosmetic operations are performed to make the eyes appear straight, not for aligning the

*Prof. Schweigger of Berlin is reported to have said of the angle kappa (Wiesinger¹²⁶), *ille mihi praeter omnes angulos ridet* (this corner [angle] smiles at me beyond all others) (Horace, *Odes* II, vi, 13) because of its role in the improved appearance of some patients after not fully successful operations.



FIGURE 12-7. Amblyoscope slide for the measurement of angle kappa.

TABLE 12-1. Distribution of the Angle Kappa in 483 Subjects with Emmetropia, Hypermetropia, and Myopia

	No.	Emmetropia (mean)	Hypermetropia (mean)	Myopia (mean)
Positive	180	73.9% (2.8°)	85.0% (2.4°)	75.85% (1.9°)
Negative	208	10.5% (1.4°)	3.8% (2.1°)	11.6% (2°)
Null	95	15.6%	11.2%	12.6%

Modified from Giovanni FG, Siracusano B, Cusmano R: The angle kappa in ametropia. *New Trends Ophthalmol* 3:27, 1988.

visual axes properly to facilitate binocular vision. If one were to aim at aligning the visual axes in a patient with a large angle kappa to facilitate binocular vision, the relative postoperative position of the eyes might be cosmetic overcorrection or undercorrection. No mother would appreciate an exotropic appearance of her previously esotropic daughter, even if the ophthalmologist could assure her quite correctly that the visual axes are now parallel.

Observation of Head Position

Patients with *comitant* heterotropias, especially those with comitant horizontal heterotropias, usually carry their head in a normal position, but there are exceptions.

In patients with nystagmus, the frequency and amplitude of the nystagmus may be reduced or there may be no nystagmus when the eyes are directed to one or the other side (see Chapter 23). In this position visual acuity is optimal. The patient keeps the head turned to one side (e.g., to the left) to bring the eyes into this optimal position (say, dextroversion) when looking straight-ahead. Patients who have a high amblyopia of one eye occasionally tend to turn their head in a direction away from the amblyopic eye, especially when reading or looking intently at an object. Patients with infantile esotropia, manifest-latent nystagmus, and strong fixation preference for one eye often have their face turn toward the side of the fixating eye (see Chapter 16).

Abnormal head positions in connection with *incomitant* and *paretic deviations* are usually assumed in the interest of obtaining binocular cooperation or avoiding diplopia. Abnormal head positions take either the form of *tipping the chin up or down*, a *head turn* (i.e., a turn around a vertical axis), or a *head tilt* to one shoulder. For example, a patient with an *A* or *V* pattern of deviation (see

Chapter 19) may tend to carry the head with the chin depressed or elevated. On the other hand, a patient with a right lateral rectus paresis may turn the head to the right, causing levoversion to bring the eyes into a position in which the right lateral rectus muscle receives no impulses to contract. With these positions of head and eyes, patients avoid diplopia and gain binocularity.

Bielschowsky wrote that “the patient chooses the least inconvenient position of the head by which the paretic muscle is sufficiently relieved so that binocular single vision can be obtained.”^{13, p.99} In many instances a patient will turn or tilt the head in the direction of the field of action of the paretic muscle. However, if fusion cannot be attained with a compensatory head posture, the head may be positioned to produce maximal separation of the double images. These and other aspects of compensatory head posture are discussed further in Chapter 20. While an anomalous head posture should alert the examiner to search for nystagmus; a paralytic horizontal, vertical, or cyclovertical strabismus; cyclotropia; or an *A* or *V* pattern, normalcy of the head position does not rule out any of these conditions. Moreover, an ophthalmologist must be aware that there are ocular causes unrelated to strabismus for an anomalous head posture, such as an uncorrected refractive error or anomalous retinal correspondence with a vertical angle of anomaly.²⁴ Nonocular causes include fibrosis of the sternocleidomastoid muscle, unilateral hearing loss, or psychogenic torticollis.

Several instruments have been developed to quantify the inclination of the head in degrees.^{104, 114, 115, 128} Among these a cervical range of motion (CROM) device used in physical medicine²⁷ and in assessing craniomandibular disorders¹⁵ also measures the degree of head turn and chin elevation and depression. Such instruments are useful in documenting and quantitating the effect of various surgical procedures on an abnormal head position.

Kushner⁷⁰ has modified the CROM to assess limitations of ductions and the range of single binocular vision at near and distance fixation.*

Determination of Presence of a Deviation—Cover and Cover-Uncover Tests

Inspection alone clearly is not always sufficient to determine a manifest misalignment of the visual axes. An epicanthus, facial asymmetry, or a wide angle kappa may simulate or conceal a deviation. The simple cover and cover-uncover tests establish whether orthotropia or an ocular deviation is present, whether a deviation is latent or manifest, the direction of a deviation, the fixation behavior, and even whether visual acuity is significantly decreased in one eye.

A cover is placed briefly before the eye that appears to fixate while the patient looks at a small object, a figure pasted on a tongue depressor, or a 6/9 visual acuity symbol. *The test should always be done for distance and near fixation* to establish any differences between the two conditions. As a cover, one may use the palm of the hand or some form of occluder or paddle. Covering one eye of a patient with normal binocular vision interrupts fusion.

If the patient has a heterotropia and the fixating eye is covered, the opposite eye, provided it is able to do so, will make a movement from the heterotropic position to take up fixation, and the covered eye will make a corresponding movement in accordance with Hering's law. An exotropia is present when the eye taking up fixation moves toward the nose, an esotropia when it moves toward the temple, and so forth. If there is no movement of the fellow eye, that eye is then covered and the other eye is observed (Fig. 12–8).

When it has been established that no manifest strabismus is present (no movement of the fellow eye when either eye is covered), a cover-uncover test will determine whether the patient has a latent deviation (Fig. 12–9). Again, one and then the other eye is covered while the patient maintains fixation. However, the examiner now directs attention to the covered eye just as the cover is re-

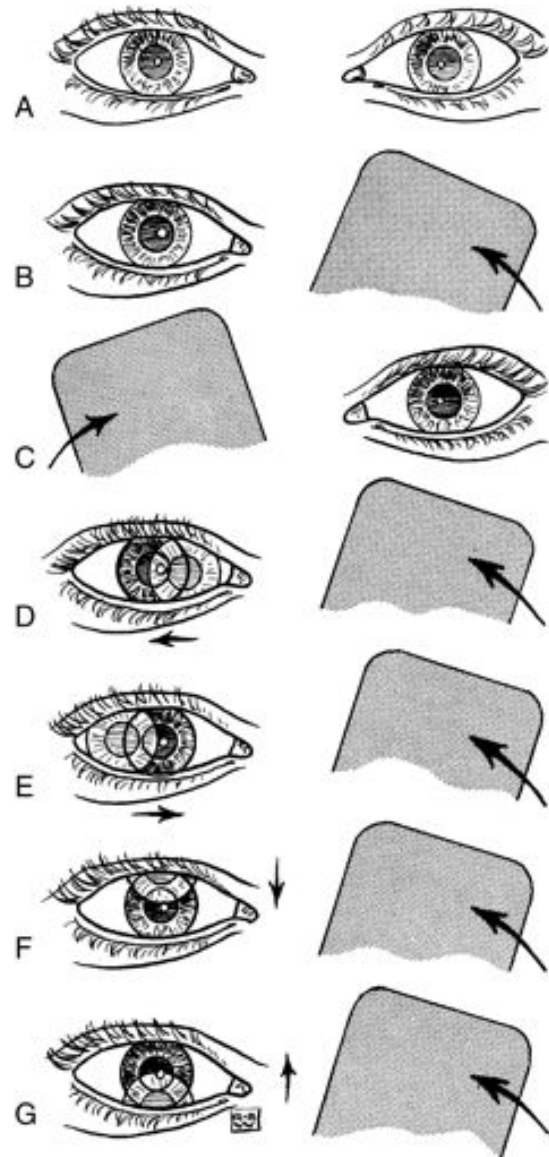


FIGURE 12–8. The cover test. *A*, Position of patient's eyes before the test. *B*, Cover placed over OS from the left does not elicit a fixation movement of OD: no deviation of OD is present. *C*, Cover placed over OD from the right does not elicit a fixation movement of OS: no deviation of OS is present. *D*, OD moves outward to fixate when OS is covered: esotropia. *E*, OD moves inward to fixate when OS is covered: exotropia. *F*, OD moves downward when OS is covered: right hypertropia. *G*, OD moves upward when OS is covered: right hypotropia. (From Noorden GK von: Atlas of Strabismus, ed 4. St Louis, Mosby-Year Book, 1983, p 39.)

moved. If the patient has a heterophoria, the covered eye will deviate in the direction of the heterophoric position. When the eye is uncovered, it will move in the opposite direction to reestablish binocular fixation, that is, toward the nose in exophoria, downward in hypertropia, and so forth.

Once the diagnosis of manifest strabismus has been made, it is possible to establish the degree

*Performance Attainment Associates, 3550 LaBore Rd., Ste 8, St. Paul, MN 55110-5126; or Binoculus 740 Piney Acres Circle, PO Box 3727, Dillon, CO 80435-8727. Phone or fax USA 970-262-0753, email: perxbvq@colorado.net, website: BinocularVision.com

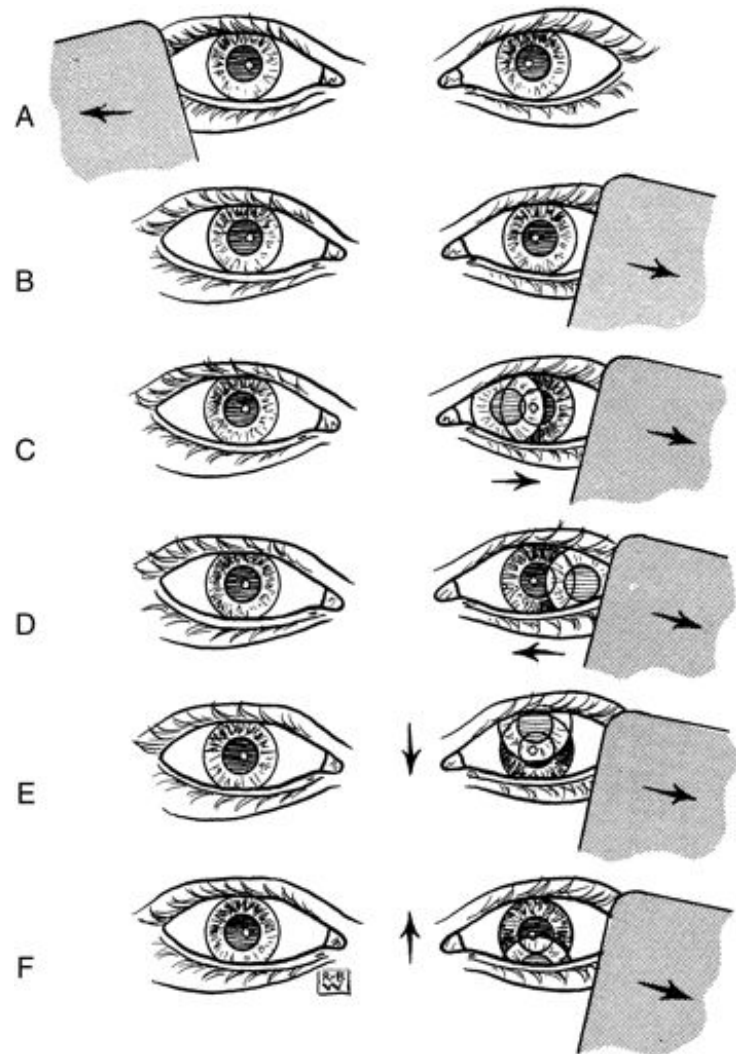


FIGURE 12-9. The cover-uncover test. *A*, Cover has been removed from OD, and no movement of OD can be detected: no latent deviation of OD. *B*, Cover has been removed from OS, and no movement of OS can be detected: no latent deviation of OS. If conditions *A* and *B* are present, the patient has no phorias that can be detected with this test. *C*, When uncovered, OS moves outward to fixate: esophoria. *D*, When uncovered, OS moves inward to fixate: exophoria. *E*, When uncovered, OS moves down to fixate: left hyperphoria. *F*, When uncovered, OS moves up to fixate: left hypophoria. The cover-uncover test must be performed on both eyes. (From Noorden GK von: Atlas of Strabismus, ed 4. St Louis, Mosby-Year Book, 1983, p 43.)

of alternation with the cover-uncover test. The fixation behavior may vary from extreme monocularly, as in patients with deep amblyopia or strong ocular dominance, to free random alternation. In the case of strong dominance the just-uncovered eye will immediately resume fixation as the fellow eye returns to its deviated position. In the case of free alternation the formerly deviated eye will continue to fixate after removal of the cover. If the usually deviated eye continues fixation for some time, for instance, until the lids close during a blink, weak but definitive alternation is present.

The possible results of the cover and cover-uncover tests may be summarized as follows:

1. On covering the seemingly fixating eye:
 - a. No movement of the other eye: there was binocular fixation before applying the cover.
 - b. Movement of redress of the other eye: a manifest deviation was present before applying the cover.

2. On uncovering the eye:

- a. Movement of redress of the uncovered eye (fusional movement); no movement of the other eye: heterophoria is present.
- b. No movement of either eye; uncovered eye deviated; opposite eye continues to fixate: an alternating heterotropia is present.
- c. Uncovered eye makes movement of redress and assumes fixation; opposite eye deviates; preference for fixation with one eye: a unilateral heterotropia is present.

The cover test also allows one to establish by observation whether a gross eccentric fixation (see Chapter 14) is present in a patient with heterotropia. When the fixating eye is covered in such usually esotropic patients, the deviated eye will make no movement of redress or only a small, incomplete one.

Infants often object to having their heads or

faces touched. In such instances the examiner may place a paddle at some distance in the path of one eye while holding a light or some other fixation object with the other hand. This test, which has been termed the *indirect cover test*, does not permit full interruption of fusion but is useful in infants and small children with heterotropia (Fig. 12-10).

When the cover test is applied to the fixating eye in a strabismic infant and the patient consistently pushes the cover aside or performs searching, nystagmoid movements with the fellow eye, chances are high that visual acuity of that eye is low and amblyopia must be suspected. This application of the cover test is of inestimable value in the diagnosis of amblyopia in infants (see Chapter 14). A pseudoptosis (see Fig. 12-1), if present, will disappear when the fellow eye is covered. The cover test may not reveal ultrasmall deviations as seen in microtropia (see Chapter 16), but in most patients this limitation does not reduce the value of this simple test.

A clinically useful modification of the cover test was introduced by Spielmann¹¹² after having been mentioned briefly by Javal.⁶⁶ Instead of an opaque cover a translucent occluder is used through which the examiner can observe or even photograph the covered eye, but through which the patient sees only diffuse light without contours. By using the Spielmann occluder the diagnosis of heterophoria is simplified because the deviation of the covered eye can be directly observed by the examiner without having to remove the cover (see Fig. 8-1). Covering both eyes with translucent occluders permits a quick preliminary

determination of whether an esotropia is of refractive-accommodative or nonaccommodative origin (Fig. 12-11). In the first case the eyes will straighten after covering both eyes; in the second the esotropia will persist. Further applications of the cover test with translucent occluders are discussed in Chapters 18 and 23.

Measurement of Deviation

Tests used to diagnose strabismus usually are classified as *objective* and *subjective*. Objective tests as performed in clinical practice, and even certain laboratory tests, reduce cooperation of the patient to the ability to hold steady fixation. The ophthalmologist performs certain manipulations, makes observations, and draws conclusions from these observations. When using subjective tests the ophthalmologist also performs certain manipulations, but the patient's response determines the results; that is, the patient must make observations and report them.

The opinion is widespread that objective tests are more reliable and therefore preferable to subjective tests.¹⁷ Objective is equated with "good," subjective with "bad." This is erroneous. In common usage objectivity in making a judgment has come to mean that the judgment is not tainted by one's prejudices and feelings. However, in subjective tests for measuring the state of the sensory and motor visual system, a patient's feelings, prejudices, and sense of value are no more suspect than the feelings, prejudices, or value judgments of the examiner. Also, the premise that the patient

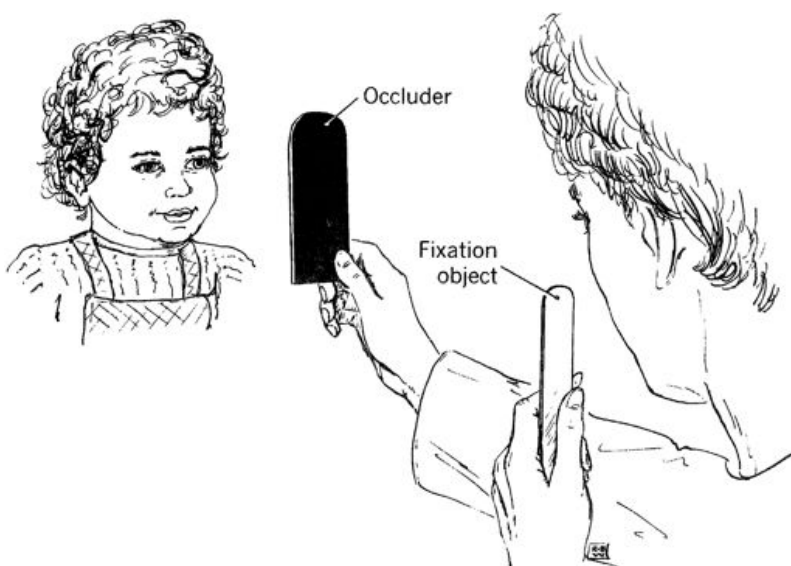


FIGURE 12-10. The indirect cover test. The occluder is placed between the patient's eye and the fixation object. (From Noorden GK von: Atlas of Strabismus, ed 4. St Louis, Mosby-Year Book, 1983, p 41.)

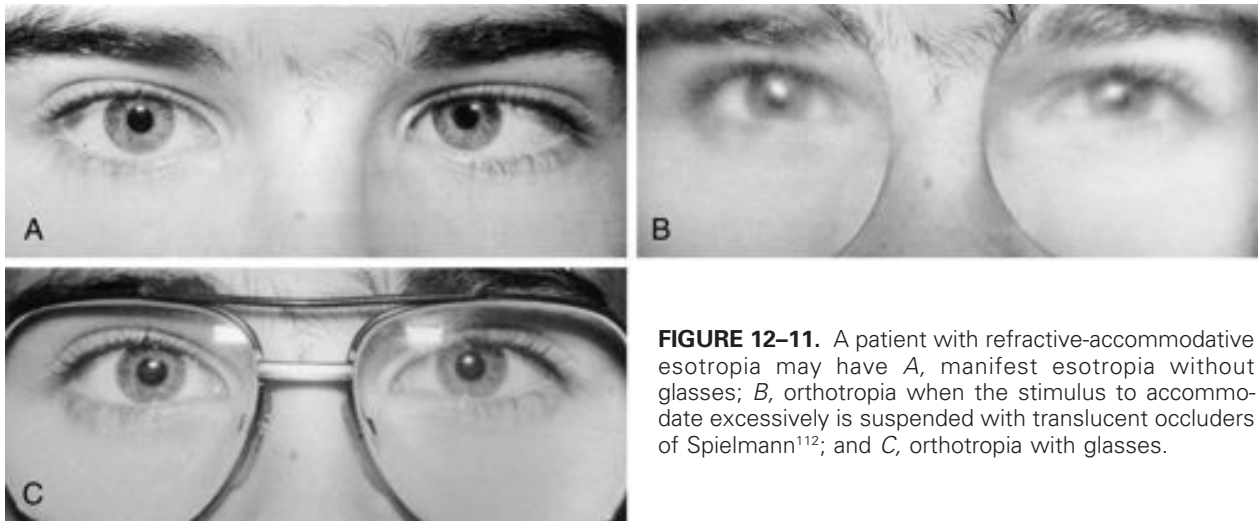


FIGURE 12-11. A patient with refractive-accommodative esotropia may have *A*, manifest esotropia without glasses; *B*, orthotropia when the stimulus to accommodate excessively is suspended with translucent occluders of Spielmann¹¹²; and *C*, orthotropia with glasses.

is a less keen or more biased observer than the ophthalmologist is by no means necessarily correct.

The truth is that most subjective tests are inherently more precise than objective tests. The enormous precision of the great body of psychophysical investigations of the visual system, which are all based on subjective testing, is the best evidence for the value of these tests. Many diagnostic and therapeutic decisions in ophthalmology are based on an assessment of visual acuity, which depends entirely on a patient's response. Is this response less reliable or trustworthy than, say, the patient's localization of double images on any of the diplopia tests? The sensory system can be evaluated clinically only by subjective responses of the patient, although there are laboratory methods that permit the sensory system to be assessed objectively.

When using subjective tests, one expects a patient to be able and willing to cooperate. Verbal responses to a change in a stimulus situation cannot be expected of an infant or someone who is severely mentally defective nor can objective tests requiring attentive fixation be performed on such patients. All tests have their limitations; not all tests are suitable for every age level and every person. This does not make one test intrinsically better or worse than another. The art of the ophthalmologist consists of judiciously applying tests in each case that provide the maximum amount of correct information needed for appropriate treatment.

Prism and Cover Test

The prism and cover test, or the *alternate cover test*, is deservedly popular. It is also known as the

screen cover test, but this term is misleading and should be avoided.⁷²

To perform this test, a cover is placed alternately in front of each eye while the patient maintains fixation. The eye that is uncovered makes a movement of redress in the direction opposite that of the deviation. The amount of the deviation is grossly estimated, and a prism of a strength less than the estimated deviation is placed in the appropriate direction in front of one eye. To measure esotropia, the prism must be placed base-out, for an exotropia base-in, for a right hypertropia base-down in front of the right eye or base-up in front of the left eye, and for a left hypertropia base-down in front of the left eye or base-up in front of the right eye. This manipulation reduces the movement of redress, and the prism strength is increased until the movement is offset (Fig. 12-12).

Combinations of horizontal and vertical deviations are frequent. In such patients it is best to first neutralize the horizontal deviation with prisms and then to add prisms to stop the vertical deviation. At that point, it may be necessary to further correct the horizontal deviation. The amount of prism strength required to offset all movements of redress is a measure of the deviation. Cyclodeviations cannot be measured in this fashion, and must be determined either subjectively or with the major amblyoscope.

Physiologic Basis

Redress in the prism and cover test is a psychophysical reflex movement that occurs when the eye fixates. The sensory origin of this reflex movement stems from stimulation of a peripheral retinal area

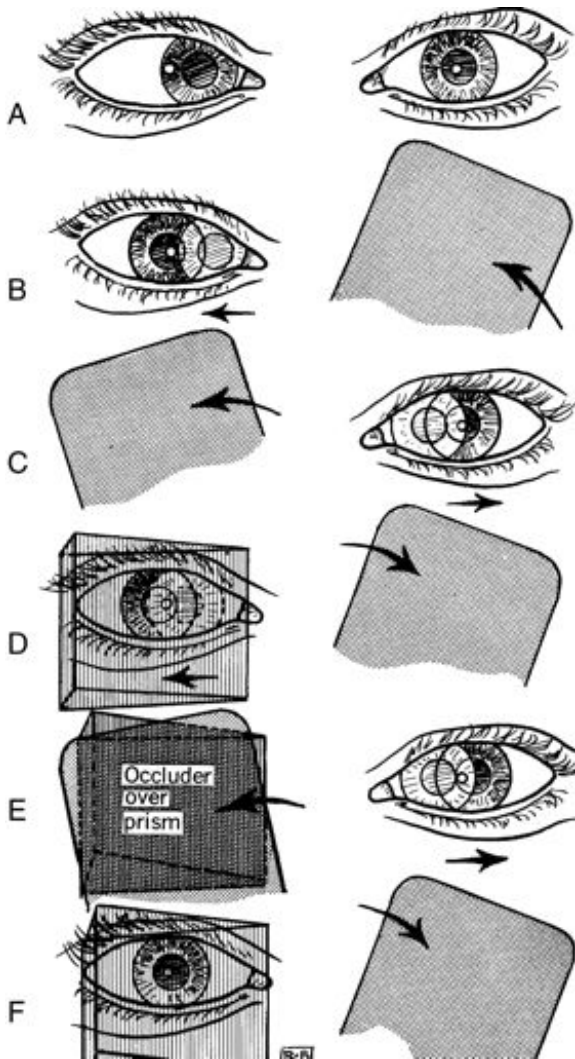


FIGURE 12-12. The prism and cover test. *A*, Right esotropia. *B*, When OS is covered, OD moves outward to take over fixation. *C*, When the cover is transferred to OD, OS moves out to take over fixation. *D*, A prism, base-out, is held before OD; the cover is transferred to OS. There is still outward movement of OD when taking over fixation, although the amplitude of this movement is decreased by the effect of the prism (compare with *B*). *E*, The cover is again transferred, and a prism of greater power is held before OD. *F*, Transfer of cover to OS does not elicit fixation movement of OD. The deviation is offset by the prism, and the power of this prism equals the deviation. (From Noorden GK von: Atlas of Strabismus, ed 4. St Louis, Mosby-Year Book, 1983, p 49.)

in the deviated eye by the fixation object. Fixation causes the eye to turn in such a way that the fixated object is imaged on the fovea. The movement is quantitative and is directly proportional to the distance of the fovea from the stimulated peripheral area. Placing prisms of increasing power in front of the eyes brings the image of the fixated object closer and closer to the fovea, causing a corresponding decrease in the movement of redress. When the prism strength equals the

amount of deviation, the image falls on the fovea. There is no longer an incentive to move the eye, and the movement of redress ceases (Fig. 12-13).

Performance

As is true of most tests to diagnose strabismus, the prism and cover test is technically very simple, yet findings can be misleading unless the test is understood and performed correctly. To properly perform this test, use adequate fixation objects and a technique that will ensure maximum dissociation of the eyes.

A penlight should never be used as a fixation object. For distance fixation a 6/9 visual acuity symbol is recommended or, in the case of a prelitererate patient, electrically operated, moving mechanical toys or projected moving cartoons. For near fixation, a similar visual acuity symbol or some small picture or object can be used. Small cutout figures pasted on the end of a tongue depressor are convenient for testing children, who are asked to identify the object (Fig. 12-14).

To maintain the child's interest, paste pictures on the ends of both sides of the tongue depressor and change the object if the child's attention wanes. The examiner should place him- or herself at the desired distance, 33 cm, and then ask the child to hold the tongue depressor against the end of the examiner's nose. This serves two purposes: to keep the examiner's hands free and to help maintain the child's interest in fixating. Instead of using a tongue depressor, the examiner may clip a small card to the bridge of his or her glasses (Fig. 12-15).

The reason for using fixation objects rather than a simple penlight is to control accommodation during measurement of the deviation at near and distance fixation. One must understand that a patient's response depends on the stimulus presented, not only during subjective tests, where it is more obvious, but also during objective tests.

Another important consideration is the manner in which the test is performed. Maximal dissociation of the eyes must be achieved to make the correct diagnosis, especially in patients with heterophoria. Such patients have a strong compensatory innervation that keeps their eyes aligned and it is not immediately suspended when one eye is covered. *It is necessary to dissociate the eyes for some time to bring out the full amount of the deviation.* The test must not be performed hurriedly, and the cover should be placed alternately

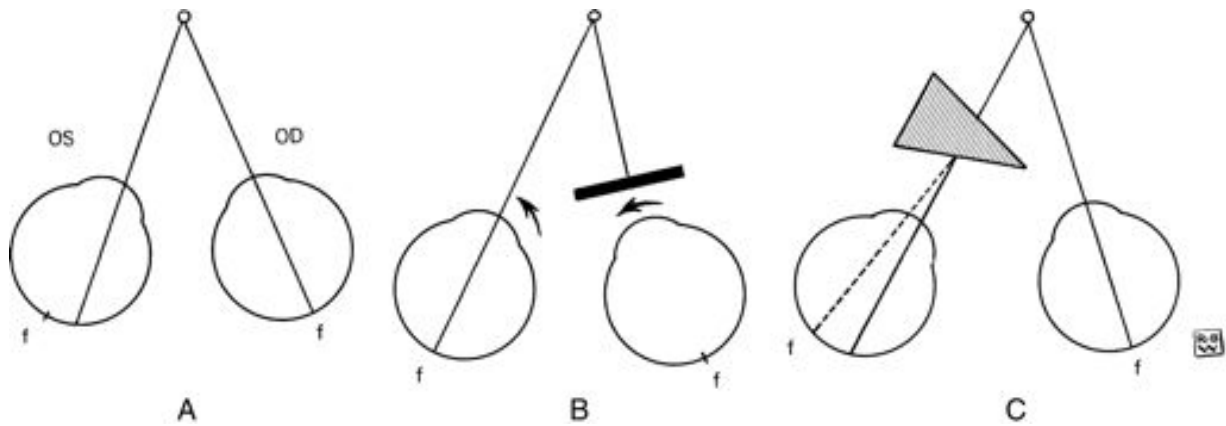


FIGURE 12-13. Optical principles of prism and cover test. *A*, Image of object fixated by OD is projected on the nasal half of the retina of OS. *B*, When OD is covered, OS moves outward to take over fixation. Under the cover, OD performs an inward movement of equal amplitude, following Hering's law of equal innervation. *C*, When a prism of sufficient power offsets the nasal displacement of the image, OS will no longer change its position when OD is covered (compare with Fig. 12-12, *F*). (From Noorden GK von: *Atlas of Strabismus*, ed 4. St Louis, Mosby-Year Book, 1983, p 51.)



FIGURE 12-14. Tongue depressors provided with photographically reduced Snellen letters and pictures for use as fixation objects.

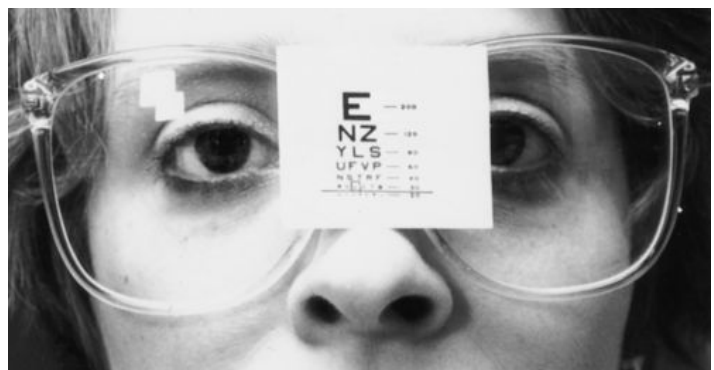

FIGURE 12-15. Photographically reduced Snellen letters mounted on the frame of the examiner's glasses.

over each eye a few times. Most important, the patient should never be permitted to regain fusion while the cover is being transferred. In patients with an exodeviation, one eye may have to be occluded for 30 to 45 minutes. The difference in measurements before and after occlusion may be significant (see Chapter 17).

In contrast to this brief occlusion is the *prolonged occlusion test* developed by Marlow⁸⁰ in an attempt to uncover the full amount of heterophoria, particularly a hyperphoria. Marlow occluded the nondominant eye for 14 days and no less than 7 days to accomplish thorough dissociation of the eyes and was convinced of the effectiveness of this procedure in uncovering clinically significant amounts of heterophoria. Prominent ophthalmologists⁹⁹ of Marlow's time supported his observations which have been reconfirmed in a recent study, using more critical methods of investigation.⁸⁷ However, the clinical significance of these findings remains questionable. Duane and Berens³⁷ stated that unilateral occlusion produces an artificial hyperphoria, an opinion shared by Lancaster.⁷³ It has yet to be shown that small degrees of horizontal and vertical heterophoria unveiled only by prolonged unilateral occlusion have any impact on the patient's ability to fuse without symptoms of asthenopia. Today, the test of Marlow has probably only historical interest and should not be confused, as it is frequently in the German strabismus literature, with the occlusion test introduced by Scobee and Burian for the diagnosis of a pseudodivergence excess type of exodeviation (see Chapter 17).

Another way to ensure full dissociation and obtain the full amount of the deviation is to add prism power not only until redress is stopped but also until a reversal of the direction of movement is noted. In so doing, one frequently finds that the endpoint is higher than originally thought. This technique is recommended for routine use.

To gain insight into a patient's deviation, perform the prism and cover test for distance and near fixation with the patient first wearing refractive correction and then with the correction removed. Comparison of these four figures allows one to draw conclusions about the part played by accommodation in the patient's deviation. The deviation measured in distance fixation while the patient is wearing full correction excludes accommodation. The fusion factor must be excluded as far as possible by a properly performed prism and cover test. With the influence of accommodation and

fusion controlled, one obtains the *static* or *basic deviation* or static (basic) angle of squint. If correction of the refractive error is inadequate, accommodation is uncontrolled and one then obtains the *dynamic deviation* or dynamic angle of squint. Likewise, in the case of insufficient dissociation of the eyes, persistent strong compensatory fusional innervation during the prism and cover test will cause dynamic factors to override and obscure the static deviation.

Precise definition of these terms is important to avoid misunderstanding. This has not always been the case in the European strabismologic literature in which different meanings have been given to classic terms in discussions of the nystagmus blockage syndrome.^{1, 31, 57, 86} For example, *dynamic angle* has been used synonymously with *variable angle* and it has been said that "the smallest observed angle is always the static angle." We, on the other hand, define a variable angle of strabismus as a deviation that increases or decreases significantly while the patient is being examined or, when measured on different occasions, while testing conditions remain equal and accommodation and fusion (dynamic factors) are fully controlled. A good example of a variable angle is that which occurs in a patient with an acute nystagmus blockage syndrome who has a variable angle of esotropia of a size that is inversely related to the nystagmus intensity (Chapter 23). It is also not true that the static angle is always smaller than the dynamic angle. For instance, fusional convergence may cause a larger static deviation to decrease at near fixation in patients with a simulated divergence excess type of exotropia (Chapter 22), or a patient with intermittent exotropia may use accommodative convergence to control the deviation at distance fixation (smaller dynamic angle). Controlling the accommodative state by asking this patient to read the 6/6 line on the visual acuity chart at 6 m distance will unmask the larger static deviation. Also, if the angle of a comitant horizontal strabismus is greater in primary position than in extreme lateral gaze, dynamic factors should not be blamed for this difference. We believe this phenomenon can be explained on simple mechanical grounds: the excursion of each eye in lateral positions of gaze is checked by orbital structures.³² Thus a fully adducted eye can no longer exhibit excessive adduction in esotropes, and excessive abduction in exotropic patients can no longer be effective once an eye is fully abducted. Consequently, depending on individual

variations of the effectiveness of these “brakes,” the angle of strabismus in lateral gaze may be smaller than in primary position. This rather lengthy explanation is necessary to define clearly the terms *dynamic*, *static*, and *variable angle* as used throughout this text.

Another useful modification of the prism cover test is to repeat it while the patient is fixating at 33 cm distance and looking through +3.00D lenses, clipped over the distance correction or, in the case of emmetropia, placed in the trial frame. With the accommodative demand for near fixation thus eliminated, the deviation at near should now approximately equal that at distance. Single clip-on lens holders are commercially available (Fig. 12-16).

It is recommended that the prism and cover test also be performed with either eye fixating. To do this, one eye is made to fixate while the other is alternately covered and uncovered and a prism is placed before the covered eye to stop movement of that eye. The process is then repeated with the other eye fixating. Differences in the amount of prism power required for each eye indicated the presence of a *primary and secondary deviation* (see Chapter 20) or an incomitance, for example, induced by an operation.

The prisms to be used in the test may be loose, in sets, or so-called prism bars or ladders, consisting of a row of prisms of increasing power. When using prism bars, two are necessary: one to measure the horizontal deviation and one to mea-

sure the vertical deviation. One also may use the horizontal bars with loose prisms held vertically.

To establish the basic deviation, the eyes must be tested in the clinical primary position for both distance and near fixation with and without additional plus lenses. Measuring the near deviation with the eyes in the reading position, as Scobee^{106, p. 300} suggested, is not desirable, because the possible presence of a V pattern of fixation may simulate an accommodative factor when none exists (see Chapter 19).

Limitations

The prism and cover test presupposes accurate fixation and cannot be performed if the deviating eye is blind or has grossly eccentric fixation. In eccentric fixation, the test provides wrong measurements, as the movement of redress of the deviated eye stops when the stimulus falls on the eccentric retinal area used for fixation and not when it reaches the fovea. Test accuracy is also limited by the optical qualities of the prisms.^{1, 89, 97} The stronger the prisms, the greater the errors; but from a practical standpoint, it is of little importance whether a deviation measures 75 Δ , 80 Δ , or 85 Δ . When large deviations are present, an error as high as 10 Δ is of no consequence for decisions on the treatment of the patient.

When using loose prisms one should remember that significant errors are produced when a low-power prism is added to a high-power prism. According to Thompson and Guyton¹¹⁸ the effect produced by adding a 5 Δ glass prism to a 40 Δ glass prism is not 45 Δ but 59 Δ . This error can be minimized by holding one prism before each eye. These authors also point out that the amount of deviation neutralized by an ophthalmic prism is variable depending on how the prism is held. For instance, a 40 Δ glass prism with a posterior face held in the frontal plane gives only 32 Δ of effect. Glass prisms are calibrated for use in the Prentice position; that is, the posterior face of the prism is perpendicular to the line of sight of the deviating eye. Plastic prisms, on the other hand, are calibrated for use in the frontal plane position, that is, parallel to the infraorbital rim.

When measuring large angle horizontal deviation with a prism bar one must be aware of the fact that even slight oblique shifts of the bar can induce a vertical displacement of the image, mimic a vertical deviation, and cause vertical diplopia.



FIGURE 12-16. Halberg clip-on lens holder.

Thompson¹¹⁷ (see also Scattergood and coworkers¹⁰³) also drew attention to the artifacts introduced by spectacles lenses in measurement of strabismic deviations. Plus lenses decrease and minus lenses increase the measured deviation. This effect becomes clinically significant with corrective lenses with powers of more than 5D (see also Adelstein and Cüppers¹).

Test accuracy is limited further by the minimum movement of redress that the examiner can detect with the naked eye. Some experienced ophthalmologists have claimed they can detect shifts as small as 1.0^Δ or even 0.5^Δ. Ludvigh⁷⁷ showed that with cooperative patients, experienced observers, and optimal conditions of illumination, 2^Δ would seem to be the limiting amount of observers, and optimal conditions of illumination, 2^Δ is the much less ideal conditions under which the test is generally performed, it is probably safer to set the limit at 3^Δ to 4^Δ. Much the same results were obtained by Romano and von Noorden.⁹⁸ In some instances, on assuming fixation, either eye overshoots the mark and returns to fixate the object of attention with a secondary corrective eye movement. For example, in esotropia the eye makes a larger outward movement than one corresponding to the angle of squint and then must turn inward to assume fixation. In these cases the endpoint of the test is not exact, but an approximate measurement can usually be obtained. According to Mehdorn and Kommerell,⁸¹ this "rebound saccade" may be caused by failure of suppression to be released instantly on covering the fixating eye. Certainly one can reasonably assume that such a mechanism would decrease precision of a preprogrammed corrective eye movement.

It is evident also that if nystagmus is present, an accurate determination of the deviation by the prism and cover test may be difficult if not impossible. The nystagmus need not be manifest but may occur only when one eye is covered. This is the so-called latent nystagmus, a rather rapid, jerky form with its quick phase toward the uncovered eye. More about this interesting form of nystagmus is found in Chapter 23.

Prism and Cover Test in Diagnostic Positions of Gaze

The prism and cover test is useful in determining incomitance in otherwise comitant deviations, confirming by measurement the degree of a pare-

sis, and establishing what muscle or muscles are involved in a paralytic condition. To this end, the deviation should be measured in the *nine diagnostic positions of gaze*. The first is the primary position; next come the secondary positions of right, left, up, and down; and last the tertiary positions of up and right, up and left, down and right, and down and left.

In the past, the eight secondary and tertiary positions have been called *cardinal positions* and are so designated, even in some recent textbooks. In discussing the physiology of ocular motility, only the secondary positions, reached by the cardinal movements, are so termed. To prevent confusion it is better to use the term *diagnostic positions*, since tertiary positions are included. The term has the added advantage of reminding the ophthalmologist that these positions are primarily for establishing certain points in the diagnosis. The practical field of fixation in the unrestricted casual use of the eyes is rather narrow (p. 79). Results of tests made 25° or 30° from the primary position in any direction may not be meaningful for the patient's use of the eyes, but they are meaningful in making diagnostic points. Deviations present only in extreme positions may not require surgical treatment. To determine whether a deviation is paretic or paralytic, the relative position of the eyes in diagnostic positions should be measured with either eye fixating, as has been described for the primary position.

Various techniques have been proposed to diagnose paretic involvement of a vertical muscle,^{58, 60, 96, 124} all of which include the head tilt test as a final step. The head tilt test, the obliquity of horizontal or vertical double images (see Chapter 15), and similar tests actually are confirmatory rather than primary tests. They are not essential to the diagnosis, although they can be helpful in complex cases such as congenital paralyzes with greater or lesser spread of comitance, marked overaction of an antagonistic muscle, and preexisting horizontal or vertical heterophoria or heterotropia. For relatively recent and simple pareses or paralyzes of vertically acting muscles, however, answers to the following three questions will definitely establish the diagnosis: (1) Is there a right or left hyperdeviation in primary position? (2) Does the hyperdeviation increase in elevation or depression? (3) Does the hyperdeviation increase in dextroversion or levoversion? These questions are answered by examining the versions and by comparing the position of the eyes in the various directions of gaze

or, better yet, by measuring them with the prism and cover test. The answer to the first question is obtained from the cover test; the answer to the second informs one whether a right or left elevator or depressor muscle is at fault; and the answer to the third determines whether the vertical rectus or the oblique muscle is involved. Thus the diagnosis is established. Further details about examination of patients with cyclovertical deviations may be found later in this chapter and in Chapters 18 and 20.

In practical performance of the prism and cover test in diagnostic positions of gaze, varying procedures are followed. Accommodative targets should be used as fixation objects to minimize variability of the deviation resulting from variations in accommodation. Such a target may be handed to the patient to hold and the hand placed successively in the desired positions, leaving the examiner's hands free to perform the test (Fig. 12-17). For the experienced ophthalmologist this method may be fully satisfactory, but it does not permit accurate repetition of the test. So-called deviometers therefore have been designed that permit all patients being tested to bring the eyes as closely as possible into the same positions. A perimeter arc on which an accommodative target could be placed for measurement of the deviation in fixation above and below the horizontal plane was described by von Noorden and Olson.⁸⁸ Such a perimeter arc can be placed in the horizontal and tertiary positions and makes a good deviometer.

In the Motility Clinic of the Department of Ophthalmology at Baylor College of Medicine, Houston, Texas, a deviometer built from scrap

metal is used in which retroilluminated slides stimulate accommodation. Each slide is positioned 35° from the primary position¹¹⁹ (Fig. 12-18).

One great advantage of using a deviometer is that the prism and cover test can be performed in diagnostic positions under exactly the same conditions on different occasions and thus permit meaningful comparison of test results (e.g., preoperative and postoperative).

Measurement with the Major Amblyoscope

The angle of deviation can be measured also by using a major amblyoscope. These devices, patterned after the Hering haploscope (see p. 72), are basic orthoptic instruments. They are especially useful for studying the sensory state of the patient and in nonsurgical treatment.

The essential parts of major amblyoscopes (Fig. 12-19) are a chinrest, a foreheadrest, and two tubes carrying targets seen through an angled eyepiece, one for each eye. The tubes are placed horizontally and supported by a column around which they are movable in the horizontal plane. A mirror, one in each tube, reflects the image of the target through the eyepiece into the corresponding eye. The distance between the tubes can be adjusted so that the centers of the eyepieces correspond accurately to the patient's interpupillary distance. When this is done and if the head and chin are properly adjusted, the axes around which the tubes turn should be in line with the center of rotation of the eyes. In addition to adjustments for horizontal positions of the arms, there are controls

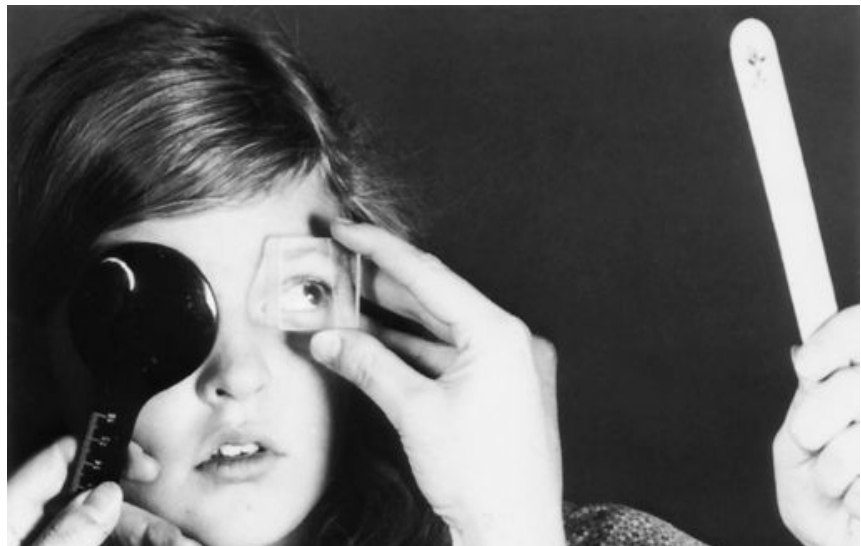

FIGURE 12-17. Example of prism and cover measurement outside primary position. Patient is looking up and to the left.




FIGURE 12-18. The Boyse-Smith deviometer. (From Toosi SH, Noorden GK von: Effect of isolated inferior oblique muscle myotomy in the management of superior oblique muscle palsy. *Am J Ophthalmol* 88:602, 1979.)

that allow a vertical separation of the targets, as well as cyclorotational adjustment. The amount of all these displacements can be read from scales, which are usually graduated both in arc degrees and prism diopters. The tubes may be locked and moved together horizontally and in some modern models also vertically. The illumination system for each target can be controlled individually to increase or decrease the stimulus luminance to

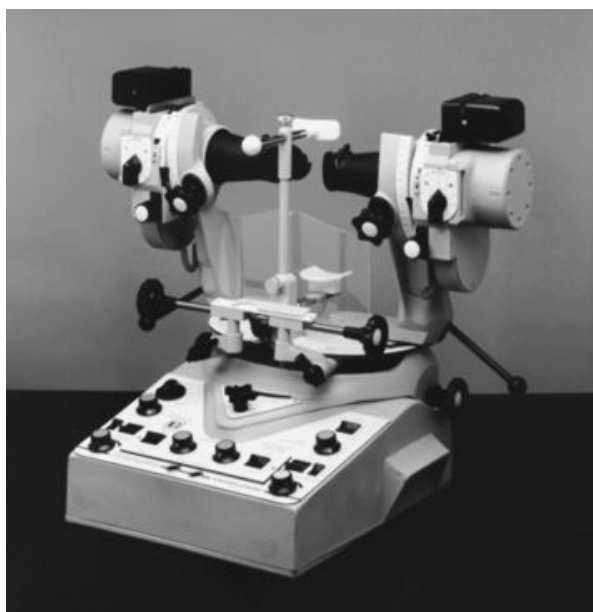

FIGURE 12-19. A major amblyoscope. (Courtesy of Clement & Clark.)

one eye. Keys are provided to manually flash the light, illuminating either target. The flashing also can be controlled automatically in certain models, with a wide range of light-dark intervals. This basic instrument may be equipped with a greater or lesser number of refinements. Some models are designed to produce afterimages or Haidinger's brushes.

The main difference between laboratory haploscopes and major amblyoscopes is the way in which accommodation is controlled. The target carrier in the haploscope can be moved along the arm, which is graduated in diopters. The position of the targets in the major amblyoscope is fixed in the focal plane of a +6.0D or +6.5D lens so that they are at optical infinity, which should prevent accommodation from affecting the deviation. However, the fact that targets are actually a short distance from the eyes causes proximal convergence to enter into play. Consequently, the deviations measured with the major amblyoscope in distance setting are frequently larger than those obtained with the prism and cover test in distance fixation.^{8, 46, 117} One major British amblyoscope (the Curpax Major Synoptiscope No. 10) uses semitransparent mirrors in lieu of opaque mirrors in front of the eyes, a feature already used in the haploscope of Ames and Gliddon,² which allows the patient to view a distant object on which the target images in the slide holders on each arm are

superimposed while deviation is being measured. In this way the influence of proximal convergence is avoided.^{78, p. 105}

To induce accommodation, auxiliary minus lenses are placed in front of the eyepieces. For measurements at near fixation (e.g., of the vergences), minus lenses are used in the amount required to offset the plus lenses in the eyepieces and the arms are set at 18D (for the convergence requirement of a 6.0 cm interpupillary distance), which thus becomes the zero setting for a 33 cm viewing distance.

The deviation is measured by moving the arms of the major amblyoscope into such a position that images of the target fall on the respective foveal areas. This is done by moving the arms until there is no further refixation movement of the eyes in an alternate cover test (either by actual covering or by alternately extinguishing the light on one side of the instrument). Vertical displacements of the target carriers measure vertical components of the deviation. Finally, it is also possible to rotate the targets around an anteroposterior axis and thus evaluate and measure cyclodeviations.

Conventional amblyoscopes do not permit determination of the angle of strabismus in peripheral positions of gaze whereby the eyes are dissociated by the patient's nose or orbital margins. Yet such measurements are important, especially in those patients with parietic or paralytic strabismus. These difficulties have been overcome by the *Synoptometer* (Oculus) of Cüppers, which is a modified amblyoscope that permits measurement of deviations by means of mirrors in peripheral positions of gaze of up to 50° in dextroversion and levoversion, 50° in elevation, and 60° in depression.^{31, 85}

To avoid the distraction of infants and children that is caused by instrumentation or by prisms and occluders switched directly before the eyes, Guyton developed an ingeniously designed *remote haploscope* to be used in combination with an infrared television-based eye tracker.^{54, 56} The efficiency of measurement of an ocular deviation with this apparatus in terms of speed and repeatability is superior to conventional methods. Campos and colleagues²⁵ developed a similar system in association with a computerized deviometer which allows one to follow automatically step-by-step the various diagnostic procedures in comitant and paralytic strabismus. There are many potential research applications for such systems, but it is questionable whether this technological extrava-

gance will eventually replace the older tests in a clinical environment.

Corneal Reflection Tests

If the deviated eye is blind or has low visual acuity or, in young children, is unable to maintain fixation for longer than a moment, the amount of the deviation cannot be determined by the prism and cover test or by any subjective tests. One must then resort to estimation of the deviation by observing the first Purkinje image using the so-called corneal reflection test. The corneal reflection is on the nasal side of the deviated eye in exotropia, on the temporal side in esotropia, below the corneal center in hypertropia, and above it in hypotropia.

Hirschberg⁶³ first suggested the use of corneal reflection for measuring ocular deviations, and his test is still widely used. Based on a simple calculation, Hirschberg found that each 1 mm of decentration of the corneal reflection corresponded to 7° of deviation of the visual axis (Fig. 12–20). His assistant, du Bois-Reymond,³⁸ determined with a modified arc perimeter that if the corneal reflection in the deviated eye is found to be in the pupil, the deviation ranges from 0° to 20°, given a pupillary diameter of 3.5 mm. If it is on the iris between the pupillary margin and the limbus, an angle of 20° to 45° may be present. If the reflection appears on the conjunctiva, a deviation of 45° or more exists.³⁸

Brodie¹⁶ reexamined the conversion factor

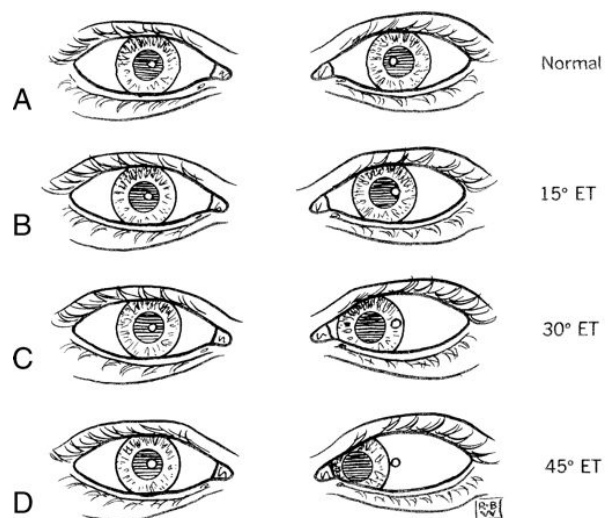


FIGURE 12–20. The Hirschberg test. For explanation, see text. ET, esotropia. (From Noorden GK von: *Atlas of Strabismus*, ed 4. St Louis, Mosby-Year Book, 1983, p 45.)

given by Hirschberg over 100 years ago and photographed the corneal reflection of normal subjects who were fixating visual targets separated by 10^Δ over a range of 200^Δ . A value of 12° per millimeter displacement of the reflection was determined in Brodie's study, which is similar to numbers reported by subsequent investigators.^{34, 44, 93, 102} The discrepancy between the traditional ($7^\circ/\text{mm}$) and this new factor may be caused by the fact that a photograph records the true reflex displacement in the frontal plane, which differs from a measurement of the reflex displacement from the corneal apex along the corneal surface.¹⁶ The rather wide range of measurements reported by different authors (10.7° to 15.6°) could be explained by the fact that the reference landmarks (corneal center, pupillary center, limbus) and the calibration method were not the same in all studies.

Paliaga and coworkers⁹²⁻⁹⁴ have revived the method of *objective strabismometry*, which was quite popular about a century ago. With a millimeter ruler, they measured displacement of the corneal light reflection that occurs in the deviated eye as this eye assumes fixation. The linear displacement of the reflection is then converted into angular values (see also p. 200).

Another method is based on the well-established principle of Hering's law of equal innervation to the two eyes. Corneal reflection is produced in the two eyes by an appropriately placed penlight, which is fixated by the patient's better eye. The examiner places him- or herself on the side of the deviated eye to avoid parallax errors in observation (Fig. 12-21).

Prisms are then placed *in front of the fixating eye* to center the corneal reflection in the deviated eye. The amount of prism power necessary to achieve this is a measure of the deviation. This test, first described by Krimsky,⁶⁹ who suggested the name "prism reflex test," is a practical method of estimating the size of the angle of squint in patients with a blind or deeply amblyopic eye with or without eccentric fixation. It is important for the examiner to be seated directly in front of the deviating eye to avoid false readings caused by parallax. In another version of this test, prisms are placed *in front of the deviating eye* until the corneal reflection is centered. However, observation of the corneal reflection through prisms is difficult, which is why we prefer the procedure outlined.

Strabismometric methods based on the corneal light reflection remain rather crude and are not as precise as the prism and cover test because the

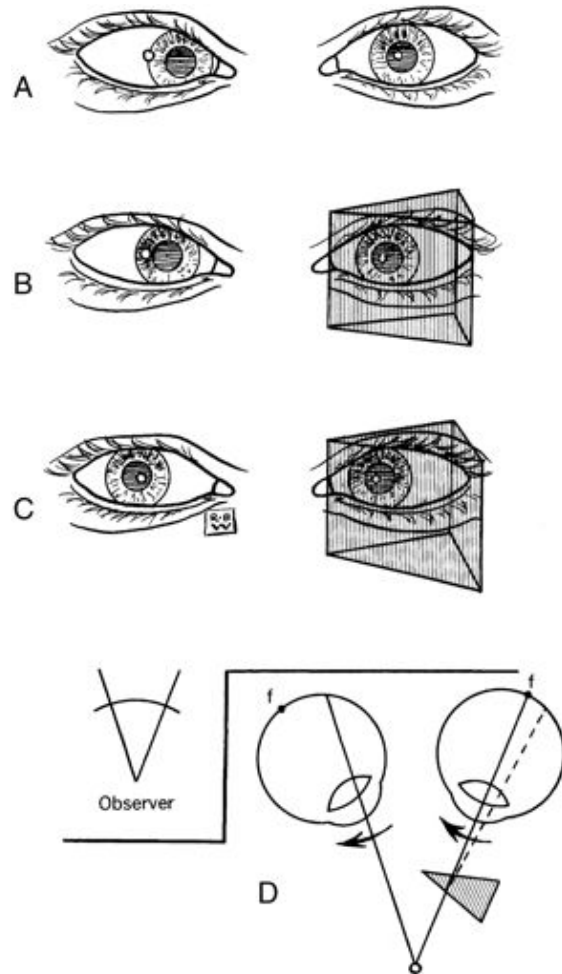


FIGURE 12-21. The Krimsky test. A-C, Prisms, base-out, of increasing power are placed before the fixating eye until the light reflex is centered on the cornea of the deviating eye. D, Optical principles of the prism reflex test. (From Noorden GK von: Atlas of Strabismus, ed 4. St Louis, Mosby-Year Book, 1983, p 47.)

deviation at distance fixation is difficult to measure with this method, accommodation cannot be controlled while maintaining fixation on a penlight, the angle kappa is included in the measurement, and, as shown by Choi and Kushner,²⁹ interpretation of the position of the light reflection on the cornea differs widely even among experienced observers. Be this as it may, the Hirschberg and Krimsky tests are valuable methods to obtain an *approximate* measurement of the angle of strabismus in patients too young to cooperate with the prism and cover test or when poor visual acuity in one or both eyes precludes adequate fixation.

Photographic Methods

Barry and coworkers⁹ developed a method to measure the angle of strabismus in infants and children

photographically (see also Lang⁷⁵). The apparatus consists of a camera with three horizontally aligned flashes and a small fixation light. The angle of strabismus is derived from the reflection pattern in the pupil of the first and fourth Purkinje images from each light source. The accuracy is said to be between 2.0^Δ and 4.5^Δ, which would make it superior to the Hirschberg test. Friedman and Preston⁴⁷ use a two-flash Polaroid camera to screen for amblyopiogenic factors, such as strabismus, media opacities, and refractive errors. Photographic methods for visual screening of children lack accuracy because accommodation is not controlled by an appropriate fixation target. Evaluations of the efficacy of this method to detect amblyopiogenic factors have thus far yielded controversial results. One study concluded that the photoscreener holds promise as a useful mass screening tool,⁹¹ but others have shown that the photographs may be noninterpretable or that amblyopiogenic factors were missed in 20% of children evaluated with this method.^{105, 110} Photoscreening is probably more accurate than screening for these factors by the pediatrician,^{120, 125} but cannot and should not take the place of a complete ophthalmologic examination.

Brückner Test

Brückner¹⁸ introduced a test to diagnose strabismus in infants that is based on judgment of the position of the corneal light reflex and the color of the light reflected from the fundus. A bright coaxial light source emitted by a direct ophthalmoscope illuminates both eyes of the patient simultaneously from a distance of 1 m in a semi-darkened room. The position of the corneal reflection and differences in the brightness of the fundus reflex between the two eyes are noted by the observer through the ophthalmoscope. In the presence of strabismus the reflex of the fixating eye is darker than in the deviated eye, a phenomenon that had been previously noted by Worth.¹²⁷ It has been estimated that this technique can be automated to detect the presence of 2° to 3° of ocular misalignment based on the difference in brightness of the bright pupil images between the two eyes.⁸⁴ In a second step one eye is illuminated at a time, and the pupil size, its reaction to light, and fixation movements are noted to detect amblyopia. Whether this test is a reliable screening method for strabismus is another matter since it has been reported that asymmetrical fundus re-

flexes occurring in infants up to 10 months of age may represent a normal stage of development⁴ and that the tests yield false positives in nonstrabismic subjects.⁵²

Subjective Tests

Subjective tests for estimating the deviation of the visual axes have a long and honorable history. All the great names, and many of the near-great ones, in Germany, England, and the United States have made their contribution to this chapter of the investigation of neuromuscular anomalies of the eyes. The story has been fascinatingly retold by Sloane,¹¹¹ but in this book the discussion must be restricted to tests in current use.

If the two visual axes are not properly aligned, the patient should have diplopia. The diplopia is either spontaneous, as in recent extraocular muscle paralyzes or acute comitant strabismus, or it must be elicited artificially if suppression or anomalous correspondence (see Chapter 13) is operative in casual seeing, as is the rule in comitant squint. If correspondence is normal, the distance of the double images may be used as a measure of deviation.

All subjective tests for measurement of the deviation are based either on the *diplopia principle* or the *haploscopic principle*.

Diplopia Tests (Red-Glass Test and Others)

In the diplopia type of test (Fig. 12–22), one determines the subjective localization of a single object point imaged on the fovea of the fixating eye and an extrafoveal retinal area in the other eye. In esotropia, where the image of the fixation point in the deviated eye falls on a retinal area nasal to the fovea, there should be *uncrossed diplopia*. In exotropia, where the image of the fixation point in the deviated eye falls on a retinal area temporal to the fovea, there should be *crossed diplopia*. If retinal correspondence is normal, double images not only should be properly oriented but also should have a distance equal to the angle of squint. The distance of the double images is then a measure of the deviation; but even with spontaneous diplopia it is difficult if not impossible for the patient to state whether the images are crossed or uncrossed. The two visual fields must be differentiated and for this purpose a red glass is placed in front of one eye (hence, *red-glass test*; see Fig. 12–22). The patient fixates a small light source and states whether the red light is to

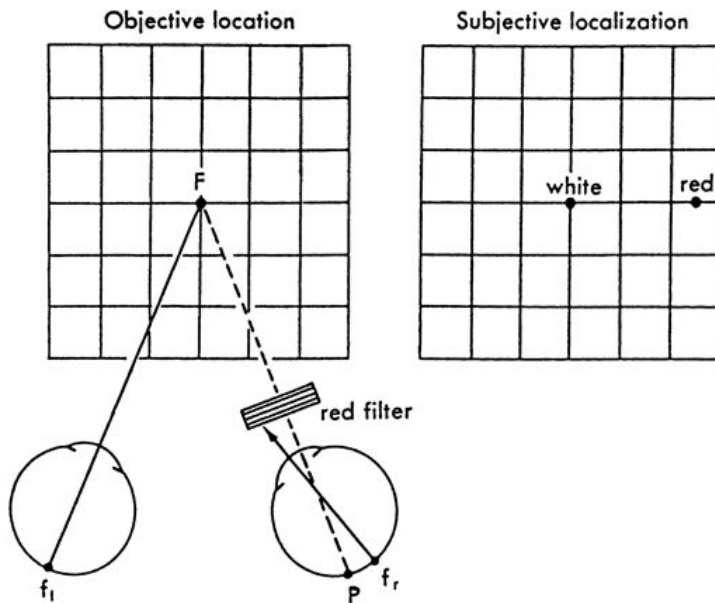


FIGURE 12-22. Principle of diplopia tests. (From Burian HM: Normal and anomalous correspondence. In Allen JH, ed: Strabismus Ophthalmic Symposium, II. St Louis, Mosby-Year Book, 1958, p 184.)

the right or to the left and above or below the white light. If the white fixation light is in the center of a *Maddox cross* (Fig. 12-23), the patient must state the numbers near which the red light is seen. If the patient is seated at the correct distance, these numbers indicate the amount of deviation.

The red glass not only must differentiate the two fields but also must dissociate them, which is especially important in patients with heterophoria, intermittent heterotropia, and particularly with intermittent exotropia. In these patients, one wants to ascertain the full amount of the deviation. For proper dissociation of the fields, the red glass must be dark enough to make it impossible for the patient to see anything but the red fixation light to prevent fusional impulses from the surroundings of the fixation light.

The test is facilitated if it is begun by alternately covering the eyes of the patient to show that a white light is seen with one eye and only a somewhat dim red light with the other eye. When both eyes are uncovered, the patient is more likely to become aware of the double image of the light. Nevertheless, eliciting diplopia in patients with comitant heterotropia is often difficult, but with patience and skill it can invariably be achieved. One must occasionally have recourse to the simple trick of placing in front of the eye a 10^{Δ} or 15^{Δ} prism base-up or base-down together with the red filter. As a rule, this throws the image outside the suppression scotoma and the patient immediately recognizes diplopia. Vertical displacement of the retinal image introduced by the prism must be taken into account when this maneuver is used.

In general, in doing the red-glass test, the filter should be placed before the fixating eye, which is less likely to suppress the darkened image of the fixation light, but one should always attempt to repeat the test by placing the red filter in front of the other eye. For various reasons, responses are not always identical. In patients with a paralytic condition, a primary and secondary deviation may be present (see Chapter 20). Retinal correspondence may change with a change in fixation (see Chapter 13). Frequently a dissociated vertical deviation may occur. If the deviation is large, it is sometimes necessary to reduce it with prisms; but it is not advisable to fully correct the angle, since this may lead to the phenomenon of horror fusionis (see p. 136). However, in some instances the ophthalmologist may want to investigate the response of the two foveas to simultaneous stimulation (e.g., before suggesting an operation). For this purpose the deviation must be fully neutralized with prisms.

The red-glass test used in conjunction with a *Maddox cross* can be performed successfully in cooperative children as young as 4 years of age. Such children should not be asked to tell where they saw the light, but they should be asked to go to the scale and put their finger on the place where they saw it. It is then wise to place a vertical prism first base-up and then repeat the test base-down. This makes it easier for the child to locate the position of the double image and serves as a check on the reliability of the report. Alternate use of vertical prisms is recommended in all cases in which the patient's answer is doubtful.

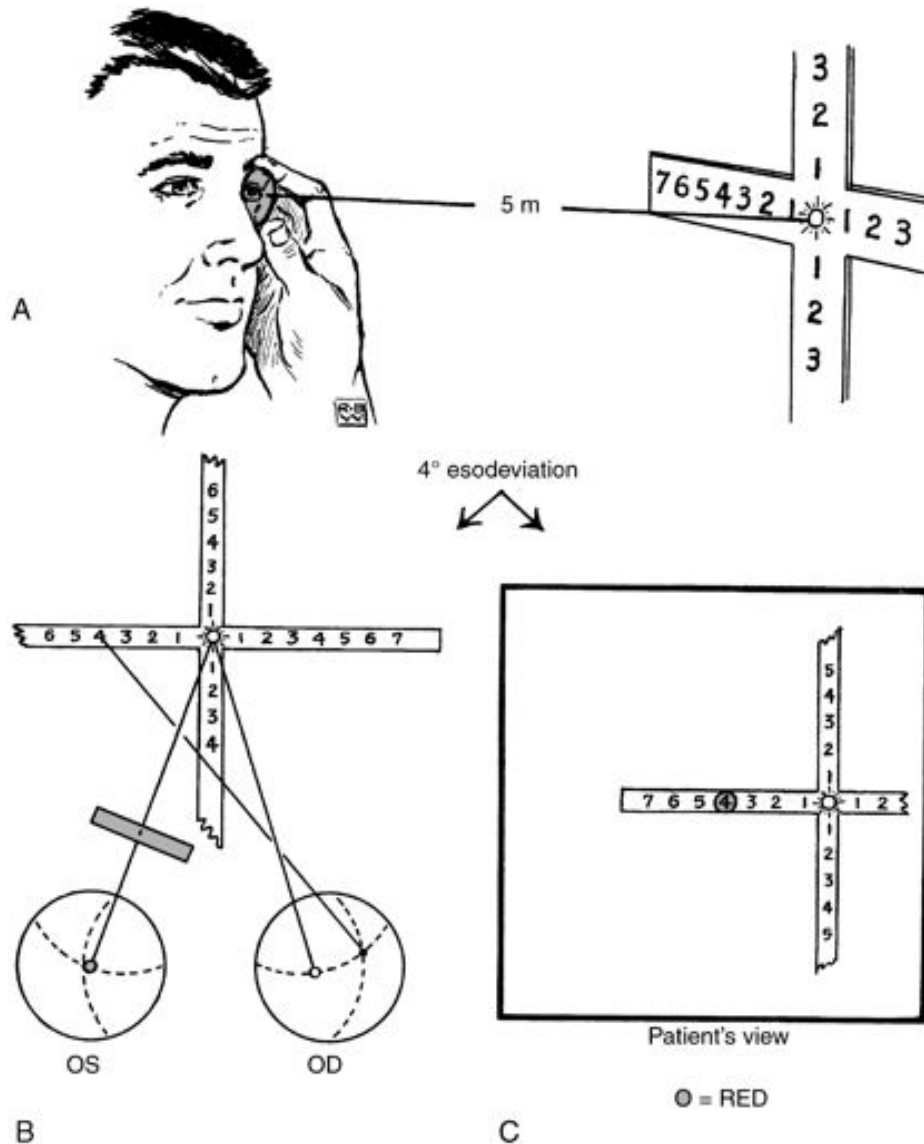


FIGURE 12-23. The Maddox cross. *A*, The test is performed at 5 m but can also be performed at 1 m, in which case the small numbers on the Maddox cross (not shown in this figure) indicate the angle of separation of the two images. This patient has a right esotropia of 4^{Δ} . *B*, If both foveas have a common visual direction (normal retinal correspondence) the red light will appear in the same visual direction as the number whose image is formed on the fovea of the deviating eye. In this case the light appears on the number 4. *C*, Homonymous diplopia in an esotropic (or esophoric) patient with a deviation of 4^{Δ} . (From Noorden GK von: *Atlas of Strabismus*, ed 4. St Louis, Mosby-Year Book, 1983, p 61.)

To determine the presence and amount of incomitant deviations with the red-glass test, one may chart the so-called *diplopia fields*. This test is best done by turning the patient's head so as to bring the eyes into the various secondary and tertiary diagnostic positions, ascertaining in each position the distances of the double images and marking them on an appropriate chart. For gross orientation in near fixation a quick and helpful procedure is to keep the patient's head straight and to move a penlight up, down, right, left, and so on and to ask the patient whether the distance

of the double images is greater in gaze up, down, right, or left. The test can be made quantitative by using a device suggested by Sloane,¹¹¹ which consists of a small, hand-held, transparent screen provided with a tangent scale designed for a viewing distance of 0.5 m and having a small fixation light in its center. The patient uses a pointer to indicate the position of the double image. To test in secondary and tertiary positions, it is necessary that the patient's head be turned. Figure 12-24 shows a diplopia field in a patient with a recent paresis of the left superior rectus muscle. Vertical

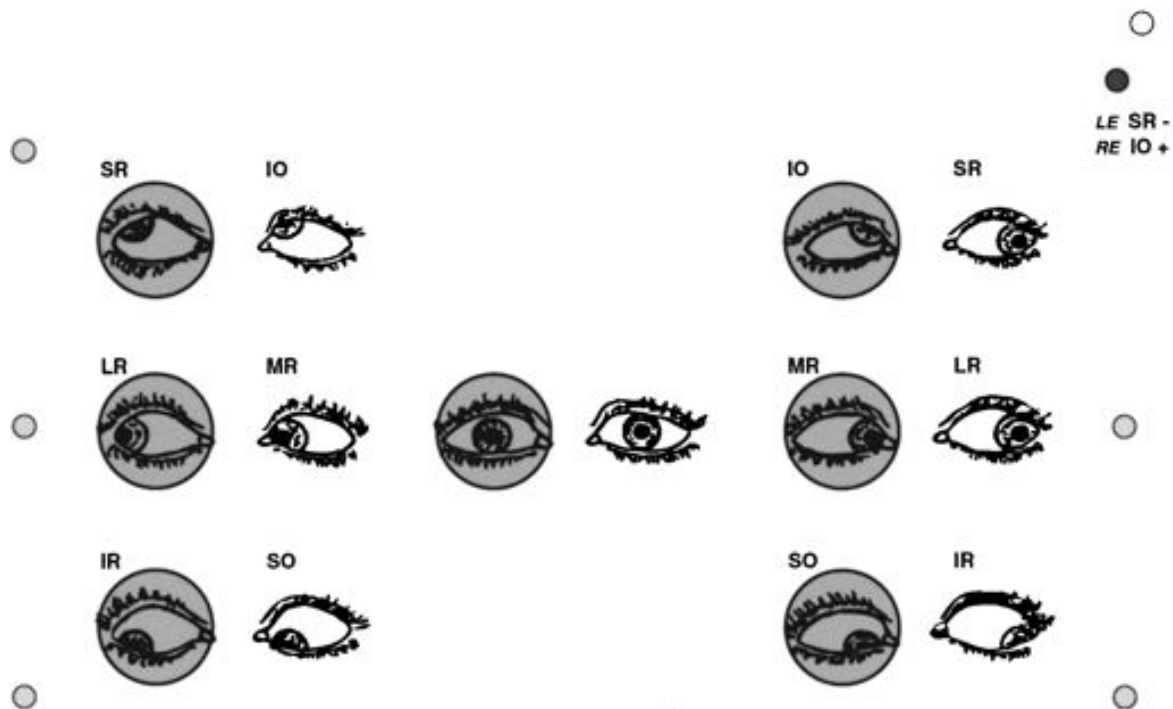


FIGURE 12-24. Diplopia field in a patient with a recent onset of a left superior rectus paresis. Vertical diplopia is present only in left upper gaze because of underaction of the paretic muscle and secondary overaction of the right inferior oblique.

diplopia is present only when the patient looks up and to the left where underaction of the left superior and secondary overaction of the right inferior oblique muscle are present.

A special tangent scale devised by Harms,⁵⁹ further developed by Mackensen,⁷⁹ and widely used mainly in Germany has a fixation light in its center, covered by a metal box. When this box is removed, in lieu of the round fixation light, a horizontal streak of light may be used to determine the obliquity of double images by placing a red glass in front of the observer's eye. The amount of obliquity may be read from a scale. When the tangent scale is used with a fixation light, the patient also wears a red glass in front of one eye and indicates the position of the red light by means of a green ring projected by a small projection device handled by the patient. In addition to the usual markings, an oblique cross at 45° on the tangent scale makes it possible to test the vertical deviations with the patient's head tilted to the right and left shoulders. Proper position of the patient's head is monitored with a special projector attached to the forehead.

A handy, routinely used method of measuring the amount of heterophoria is to replace the red glass with a white or preferably red *Maddox rod*.

This device, consisting of small glass rods, causes an astigmatic elongation of the fixation light and may be placed to produce a vertical or horizontal streak to measure the horizontal and vertical deviation. If the streak does not go through the fixation light, prisms of increasing strength are placed in front of the eye until it does. The amount of prism power required to achieve this goal is a measure of the heterophoria (Figs. 12-25 and 12-26). The amount of the heterophoria in near fixation also may be measured with the *Maddox wing test*,^{78, p. 200} the *heterophorometer*,^{13, p. 41} or similar devices, all based on the diplopia principle. As has been pointed out, all tests require that the retinal correspondence be normal. Their application to the study of retinal correspondence is discussed in Chapter 13.

Haploscopic Tests

Haploscopic tests differ from diplopia tests in their mode of stimulation. Two test objects rather than one are presented to the patient, who is required to place them in such a fashion that they appear superimposed (Fig. 12-27). Again assuming that correspondence is normal, the two objects are placed to stimulate the foveae of the two eyes.

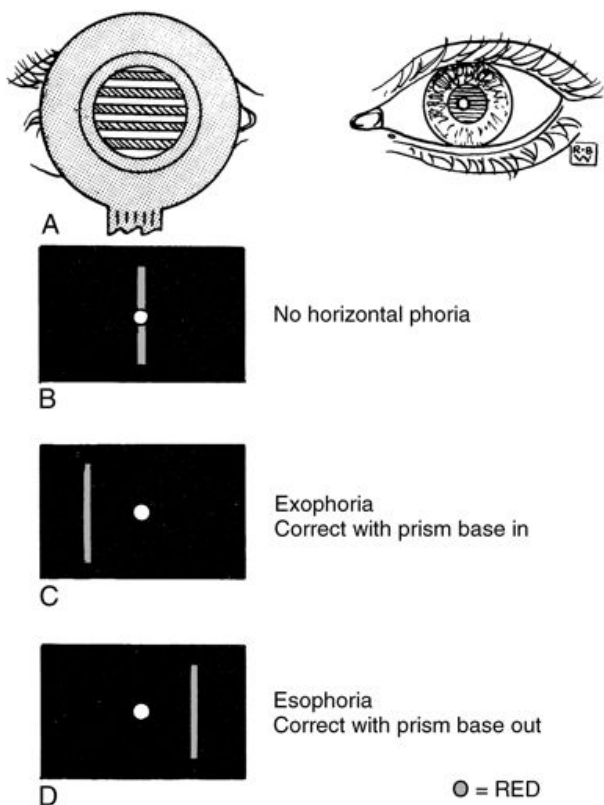


FIGURE 12-25. A, Maddox rod in testing position for horizontal heterophoria. B, Patient sees the line going through the light: no horizontal phoria is present. C, The line is seen to the left of the light (crossed diplopia): exophoria. Add prisms, base-in, to OD until the line is centered on the light. The power of the prism is read and equals the amount of phoria. D, The line is seen to the right of the light (uncrossed diplopia): esophoria. Add prisms, base-out, to OD until the line is centered. (From Noorden GK von: Atlas of Strabismus, ed 4. St Louis, Mosby-Year Book, 1983, p 53.)

The visual fields of the two eyes are differentiated and dissociated in various ways. Each eye may be presented with a different target, as is done when using a major amblyoscope. Also, complementary colors may be placed in the visual field of the patient, either directly or by projection, and each eye may be provided with a corresponding colored filter. Instead of color differentiation, a Polaroid projection system or some other system, such as the phase difference projection haploscope of Aulhorn⁵ (see p. 74), may be used.

Color differentiation is convenient in clinical practice. It is applied, for instance, in the Lancaster^{71, p. 78} red-green test (Fig. 12-28), which uses a window shade type of screen that can be rolled up when not in use. The screen is ruled into squares of 7 cm so that at a distance of 2 m each square subtends approximately 2°. The squares are

all of the same size and the tangential error is not taken into account. Lancaster claimed that at 2 m distance this error did not produce a significant inaccuracy. The patient is equipped with red-green reversible goggles. Two projectors are used: a green projector, handled by the patient, and a red projector, handled by the examiner. The image formed by the projector is linear. The red filter may be placed in front of either eye to investigate differences caused by changes in fixation. Instead of inverting the glasses, the examiner can exchange projectors with the patient. The examiner projects the line from his or her projector onto the screen at any desired place, the patient's head is held steady, and the patient is asked to place the streak from his or her projector so that it appears to the patient to coincide exactly with the other streak. If one assumes that correspondence is normal, the two streaks will be separated objectively on the screen by an amount corresponding to the deviation of the visual axes. The positions of the streak shown by the patient are entered into a small chart on which the screen is reproduced.

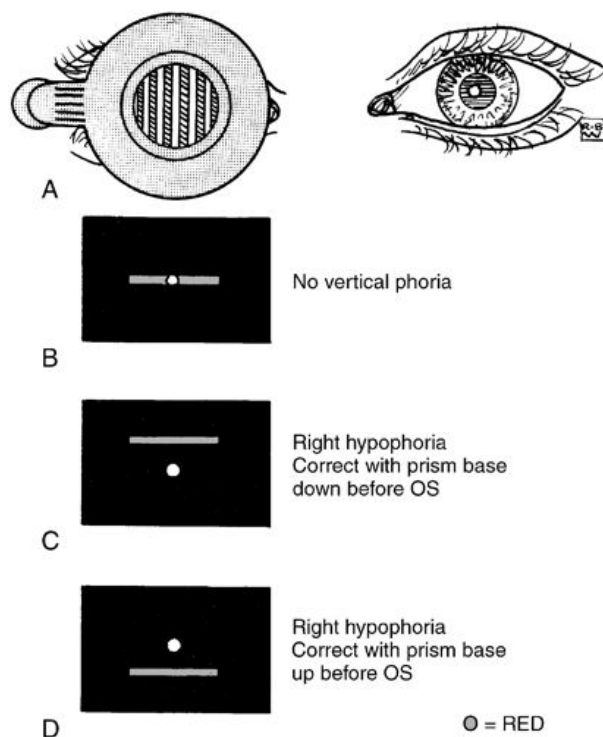


FIGURE 12-26. A, Maddox rod in testing position for vertical phoria. B, No vertical phoria is present. C, Right hypophoria (usually left hyperphoria also). Add prisms, base-down, to OS until the line is centered. D, Right hyperphoria. Add prisms, base-up, to OS until the line is centered. (From Noorden GK von: Atlas of Strabismus, ed 4. St Louis, Mosby-Year Book, 1983, p 53.)

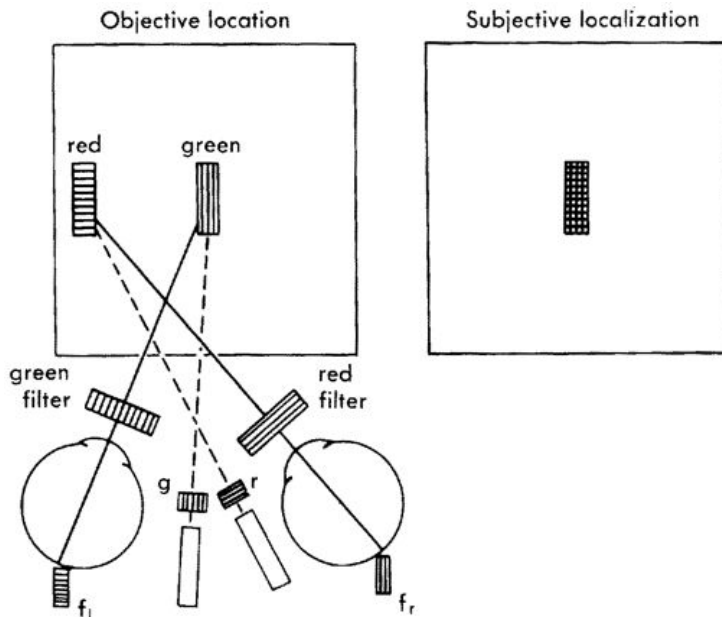


FIGURE 12-27. Principle of haploscopic tests. (From Burian HM: Normal and anomalous correspondence. In Allen JH, ed: Strabismus Ophthalmic Symposium, II. St Louis, Mosby-Year Book, 1958, p 184.)

Since the projected image is a line, the patient's response may indicate the presence of cyclotropia when the streak is tilted. The Lancaster red-green test is most useful in patients with ocular paralysis. It is least useful in patients with heterophorias or intermittent heterotropias since suppression is not perfect. Reducing the ambient illumination lessens the unwanted effect of fusional stimuli.

The same holds true when the eyes are dissociated with Polaroid material.¹⁹ When such tests are used, the position of the patient's head must be fixed and maintained in a headrest. Even slight tipping of the head will reduce the angle between the analyzer in front of the patient's eyes and the polarizer in front of the projectors and reduce the extinction.

*The Hess screen test*⁶² (Fig. 12-29) is based on the haploscopic principle. It was popularized by Lyle, in particular for diagnosing possible paretic or paralytic conditions in patients with normal correspondence. To perform this test, a black cloth 3 ft wide by 3½ ft long, marked out by a series of red lines subtending between them an angle of 5°, is used. At the zero point of this coordinate system and at each of the points of intersection of the 15° and 30° lines with one another and with corresponding vertical and horizontal lines, there is a red dot. These dots form an inner square of 8 dots and an outer square of 16 dots. An indicator is provided consisting of three short green cords knotted to form the letter *Y*. The end of the vertical green cord is fastened to a movable black rod 50 cm long. The ends of the other two cords are kept

taut by black threads that pass through loops to small weights at corresponding upper corners of the screen. This arrangement enables the patient to move the indicator freely and smoothly over the whole surface of the screen in all directions. The patient wears red-green goggles and is seated 50 cm from the screen, preferably with his or her head fixed in a headrest. The patient now sees the red dots with one eye and the green cords with the other and is instructed to place the knot joining the three green cords over each of the red dots in turn. The examiner marks the positions indicated by the patient on the small card with a reduced copy of the screen. The points found by the patient are connected by straight lines and permit the examiner to determine which, if any, muscles react abnormally. To change fixation, the red-green goggles are reversed with the red filter now in front of the left eye.

Measurements of the angle of strabismus that are based on image separation with red and green glasses or other haploscopic methods have become justifiably popular in many countries, especially in Europe. Provided the patient is cooperative, these tests are precise and repeatable on different occasions. However, they are less popular in the United States, partially because they are somewhat time-consuming and require a prolonged attention span and reliable patient responses, which excludes a large segment of pediatric patients with strabismus problems.

Subjective determinations of the angle of deviations with the major amblyoscope, also based on

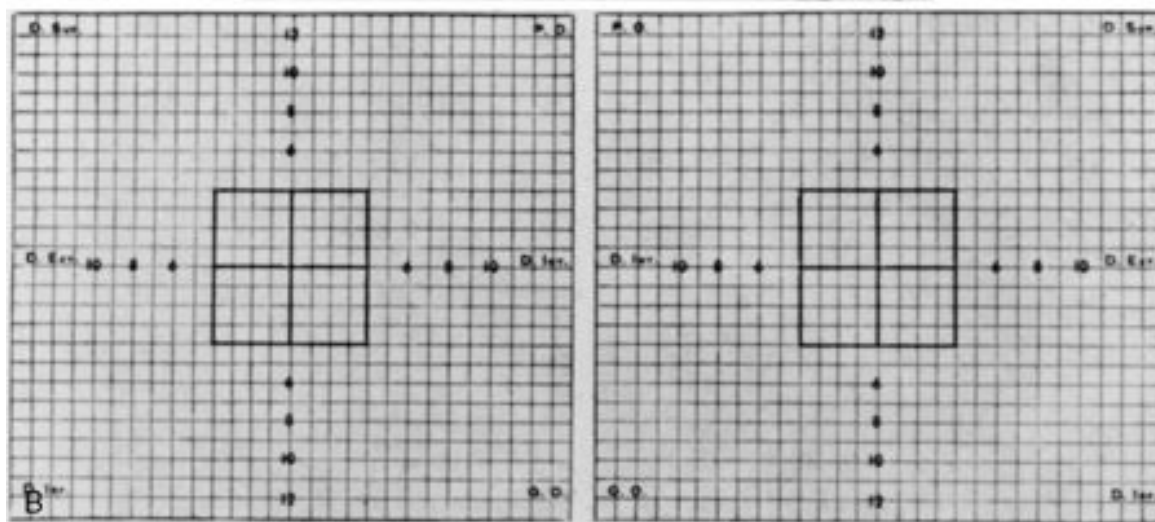



FIGURE 12-28. Lancaster red-green test. *A*, Equipment for the test. *B*, Charts to record results. (Courtesy of Luneau and Couffignon, Chartres, France.)

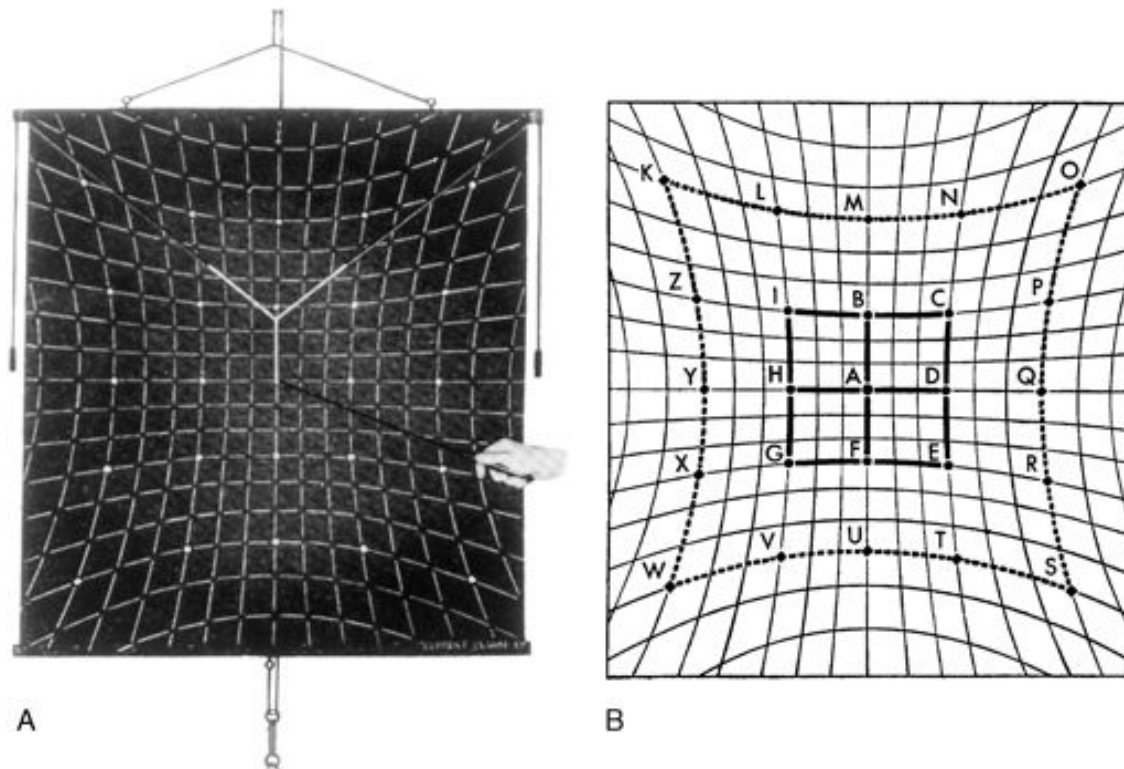


FIGURE 12-29. The Hess screen test. *A*, The screen. *B*, Chart for recording the results (From Lyle TK, Wybar KC: Lyle and Jackson's Practical Orthoptics in the Treatment of Squint [and Other Anomalies of Binocular Vision], ed. 5. Springfield, IL, Charles C Thomas, 1967.)

the haploscopic principle, are aimed primarily at establishing the sensory state of the patient and are discussed in Chapter 13.

Measurement of Cyclodeviations

Qualitative Diagnosis Based on Position of Double Images

The measurement of cyclodeviations in clinical practice relies largely on subjective tests. In patients who have spontaneous diplopia or who can be made to appreciate diplopia by interrupting fusion with alternate covering of the eyes, cyclodeviations can be grossly estimated by holding a ruler horizontally with the straight edge in front of their eyes and slightly below the midline. If one of the cyclovertical rotators is involved, there will be vertical diplopia. By alternately covering the eyes, the examiner then ascertains to which eye the higher or lower image belongs and asks whether the two rulers seen by the patient appear closer on the right or on the left. To avoid any misunderstanding, one should draw a horizontal line and then let the patient add the obliquely seen line. For quantitative determination of cyclotropia the Lancaster red-green test may be used.

The tilt of the retinal image is opposite the tilt of the horizontal line, as seen by the observer. Therefore, when the line is seen slanted toward the nose (to the left for the right eye or to the right for the left eye), an excyclodeviation is present. Tilting of the line down toward the temple will indicate the presence of an incyclodeviation. For correct interpretation refer to the diagram shown in Figure 12-30. A simple mnemonic rule is that the line is always tilted in the direction in which the offending muscle would rotate the eye if it were acting alone. Since, for example, the superior oblique is an intortor in addition to being a depressor, paralysis of that muscle will cause the image seen by the involved eye to appear lower and slanted toward the nose.

Maddox Double Rod Test

For quantitative determination of a cyclodeviation, red and white Maddox rods are placed in a trial frame, the red before the right eye and the white before the left eye (Fig. 12-31). The direction of the glass rods is aligned with the 90° marks of the trial frame. A small scratch on the metal frame of the Maddox rods facilitates this alignment. Special care must be taken to avoid tilting the trial frames

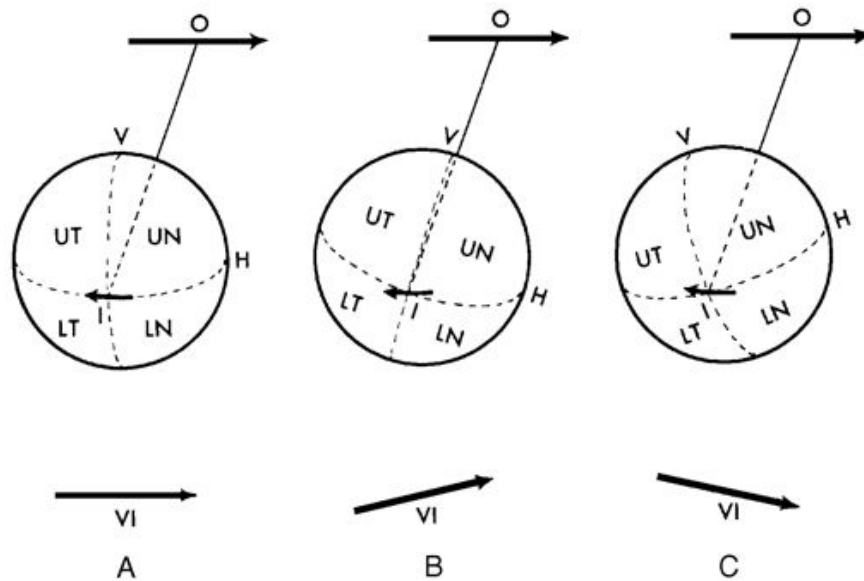


FIGURE 12-30. Subjective appearance and retinal image of a horizontal line seen by the left eye. *A*, In the absence of a cyclodeviation. *B*, With incyclotropia. *C*, With excyclotropia. *V* and *H*, The vertical and horizontal meridians of the retina; *UT*, *UN*, *LT*, and *LN*, the upper and lower temporal and nasal quadrants of the retina; *VI*, the resulting visual impression.

during the test. The patient looks through the Maddox rods and is shown a penlight, the images of which appear as horizontal streaks. A vertical prism may be added to separate the images for easier identification. If one of the lines (say, the red one) appears slanted toward the nose (Fig. 12-31A), excyclotropia of the right eye is present. The red Maddox rod is then turned by the ophthalmologist (or by the patient) until the red line is seen parallel with the white line (Fig. 12-31B). If at the end of this adjustment the scratched mark points, for example, toward the 100° mark of the right trial frame, the patient has a right excyclotropia of 10°. In the presence of bilateral cyclotropia, for instance, excyclotropia of the right and left eye in bilateral traumatic superior oblique paralysis, both the red and white lines will be seen slanted toward the nose. The settings are repeated two or three times. With good observers the measurements are extremely accurate. To test the cyclodeviation outside the primary position, shift the penlight to the right, left, above, and below, and repeat the test.

The Maddox double rod test is valuable as a qualitative test to substantiate a patient's complaint about image tilting and to quantitatively determine the degree of tilt. However, the dissociating characteristics of the test preclude cyclofusion, which is a most effective compensating mechanism in cyclodeviations.^{100, 101} Thus the Maddox double rod test may indicate a cyclotropia

that, in some patients, may be clinically insignificant under casual viewing conditions that permit cyclofusion. Moreover, since ocular dominance determines the patient's response to the Maddox double rod test, contradictory results with respect to the laterality of the paralyzed muscle are common.⁹⁰

Simons and coworkers¹⁰⁹ have shown that the two-color format of the Maddox double rod test, with the red rods placed before the right eye and the clear rods before the left eye, may produce artifactual localization of the image perceived through the red rods in patients with superior oblique paralysis. Thirty-three of 40 patients (83%) localized the excyclodeviation to the eye viewing through the red Maddox rods, regardless of the laterality of the paralysis or the fixation preference. To avoid this artifact and the influence of peripheral visual clues the authors suggested that red Maddox rods be placed before both eyes and that the test be performed in a dark room. To distinguish which eye is cyclodeviated one Maddox rod is then slightly rotated back and forth in the trial frame and the patient is asked whether it is the horizontal or tilted luminous line that is "rocking."

Bagolini Striated Glasses

To test for cyclotropia under casual viewing conditions, we replace the Maddox rods with the stri-

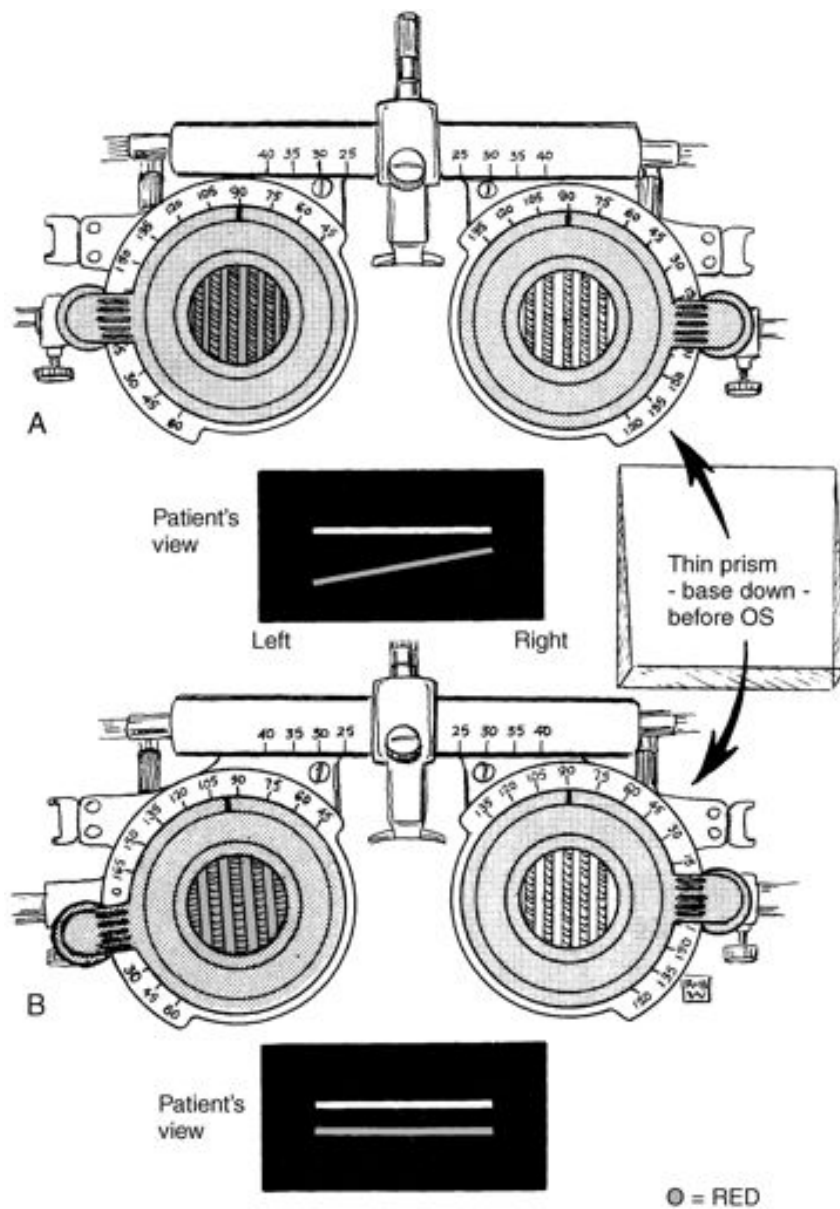


FIGURE 12-31. The Maddox double-rod test. For explanation, see text. (From Noorden GK von: Atlas of Strabismus, ed 4. St Louis, Mosby-Year Book, 1983, p 57.)

ated glasses of Bagolini.⁷ Like Maddox rods, these glasses produce an image of a streak of light, perpendicular to the axis of the striations when viewing a punctate light source, without, however, obstructing surrounding fusible visual details. The glasses are placed in the trial frame with the axes of striation pointing toward the 90° mark. If the patient is unable to fuse the two vertical lines, the glasses are turned until fusion occurs and the amount and direction of the cyclotropia is read off the trial frames as during the Maddox double rod test.¹⁰⁰ The use of the Bagolini glasses to test for retinal correspondence is discussed in Chapter 14.

Major Amblyoscope

To test for cyclotropia, the targets positioned in the arms of this instrument are rotated around an

axis until there is no more movement of redress of the eye that takes up fixation. The amount of cyclodeviation, expressed in degrees, can be read off the instrument.

Ophthalmoscopy and Fundus Photography

Indirect ophthalmoscopy and fundus photography are useful auxiliary methods to diagnose cyclotropia. As early as 1855 and not long after the invention of the ophthalmoscope by von Helmholtz (1851), von Graefe⁵¹ pointed out an apparent vertical displacement of the optic disk in cyclodeviations and discussed using ophthalmoscopy to study the action of muscles involved in cyclorotations of the globe. Normally, the average location of the fovea in relation to the optic nerve

head is 0.3 disk diameter below a horizontal line extending through the geometric center of the optic disk. From this position, an imaginary horizontal line will cross the optic nerve head just below the halfway point between its geometric center and lower pole (Fig. 12–32A). The range of variation of this relationship in nonstrabismic persons is indicated by the solid lines in Figure 12–32A. Incyclotropia is present when the fovea appears above a line extending horizontally from the center of the optic nerve head (Fig. 12–32B), and excyclotropia is present when the fovea is below a line extending horizontally from just below the lower pole of the optic disk (Fig. 12–32C). The fovea's position may vary slightly between the two eyes, but a difference of 0.25 or more of a disk diameter in the vertical position should be considered abnormal.¹⁴

To measure the amount of torsion accurately while viewing the fundus through a 60D lens on

the slit lamp, Spierer¹¹³ suggested projecting a horizontal slit beam on the retina so that it crosses the fovea while the patient fixates on a target straight-ahead with the other eye. In the presence of cyclotropia the examiner tilts the slit beam until it crosses the fovea on one side and the border between the center and lower third of the optic disk on the other side. The amount of tilting needed for this position to occur is then read off the scale mark on the slit lamp. De Ancos and Klainguti³ described a special lens to measure the angular displacement of the lower border of the optic disk with respect to the fovea during indirect ophthalmoscopy.

Discrepancies between sensory and motor aspects of cyclodeviations, as expressed in differences between subjective (Maddox double rod test, Bagolini lenses) and objective (ophthalmoscopy, fundus photography) findings, are discussed in Chapter 18.

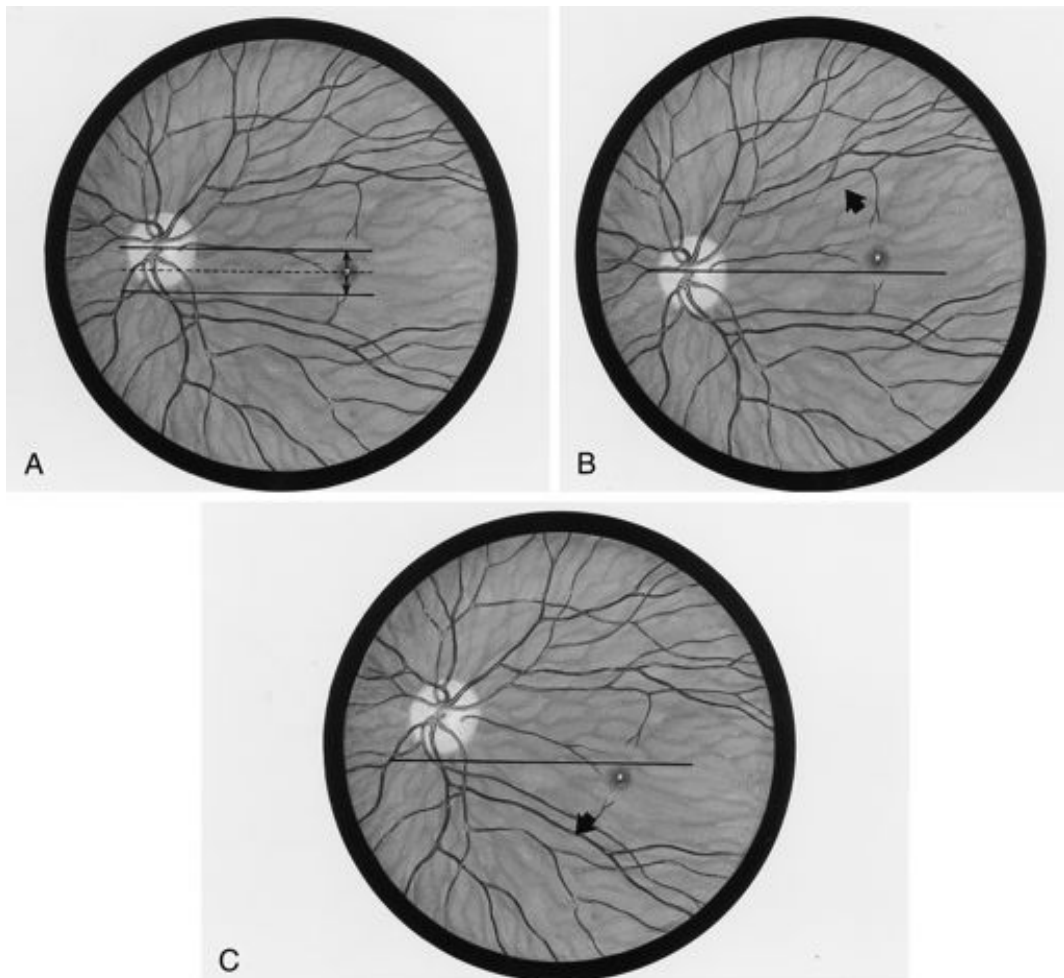


FIGURE 12–32. A, Average foveal position (*dashed line*) and range of normal (*solid line*). B, Fundus in patient with incyclotropia. C, Fundus in excyclotropia. (From Bixenmann WW, Noorden GK von: Apparent foveal displacement in normal subjects and in cyclotropia. *Ophthalmologica* 89:58, 1982.)

The “New Cyclo Test”

The New Cyclo Test,* introduced by Awaya and coworkers,⁶ is similar in principle to the Awaya test for aniseikonia (see p. 121) and based on haploscopic image separation with red-green spectacles. A red half-moon is viewed through the green glass and a green half-moon through the red glass. In a series of printed figures the green half-moon is tilted in a stepwise fashion. The patient selects the figure in which the two half-moons appear to be aligned and the amount of cyclodeviation in degrees is then read off this figure.

Scotometry

Locke⁷⁶ showed that the vertical displacement of the blind spot in cyclotropic eyes may be used to determine its degree. This method, while precise, is rarely used in clinical practice.

Determination of the Subjective Horizontal or Vertical

Determination of the subjective horizontal or vertical with and without spatial clues distinguishes between the contribution of such clues to the adaptation to cyclotropia. This method, almost forgotten now but once used widely in clinical practice as part of the workup of a patient with paralysis of the cyclovertical muscles,^{61, 121} is still a useful diagnostic tool⁹⁹ (see Chapter 18). The patient whose head is stabilized views with either eye a luminous line that is projected in random oblique positions onto an optically empty screen. The pa-

*Distributor for the Western Hemisphere: Binoculus (see p. 174 for address).

tient then rotates the slide containing the line until it appears exactly horizontal to him or her. The deviation from the objective horizontal as determined with a carpenter’s level is measured by the examiner with a protractor and indicates the degree of cyclotropia.

Measurement of Dissociated Vertical Deviations

Bielschowsky¹² classified vertical deviation into four groups: (1) true comitant hyperphorias and hypertropias, (2) dissociated vertical divergence (alternating sursumduction), (3) paretic vertical deviations, and (4) vertical deviations in the right and left half of the field of fixation caused by primary overaction of an inferior oblique muscle. The diagnostic differentiation of these forms is discussed in Chapter 18, but a few words must be said about the diagnosis of *dissociated vertical deviation*, commonly abbreviated as DVD.

In patients with DVD, the alternate cover test reveals that each eye turns upward under cover in contrast to the situation in vertical heterophoria. After removal of the cover, the eye makes a slow downward movement to reach the midline, at times even going below it, accompanied by incycloduction. The translucent occluder of Spielmann¹¹² is especially useful in the diagnosis of this condition and in demonstrating it to the patient’s parents (Fig. 12–33). As pointed out in Chapter 18 a precise measurement of the vertical excursions of each eye during DVD is nearly impossible because of the variable nature of this condition.

The Head Tilt Test

The maneuver of comparing the angle of strabismus with the head tilted successively toward one

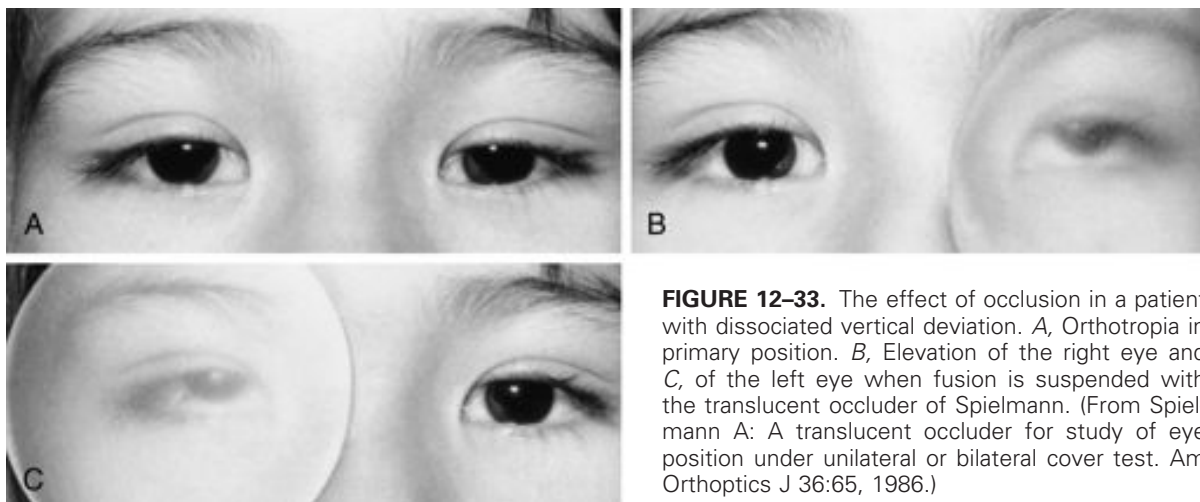


FIGURE 12–33. The effect of occlusion in a patient with dissociated vertical deviation. *A*, Orthotropia in primary position. *B*, Elevation of the right eye and *C*, of the left eye when fusion is suspended with the translucent occluder of Spielmann. (From Spielmann *A*: A translucent occluder for study of eye position under unilateral or bilateral cover test. *Am Orthoptics J* 36:65, 1986.)

and then the other shoulder, introduced by Hofmann and Bielschowsky⁶⁴ in 1900 and widely developed by Bielschowsky, is known as the *head tilt test*. This useful test gives positive findings regardless of whether the patient has any binocularity. The physiologic principles of the head tilt test and its application during the diagnosis of cyclovertical deviations are discussed in Chapter 20. The deviation may differ in various head positions in patients with congenital and acquired paralyses of the cyclovertical muscles when other diagnostic signs have become blurred with the passage of time. Two valuable assets of the test are that the difference in the deviation can be seen and measured by the examiner and that it can be readily used in examining young children who cannot yet respond to subjective tests. In some instances it is difficult to see the difference in the vertical deviation in the head tilt test. In such instances a prism and cover test with the head tilted first to one shoulder and then to the other is advisable. The prism should always be tilted so that it has the same relation to the eye as in primary position (Fig. 12–34).

Examination of the Motor Cooperation of the Eyes

Ductions and Versions

Determination of the deviation amount in the nine diagnostic positions of gaze by means of the prism



FIGURE 12–34. Head tilt test with prism and cover measurement. Note that the prism is held so that its base and axis are parallel with the palpebral fissure and not with the floor.

and cover test or by one of the subjective tests establishes certain important points in the diagnosis. These points must be amplified by a study of the extent to which the eyes, singly or together, perform movements in various directions of gaze.

When examining *ductions*, cover one eye and have the patient follow a penlight or other fixation target, bringing the eye to the farthest possible position in the directions right, left, up, down, up and right, up and left, down and right, and down and left. The examiner observes whether movement lags or is excessive in any direction. Bielschowsky¹³ pointed out that a study of the versions is of more value than a study of the ductions. He stated that it is easier for the patient to overcome a weakness in the action of a muscle by a very strong innervational impulse during ductions than while performing version movements.

To study the *versions*, one places a penlight in the midline before the patient's eyes and moves it in the various directions, keeping the penlight at such a distance that one can always observe the corneal reflections in both eyes. While doing so, carefully watch for excessive or defective movements in any direction. Remove the patient's glasses to observe the movement of the eyes in peripheral positions of gaze.

In judging the normalcy of adduction and abduction, a gross but useful guideline is followed. In maximal adduction an imaginary vertical line through the lower lacrimal punctum should coincide with a boundary line between the inner third and the outer two thirds of the cornea (Fig. 12–35A). If more of the cornea is hidden, the adduction is excessive (Fig. 12–35B). If more of the cornea is visible on maximal adduction and if some of the sclera remains visible, adduction is defective (Fig. 12–35C). If abduction is normal, the corneal limbus should touch the outer canthus (Fig. 12–35D). If the limbus passes that point and some of the cornea is hidden, the abduction is excessive (Fig. 12–35E). If some of the sclera remains visible, abduction is defective (Fig. 12–35F).

Guibor⁵³, p. 28 rated overaction in adduction and underaction in abduction on a scale of 1 to 4; however, he assigned no specific figures to the grades of overaction or underaction. Urist¹²³ developed what he called the lateral version light reflex test, which is performed by holding a penlight exactly in the midline of the patient's head at a distance of about 25 cm. The patient makes extreme dextroversions and levoversions. Normally,

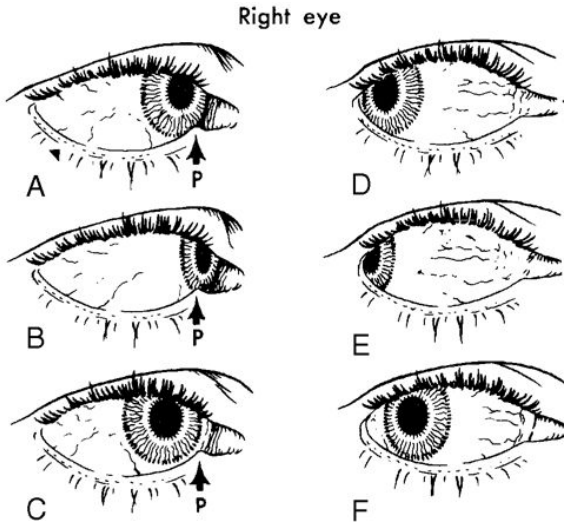


FIGURE 12-35. The ductions of the eyes. *A*, Normal adduction. *B*, Excessive adduction. *C*, Defective adduction. *D*, Normal abduction. *E*, Excessive abduction. *F*, Defective abduction. *P*, Lacrimal punctum. While the versions are being tested, the fellow eye is kept open and, as a rule, fixates. The left eye is not shown in this figure.

the light reflex in the adducted eye should be on the cornea at 35° temporally (Hirschberg scale) and at 10 mm nasally from the limbus on the sclera of the abducted eye.

A much more precise procedure is the *limbus test of motility* of Kestenbaum,⁶⁸ intended especially for evaluating the action of paretic muscles. This test avoids some pitfalls inherent to older tests in attempting to determine the shift in relative position of certain fixed points in different positions of gaze. The test is performed by holding a transparent millimeter ruler horizontally in front of the cornea. In measuring abduction, the location of the nasal limbus point is noted on the ruler in primary position and in maximum abduction. The difference immediately gives the degree of abduction in millimeters. Adduction is measured similarly by determining the positions of the temporal limbus. To measure elevation and depression, hold the ruler vertically. The examiner should test each eye with his or her own homonymous eye. Normal values established by Kestenbaum are 10 mm for adduction, abduction, and depression, and 5 to 7 mm for elevation (Fig. 12-36). It is interesting to note that there is no shift of the midpoint of the excursions toward the nose in normal subjects.⁶⁸

Patients with esotropia (infantile or accommodative; see Chapter 16) and alternating fixation or with manifest-latent nystagmus (see Chapter 23)

may employ the left eye for viewing objects in the right field of vision and the right eye for objects in the left field of vision. No effort is made to abduct the nonfixating eye, which shows an apparent limitation of abduction (Fig. 12-37A and B). This behavior is called *crossed fixation* and in the older literature is also referred to as *tripartite fixation*. To distinguish between pseudo-paralysis and true paralysis of the lateral rectus muscle, the ductions of each eye are examined while the fellow eye is patched (Fig. 12-37C).

In general, the agreement between the measurements in the diagnostic positions and the behavior of the versions is good, but there are exceptions. For example, simultaneous weakness of adduction in one eye and an excess of abduction in the other eye may offset each other and the abnormalities of the versions may not be apparent from the differences in measurements of the deviation.²¹

In watching pursuit movements of the eyes, one may find that the fixating eye will follow the light, but the deviated eye will remain stationary for some time and then make a sudden movement in the direction taken by the fixating eye. Infrequently, version movements (e.g., a dextroversion movement) are replaced by vergence movements.^{22, 23}

As a rule, children with comitant strabismus will follow an appropriate fixation object without difficulty. However, they frequently have much more difficulty in making version movements in a direction opposite that of the deviation (e.g., in levoversion in a left esotropia). This behavior is mentioned briefly in the discussion of the etiology of heterotropia.

Tests that distinguish between innervational and mechanical-restrictive limitations of ocular ro-

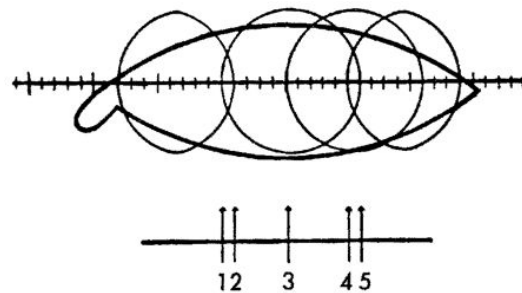


FIGURE 12-36. The limbus test of Kestenbaum. (From Kestenbaum. *A: Clinical Methods of Neuro-Ophthalmologic Examination*, ed 2. New York, Grune & Stratton, 1961, p 237.)

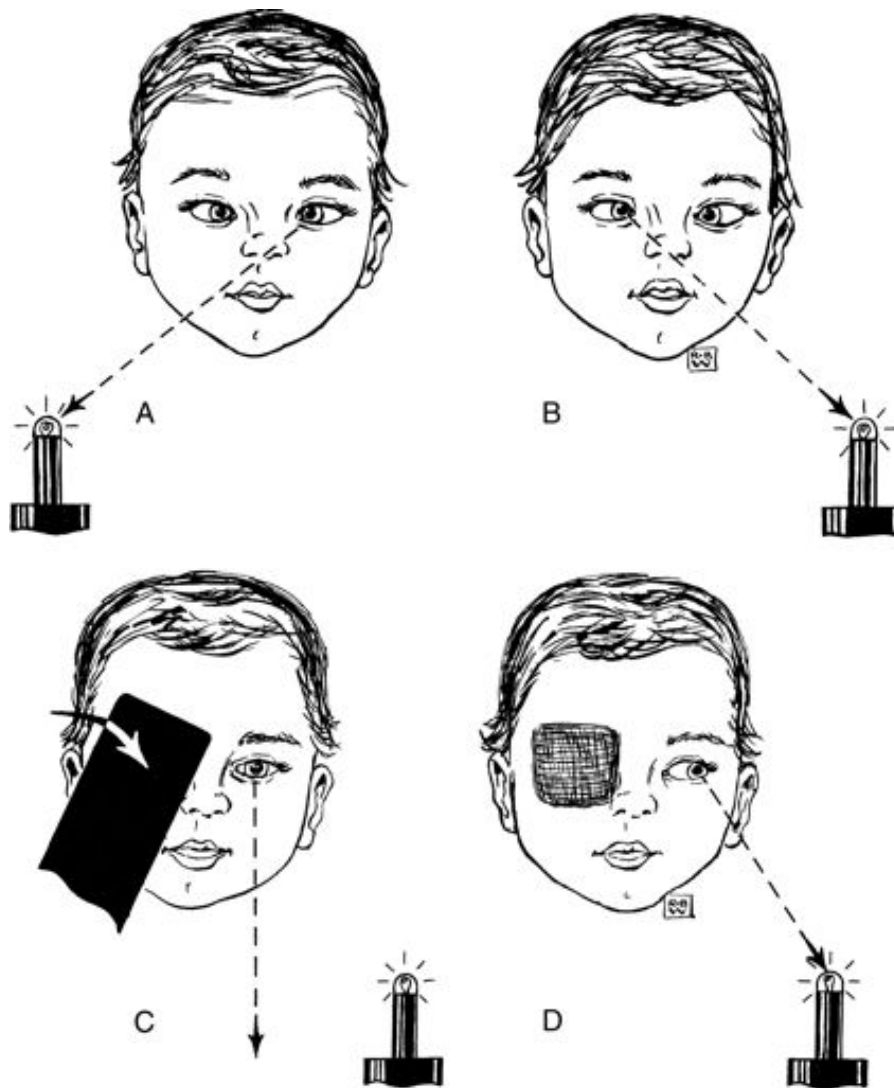


FIGURE 12-37. Crossed fixation. *A*, Children with esotropia may employ the left eye for viewing objects in the right field of vision and *B*, the right eye to view an object in the left field of vision. Thus no effort is made to abduct the nonfixating eye, and the examiner must differentiate between a true and a simulated abducens paralysis. *C*, Momentary occlusion of the fixating eye may not suffice to force the fellow eye to take up fixation. *D*, Occlusion for several minutes may be required to restore good abduction. (From Noorden GK von: Atlas of Strabismus, ed 4. St Louis, Mosby-Year Book, 1983, p 121.)

tations (forced duction test, estimation of generated muscle force, saccadic velocities) are discussed in Chapter 20.

Elevation or Depression of the Adducted Eye (Upshoot or Downshoot in Adduction)

When studying the versions, one often finds the adducted eye to be elevated. The phenomenon may be unilateral or bilateral. This elevation in adduction is called *strabismus sursoadductorius* and in the more recent American literature is also referred to as *upshoot in adduction*. It is often overlooked but important to note that *overaction of the inferior oblique muscle is but one of several*

causes for this phenomenon. Other causes are paralysis of the contralateral superior rectus muscle, dissociated vertical deviation, certain forms of Duane retraction syndrome, excyclotropia of the involved eye, and atopic muscle pulleys. The differential diagnosis of these conditions from primary and secondary overaction of the inferior oblique muscle is discussed in Chapter 18.

Depression of the adducted eye, also called *strabismus deorsoadductorius* or *downshoot in adduction*, is seen with overaction of the superior oblique muscles, paralysis of the contralateral inferior rectus muscle (see Chapter 18), atopic muscle pulleys, and may also occur with Duane retraction syndrome (see Chapter 21).

Measurement of Vergences

Determination of the vergences is of major importance in examination of the motor state of a patient's eyes. It provides information about the patient's ability to cope with a deviation and is also helpful in establishing the type of deviation according to Duane's classification.³⁶ The characteristics of the disjunctive ocular movements, the fusional movements or vergences, are discussed in some detail in Chapter 4. What follows deals with their practical determination rather than the physiologic basis of the tests.

To produce a vergence movement, retinal images must be shifted so that they fall outside the Panum area of the retinal region under investigation. Since the extent of that area in the foveal region is roughly of the magnitude of 6 minutes of arc and since vergences are usually measured with bifoveal fixation, a shift of 1^Δ is ample to produce an image displacement capable of eliciting a fusional movement.

Measurement With Prisms

The patient is seated comfortably and asked to fixate the appropriate object. A rotary prism is then placed in front of one eye and moved to produce the desired fusional movement. The prism may be hand-held, or it may be part of a phorometer or phoropter. The prism strength is increased slowly and stepwise, and the patient is asked to report when the fixation object appears double. When the patient reports diplopia, at which point the two images are rather suddenly quite far apart, the required amount of prism power is noted. It represents the limit of the patient's fusional amplitude in the direction tested, the so-called breakpoint. The prism power is then reduced, again slowly and stepwise, and the point at which the patient regains single vision is noted. This is the so-called *recovery point*.

Many ophthalmologists disregard the recovery point, depriving themselves of an important bit of information. The recovery point indicates a patient's readiness to fuse the images. It should be 2^Δ to 4^Δ below the breakpoint. If the breakpoint for convergence at near is, say, at 24^Δ, the recovery point should be 20^Δ to 22^Δ. Some patients may not recover until the prism power is much reduced, to 10^Δ, 8^Δ, or even 0^Δ. This is especially common in patients with intermittent deviations and indicates that once fusion is broken they have great difficulty regaining it.

When the convergence amplitudes are measured, the patient will see singly and clearly up to a point. Beyond this point the fixation object will appear blurred but single until the breakpoint is reached, where the fixation point doubles up and again is seen clearly. The point at which the blurring occurs is known as the *blur point*. It measures the limits within which accommodation can clear the image of the fixation point in spite of increased convergence. The amount of fusional convergence that can be elicited between the blur point and breakpoint represents the absolute convergence. Orthoptists use accommodative targets to determine the blur point and nonaccommodative targets to determine the breakpoint.

Vergence movements are *slow* and *tonic*. They must be elicited by increasing the prisms slowly to allow the patient to regain fusion after each change. If the prism power is changed too quickly, lower fusional amplitudes are obtained than if the test is properly performed. For a smooth and continuous increase of prismatic power we prefer a rotary prism (Fig. 12–38) rather than a prism bar with a stepwise increase of prismatic power. One must also remember that when a strong impulse to perform a convergence movement has been given, the tonic innervation does not suddenly stop with removal of the stimulus but continues for quite some time. If one starts by measuring the convergence amplitude and this is followed immediately by measurement of the divergence amplitude, divergence is opposed by the lingering tonic innervation to converge. The resulting divergence amplitude is then likely to have a lower value than if it had been measured first because any fusion-induced vergence has an aftereffect⁴¹ that is stronger after sustained convergence than after divergence or vertical vergences. The longer the duration of the vergence effort, the longer the rate of recovery from the aftereffect.¹⁰⁷ The best means of reducing this effect is to induce a vertical vergence. The following order in testing fusional amplitudes is recommended: prisms base-out (convergence), prisms base-up (deorsumvergence), prisms base-in (divergence), and prisms base-down (sursumvergence).

Vergences should always be tested both in distance and near fixation. Frequently they are tested at one fixation distance only (e.g., in distance fixation), especially when the divergence amplitudes are determined with a major amblyoscope. In patients who complain of difficulties in close work, especially when a convergence insufficiency

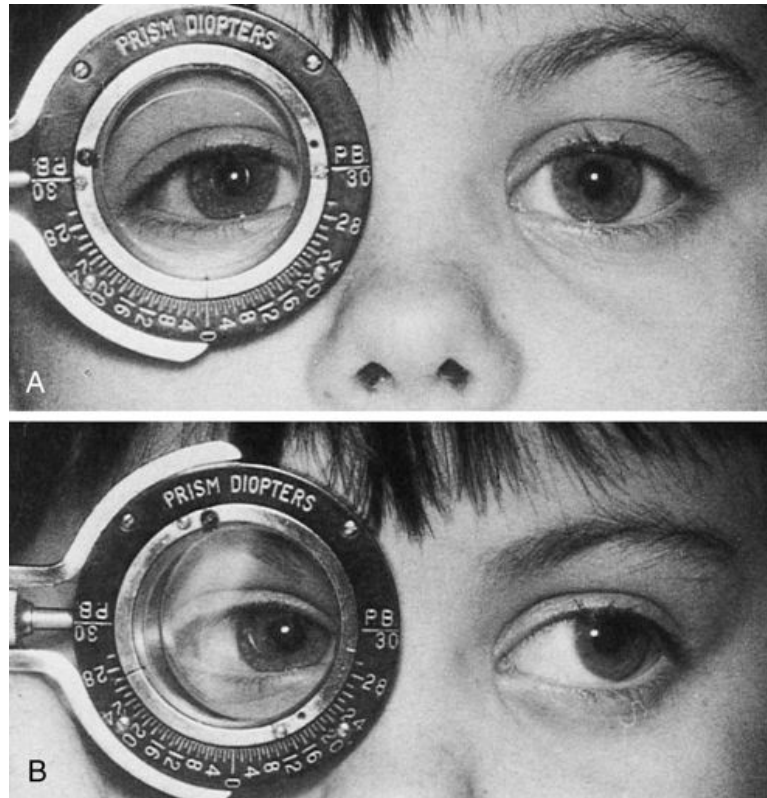


FIGURE 12-38. Objective measurement of endpoint of vergence. *A*, Rotary prism at zero. The eyes are parallel. *B*, Rotary prism has reached 26 Δ base-out. The left eye is in divergent position.

is suspected, a comparison of the vergences in distance and near fixation is often very enlightening.

Since vergences are fusional movements, amplitudes depend on the amount of fusible material in the field of view of the person examined; the greater the amount of fusible material, the larger the amplitudes. They are smallest when a fixating light is seen in a completely dark room,⁵⁰ and they cannot be elicited with dissimilar targets in a major amblyoscope. In 1948 Fink⁴⁵ made a careful study of this subject and recommended a 6/9 letter as a suitable fixation object. Actually, a small fixation light serves the purpose well since its doubling up is most easily recognized by the patient, provided the light is surrounded by ample fusible material (such as vertical and horizontal lines) usually available in a well-lighted office. The images of this fusible material occupy the whole of the two retinas and provide an adequate fusion stimulus.

Most patients are able to recognize diplopia when the breakpoint is reached, but some do not and instead suppress the image in the deviated eye. Even in such instances the breakpoint can be determined by observation, at least in near fixation. Both eyes will appear properly aligned as long as they follow the vergence stimulus induced,

for example, by base-out prisms. As soon as the breakpoint is reached, one eye will turn out (see Fig. 12-38).

The question most frequently asked and most difficult to answer concerns normal limits of the different vergences. It is not possible to state in specific numbers what the amounts of the vergences are or should be. Convergence normally is larger than divergence, and vertical vergences are smaller than either of the two. In some texts normal limits for distance fixation are given as 20 Δ for convergence, 6 Δ to 8 Δ for divergence, and 3 Δ to 4 Δ for sursumvergence and deorsumvergence. Cyclovergence amplitudes may range between 8 $^\circ$ and 22 $^\circ$, depending on the size and orientation of the targets being used.^{30, 55, 67, 95}

Horizontal vergences measured in distance fixation are smaller than those obtained in near fixation, and the most useful data are probably still those of Berens and coworkers¹⁰ (Table 12-2). These data were taken with prism bars in 104 subjects with normal vision. Sharma and Abdul-Rahim¹⁰⁸ reported larger vertical amplitudes (mean 4.63 Δ) than those found by Berens and coworkers.

Mellick⁸² used a variable prism stereoscope and the synoptophore (a form of major amblyoscope) and two targets (a fusion target and a stereoscopic target) to study horizontal fusional amplitudes in

TABLE 12-2. Average Vergence Amplitudes of 218 Men

	Convergence	Divergence	Sursumvergence
At 6 m	14.1 ^Δ	5.82 ^Δ	2.54 ^Δ
At 25 cm	38.02 ^Δ	16.47 ^Δ	2.57 ^Δ

Data from Berens C, Losey CC, Hardy LH: Routine examination of the ocular muscles and non-operative treatment. Am J Ophthalmol 10:910, 1927.

relation to age. He could find no significant influence of age but did observe that the amplitude of convergence for distance and near vision was twice as large when measured with the synoptophore as when measured with a prism stereoscope. The average figures for his 561 subjects of all ages are presented in Table 12-3. The data of Tait¹¹⁶ obtained from 500 ocularly normal subjects (Fig. 12-39) reflect the distribution of both breakpoint and recovery point.

From these figures it is evident that amplitudes of the vergences vary considerably from one person to another, even if function of the binocular system is normal. They are a measure in the motor sphere of a person's responsiveness to disparate stimulation, as stereoscopic acuity is a measure of a person's responsiveness in the sensory sphere.

It is important to relate the vergence amplitudes to another individual characteristic, the heterophoric position for the distance at which the amplitudes are measured. In this regard, measurements with a rotary prism may be misleading unless they are properly understood. In performing this test, the patient's eyes start from the primary position, as defined clinically; that is, the eyes intersect in the fixation point, having already overcome any heterophoric position that might be present. The test with the rotary prism tells only how much additional vergence the patient can perform. Case 12-1 may make this point a little clearer.

CASE 12-1

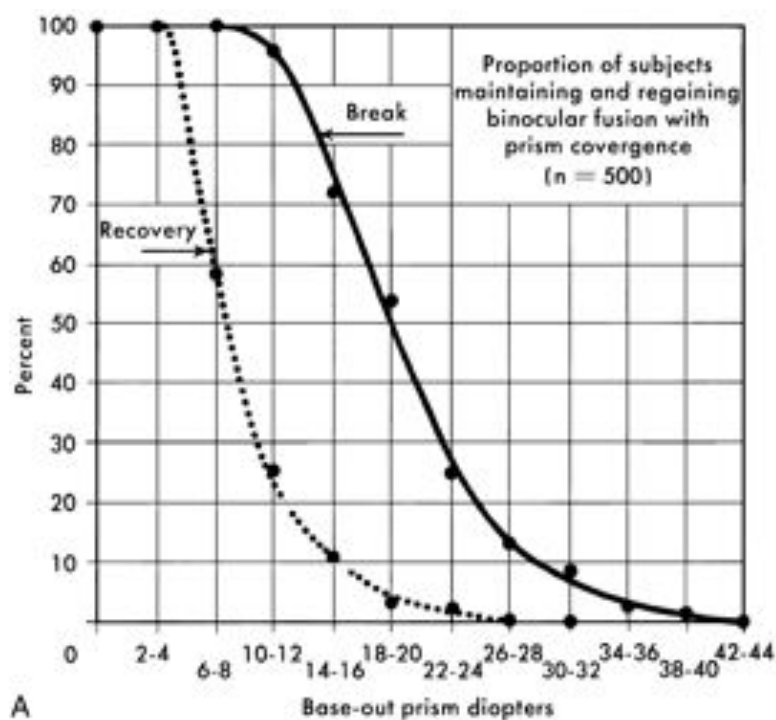
A 27-year-old woman had an intermittent exotropia for distance of 22^Δ, which she could control quite well. Measured with rotary prisms for distance, she had a convergence breakpoint at 8^Δ and a divergence breakpoint at 26^Δ. This appeared to be an obvious case of insufficient prism convergence and excessive prism divergence, a conclusion that would only be true if the zero position of the rotary prism had a biological significance, which it did not. Actually, this patient was able to overcome by convergence a divergent heterophoric position of 22^Δ to keep her eyes straight. With a rotary prism she overcame an additional 8^Δ of convergence. This patient, then, in fact possessed a convergence amplitude of 30^Δ, although her divergence beyond the heterophoric position was only 4^Δ. The patient was operated on, and the deviation for distance was reduced approximately to zero. Following the operation, the amplitudes were found to be 30^Δ of convergence and 6^Δ of divergence.

Case 12-1 illustrates that measurements of vergence amplitudes with a rotary prism are meaningful only insofar as they are related to the patient's *heterophoric position*, yet the absolute values are not completely without significance. They indicate the reserve that the patient has beyond the parallel position of the visual lines. A reserve of 8^Δ of convergence, as the above patient had, is clearly insufficient. Such a patient may readily

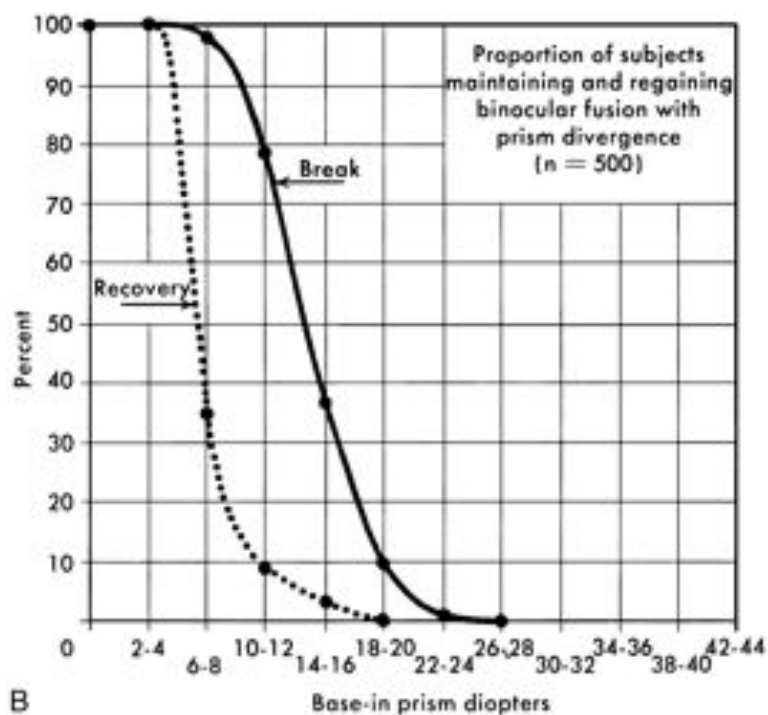
TABLE 12-3. Mean Values and Standard Errors of Horizontal Vergences in 561 Subjects with Normal Neuromuscular Systems

	Variable Prism Stereoscope		Synoptophore	
	Fusion Target	Stereoscopic Target	Fusion Target	Stereoscopic Target
Convergence amplitudes				
Distance	17.68 ± 0.26	18.29 ± 0.50	38.47 ± 0.76	40.33 ± 0.79
Near	26.42 ± 0.39	22.18 ± 0.26	51.36 ± 0.83	55.68 ± 0.86
Divergence amplitudes				
Distance	7.97 ± 0.10	9.00 ± 0.15	10.78 ± 0.12	11.77 ± 0.16
Near	13.61 ± 0.16	12.04 ± 0.15	12.63 ± 0.13	13.36 ± 0.16

Data from Mellick A: Convergence. An investigation into the normal standards of age groups. Br J Ophthalmol 33:725, 1949.



A



B

FIGURE 12-39. Data of Tait for breakpoint and recovery point in 500 subjects. A, Prism convergence. B, Prism divergence. (From Tait EF: Fusional vergence. *Am J Ophthalmol* 32:1223, 1949.)

experience diplopia under conditions of stress and annoying asthenopic symptoms.

In contrast, one may find remarkably large fusional amplitudes in patients with well-developed binocular vision. This is particularly impressive in vertical heterophorias in which fusional amplitudes may amount to 20^Δ and more, especially in cases of long-standing superior oblique muscle paralysis.

In 1900, Hofmann and Bielschowsky⁶⁵ made a thorough study of vertical fusional amplitudes and concluded that they gradually increase by training up to a maximum value of 5.5° (approximately 11^Δ). Ellerbrock,⁴⁰ on further investigation of vertical amplitudes, discovered that they were greater in magnitude when larger fusional targets were presented and when the rate of separation of the targets was slower. He reported amplitudes as large as 7.5° to 8.4° (approximately 16^Δ).⁴²

An example of extraordinarily large vertical amplitudes, which developed in a patient who had a hyperphoria throughout his life, is given in Case 12–2.⁸³

CASE 12–2

A 42-year-old man who complained of blurring and distortion at close work had been given glasses incorporating a correction for a mild hypermetropic astigmatism and 6^Δ base-down for a correction of a right hypertropia (RHT). Our examination revealed a vision of 6/4.5 in each eye with a correction of +1.00D sph –1.00D cyl ax 80° OD and +5.00D sph –1.00D cyl ax 85° OS. With this correction he had 10^Δ of comitant RHT for distance and 12^Δ of comitant RHT for near. He had excellent horizontal fusional amplitudes, and his vertical fusional amplitudes were extraordinarily large (24/16^Δ of sursumvergence and 24/10^Δ of deorsumvergence). He had satisfactory binocular cooperation with a stereoscopic threshold of 40 seconds of arc. The patient was given his refractive correction with a reading add but no prisms since he was so well adapted to his motor anomaly. Over a follow-up period of 6 years, his motor condition has not changed and he has remained free of symptoms.

Measurement With a Major Amblyoscope

When vergences are measured with a major amblyoscope, the point of departure is the heterophoric position, that is, the arms are set at the patient's

angle of deviation. From this position, various vergence movements are induced by moving the arms (for the horizontal vergences) or the targets (for vertical and cyclovergences). This procedure determines total vergence amplitudes, but no information is gained about the fusional reserve beyond the straight position of the eyes. This test can be done also in heterophoric patients by starting with the arms of the major amblyoscope at zero. These measurements correspond to those obtained with the rotary prism.

Ordinarily, the major amblyoscope is adjusted for optical infinity. Placing minus lenses of appropriate strength in front of each eye and setting the arms at 18^Δ adapt the instrument for near fixation, and vergences can also be measured for near visual distance.

Targets that incorporate fusible material must be used to measure vergence amplitudes when a major amblyoscope is used. Using targets that contain larger or smaller amounts of fusible material allows the effect of the amount of fusible material on the amplitudes to be determined.

Fusional Movements Elicited by Peripheral Retinal Stimuli in Strabismus

Burian²⁰ applied the peripheral fusion technique (see p. 74) in 75 patients with comitant strabismus and showed that patients with manifest strabismus can display fusional movements. The main results obtained in eliciting fusional movements by peripheral retinal stimuli can be summarized as follows: patients with strabismus in whom peripheral fusional stimuli were effective, as a rule, experienced sensory disturbances (suppression, changes in mode of localization, changes in deviation) when the two retinal centers were stimulated simultaneously; patients who did not follow peripheral fusional stimuli did not have retinocentral disturbances. Although the technique used in Burian's studies is not directly applicable in ordinary clinical practice to examination of patients, it can be used to some extent in the major amblyoscopes by designing or selecting appropriate targets both for diagnostic and therapeutic purposes.

Near Point of Convergence

The near point of convergence (NPC) is determined by placing a fixation object at 30 to 40 cm in the midplane of the patient's head; the patient

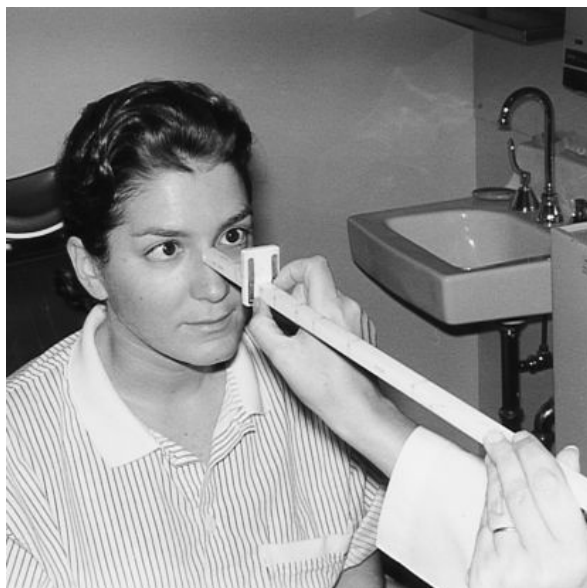

FIGURE 12–40. Objective measurement of near point of convergence.

is then asked to maintain fixation on the object. The object is then moved toward the eyes until one of the eyes loses fixation and turns out. The distance at which this occurs is the NPC. It is measured by a Prince ruler or similar device (Fig. 12–40). This NPC lies approximately in the plane of the centers of rotation of the eyes.

The eye that maintains fixation at the NPC is generally considered to be the dominant eye, and the deviated one is the nondominant eye. Determination of the NPC is one of many tests suggested for establishing ocular dominance.

The NPC should be at 8 to 10 cm. A distance closer than 5 cm is excessive. An NPC farther away than 10 cm is defective or remote. In patients with convergence insufficiency, it may be as remote as 25 or 30 cm or more. As the test is repeated, the NPC often comes closer to the eyes. The NPC is readily trained, except in extreme cases of convergence insufficiency. On the other hand, in a single testing session patients may make a special effort to converge and have a better NPC than they actually use in casual seeing.

These statements are justified to some extent when the test is performed *objectively*. They also apply to the subjective form of the test in which the endpoint is established by the patient's report of diplopia. They very definitely do not apply to modification of the *subjective test* as described by Capobianco²⁶ and used routinely in our clinic. In this test a moderately dense red filter is placed in front of one of the patient's eyes, preferably the

dominant eye. A penlight is held at a distance at which the patient can fuse the two images. One pinkish light is then seen. The penlight is now advanced in the midline of the patient's head, and the point is noted at which binocular single vision is lost and diplopia is reported.

This test offers a slight obstacle to fusion, minimizes the effect of voluntary convergence, and yields results of diagnostic and prognostic value. In comparing findings in the objective test and the red-glass test, the following observations can be made: (1) In patients with good convergence function, results obtained with two tests are comparable and both are within normal limits; (2) in patients with convergence insufficiency, the subjective NPC is generally more remote than the objective NPC and the difference may be quite large; (3) in patients with convergence insufficiency who have a slightly remote NPC but in whom the NPC established by the red-glass subjective test coincides with the objectively measured NPC, the prognosis for speedy, successful recovery by treatment is good; (4) throughout the treatment the NPC, as measured by the subjective red-glass test, normalizes more rapidly than the objectively determined NPC; and (5) at the successful completion of treatment, the NPC should not only be normal but values obtained in the objective and red-glass subjective tests should be in agreement.

Maintenance of Convergence

A patient not only must be able to converge the eyes to a near vision distance but also must be able to maintain convergence. This ability may be tested by what is called, inaccurately, the drop convergence test. When NPC is measured, an object is brought closer to the eyes. Accommodative and fusional convergence are stimulated by the object and assist in performance of the convergence movement. After bringing the fixation object into reading distance, ask the patient to maintain convergence after the fixation object is removed ("dropped"). Some patients are better able than others to keep their eyes converged in the absence of a fixation object.

REFERENCES

1. Adelstein FE, Cüppers C: Analysis of the motor situation in strabismus. In Arruga A, ed: International Strabismus Symposium (University of Giessen, 1966). New York, S Karger, 1968, pp 139–148.

2. Ames A Jr, Gliddon GH: Ocular measurements. *Trans Section Ophthalmol A M A* 1928, p 102.
3. Ancos W de, Klainguti G: Mesure objective de la torsion oculaire: Une nouvelle loupe d'ophtalmoscopie indirecte. *Klin Monatsbl Augenheilkd* 204:360, 1994.
4. Archer SM: Developmental aspects of the Brückner test. *Ophthalmology* 95:1098, 1988.
5. Aulhorn E: Phasendifferenz-Haploskopie. Eine neue Methode zur Trennung der optischen Eindrücke beider Augen. *Klin Monatsbl Augenheilkd* 148:540, 1966.
6. Awaya S, Miyuki I, Motoya M, et al: The New Cyclo Test and its clinical application. In Campos E, ed: *Proceedings of the Fifth Meeting of the International Strabismological Association (ISA)*. Modena, Italy, Athena Scientific Distributors, 1986, p 225.
7. Bagolini B: Tecnica par l'esame della visione binoculare senza introduzione di elementi dissocianti: "Test del vetro striato." *Boll Ocul* 37:195, 1958.
8. Bagolini B: Ricerche sul comportamento della "convergenza prossimale" in soggetti strabici e normali (rilievi mediante determinazione al sinottoforo e con prismi). *Boll Ocul* 40:461, 1961.
9. Barry JC, Effert R, Kaupp A: Objective measurement of small angles of strabismus in infants and children with photographic reflection pattern evaluation. *Ophthalmology* 99:320, 1992.
10. Berens C, Losey CC, Hardy LH: Routine examination of the ocular muscles and non-operative treatment. *Am J Ophthalmol* 10:910, 1927.
11. Bielschowsky A: Ein ungewöhnlicher Fall von vertikaler Heterotropie der Makulae. *Klin Monatsbl Augenheilkd* 84:755, 1930.
12. Bielschowsky A: Disturbances of vertical motor muscles of the eyes. *Arch Ophthalmol* 20:175, 1938.
13. Bielschowsky A: *Lectures on Motor Anomalies*, Hanover, NH, Dartmouth College Publications, 1943/1956.
14. Bixenmann WW, Noorden GK von: Apparent foveal displacement in normal subjects and in cyclotropia. *Ophthalmologica* 89:58, 1982.
15. Braun B, Schiffman EL: The validity and predictive value of four assessments for evaluation of the cervical and stomatognathic systems. *J Craniomandibular Disord* 5:239, 1991.
16. Brodie SE: Photographic calibration of the Hirschberg test. *Invest Ophthalmol Vis Sci* 28:736, 1987.
17. Brown HW: The cover test. In Allen JH, ed: *Strabismus Ophthalmic Symposium, II*. St Louis, Mosby-Year Book, 1958, p 225.
18. Brückner R: Exakte Strabismusdiagnostik bei 1/2–3 jährigen Kindern mit einem einfachen "Durchleuchtungstest." *Ophthalmologica* 144:184, 1962.
19. Burian HM: Fusional movements: The role of peripheral retinal stimuli. *Arch Ophthalmol* 21:486, 1939.
20. Burian HM: Fusional movements in permanent strabismus. A study of the role of the central and peripheral retinal regions in the act of binocular vision. *Arch Ophthalmol* 26:626, 1944.
21. Burian HM: Closing remarks. In discussion of Burian HM, Spivey BE, on the surgical management of exodeviations. *Trans Am Ophthalmol Soc* 62:305, 1964.
22. Burian HM, Cahill JE: Congenital paralysis of medial rectus muscle with unusual synergism of the horizontal rectus muscles. *Trans Am Ophthalmol Soc* 50:87, 1952.
23. Burian HM, Van Allen MW, Sexton RR, et al: Substitution phenomena in congenital and acquired supranuclear disorders of eye movement. *Trans Am Acad Ophthalmol Otolaryngol* 69:1105, 1965.
24. Campos EC: Classification et physiopathologie du torticollis oculaire—aspect sensoriel. *Bull Soc Belge Ophthalmol* 221–222:9, 1987.
25. Campos EC, Orciuolo M, Schiavi C: A new automatic computerized deviometer. *Int Ophthalmol* 13:291, 1989.
26. Capobianco NM: The subjective measurement of the near point of convergence and its significance in the diagnosis of convergence insufficiency. *Am Orthopt J* 2:40, 1952.
27. Capuano-Pucci D, Rheault W, Aukai J, et al: Intratester and intertester reliability of the cervical range of motion device. *Arch Phys Med Rehabil* 72:338, 1991.
28. Chavasse FB: *Worth's Squint or the Binocular Reflexes and the Treatment of Strabismus*. Philadelphia, P Blakiston's Son & Co, 1939.
29. Choi RY, Kushner BJ: The accuracy of experienced strabismologists using the Hirschberg and Krimsky tests. *Ophthalmology* 105:1301, 1998.
30. Crone RA, Everhard-Halm Y: Optically induced eye torsion. 1. Fusional cyclovergence. *Graefes Arch Clin Exp Ophthalmol* 195:231, 1975.
31. Cüppers C: Determination of the objective angle. In Mein, J, Bierlaagh JJM, Brummelkamp-Dons TEA, eds: *Orthoptics*. Amsterdam, Excerpta Medica, 1972, p 65.
32. Cüppers C: *Korrektur der Horizontalabweichung*, vol 5. Wiesbaden, Germany, BVA Arbeitskreis Schielbehandlung, 1973, p 1.
33. Damms T, Damms C, Schulz E, et al: Pseudoesotropie durch Verlängerung der Makula nach nasal bei Patienten mit infantiler hoher Myopie. *Ophthalmologie* 91:77, 1994.
34. DeRespinis PA, Naidu E, Brodie SE: Calibration of Hirschberg test photographs under clinical conditions. *Ophthalmology* 96:944, 1989.
35. Donders FC: *On the Anomalies of Accommodation and Refraction of the Eye*. Translated by Moore WD. London, New Sydenham Society, 1864.
36. Duane A: A new classification of the motor anomalies of the eyes based upon physiological principles, together with their symptoms, diagnosis and treatment. Reprinted from *Ann Ophthalmol Otolaryngol* 5:969, 1896.
37. Duane A, Berens C Jr: Ocular movements. *Ophthalmol Lit* 17:53, 1921.
38. du Bois-Reymond C: Ueber Schielmessung. *Centralbl Prakt Augenheilkd* 10:5, 1886.
39. Duke-Elder S: *System of Ophthalmology*, vol 3, pt 2: *Congenital Deformities*. London, Henry Kimpton, 1964, p 851.
40. Ellerbrock VJ: Experimental investigations of vertical fusional movements. *Am J Optom* 26:327, 1949.
41. Ellerbrock VJ: Tonicity induced by fusional movements. *Am J Optom* 27:8, 1950.
42. Ellerbrock VJ: The aftereffect of aniseikonia on the amplitude of vertical divergence. *Am J Optom* 29:403, 1952.
43. Ellis PP: Ectopia of the macula. *Am J Ophthalmol* 44:262, 1957.
44. Eskridge JB, Perrigin DM, Leach NE: The Hirschberg test: Correlation with corneal radius and axial length. *Optom Vis Sci* 67:243, 1990.
45. Fink WH: The vergence test—an evaluation of the various techniques. *Am J Ophthalmol* 31:48, 1948.
46. Franceschetti AT, Burian HM: Proximal convergence. An evaluation by comparison of major amblyoscope and alternate prism and cover test measurements and by AC/A ratio determinations. In *Strabismus '69 Transactions of the Consilium Europaeum Strabismi Studio Deditum Congress (London 1969)*. St Louis, Mosby-Year Book, 1970, p 125.
47. Freedman HL, Preston KL: Polaroid photoscreening for amblyogenic factors. *Ophthalmology* 99:1785, 1992.
48. Fry GW, quoted by Lancaster WB: Terminology in ocular motility and allied subjects. *Am J Ophthalmol* 26:122, 1943.
49. Giovanni FG, Siracusano B, Cusmano R: The angle kappa in ametropia. *New Trends Ophthalmol* 3:27, 1988.

50. Goldstein JH, Hornblass A, Clahane AC: Effect of peripheral vision on the binocular relationship: A further study. *Am J Ophthalmol* 66:86, 1968.
51. Graefe A von: Ueber die ophthalmoskopische Beobachtung gewisser Augenmuskelwirkungen. *Graefes Arch Clin Exp Ophthalmol* 2:322, 1855–1856.
52. Griffin JR, Cotter SA: The Brückner test: Evaluation and clinical usefulness. *Am J Optom Physiol Opt* 63:957, 1986.
53. Guibor GP: *Squint and Allied Conditions*. New York, Grune & Stratton, 1959.
54. Guyton DL: Remote optical systems for ophthalmic examinations. *Trans Am Ophthalmol Soc* 84:869, 1986.
55. Guyton DL: Ocular torsion: Sensorimotor principles. *Graefes Arch Clin Exp Ophthalmol* 226:241, 1988.
56. Guyton DL, Moss A, Simons K: Automated measurement of strabismic deviations using a remote haploscope and an infrared television-based eye tracker. *Trans Am Ophthalmol Soc* 85:320, 1987.
57. Haase W, Malchartzeck C, Rickers J: Ergebnisse der Fadenoperation nach Cüppers. *Klin Monatsbl Augenheilkd* 172:313, 1972.
58. Hardesty HH: Diagnosis of paretic vertical rotators. *Am J Ophthalmol* 56:818, 1963.
59. Harms H: Über die Untersuchung der Augenmuskellähmungen. *Graefes Arch Clin Exp Ophthalmol* 144:129, 1941.
60. Helveston EM: Two-step for diagnosing paresis of vertically acting extraocular muscle. *Am J Ophthalmol* 64:914, 1967.
61. Herzau W: Bestimmung der Medianabweichung des Auges. *Klin Monatsbl Augenheilkd* 86:406, 1931.
62. Hess WR: Ein einfaches messendes Verfahren zur Motilitätsprüfung der Augen. *A Augenheilkd* 35:201, 1916.
63. Hirschberg J: Über die Messung des Schielgrades und die Dosierung der Schieloperation. *Zentralbl Prakt Augenheilkd* 9:325, 1885.
64. Hofmann FB, Bielschowsky A: Die Verwertung der Kopfneigung zur Diagnose der Augenmuskellähmungen. *Graefes Arch Clin Exp Ophthalmol* 51:174, 1900.
65. Hofmann FB, Bielschowsky A: Über die der Willkür entzogenen Fusionsbewegungen der Augen. *Pflügers Arch* 80:1, 1900.
66. Javal E: *Manuel du strabisme*. Paris, Masson, 1896, p 55.
67. Kertesz AE, Sullivan MJ: The effect of stimulus size on human cyclofusional response. *Vision Res* 18:567, 1978.
68. Kestenbaum A: *Clinical Methods of Neuro-Ophthalmologic Examination*, ed 2. New York, Grune & Stratton, 1961, p 237.
69. Krinsky E: The binocular examination of the young child. *Am J Ophthalmol* 26:624, 1943.
70. Kushner BJ: The usefulness of the cervical range of motion device in the ocular motility examination. *Ophthalmology* 118:946, 2000.
71. Lancaster WB: Detecting, measuring, plotting and interpreting ocular deviations. *Trans Section Ophthalmol AMA 90th session*, 1939, p 78.
72. Lancaster WB: Terminology in ocular motility and allied subjects. *Am J Ophthalmol* 26:122, 1943.
73. Lancaster WB: Personal communication, quoted by Roper, KN, Bannon RE: Diagnostic values of monocular occlusion. *Arch Ophthalmol* 51:316, 1944.
74. Lancaster W: *Refraction Correlated with Optics and Physiological Optics and Motility Limited to Heterophoria*. Springfield, IL, Charles C Thomas, 1952, p 102.
75. Lang J: The fourth image of Purkinje: A diagnostic tool in microtopia. *Doc Ophthalmol* 58:91, 1984.
76. Locke JC: Heterotopia of the blind spot in ocular vertical muscle imbalance. *Am J Ophthalmol* 65:362, 1968.
77. Ludvigh E: Amount of eye movement objectively perceptible to the unaided eye. *Am J Ophthalmol* 32:649, 1949.
78. Lyle TK, Wybar KC: *Lyle and Jackson's practical orthoptics in the treatment of squint (and other anomalies of binocular vision)*, ed 5. Springfield, IL, Charles C Thomas, 1967.
79. Mackensen G: Die Tangentenskala nach Harms. In *Augenmuskellähmungen*. Bücherei d. Augenarztes, vol 46. Stuttgart, Ferdinand Enke Verlag, 1966.
80. Marlow FW: Prolonged monocular occlusion as a test for muscle balance. *Am J Ophthalmol* 4:238, 1921.
81. Mehdorn E, Kommerell G: "Rebound saccade" in the prism cover test. *Int Ophthalmol* 1:63, 1978.
82. Mellick A: Convergence. An investigation into the normal standards of age groups. *Br J Ophthalmol* 33:725, 1949.
83. Miles DR, Burian HM: Unpublished case observed in the Department of Ophthalmology, University of Iowa, Iowa City.
84. Miller JM, Hall HL, Greivenkamp JE, et al: Quantification of the Brückner test for strabismus. *Invest Ophthalmol Vis Sci* 36:897, 1995.
85. Mühlendyck H: Der Synoptometer als Grundlage von Operationsindikationen und Verlaufskontrolle bei komplizierten Augenmuskelstörungen. *Klin Monatsbl Augenheilkd* 167:892, 1975.
86. Mühlendyck H, Linnen HJ: Die operative Behandlung nystagmusbedingter schwankender Schielwinkel mit der Fadenoperation nach Cüppers. *Klin Monatsbl Augenheilkd* 167:273, 1975.
87. Neikter B: Effects of diagnostic occlusion on ocular alignment in normal subjects. *Strabismus* 2:67, 1994.
88. Noorden GK von, Olson CL: Diagnosis and surgical management of vertically incomitant horizontal strabismus. *Am J Ophthalmol* 60:434, 1965.
89. Ogle KN: Distortion of the image by prisms. *J Opt Soc Am* 41:1023, 1951.
90. Olivier P, Noorden GK von: Excyclotropia of the nonparetic eye in unilateral superior oblique muscle paralysis. *Am J Ophthalmol* 93:30, 1982.
91. Ottar WL, Scott WE, Holgado LI: Photoscreening for amblyogenic factors. *J Pediatr Ophthalmol Strabismus* 32:289, 1995.
92. Paliaga GP: Linear strabismometric methods. *Binocular Vision* 7:139, 1992.
93. Paliaga GP, Ghisofi A, Guinta G, et al: Millimetric cover test—a linear strabismometric technique. *J Pediatr Ophthalmol Strabismus* 17:331, 1980.
94. Paliaga GP, Paliaga A, Decarli A: Evaluation of ocular rotation by measurement of corneal light reflex movements. *Clin Oculistica Patol Ocul* 6:449, 1983.
95. Parkinson DK, Burke JP, Shipman TL: Normal fusional amplitudes: With special attention paid to cyclofusion. In *Lennerstrand G, ed: Advances in Strabismology. Proceedings of the Eighth Meeting of the International Strabismological Association, Maastricht, The Netherlands, Sept 10–12, 1998*. Buren, The Netherlands, Aeolus Press, 1999, p 95.
96. Parks MM: Isolated cyclovertical muscle palsy. *Arch Ophthalmol* 60:1027, 1958.
97. Putnam OA, Quereau JV: Precision errors in measurement of squint and phoria. *Arch Ophthalmol* 34:7, 1945.
98. Romano PE, Noorden GK von: Limitations of cover test in detecting strabismus. *Am J Ophthalmol* 77:10, 1971.
99. Roper KN, Bannon RE: Diagnostic values of monocular occlusion. *Arch Ophthalmol* 31:316, 1944.
100. Ruttum M, Noorden GK von: Adaptation to tilting of the visual environments in cyclotropia. *Am J Ophthalmol* 96:229, 1983.
101. Ruttum M, Noorden GK von: The Bagolini striated lens test for cyclotropia. *Doc Ophthalmol* 58:131, 1984.
102. Ruttum MS, Shimshak KJ, Chesner M: Photographic

- measurement of the angle of strabismus. In Campos ES, ed: *Strabismus and Motility Disorders*. Proceedings of the Sixth Meeting of the International Strabismological Association. London, Macmillan, 1990, p 155.
103. Scattergood KD, Brown M, Guyton D: Artifacts introduced by spectacle lens in the measurement of strabismic deviations. *Am J Ophthalmol* 96:439, 1983.
 104. Schatz H: An instrument for measuring ocular torticollis (head turn, tilt, and bend). *Am Acad Ophthalmol Otol* 75:650, 1971.
 105. Schworm HD, Kau C, Reindl B, et al: Zur Früherkennung amblyopieauslösender Augenveränderungen. *Klin Monatsbl Augenheilkd* 21:158, 1997.
 106. Scobee RG: *The Oculorotary Muscles*, ed 2. St Louis Mosby-Year Book, 1952.
 107. Sethi B, Henson DB: Adaptive changes with prolonged effect of comitance and incomitance vergence disparities. *Am J Optom Physiol Opt* 61:505, 1984.
 108. Sharma K, Abdul-Rahim AS: Vertical fusion amplitude in normal adults. *Am J Ophthalmol* 114:636, 1992.
 109. Simon K, Arnoldi K, Brown MH: Color dissociation artifacts in double Maddox rod cyclo-deviation testing. *Ophthalmology* 101:1897, 1994.
 110. Simons BD, Siatkowsky RM, Schiffman JC, et al: Pediatric photoscreening for strabismus and refractive errors in a high-risk population. *Ophthalmology* 106:1073, 1999.
 111. Sloane AE: Analysis of methods for measuring diplopia fields. Introduction of device for such measurements. *Arch Ophthalmol* 46:277, 1951.
 112. Spielmann A: A translucent occluder for study of eye position under unilateral or bilateral cover test. *Am Orthopt J* 36:65, 1986.
 113. Spierer A: Measurement of cyclotorsion. *Am J Ophthalmol* 122:911, 1996.
 114. Sradj N: Über die Bedeutung ocular bedingter Zwangshaltungen und die Möglichkeit ihrer Messung mit dem Torticollometer. *Klin Monatsbl Augenheilk* 1656:823, 1974.
 115. Sradj A: Torticollometry for direct measurement of head position. *Am Orthopt J* 34:117, 1984.
 116. Tait EF: Fusional vergence. *Am J Ophthalmol* 32:1223, 1949.
 117. Thompson DA: Measurements with cover test vs. troposcope. *Am Orthoptics J* 2:47, 1952.
 118. Thompson JT, Guyton DL: Ophthalmic prisms: Measurement errors and how to minimize them. *Ophthalmology* 90:204, 1983.
 119. Toosi SH, Noorden GK von: Effect of isolated inferior oblique muscle myectomy in the management of superior oblique muscle palsy. *Am J Ophthalmol* 88:602, 1979.
 120. Tong PY, Enke-Miyazaki E, Bassin RE, et al: Screening for amblyopia in preverbal children with photoscreening photographs. National Children's Eye Care Foundation Vision Screening Study Group. *Ophthalmology* 105:856, 1998.
 121. Tschermak-Seysenegg A von: *Introduction to Physiological Optics*. Translated by Boeder P. Springfield, IL, Charles C Thomas, 1952, p 140.
 122. Tscherning H: *Optique physiologique*. Paris, Georges Carré et C. Naud, 1898, p 42.
 123. Urist MJ: Lateral version light reflex test. *Am J Ophthalmol* 63:808, 1967.
 124. Urist MJ: Head tilt in vertical muscle palsy. *Am J Ophthalmol* 69:970, 1970.
 125. Weinand F, Graf M, Denning K: Sensitivity of the MTI photoscreener for amblyogenic factors in infancy and early childhood. *Graefes Arch Clin Exp Ophthalmol* 236:801, 1998.
 126. Wiesinger: *Neuere Methoden der Schielbehandlung*. Gesellschaft Charité Aerzte. Report of meeting of May 10, 1906. *Klin Wochenschr* 43:1025, 1906.
 127. Worth C, cited by Brückner R: Exakte Strabismusdiagnostik bei 1/2–3 jährigen Kindern mit einem einfachen "Durchleuchtungstest." *Ophthalmologica* 144:184, 1962.
 128. Young JD: Head posture measurement. *J Pediatr Ophthalmol Strabismus* 25:86, 1988.

Examination of the Patient—III

SENSORY SIGNS, SYMPTOMS, AND BINOCULAR ADAPTATIONS IN STRABISMUS

When a manifest deviation of the visual axes of the two eyes is present, images of all objects in the binocular field are shifted onto the retinas relative to each other; the larger the shift, the greater the deviation. Motor and sensory fusion may become impossible, with two distressing results. First, different objects are imaged on corresponding areas (the two foveae) and therefore are seen in the same visual direction and overlap (Fig. 13–1A). Second, identical objects (the fixation point) are imaged on disparate retinal areas (the fovea of one eye and the peripheral retina of the other eye) and therefore are seen in different visual directions; that is, they are seen double (Fig. 13–1B). The first phenomenon is termed *confusion*⁹⁶; the second, *diplopia*.

Strictly speaking, confusion and diplopia are not abnormal. They are physiologically correct sensory responses. They must occur in every patient who has adequate vision in each eye but in whom an acute relative deviation of the visual axes has developed. To avoid them, the visual system has at its disposal two mechanisms: *suppression* and *anomalous correspondence*. Another prominent sensory sign in comitant strabismus,

likely to be closely related to suppression, is *amblyopia*.

Suppression, amblyopia, and anomalous correspondence are “nature’s way out of trouble” for the patient who by these mechanisms gains comfortable single monocular vision or an anomalous form of binocular cooperation. One may consider them to be adaptive sensory mechanisms by which the sensory system adjusts to an abnormal motor situation. This interpretation implies that the sensory responses are a consequence of the motor anomaly. In contrast, it has been stated that the sensory anomalies in strabismus may be present at birth,¹ heritable,^{131, 154} and indeed the cause of a deviation. Evidence supporting this view is extremely tenuous. Moreover, sensory anomalies can often be eliminated with treatment, another argument in favor of the fact that these anomalies cannot be the cause of a deviation. However, it is true that there must be a predisposition to sensory anomalies; that is, a weakness in the sensory anlage, more pronounced in families in which strabismus occurs in several members, and this weakness is possibly a heritable trait.⁴³ Thus some patients suppress very readily and others only with

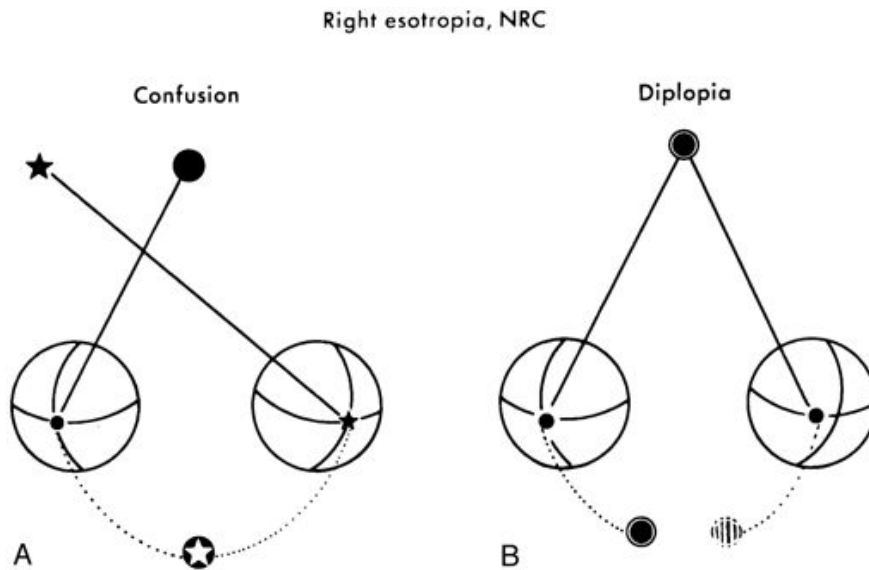


FIGURE 13–1. Effects of the relative deviation of the visual lines. *A*, Confusion. *B*, Diplopia. NRC, Normal retinal correspondence. (From Burian HM: Adaptive mechanisms. *Trans Am Acad Ophthalmol Otolaryngol* 57:131, 1953.)

difficulty or not at all. In some, the angle of anomaly (see p. 230) adapts almost instantaneously to changed motor conditions; in others it remains unchanged over years and decades in spite of changes in the deviation. In adults, suppression, amblyopia, and changes in retinal correspondence do not occur. Hence in adults an acquired strabismus will cause constant diplopia. On the other hand, visually immature children usually adapt readily to strabismus and diplopia rarely becomes a problem.

None of the abnormal sensory responses add anything *qualitatively* new to the act of vision. All abnormal responses of squinters are *performed* in the normal act of vision and are perversions or exaggerations of it.³³ Thus suppression and, by extension, amblyopia represent a loss of the rhythm of binocular rivalry. Anomalous correspondence is an extreme shift in visual directions that occurs under physiologic conditions in stereopsis (see Chapter 2).

Confusion and diplopia obviously occur only when the patient uses both eyes, but suppression and anomalous correspondence are also basically binocular phenomena. To be sure, suppression may be restricted to one eye, amblyopia may be an extreme form of such suppression, and maintenance of a shift in monocular visual directions, akin to anomalous correspondence, has been claimed to be responsible for eccentric fixation in amblyopia.⁵⁰ The fact remains, however, that exclusion of one eye from the act of vision sig-

nificantly affects depth of suppression in the other eye and even the functioning of amblyopic eyes. Suppression in one eye can be interrupted by reducing the stimulus to the other eye; the size and depth of the suppression scotoma depend on the amount of stimulation to the other eye, as does visual acuity of the amblyopic eye.

The examination of the sensory state of a patient with neuromuscular anomalies of the eyes consists of establishing (1) the presence of confusion and diplopia, (2) the presence and degree of suppression, (3) the presence and degree of amblyopia, (4) the type of interocular relationship present (normal and anomalous correspondence), and (5) the patient's responsiveness to disparate retinal stimulation (stereopsis).

Confusion and Diplopia

Confusion is not often reported voluntarily, but when patients do notice overlap of the different foveal images, they find it very distressing. On the other hand, diplopia is a common complaint.

When a patient has a complaint about double vision or admits, when questioned, to seeing double, a methodical algorithmic approach (Fig. 13–2) is helpful in analyzing the problem, especially when an obvious strabismus is not apparent during the initial examination. The ophthalmologist must realize that “double” vision means different things to different people. Blurred vision of one

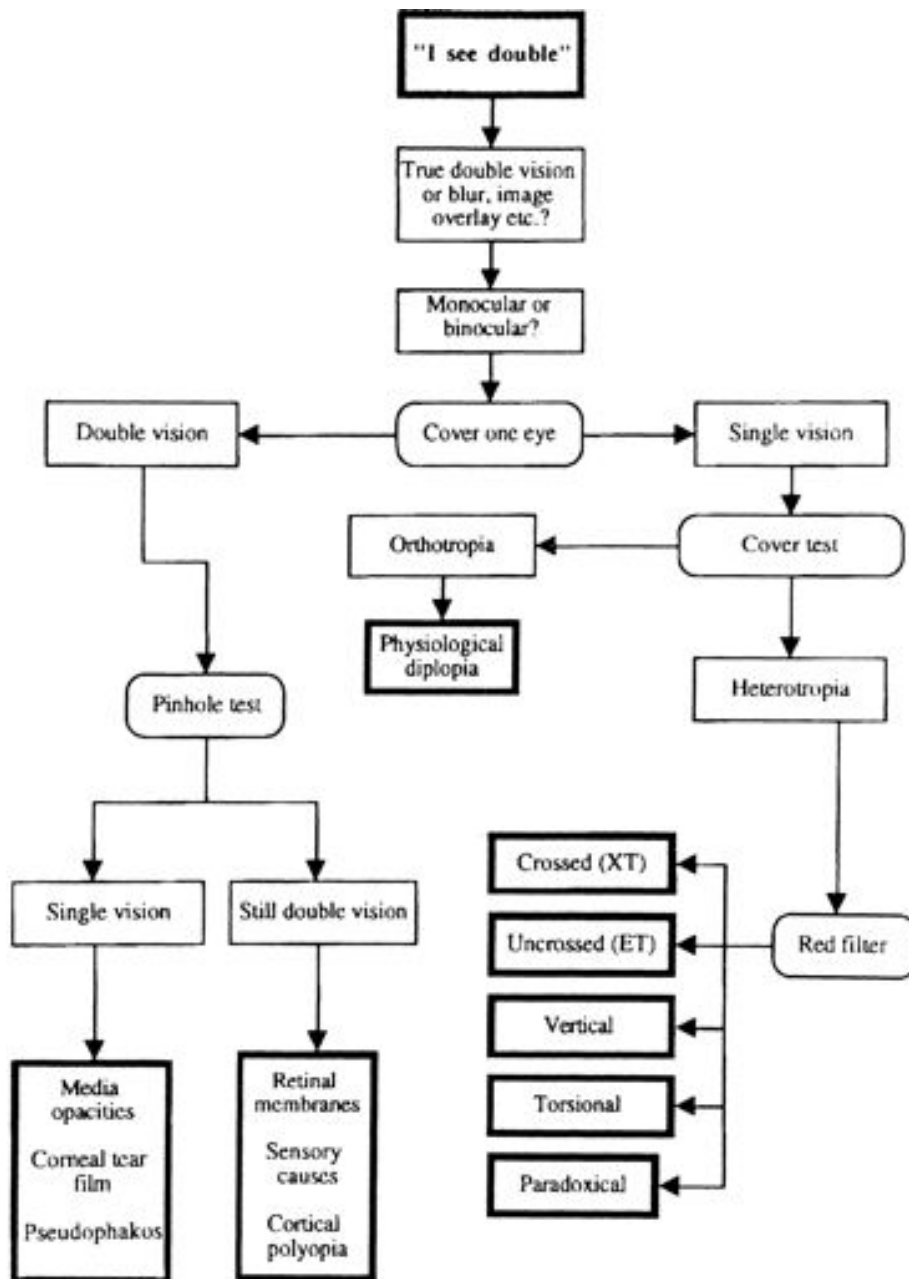


FIGURE 13-2. Algorithmic approach to analyzing double vision. For explanation, see text. (Modified from Noorden GK von, Helveston EM: Strabismus: A Decision-Making Approach. St Louis, Mosby-Year Book, 1994, p 68.)

eye, an overlay of the image seen by both eyes, or a halo surrounding this image is often interpreted as double vision. Thus at the beginning of the examination it must be established whether the images are truly separated. We let the patient draw what is seen or hold a vertical prism before one eye to demonstrate to the patient what true double vision is like. Once it can be confirmed that diplopia is real, placing a cover over either eye will determine whether it is *monocular* or *binocular* in character. In the former case any further search for a neuromuscular anomaly of the eyes can be suspended.

Monocular Diplopia

Monocular diplopia may occur in one or in both eyes and is usually caused by anomalies of the ocular media, in which case it will disappear readily when the patient looks through a pinhole. The most common cause, in our experience, is subtle changes in optical density of the anterior and posterior layers of the lens in certain cases of incipient cataracts, which can only be appreciated after pupillary dilation and with a narrow, oblique slit beam. Because of the different refractive indices of the lens layers in such eyes, a parallel

bundle of light is not refracted uniformly but at different angles so that two or more retinal points receive the same image (*polyopia*). Occasionally, monocular diplopia may be caused for optical reasons by anomalies of the tear film, the cornea, the vitreous, a dislodged pseudophakos, or ordinary refractive errors.⁴⁸ An unusual case of monocular diplopia caused by pressure of the upper lid on the cornea was reported by Kommerell.⁹⁵

Monocular diplopia of sensory origin occurs infrequently and will persist even when viewing through a pinhole. It is sometimes observed after brain trauma or a cerebrovascular accident, in which case the patient usually becomes aware of more than two images seen with one eye (*polyopia*). It may also occur during treatment of amblyopia or, transiently, in a deeply amblyopic patient after loss of the sound eye.

Binocular Diplopia

When diplopia is binocular, a red filter held before one eye will determine whether it is *uncrossed* (or homonymous), in which case an esotropia is present; *crossed* (or heteronymous), in which case the patient has exotropia; or vertical, in which case hypertropia or hypotropia is present; or torsional in the case of cyclotropia. If diplopia occurs after surgery, it must be determined whether it is in accordance with the postoperative deviation or *paradoxical* (crossed with esotropia or uncrossed with exotropia), in which case there is a persistence of the preoperative angle of anomaly (see p. 237).

If the diplopia is binocular, one must determine the frequency of its occurrence, whether it is constant or transient, and whether the distance between the images increases or decreases in different directions of gaze and with different head positions. Information on these points is helpful in making a presumptive diagnosis. Confusion between the two competing images often becomes the most disturbing problem for the patient. The decision which of the two visual objects to fixate is probably related to the attention value of each object. The diplopia pattern is the subjective correlate of the prism and cover test. When the sensory relationship between the eyes is normal, the relative position of the two images is a measure of the deviation. Application of the diplopia methods for determination of the amount of the deviation is described in Chapter 12.

Spontaneous diplopia, though always present in

adults with recently acquired extraocular muscle paralysis, is by no means the rule in all patients with neuromuscular anomalies of the eyes. In patients with congenital paralytic strabismus or comitant deviations, spontaneous diplopia is rare and usually the result of a spontaneous surgical change of the angle of strabismus that causes the image in the deviated eyes to fall outside of a previously established suppression scotoma. Other causes include a switch in fixation preference in strabismic patients who do not alternate spontaneously. This condition was defined as *fixation switch diplopia*.²⁶ Its pathogenesis can be sought in an asymmetry of the depth of the suppression scotomas in nonalternating strabismus; the potential for suppression is weaker in the habitually preferred eye. Therefore, the patient experiences diplopia when the usually deviated eye takes up fixation. This can happen in anisometropia, when fixation switches from an eye with incipient myopia to the less myopic or hypermetropic fellow eye.¹³⁰ Correction of the myopia will quickly resolve this problem. Even changes in the refractive correction of spectacles lenses can cause this phenomenon.⁹⁷

Another cause of sudden awareness of diplopia in strabismus of long standing is a change in the angle of anomaly or normalization of retinal correspondence after surgery or prolonged alternating occlusion.¹⁴⁶

An unusual and intriguing form of binocular diplopia occurs in the absence of manifest strabismus or a history of such and in association with *subretinal neovascular membranes*²⁸ or retinal wrinkling.²¹ Because of retinal traction the foveal photoreceptors become disarranged with respect to the retinal periphery. While peripheral fusion is maintained, such patients may experience metamorphopsia or diplopia with both eyes open. It has been suggested that this phenomenon is caused by an induced fixation disparity.¹⁵² Special diagnostic slides for the synoptophore have been developed for such patients to compare superimposition of foveal targets simultaneously with peripheral targets⁷⁷ and a partially occlusive Bangerter foil over the affected eye may give relief from diplopia.²⁸

Spontaneous diplopia has also been associated with *aniseikonia* from separation or compression of photoreceptors in patients with epiretinal membranes or vitreomacular traction. An incorrect diagnosis of central disruption of motor fusion (see Chapter 21) could be erroneously made in such cases.¹⁶

Binocular diplopia in the absence of strabismus

or a history of such that is eliminated by covering one eye may be caused by awareness of *physiologic diplopia* (see Chapter 2). In such cases we try to explain this phenomenon and to reassure the patient.

Binocular triplopia, a combination of monocular and binocular diplopia, is discussed on page 238.

Suppression

Diplopia is most repugnant, and persons so affected make every effort to avoid it. Wherever possible the images are brought together by motor fusion, even at the expense of muscular asthenopia. In some patients an abnormal head position is assumed in which the distance between the two images is minimized (see Chapter 12). When fusion is not possible and the patient is a child, suppression may develop to eliminate double vision. *Suppression may be defined as the active central inhibition of disparate and confusing images originating from the retina of the deviated eye.* Since there is no need to suppress when double vision is eliminated by closing one eye, suppression is strictly limited to binocular vision.

Mechanism and Seat

Binocular rivalry is basic to binocular vision (see Chapter 2), but disappears in patients with strabismus. Only images received by one eye can enter consciousness. Suppression may be alternating or strictly monocular, depending on the type of fixation used by the patient.

The mechanism and seat of rivalry and suppression in abnormal binocular vision have been extensively studied. Burian's concept that suppression is merely an exaggeration of the same process involved in blocking out certain parts of the image seen by each eye in binocular rivalry was challenged by Smith and coworkers.¹⁵¹ These authors found that binocular rivalry differentially attenuates chromatic mechanisms relative to luminance mechanisms. In contrast, strabismic subjects did not manifest wavelength-specific sensitivity loss. Smith and coworkers concluded that suppression and normal binocular rivalry are mediated by different neural processes, but conceded that rivalry may be an important phase in the development of strabismic suppression. It must be noted that the strabismic subjects examined by Smith and co-

workers also had mild degrees of amblyopia and it remains to be shown that the same findings can be obtained in suppression uncontaminated by a coexisting amblyopia, that is, in true alternators. More recent neurophysiologic work has substantiated Burian's original concept about the relationship between retinal rivalry and suppression by showing the similarity of interocular suppression in strabismic cats vs. normal cats that were presented with conflicting visual stimuli.¹⁴²⁻¹⁴⁴ Quite recently, this subject was analyzed again by Har-rad,⁷² who also considered binocular rivalry to be the basis for suppression. Another argument in favor of Burian's concept is the fact that the different time courses of suppression and rivalry can be eliminated. Artificial attenuation of the dominant eye in strabismic amblyopia produces time courses of suppression which are similar to those of normal observers.^{53, 147}

Bárány and Halldén¹⁵ demonstrated that in binocular rivalry the threshold of pupillomotor responses is higher during the suppression phase than when the eye is perceiving. These results were not confirmed by Lowe and Ogle,¹⁰⁴ but Brenner and coworkers²⁷ found the pupillomotor response to be greater when the fixating eye is stimulated than when the suppressed or amblyopic eye is stimulated. The difference in effect was small in binocular rivalry; it increased in magnitude as suppression and amblyopia deepened.

Responses of the visual cortex to photic stimuli (visual evoked responses, VERs) also have been recorded during retinal rivalry. Some authors^{37, 91, 99, 100, 163} found the amplitude to be reduced during the suppressed phase, but others^{47, 132} found no change.

Franceschetti and Burian⁵⁸ studied VERs in patients with alternating esotropia. In each instance they found that considerably larger amplitudes were present when the fixating eye was stimulated than when the nonfixating eye was stimulated. The effect reversed with alternation of fixation.

Differences in the VER recorded during rivalry and with suppression leave no doubt that cortical cells participate in the mechanism responsible for these phenomena. Blake and Lehmkuhle²² presented additional evidence for this view. They showed that a grating pattern presented to one eye of a patient who is capable of alternating suppression induces a visual aftereffect (contrast threshold elevation), even when the pattern is suppressed while being viewed by the patient. This finding seems to indicate that suppression occurs

within the visual system beyond the site of the aftereffect.

A reduction in pupillomotor sensitivity of the suppressed eye, if definitely established, however, might favor retinal involvement in suppression. A final answer to the question of the primary seat of the suppressive mechanism is not available at present, although most studies implicate the cortex. For example, van Balen¹⁵⁹ simultaneously recorded the electroretinogram (ERG) and the VER and found no reduction in the ERG, even when the amplitude of the VER was reduced.

Compared with the wealth of clinical, psychophysical, electrophysiologic, and even histologic information available on amblyopia it is disconcerting how little corresponding information has been collected on suppression. Most electrophysiologic and psychophysical evidence places the seat of suppression in the visual cortex. This view is supported by the findings of Sengspiel and coworkers¹⁴⁴ who recorded from cortical neurons in cats with alternating eso- and exotropia and showed that there is only minimal excitatory input from the suppressed eye. These authors suggested that suppression may depend on inhibitory interactions between neighboring ocular dominance columns. Horton et al.⁸² recently reported results obtained by metabolic mapping of suppression scotomas in the striate cortex of adult macaques that underwent a free tenotomy of both medial rectus muscles and developed an exotropia with strong fixation preference for one eye. Autoradiographic labeling of the ocular dominance columns in the striate cortex and cytochrome oxidase processing for assessment of local metabolic activity showed such activity to be reduced in the deviated eye's monocular dominance columns and in the binocular border strips. In two animals with a weak fixation preference, resembling alternating fixation, anomalous staining was present within the central visual field representation in both hemispheres. According to the authors, this is the first experimental demonstration of structural and metabolic anomalies in association with suppression in the striate cortex of primates. However, the authors did not test for suppression psychophysically or electrophysiologically so that the presence of suppression in these adult monkeys is only inferred. Whether these findings are directly applicable to suppression in humans remains to be seen because the ability to develop suppression in humans is limited to childhood and because suppression rarely occurs in paralytic, incomitant

strabismus where diplopia is avoided by an anomalous head posture.

Crewther and Crewther⁴⁹ had shown earlier in strabismic cats that active suppression of the response to monocular stimulation of the deviated eye occurs when the fixating eye is simultaneously stimulated. While these data support what can be observed in patients with strabismus, it is still not clear by what process the visual system manages so effectively and within milliseconds to switch on and off selected information that reaches the cortex from the retina of either eye.

Clinical Features

In strabismus one eye is not excluded entirely from vision in spite of the presence of suppression. Most patients have some binocular cooperation, ranging from rudimentary to remarkably high forms of binocularity. Only in rare cases, particularly in exotropic patients with alternation, are there two seemingly quite independent visual systems with suppression of essentially the whole of one retina. In all other patients, *suppression is regional*.

To avoid confusion and diplopia, suppression must occur in the fovea of the deviated eye and that region in the periphery of the deviated eye on which the object of attention is imaged (fixation point scotoma⁷⁰). Using some form of binocular perimetry, it can be shown that in the deviated eye there are two *functional scotomas* corresponding to these areas^{70, 106} (Fig. 13-3). The greater the deviation, the larger the extent of the second peripheral scotoma. In some instances of very deep suppression, the two scotomas may fuse into one. These scotomas are less frequently found when the testing conditions resemble those present under casual conditions of seeing.^{19, 32, 77} Indeed, it has been suggested that they are artifacts, caused by binocular rivalry.^{94, 110} The fixation point scotoma found so frequently in microtropia with the Bagolini striated glass test¹² (see Fig. 13-15C) is certainly not an artifact. Interestingly, the fovea of the deviated eye is not always suppressed in small angle strabismus, even in the presence of moderate amblyopia. There may be a range of different manifestations of suppression: (1) antidiplopic and anticonfusion suppression scotomas and (2) only antidiplopic suppression scotoma (fixation point scotoma).

In strabismic patients who strongly prefer one eye for fixation, scotomas are always found in the

Right esotropia
Suppression scotomas
 corresponding to image of fixation point
 and foveal area in deviated eye

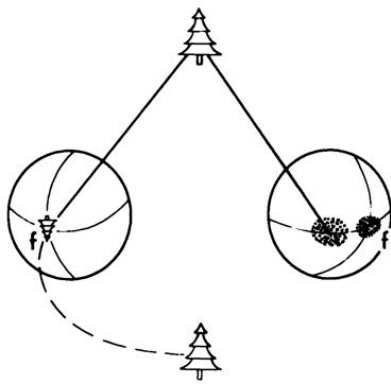


FIGURE 13-3. Peripheral fixation point and central suppression scotomas in deviated eye. (Modified from Burian HM: Adaptive mechanisms. *Trans Am Acad Ophthalmol Otolaryngol* 57:131, 1953.)

fellow eye. In those patients who can be made to fixate with either eye and in those who alternate freely, scotomas are found alternately in the right eye or the left, depending on fixation (Fig. 13-4). Steinbach¹⁵³ determined that it takes less than 80 ms to switch fixation and suppression from one eye to the other in alternating exotropes.

Suppression scotomas are not limited to the deviated eye. They can also be found in the fixating eye near the fovea¹⁵⁷ or in the periphery¹⁴⁶ during stimulation of the fovea of the deviated eye. Suppressed areas in the field of vision of one

eye may be complemented by a nonsuppressed portion from the field of vision of the other eye.

As with other types of sensorial adaptations, such as amblyopia and anomalous retinal correspondence (ARC), the ability to suppress is limited to the immature visual system, that is, it develops only in children. Although no comparative studies exist, it is our clinical impression that the *sensitive period* during which suppression may develop ends after the age of 8 or 9 years; thus it is similar to the sensitive period for amblyopia. However, once developed, suppression may persist throughout life. If a patient loses the ability to suppress during adulthood through head trauma, ill-advised orthoptic treatment, or surgical or spontaneous change of the angle of strabismus, it can never be regained and double vision prevails.

Tests for Suppression

Binocular Perimetry and Haploscopy

Binocular perimetry can be done with any type of haploscopic device that allows scanning of the retinas. For the clinician, the simplest means is the use of one form of color differentiation, such as red-green spectacles. If the left eye, provided with a green filter, fixates a green spot and the right eye is provided with a red filter, a projected red light will be seen everywhere by the right eye except in the region of the scotomas. To test the left eye, reverse the filters before the eyes. One may also use the system, introduced by Travers,¹⁵⁷

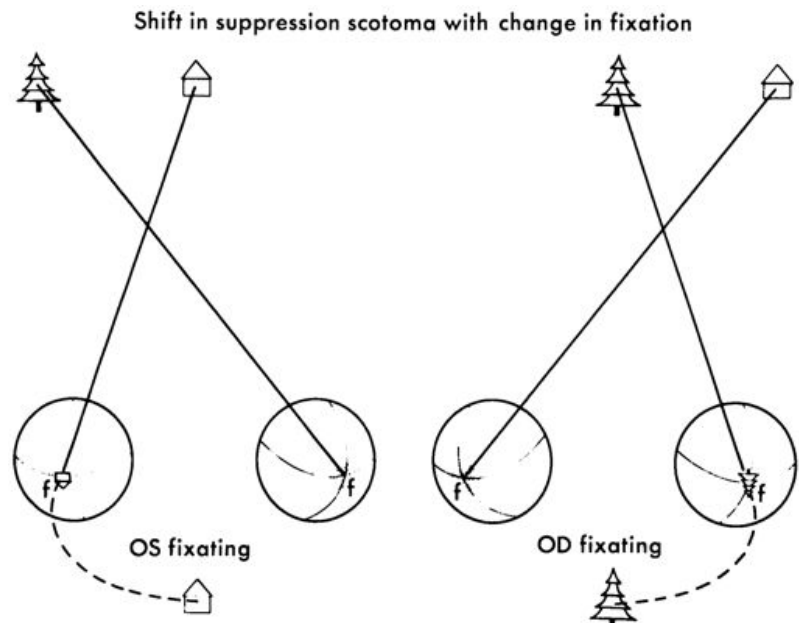


FIGURE 13-4. Alternating foveal suppression. (From Burian HM: Adaptive mechanisms. *Trans Am Acad Ophthalmol Otolaryngol* 57:131, 1953.)

consisting of two tangent screens at right angles to each other. The patient faces the screen in front of him or her, the middle of which the patient fixates, say, with the left eye. The second screen is to the right. Before the right eye is a mirror so adjusted that it offsets the deviation. The center of the second screen is then imaged on the fovea. While the patient fixates with the left eye, perimeter targets are presented to the right eye and the scotomas are mapped out (Fig. 13-5).

When one interprets the results of clinical research on suppression, it is important to know the testing conditions under which such data were obtained. For instance, dissociation of the eyes by the use of red-green spectacles introduces conditions different from those that prevail when the eyes are used under casual conditions. Polaroid dissociation or dissociation with the phase difference haploscope of Aulhorn³ (see Chapter 4) produces more natural conditions of seeing. Using Polaroid methods, Pratt-Johnson and MacDonald¹²⁸ (see also Herzau⁷⁷) showed that suppression does not exclusively involve the nasal retina in esotropes and the temporal retina in exotropes but extends nasalward and templeward from the fixation point, regardless of the direction of the deviation.

Similar findings were reported by Campos,³⁸ who used the mirror-screen technique of Travers (see Fig. 13-5) and found that the suppression scotoma in large angle exotropia often overrides the vertical retinal meridian to extend into the nasal retina. In contrast, the same author, by using

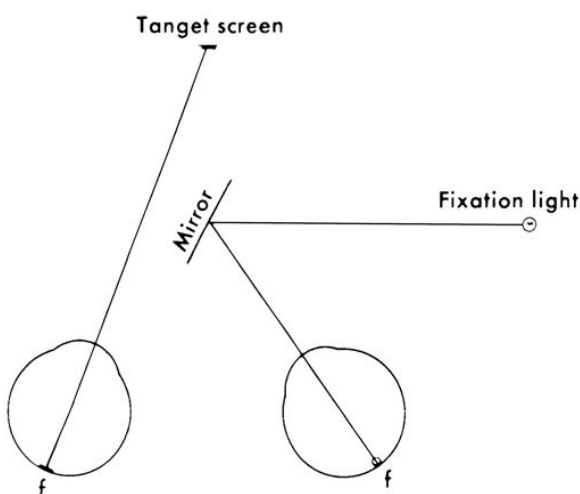


FIGURE 13-5. Screen and mirror arrangement of Travers for the mapping of suppression scotomas in strabismus. (From Burian HM: Adaptive mechanisms. *Trans Am Acad Ophthalmol Otolaryngol* 57:131, 1953.)

a modified von Graefe's technique for binocular visual field examinations, found a hemianopic scotoma with a dense red filter before the fixating eye (see Fig. 17-2). Thus it appears that the concept of "hemiretinal suppression"⁸⁶ according to which only the temporal retina is suppressed in alternating exotropia, can no longer be upheld when less dissociating tests are being used.

When orthoptic instruments are available, the haploscopic arrangement is provided by a major amblyoscope with which the suppression scotoma can be mapped, at least in the horizontal meridian. One arm is rotated, and the points are noted at which the target carried by the moving arm disappears and reappears.

Prisms

In clinical practice, by using prisms one can estimate in a simple way the extent of a suppression scotoma. The patient may not see double either spontaneously or with the addition of a red glass placed in front of one eye. By placing prisms of increasing strength in front of the eye, one will soon find a prism with which the patient reports diplopia. The image of the fixation point, preferably a small light source, is now thrown out of the region of the suppression scotoma onto a retinal area that is not habitually suppressed. The power and direction of the base of the prisms required to produce diplopia is a measure of the extent of the suppression scotoma (Fig. 13-6).

The Four-Prism Diopter Base-Out Prism Test

The four-prism diopter base-out prism test is of some value in determining whether a patient has bifoveal (sensory) fusion or a small suppression scotoma under binocular conditions or to assess the quality of binocular vision in postoperative orthotropes. This test was introduced by Irvine⁸⁴ and popularized by Jampolsky⁸⁷ and is illustrated in Figure 13-7.¹¹⁶ A four-prism diopter base-out prism is held before one eye while the patient fixates on a penlight and the observer notes the presence or absence of a biphasic movement of the fellow eye (Fig. 13-7A,B). Several atypical responses to this test have become known, which limits its value as an objective screening device for the presence of foveal suppression.^{56, 59, 133, 137} This is especially so in microtropias where the prism held before the minimally deviated eye may

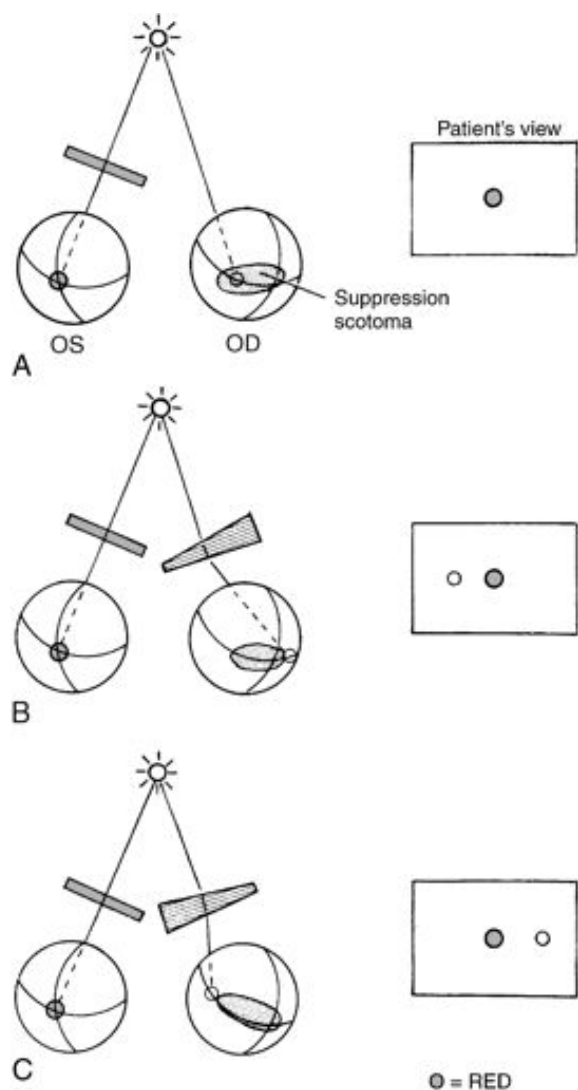


FIGURE 13-6. Measuring the size of a suppression scotoma. *A*, Right esotropia causes the image of the visual object fixated by the left eye (OS) to fall on nasal retinal elements of the deviated right eye (OD). Suppression eliminates diplopia. *B*, Base-out prisms before OD are increased until crossed diplopia occurs; the temporal border of the scotoma has been defined. *C*, Base-in prisms before OD are increased until uncrossed diplopia occurs; the nasal border of the scotoma has been defined. The total prismatic power required to move the image from the temporal to the nasal border of the scotoma indicates the horizontal diameter of the scotoma. The vertical extent of the suppression scotoma can be determined in a similar fashion. (From Noorden GK von: *Atlas of Strabismus*, ed 4. St Louis, Mosby-Year Book, 1983.)

merely shift the retinal image within an area of abnormal binocular vision, maintained by abnormal retinal correspondence. The patient will experience single binocular vision in spite of the shifted retinal image and without a corrective eye movement.¹³ However, a biphasic movement response of either eye (see Fig. 13-7*B*) in an orthotropic patient after placing the prism before the fellow eye usually indicates bifoveal fusion, al-

though atypical responses may occur even in this condition.¹³⁸

A foveal (central) suppression scotoma in orthotropic patients or a fixation point scotoma in microtropes can also be detected with the striated glasses test of Bagolini (p. 228). In the former the patient will see a central interruption of the light streak at the crossing point. In the latter the interruption will be off center in one streak. A Polaroid test has been recently introduced for testing rapidly and reliably the presence of a central suppression scotoma.¹²¹ Yet, in the fixation area the stimulus is presented only to one eye at a time, thus favoring retinal rivalry and hence suppression. Moreover, the position of the eyes is crucial as with all tests based on the use of polarized filters.

Monocular Visual Acuity Measured Under Binocular Conditions

A more effective test for foveal suppression in microtropias or in patients with subnormal binocular vision after surgical correction of essential infantile esotropia (see Chapter 16) is to measure the visual acuity of each eye under binocular conditions with the Project-O-Chart slide of American Optical.¹³⁷ A decrease of visual acuity of one eye that is not present when the eye is tested under monocular conditions will readily indicate foveal suppression.

The Worth Four-Dot Test

Suppression involving the peripheral retina can also be diagnosed with the widely used Worth four-dot test (Fig. 13-8). In our opinion this test is only of limited value and therefore is rarely used in our clinic. Among its disadvantages is that the eyes are easily dissociated with red-green spectacles. Thus a patient with unstable but functionally useful binocular vision may exhibit a suppression response when the Worth four-dot test is used. Another disadvantage is that the presence or absence of bifoveal fusion cannot be assessed. A fusion response (the patient sees all four dots in a rectangular arrangement) may occur in the presence of heterotropia with ARC and may be misinterpreted, as is frequently done in the literature, as evidence of normal binocular vision. It is all too often neglected that this test becomes meaningful only when used in conjunction with the cover test.¹¹⁸

Arthur and Cake² proposed a modification of

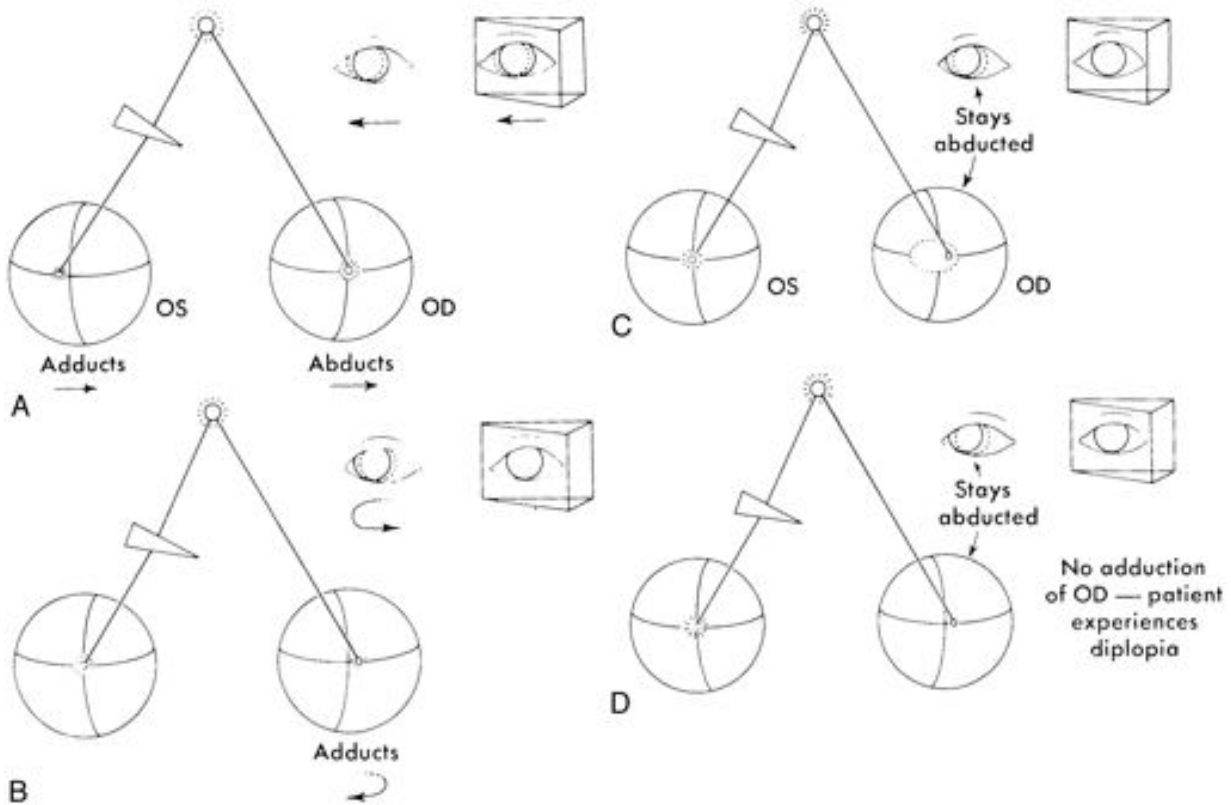


FIGURE 13-7. The four-prism diopter base-out prism test. *A*, When a prism is placed over the left eye, dextroversion occurs during refixation of that eye, indicating absence of foveal suppression in the left eye. If a suppression scotoma is present in the left eye, there will be no movement of either eye when placing the prism before the left eye. *B*, A subsequent slow fusional adduction movement of the right eye is observed, indicating absence of foveal suppression in the right eye. *C*, In a second patient the right eye stays abducted, and the absence of an adduction movement (*B*) indicates foveal suppression in the right eye or anomalous retinal correspondence. *D*, Another cause for absence of the adduction movement is weak fusion, and such patients will experience diplopia until refusion occurs spontaneously. (From Noorden GK von: Present status of sensory testing in strabismus. In Symposium on Strabismus: Transactions of the New Orleans Academy of Ophthalmology. St Louis, Mosby-Year Book, 1978, p 51.)

the Worth four-dot test, in which the differentiation of the stimuli for the two eyes is obtained with Polaroid filters rather than with red-green glasses. This test is less dissociating than the original Worth four-dot test, where red and green induce retinal rivalry even in normals. Yet, the comparison proposed by the authors of their test with the Bagolini striated glasses test seems unwarranted. Contrary to the striated glasses test, the polarized four-dot test does not present the patient with a fusible stimulus in the fixation area. Hence the higher percentage of central suppression detected with this test.

The reader should be aware that all information derived from the current or past literature about the presence, location, and depth of retinal suppression scotomas is tainted by our inability to create testing conditions that are identical to casual conditions of seeing. Image separation with

red-green spectacles, polarizing filters, a screen-and-mirror arrangement, and even the phase difference haploscope or Bagolini striated glasses create conditions that are not entirely identical to those in casual seeing. Numerous studies in recent years have shown great variability, and contradictory results can be expected under different testing conditions.^{13, 38, 77, 93, 94, 137}

Suppressing Versus Ignoring a Double Image

The absence of spontaneous diplopia in a patient with a manifest ocular deviation does not always imply that suppression has developed. The patient may have developed ARC (see p. 222). Other patients, especially older children and adults who are no longer capable of developing suppression, simply learn to disregard the second image, espe-

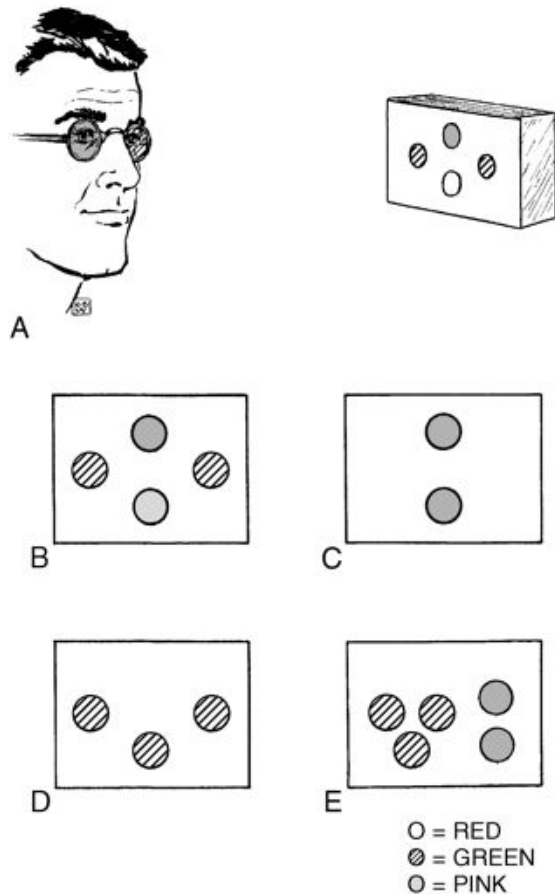


FIGURE 13-8. The Worth four-dot test. *A*, Looking through a pair of red and green goggles, the patient views a box with four lights (one red, two green, one white) at 6 m and at 33 cm (with the four lights mounted on a flashlight). The possible responses are given in *B* to *E*. *B*, Patient sees all four lights: peripheral fusion with orthophoria or esotropia with anomalous retinal correspondence. Depending on ocular dominance, the light in the 6-o'clock position is seen as white or pink. *C*, Patient sees two vertically displaced red lights: suppression OS. *D*, Patient sees three green lights: suppression OD. *E*, Patient sees five lights. The red lights may appear to the right, as in this figure (uncrossed diplopia with esotropia), or to the left of the green lights (crossed diplopia with exotropia). (From Noorden GK von: Atlas of Strabismus, ed 4. St Louis, Mosby-Year Book, 1983.)

cially when the deviation is large and the second image appears in the periphery of the field of vision. However, such patients easily can be made aware of double vision by placing a light-red filter before one eye. The ability to ignore a disturbing second image is an entirely different process from suppression. The first occurs on a *psychological level*, depends on the attention value of the image to be ignored, and, as mentioned in the discussion of physiologic diplopia (see Chapter 2), is part of normal binocular vision. The second is *active intrinsic inhibition of afferent visual information*. The distinction between suppression and ignoring

is of more than theoretical interest since the absence of spontaneous diplopia may mislead the ophthalmologist to assume that the strabismus problem has been present since early childhood, when in fact the deviation may be of relatively recent onset, in which case a neuro-ophthalmologic evaluation may be required. Wright and co-workers¹⁶³ found reduced pattern visual evoked potentials (VEPs) in adults with acquired strabismus and absence of diplopia and concluded from these findings that cortical suppression had developed in these patients. Unless it is also known what, if any, effect the channeling of attention from the images seen by one eye to those seen by the other eye has on the VEPs, this conclusion is not warranted.

Measurement of Depth of Suppression

Suppression is not equally deep in all patients. In some it may be readily overcome; in others it is difficult to do so. It is useful and easy to establish how deep the suppression is in a patient.

To make a patient aware of the images perceived by the deviated eye, one must reduce the retinal illuminance of the fixating eye until the patient sees double. This is best done with a series of red filters of increasing density arranged in the form of a ladder (Fig. 13-9). Such a ladder may consist of gelatin filters, beginning with one layer and increasing to six or eight layers. The more layers, the darker the filter. The patient fixates a small light source, and the filters are placed in front of the fixating eye. Some patients see double with a single layer; others require three or more layers before they recognize diplopia. The greater the number of layers needed, the deeper the suppression.^{5, 113}

Laboratory experiments have produced data that seem to contradict this common clinical finding. Holopigian's data⁸¹ show that the depth of suppression is constant, regardless of changes in contrast, luminance, and spatial frequency of the inducing stimulus (see also Freeman and Jolly⁶¹). The reason for the difference between a common and an easily observed clinical phenomenon and these data is not at once obvious and may be due to methodological variations.

Blind Spot Mechanism

Swan¹⁵⁵ described a mechanism by which some patients with 30^Δ to 40^Δ of esotropia make use of




FIGURE 13-9. Red filter ladder.⁵ (Courtesy of Prof. Bruno Bagolini, Rome.)

the blind spot to avoid diplopia. He later discovered the interesting fact that this possibility had been mentioned by George Adams, optician to His Royal Highness, the Prince of Wales, in 1792.

The patients reported by Swan¹⁵⁵ in his first description of this mechanism had accommodative esotropia with the following characteristics: (1) occasional diplopia and confusion of images, (2) esotropia of 12° to 18°, (3) blind spot of deviating eye consistently overlying the fixation area, (4) good vision of each eye, (5) normal correspondence, and (6) good fusional potential demonstrable on haploscopic devices. In a later publication, however, Swan¹⁵⁶ included a number of other groups of patients who also utilized the blind spot mechanism. These were patients with sensory abnormalities, amblyopia, anomalous correspondence, and suppression.

As pointed out by Olivier and von Noorden,¹²³ many physiologic and clinical considerations indicate that the use of the blind spot to avoid diplopia is no more than a *coincidence*. The small size of the optic disk and the constant change of the deviation with different fixation distances makes

the effectiveness of the use of the blind spot to elude diplopia improbable. Incessant slippage of the image from the blind spot to the adjacent retina would be unavoidable and cause intermittent diplopia with the need for continuous motor readjustment to avoid double vision. We are not aware of such occurrences. Moreover, there is no known physiologic mechanism, similar to a fixation reflex, by which a retinal image would remain locked onto the optic nerve head. Olivier and von Noorden¹²³ used the Bagolini glasses to examine patients with characteristics of the blind spot syndrome and found that the absence of diplopia in the patient group described by Swan can be explained by ARC. From these and other observations, the conclusion was reached that the blind spot syndrome does not exist.¹²³

Anomalous Correspondence

Basic Phenomenon and Mechanism

If one examines the visual field of a patient with heterotropia by placing a red filter in front of the habitually fixating eye while the patient is looking at a small light source, a number of different responses may be elicited (Fig. 13-10).

1. The patient may report that two lights are seen, a red one and a white one. In esotropia the images appear in homonymous (uncrossed) diplopia, with the red light to the right of the white one when the red filter is in front of the right eye (Fig. 13-10A). In exotropia the images appear in heteronymous (crossed) diplopia, with the red light to the left of the white light when the red filter is in front of the right eye (Fig. 13-10B). If one now measures the distance between the double images (e.g., on a Maddox cross), one may find that this distance equals the amount of the previously determined deviation. The response of this patient is normal because it is the same as the response expected from a normally acting sensory system in the presence of a deviation of the visual axes. The patient has *normal retinal correspondence* (NRC). The patient may report that only one pinkish light in the position of the white fixation light is seen; that is, the red and white images appear to be superimposed. This would be a normal response for someone whose eyes are

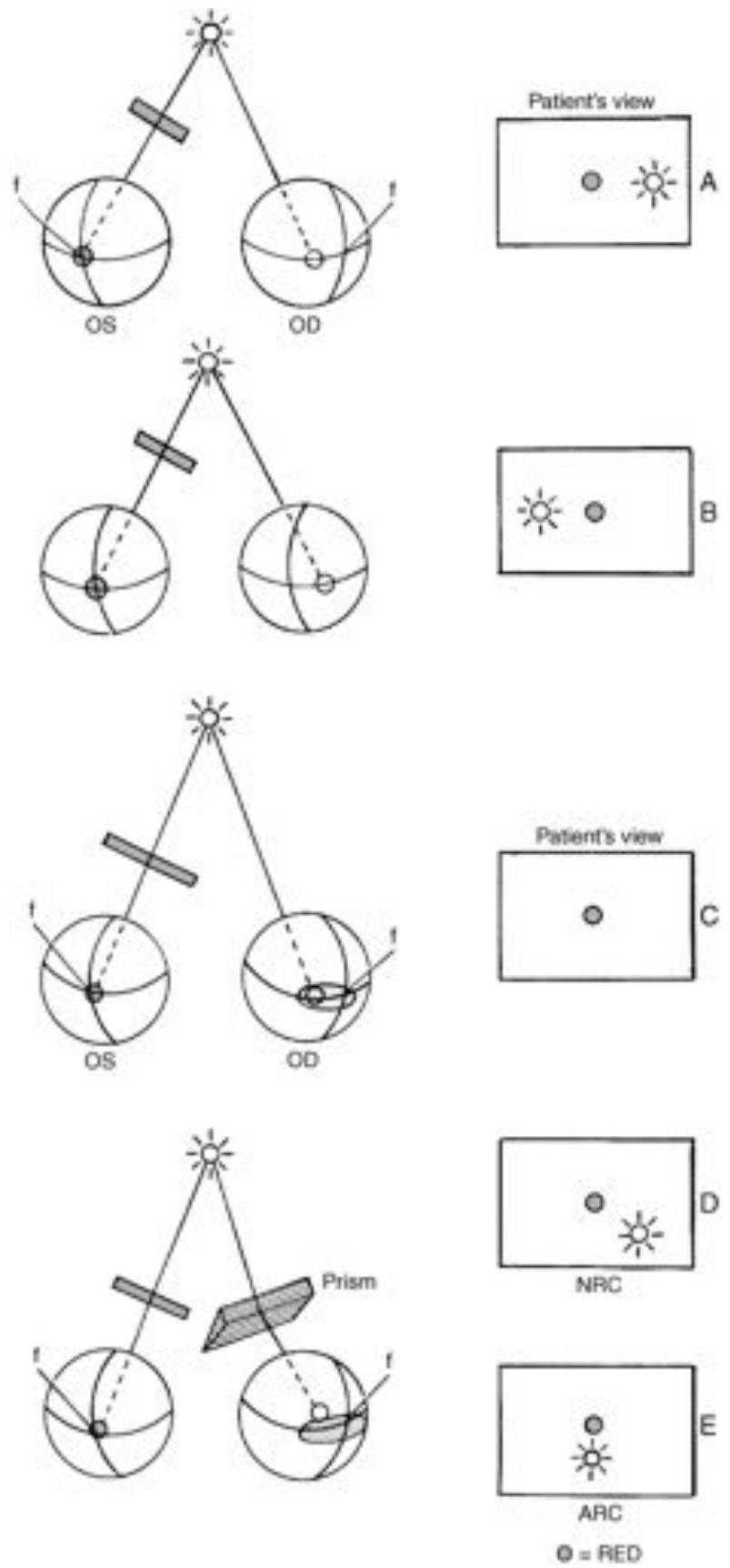


FIGURE 13-10. Red filter test for suppression and anomalous retinal correspondence. NRC, normal retinal correspondence; ARC, anomalous retinal correspondence. For explanation, see text. (From Noorden GK von: Atlas of Strabismus, ed 4. St Louis, Mosby-Year Book, 1983.)

straight. It is clearly an abnormal form of localization in the presence of a relative deviation of the visual axes, and the following two possibilities exist.

2. The patient suppresses the image originating from the deviated right eye (Fig. 13–10C). If under these circumstances a very dark-red filter is placed before the fixating eye, diplopia may still be elicited. The depth of suppression can be quantitated by increasing the density of the filter held before the fixating eye until the patient experiences diplopia.
3. The patient has ARC, that is, single binocular vision occurs in the presence of a manifest strabismus. To distinguish between suppression and ARC a vertical prism is placed base-up before the deviated right eye (Fig. 13–10D and E). In the case of suppression the prism will move the white image above the suppression scotoma and the patient will experience diplopia. The white image will be localized correctly, that is, below and to the right of the red image. When the white image appears directly below the red image it is localized incorrectly (Fig. 13–10E). This condition has been termed *anomalous correspondence*.

Consideration of the response in which the patient perceived both images but localized them abnormally shows that normal coupling of the

retinal elements of the two eyes is somehow broken up and has been replaced by a new coupling. This concept is indeed the classic explanation of the observed phenomena. Anomalous correspondence is thought of as a shift of the subjective visual directions of the nonfixating eye relative to those of the fixating eye, crudely symbolized in Figure 13–11.

Although anomalous correspondence is always considered to be associated with strabismus or with a history of such, it has been shown recently that it can occur or be induced in normal subjects under binocular stress.⁵⁷ Binocular stress can be produced by forced convergence, which is the introduction of a change in the convergence stimulus without a coordinated change in the accommodative stimulus. A fixation disparity takes place that causes a distortion of the nonius horopter (a “dimple” is found). It is not clear at this time whether these findings are of potential clinical relevance.

When one eye is constantly deviated, the existing stimulus situation produces suppression scotomas in that eye. The normal relationship between the two foveae is then loosened, and the visual directions of the nonfixating eye shift. As a result, the fovea of the fixating eye acquires an anomalous common visual direction with a peripheral area of the nonfixating eye. This shift also implies that the two foveae no longer have a common visual direction. Anomalous correspon-

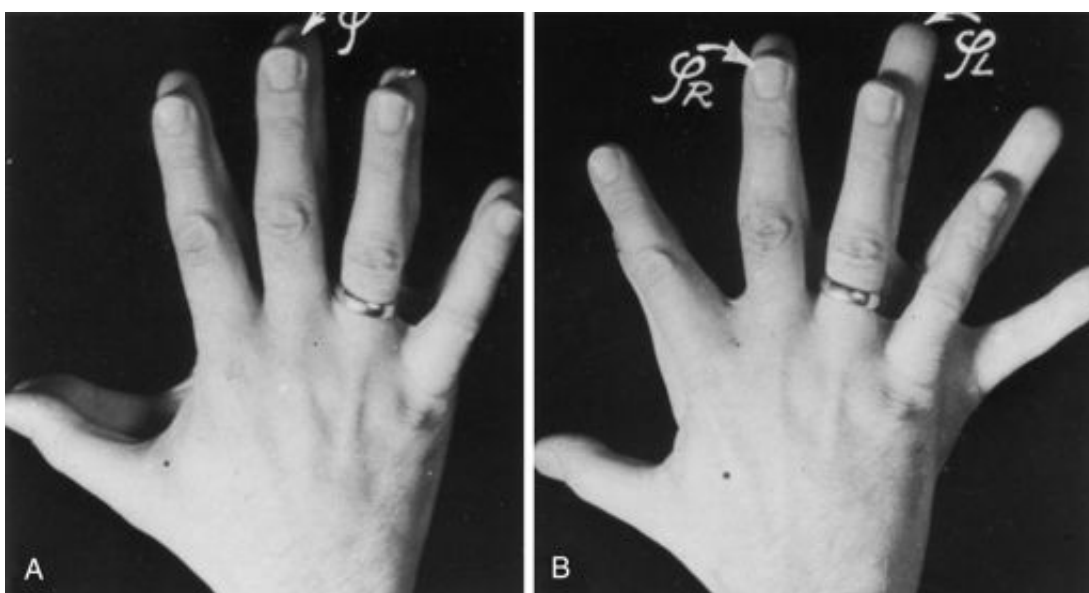


FIGURE 13–11. Anomalous correspondence. *A*, The two hands are placed together so the fingers match, with the middle fingers representing the normal common foveal subjective visual direction. *B*, The fingers of the right hand are shifted so they no longer match, and two different foveal visual directions are symbolized.

dence therefore can be defined in two ways. *One may say either that in this condition the two foveae have two different visual directions or that the fovea of the fixating eye has acquired an anomalous common visual direction with a peripheral element in the deviated eye.* Both these descriptions are important, since all tests for anomalous correspondence are based on one or the other.

Anomalous correspondence presumably adapts the sensory visual system to the abnormal motor condition created by the deviation in an effort to restore some semblance of binocular cooperation. If the fovea of the fixating eye acquires a common visual direction with the area in the retina of the deviated eye on which the fixation point is imaged, the deviation is fully neutralized sensorially, that is, the shift in visual directions has fully offset the amount of the deviation. In this situation the sensory adaptation is most successful, and one speaks of *harmonious anomalous correspondence* when both images in the red filter test coincide. If the amount of the shift in visual directions does not fully compensate for the deviation, the adaptation is not complete and one speaks of *unharmonious anomalous correspondence*.

Tests

All tests for determination of the status of the sensory relationship of the two retinas are necessarily subjective. Most clinicians have preferences for one or another test, and it is not necessary to perform all tests in each patient. However, it is necessary to understand the principle underlying the most commonly used procedures. Basically all tests belong to one of two groups—diplopia-type and haploscopic-type tests. The most commonly performed tests for retinal correspondence are the afterimage test, the Bagolini striated glasses test, and the determination of the angle of anomaly on the major amblyoscope.

Afterimage Test

Hering⁷⁵ found convincing proof for the unity of the binocular field in the following simple experiment. A small, lasting afterimage is produced in the left eye, and the eye is then closed. In the open right eye the afterimage appears in the field of vision and shifts with the movements of the eyes, just as if the left eye were open. Afterimages produced successively on the foveae of the two eyes will appear in their common visual direction,

regardless of whether the eyes are open or closed and regardless of the position of the eyes relative to each other. Afterimages therefore appear to be an ideal means of studying the sensory relationships of the retinas. Bielschowsky¹⁹ applied this test on a large scale to the examination of patients, and the afterimage test has become one of the most widely used tests for retinal correspondence.

In clinical practice the test is performed by using a battery-powered camera flash (Fig. 13–12) to produce a vertical afterimage in one eye and a horizontal afterimage in the other eye. The reflecting surface is covered with black paper to expose a narrow slit, the center of which is covered with tape and serves as a fixation mark, thus protecting the fovea from exposure. The resulting afterimage is that of a line with a break in its middle, which represents the fovea. The patient is required to fixate steadily the central mark, first with one eye while the slit is in a horizontal position (Fig. 13–13A), and then with the other eye while the slit is in a vertical position (Fig. 13–13B). The nonexposed eye must be well covered. During the exposure, a strong stimulus reaches the principal horizontal and vertical meridians of the right and left eyes *but in neither eye is the foveal area stimulated*. In a darkened room or with the eyes closed, the patient now sees the two successively imprinted afterimages simultaneously as positive afterimages (bright lines). In a lighted room or with the eyes open, negative afterimages (dark lines) will be seen. The region of the fovea will appear as a gap in each line.



FIGURE 13–12. Camera flash attachment for afterimage test.

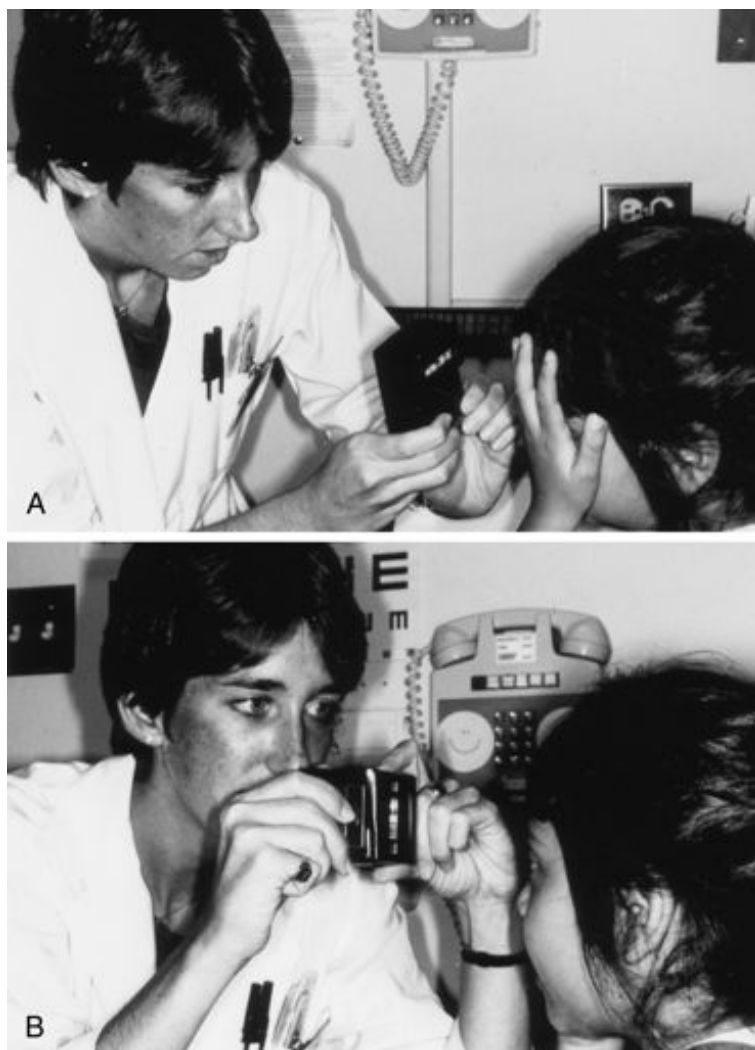

FIGURE 13-13. Afterimage test. For explanation, see text.

These gaps will be seen in the same direction, that is, superimposed, if the foveae have the same visual direction. Consequently, the two afterimages will be seen in the form of a cross with a single hole in the center (Fig. 13-14A), which indicates that correspondence is normal.

If the vertical afterimage with its central hole appears to the left or to the right of the hole in the horizontal afterimage, this displacement implies that the two foveae have different visual directions, that is, there is anomalous correspondence (Fig. 13-14B and C).

The test can be performed in normally developed children as young as 4 years of age. During the exposure, the examiner must observe patients closely and those with wandering or *eccentric fixation* (see Chapter 14) must be excluded from the test. This is because the localization of the afterimage created in an eccentrically fixating eye no longer corresponds to the principal visual direction but to a secondary one. If the test is applied

to such patients for special purposes, the position of the stimulating light on the retina of the deviated eye relative to the fovea must be taken into account in evaluating the test result. For instance, if there is identity between the angle of anomaly and the degree of eccentricity, localization of the afterimages in the form of a cross may then indicate NRC rather than ARC! Suppression of the poorer eye or alternating fixation at times may interfere greatly with visualization of both afterimages. To minimize these difficulties, it is advisable to use certain precautions. The fixating eye should always be exposed first to the flash placed in a horizontal position. The habitually deviated eye is then exposed to the vertical flash. Always producing the vertical afterimage in the habitually deviated eye will ensure uniform data that show at a glance the state of the retinal correspondence.

Of greatest importance for understanding the afterimage test is the realization that once the afterimages have been imprinted, their relation

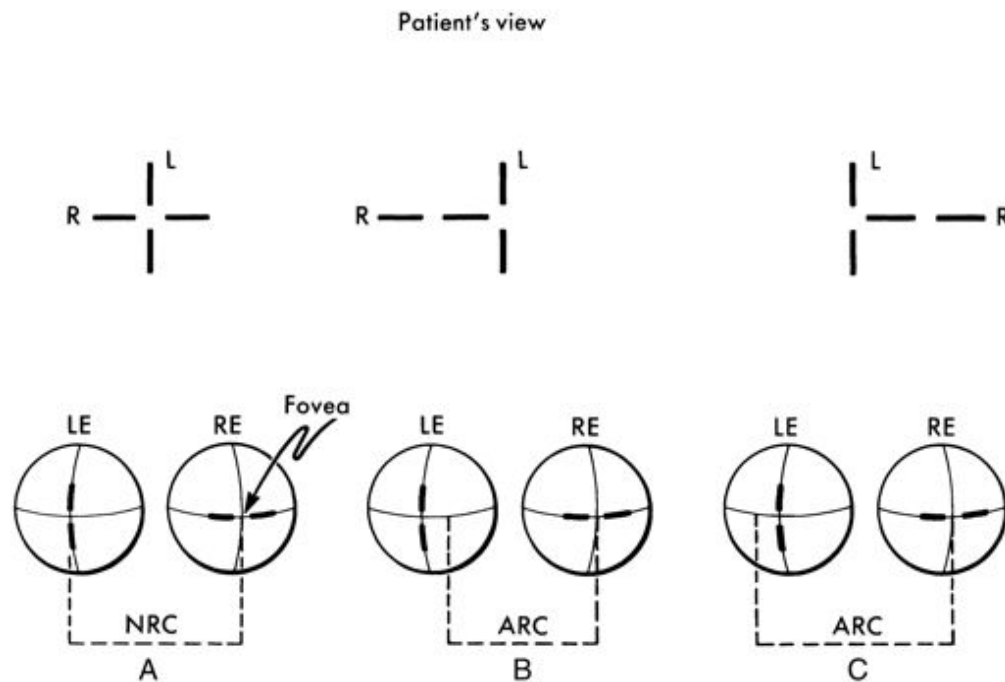


FIGURE 13-14. Afterimage test. *A*, Normal localization (*cross*) in normal correspondence (NRC). *B*, Anomalous crossed localization (ARC) in a case of esotropia. *C*, Anomalous uncrossed localization in a case of exotropia.

remains unchanged, regardless of any later changes in the position of the eyes. This is one great advantage the afterimage test has over all other tests for retinal correspondence. In other tests, changes in the position of the eyes will cause a shift of the images on the retina and therefore a change in the stimulus situation. No change in the stimulus situation can occur as a result of eye movements once the afterimages have been produced. This point cannot be emphasized strongly enough. To prove it, the reader need only produce an afterimage in each eye and then move the eyes in any direction of gaze, converge voluntarily, or gently push one eye with a finger to one side. No change in the relative position of the afterimages will take place.

In some clinical situations it may appear as if a change in the position of the eyes had indeed caused a change in the relative position of the afterimages. For example, a patient with intermittent exotropia may report that afterimages in the form of a cross are seen when the eyes are aligned but that they are separated when the patient allows one eye to deviate. This phenomenon can be observed frequently in patients with this condition and has been used to support the notion that extra-retinal signals from proprioception sensors in the extraocular muscle influence the relative position of the afterimages.¹²⁹ However, this change is not

a result of the movement or the divergent position of the eyes but of a change from normal to anomalous correspondence.¹⁵⁸

Striated Glasses Test of Bagolini

All tests for retinal correspondence introduce an artificial situation that may affect the test result to a greater or lesser degree. To minimize the influence of the testing procedure, Bagolini⁶ devised a test that permits an evaluation of the sensory retinal relationship under conditions that come as close as possible to natural conditions of seeing.

The striated glasses are plano glasses without refractive power that do not modify the state of accommodation. They have fine parallel linear striations that do not alter significantly the visual acuity and the perception of the visual space. The patient fixates a small light, at the reading distance or at the end of the examination lane, through the striated glasses placed before each eye in a trial frame. The glasses are usually placed at 45° and 135°. Optical correction should be worn during the test. Through each striated glass the fixation light is perceived as crossed by an elongated streak across one meridian. The light source is a fusible stimulus, equal for each eye. The striations are check marks and allow differentiation of a single perception of the light due to suppression

(one streak) from binocular perception in normals or patients with ARC (two streaks crossed in the center) or from diplopia (two streaks separate from each other or crossing in the peripheral part of the streaks).

Figure 13–15 shows the appearance of the streaks as they may be seen by a patient and the interpretation of this test.

The striated glasses may also be used in conjunction with the red filter bar of Bagolini (see Fig. 13–9), for evaluating the strength of the normal binocularity or of the binocular sensorial adaptation.¹² In this way it is possible to establish the amount of dissociation necessary for disrupting

binocular cooperation (normal or anomalous) and to know which image belongs to which eye.

The usefulness of the Bagolini striated glasses for measuring cyclotropia under nearly normal conditions of seeing is discussed in Chapter 12 and yet another application for their use during monocular and binocular investigation of the visual field has been recently proposed.⁸⁰

Testing With the Major Amblyoscope

This test is illustrated in Figure 13–16. Both arms of the instrument area are moved by the examiner while alternately flashing the light behind each

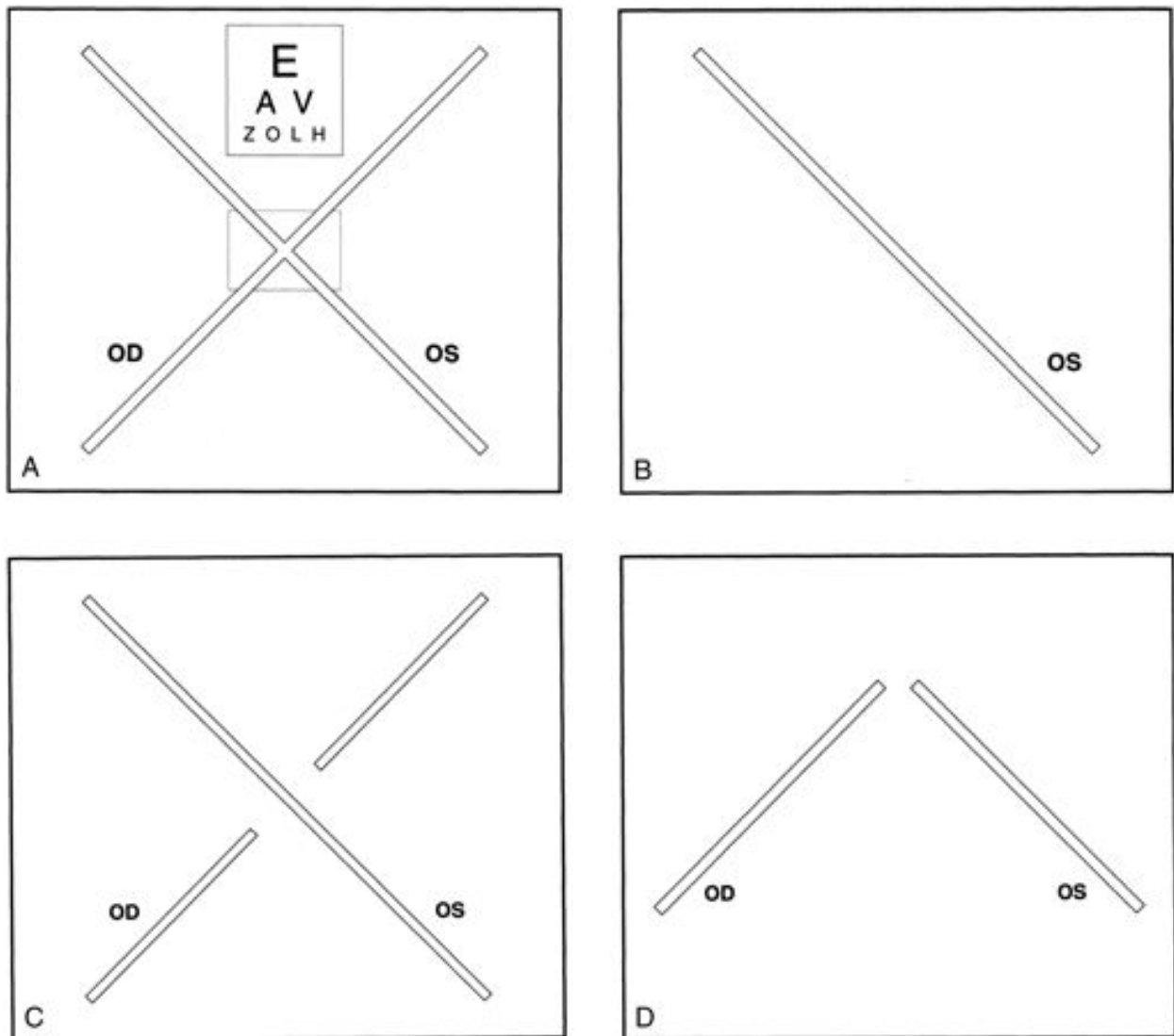


FIGURE 13–15. Use of striated glasses to test for suppression and anomalous retinal correspondence (ARC). *A*, Crossing of the luminous lines when a manifest ocular deviation (cover test) is present indicates ARC. *B*, Suppression of the right eye. *C*, Fixation point scotoma (with manifest deviation and ARC) or foveal scotoma (with orthophoria and normal retinal correspondence) of the right eye. *D*, Double vision with esotropia.

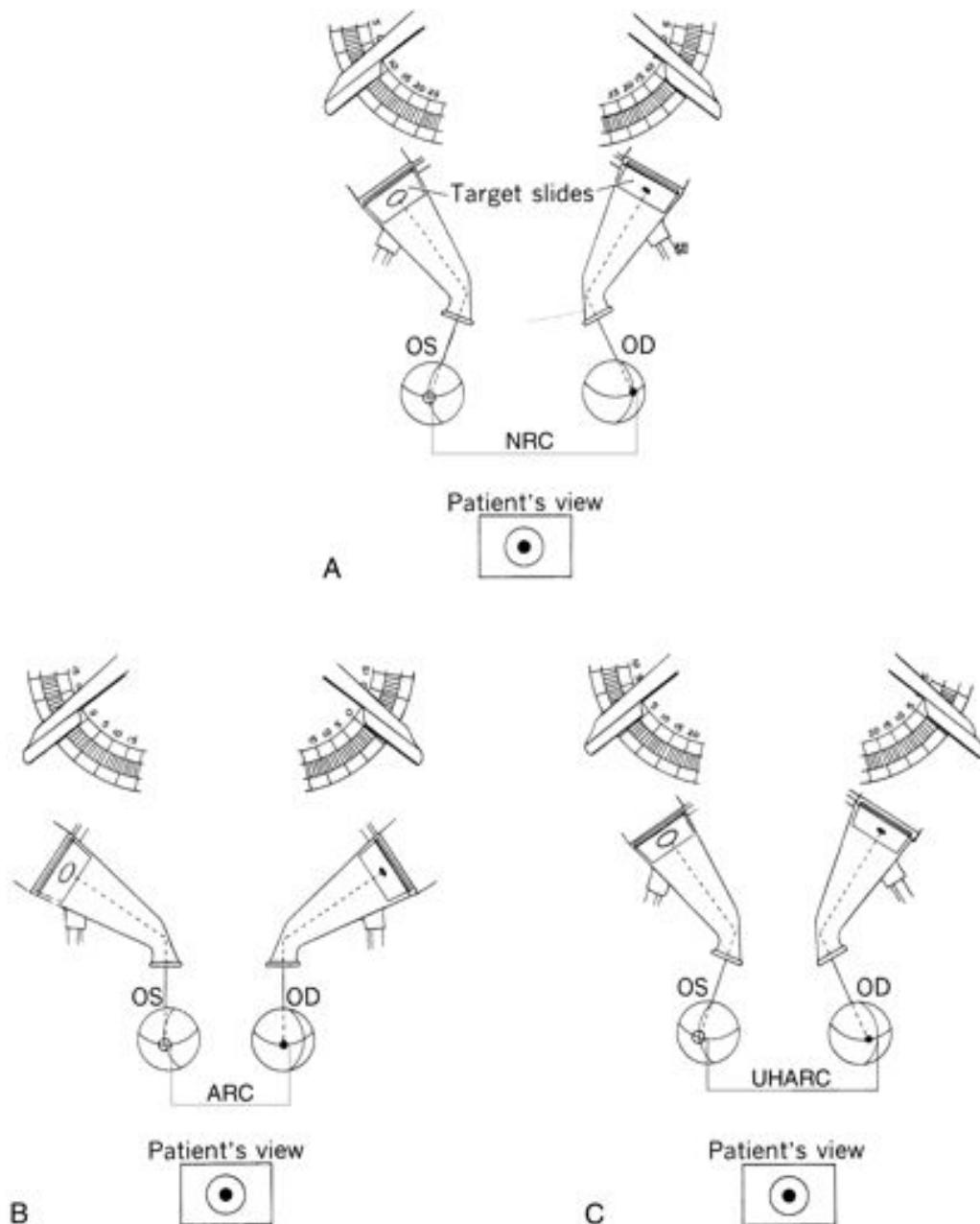


FIGURE 13-16. A–C, Testing with the major amblyoscope for retinal correspondence. NRC, Normal retinal correspondence; UHARC, unharmonious retinal correspondence. For explanation, see text. (From Noorden GK von: *Atlas of Strabismus*, ed 4. St Louis, Mosby-Year Book, 1983.)

slide until there is no further fixation movement of the patient's eye. The angle of strabismus (20^{Δ} in Fig. 13-16A) determined in this manner is called the objective angle. The arms of the major amblyoscope are now placed so that the targets are imaged on the two foveae of the patient's eyes. If normal correspondence exists, the images of two dissimilar targets appear to be superimposed. In the presence of anomalous correspondence and if the patient is esotropic, there will be crossed diplopia; if the patient is exotropic, uncrossed diplopia will occur.

To determine the degree of shift in visual directions (the so-called angle of anomaly), proceed in the following manner: Both arms of the instrument are moved by the examiner while alternately flashing the light behind each slide until there is no further fixation movement of the patient's eye (alternate cover test; Fig. 13-16A). Each arm of the instrument is now set at 10^{Δ} ET (esotropia); this patient has an ET of 20^{Δ} . The angle of strabismus determined in this manner is called the objective angle. If the patient sees the visual targets superimposed when the instrument is in this posi-

tion, his *subjective angle* equals the *objective angle*; NRC is present. When the patient reports that the targets are separated with the instrument set at the objective angle, ARC is present. The patient's foveae no longer have a common visual direction (paradoxical diplopia, p. 237). When the patient reports superimposition of the visual targets with the instrument arms set at zero (Fig. 13–16B), the subjective angle is zero and retinal correspondence is abnormal. In this case, the *angle of anomaly* equals the objective angle and the sensory adaptation is complete; anomalous correspondence is said to be harmonious. When the angle of anomaly is smaller than the objective angle (Fig. 13–16C), *unharmonious* retinal correspondence is present. In this drawing, a patient with 20^Δ ET reports superimposition with the arms of the instrument set at 10^Δ ET. The sensory adaptation is incomplete; the subjective angle is smaller (10^Δ ET) than the objective angle (20^Δ ET) but larger than zero. In most instances, unharmonious retinal correspondence can be explained on the basis of a secondary enlargement of the objective angle. Some authors have suspected that this finding is an instrument artifact.^{22, 25}

The determination of retinal correspondence with a major amblyoscope may be difficult because of suppression and changes in the mode of localization. Experience and skill in overcoming these difficulties and the ability to interpret patient responses correctly are required to obtain useful information by this method. The following tests must be considered ancillary but may be useful under special conditions and for research purposes.

Diplopia Test

The diplopia test with a red filter, shown in Figure 13–10, requires excellent patient cooperation. The patient's deviation is first determined objectively, and the diplopia test is then performed at the same fixation distance and with the same refractive correction to permit comparison. The test can be quantitated when a tangent scale or screen is available by asking the patient where the red light is seen in relationship to the fixation light.

The red filter test may also be performed after reducing the deviation fully by prisms. When this is done, the two foveae are simultaneously stimulated by the fixation light. With simultaneous stimulation of the two foveae, patients with anomalous correspondence may suddenly revert to normal

correspondence and see double.^{30, 32} The red filter test is time-consuming and therefore rarely performed in clinical practice.

Testing With Projection Devices

Projection methods (Lancaster red-green test, Polaroid projection method of Burian, and the phase difference haploscope of Aulhorn) (see Chapter 4) do not differ in principle from the major amblyoscope. They also use two targets that are presented separately in haploscopic fashion to the two eyes. However, these methods are generally more flexible and avoid proximal convergence since they are used in distance fixation.

Targets used in these devices may be placed in various positions on the screen, either superimposed or displaced at the objective angle of the patient or in any other desired position. Thus any desired stimulus situation may be achieved. In searching for the subjective angle, the patient may handle one of the projectors.

Foveo-Foveal Test of Cüppers

As stated earlier, it is not possible to do the afterimage test unless the patient fixates reasonably well with the foveal area. To overcome this difficulty, Cüppers⁵⁰ devised a test that permits investigation of the foveo-foveal relationship in patients with eccentric fixation. An asterisk is placed on the fovea of the deviated eye under ophthalmoscopic guidance while the other eye fixates the light on a Maddox cross or tangent screen (Fig. 13–17A). If one can break through the suppression scotoma of the deviated eye, which is generally possible, the patient can then report to the examiner the position of the images. If the fixation target appears to be superimposed on the central fixation light of the Maddox cross the foveae have a common visual direction, that is, retinal correspondence is normal (Fig. 13–17B). In the presence of anomalous correspondence the foveae have different visual directions and the asterisk will be superimposed on one of the numbers on the horizontal bar of the Maddox scale. This number indicates the angle of anomaly in degrees (4° in Fig. 13–17C).

This procedure has great intrinsic accuracy, but one must keep in mind that simultaneous stimulation of the two foveae may result in changes of localization. Similar reasoning applies to the afterimage test. In the latter, however, pure foveal

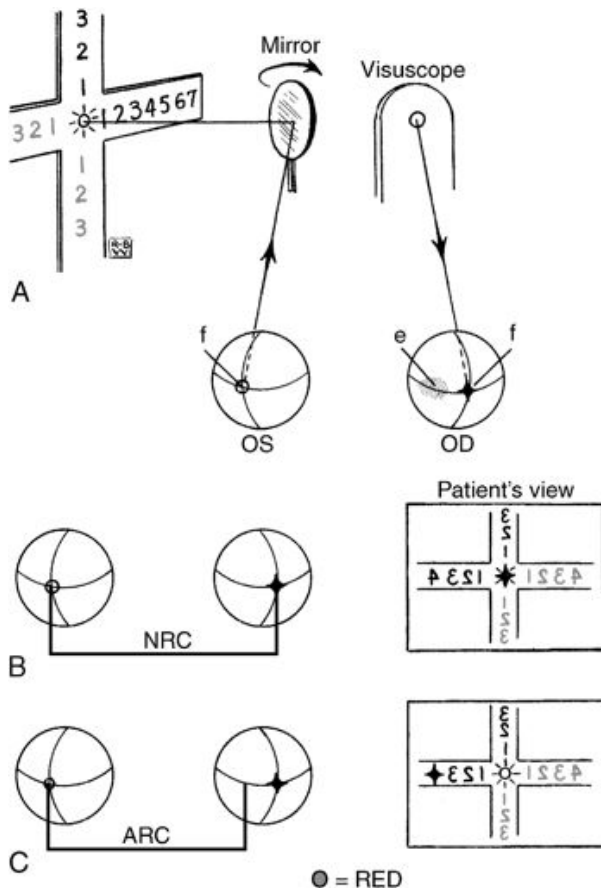


FIGURE 13-17. The foveo-foveolar test of Cüppers.⁵¹ *A*, Schematic representation of the testing arrangement. If the test is performed at 5 m distance from the Maddox scale the larger figures indicate the angle of anomaly. The small figures (not shown) are valid for a testing distance of 1 m. This patient has eccentric fixation OD; *e* indicates the fixation area. *B*, Patient sees the asterisk superimposed on the central fixation light of the Maddox scale. The two foveae have a common visual direction (NRC, normal retinal correspondence). *C*, The asterisk appears over the number 4 on the horizontal bar of the Maddox scale. The two foveae have acquired different visual directions (ARC, anomalous retinal correspondence). The angle of anomaly in this case is 4°. (From Noorden GK von: *Atlas of Strabismus*, ed 4. St Louis, Mosby-Year Book, 1983.)

stimulation is avoided. A modification of the foveo-foveal test consists of producing a vertical afterimage on the principal vertical meridian of the fixating eye and stimulating the foveal area of the deviated eye by means of Haidinger's brushes.

Evaluation of Tests

If anomalous correspondence represents an adaptation to the prevailing conditions in which a patient uses his or her eyes, tests that duplicate these conditions should provide ready evidence of this adaptation. Tests that are foreign to the visual

experience of the patient should be least likely to do so. One should expect anomalous correspondence, especially the harmonious type, to occur more frequently with the first type of test than with the second type. The diplopia test and the major amblyoscope test are close to the natural conditions of seeing,³⁰ and the afterimage test is the farthest removed. However, the striated glasses test of Bagolini⁶ fulfills best the requirement of interfering minimally with the patient's use of his or her eyes. Partly for this reason and partly because of its convenience and extreme ease of execution, this test is the test most widely and successfully applied in clinical practice.

Bagolini and Tittarelli¹⁴ found harmonious anomalous correspondence in 83% of their patients, using the striated glasses, but in only 13%, using the synoptophore. With the synoptophore 53% of the patients were found to have an unharmonious anomalous response. Conversely, normal correspondence was noted in only 10% tested with the striated glasses test, but when the synoptophore was used this figure was 40% (Table 13-1). Pasino and Maraini¹²⁵ made similar observations, but the percentage of patients with harmonious anomalous correspondence tested with the striated glasses test was considerably lower.

There was a great discrepancy between the normal responses from the afterimage test (51%) and a major amblyoscope (7%) in the 100 patients reported on by Burian and Luke.³⁵ They found anomalous correspondence in 30% with the striated glasses test, in 84% with the major amblyoscope, and in only 27% of patients with the afterimage test (Table 13-2). Generally speaking, all these data confirm the hypothesis that in a larger number of patients there tends to be an anomalous response in tests that interfere least with the ordinary conditions of seeing. The rather wide numerical differences in the various reported series no doubt reflect the heterogeneity of the material. Esotropes and exotropes respond differently, as do the various subgroups among these patients. Only a detailed analysis of the cases and unified classification will reconcile these differences.

The emphasis placed on the data obtained with tests that closely imitate natural conditions of seeing carries the implication that other tests give results that are unreliable or are of no clinical significance. This conclusion is not justified. It is clearly of interest to know how a patient's eyes are used in daily life, especially if one wishes to

TABLE 13-1. Comparison of Results of Determination of Status of Sensory Response of Strabismic Patients Using Various Methods of Testing

	Normal Correspondence	Anomalous Correspondence	Suppression	Diplopia
Striated glasses	3.8%	83.4% (harmonious)	9.7%	2.9%
Worth four-dot test	0%	33.9% (harmonious)	56.3%	9.7%
Major amblyoscope (synoptophore)	34.9%	12.6% (harmonious) 52.4% (unharmonious)	0%	0%

Modified from Bagolini B, Tittarelli R: Considerazioni sul meccanismo antidiplopico nello strabismo concomitante. *Boll Ocul* 39:211, 1960.

assess spontaneous changes, as after operations, or changes induced by other therapeutic measures; but for the evaluation of the patient's total condition, especially from a prognostic standpoint, it is just as significant to know that normal correspondence can be elicited with some of the tests as it is to know that there is harmonious anomalous correspondence in ordinary environmental situations. One is reminded of Chavasse's dictum expressed in his inimitably vivid prose: "The optimist, at all events, will agree that, with the restoration of normal function in view, it is more important in any given case to seek out the remnant of normal sensory correspondence than morbidly to uncover the nakedness of the abnormal."⁴⁵, p. 455

Why do certain tests produce normal responses and others anomalous responses? As has been pointed out repeatedly, in the development of anomalous correspondence the innate normal sensory relationship is only gradually replaced and

then not always completely. Patients who readily adapt their sensory systems to changes in the stimulus situation—and these seem to represent a majority—may have a superficial rearrangement of their sensory system. In those patients with a long-standing deviation or in those with an ability to adapt more completely, anomalous correspondence is more deeply rooted, and normal responses may be elicited only with difficulty, if at all. In those in whom a deviation is not of long standing, anomalous correspondence can be elicited only if the tests closely duplicate the ordinary environmental conditions.

Tests currently in use to diagnose ARC are listed in Figure 13-18 in ascending order according to their dissociating power. The chart is modified from Bagolini,⁸ who defined *dissociation* as the property of a test to alter the casual conditions of seeing.^{76, 134} *For practical purposes and to assess correspondence under the least and most dissociating conditions, we advocate use of the*

TABLE 13-2. Comparison of Determination of Sensory Response in 100 Patients with Heterotropia Using Three Different Methods

	NRC	ARC	Mixed ARC and NRC	ARC/Suppression	Suppression	Unreliable Response	Total
All 100 patients							
Striated lenses	11	30	5	24	24	6	100
Major amblyoscope	7	84	0	0	8	1	100
Afterimage test	51	27	7	2	9	4	100
All 80 esotropic patients							
Striated lenses	6	27	2	23	18	4	80
Major amblyoscope	6	65	0	1	8	1	80
Afterimage test	42	21	5	2	6	4	80
All 20 exotropic patients							
Striated lenses	5	3	3	1	6	2	20
Major amblyoscope	1	19	0	0	0	0	20
Afterimage test	9	6	2	0	3	0	20

NRC, normal retinal correspondence; ARC, anomalous retinal correspondence.

Adapted from Burian HM, Luke N: Sensory retinal relationships in 100 consecutive cases of heterotropia. A comparative clinical study. *Arch Ophthalmol* 84:16, 1970.

DISSOCIATING EFFECT OF TESTS FOR RETINAL CORRESPONDENCE

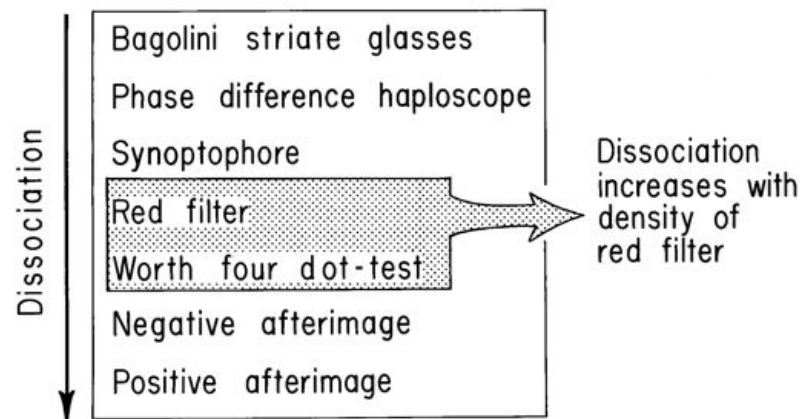


FIGURE 13-18. Tests for retinal correspondence listed in order of their dissociating effect. (Modified from Bagolini B: I. Sensorial anomalies in strabismus (suppression, anomalous correspondence amblyopia). *Doc Ophthalmol* 41:1, 1976.)

Bagolini glasses and of the afterimage test. Another option is to use the striated glasses in conjunction with the Bagolini red filter bar.

Neurophysiologic Basis

The neurophysiologic basis of ARC is beginning to unravel. Animal experiments, which thus far have only been performed in eso- and exotropic cats, have shown strabismus-induced modification of the lateral suprasylvian cortex. Receptive fields of binocularly driven neurons were found to be located on noncorresponding retinal points.^{52, 64, 148} It is necessary to repeat these experiments in primates to further explore the possibility that this adaptive shift of spatial coordinates could form the neural basis for ARC.

Dengler and Kommerell⁵⁴ addressed the question of whether anomalous correspondence occurs between disparate retinal elements that have acquired new interocular connections or whether the existing connections in normal humans suffice to subserve anomalous correspondence. They showed in normal subjects that interocular connections reach over disparities as large as 21° . This held true not only for connections between symmetrical areas in the retinal periphery of both eyes (bitemporal and binasal) but also for connections between the fovea of one eye and the temporal periphery of the other eye. Crossed disparities reach over wider angles than nasal disparities. These findings suggest the possibility that ARC occurs on the basis of connections that already exist in normal subjects and that the anatomical

basis for large angle anomalous correspondence could be better for exotropes than for esotropes.

Suppression and Anomalous Correspondence

Suppression and anomalous correspondence do coexist in patients with comitant strabismus, a fact that has been known since the early studies of Tschermak-Seysenegg¹⁵⁸ and Bielschowsky.¹⁸ Travers,¹⁵⁷ who made a thorough investigation of the relation of suppression scotomas, amblyopia, and anomalous correspondence, believed that suppression was a prerequisite of establishment of anomalous correspondence. Harms⁷⁰ went so far as to say that proving the presence of regional suppression scotomas was equivalent to demonstrating that there was anomalous correspondence. Halldén⁶⁸ showed that suppression scotomas do exist in the fovea and that part of the peripheral retina of the deviated eye receiving the same image as the fovea (fixation point scotoma). Herzau⁷⁷ reported similar findings.

In esotropes fixation point scotomas are small and well circumscribed, but occasionally they reach hemianopic proportions in exotropes with anomalous correspondence.⁶⁸ Suppression scotomas are found not only in the deviated eye but also at the point in the peripheral retina of the fixating eye at which the same image is received as that on the fovea of the deviated eye.^{71, 77} According to Herzau,⁷⁸ harmonious anomalous correspondence may permit anomalous binocular vision only between those parts of the two retinas in

which nonsignificant functional differences exist between retinal elements that receive identical images. In other areas of the binocular visual field, anomalous correspondence permits optimal perception of visual detail by suppressing the more peripherally located retinal points.

Campos³⁸ challenged this view and pointed out that most studies in which suppression scotomas were detected in patients with anomalous correspondence were performed with perimetric techniques that caused dissociation of the eyes or retinal rivalry. He used fusible test targets and nondissociating perimetric techniques and control marks and demonstrated that areas of single perception, interpreted by others as being caused by a suppression scotoma, are actually areas of binocular perception.¹⁰⁹ Campos³⁶ proposed that in some strabismic patients, particularly in those with a small angle deviation, ARC functions as the only antidiplopic mechanism and that even amblyopia may develop in such patients without suppression and from an “inhibition of normal directional localization.” This means that reduced visual acuity of the amblyopic eye cannot be explained exclusively with prolonged suppression of its fovea. The inhibition of normal directional localization may be considered as an additional amblyopio-genic factor. This should not distract from the fact that the central portion of the streak, produced by a Bagolini glass before the deviated eye, is missing in most patients with small angle esotropia (see Fig. 13–15C). There is no interpretation other than that of a fixation point scotoma for this phenomenon.

The view that suppression and anomalous correspondence exclude each other to a degree is also supported by Bagolini and Tittarelli¹⁴ and Bagolini.¹⁰ Using the striated glasses test, they found that harmonious anomalous correspondence is present in patients with low degrees of strabismus of 30^A or less, whereas suppression is the rule in patients with larger deviations. Others have confirmed these findings.^{37, 87, 125}

The enormous variations regarding the relationship between the deviation size, type of strabismus, and prevalence of ARC reported in the older literature can only be explained by differences in testing procedures and the heterogeneity of the populations under study.

Development and Clinical Picture

Normal correspondence is a stable innate condition that cannot be altered experimentally in hu-

mans, but this stability is not so rigid as not to allow for changes if abnormal conditions warrant them. When a disturbance in the motor conditions is present, such as a deviation of the visual axes in comitant strabismus, a profound rearrangement in the sensory system takes place, which is expressed in the sensory symptoms of strabismus.

Adaptability is a general characteristic of the visual system. It reacts with appropriate responses to changes in the environment, that is, the stimulus conditions. Accommodation, dark adaptation, Panum’s area of single binocular vision, and anomalous correspondence are obvious examples. All these functions are useful, but the teleological meaning of the term *adaptation* must not be exaggerated. Anomalous correspondence is the result of a physiologic mechanism that takes place regardless of its usefulness to the organism. It is not a “psychological” interpretive phenomenon.

Development

Whatever the mechanism of anomalous correspondence, a study of a large number of patients with comitant heterotropia has shown that certain factors are necessary for its establishment.³⁰ First, a certain flexibility of the sensory visual system is required. This flexibility decreases with the passing of years. Anomalous correspondence therefore is found in patients in whom the deviation of the visual axes arose early in life, as stressed by von Graefe.⁶³ Adults who acquire such a deviation maintain normal correspondence, but abnormal correspondence may be found in patients with a deviation of early onset when they are examined later in life. There are various reasons for such behavior.

To break through the innate retinocortical relationship requires time. The stimulus situation that leads to establishment of anomalous correspondence must persist for a sufficiently long period to produce its result. Consequently, the more constant the magnitude of the deviation and the more constantly a patient uses the same eye for fixation, the more readily anomalous correspondence will be established. Instability of the deviation and frequent changes in fixation tend toward maintenance of the normal retinocortical relationship. Normal correspondence is not immediately and rarely totally suppressed. Normal and anomalous correspondence frequently coexist in the same patient, especially in those with intermittent exotropia. The Hugonniers have introduced the term

duality of correspondence for this phenomenon.⁸³ Others have shown that different patterns of retinal correspondence may affect the central and peripheral visual fields.^{149, 150} Retinal correspondence tended to be closer to normal in the central parts and anomalous in the more peripheral parts of the visual field.

It has been shown that in development of anomalous correspondence the angle of anomaly gradually increases until it equals the amount of the deviation and the anomalous correspondence becomes harmonious.^{67, 68} A gradual decrease in the angle of anomaly has also been reported during the process of normalization by treatment.⁴⁴ This gradual increase and decrease may well be true during the periods of establishment and regression of anomalous correspondence. However, once established, a reversal from anomalous to normal correspondence and vice versa may occur within seconds or fractions of a second.

The *sensitive period* during which anomalous correspondence develops is not exactly known because the precise onset of strabismus and its constancy are difficult to assess in young children by history alone. It is our clinical impression, however, that the capacity to develop ARC, even if only superficially seated, extends beyond the sensitive period established for amblyopia (Chapter 14) and into the early teens.

Clinical Picture

For all the reasons stated above, responses of patients to the different tests for anomalous correspondence, and indeed to the same test, may be varied and are often described as confusing or even frustrating to the examiner. Jampolsky⁸⁹ is quoted as having remarked that “the world would be a happier place if no one had thought about anomalous retinal correspondence.” However, if the basis of each test and the processes involved are clearly understood, the patient’s responses become meaningful and provide indispensable information about the degree of normal or anomalous binocular cooperation.

As has been pointed out, anomalous correspondence is not established with equal firmness in all patients. It is necessary to list and describe some of the more common variants that make up the clinical picture of anomalous correspondence.

HARMONIOUS ANOMALOUS CORRESPONDENCE. This mode of localization has already

been described and should not be difficult to understand. The patient in Figure 13–19 demonstrates that the angle of anomaly equals the deviation. The motor and sensory conditions are in good accord.

UNHARMONIOUS ANOMALOUS CORRESPONDENCE. If the angle of anomaly is smaller than the angle of squint, adaptation to the deviation is incomplete. The explanation for this situation poses questions that have been answered in various ways. It has been suggested that it is an artifact of some testing situations.^{67, 102} This is quite possible; however, other investigations have shown that this is not always the case and that unharmonious anomalous correspondence is a genuine clinical entity.^{4, 31, 78} To explain this puzzling phenomenon, Rønne and Rindziunski¹³⁶ suggested that in some patients the gradual increase of the angle of anomaly, postulated by Travers,¹⁵⁷ stops before reaching the stage of harmonious anomalous correspondence. Burian³⁰ emphasized and cited many examples in which a more or less sudden change in the angle of squint preceded the finding of an unharmonious anomalous localization. The cause for this change may be known (prescription of glasses, prismatic corrections, or operations) or unknown.

PARADOXICAL DIPLOPIA. The obvious example of an unharmonious anomalous correspondence is paradoxical diplopia. It occurs when anomalous correspondence persists after surgery, and the

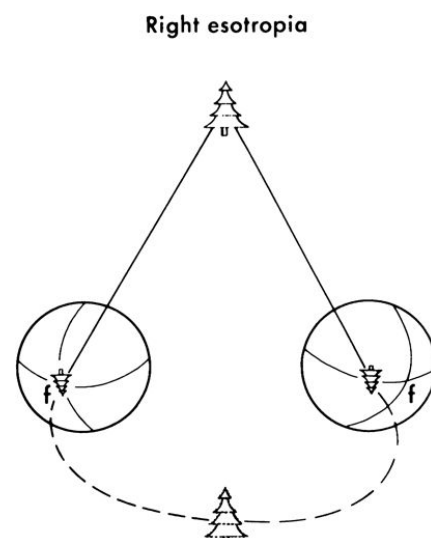


FIGURE 13–19. Superimposition with harmonious anomalous retinal correspondence. (From Burian HM: Adaptive mechanisms. *Trans Am Acad Ophthalmol Otolaryngol* 57:131, 1953.)

postoperative position of the eyes no longer conforms to the preoperatively established angle of anomaly. Esotropic patients whose eyes have been set straight, or almost straight, may exhibit in one or all tests a crossed localization of the foveal or parafoveal stimuli³¹ (Fig. 13–20), and former exotropic patients whose eyes have been surgically aligned will experience uncrossed diplopia. Clearly, disharmony between the motor and sensory conditions is present, and these patients respond with a type of diplopia that is contrary to what one would expect on the basis of the postoperative position of the eyes.

Paradoxical diplopia can nearly always be elicited in patients with anomalous correspondence when both foveae are stimulated simultaneously with the major amblyoscope or when the position of the afterimages during the afterimage test is compared with the underlying deviation. For example, an esotrope with anomalous correspondence will localize a horizontal afterimage produced in the right eye to the left (crossed) of a vertical afterimage produced in the left eye (see Fig. 13–14B).

In deep-rooted harmonious anomalous correspondence, the amount of the postoperative crossed diplopia may be used to guess at the amount of the preoperative deviation. For example, if a patient has 5 Δ of residual esotropia and if the angle of anomaly determined postoperatively equals 25 Δ , the patient in all probability originally had a deviation of 30 Δ .

From a clinical point of view, paradoxical di-

plopia is a fleeting phenomenon limited to the immediate postoperative period. Rarely does it persist longer than a few days or weeks; however, there are exceptions. We have examined a patient in whom paradoxical diplopia persisted for 2 years after surgery.

CASE 13-1

This 38-year-old man had had exotropia since childhood. He had undergone muscle surgery on the right eye for a deviation of 35 Δ before we saw him. The patient had experienced double vision since the operation. The prism cover test revealed a residual exotropia of 10 Δ at near and distance fixation. The patient had uncrossed diplopia. The afterimage test and the Bagolini striated glasses test revealed ARC. Diplopia disappeared with a 25 Δ base-out prism.

The sensory state of the patient in Case 13–1 is shown in Figure 13–21. The image in the right eye falls nasal to a retinal area that still shares a common visual direction with the fovea of the left eye and therefore it is localized to the right of the patient in an uncrossed fashion. The preoperative deviation of 35 Δ exotropia corresponds with the persisting angle of anomaly since a 25 Δ base-out prism is required to eliminate the image. This case demonstrates the practical importance of analyzing with the red-glass test postoperative diplopia to determine whether it is paradoxical or in accordance with a residual deviation.

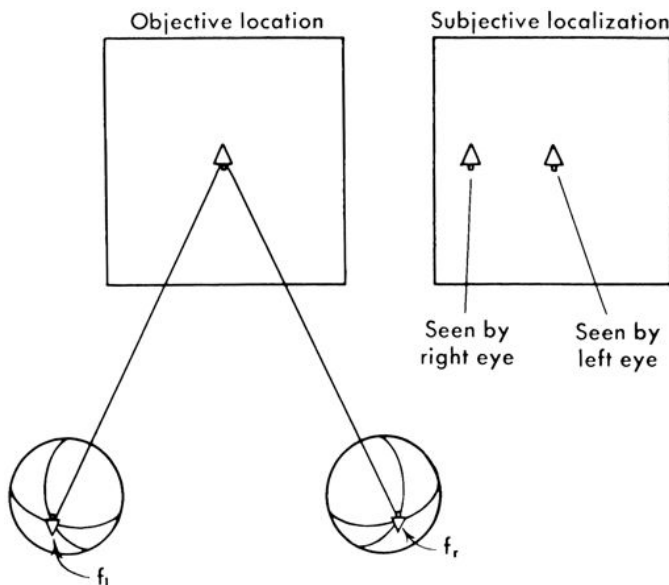


FIGURE 13–20. Crossed (paradoxical) diplopia after surgical alignment in a formerly esotropic patient with persistent anomalous correspondence. (From Burian HM: Adaptive mechanisms. *Trans Am Acad Ophthalmol Otolaryngol* 57:131, 1953.)

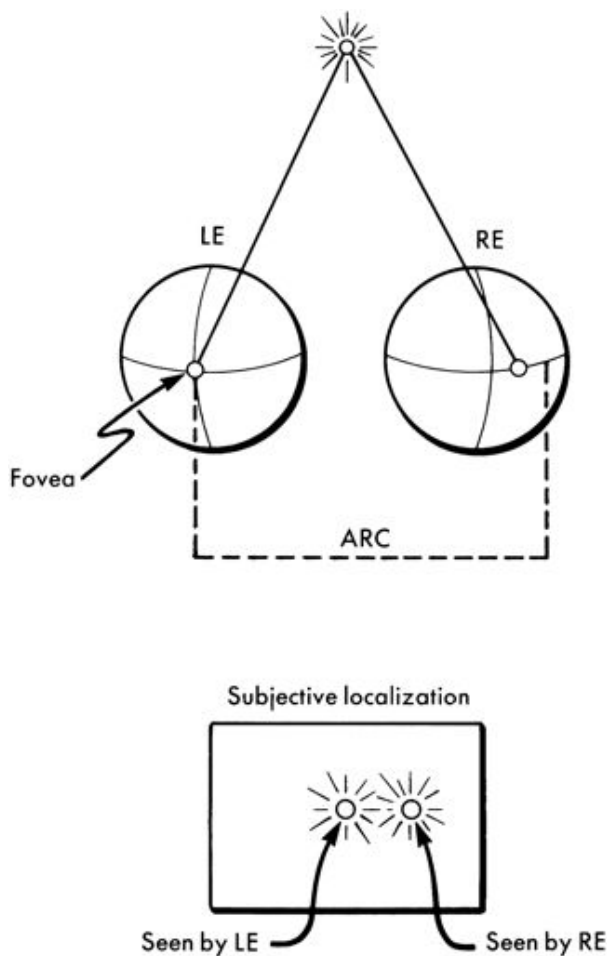


FIGURE 13-21. Paradoxical diplopia in exotropia. ARC, anomalous retinal correspondence. See text for explanation.

CHANGES IN LOCALIZATION WITH CHANGE IN FIXATION. The sensory system of a patient who fixates habitually with one eye is adjusted to this motor condition. If forced in a test situation to assume fixation with the other eye, the patient may continue to localize anomalously; or quite frequently if the anomalous correspondence is not firmly established, the patient will revert to normal correspondence. Such behavior is a good prognostic sign. It was made use of in orthoptic techniques for treatment of anomalous correspondence (Walraven technique¹⁶²).

MONOCULAR DIPLOPIA (BINOCULAR TRIPLOPIA). In so-called paradoxical diplopia, anomalous localization is maintained after operative alignment of the eyes. Under the same circumstances, another phenomenon, known as monocular diplopia or binocular triplopia, may be observed. The patient perceives two images of the fixation object with the deviated or formerly devi-

ated eye, one localized normally and the other anomalously. In binocular viewing the patient will then perceive three images, one with the fixating eye and two with the deviated eye, one to each side of the image seen by the fixating eye (Fig. 13-22). Thus if there is a residual right esotropia of, say, 4^{Δ} or 5^{Δ} , the patient will have an uncrossed diplopia in that amount relative to the object seen by the fixating left eye and, at the same time, a crossed diplopia equal in amount to the preoperative angle of anomaly (minus the amount of uncrossed diplopia). Characteristically, the uncrossed, normally localized image is at first the dimmer of the two (see Fig. 13-22). As time goes on, the crossed image gradually fades and may eventually disappear, while the uncrossed image strengthens as the normal correspondence becomes reestablished.

BINOCULAR TRIPLOPIA. First mentioned by Javal⁹⁰ binocular triplopia was observed in the form of monocular diplopia in the now famous case of the “moderately well-educated and intelligent electrician Georg Sturm” reported in 1898 by Bielschowsky.¹⁷ This patient had a long-standing strabismic amblyopia and lost his good eye through a perforating injury. Shortly after the injury he began seeing double with his amblyopic eye. The meticulous analysis and interpretation of this patient’s problem launched Bielschowsky on his career as one of the foremost experts in strabismus of his time. He explained the phenomenon correctly on the basis of a competition between normal and anomalous relative localization: the fovea of the amblyopic eye localized one visual object simultaneously in two visual directions, the innate normal and the acquired anomalous one. Monocular diplopia has since been much misinterpreted.³⁴ The inadequate attempts at other explanations only confuse the uninitiated who try to understand the phenomenon. In rare cases binocular triplopia occurs spontaneously, but just like paradoxical diplopia, binocular triplopia can frequently be provoked instrumentally. Cass⁴⁴ was able to produce it with the synoptophore in 30 out of 70 patients by appropriate stimulation, and Walraven¹⁶² used it to develop a special orthoptic technique for treatment of anomalous correspondence.

POSTOPERATIVE CHANGES IN CORRESPONDENCE AND INSTANTANEOUS CHANGES IN THE ANGLE OF ANOMALY. Bielschowsky²⁰ and Ohm¹²² followed spontaneous changes in the sen-

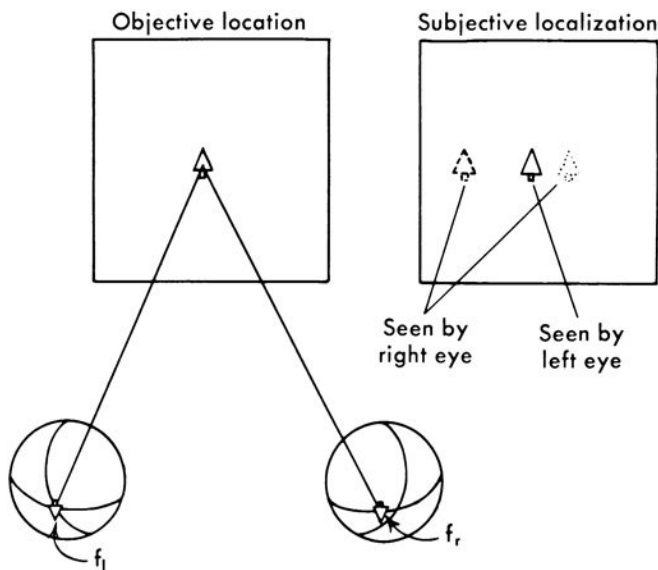


FIGURE 13–22. Appearance of fixated object seen in binocular triplopia. (From Burian HM: Adaptive mechanisms. *Trans Am Acad Ophthalmol Otolaryngol* 57:131, 1953.)

sory relationship of the eyes after operations for strabismus. Ohm postulated three stages in this development. In the first stage, correspondence remained anomalous; in the second, rivalry occurred between normal and anomalous correspondence; and in the third, normal correspondence was reestablished in favorable cases. Ohm recognized that not every patient goes through all three stages and that development may stop at any stage. He believed that the patient's age at the time of the operation, individual adaptability, the depth with which anomalous correspondence was established preoperatively, and the use the patient made of the eyes influenced this development.¹²²

These descriptions of the postoperative development of anomalous correspondence in older publications agree with the concept emphasized previously, that development of anomalous correspondence requires time. However, Halldén⁶⁷ was able to demonstrate an instantaneous change in the angle of anomaly in patients with esotropia and harmonious anomalous correspondence. Halldén likened these covariations to the fusional movements of subjects with normal binocular vision. Rønne and Rindziunski¹³⁵ claimed that they could even induce changes in the position of afterimages by quickly moving a prism rack in front of one eye. This startling finding was partially confirmed by Hansen and Swanljung.⁶⁹

More recently Bagolini,⁷ among others, found that there is an immediate postoperative adaptation to the newly created deviation, so that a harmonious anomalous correspondence can be measured as soon as the patient can be tested. This interesting finding, which we have been able to confirm,

must not be misinterpreted to indicate that a new system of ARC develops within days after surgery. Rather, it appears that there are an infinite number of retinal elements between the fovea and the preoperative fixation point that are capable of sharing a common visual direction with the fovea of the fixating eye (point-to-area relationship). Reduction of the angle of strabismus by surgery merely shifts the retinal image in the deviating eye closer to the fovea but within an area that had corresponded preoperatively with the fovea of the sound eye. This point-to-area vs. point-to-point concept of ARC is useful also in explaining adaptation of the angle of anomaly to variations of the angle of squint at different fixation distances. This concept is supported further by the observation that anomalous correspondence may be present in primary position, as well as in upgaze or downgaze in patients with A and V patterns of strabismus.^{46, 74}

Thus the angle of anomaly may adapt to considerable variations in the angle of strabismus. Even though these and other clinical findings⁴ indicate that there may be numerous peripheral retinal points in the deviated eye capable of acquiring a common visual direction with the fovea of the fixating eye, this anomalous interretinal relationship is quite precise and, actually, “point to point” for any given angle of strabismus.¹¹⁵

Finally, the fact that the angle of anomaly may change in different gaze positions^{4, 74} should not be taken in support of the previously expressed notion that innervational factors are capable of modifying the interretinal relationship. Whereas such factors do influence egocentric localization,

as in the example of past-pointing (see Chapter 20), they have no effect on the rearrangement of visual directions as occurring in ARC.

Quality of Binocular Vision in Anomalous Correspondence

In assessing the binocular cooperation of patients with anomalous correspondence, one must keep in mind that their response depends on the stimulus situation presented to them. There is no doubt that patients with anomalous correspondence are capable of performing *fusional movements triggered by retinal disparity*. This possibility was reported by Bielschowsky¹⁸ and subsequently studied and confirmed by Burian,²⁹ Halldén,⁶⁷ and others.^{40, 107, 124, 140}

Bagolini⁸ and Pasino and Maraini¹²⁶ explained that patients with anomalous correspondence have a much larger area of horizontal single binocular vision (named the pseudo-Panum area by Bagolini) than people with normal binocular vision. To show this, Bagolini used a form of horopter apparatus, provided with a small light on the movable rods, and his striated glasses. Bagolini and his school⁸ demonstrated in a series of papers eye movements (anomalous movements) in response to horizontal and even vertical prisms in patients with anomalous correspondence.^{10, 12, 41, 42} These movements may fully offset the prism-induced disparity and have been likened to fusional movements (vergences) in normal persons (see also Kertesz,⁹² and Boman and Kertesz²⁵).

However, they are less precise and much slower than normal fusional vergences since the movement may take hours or days to complete. Whether their purpose is to return the prismatically misplaced retinal images to retinal elements that share an anomalous common visual direction has not been unequivocally established. Bagolini^{10, 11} believes that this is generally the case but concedes that they may also occur independently of the underlying behavior of retinal correspondence. We are inclined to agree with this modified view since prism-induced fusional movements (prism adaptation) are not limited to patients with ARC but can also be elicited in those with NRC.^{41, 139} Prism-induced anomalous movements form the basis of the prism adaptation test which is used by some clinicians in their surgical planning (see Chapter 26).

The presence of true stereopsis in anomalous correspondence is much less firmly established.

Several investigators were unable to find stereoscopic thresholds that were higher than those in patients with deep suppression,^{65, 105, 113, 127} and Nelson¹¹⁴ concluded on theoretical grounds that once anomalous correspondence is present stereopsis can no longer exist. On the other hand, there can be no argument that gross stereopsis (usually less than 120 minutes of arc) is a common finding in patients with anomalous correspondence and small angle esotropia or microtropia^{73, 85, 88, 98, 102} and may occasionally even be demonstrable with random-dot stereograms. A gross type of depth perception can be also detected in patients with anomalous correspondence by means of the Lang two-pencil test (see Fig. 15–8).

In addition to simultaneous perception in the presence of a manifest deviation, as well as possible restoration of some form of motor fusion, there are other functional advantages to anomalous binocular vision as a result of ARC. Bagolini and Campos¹² described patients who had a manifest deviation while assuming a compensatory head position. Such patients have *anomalous correspondence in the position of torticollis and suppression of the deviating eye in other gaze positions*. Clearly, these individuals must prefer anomalous correspondence over suppression and will keep their heads turned or tilted to take advantage of this sensorial adaptation. Exteroceptive and visual-motor tasks are other functions that may be enhanced by anomalous binocular vision.^{39, 66} Objective evidence for increased binocular activity in patients with anomalous correspondence over those with suppression has also been found. Binocular summation of VERs occurs in normal patients and in patients with anomalous correspondence but not when the deviated eye is suppressed.³⁸

Prevalence

The question of how often anomalous correspondence is encountered in untreated patients with strabismus cannot be answered unequivocally. Figures reported in the literature vary from 0.6% to 95%. Various factors are involved, one being the choice of criteria for the diagnosis of anomalous correspondence. Its rate of occurrence is high in infantile esotropia,^{14, 35, 53, 119} less common in exotropia,⁵⁵ and uncommon in vertical strabismus.^{8, 60, 108}

Theories

The theory presented in this chapter is the classic one now almost generally accepted, though not necessarily fully understood. It provides the only satisfactory explanation of all clinically observable phenomena, but some attention must be given to other thoughts on the subject, which permeate the older and even more recent literature.

Until recently the so-called projection theory of binocular vision (see Chapter 2) was well accepted. However, it cannot explain physiologic diplopia, let alone the phenomena of localization in anomalous correspondence. This theory is now only of historical interest, as in Chavasse's concept of anomalous correspondence as a perverted binocular reflex.

Linksz¹⁰³ returned to the original rigid theory (Müller¹¹² and von Graefe⁶²) that normal correspondence is a strictly anatomical fact based on an immutable connection between distinct retinal and cortical areas. Excitations arising in specified, corresponding areas of the retinas of the two eyes are always transmitted to the same cortical area, so that the resulting cortical process, and consequently the sensation produced, is always a single one. Stimulation of these corresponding retinal areas is consummated in Gennari's stripe (the cortical correlate of the horopter), and stimulation of noncorresponding points is transmitted to the granular layers in front of or behind that stripe, with resultant stereopsis.

In this theory of isomorphism (see p. 35), there is clearly no room for the concept of common visual directions and it is useless to inquire how disparate elements could acquire them. Therefore anomalous correspondence in the classic sense does not exist. Phenomena observed in patients with strabismus are explained in two ways. In some of them, retinal rivalry ceases and one eye is suppressed. In others, there is complete alternation of foveal vision, a view reminiscent of Verhoeff's replacement theory of fusion¹⁶⁰ (see p. 35). In these patients, rivalry is also suspended, the foveal images being consummated one at a time in the cerebral cortex. The anomalous localization is a result of a form of panoramic vision; the patient "sees the things where they are." Linksz's theory¹⁰³ cannot account for many phenomena observed in patients with anomalous correspondence—the instability of the angle of anomaly, monocular diplopia—and therefore it is of little help in clinical work.

Boeder^{23, 24} also assumed the immutability of the innate normal correspondence. He based his theory of the anomalous responses in patients with strabismus on the observations of past-pointing associated with paralyses of recent origin and on the apparent movement of the surround when an intended ocular movement is not executed.

Boeder combined these observations with Walls's findings¹⁶¹ on visual directions and with Verhoeff's replacement theory¹⁶⁰ and postulated that the anomalies of localization in strabismus are not the result of the assimilation of visual directions but rather of a substitution of the visual direction of the stimulated element by another retinal element, which turns the visual directions into an appropriate egocentric direction. This is brought about by continued frustration of nearly equal amounts of convergence innervation in the deviated eye until the "response shift" has become an established conditioned reflex. Boeder's theory is not supported by clinical facts. For example, his speculations on how the "response shift" invariably induces an amblyopia is not in accord with the clinical observation that not all patients with anomalous correspondence have amblyopia. Second, and most important, this theory is based on the unsupported assumption that a discrepancy exists between intended and executed eye movement in patients with comitant strabismus and that this discrepancy causes errors in egocentric localization, similar to past-pointing in paralytic strabismus (see Chapter 20).

According to Boeder,²⁴ the lack of execution of an eye movement for which the proper innervation has been issued will cause a substitute directional response of retinal elements in the amount of the angle of the frustrated rotation. In comitant strabismus we know of no frustration of intended eye movements as they may occur in paralytic strabismus. Moreover, the discrepancy between intended and executed eye movements in cases of paralytic strabismus of recent onset causes a shift in egocentric (absolute) localization (see p. 29) of visual objects when viewed monocularly with the paretic eye. However, the essence of ARC is a rearrangement of binocular relative visual directions.

Postural and other functions of the motor sphere have long been resorted to by supporters of the projection theory of binocular vision in an attempt to obviate its difficulties. Motor phenomena, usually presented in up-to-date cybernetic terms, have been alleged to explain such anoma-

lies as monocular diplopia. Le Grand,¹⁰¹ in calling attention to past-pointing and similar phenomena, spoke of a disturbance of “motor compensation” in strabismus or the relation between ocular rotation and image shift on the retina. When the ocular position returns to normal, so does the “motor compensation,” but it may coexist with the old disturbed motor compensation and cause monocular diplopia. Schober and Leisinger¹⁴¹ explained Le Grand’s dynamic motor compensation in terms of cybernetics. Morgan¹¹¹ proposed that some ocular movements are “registered” in coordinating centers and some are “not registered,” depending on whether they affect egocentric localization. He used this concept to explain not only anomalous correspondence but also monocular diplopia.

A detailed discussion of these views on the pathogenesis of monocular diplopia, which can be found in a publication by Burian,³⁴ will not be given here, but the reader should be reminded that monocular diplopia can be elicited by stimulating the fovea of the deviated eye by means of a major amblyoscope or with an ophthalmoscopic device, which clearly does not involve motor or postural factors.

Review and Summary

The phenomenon of anomalous correspondence has been described in considerable detail, and a summary of the essential points, emphasizing their clinical importance, may be useful. Anomalous correspondence consists of a reordering of the visual directions of the two eyes so that the motor anomaly, the deviation, is fully or partially compensated by the sensory system. Thus anomalous correspondence may represent an adaptation of the sensory system to the abnormal motor situation. Adaptation to this condition requires individual adaptability as well as time. The younger the patient is at the time of onset of the deviation, the more readily and more speedily anomalous correspondence develops. Adults who acquire a deviation maintain normal correspondence, but even in young patients the depth of this adaptation varies within wide limits. Different tests are required to determine the depth of retinal correspondence. Generally speaking, tests that closely simulate the conditions of everyday use of the eyes give evidence of anomalous localization. Tests presenting the patient with unusual conditions of seeing are more likely to produce a normal response, and if such tests elicit anomalous localiza-

tion, the anomalous correspondence is deeply rooted. Similarly, if the patient is forced to use his or her eyes in an unusual manner, made to fixate with the usually deviated eye, or forced to accept bifoveal stimulation, he or she may revert to normal localization. Normal and anomalous correspondence thus may coexist and on occasion result in monocular diplopia (binocular triplopia). This phenomenon, though rarely occurring spontaneously, can be elicited artificially in patients whose anomalous correspondence is not too deeply rooted.

Anomalous correspondence is an attempt by the patient to recover binocular cooperation when the visual axes are misaligned. To a degree, this attempt is successful, and *anomalous binocular vision is a functional state superior to that prevailing in the presence of suppression in alternating strabismus*. This concept has been reinforced.⁷⁹ The visual input from a suppressed eye is limited and of no apparent benefit to binocular vision other than elimination of diplopia and confusion.

Fifty years ago anomalous correspondence was seen as a major obstacle to restoration of normal binocular vision and treated with great conviction by many orthoptists. It is astounding that this attitude still prevails in some parts of the world. As a result of this therapeutic zeal many patients with comfortable binocular vision on an anomalous basis regained normal correspondence and with it, intractable diplopia. A small angle, cosmetically inconspicuous residual strabismus with anomalous correspondence is now considered by most strabismologists and orthoptists an acceptable or even desirable endstage of therapy in infantile esotropia.¹¹⁹ It requires no further treatment except for a coexisting amblyopia and affords the patient many functional advantages of binocular vision on an anomalous basis in spite of the ocular misalignment. According to current views, orthoptic treatment of anomalous correspondence (see Chapter 24) is contraindicated.

REFERENCES

1. Adler FH, Jackson FE: Correlations between sensory and motor disturbances in convergent squint. *Arch Ophthalmol* 38:289, 1947.
2. Arthur BW, Cake S: Bagolini lenses vs the polarized four-dot test. *J Pediatr Ophthalmol Strabismus* 33:98, 1996.
3. Aulhorn E: Erfahrungen mit der Phasendifferenzhaploskopie. *Bericht Dtsch Ophthalmol Ges* 69:593, 1969.
4. Awaya S, Noorden GK von, Romano PE: Anomalous retinal correspondence in different positions of gaze. *Am Orthopt J* 20:28, 1970.

5. Bagolini B: Presentazione di una sbarra di filtri a densità scalare assorbenti i raggi luminosi. *Boll Ocul* 36:638, 1957.
6. Bagolini B: Tecnica per l'esame della visione binoculare senza introduzione di elementi dissocianti: "test del vetro striato." *Boll Ocul* 37:195, 1958.
7. Bagolini B: Diagnostic et possibilité de traitement de l'état sensoriel du strabisme concomitant avec des instruments peu dissociants (test du verre strié et barre de filtres). *Ann Ocul* 194:236, 1961.
8. Bagolini B: Anomalous correspondence: Definition and diagnostic methods. *Doc Ophthalmol* 23:346, 1967.
9. Bagolini B: I. Sensorial anomalies in strabismus (suppression, anomalous correspondence, amblyopia). *Doc Ophthalmol* 41:1, 1976.
10. Bagolini B: II. Sensorio-motorial anomalies in strabismus (anomalous movements). *Doc Ophthalmol* 41:23, 1976.
11. Bagolini B: Anomales Binokularsehen und dessen Konsequenzen für die Schieloperation. In Herzau V, ed: *Pathophysiologie des Sehens*. Stuttgart, Ferdinand Enke Verlag, 1984, p 233.
12. Bagolini B, Campos EC: Practical usefulness of anomalous binocular vision for the strabismic patient. *Int Ophthalmol* 6:19, 1983.
13. Bagolini B, Campos EC, Chiesi C: The Irvine 4 diopter prism test for the diagnosis of suppression: A reappraisal. *Binocular Vision* 1:77, 1985.
14. Bagolini B, Tittarelli R: Considerazioni sul meccanismo antidiplopico nello strabismo concomitante. *Boll Ocul* 39:211, 1960.
15. Bárány EH, Halldén U: Phasic inhibition of the light reflex of the pupil during retinal rivalry. *J Neurophysiol* 11:25, 1948.
16. Benegas NM, Egbert J, Engel WK, et al: Diplopia secondary to aniseikonia associated with macular disease. *Arch Ophthalmol* 117:896, 1999.
17. Bielschowsky A: Über monoculäre Diplopie ohne physikalische Grundlage, nebst Bemerkungen über das Sehen Schielender. *Graefes Arch Clin Exp Ophthalmol* 46:143, 1898.
18. Bielschowsky A: Untersuchungen über das Sehen der Schielenden. *Graefes Arch Clin Exp Ophthalmol* 50:406, 1900.
19. Bielschowsky A: Application of the afterimage test in the investigation of squint. *Am J Ophthalmol* 20:408, 1937.
20. Bielschowsky A: Lectures on motor anomalies. V. Development and causes of strabismus. *Am J Ophthalmol* 22:38, 1939.
21. Bixenmann W, Joffe L: Binocular diplopia associated with retinal wrinkling. *J Pediatr Ophthalmol Strabismus* 21:215, 1984.
22. Blake R, Lehmkuhle SW: On the site of strabismic suppression. *Invest Ophthalmol* 15:660, 1976.
23. Boeder P: Anomalous retinal correspondence refuted. *Am J Ophthalmol* 58:366, 1964.
24. Boeder P: Eighth Annual Richard G. Scobee Memorial Lecture: "Response shift" vs. anomalous retinal correspondence. *Am Orthopt J* 28:44, 1978.
25. Boman D, Kertesz AE: Fusional responses of strabismics to foveal and extrafoveal stimulation. *Invest Ophthalmol Vis Sci* 26:1731, 1985.
26. Boyd TAS, Karas Y, Budd GE, et al: Fixation switch diplopia. *Can J Ophthalmol* 9:310, 1974.
27. Brenner RL, Charles ST, Flynn JT: Pupillary responses in rivalry and amblyopia. *Arch Ophthalmol* 82:1, 1969.
28. Burgess D, Roper-Hall G, Burde RM: Binocular diplopia associated with subretinal neovascular membranes. *Arch Ophthalmol* 98:311, 1980.
29. Burian HM: Fusional movements in permanent strabismus. A study of the role of the central and peripheral retinal regions in the act of binocular vision in squint. *Arch Ophthalmol* 26:626, 1941.
30. Burian HM: Sensorial retinal relationship in concomitant strabismus. *Trans Am Ophthalmol Soc* 81:373, 1945.
31. Burian HM: Normal and anomalous correspondence. In Allen JH, ed: *Strabismus Ophthalmic Symposium I*. St Louis, Mosby-Year Book, 1950, p 130.
32. Burian HM: Anomalous retinal correspondence: Its essence and its significance in diagnosis and treatment. *Am J Ophthalmol* 34:237, 1951.
33. Burian HM: Adaptive mechanisms. *Trans Am Acad Ophthalmol Otolaryngol* 57:131, 1953.
34. Burian HM: Über neuere Erklärungsversuche der monokulären Diplopie bei Schielenden. *Klin Monatsbl Augenheilkd* 140:813, 1962.
35. Burian HM, Luke N: Sensory retinal relationships in 100 consecutive cases of heterotropia. A comparative clinical study. *Arch Ophthalmol* 84:16, 1970.
36. Campos EC: Some functional abnormalities in amblyopia. *Trans Ophthalmol Soc UK* 99:413, 1979.
37. Campos EC: Anomalous retinal correspondence: Monocular and binocular visual evoked responses. *Arch Ophthalmol* 98:299, 1980.
38. Campos EC: Binocularity in comitant strabismus: Binocular visual fields studies. *Doc Ophthalmol* 53:249, 1982.
39. Campos EC, Aldrovandi E, Bolzani R: Distance judgment in comitant strabismus with anomalous retinal correspondence. *Doc Ophthalmol* 67:229, 1988.
40. Campos EC, Bolzani R, Galdi G, et al: Recording of disparity vergence in comitant esotropia. *Doc Ophthalmol* 71:69, 1989.
41. Campos EC, Catellani T: Further evidence for the fusional nature of the compensation (or "eating up") of prisms in concomitant strabismus. *Int Ophthalmol* 1:57, 1978.
42. Campos EC, Zanasi MR: Die anomalen Fusionsbewegungen: Der senso-motorische Aspekt des anomalen Binokularsehens. *Graefes Arch Clin Exp Ophthalmol* 205:101, 1978.
43. Cantolino SJ, Noorden GK von: Heredity in microtropia. *Arch Ophthalmol* 81:753, 1969.
44. Cass EE: Strabismus—abnormal retinal correspondence. *Trans Ophthalmol Soc U K* 58:276, 1938.
45. Chavasse BF: Worth's squint or the binocular reflexes and the treatment of strabismus. Philadelphia, P Blakiston's Son & Co, 1939.
46. Ciancia AO: Sensorial relationship in A and V syndromes. *Trans Ophthalmol Soc U K* 82:243, 1962.
47. Cobb WA, Morton HB, Ettlinger G: Cerebral potentials evoked by pattern reversal and their suppression in visual rivalry. *Science* 216:1123, 1967.
48. Coffeen P, Guyton D: Monocular diplopia accompanying ordinary refractive errors. *Am J Ophthalmol* 105:451, 1988.
49. Crewther SG, Crewther SP: Amblyopia and suppression in binocular cortical neurons of strabismic cat. *Neuroreport* 4:1083, 1993.
50. Cüppers C: Moderne Schielbehandlung. *Klin Monatsbl Augenheilkd* 129:579, 1956.
51. Cüppers C: Grenzen und Möglichkeiten der pleoptischen Therapie. In Schider-Pleoptik-Orthoptik-Operation: Bücherei des Augenarztes, No. 38. Stuttgart, Ferdinand Enke Verlag, 1961, p 1.
52. Cynader M, Gardner JC, Mustari M: Effects of neonatally induced strabismus on binocular responses in cat area 18. *Exp Brain Res* 53:384, 1984.
53. de Belsunce S, Sireteanu R: The time course of interocular suppression in normal and amblyopic subjects. *Invest Ophthalmol Vis Sci* 32:2645, 1991.
54. Dengler B, Kommerell G: Stereoscopic cooperation be-

- tween the fovea of one eye and the periphery of the other eye at large disparities. *Graefes Arch Clin Exp Ophthalmol* 231:199, 1993.
55. Enos MV: Anomalous correspondence. *Am J Ophthalmol* 33:1907, 1950.
 56. Epstein DL, Tredici TJ: Microtropia (monofixational syndrome) in flying personnel. *Am J Ophthalmol* 76:832, 1973.
 57. Fogt N, Jones R: The effect of forced vergence on retinal correspondence. *Vision Res* 38:2711, 1998.
 58. Franceschetti AT, Burian HM: Visually evoked responses in alternating strabismus. *Am J Ophthalmol* 71:1292, 1971.
 59. Frantz KA, Cotter SA, Wick B: Re-evaluation of the four prism diopter base-out test. *Optom Vis Sci* 69:777, 1992.
 60. Frantz JM, Tomlinson E, Morgan KS: Vertical abnormal retinal correspondence: A case study. *Am Orthopt J* 37:71, 1987.
 61. Freeman AW, Jolly N: Visual loss during intraocular suppression in normals and strabismic subjects. *Vision Res* 34:2043, 1994.
 62. Graefe A. von: Über das Doppelsehen nach Schiel-Operationen und Incongruenz der Netzhäute. *Arch Ophthalmol* 1:44, 1854.
 63. Graefe A. von: Symptomenlehre der Augenmuskellähmungen. Berlin, Hermann Peters, 1867.
 64. Grant S, Berman NE: Mechanism of anomalous retinal correspondence: Maintenance of binocularity with alteration of receptive field position in the lateral suprasylvian (LS) visual area of strabismic cats. *Vis Neurosci* 7:259, 1991.
 65. Guzzinati GC, Salvi C: Ricerche sull'eventuale presenza di una visione stereoscopica negli strabici. *Ann Ottalmol* 83:417, 1957.
 66. Haase W, Wermann O: Postoperativer Mikrostrabismus. Handlungssicherheit in räumlicher Tiefe. *Klin Monatsbl Augenheilkd* 186:377, 1985.
 67. Halldén V: Fusional phenomena in anomalous correspondence. *Acta Ophthalmol Scand* 37:1, 1952.
 68. Halldén V: Suppression scotoma in concomitant strabismus with harmonious anomalous correspondence. *Acta Ophthalmol Scand* 60:828, 1962.
 69. Hansen AK, Swanljung H: Studies in the clinical investigation of retinal correspondence. *Arch Ophthalmol* 54:744, 1955.
 70. Harms H: Ort und Wesen der Bildhemmung bei Schielenden. *Graefes Arch Clin Exp Ophthalmol* 138:149, 1938.
 71. Harms H: Über die Untersuchung von Augenmuskellähmungen. *Graefes Arch Clin Exp Ophthalmol* 144:129, 1941.
 72. Harrad R: Psychophysics of suppression. *Eye* 10:270, 1996.
 73. Helveston EM, Noorden GK von: Microtropia, a newly defined entity. *Arch Ophthalmol* 78:272, 1967.
 74. Helveston EM, Noorden GK von, Williams F: Retinal correspondence in the A and V pattern. *Am Orthopt J* 20:22, 1970.
 75. Hering E: Zur Lehre vom Ortssinn der Netzhaut. Beiträge zur Physiologie, vol 3. Leipzig, Wilhelm Engelmann, 1861, p 182.
 76. Herzau V: Über die Prüfung der Netzhautkorrespondenz bei geringer Dissoziation. *Klin Monatsbl Augenheilkd* 168:769, 1976.
 77. Herzau V: Untersuchungen über das binokulare Gesichtsfeld Schielender. *Doc Ophthalmol* 49:221, 1980.
 78. Herzau V: Anomales beidäugiges Einfachsehen bei grossem Schielwinkel. Untersuchungen mit Schweiftest Gläsern. *Klin Monatsbl Augenheilkd* 178:81, 1981.
 79. Herzau V: How useful is anomalous correspondence? *Eye* 10:266, 1996.
 80. Hirai T, Arai M, Sato M: Modified Bagolini striated glass test: Clinical applications of starlight test in binocular visual field testing. *Br J Ophthalmol* 82:1288, 1998.
 81. Holopigian K: Clinical suppression and binocular rivalry suppression: The effects of stimulus strength on the depth of suppression. *Vision Res* 29:1325, 1989.
 82. Horton JC, Hocking DR, Adams DL: Metabolic mapping of suppression scotomas in striate cortex of macaques with experimental strabismus. *J Neurosci* 19:7111, 1999.
 83. Hugonnier R, Clayette-Hugonnier S: Strabismus, heterophoria, ocular motor paralysis. Clinical ocular muscle imbalance. Translated and edited by Véronneau-Troutman S. St Louis, Mosby-Year Book, 1969, p 201.
 84. Irvine SR: A simple test for binocular fixation: Clinical application useful in the appraisal of ocular dominance, amblyopia ex anopsia, minimal strabismus and malingering. *Am J Ophthalmol* 27:740, 1944.
 85. Jampolsky A: Retinal correspondence in patients with small degree strabismus. *Arch Ophthalmol* 45:18, 1951.
 86. Jampolsky A: Characteristics of suppression in strabismus. *Arch Ophthalmol* 54:683, 1955.
 87. Jampolsky A: The prism test for strabismus screening. *J Pediatr Ophthalmol* 1:30, 1964.
 88. Jampolsky A: Some anomalies of binocular vision. In *The First International Congress of Orthoptics*. St Louis, Mosby-Year Book 1968, p 1.
 89. Jampolsky A: Cited by Duke-Elder S, Wybar K: *System of Ophthalmology*, vol 6. *Ocular Motility and Strabismus*. St Louis, Mosby-Year Book, 1973, p v.
 90. Javal E: De quelques phénomènes de diplopie chez certains strabiques. *Ann Ocul* 54:123, 1865.
 91. Kawasaki K, Jacobson JH, Hirose T, et al: Binocular fusion. Effect of breaking on the human visual evoked response. *Arch Ophthalmol* 84:25, 1970.
 92. Kertesz AE: The effectiveness of wide-angle fusional stimulation in strabismus. *Am Orthopt J* 33:83, 1983.
 93. Kolling G, Schuy K: Statische Perimetrie beim Mikrostrabismus convergens und bei Vernebelung durch Plusgläser und Bangerter Folien. *Fortschr Ophthalmol* 83:507, 1986.
 94. Kommerell G: Das Fixierpunktskotom des schielenden Auges: Ein Artefakt? *Orthoptik Pleoptik* 13:29, 1986.
 95. Kommerell G: Monokulare Diplopie durch Druck des Oberlides auf die Hornhaut. *Klin Monatsbl Augenheilkd* 203:384, 1993.
 96. Kries J von: On changes in localization for anomalous adjustments of the eyes. In Southall JP, ed: *Helmholtz's treatise on physiological optics*. English translation from 3rd German edition. Ithaca NY, Optical Society of America. 1924. Dover reprint, New York, Dover Publications, 1962, vol 3, p 577.
 97. Kushner BJ: Fixation switch diplopia. *Arch Ophthalmol* 113:896, 1995.
 98. Lang J: Evaluation in small angle strabismus or microtropia. In Arruga A, ed: *International Strabismus Symposium (University of Giessen, 1966)*. Basel, S Karger, 1968.
 99. Lansing RW: Electroencephalographic correlates of binocular rivalry in man. *Science* 146:1325, 1964.
 100. Lawwill T, Biersdorf WR: Binocular rivalry and visual evoked responses. *Invest Ophthalmol* 7:378, 1968.
 101. Le Grand Y, quoted by Schober H, Leisinger KF: Einäugige Doppelbilder und Reafferenzprinzip und ihre Bedeutung für die Theorie des binokularen Sehraums und der Schielwinkelbestimmung. *Klin Monatsbl Augenheilkd* 130:824, 1957.
 102. Levinge M: Value of anomalous retinal correspondence in binocular vision. *Br J Ophthalmol* 38:332, 1954.
 103. Linksz A: *Physiology of the Eye*, vol 2. Vision, New York, Grune & Stratton, 1952, p 534 ff.

104. Lowe SW, Ogle KN: Dynamics of the pupil during binocular rivalry. *Arch Ophthalmol* 75:395, 1966.
105. Lyle TK, Foley J: Subnormal binocular vision with special reference to peripheral fusion. *Br J Ophthalmol* 39:474, 1955.
106. Mackensen G: Monokulare und binokulare statische Perimetrie zur Untersuchung der Hemmungsvorgänge beim Schielen. *Graefes Arch Clin Exp Ophthalmol* 160:573, 1959.
107. Maraini G, Pasino L: Variations in the fusional movements in cases of small angle convergent strabismus with harmonious anomalous retinal correspondence. *Br J Ophthalmol* 48:439, 1964.
108. Matsuo T, Ohtsuki H, Sogabe Y, et al: Vertical abnormal retinal correspondence in three patients with congenital absence of the superior oblique muscle. *Am J Ophthalmol* 106:341, 1988.
109. Mehdorn E: On the nature of suppression scotomas in strabismus. In Boschi MD, Frosini R, eds: *Proceedings of the International Symposium on Strabismus*, Florence, Italy, June 21–23, 1982, p 177.
110. Mehdorn E: Suppression scotomas in primary microstrabismus—a perimetric artefact. *Doc Ophthalmol* 71:1, 1989.
111. Morgan MW Jr: Anomalous correspondence interpreted as a motor phenomenon. *Am J Optom* 38:131, 1961.
112. Müller J: *Zur vergleichenden Physiologie des Gesichtsinnes des Menschen und der Thiere*. Leipzig, C. Cnobloch, 1826.
113. Naylor EJ, Stanworth A: Binocular depth perception in small angle squint. *Br J Ophthalmol* 43:662, 1959.
114. Nelson JI: Binocular vision: Disparity detection and anomalous correspondence. In Edwards K, Llewellyn R, eds: *Optometry*. London, Butterworth, 1988, p 217.
115. Noorden GK von: Symposium: Sensory Adaptations in Strabismus. Conclusion. *Am Orthopt J* 20:36, 1970.
116. Noorden GK von: Present status of sensory testing in strabismus. In *Symposium on Strabismus: Transactions of the New Orleans Academy of Ophthalmology*. St Louis, Mosby-Year Book, 1978, p 51.
117. Noorden GK von: *Atlas of Strabismus*, ed 4. St Louis, Mosby-Year Book, 1983.
118. Noorden GK von: Infantile esotropia: A continuing riddle (Scobee Lecture). *Am Orthopt J* 34:52, 1984.
119. Noorden GK von: A reassessment of infantile esotropia (XLIV Jackson Memorial Lecture). *Am J Ophthalmol* 105:1, 1988.
120. Noorden GK von, Helveston EM: *Strabismus: A Decision-Making Approach*. St Louis, Mosby-Year Book, 1994, p 68.
121. Nuzzi G, Cantù C, Camparini M: Second generation binocular Polaroid test. *J Pediatr Ophthalmol Strabismus* 33:235, 1996.
122. Ohm J: Klinische Untersuchungen über das Verhalten der anomalen Sehrichtungsgemeinschaft der Netzhäute nach der Schieloperation. *Graefes Arch Clin Exp Ophthalmol* 67:439, 1908.
123. Olivier P, Noorden GK von: The blind spot mechanism: Does it exist? *J Pediatr Ophthalmol Strabismus* 18:20, 1981.
124. Pasino L, Maraini G: Caratteristiche della visione binoculare anomala nell'ambiente. II. Movimenti fusionali in conseguenza di modificazioni della disparità orizzontale. *Ann Ottalmol* 89:681, 1963.
125. Pasino L, Maraini G: The importance of natural test conditions in assessing the sensory state of the squinting subject. *Br J Ophthalmol* 48:30, 1964.
126. Pasino L, Maraini G: The area of binocular vision in anomalous correspondence. *Br J Ophthalmol* 50:646, 1966.
127. Pasino L, Maraini G, Santori M: Caratteristiche della visione binoculare anomala nell'ambiente. III. Acutezza visiva stereoscopica. *Ann Ottalmol* 89:1005, 1963.
128. Pratt-Johnson JA, MacDonald AL: Binocular visual field in strabismus. *Can J Ophthalmol* 11:37, 1976.
129. Ramachandran VS, Cobb S, Levi L: The neural locus of binocular rivalry and monocular diplopia in intermittent exotropes. *Neuroreport* 5:1141, 1994.
130. Richards R: The syndrome of antimetropia and switched fixation in strabismus. *Am Orthopt J* 41:96, 1991.
131. Richter S: Untersuchungen über die Heredität des Strabismus concomitans. *Abhandlungen aus dem Gebiet der Augenheilkunde*, vol 23. Leipzig, VEB Georg Thieme, 1967.
132. Riggs LA, Whittle P: Human occipital and retinal potentials evoked by subjectively faded visual stimuli. *Vision Res* 7:441, 1967.
133. Romano PE, Noorden GK von: Atypical responses to the four-diopter prism test. *Am J Ophthalmol* 67:935, 1969.
134. Romano PE, Noorden GK von, Awaya S: A reevaluation of diagnostic methods for retinal correspondence. *Am Orthopt J* 20:13, 1970.
135. Rønne G, Rindziunski E: The diagnosis and clinical classification of anomalous correspondence. *Acta Ophthalmol* 31:321, 1953.
136. Rønne G, Rindziunski E: The pathogenesis of anomalous correspondence. *Acta Ophthalmol* 31:347, 1953.
137. Roundtable discussion. In Gregerson E, ed: *Transactions of the European Strabismological Association*, Copenhagen, Jencodan Tryk, 1984, p 215.
138. Savino G, Di Nicola D, Bolzani R, et al: Four diopter prism test recording in small angle esotropia: A quantitative study using a magnetic search coil. *Strabismus* 6:59, 1998.
139. Schildwachter von Langenthal A, Kommerell G, Klein U, et al: Preoperative prism adaptation test in normosensory strabismus. *Graefes Arch Clin Exp Ophthalmol* 227:206, 1989.
140. Schlodtmann W: Studien über anomale Sehrichtungsgemeinschaft bei Schielenden. *Graefes Arch Clin Exp Ophthalmol* 51:256, 1900.
141. Schober H, Leisinger KF: Einäugige Doppelbilder und Reafferenzprinzip und ihre Bedeutung für die Theorie des binokularen Sehraums und der Schielwinkelbestimmung. *Klin Monatsbl Augenheilkd* 130:824, 1957.
142. Sengspiel F, Blakemore S: Interocular control of neuronal responsiveness in cat visual cortex. *Nature* 368:874, 1994.
143. Sengspiel F, Blakemore C, Harrad R: Interocular suppression in the primary visual cortex: A possible neural basis of binocular rivalry. *Vision Res* 35:179, 1995.
144. Sengspiel F, Blakemore C, Kind PC, et al: Interocular suppression in the visual cortex of strabismic cats. *J Neurosci* 14:6855, 1994.
145. Silverberg M, Schuler E, Veronneau-Troutman S, et al: Nonsurgical management of binocular diplopia induced by macular pathology. *Arch Ophthalmol* 117:900, 1999.
146. Sireteanu R: Binocular vision in strabismic humans with alternating fixation. *Vision Res* 22:889, 1982.
147. Sireteanu R: The binocular act in strabismus. In Lenners-trand G, Ygge J, eds: *Symposium on Strabismus*, Wenner-Gren Center, Stockholm. London, Portland Press, 2000, p 63.
148. Sireteanu R, Best J: Squint-induced modification of visual receptive fields in the lateral suprasylvian cortex of the cat: Binocular interaction, vertical effect and anomalous correspondence. *Eur J Neurosci* 4:235, 1992.
149. Sireteanu R, Fronius M: Different patterns of retinal correspondence in the central and peripheral visual fields of strabistics. *Invest Ophthalmol Vis Sci* 30:2033, 1989.

150. Sireteanu R, Lagreze WD: Distortions in two-dimensional visual space perception in strabismic observers. *Vision Res* 33:677, 1993.
151. Smith EL, Levi DM, Manny R, et al: The relationship between binocular rivalry and strabismic suppression. *Invest Ophthalmol Vis Sci* 26:80, 1985.
152. Steffen H, Kruegel U, Holz FG, et al: Erworbene vertikale Diplopie bei Makuladystrophie als Modell für obligate Fixationsdisparität. *Ophthalmologie* 93:383, 1996.
153. Steinbach M: Alternating exotropia: Temporal course of the switch in suppression. *Invest Ophthalmol Vis Sci* 20:129, 1981.
154. Strazzi A: La corrispondenza retinica nello strabismo funzionale. *Boll Ocul* 29:517, 1950.
155. Swan KC: The blind-spot syndrome. *Arch Ophthalmol* 40:371, 1948.
156. Swan KC: Blind spot mechanism in strabismus. In Allen JH, ed: *Ophthalmic Strabismus Symposium II*. St Louis, Mosby-Year Book, 1958.
157. Travers TàB: Suppression of vision in squint and its association with retinal correspondence and amblyopia. *Br J Ophthalmol* 22:577, 1938.
158. Tschermak-Seysenegg A von: *Introduction to Physiological Optics*. Translated by Boeder P. Springfield, IL, Charles C Thomas, 1952.
159. van Balen AT: The influence of suppression on the flicker ERG. *Doc Ophthalmol* 18:440, 1964.
160. Verhoeff FH: Anomalous projection and other visual phenomena associated with strabismus. *Arch Ophthalmol* 19:663, 1938.
161. Walls GL: The problem of visual direction. *Am J Optom* 28:55, 115, 173, 1951.
162. Walraven F, cited by Kramer ME: *Clinical Orthoptics: Diagnosis and Treatment*. St Louis, Mosby-Year Book, 1949, p 349.
163. Wright KW, Fox BE, Eriksen KJ: PVEP evidence of true suppression in adult onset strabismus. *J Pediatr Ophthalmol Strabismus* 27:196, 1990.

Examination of the Patient—IV

AMBLYOPIA

One of the most dramatic sensory anomalies common in strabismus is the low visual acuity of one eye, known by the term *amblyopia*. This term means literally “dullness of vision” (G. *ambly* dull, + *ops*, vision, sight). It indicates a decrease of vision, not complete blindness, but does not specify the cause. The term is restricted to dullness of vision as found, for example, in patients with strabismus, anisometropia, or pattern vision deprivation. It is not applied to a decrease in vision caused by an uncorrected refractive error, opacification of the media, chorioretinal damage, or the like. It has acquired a specific meaning. In this meaning, amblyopia is defined as a *decrease of visual acuity in one eye when caused by abnormal binocular interaction or occurring in one or both eyes as a result of pattern vision deprivation during visual immaturity, for which no cause can be detected during the physical examination of the eye(s) and which in appropriate cases is reversible by therapeutic measures.*³³⁶

Albrecht von Graefe is said to have defined amblyopia as the condition in which the observer sees nothing and the patient very little.³⁸¹

Prevalence, Social and Psychosocial Factors

With the increasing visual demands of an ever more mechanized society, amblyopia, as defined

above, is a growing socioeconomic problem. It is difficult to assess the frequency of amblyopia in the general population. Some rather large-scale studies have been done, but they refer to selected populations, such as military draftees, soldiers, schoolchildren, certain patient groups, and ametropes. The figures vary with these populations and with the visual acuity criterion adopted. They range from 1.0% to 3.2% among military recruits, to 0.5% to 3.5% in preschool and school-age children, to 4.0% to 5.3% in patients with ophthalmic problems (Table 14–1). From all these numbers one can reasonably assume that 2.0% to 2.5% of the general population have amblyopia.

In a recent population-based study, aimed to determine the prevalence, causes of, and associations with amblyopia in a defined *older population*, Attebo and coworkers¹⁸ evaluated 3654 people 49 years of age and older from an area west of Sydney, Australia. Amblyopia was diagnosed in 118 subjects, or 3.2% of the population, using a visual acuity criterion of 20/30 or less and 2.9% using a visual acuity criterion of 20/40 or less. Using a two-line visual acuity difference between the two eyes, the prevalence of amblyopia was 2.6% and 2.5%, respectively, for the above criteria.

This is a considerable number and in the current population of 280 million in the United States

would amount to about 7 million amblyopes. Comparisons made by some authors are interesting but must be accepted with some caution. Sachsenweger³⁹⁰ stated that during the first 45 years of life amblyopia is responsible for loss of vision in more people than all ocular diseases and trauma put together. This view received support from Evens and Kuypers¹³² who observed that among 56,055 recruits, 852 had strabismic amblyopia with a vision below 3/10. In a second group of 56,879 subjects the figure was similar (867 cases). In the first group, in addition to the 852 amblyopes, the authors found 60 who had a high unilateral myopia and 80 with various unilateral conditions (cataract, chorioretinitis, retinal detachment, and sequelae of trauma). Thus in this young male population, amblyopia had caused severe unilateral impairment of vision 10 times more frequently than all other diseases and trauma.

Without question, amblyopia poses an important socioeconomic problem, especially since the risk of the amblyopic patient becoming blind is significantly higher than in the general population.⁴⁴¹ Vereecken and Brabant⁴⁵¹ reported on the basis of their experience and a questionnaire sent to 140 ophthalmologists that an improvement of visual acuity in the amblyopic eye after loss of the sound eye occurred in only 28.5% of 203

cases, either spontaneously (17.4%) or after pleoptic treatment (11.1%).

Krumpaszky and Klauss²⁵⁰ found that in 1% of subjects aged under 65 years amblyopia is listed as the cause of blindness when occurring in combination with another disorder such as chorioretinitis or cataract. In those aged over 65 years, amblyopia was listed as a cause of blindness in only 0.5% of cases, always in conjunction with retinal detachment.

One may wonder whether the increased attention paid in recent years by the media and medical community to early detection of strabismus has decreased the prevalence of amblyopia. Several studies indicate that this may not be the case; its prevalence has remained unchanged over the years.^{220, 241, 248, 375} On the other hand, Lennerstrand and coworkers compared data from a prevalence study conducted in Sweden in 1970 with those of a later study in 1998.^{255, 269} They showed a significant lowering of the prevalence of amblyopia in Sweden after introduction of the screening system and the availability of more extensive pediatric ophthalmology services. These differences are particularly pertinent with regard to the prevalence of deep amblyopia. *Early detection and treatment of amblyopia remain ideal goals to strive for, as documented by this and other population-based studies.*²⁵⁷

Certain conditions that are associated with amblyopia, such as primary microstrabismus (see Chapter 16), cannot be prevented. Moreover, the identification of risk factors such as heredity, failure to emmetropize, and high hypermetropia at the age of 1 year is not sufficient to justify preventive measures.⁴¹⁴ Such measures include photorefraction,³⁶⁵ the validity of which has been questioned,⁴⁰² and the prescription of early spectacles correction, based on photorefraction.¹⁷

It is important to ask whether amblyopia can be considered a handicap and whether it has any psychosocial effects. In a May 1997 survey of the Health Services Research Unit of Oxford University,⁴²⁰ both health personnel and people with amblyopia and their families were questioned on various subjects possibly related to this condition. These questions concerned limitations on career choice, driving ability, educational as well as social and personal development, and negative effects of treatment. The study concluded that amblyopia is disabling for a person wanting to enter a career for which high standards of vision have to be met and for the person who suffers from

TABLE 14-1. Prevalence of Amblyopia in Selected Populations

Populations	Percentage
Recruited soldiers	
Irvine ²³⁰	1.0
Helveston ¹⁹⁸	1.0
Theodore et al ⁴³⁵	1.4
Evens and Kuypers ¹³²	1.8
Glover and Brewster ¹⁶⁴	2.4
Downing ¹²¹	3.2
Preschool and school-age children	
Friedman et al ¹⁵⁸	0.5
Russell et al ³⁸⁶	1.3
DaCunha and Jenkins ¹⁰³	1.7
Flom and Neumaier ¹⁴⁵	1.8
McNeil ³⁰⁶	2.7
Frandsen ¹⁵⁴	3.1
Vereecken et al ⁴⁵²	3.5
Older population	
Vinding et al ⁴⁵⁴	2.9
Attebo et al ¹⁸	3.2
Ophthalmic patients	
Irvine ²³⁰	4.0
de Roeth ¹¹¹	4.5
Cole ⁹⁴	5.3

subsequent loss of vision in the nonamblyopic eye. However, this study did not support the belief that amblyopia is, in general, disabling. On the other hand, Packwood and coworkers³⁶⁷ concluded that psychosocial difficulties related to amblyopia affect an individual's self-image, work, school, and friendships. These consequences of untreated amblyopia must be explained to the parents so that they can make an informed choice about the necessity of treatment. *We are convinced that once a timely diagnosis of amblyopia is made, it is a professional as well as ethical duty of the practitioner to institute treatment.* In many instances equal vision in the two eyes can be achieved but even where this is not possible we do not know of data that have shown the treatment to be detrimental to a patient.

Classification and Terminology

At first glance, there appear to be fundamental differences in the etiologies of amblyopia caused by opacities of the ocular media, occlusion, strabismus, anisometropia, and uncorrected high refractive errors. In fact, Fankhauser and Röhler¹³⁶ have suggested that the term *amblyopia* covers a number of distinctly different abnormalities resulting from impairment at different levels of the retinocortical pathway. However, a synthesis of the results of clinical research and of basic research performed in animal models has provided sufficient evidence to propose that the basic mechanisms operative in many forms of amblyopia are similar, though not necessarily identical, and can be identified as *abnormal binocular interaction* and *foveal pattern vision deprivation* or a *combination of both factors*.³⁴¹ This similarity also is borne out by the fact that the time period during which children are likely to develop amblyopia is the same, regardless of the underlying cause. The age at which children are most sensitive to amblyopia is during the first 2 to 3 years of life, and this sensitivity gradually decreases until the child reaches 6 or 7 years of age, when visual maturation is complete and the retinocortical pathways and visual centers become resistant to abnormal visual input.³³⁹ The age limit of 6 years has been recently confirmed by Keech and Kutsche,²⁴³ who used statistical analysis. Milder forms of amblyopia may occur even after this period from visual deprivation (traumatic cataract) and

are usually rapidly reversible by occlusion therapy. Other sensorial adaptations, such as suppression and anomalous retinal correspondence, are most likely to occur during the same age range as does amblyopia.

In spite of the similarities of the basic amblyopiogenic mechanisms, certain clinical differences exist between *strabismic*, *anisometropic*, and *visual deprivation amblyopia* in terms of severity, reversibility, and psychophysical characteristics. These differences are discussed later in this chapter.

It has been customary to distinguish between *reversible* (functional) and *irreversible* (organic) types of amblyopia. This differentiation becomes tenuous if one considers that reversibility of amblyopia may be determined by the ability of the visual system to recover from the neurophysiologic, anatomical, and perhaps neurochemical consequences of abnormal visual input early in life. Thus recovery depends on the stage of maturity of the visual connections at which abnormal visual experience began, the duration of deprivation, and the age at which therapy was instituted. It follows that reversibility, and with it the concept of a functional nature of the impairment, may well be a quantitative rather than a qualitative point of differentiation and that irreversibility may merely characterize the most severe form of amblyopia.³³⁶ This does not detract from the possibility that there are patients with loss of vision in one eye caused by retinal damage that is not detectable with the ophthalmoscope and for which the term *organic amblyopia* is quite applicable.

Attempts have been made to classify amblyopia on the basis of a broad spectrum of shared clinical psychophysical and oculomotor abnormalities rather than on the traditional basis of etiology.³⁰³ Visual acuity as determined by different methods, contrast sensitivity, hyperacuity, optokinetic nystagmus velocity, and binocular summation were determined in a group of amblyopes in a multicenter prospective feasibility study. Using the statistical method of cluster analysis, subjects were grouped according to similar performance on a variety of these measurements. Paliaga³⁶⁸ proposed a classification of amblyopia based on the practical importance of the visual deficit, on the treatment prognosis, and on the results. An attempt has also been made to classify amblyopia on the basis of response to treatment. With this aim and to define the nature of the functional visual loss, Simmers and coworkers⁴⁰⁷ correlated several mea-

asures of visual acuity such as high contrast linear, single optotype, repeat letter, and low contrast linear acuities, plus Vernier and displacement thresholds in patients who underwent occlusion treatment.

The above approaches, if employed on a larger scale, may eventually yield useful information on the pathophysiology of amblyopia and, perhaps, even lead to a different classification. However, at this time we see no reason to abandon the clinically useful classification that is used throughout this book. This classification is based on the etiology of amblyopia.³³⁰ Because the emphasis of this book is on strabismus, amblyopia resulting from other causes will be considered only briefly.

Strabismic Amblyopia

Patients with strabismus who strongly favor one eye for fixation and who have a unilateral rather than an alternating fixation pattern are most likely to acquire strabismic amblyopia. In a survey of 5000 patients with infantile esotropia Schiavi and coworkers³⁹¹ found that amblyopia developed at some stage in 734 patients. Conditions that could explain the loss of free alternation of fixation were present in all affected patients and included anisometropia, strabismus, or a history of previous occlusion for reasons unrelated to strabismus. Other authors have reported a much higher prevalence of amblyopia in infantile esotropia (see Chapter 16) and it is of interest that this prevalence dropped dramatically in a patient group not operated on until visual adulthood.⁷¹

One can expect to find amblyopia far more often in esotropes than in exotropes, because exotropia is often intermittent at its onset. The higher prevalence of amblyopia in esotropes may also be related to the nasotemporal asymmetry of the retinocortical projections. In esotropia the fovea of the deviating eye has to compete with the strong temporal hemifield of the fellow eye. In exotropia the fovea competes with the weaker contralateral nasal hemifield.¹³⁴ Amblyopia occurs only rarely in hypertropes, who usually manage to maintain fusion in some positions of gaze with an anomalous head posture. Frandsen¹⁵⁴ reported that amblyopia is milder in small angle esotropia than in larger deviations; however, von Noorden and Frank³⁵¹ could not confirm this correlation in their patients.

Strabismic amblyopia is *always* unilateral and is caused by active inhibition within the retinocor-

tical pathways of visual input originating in the fovea of the deviating eye. This inhibition is the consequence rather than the cause of strabismus and is elicited by overlap of the different foveal images (confusion: see Chapter 13) transmitted to the visual centers from the retinas of the fixating eye and the deviating eye (Fig. 14–1). The etiology of strabismic amblyopia is similar to that of suppression. However, whereas suppression is restricted to binocular vision, and the visual acuity of each eye, when measured monocularly, is normal, amblyopia exists under binocular and monocular conditions. Thus amblyopia may be considered a carryover of suppression into monocular vision, giving rise to an alternative term, *suppression amblyopia*. It must be mentioned, however, that amblyopia may also occur occasionally in strabismus without suppression of the fovea of the deviated eye.³⁹¹ Thus, suppression alone cannot always be the cause of amblyopia.^{78, 218, 391} and other, still unknown factors may contribute to it.

An older concept, developed by Chavasse,⁸⁷ who coined the term *amblyopia of arrest*, implies that turning and consequent disuse of one eye will arrest the development of visual acuity. According to Chavasse, visual acuity remains at the level of development present at the time strabismus occurred. Linksz²⁸³ expressed a similar thought when he stated that an eye did not become amblyopic but stayed amblyopic. Chavasse reported that if amblyopia of arrest is allowed to persist, then suppression amblyopia, which he termed *amblyopia of extinction*, would become superimposed on

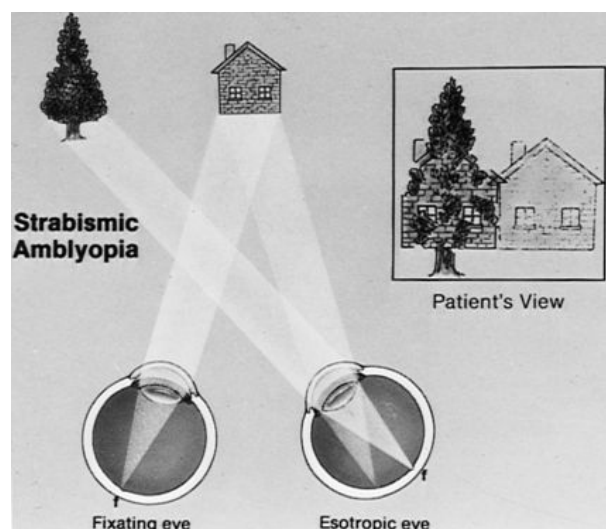


FIGURE 14–1. Visual confusion and diplopia caused by strabismus. (From Noorden GK von: *Amblyopia: A multidisciplinary approach* [Proctor Lecture]. *Invest Ophthalmol Vis Sci* 26:1704, 1985.)

it. Only that part of amblyopia attributable to inhibition could be reversed by therapy. This theory can no longer be supported in the light of our current knowledge. Sufficient clinical evidence is available to demonstrate that vision actually can be restored to a much higher level than was present at the onset of a constant unilateral ocular deviation.³⁴¹ The data of Costenbader and coworkers⁹⁸ show the duration of strabismus to be more closely correlated with the appearance of amblyopia than with the age of the child at the time the squint appeared.

Another, and indeed the oldest, view is that amblyopia is a result of disuse, as expressed by the term *amblyopia of disuse* (*amblyopia ex anopsia*, i.e., amblyopia from nonseeing). This term has been discarded in connection with strabismus because the amblyopic eye of a strabismic patient is not prevented from being used. Light enters it, and images are formed on the retina.⁵⁸ If the amblyopic eye of a strabismic patient is occluded, the patient will notice a loss in the field of vision and in many cases one can detect some cooperation between the amblyopic eye and its fellow eye. Central fixation is the only function for which some amblyopic eyes are not used habitually.

Ikeda and Wright²²⁷ reintroduced the disuse concept in connection with strabismic amblyopia. They showed in animal experiments that the fine spatial discrimination characteristic of high visual acuity depends on “sustained” retinal ganglion cells in the area centralis that require sharply focused, small objects as appropriate stimuli. Ikeda and Wright postulated that the image received by the fovea of the deviated eye is not only different from that in the fixating sound eye but also is out of focus unless the object corresponding to that image happens to lie at the same distance from the object of interest. The ineffective stimulation caused by depriving the foveal ganglion cells of the squinting eye of finely focused stimuli is said to cause a developmental anomaly in the neurons that provide fine spatial discrimination. Thus, according to Ikeda and Wright²²⁷ and Ikeda and Tremain,²²⁶ strabismic amblyopia may be caused by the lack of adequate stimulation of the fovea rather than active suppression of the input from the squinting eye.

That the mechanism proposed by Ikeda and Wright applies to strabismic amblyopia is unlikely for the following reasons:

1. Contrary to Ikeda’s view, the amblyopic eye in strabismus is not deprived of form or

contour. There is, in fact, no basis for the assumption that the fovea of the deviated eye always receives a blurred image. In a normal visually enriched environment, there will be any number of visual objects in visual space that are equidistant from the object fixated by the dominant eye and thus imaged on the fovea of the deviated eye. The salient feature of strabismic amblyopia is not the lack of afference but the incompatibility of visual impressions received by both eyes. Strabismic amblyopia is, as the late Hermann Burian once said to one of us (G.K.v.N.), “amblyopia of *misuse* and not of *disuse*!”

2. Amblyopia occurs in older children with documented normal visual acuity prior to or at the time of onset of strabismus, that is, at an age when the development of foveal anatomy and function has been completed.³⁴¹
3. Amblyopia is commonly more severe than the visual acuity established for normal infants at birth (see Chapter 11).
4. In support of Ikeda and Wright’s theory, one would expect some correlation between the depth of amblyopia and the angle of strabismus, but such a correlation does not exist.³⁵¹

It seems unwarranted to look at the retina as the primary site of amblyopia. However, this does not exclude the possibility of secondary retinal involvement. Retinal receptive fields have been shown to be altered in severe amblyopia^{75, 148} and anomalies of the electro-oculogram (EOG) have been reported.⁴⁶⁹ Campos and coworkers⁸³ found in a preliminary study that age-related maculopathy affects the amblyopic eye less commonly than the sound eye. They consider the possibility that amblyopia “protects” the inner retinal metabolism.

Anisometropic Amblyopia

Strabismus frequently is associated with anisometropia, and to determine whether the amblyopia in an anisometropic strabismic patient is caused by the strabismus, the anisometropia, or perhaps both is difficult.²³ This problem is complicated because in many anisometropic amblyopes with no apparent strabismus a more detailed examination will reveal microstrabismus (see Chapter 16). As in the case of strabismic amblyopia, there is active inhibition of the fovea in anisometropic amblyo-

pia; however, in the latter instance, the purpose of inhibition is to eliminate sensory interference caused by superimposition of a focused and a defocused image originating from the fixation point (abnormal binocular interaction) (Fig. 14-2). As a result of this binocularly elicited foveal inhibition, visual acuity of the anisometropic eye is lower under binocular conditions than when tested monocularly.²⁵ In addition to the reduction of central visual acuity there is an overall reduction of contrast sensitivity, which unlike in strabismic amblyopia involves the retinal periphery as well.^{82, 209, 409} If the anisometropia is optically corrected, the resulting aniseikonia may be another amblyopiogenic factor, since retinal images of different sizes also may present an obstacle to fusion.^{129, 232, 330}

Abrahamsson and Sjostrand⁴ followed 20 children to the age of 10 years who at the age of 1 year had greater than 3.0D of anisometropia. In some the anisometropia decreased and no amblyopia resulted. In others the anisometropia increased and all developed amblyopia.

On the basis of monkey experiments Kiorpes and Wallman²⁴⁵ raised the intriguing question whether unilateral hypermetropia associated with changes of axial length and anterior chamber depth may be the consequence rather than the cause of amblyopia. Artificial strabismus and unilateral defocusing during visual infancy was associated with amblyopia and anisohypermetropia,

the amblyopic eye being the more hypermetropic eye. The degree of anisometropia correlated well with the severity of amblyopia. Monkeys who did not become amblyopic did not develop hypermetropia.

Foveal pattern vision deprivation plays a further role in anisometropic amblyopia. As a rule, amblyopia is more common and of a higher degree in patients with anisohypermetropia than in those with anisomyopia,^{96, 232, 305} although contrasting views have been reported.²⁶ The retina of the more ametropic eye of a pair of hypermetropic eyes never receives a clearly defined image, since with details clearly focused on the fovea of the better eye, no stimulus is provided for the further accommodative effort required to produce a clear image in the fovea of the more hypermetropic eye.³⁰⁵ When myopia is unequal, the more myopic eye can be used for near work and the less myopic eye for distance. Therefore, unless the myopia is of a high degree, both retinas receive adequate stimulation and amblyopia does not develop.^{305, 373} However, since the degree of amblyopia cannot be consistently correlated with the degree of anisometropia,^{199, 221} it follows that pattern vision deprivation cannot be the only factor and that the abnormal binocular interaction that is caused by unequal foveal images in the two eyes also must play a role in the production of anisometropic amblyopia.

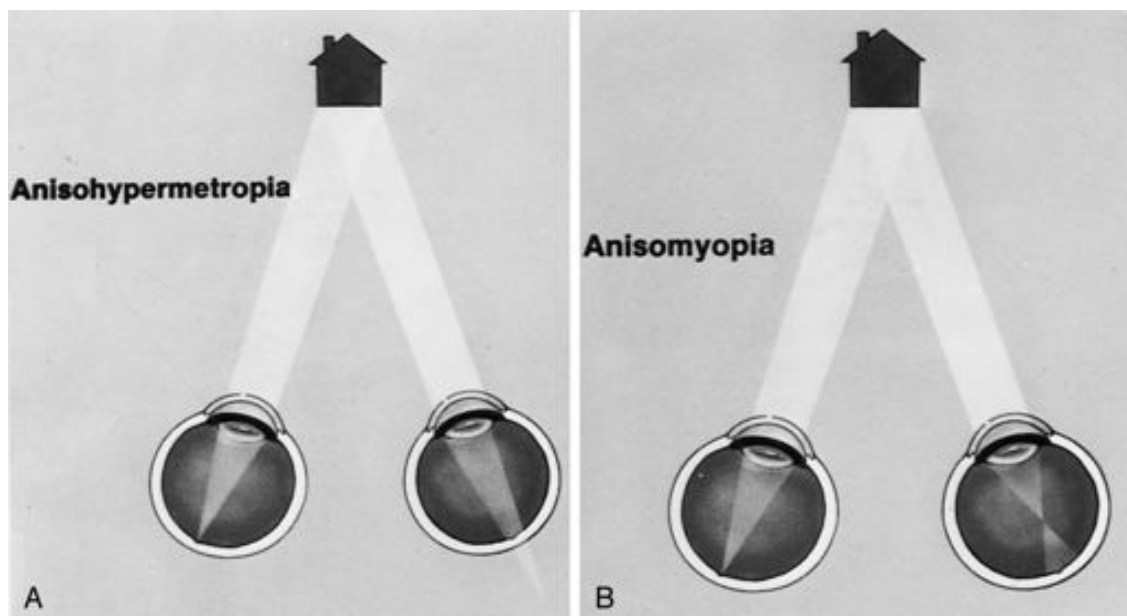


FIGURE 14-2. A, Anisohypermetropia and B, anisomyopia, causing the retinal image in the more ametropic eye to be out of focus. (From Noorden GK von: Amblyopia: A multidisciplinary approach (Proctor Lecture). Invest Ophthalmol Vis Sci 26:1704, 1985.)

Visual Deprivation Amblyopia (Amblyopia Ex Anopsia)

In the past, the term *amblyopia ex anopsia* was applied to all forms of amblyopia; however, the lack of foveal stimulation with well-focused images is not the only cause of anisometric amblyopia, and whether it is a factor at all in strabismic amblyopia is debatable. Thus, the use of the term should be reserved for a condition in which disuse or understimulation of the retina is the primary cause of poor vision.³³⁰ Such conditions exist in children with opacities of the ocular media, such as congenital or traumatic cataracts, corneal opacities, blepharospasm, surgical lid closure,^{9, 24, 185, 188, 334, 360, 405, 408} or unilateral complete ptosis. Bilateral ptosis is not amblyopiogenic because the patient maintains normal visual activity with a chin elevation. Visual deprivation amblyopia may also be produced iatrogenically in the formerly fixating eye of an amblyopic patient after prolonged and indiscriminate patching (*occlusion amblyopia*)^{62, 182, 333} or after prolonged unilateral atropinization.³⁶⁰

Visual deprivation amblyopia may be unilateral or bilateral (Fig. 14-3). The unilateral form usually is more severe and often accompanied by secondary (sensory) esotropia or exotropia. With regard to the pathophysiology of eccentric fixation (see p. 365), it is of interest that eccentric fixation may develop in the occluded eye, apparently on

TABLE 14-2. Mechanism of Amblyopia

Causes	Abnormal Binocular Interaction	Deprivation of Form Vision
Strabismus	+	-
Anisometropia	+	+
Visual deprivation		
Unilateral	+	+
Bilateral	-	+

a uniocular basis, in patients who do not have strabismus.^{62, 182, 333} In patients affected unilaterally because of a cataract or surgical lid closure, both pattern vision deprivation and abnormal binocular interaction are active amblyopiogenic factors (Table 14-2). In addition to the decreased optical quality of the image received by the fovea of the deprived eye, competition exists between this blurred image and the focused image received by the fovea of the healthy eye. On the other hand, if the optical quality of the images is decreased equally in both eyes, no such competitive situation is present and pattern vision deprivation is the only amblyopiogenic factor (see Table 14-2). This latter condition is caused by bilateral cataracts of equal density and, in a milder and usually reversible form,⁸⁶ by bilateral uncorrected high hypermetropia (Fig. 14-4) or astigmatism (*ametropic amblyopia*).³⁹⁶

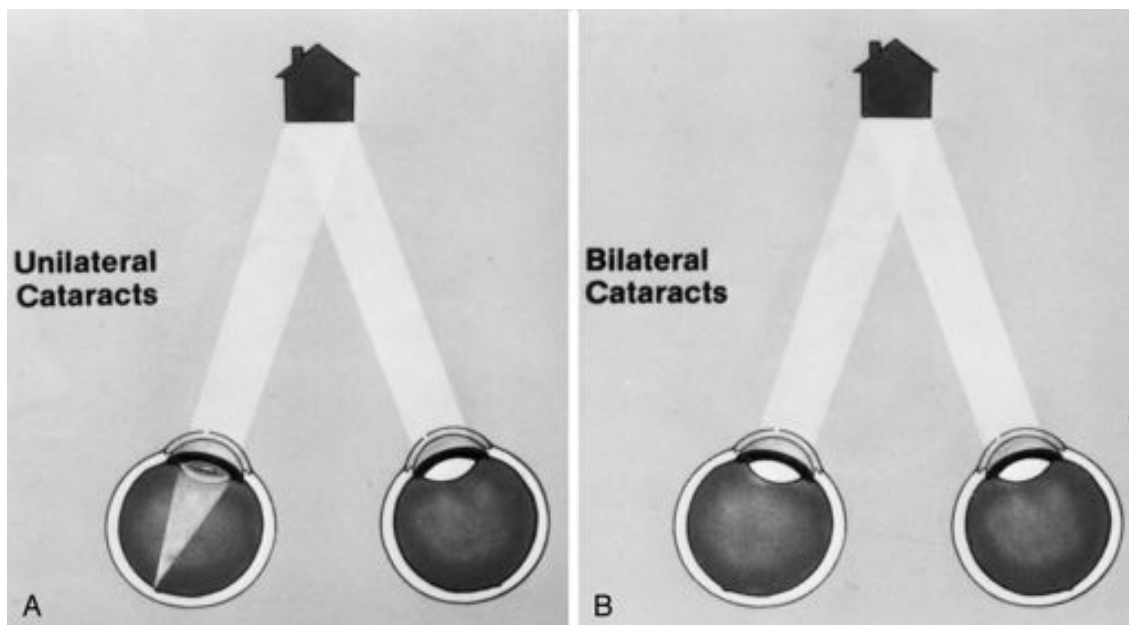


FIGURE 14-3. Only diffuse and reduced amounts of light enter the eye through the cataractous lens (A), or both lenses (B). (From Noorden GK von: Amblyopia: A multidisciplinary approach (Proctor Lecture). Invest Ophthalmol Vis Sci 26:1704, 1985.)

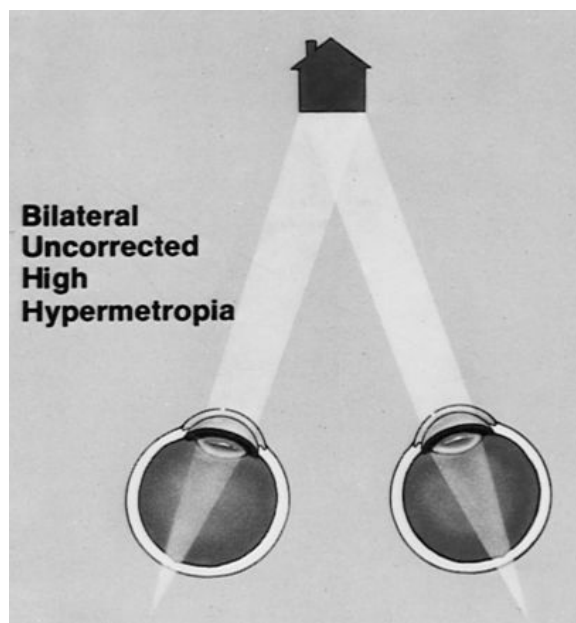


FIGURE 14-4. Blurred retinal images in both eyes in uncorrected high hypermetropia. (From Noorden GK von: *Amblyopia: A multidisciplinary approach* [Proctor Lecture]. *Invest Ophthalmol Vis Sci* 26:1704, 1985.)

Selective visual deprivation of visual stimuli of a certain spatial orientation is caused by uncorrected astigmatism (meridional amblyopia).^{298, 315} This explains why accurate cylindrical lenses do little to correct vision in certain astigmatic patients.

Idiopathic Amblyopia

An infrequently occurring and most intriguing form of unilateral amblyopia has been observed in the absence of the usual amblyopiogenic conditions and in apparently normal patients with a negative history for strabismus, uncorrected refractive errors, or visual deprivation.³⁴⁰ Since our description of the first two cases we have observed two additional patients with idiopathic amblyopia and another case has been reported in the literature.¹⁴¹ As in other forms of amblyopia, visual acuity improves after patching of the sound eye, but the amblyopia recurs when treatment is suspended. Clinically, such patients have foveal suppression of the amblyopic eye, and we have postulated that binocularly provoked inhibition has been conditioned during infancy by an amblyopiogenic factor, such as transient anisometropia that persists even though this original obstacle to bifoveal fusion is no longer evident. In support of this hypothesis are observations that clinically significant

astigmatism^{3, 315} or anisometropia^{2, 114, 229} in infancy may disappear with advancing age.

Organic Amblyopia

The absence of gross, readily detectable anomalies in an eye with reduced visual acuity does not exclude the possibility of subtle, subophthalmoscopic morphologic changes. Clinically, one may assume the presence of such changes if adequate amblyopia treatment improves vision in a patient only to a certain level but is unable to restore standard acuity to the eye^{233, 312} (so-called *relative amblyopia* of Bangerter²⁸). This would then indicate that a reversible amblyopia is superimposed on an irreversible one. Kushner²⁵²⁻²⁵⁴ has shown that relative amblyopia may also coexist in patients with organic loss of vision from recognizable structural anomalies of the ocular media, retina, or optic nerve and responds to occlusion treatment.

The first to suggest a specific cause for an organic anomaly resulting in a nonreversible amblyopia was Enoch,¹²⁷ who demonstrated that in some amblyopic eyes a malorientation of the retinal receptors exists. He did this by measuring the Stiles-Crawford effect, that is, the directional sensitivity of the retinal elements by means of a pencil of light moved across the pupil. He found not only various types of malorientation of the retinal elements but also some amblyopic eyes in which the retinal elements appeared to be properly oriented. The question arose in connection with Enoch's work⁶⁰ whether the well-known and frequent retinal hemorrhages of neonates might be an etiologic factor in a malorientation of the foveal receptors if such hemorrhages occurred in the central retinal regions. To cite just one example from a rather extensive literature, Sachsenweger³⁸⁹ found retinal hemorrhages in as many as 24% of 1025 neonates. However, several studies have failed to establish a correlation between neonatal foveal hemorrhages and the appearance of amblyopia later in life.^{51, 288, 354, 431}

Over the years, Enoch¹²⁸ further developed and broadened his work on *receptor amblyopia*, treating the retina as a fiberoptic bundle and investigating the optical characteristics of retinal receptors in normal and pathologic states. He has now concluded that in most patients with amblyopia the loss of central retinal resolution capability is *not* caused by disturbances in the physical or optical properties or in the malorientation of the retinal

fiberoptic bundle. The same conclusions were reached by Bedell,³⁶ who reinvestigated the role of photoreceptor misalignment in Enoch's laboratory, and were recently reiterated by Enoch.¹³⁰

Findings from animal experiments and histologic studies of brains from human amblyopes (see p. 286) have added a different dimension to organic amblyopia and have placed its seat more centrally than in the retina. One can reasonably assume that recovery of visual acuity depends on reversibility of the neurophysiologic and histologic anomalies that have been shown to exist in the striate cortex and lateral geniculate nucleus of cats and monkeys with experimental amblyopia and in the lateral geniculate nuclei (LGN) of human patients with anisometropic³⁴⁹ and strabismic³⁴⁸ amblyopia (see p. 282).

So-called *bilateral congenital amblyopia* has always been regarded as being organic, a theory confirmed by Goodman and coworkers,¹⁶⁷ who showed that these patients have low vision, nystagmus, poor color vision (achromatopsia), and defective photopic elements in their electroretinograms (ERGs). All these findings point to an irreversible, generally defective cone function, and these investigators therefore suggested that the older term *congenital amblyopia* be abandoned in favor of the term *cone deficiency syndrome*.

Amblyopia Secondary to Nystagmus

The effect abnormal eye movements have on visual threshold is significant in patients with nystagmus. Nystagmus may account for reduced visual acuity in its latent and manifest forms; however, one cannot always easily determine whether nystagmus is the cause or effect of reduced vision^{337, 338} (see Chapter 23). Nystagmus cannot always be detected on gross clinical examination because of its small amplitude and high frequency. Therefore, in the differential diagnosis of bilateral amblyopia, it is helpful to observe the fixation behavior in each eye during examination with the visuscope or a conventional direct ophthalmoscope containing a fixation target in one of the interchangeable disks. When micronystagmus is present, horizontal to-and-fro oscillations of the eye can be observed. These movements consist of a quick and a slow phase, may exist only in certain gaze positions, and are quite different from the irregular jerky fixation pattern in the strabismic

amblyope or the pendular slow-frequency nystagmus in blind patients or in those with defects of color vision or ocular pigmentation.³³⁰

Clinical Features of Strabismic Amblyopia

Fixation Preference

In children old enough to cooperate with the illiterate E test or to read the visual acuity chart, diagnosis of amblyopia presents no difficulties. The determination of visual acuity in younger children and infants is discussed in Chapter 11. In addition to the laboratory techniques mentioned there (grating acuity, preferential looking, visual evoked cortical potentials), the assessment of fixation preference is used by most clinicians and orthoptists as a more practical test for visual acuity differences between the two eyes. With free alternation one may safely assume that amblyopia is absent (Fig. 14-5). If a patient habitually prefers one eye for fixation, the degree of this preference may provide insight into the functional state of the habitually deviated eye (Fig. 14-6).

For instance, if a child repeatedly and strongly objects to having the fixating eye covered but does not mind if the cover is placed over the deviated eye, it is reasonable to assume that visual acuity in the deviated eye is severely reduced (Fig. 14-7). This conclusion is reinforced when the child

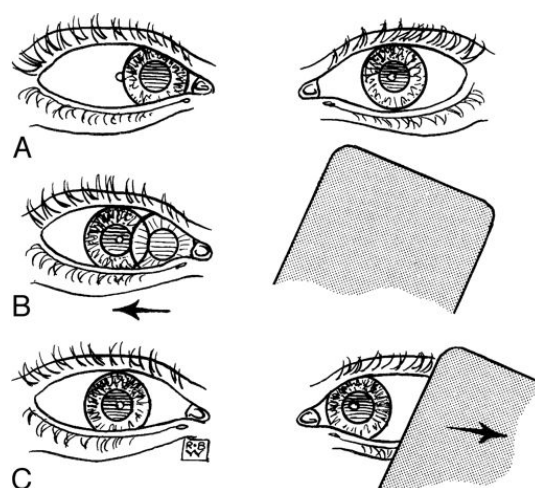


FIGURE 14-5. Alternating fixation. A, Patient with right esotropia. B, Covering of OS requires patient to fixate with OD; under the cover, OS turns inward. C, On uncovering OS, OD maintains fixation and OS stays turned inward. This fixation behavior suggests equal visual acuity in either eye. (From Noorden GK von: Atlas of Strabismus, ed 4. St Louis, Mosby-Year Book, 1983, p 63.)

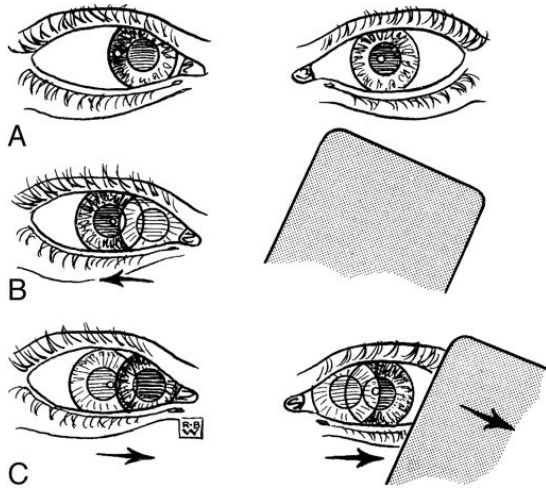


FIGURE 14-6. Fixation preference for OS. *A*, Patient with right esotropia. *B*, Covering OS forces the patient to fixate with OD. OS turns inward under cover. *C*, Removal of cover results in immediate return of fixation with OS and right esotropia. This fixation behavior suggests reduced visual acuity OD, especially when OD fixates unsteadily and performs searching movements while the left eye is covered (From Noorden GK von: Atlas of Strabismus, ed 4. St Louis, Mosby-Year Book, 1983, p 63.)

performs searching, nystagmoid movements with the deviated eye when the fixating eye is covered. From observing the length of time required for the fixating eye to resume fixation once the cover is removed, further information may be gained.^{247, 477} If this occurs after a few seconds and before the next blink, a strong fixation preference exists, and the deviated eye is probably amblyopic. However, when the formerly deviated eye holds fixation beyond the next blink, amblyopia is probably absent. For the diagnosis of amblyopia in microtropic or orthotropic children, fixation preference is more difficult to establish. Wright and coworkers⁴⁷⁴ suggested in such cases that an artificial hypertropia be induced by holding a 10-prism diopter prism with the base up or down before one eye.

Assessment of fixation preference is widely used in the presumptive diagnosis of amblyopia and often has to serve as the only guide to monitor the effect of occlusion therapy in preverbal children (see Chapter 24). However, caution is in order in interpreting this phenomenon. The clinician must be aware that even strong fixation preference may occur in the absence of amblyopia, especially in patients with small angle esotropias.^{155, 387, 473} Also, since it is generally impossible to achieve free alternation of fixation in patients who have reached full vision in the formerly am-

blyopic eye after the fifth year of age,⁷⁹ the evaluation of fixation preference as an indirect test of amblyopia is valid only for patients younger than 5 years. Contrary to traditional thought, the presence of crossed fixation (see p. 200) does not infer alternation and thus the absence of amblyopia.¹¹³ Specific attention should be paid to the point at which a switch of fixation occurs as the eye follows a fixation target from adduction to abduction.¹¹³ If there is equal visual acuity in both eyes this switch will occur close to the primary position. If amblyopia is present the sound eye will continue to follow the fixation target beyond the primary position into abduction before the amblyopic eye will take up fixation.¹¹³

Visual Acuity

What degree of reduction in visual acuity of one eye should be designated as amblyopia? Strictly speaking, any difference in acuity between the two eyes represents an amblyopia of the eye with the poorer vision, but a certain small difference is

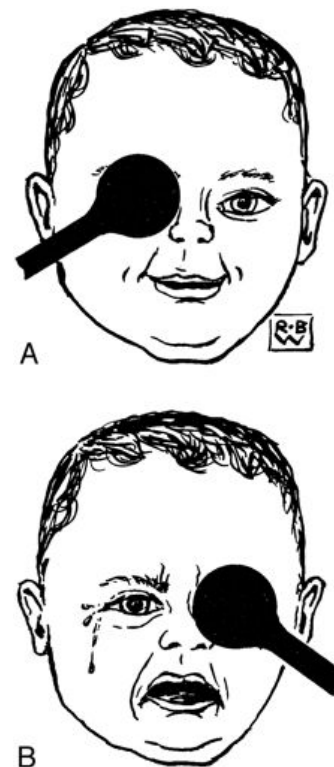


FIGURE 14-7. Strong fixation preference in a strabismic infant. *A*, A child with right esotropia may not object to having the deviated eye covered but protests occlusion of the dominant left eye. *B*, In this patient amblyopia of OD must be suspected. (From Noorden GK von: Atlas of Strabismus, ed 4. St Louis, Mosby-Year Book, 1983, p 65.)

common in the general population. From a practical clinical standpoint, a difference of two lines on a visual acuity chart is commonly used as a diagnostic criterion for amblyopia. However, a strabismic patient in whom visual acuity in the amblyopic eye has improved from, say, 6/30 to 6/7.5 must still be considered amblyopic when acuity in the fixating eye is 6/6. Paliaga³⁶⁸ pointed out that any and every difference in visual acuity produced by amblyopiogenic factors should be classified as an amblyopia.

EFFECT OF NEUTRAL DENSITY FILTERS. The use of neutral density filters is based on an observation by Ammann⁸ who found that neutral filters profoundly reduce vision in eyes with central retinal lesions and glaucoma, whereas the vision of eyes with amblyopia was not reduced by such filters and was occasionally even slightly improved. This anecdotal observation was confirmed in a study by von Noorden and Burian³⁴³ who introduced the *neutral density filter test* (Kodak Wratten gelatin filter No. 96, N.D.3.00) to distinguish reversible from organic amblyopia. The existence of the Ammann phenomenon was corroborated in subsequent studies.^{151, 212, 416} Analogous findings were obtained by Niermann and Dodt³²⁴ (see also Schmidt³⁹³) who recorded visual evoked response (VER) pattern threshold, amplitude, and latency at various levels of light attenuation in eyes with functional and organic amblyopia. Normal subjects and patients with strabismic amblyopia behaved similarly by exhibiting significantly smaller amplitude and latency changes than patients with poor vision from organic causes. The clinical value of the test was confirmed by Thomas and Spielmann.⁴³⁶ Caloroso and Flom⁷³ repeated the study of von Noorden and Burian³⁴⁴ and believed that their findings disprove the theory of relative improvement of visual acuity of the amblyopic eye with reduced illumination and in dark adaptation. However, comparison of their figures with those of von Noorden and Burian shows no disagreement. Their data demonstrate clearly, as do those of von Noorden and Burian, the relative increase in mesopic visual acuity of eyes with strabismic amblyopia in which acuity approaches and occasionally matches that of the normal eye under the same conditions (see also Hess and Howell²¹²).

Herzau and coworkers²⁰² found no improvement in visual acuity in amblyopic eyes with a neutral density filter but confirmed the difference

in the filter effect in amblyopia and in eyes with organic retinal lesions and optic atrophy. However, a certain overlap existed in the authors' data between the visual acuity reduction by filters in normals, amblyopes, and patients with organic lesions. This led them to conclude that the test is clinically useful in diagnosing organic amblyopia only when the reduction of acuity by a neutral density filter lies outside this overlap. From the standpoint of the theory of amblyopia, the effect of neutral density filters on visual acuity is important. The evidence is overwhelming that the amblyopic eye is not at its best under photopic conditions.

PHARMACOLOGIC EFFECTS ON VISION OF AMBLYOPIC EYES. Bietti and Scorsonelli⁴⁸ noted that anoxia deepens all suppression phenomena, whereas inhalation of oxygen alleviates them. These effects can be produced not only by inhalation of different gas mixtures but also by compression of the globe; extra oxygen supplied by subconjunctival injection produces the same effect as inhalation of oxygen. Bietti⁴⁷ also found that instillation of strychnine into the conjunctival sac has beneficial effects on visual acuity and that these effects are not transient. Gallois¹⁶¹ found that the use of vasodilators improved vision of amblyopic eyes.

Since the days of Nagel¹³²⁰ and von Hippel,²¹⁵ claims have been made that local or systemic application of strychnine can improve vision in various conditions of the retina and the optic nerve. These claims often have been repudiated. Whether the effect of strychnine on amblyopic eyes is different from that on normal eyes deserves further study, as does the effect of anoxia on the size of suppression scotomas.

Bárány and Halldén²⁹ found that central nervous system depressant drugs may weaken and even completely abolish retinal rivalry. Since they conceived of amblyopia as a phenomenon of suppression, closely related to retinal rivalry, and believed that the fixating eye inhibits the affected eye, they tried alcohol as a therapeutic agent³⁰ and found encouraging results in one adult.

It is tempting to speculate that the inhibitional mechanisms in amblyopia involve the synaptic neurotransmitters.³⁴¹ The older and often anecdotal observations cited above have been supplanted in more recent times by systematic studies of the effect of neurotransmitters, especially levodopa, on amblyopic vision. Duffy, Burchfield, and co-

workers^{57, 122–124} evaluated the effect of bicuculline a γ -aminobutyric acid (GABA) receptor blocker that causes catecholamine depletion, on reversing visual deprivation. If injected intracisternally in animals, substances involved in the maturation of the central nervous system delayed the maturation time and therefore eliminated the occurrence of amblyopia. Pettigrew and Kasamatsu³⁷² and Kasamatsu³⁷ used activation of the central norepinephrine system for the purpose of enhancing neuronal plasticity, and Kasamatsu²³⁸ reported that catecholamine depletion prevented the ocular dominance shift seen in kittens after monocular occlusion.

Maffei and coworkers injected nerve growth factor (NGF) into rats and found that exogenous NGF prevents the effects of deprivation, that is, the shrinkage of cells in the LGN and the functional and anatomical organization of the visual cortex.^{43, 115–117, 292} They speculated that loss of competition for the deprived eye is explained by the lack of neurotrophic factor. The monocular portion of the visual cortex of the deprived rats treated with NGF did not differ from that of the fellow eye. It is already known that many neurotrophic factors besides NGF are involved in the regulation of plasticity of the visual system. It is therefore tempting to predict that amblyopia will be preventable some day even in humans when these factors are fully understood and methods of administration developed.

Various attempts have been made to pharmacologically influence visual performance of human amblyopes, as neurotransmitters are presumably involved. Levodopa administered for as long as 1 week appears to provide positive results in the short term. These effects were explained in terms of the general role of dopamine both in the retina and in the visual pathway.^{168, 169, 186, 267, 268} Modest degrees of improvement of visual acuity (2.7 lines) and contrast sensitivity (72%) have been reported, which declined but were still significant 1 month after cessation of therapy.²⁶⁷ More recently, Leguire and coworkers²⁶⁸ found an improvement which lasted 6 weeks following cessation of treatment, with some side effects as nausea, headache, and mood changes. A more permanent effect on visual acuity of the amblyopic and of the sound eye that lasted as long as 4 months was reported by Campos and coworkers^{76, 84} after the use of cytidine-5'-diphosphocholine (citicoline), a drug that increases the level of consciousness in patients with head trauma and parkinsonism. Citicoline improves membrane adenosinetriphospha-

tase (ATPase) activity,³⁸³ and modulates the turnover of catecholamines and serotonin.⁷⁵ The age of these patients ranged from 12 to 40 years and thus was beyond the age at which improvement can usually be expected. Because an improvement was found in both eyes, diplopia never occurred after treatment. Porciatti and coworkers³⁷⁶ showed that citicoline in adult patients improves not only visual acuity but also contrast sensitivity and VERs. Campos and coworkers⁷⁷ evaluated the effect of citicoline in children with amblyopia. It was shown that after a 1-year follow-up visual acuity had improved more in patients treated with a combination of citicoline and part-time occlusion than in those treated only with citicoline or with part-time occlusion. It is noteworthy that no systemic side effects were found with this type of treatment. These studies are of theoretical and clinical interest. It is not quite clear at this point to what extent the neurotransmitter effect is specific for amblyopia, as these substances improve visual acuity in both eyes. Whether the pharmacologic treatment of amblyopia will one day have a firm place in our therapeutic armamentarium remains to be established.

CROWDING PHENOMENON. In patients with amblyopia it is always of interest and importance to compare the vision obtained with visual acuity symbols presented in a row to that obtained with isolated symbols on a uniform background. Many patients with amblyopia are capable of discriminating rather small visual acuity symbols when they are presented singly against a uniform background, whereas when presented in a row, as on a visual acuity chart, the symbols must be larger, often considerably larger, for a patient to be able to recognize them with the amblyopic eye. In other words, a frequent characteristic of amblyopic eyes is the inability to discriminate optotypes that are crowded together closely. This finding has been named the crowding phenomenon or *separation difficulties*. Thus most amblyopic eyes would seem to have two acuities, which could be designated as line acuity, or “Snellen” acuity, and single E acuity. The terms “morphoscopic acuity” for line acuity and “angular acuity” for single E acuity, used especially in the European literature, are misleading, since vision is always a complex process involving both “angular” (retinal) and “morphoscopic” (central recognition) factors.⁴³⁰ These terms should be avoided.

The difference between line acuity and single

E acuity varies greatly with different amblyopic eyes. This difference is generally greater when the line acuity is lower. In some patients the difference is quite startling, as when a line acuity of 6/30 corresponds to 6/6 symbols presented singly.

Little attention had been paid to the crowding phenomenon until the 1950s when there was an upsurge of interest in amblyopia studies. The first description in the literature of the crowding phenomenon in amblyopia was that of Irvine.²³⁰ The crowding phenomenon when first reported was thought to be specific for amblyopia, occurring only during occlusion or pleoptic treatment.³¹⁹ Cüppers¹⁰⁰ explained it on the basis of simultaneous normal and abnormal localization awakened by the treatment, leading to an overlay of the abnormally localized image over the images of objects adjacent to the centrally fixated one.

This view is not correct on a number of counts. The recognition of form is influenced by adjacent contours in both normal and amblyopic eyes. Snellen⁴¹⁷ (1873) has been credited with the observation that letters are less easily recognized when surrounded by other letters. Crowding is a universal phenomenon and has nothing to do with monocular diplopia.^{97, 126, 163, 430, 438} or visual confusion, as postulated by Cüppers.¹⁰⁰

Flom and coworkers¹⁴⁷ gave a quantitative description of the effect of contour interaction on visual resolution of normal and amblyopic eyes by evaluating the effect of black bars on the visibility of a Landolt C. They found that below a critical separation between the bars and the C, the probability of seeing the C decreased rapidly with further reduction in the separation. The critical separation was between 1.9 and 3.8 minutes of arc for normal eyes and between 8.4 and 23.3 minutes of arc for amblyopic eyes. Thus in absolute angular units the extent of interaction was considerably larger in amblyopic eyes; but in terms of the subject's minimum angle of resolution, that is, multiples of the size of the opening of the C visible to the amblyopic eyes, curves for the normal and amblyopic eyes were essentially similar. In other words, contour interaction was related to the patient's resolution capacity or visual acuity, a conclusion that Stuart and Burian also had reached on the basis of their study.⁴³⁰ Plotting their data in linear units of distance, Thomas-Decortis⁴³⁸ and Stuart and Burian⁴³⁰ found that amblyopic eyes exhibited the crowding phenomenon much more dramatically than did normal eyes but Stuart and Burian also showed that this phe-

nomenon may be related to the level of visual acuity. This was evident not only from scattergrams plotting line acuity against the linear separation of the symbols required to afford 80% of correct answers (Fig. 14–8) but also from data obtained by inducing an optic blur with lenses. When such a blur was induced, a definite increase in the crowding, or zone of interaction, was noted.

The crowding effect in normal eyes and its relation to visual acuity was also shown by Cordella,⁹⁷ who devised visual acuity symbols, both linear and isolated, for acuities exceeding 10/10. When subjects with normal visual acuity were presented with symbols ranging from size 11/10 to 15/10, the number of correct answers declined rapidly to less than 30% with 15/10 symbols displayed in a row, whereas about 80% of correct answers were obtained with the same symbols undisturbed by contour interaction. Haase and Hohmann¹⁷⁸ developed a test chart on which Landolt Cs are presented with constant angular separations. They recommended that this chart be used for quantitative determination of the crowding phenomenon.

From the foregoing it is clear that the crowding phenomenon is not specific to amblyopia (see also Morad et al³¹⁶) and is not related to anomalous correspondence, nor does one observe crowding only during the treatment of amblyopic eyes since about two thirds of patients with amblyopia exhibit the phenomenon on the first examination.⁸⁹ Contour interaction may not be the only factor in causing crowding and a reduction of lateral retinal inhibition (see p. 271) may play a role.²⁴⁰ Hess and coworkers²¹⁰ recently reported that crowding is caused less by inhibitory interaction than by the physical characteristics of the stimulus.

Reports on crowding in patients with *organic retinal lesions* vary. Müller³¹⁹ believed that crowding was not present in such patients and that this fact differentiated them from patients with reversible amblyopia. Thomas-Decortis,⁴³⁸ on the contrary, found essentially the same improvement with isolated symbols in patients with organic lesions as in patients with normal sight. Cibis and coworkers⁸⁹ noted no crowding in 40 patients who underwent surgery for retinal detachment with a resultant vision of 6/12 to 6/30, nor in eight patients with incipient maculopathy with acuities of 6/7.5 to 6/15. Campos and coworkers⁸⁰ measured VERs to optotypes arranged with different degrees of separation on a television screen. The degree of separation was without effect in normal patients

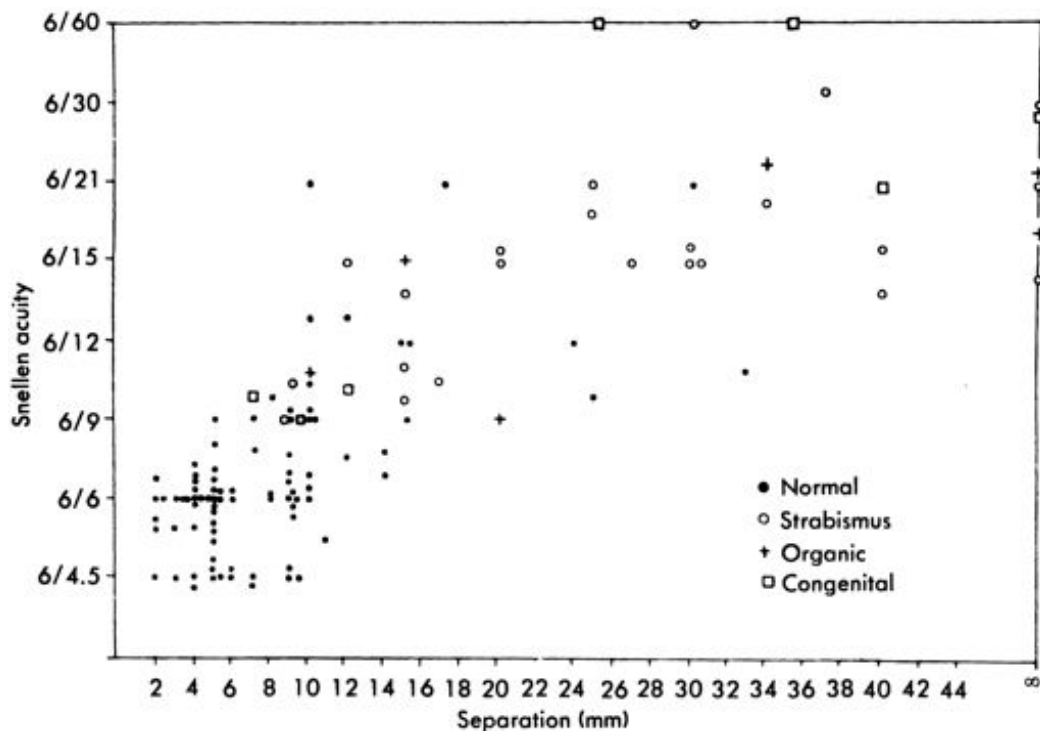


FIGURE 14-8. Scattergram demonstrating the dependence of the crowding phenomenon on line visual acuity. (From Stuart VA, Burian HM: A study of separation difficulty: Its relationship to visual acuity in normal and amblyopic eyes. *Am J Ophthalmol* 53:471, 1962.)

and in those with maculopathies, but had a significant influence on the VER of strabismic amblyopes.

In the course of treatment of amblyopia, *single optotype acuity improves more rapidly than line acuity*.⁴³⁰ Though not generally stressed, this fact is evident in all cases and is expressed in the frequent outcome of therapy in which single E vision is normalized but the line vision remains substandard. Thus the greater sensitivity of the amblyopic eye to the presence of contours near the fixated object remains the expression of an abnormality. Only if the line acuity of the amblyopic eye can also be made to reach the standard level and if the discrepancy is not greater than expected in normal eyes is there any prospect of maintaining good vision in the amblyopic eye. If standard line acuity is not or cannot be achieved, the probability is high that the vision of the amblyopic eye will regress significantly. Thus, at least at the completion of treatment, the presence or absence of the crowding phenomenon has significant prognostic value.

Opinions differ with regard to the *prognostic value* of the crowding phenomenon before treatment. High visual acuity with isolated symbols would seem *prima facie* to be a good prognostic sign. This thought has been expressed several

times in the literature,^{392, 430} but others^{89, 432} did not find the presence or absence of crowding to be helpful in estimating the amount of visual improvement to be achieved. The fact that an eye has potentially good visual resolving power, or at least a better visual resolution than indicated by its line acuity, does not itself prove that such optimal vision actually can be restored under all circumstances. Nevertheless, testing the vision of amblyopic eyes by means of isolated symbols and symbols in a row is of clinical value and should be carried out regularly. The emphasis in the literature has been persistently on reducing vision with symbols present in a line rather than on increasing it with isolated symbols. The above statements were further substantiated by the observation that the Sheridan-Gardiner single optotype test of visual acuity has a negative predictive value for amblyopia, as crowding is lacking in this test.³²⁰ Rydberg³⁸⁸ assessed visual acuity in adults with strabismic amblyopia and found that both single optotypes and preferential looking techniques lead to an overestimation of visual acuity. Thus, both of these techniques are unreliable as screening methods for amblyopia.

As pointed out, line acuity is what counts clinically and the amblyopic eye cannot be considered cured unless it has standard line acuity, but one

must not lose sight of the fact that the single E acuity represents the true potential functional ability of the eye, which is masked by the amblyopic process.^{450, 453} The crowding phenomenon must be considered in the design of visual acuity charts. Unfortunately, enormous differences exist in the separation of letters on currently available test charts and projection slides. One cannot help but gain the impression that the design of such charts is inspired more often by aesthetic than by physiologic considerations. As a result, the visual acuity of amblyopic patients may vary significantly when tested on different charts that are often used in the same office or clinic. This may lead to erroneous interpretations of the effect of therapy or the apparent lack of such an effect. Ideally, a visual acuity chart should be designed by taking under consideration contour interaction as a normal phenomenon and by correlating the separation between the letters and lines with the letter sizes. Such charts have been developed only in recent years and are available not only for letters of the alphabet¹³⁹ but also for illiterate acuity symbols.^{178, 217, 300}

VISUAL ACUITY IN DISTANCE AND NEAR FIXATION, THE BEHAVIOR OF ACCOMMODATION, REFRACTION, AND COLOR VISION. Visual acuity at near fixation has been found to be better than at distance fixation in a number of amblyopes. Cüppers¹⁰² referred to an improvement in the fixation pattern of the amblyopic eye in downward gaze. Von Noorden and Helveston³⁵¹ could not confirm Cüppers's theory, but in testing 46 amblyopic patients with the eyes in primary position, they did find an improvement in near visual acuity in 17 patients (37%), better acuity at distance in 9 (20%), and no difference in 20 patients (43%).

Other authors reported better distance than near vision in 40%⁴³⁶ and 47%⁴⁶³ of their patients, that these patients have a *remote near point of accommodation*, and that visual acuity at near could be improved with plus lenses.⁴³⁶ This seems to suggest that accommodation may be defective in amblyopia. Indeed, Abraham¹ was the first to point out that this may be the case, and his claim has been supported by several more recent studies. Otto and Safra³⁶⁶ reported erratic accommodation in amblyopic eyes that was also similar to that observed in eyes in which there is a central scotoma caused by organic disease of the macula or the optic nerve. Ciuffreda and coworkers⁹⁰ re-

ported that the accommodative response of amblyopic eyes was characterized by a reduction in the slope of the stimulus-response curve and increased depth of focus. These authors concluded from their work that reduced accommodative response in amblyopic eyes reflects a sensory loss of the foveal region that occurs from abnormal visual experience early in life. Hatsukawa and Otori¹⁹⁴ measured dynamic refractions of both eyes simultaneously with two modified Canon R-1 refractometers and considered that reduction of accommodative response in amblyopic eyes is mainly attributable to the afferent pathway of the accommodation control system. These findings confirm Abraham's original contention and have raised the question of whether optical correction of mild hypermetropic refractive errors in the amblyopic eye may be warranted during occlusion therapy³⁹⁷ or even after successful treatment.⁸¹ Several longitudinal studies have compared the change in refractive errors of normal and amblyopic eyes during growth and development and have shown that the eye with normal visual acuity becomes significantly more myopic with time.^{45, 265, 271, 321} No differences in refraction between the two eyes developed in strabismic patients without amblyopia. Interpretation of these interesting findings must remain speculative at this time.

Color sense in amblyopic eyes is often abnormal, especially when the amblyopia is severe. It seems, however, that the color vision defect resembles one detected in normal eyes when eccentric retinal areas are being tested.^{153, 297} Thus an erratic response in deep amblyopia could simply be a function of the eccentricity of fixation.³³² This argument is further substantiated by a recent study by Mangelschots and coworkers.²⁹³ These authors found that color contrast thresholds along the tritan axis measured with a computer-controlled color vision test are normal in patients with functional (reversible) amblyopic and central fixation. These findings suggest that the presence of changes in color sense in patients with questionable amblyopia could be used to differentiate between functional amblyopia and any superimposed organic factors.

Fixation Pattern of the Amblyopic Eye

For a long time it has been known that there is a class of amblyopic patients with *eccentric fixation*.

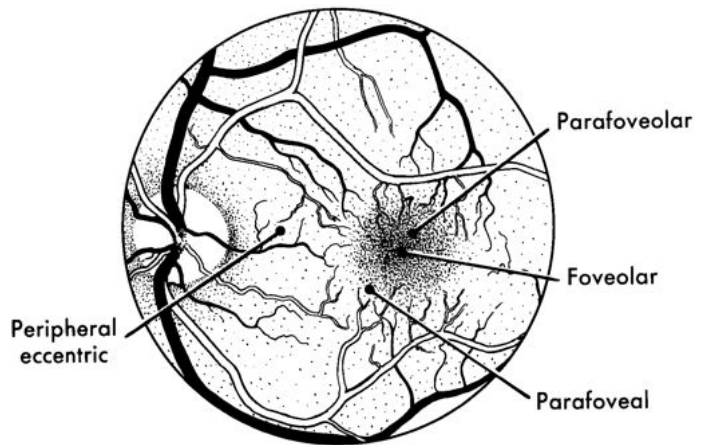


FIGURE 14–9. Schematic drawing showing the various types of nonfoveolar fixation.

Such patients do not assume central fixation when the fellow eye is covered; the amblyopic eye remains more or less deviated. In 1955 Bangerter²⁸ demonstrated that an amblyopic eye may fixate nonfoveolarly even if it appears to have central fixation on gross clinical tests. This observation assumed great importance during the 1950s and early 1960s when subtle modification of the fixation behavior had to be carefully monitored to chart the progress during active (pleoptic) treatment of amblyopia (see Chapter 24). In recent years the concept of a sensitive period for the development of amblyopia has reduced interest in anomalies of fixation. Early detection and treatment are now considered to be of foremost importance. As a consequence, most patients are examined and treated regardless of their fixation behavior and before they reach an age at which a reliable diagnosis of eccentric fixation becomes possible. These observations notwithstanding, we feel it is appropriate to discuss in detail anomalies of fixation which still pose many tantalizing questions and clinical problems and are often ignored in the current literature.

The variation in prevalence of eccentric fixation in strabismic amblyopia reported by different authors can only be explained by a lack of uniform diagnostic criteria. In a study published 40 years ago we found eccentric fixation in 44% of 433 amblyopic patients with strabismus.³²⁶ In anisometric amblyopia, eccentric fixation was encountered only rarely except in patients with microtropia (see Chapter 16). Recent data on the prevalence of eccentric fixation are lacking and as we are seeing and treating amblyopic patients at a much younger age than before it is our impression that eccentric fixation has become less frequent.

Bangerter's classification²⁸ of fixation patterns in amblyopia is as follows:

- I. Central fixation
- II. Eccentric fixation (nonfoveolar)
- III. No fixation

Nonfoveolar fixation may be divided into a number of classes, depending on the retinal area with which the eye appears to fixate (Fig. 14–9). Fixation may be *parafoveolar* (adjacent to the foveolar reflex), *parafoveal* (outside but close to the foveal wall), or *peripherally eccentric* (somewhere between the edge of the fovea and the disk and occasionally even beyond the disk). We have abandoned the term *paramacular fixation* used in our earlier publications because of the vague ophthalmoscopic definition of the macula. The general term *eccentric*, though logically applicable to all nonfoveolar patterns of fixation, is often restricted to peripheral fixation as defined here. Nonfoveolar fixation occurs not only with horizontal but also with vertical eccentricity; it should be nasal with esodeviations and temporal with exodeviations, but there are exceptions (see p. 262). Figure 14–9 may create the impression that nonfoveolar fixation is as precise as foveolar fixation. This is not the case. Nonfoveolar fixation always covers an area that is larger the farther it is from the fovea.³⁵⁷ Successively repeated ophthalmoscopic observations or, better yet, successive fundus photographs show this very clearly (Fig. 14–10)

Central as well as nonfoveolar fixation may be *steady* or *wandering*. Wandering fixation, which occurs only upon covering the sound eye, must be distinguished from the monocular, spontaneous, pendular, and vertical oscillations that are occasionally found in deeply amblyopic eyes. This

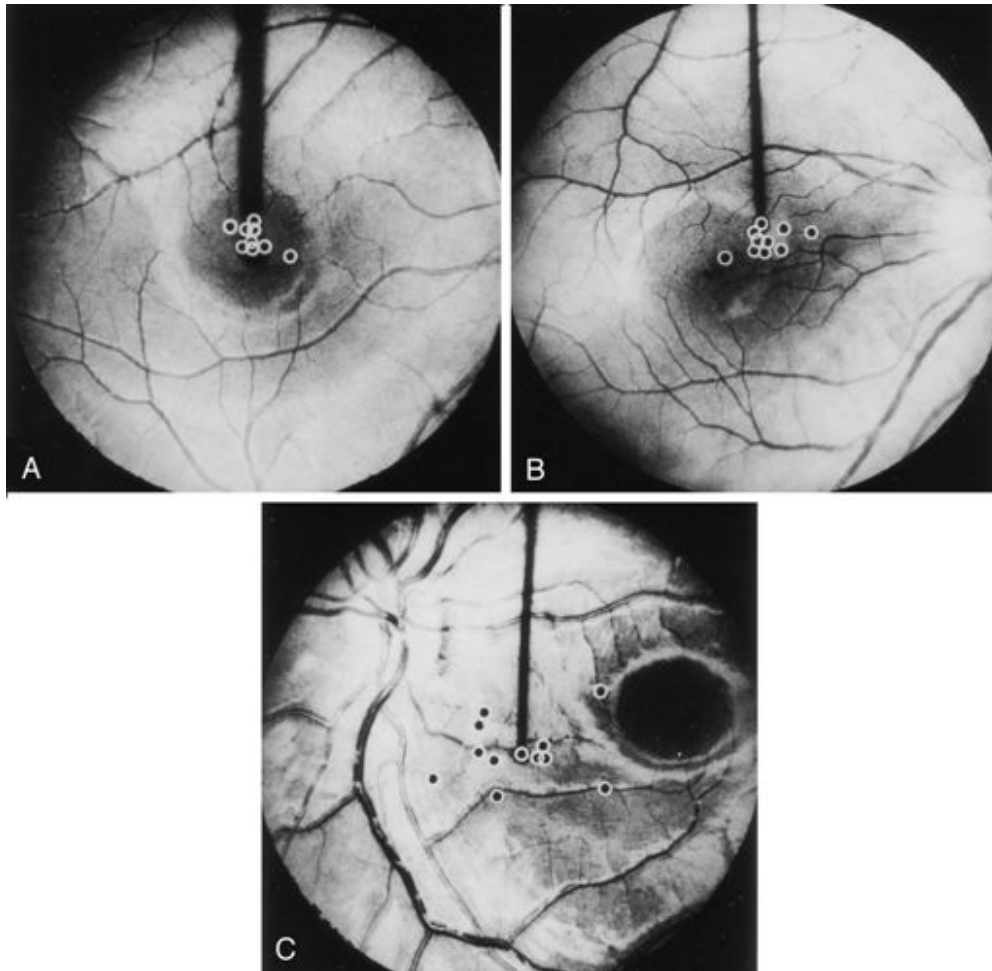


FIGURE 14-10. Fixation photographs of three amblyopic patients with *A*, foveolar, *B*, parafoveolar, and *C*, peripheral eccentric fixation. Each circle represents a fixation during which a photograph was taken. The different fixation locations on 9 to 12 consecutive photographs were superimposed on the photographs shown in this figure. Note the increasingly greater scatter with increasingly greater eccentricity. All three patients had a visual acuity of 6/60 despite the great difference in fixation pattern. (From Noorden GK von, Mackensen G: Phenomenology of eccentric fixation. *Am J Ophthalmol* 53:642, 1962.)

condition has been designated as the *Heimann-Bielschowsky phenomenon*.⁴¹⁹ It is clinically similar to other forms of monocular nystagmus that may occur in connection with a posterior fossa or brain stem disorder.

In patients with esotropia, one would expect a nasal eccentricity, and in patients with exotropia, a temporal eccentricity of fixation. This is actually the case in the majority of patients. There are, however, esotropic patients with temporal eccentric fixation and exotropic patients with nasal eccentric fixation (*paradoxical fixation behavior*). This type of fixation occurs most frequently in patients who have consecutive deviations following surgery; for example, a formerly esotropic patient with long-standing amblyopia becomes exotropic, or vice versa. However, paradoxical fixation may also appear as a primary anomaly. Op-

pel³⁶² noted that 15 out of 50 untreated esotropic patients (30%) fixated temporally, whereas von Noorden and Mackensen³⁵⁷ found 6 of 40 esotropic patients (15%) who fixated temporally, but only two of these had not been treated surgically.

DIAGNOSIS. Grossly eccentric fixation is readily established by holding a small light source in front of the patient's eyes in the midline of his head; the fixating eye is covered, and the patient is asked to fixate the light with the amblyopic eye. If the eye has grossly eccentric fixation, it will make no movement of redress, or perhaps only a small one, but the reflection of the light will not be centered in the pupil (Fig. 14-11).

To detect the more subtle forms of eccentric fixation, it is necessary to resort to ophthalmoscopic observation or to such entoptic phenomena

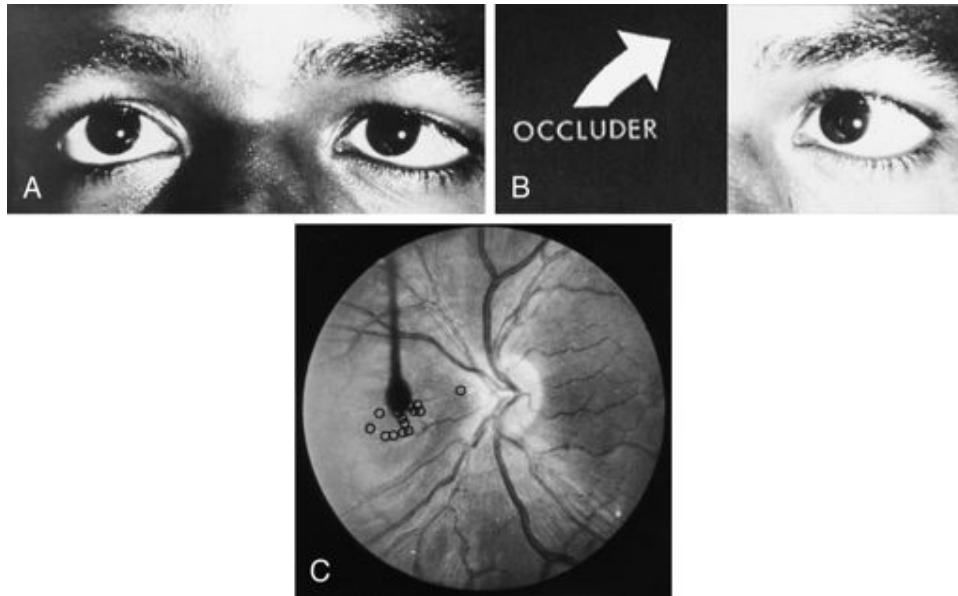


FIGURE 14-11. A, Temporally decentered light reflex OS. Visual acuity OS: 5/200. B, Light reflex OS remains decentered when OD is occluded. C, Series of fixation photographs of OS reveal fixation with a retinal area one disk diameter nasal to the optic disk. Each open circle represents a position of the fixation target on the retina when a series of photographs is taken. (From Noorden GK von: Atlas of Strabismus, ed 4. St Louis, Mosby-Year Book, 1983, p 35.)

marking the fovea as *Haidinger's brushes* or *Maxwell's spot*. Both phenomena were originally employed to assess the anatomical integrity of the fovea. However, with the advent of pleoptics (see Chapter 24) and the awareness that subtle fixation anomalies may exist in amblyopic eyes, additional diagnostic and even therapeutic applications of Haidinger's brushes or Maxwell's spot emerged. Haidinger's brushes are yellowish, brushlike shapes that seem to radiate from the point of fixation when polarized, preferably blue light is viewed. With central fixation the center of the brushes is superimposed on the fixation point; with eccentric fixation the brushes appear peripheral to the fixation point. Maxwell's spot is another entoptic phenomenon whereby the macular region is represented by a dark spot appearing in the blue region of the visible spectrum. Its position, relative to that of a fixation mark, should be a sensitive index of the retinal area used for fixation.

For routine use, the ophthalmoscope is the most convenient method to determine fixation behavior. As early as 1854 von Graefe¹⁷¹ had used the Coccius ophthalmoscope for this purpose by having the patient fixate the hole in the mirror with the amblyopic eye while closing the other eye. In this way he established that some esotropes fixated with a retinal area one or two disk diameters nasal to the fovea. This somewhat crude but effective method was completely forgotten. Cüppers¹⁰⁰ de-

vised a more refined system by designing the *visuscope*, an ophthalmoscope that projects a small star as a fixation object onto the retina. Its position on the retina indicates the area patient uses for fixation (Fig. 14-12). Other ophthalmoscopes, modified for the diagnosis of fixation behaviors, were developed^{307, 325} and many of the most recent commercially available direct ophthalmoscopes come equipped with a fixation target.

When any of these devices is used, the fixating eye is covered, the patient is asked to fixate the target, and the position of the mark on the retina is recorded on a suitable chart. Cüppers¹⁰⁰ and his followers have emphasized that it is not sufficient to determine objectively the position of the projected target on the retina to establish true eccentric fixation. One must also establish how the patient subjectively localizes the target. The patient is asked whether the target appears "straight-ahead." If it does, this indicates that the "straight-ahead" localization has shifted from the fovea to the eccentric area used for fixation and denotes "true eccentric fixation." If the eccentrically imaged target is not localized "straight-ahead" but "to the side," this indicates that the fovea has maintained its "straight-ahead" localization and the target is said to be seen in "eccentric viewing."³⁵⁷ This interpretation is based on the so-called anomalous correspondence theory of eccentric fixation (see p. 265).

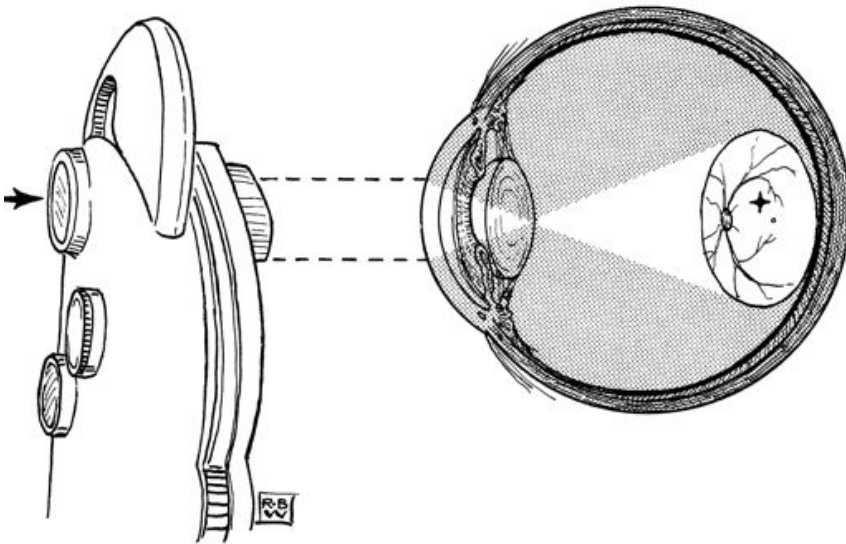


FIGURE 14-12. The visuscope. This is a modified ophthalmoscope that projects a fixation target on the fundus. The eye not tested is to be occluded. The examiner projects the fixation mark close to the fovea and the patient is asked to look directly at the asterisk. The position of the fixation target on the fundus is noted. (From Noorden GK von: Atlas of Strabismus, ed 4. St Louis, Mosby-Year Book, 1983, p 83.)

RELATION TO VISUAL ACUITY. An important consideration is the relation between the fixation pattern and visual acuity. The normal decrease in visual acuity as a function of the distance of the object image from the foveola is discussed in Chapter 2. Such a relationship must also hold true for the amblyopic eye, and it has been stated that the acuity of an amblyopic eye could be predicted from the position of the eccentric fixation area.^{146, 264} While there is a general trend for eyes with low visual acuity to have greater eccentricity of their fixation pattern,⁶⁷ factors other than eccentricity of fixation alone clearly supervene in determining the degree of visual acuity of an amblyopic eye. For instance, visual acuity as low as 6/60 may be associated with foveolar, parafoveolar, paramacular, and peripheral eccentric fixation.³⁵⁷

Trauzettel-Klosinski⁴⁴² analyzed fixation with a scanning laser ophthalmoscope in patients with hemianopic visual field defects, with an onset during adult life. She found eccentric fixation despite intact visual acuity, which was considered as a valuable strategy to improve reading performance. Fixation depended on stimulus size: foveolar fixation was used for stimuli requiring high resolution and eccentric fixation was used for larger targets and reading. Reading speed was increased in patients with eccentric fixation, as a sufficient reading visual field was thus obtained. This phenomenon is of particular interest as it provides additional evidence for a certain degree of adaptability of the fixation behavior in adults.

EFFECT OF DARK ADAPTATION. Observation of improved functioning of the amblyopic eye in low luminances led to investigation of whether the

fixation pattern underwent any changes in scotopic conditions. Lawwill²⁶⁰ studied this by using a modified binocular indirect ophthalmoscope equipped with infrared illumination and an observation device. In 20 amblyopic eyes, he found no change in area or steadiness of fixation, but he did notice that the fixation movements were considerably larger when the eyes were observed in bright light through the ophthalmoscope.

EFFECT OF EYE POSITION AND OPERATIONS.

The observation has been made that the fixation area of an amblyopic eye may change with changes in the direction of gaze, usually in the sense that in esotropes fixation becomes more eccentric in abduction and less eccentric in adduction.⁵⁰ Much theoretical importance has been attributed to this.^{299, 378} Von Noorden and Mackensen³⁵⁷ found in one third of 23 cases that such changes did occur. However, these changes were not consistent, so no systematic change in fixation pattern was evident. If ocular motility is mechanically limited, the distance between fixation area and foveola is likely to increase. Von Noorden and Helveston³⁵² reported such a case and pointed out that this phenomenon does not represent a change in eccentric fixation in the accepted sense of the word.

Similar considerations apply to increases in visual acuity in various directions of gaze. It is obvious that a patient with paralysis of a lateral rectus muscle who is unable to abduct his or her eye to the midline may have very poor vision in that eye with the head straight but may reach normal or about normal visual acuity with the

head turned so that the image of the test object falls on the foveola.

The improvement in visual acuity sometimes observed after operative straightening of the amblyopic eye does not require an explanation based on more or less conjectural innervational or proprioceptive mechanisms. Eyes capable of spontaneous visual improvement will improve if an operation places them mechanically in such a position that stimulation of the foveola by the object of attention is facilitated.

CLINICAL SIGNIFICANCE. The attention directed to the fixation pattern of amblyopic eyes is justified by the importance of that pattern for the prognosis and selection of treatment. In our experience steady and peripheral eccentric fixation is an unfavorable sign and unsteady and wandering fixation are more favorable prognostic signs. It does not follow that standard vision can be more readily and permanently restored to an eye that already has central fixation. On the other hand, as it is often difficult to be sure of the presence of central or eccentric fixation at an early age,¹⁷⁵ it is always appropriate to start treatment with direct occlusion. Inverse occlusion is sometimes indicated at the beginning of therapy in cases of steady eccentric fixation. Monitoring the fixation behavior in addition to checking visual acuity may be helpful during the treatment for amblyopia. Determination of the fixation behavior is indispensable to the diagnosis of microstrabismus (see Chapter 16).

PATHOGENESIS OF ECCENTRIC FIXATION. There are three theories to which no significant additional contributions have been made since the late 1960s. One theory, developed by Cüppers,¹⁰⁰ states that the “straight-ahead” sensation is no longer transmitted by the fovea but rather by some eccentric retinal area and because of this shift in subjective localization the patient no longer fixates with the fovea.

This concept is also the basis of differentiation between “eccentric fixation” and “eccentric viewing,” introduced by von Noorden and Mackensen.³⁵⁷ In eccentric fixation the patient reports that he looks “straight at” the object imaged on the nonfoveolar retinal area. These individuals are the only true eccentric fixators. A patient with eccentric viewing reports that he is “looking past” the object that he is asked to fixate.

Cüppers^{100–102} equated alleged loss of the “straight-ahead” sensation by the fovea with its

loss of the principal visual direction in anomalous correspondence. In anomalous correspondence an eccentric area of the retina assumes the principal visual direction.²⁰⁰ Cüppers argued that the eccentric area carries this new visual orientation over into monocular vision in amblyopic eyes, thereby establishing and maintaining extrafoveal fixation of the amblyopic eye. Because of this interpretation of the situation, Cüppers’s theory is often referred to as the *anomalous correspondence theory*. Cüppers’s hypothesis is quite untenable on theoretical grounds.^{59, 61} The basic fallacy is the equation of the “straight-ahead” sensation with the principal relative subjective visual direction of the foveola, resulting from a confusion between relative and egocentric localization.^{59, 61} In relative localization the visual objects are arranged subjectively in relation to the principal visual direction of the foveola and to each other. In egocentric localization they are arranged in relation to the egocenter or the body image (see Chapter 2). The foveola carries the “straight-ahead” sensation only in primary position of the eye but it maintains the principal relative subjective visual direction in all positions of the eye.

One can readily convince oneself of this by a simple experiment³³³ (Fig. 14–13). Close one eye and fixate an object with the other eye. Now look at another object at some distance to the right or left in the plane of the first object without moving the head. The first object remains “straight-ahead” with regard to the body; the second fixated object lies in the principal visual direction of the fovea. No change in *relative localization* has taken place; one is “looking at” the second object, although the first object remains “straight-ahead.” This is how a patient with eccentric fixation must see the object fixated nonfoveolarly, unless a change in egocentric localization has taken place for which there is no evidence. The fact that in anomalous correspondence the principal visual direction has been ceded by the foveola to an eccentric retinal area does not imply a change in egocentric localization, which remains undisturbed. This is also the reason why differentiation between “eccentric fixation” and “eccentric viewing” is unconvincing with regard to the pathogenesis of eccentric fixation. When one creates a central scotoma in a normal eye³⁵⁷ or when a patient has acquired an organic central scotoma, the fact that the patient “looks past” the fixated object simply means that he or she has also maintained normal relative subjective localization and

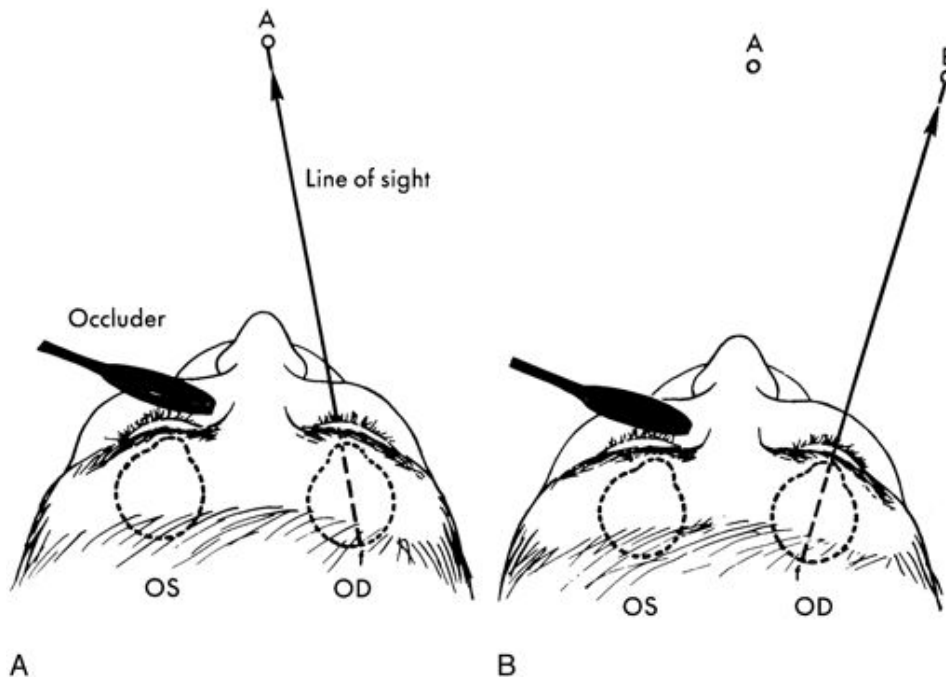


FIGURE 14-13. The difference between egocentric and relative localization. *A*, The line of sight coincides with point A, which lies in the subjective median plane. *B*, The subjective straight-ahead localization of point A remains unchanged when the line of sight is directed toward point B in the temporal field of vision. (From Noorden GK von: The etiology and pathogenesis of fixation anomalies in strabismus. *Trans Am Ophthalmol Soc* 67:698, 1969.)

localized the fixation object according to the secondary visual direction of the retinal area on which it is imaged.³³⁰

Cüppers¹⁰¹ found evidence for his correspondence theory of eccentric fixation in the fact that he never observed normal correspondence in patients with eccentric fixation and that in 50% of the cases the angle of anomaly coincided with the degree of eccentricity. A great deal of effort has been spent on verifying Cüppers's claim^{333, 357} and the results obtained have varied widely. Whatever the answer is, it can neither prove nor disprove Cüppers's theory. From what is known, one would expect most patients with eccentric fixation to display anomalous correspondence.

Opposed to this theory is the older, more conventional one, according to which eccentric fixation is the result of a foveal scotoma. According to this *scotoma theory* the amblyopic eye fixates with that retinal area adjacent to the scotoma that has the highest resolving power.^{6, 28, 50, 454, 472} Several authors have shown that this is indeed the case,^{19, 312, 363} but others have reported equivocal results^{205, 390} or have actually found the opposite, namely that visual acuity is as high or even lower in the eccentric fixation area than in the anatomical fovea.^{21, 22} Von Noorden³³² has warned about the nearly insurmountable difficulties in determin-

ing peripheral visual acuity in eccentric fixators because of the inability to maintain steady fixation (see Fig. 14-10), but believes that the stepwise improvement of the fixation behavior under the influence of occlusion treatment (Fig. 14-14) may provide indirect support for the scotoma theory.

An alternative explanation of the mechanism of eccentric fixation was given by von Noorden,^{326, 331, 333} who suggested that eccentric fixation may be caused by an *abnormal fixation reflex* (Fig. 14-15). In addition to its other functions, the fovea is also the *retinomotor center* or *retinomotor zero point* (see Chapter 2). A visual image falling on the peripheral retina of a normal eye (Fig. 14-15A) will elicit a fixation reflex that will cause the eye to move so that the image is shifted from the periphery (1) to the fovea (2). In acquired maculopathy (Fig. 14-15B) the fovea remains the center of oculomotor orientation, even though the function of the peripheral retina is superior. On occlusion of the sound eye, a saccadic movement will position the image from the periphery (1) to the fovea (2) where it may not be seen. Subsequent searching eye movements are then performed, and the image is eventually viewed with parascotomatous retinal elements (3). The patient will have the sensation of indirect vision and be aware that he or she must look past the object of

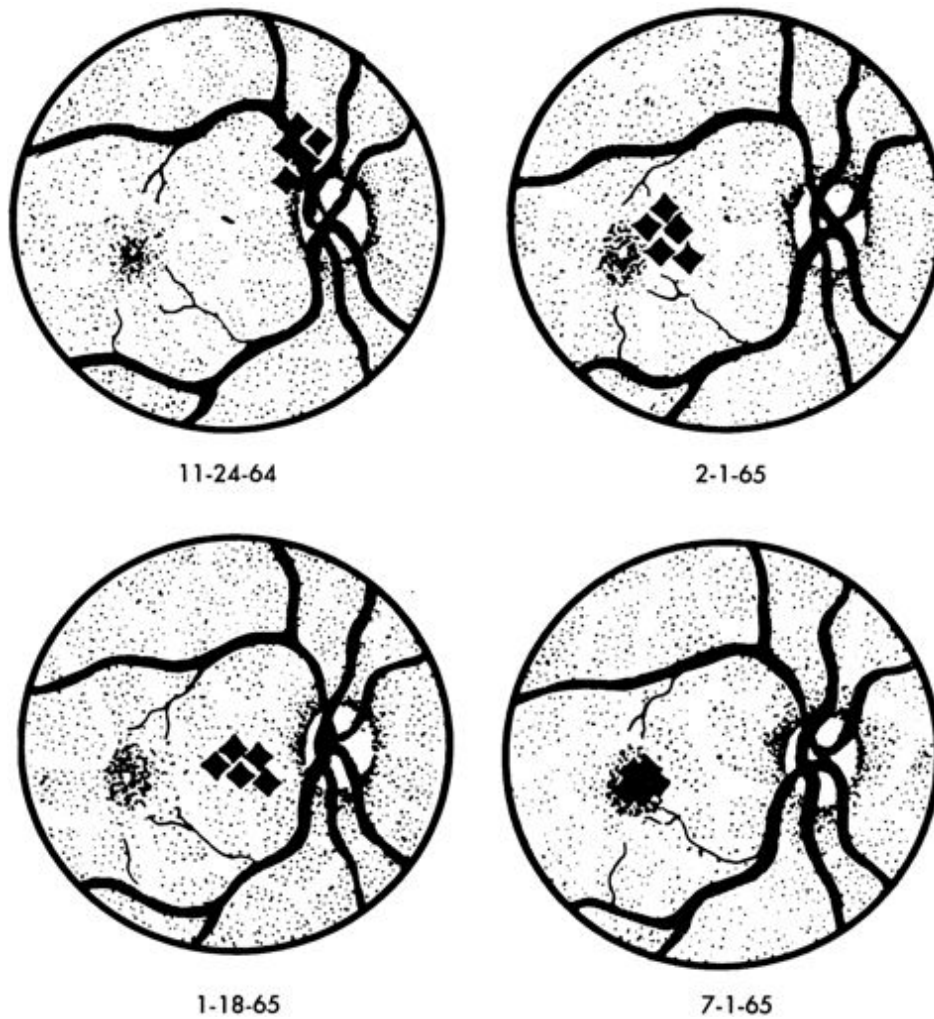


FIGURE 14-14. Stepwise normalization of the fixation behavior under the influence of occlusion of the left eye. (From Noorden GK von: The etiology and pathogenesis of fixation anomalies in strabismus. *Trans Am Ophthalmol Soc* 67:698, 1969.)

regard to see it. This sensation is comparable to that experienced when viewing a dimly lit object, such as a faintly shining star, with dark-adapted eyes³²⁹ or that can be reproduced experimentally in normal eyes in which a temporary foveal scotoma has been produced by dazzling.³⁵⁷

In amblyopic eyes the situation is quite different. The fixation reflex may become adjusted to the eccentric fixation area, perhaps because of decreased foveal visual acuity from suppression early in life at a time when the visual reflexes can be modified by abnormal conditions. The possibility that such a motor adaptation may exist was suggested initially by Bielschowsky.⁴⁶ When the image of a visual object attracting attention falls on peripheral retina (Fig. 14-15C, 1), the resulting saccadic movement will position the image directly on the eccentric fixation area (Fig. 14-15C, 2) without placing it first on the fovea. Thus the fovea has lost its zero retinomotor value, which

has now become associated with the eccentric fixation area. These observations can easily be verified by observing the fundus of an eccentric fixator with a visuscope or direct ophthalmoscope equipped with a fixation target.

From the foregoing discussion, it becomes obvious that a wide spectrum of sensory and motor adaptations exists that contributes to eccentric fixation. The variety of these mechanisms is analogous to other forms of sensory and motor adaptations of visual functions in strabismic patients, which may account for the futile attempts to explain eccentric fixation in a general manner based exclusively on one theory or another. Thus some amblyopes may fixate randomly at the margin of a central suppression scotoma to obtain better vision when the sound eye is covered. In others, the adaptation is more complete and the motor component of the fixation reflex becomes firmly associated with a paracentral retinal area that has ac-

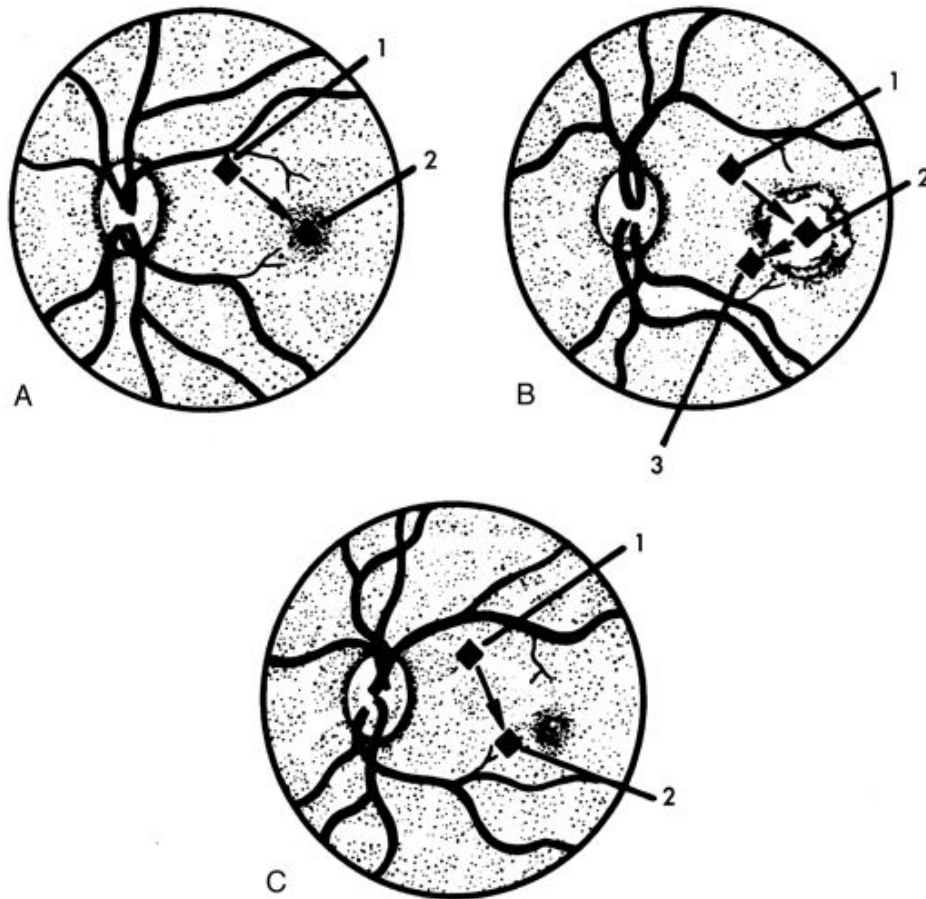


FIGURE 14-15. Fixation reflex in a normal left eye (A), in an eye with organic maculopathy (B), and in an amblyopic eye with eccentric fixation (C). For explanation, see text. (From Noorden GK von: The etiology and pathogenesis of fixation anomalies in strabismus. *Trans Am Ophthalmol Soc* 67:698, 1969.)

quired the foveal characteristic of being the center of oculomotor orientation. In others, the eccentric retinal area may be used during both binocular and monocular viewing, which is the most advanced form of adaptation. In that case anomalous retinal correspondence usually is present, and the angle of anomaly coincides with the angle of eccentricity of fixation. This situation is most frequently encountered in patients with microtropia (see Chapter 16).

BILATERAL ECCENTRIC FIXATION. Bilateral eccentric fixation may occur in patients without strabismus and with bilateral central scotomas caused by macular disease.^{15, 19} Two most unusual cases in which bilateral eccentric fixation was associated with strabismus were reported by von Noorden.³²⁸

The Sensitive Period

The capacity of the visual system to develop amblyopia is limited by its state of maturity. During immaturity of the visual system the retinocortical

connections are not firmly established and may be modified by the quantity or quality of the visual input. This phase has been described as the *sensitive, critical, or susceptible period*. Once the visual system has reached maturity, functional modifications by abnormal visual experience no longer occur. One must distinguish between a sensitive period during which amblyopia may develop, a sensitive period during which amblyopia, once treated and even cured, may recur, and a sensitive period during which amblyopia is reversible. These different sensitive periods are not identical and clinical experience as well as animal experiments have shown that there exist different sensitive periods for different sensory functions. The capacity to develop strabismic amblyopia extends up to the seventh year of life. After that age it would be most unusual for strabismic amblyopia to develop, although milder and reversible forms of visual deprivation amblyopia may occasionally still be observed.³⁵⁸ Individual variability is the hallmark of all sensitive periods; exceptions do

occur and may be related to interindividual differences in the rate of maturation of the visual system. The sensitive period during which strabismic amblyopia, once improved or even cured by treatment, may relapse extends beyond the seventh year of life and milder degrees of recurrence can occur as late as in the early teens.^{142, 173} The sensitive period during which recovery is possible is less well defined although there seems to be general agreement that it ends with the eighth year of life.^{16, 104, 131} On the other hand, it has been well established by clinical and animal studies that partial or even full recovery of visual acuity may take place in adult patients with strabismic amblyopia after loss of vision in the normal eye.^{10, 46, 246, 445, 451, 470} Similar recovery has been observed after enucleation of the sound eye in monkeys with strabismic amblyopia¹⁹³ but not in those with visual deprivation amblyopia.¹⁹²

Pathogenesis and Pathophysiology of Amblyopia

The mechanism of amblyopia continues to hold the interest of clinicians and visual scientists from various disciplines. The literature has expanded in recent years at an enormous pace. Since preparation of the last two editions of this book nearly 1200 articles have been published on this subject. The information contained in these reports alone could easily fill a book, and not all of it can or should be included in this volume. For supplemental information the reader is referred to recent reviews.^{75, 138, 149, 341}

Since the low vision of the amblyopic eye is not explained by demonstrable organic defects, it is of considerable theoretical and practical importance to investigate the visual functions of such eyes. For this purpose, psychophysical and electrophysiologic methods are available. Psychophysical methods are subjective methods in which responses of the amblyopic visual system to specific test situations are compared with responses of normal visual systems. The electrophysiologic methods are objective methods that record the electric responses, usually induced by photic stimuli, of various parts of the normal and amblyopic visual systems. In addition, studies of behavior of the pupils, making use of objective methods, must also be considered.

Psychophysical Studies

One question frequently raised relates to the location within the visual system of the disturbance responsible for the amblyopia. Results of psychophysical studies are often invoked to argue for a specific location. However, caution is necessary in making stringent assertions on this basis, since psychophysical findings represent a response of the total visual system and, in general, may not permit definite localization of the disturbance to a specific level of the system. Nevertheless, psychophysical investigations have contributed greatly to better understanding of the amblyopic process.

A comprehensive review of the voluminous literature on the subject was published in 1969 by Conreux and coworkers.⁹⁵

ABSOLUTE THRESHOLD AND BEHAVIOR OF LIGHT SENSE. As far back as 1884, Bjerrum⁴⁹ noted that there was no difference in the light sense of the amblyopic and the normal fellow eye. These findings were confirmed at a later date.^{5, 356} The first study using refined and critical methods for investigation of the light sense of amblyopic eyes was that of Wald and Burian.⁴⁵⁷ Using a 2° white test field, located 8° below the fovea and exposed as a flash of 40 ms duration, they found that the dark-adaptation curves of normal and amblyopic eyes could be superimposed. Furthermore, they found that the threshold contours or retinal profiles (the thresholds obtained with 1° stimuli at the fovea and at various distances above and below it) were similar in the amblyopic and normal eyes. Last, these authors established that the spectral sensitivity of the amblyopic eye (determined with a 1° centrally fixated target and with a 2° target placed 8° below the fovea) was in good agreement with that of the normal eye. Wald and Burian made several other observations and drew these conclusions⁴⁵⁷:

1. The amblyopic eye yields the typical responses and typical differences between center and periphery expected from normal eyes. The threshold of the amblyopic eye, therefore, is essentially normal both foveally and peripherally in rods and cones, and the entire apparatus of simple light perception is virtually normal in those eyes.
2. In the dark-adapted state, the amblyopic eye exhibits remarkably steady central fixation, even if the eye in ordinary clinical tests shows nonfoveolar or wandering fixation.
3. The whole amblyopic process seems to rep-

resent a dissociation between the (normal) light sense and the (impaired) acuity function.

4. Functionally, the amblyopic eye is at its best in mesopic and scotopic conditions and at its worst under photopic conditions.

The paper by Wald and Burian, which was confirmed by other investigators,^{233, 385} provided impetus for numerous studies, not only of the light sense but also of other functional responses of amblyopic eyes. Bedell and Kandel⁴¹ reported that differences in the dark-adaptation characteristics between normal and amblyopic eyes depend on preadaptation conditions. Opper and Kranke³⁶⁴ noted a higher cone threshold and an earlier onset of rod adaptation in amblyopic eyes than in the dominant eyes. However, as Lavergne²⁵⁸ pointed out, there was a wide scatter, and the differences between the amblyopic and control eyes were small and could be detected only by statistical analysis.

In any event, it is clear that a reduction in absolute threshold at the level of the cones is of an entirely different order of magnitude than the reduction in pattern vision and that the concept of a dissociation of pattern vision and light perception, suggested by Wald and Burian, has not been seriously challenged by more recent investigations.⁶³ Clear evidence for this was also given by Best and Bohnen,⁴⁴ who compared visual acuity and the threshold of the light sense, determined by the smallest, dimmest test object, just visible centrally on the Goldmann perimeter.

A last point of interest with regard to the retinal sensitivity of amblyopic eyes is the finding by Maraini and Cordella²⁹⁵ that there was no statistically significant difference in the recovery time between 20 normal and 20 amblyopic eyes when a glare stimulus was applied to the foveae of these eyes.

DIFFERENTIAL THRESHOLD. The differential threshold of retinal sensitivity, as contrasted with the absolute threshold, has also been investigated in amblyopic eyes. In testing the differential threshold, one asks how much brighter than its surroundings a test field must be so that it may be just perceived.

A number of workers studied this question, and most found a slight elevation of the differential threshold of amblyopic eyes, provided the test field was small enough, on the order of magnitude of a few minutes. In other words, a small, shallow

relative scotoma of the amblyopic eyes could be shown to exist. Various methods have been used to establish this fact, among them monocular static perimetry. Aulhorn¹⁹ reported on 70 amblyopes tested with this method, 35 of whom had foveolar or extrafoveolar depression, 26 had only flattening of the curve, and 9 had the normal foveolar peak in their sensitivity curve. Donahue and coworkers¹²⁰ recently revisited this problem, using automated perimetry. They found that all types of amblyopia are associated with a generalized depression of light sensitivity, which was proportionately greatest at the fovea and highly correlated with visual acuity loss.

A higher-than-normal central differential threshold was also found by EF Miller³⁰⁹ under photopic conditions using rectangular test objects in the shape of luminous bars or slits of different widths. Grosvenor¹⁷⁴ confirmed the work of Miller but added important amplifications by testing normal and amblyopic eyes over a wide range of exposure times and background luminance levels. He found that "the normal and amblyopic eyes have essentially equal thresholds at the absolute threshold level, which substantiates the work of Wald and Burian." In addition, the fact that the thresholds for the two eyes are not the same at higher luminance levels "bears out their prediction that amblyopia has its effects mainly at higher levels of luminance."¹⁷⁴ Because of the impaired differential threshold of the light-adapted amblyopic eyes, Harms¹⁸⁴ questioned the conclusion by Wald and Burian⁴⁵⁷ that the entire apparatus of simple light perception was normal in amblyopic eyes. However, Wald⁴⁵⁶ pointed out that every brightness discrimination involved some degree of form discrimination, which indeed is impaired in amblyopia. Jung²³⁴ explained the apparent contradiction between the findings of Wald and Burian and those of Harms by the following neurophysiologic considerations. The lateral inhibition, essential to contrast vision and visual acuity, disappears in dark adaptation, and spatial summation prevails. For scotopic vision there is no reduction in dark-light perception, and diffuse light perception is retained by the amblyopic eye. This favors a separate neuronal mechanism for brightness perception.

Herzau and coworkers²⁰¹ measured the differential light thresholds in the nasal and temporal visual field periphery in patients with strabismic amblyopia and found consistent threshold elevation in the nasal field. These data may be the

psychophysical correlate of our finding that in human strabismic amblyopia the LGN has the most pronounced cell shrinkage in layers connected with the temporal retina, which corresponds to the nasal visual field.³⁴⁸

Bowering and coworkers⁵³ evaluated the visual field with manual Goldmann perimetry in patients with deprivation amblyopia from congenital cataracts. They found in all children a restricted field, especially temporally, even when the deprivation began as late as 6 years of age and lasted less than 6 months. The restrictions were larger than those shown by the adults who developed cataracts. The restrictions were also larger after longer deprivation and monocular deprivation than after binocular deprivation. However, children who regularly patched the fellow nondeprived eye and, therefore, experienced less interocular competition, exhibited smaller restrictions temporally. Neither visual acuity nor optical factors could account for all of the restrictions in the deprived children.

SUMMATION AND RETINAL RECEPTIVE FIELDS.

EF Miller³⁰⁹ and Grosvenor¹⁷⁴ used luminous bars of different width but equal length to study spatial summation in the foveal region. The ability for spatial summation is high in the periphery. Furthermore, with dark adaptation, spatial summation improves over the whole of the retina but more particularly in the central region. Miller found that for narrow bars the brightness difference required for recognition is inversely proportional to the width, but there is a critical width beyond which further increments in luminance do not affect the threshold. In normal eyes this width is 4 to 6 minutes of visual angle, whereas in amblyopic eyes it is 10 minutes of visual angle. Miller concluded from this fact that the amblyopic fovea behaved like the peripheral portion of the dark-adapted retina in which spatial summation is a potent factor.³⁰⁹ Miller³¹⁰ believed that his work was evidence that the impaired visual acuity in amblyopia is not the result of suppression but of impaired brightness discrimination.

Meur³⁰⁵ was able to show with the Goldmann adaptometer an elevation of the coefficient of summation in the foveal area of light-adapted amblyopic eyes relative to the normal eye. No differences were found in the retinal periphery. A similar increase in summation at the foveal level took place when normal eyes were rendered artificially “amblyopic” by plus lenses.

Mackensen²⁹⁰ established that it is necessary to use small stimuli to elicit a central depression in retinal sensitivity in amblyopic eyes and that the scotoma deepens with a decrease in stimulus size. This implies an abnormal summation property of the amblyopic fovea. Flynn¹⁴⁷ also described a high coefficient of summation in the central retinal area of amblyopes.

JE Miller and coworkers³¹¹ gave an intriguing explanation for the reduced function of the amblyopic fovea—that lateral inhibition of the foveal cones is reduced. It is known that the bipolar and ganglion cell layers of the retina contain horizontal connections that mediate regulating impulses between the foveal cones and the extrafoveal system. A reduction in lateral inhibition would cause disinhibition of the monosynaptic foveal cone system, creating a “physiologic blur” so that a fuzzy image would be transmitted to the visual centers. Harwerth and Levi¹⁸⁹ determined increment threshold spectral sensitivity curves for amblyopic and normal eyes. The sensitivity of the amblyopic eyes was lower across the visible spectrum. The differences in the curves of the two eyes can be accounted for by anomalous lateral inhibition between the red and green cones of the retina of the amblyopic eye.

JE Miller’s theory is attractive because it might offer an explanation for the crowding phenomenon. Direct²⁶³ and indirect⁴⁴⁸ experimental evidence for this theory was provided by subsequent studies.

Hartline,¹⁸⁷ in his classic electrophysiologic studies on the retina and optic nerve of the frog, established that there existed on-elements, responding to the onset of the stimulus; off-elements, responding to the cessation of the stimulus; and on/off-elements, responding to either. These different elements were grouped into receptive fields whose center had the highest sensitivity, decreasing from the center toward the periphery. Kuffler²⁵¹ demonstrated an antagonism between center and periphery of the receptive fields in the retina of cats; stimulation of the periphery inhibited the centers. Hubel and Wiesel²²³ measured the size of the retinal receptive fields in monkeys and found it to be 4 minutes of arc in the foveal area, increasing toward the periphery.

Numerous psychophysical studies over the decades have shown that the size of the retinal areas over which spatial summation takes place is 4 to 10 minutes of arc for the retinal center and 15 to 30 minutes of arc for the retinal periphery. The

size of these summation areas and that of the area of the receptive fields involved are correlated. In the retinal center the receptive fields are small and the coefficient of summation is low, and in the periphery the receptive fields are larger and the coefficient high. Flynn¹⁴⁸ suggested the possibility that the high summation coefficient of the retinal center of amblyopic eyes may mean that the receptive fields involved are enlarged beyond their normal size, attaining dimensions similar to those in the periphery. He further suggested that the size of the receptive fields in amblyopic eyes could be directly determined by the use of the *Hermann grid*, an elegant test introduced by Baumgartner.³⁴ This was done on two amblyopic eyes by Meur and coworkers.³⁰⁸ The Hermann grid consists of black squares separated by white stripes. At the intersection of these stripes, grayish patches appear; they are more apparent in indirect than in central vision. These gray patches result from phenomena of induction or inhibition and may be explained as follows. Assume that the center of the intersection of two white stripes falls on a retinal receptive field with an on-center, so that the off-periphery is most intensely stimulated and the center maximally inhibited. A greater portion of the receptive field would be illuminated than would a unit located some distance from the intersection. Hence, the gray spot at the intersection. However, if the size of the receptive field is small,

relative to the width of the white stripes, there would be no inhibiting effect (Fig. 14–16).⁵⁶ Since they are indeed smaller in the foveal region, the phenomenon is less prominent in central viewing.

Baumgartner³⁴ has shown that one can determine the size of the human retinal receptive fields with the Hermann grid by knowing the width of the stripes and changing the viewing distance. The distance at which the gray patch just disappears is a measure of the size of the receptive field, which is then equal to the angular width of the stripe at the critical viewing distance. With this method different investigators have reported the size of the human foveolar receptive fields to vary from 2.6 to 5.72 minutes of arc^{34, 219, 308} and the prediction of enlarged retinal receptive fields in amblyopic eyes has been confirmed.

CONTRAST. Contrast and spatial summation are closely related functions. A study of the contrast function of amblyopic eyes was done in two series of experiments by Burian and Mazow⁶⁹ and Lawwill and Burian.²⁶² Normal eyes were found to require a much higher contrast for low luminances than for high luminances, regardless of the state of adaptation of the eye. For low luminances, though the data were somewhat chaotic, the amblyopic eye essentially has the same requirements as the normal eye. However, without exception, all amblyopic eyes increased their contrast re-




FIGURE 14–16. The Hermann grid. (From Brown JL, Mueller CG: Brightness discrimination and brightness contrast. In Graham CH, ed: Vision and Visual Perception. New York, John Wiley & Sons, 1965.)

quirement markedly with high background luminances and clearly differed in the photopic state from the normal eyes (see also Levi and Harwerth²⁷⁵). Thomas⁴³⁷ showed that contrast sensitivity functions obtained from the foveal region of strabismic amblyopes resembled those obtained from the peripheral retina of normal eye.

Lawwill²⁶¹ studied *local adaptation* (the Troxler phenomenon) in six amblyopic eyes. Compared with that of the normal eyes of these patients, local adaptation was faster; that is, the target disappeared more rapidly, both centrally and peripherally, in the amblyopic eye.

Visual acuity represents only one level of visual function in amblyopia. In fact, it provides information only on the resolution of the tested eye. The visual system is exposed to low and high spatial frequencies. This is why the presence of alterations in more sophisticated functions such as *contrast sensitivity* at photopic levels is of great importance in amblyopia. A method of measuring contrast sensitivity function that has gained wide acceptance among vision researchers is determination of the threshold for detection of an alternating pattern of black and white stripes (gratings) of variable width (spatial frequency).^{222, 301, 302, 318} In the 1970s Hess and coworkers^{203, 206, 208, 211, 214} and, independently, Levi and Harwerth²⁷⁵ began to use contrast sensitivity to study different types of amblyopia; a lower resolution limit was found in the amblyopic eye of strabismic amblyopia.^{54, 74} Hess and Pointer²⁰⁹ also suggested the existence of two subgroups in strabismic amblyopia, one group that showed the abnormality only at high spatial frequencies and the other that showed abnormalities at both high and low spatial frequencies. Contrast threshold became normal in strabismic amblyopia when luminance levels were reduced, while the deficit persisted in anisometric amblyopia,²⁶¹ a finding that confirms earlier observations by von Noorden and Burian.^{343, 344} Hess also described subjects with normal contrast thresholds, but severe local distortions within the pattern both at and above threshold. The two types of strabismic amblyopia proposed by Hess were eventually considered an artifact by Katz and coworkers.²⁴² Moreover, the different features found in strabismic amblyopia can be due to the coexistence of anisometropia. This series of studies prompted an in-depth evaluation of psychophysical parameters in human amblyopia, which was studied as a model of plasticity of the visual cortex.^{138, 149}

Several reports have described significant differ-

ences between normal and amblyopic eyes in patients with strabismic,^{179, 212, 384} anisometric,^{54, 384} stimulus deprivation,^{211, 276} and meridional amblyopia.¹⁵⁶ Leguire and coworkers²⁶⁶ noted that loss of contrast sensitivity occurs not only in the amblyopic eye but also in the sound eye of amblyopic patients. In explaining their findings these authors speculated that the sound eye may be adversely influenced by the amblyopic eye. Other authors have reported that the normal eye of amblyopic patients shows defective processing of motion-defined form and thus may not be normal after all.¹⁶² Cascairo and coworkers⁸⁵ recently introduced a new contrast visual acuity card (Holladay Contrast Acuity Test—Stereo Optical, Chicago) that is able to differentiate clinically anisometric from strabismic amblyopes. Also, in strabismic amblyopia the functional defect is limited to the central 20° to 30° of the visual field,^{214, 242} and larger stimulus fields are necessary to produce contrast sensitivity peaks that are equal to those in the sound eye.²⁴² In esotropic amblyopes the grating acuity reduction is more pronounced in the nasal than in the temporal retina.⁴⁰⁹ In anisometric amblyopia, on the other hand, the threshold elevation persists at all luminance levels and is independent of visual field location.²¹⁴ Unlike strabismic amblyopia wherein contrast sensitivity is depressed for only a limited band of high spatial frequencies, this depression extends over the entire frequency range in anisometric amblyopes.⁴¹³

Wood and coworkers⁴⁷¹ studied the contrast threshold of random-dot stereograms in anisometric amblyopia and found not only elevation of the threshold in the amblyopic eye under binocular testing conditions but also in some instances a higher threshold in the normal fellow eye (see also Giaschi and coworkers¹⁶² and Leguire and coworkers²⁶⁶).

Thompson and Nawrot⁴³⁹ showed in amblyopic observers anomalies in depth perception from stereopsis and from motion parallax and concluded that these results suggest a psychoanatomical link between the perception of depth from motion and the perception of depth from binocular disparity. Hess²⁰⁷ found that in anisometric amblyopia only the more severe contrast sensitivity losses limit stereo performance. This deficit represents binocular dysfunction unimpeded by the accompanying amblyopia. On the other side, in strabismic amblyopia where there are independent losses of contrast sensitivity and positional accuracy, the

greatest obstacle is not the contrast losses but the position losses. These are best thought of in terms of a spatial disarray of filters that optimally sample space and spatial frequency.

In summary, neural activities were sought that could be affected in amblyopia.⁷⁵ Thus, it was shown that *the visual performances, and, by inference, the underlying neural losses of strabismic and anisometric amblyopes, are fundamentally different.* It was argued that the spatial deficits that are found in anisometric amblyopes can be understood largely in terms of reduced resolution and contrast sensitivity, as would be expected on the basis of early experience with a defocused image in one eye. In contrast, the spatial deficits found in strabismic amblyopes are more profound than can be predicted on the basis of either resolution or contrast sensitivity and may have their basis in a coarse sampling grain, as argued Levi and coworkers,^{273–279} or an irregular sampling.¹⁰⁶ This anomaly was shown mainly by using various *hyperacuity tasks.*

HYPERACUITY. The term hyperacuity was coined by Westheimer⁴⁶⁵ to describe a variety of tasks that involve sensing the direction or spatial offset of a line or a point relative to a reference. Vernier acuity represents the most widely studied of these tasks. The visual system is capable of making much finer spatial discriminations than it does during determination of Snellen acuity. For example, relative position, size, and orientation can be judged with an accuracy of 3 to 6 seconds of arc or better. Vernier acuity is a cortical function and is not disturbed by retinal image motion or blur. Hyperacuity or positional acuity is useful because it contributes to the understanding of how the visual system achieves this degree of accuracy, that is, how it solves the technical problem of “subpixel” resolution.¹⁴⁹ It seems likely that the mechanisms underlying hyperacuity have the more general task of form and shape analysis. Hyperacuity is obviously involved in orientation capabilities of a visual stimulus. Skottun and coworkers⁴¹⁵ demonstrated substantial deficiencies in *orientation discrimination* in amblyopic eyes. The elevated discrimination thresholds were present over a wide range of stimulus contrasts and cannot easily be attributed to elevated contrast thresholds or fixation anomalies.

MOVEMENT PERCEPTION. In recent years two pathways carrying visual information have been identified: the P and the M systems. The first is

connected with parvocellular cortical areas, where high spatial frequency stimuli are elaborated, that is, where visual resolution takes place. The second system is connected with the magnocellular cortical area, concerned with movement perception where low spatial frequency stimuli are evaluated. A dissociation between P and M systems takes place in amblyopia, with deficits involving mainly the P system, while the M system performance has actually been described as better than that deriving from the P system.¹³⁵

Speaking of movement perception, it is possible to evaluate the smallest movement of a given stimulus that gives rise to the perception of movement by means of the *oscillatory movement displacement threshold* (OMDT). OMDTs fall into the category of hyperacuities. Kelly and Burckingham²⁴⁴ found no OMDT deficits in amblyopes with stereopsis but elevated OMDT in amblyopia without stereopsis. These authors showed also that whereas OMDTs improve with age in normals, the thresholds of the dominant eye of amblyopes without stereopsis do not. This finding could be due to an occlusion treatment performed earlier, but no evidence was found for this. The alternative theory suggests the existence of deficits in the dominant eye. Donahue and coworkers¹²⁰ evaluated motion detection abnormalities in patients with anisometric amblyopia and found abnormalities in motion detection that extend into the midperiphery of the visual field. Motion detection is altered also in optic nerve disorders and open angle glaucoma. The significance of these results needs still to be established.

SPATIAL DISTORTION AND ERRORS OF LOCALIZATION. Errors of spatial localization have been described in amblyopic eyes in several studies. Pugh³⁷⁹ was the first to report that amblyopes report distortion of optotypes as well as changes in shape or fragmentation of the test letters or increased spaces between the letters. Hess and coworkers²⁰⁹ noted that amblyopic subjects perceived distortion and fading of a grating pattern when tested for contrast sensitivity. Bedell and coworkers^{37, 40} expanded on these studies by showing anomalies of relative localization (judging whether two targets are in vertical alignment) and positioning (equating left and right field spaces). Further evidence for visual distortion, positioning, and localization errors was accumulated by other investigators.^{144, 160, 176, 177, 256, 409, 411} The cause for this deficiency is still subject to speculation, and

there have been arguments as to whether it is related to contrast sensitivity or an additional defect in spatial coding. From their studies Hess and Holiday²¹³ concluded that contrast sensitivity does not correlate with spatial localization deficits. The decreased spatial integration efficiency in the strabismic visual system suggests that spatial undersampling may occur at a secondary stage of visual processing, beyond the detection stage.⁴⁵⁸ Amblyopia is characterized by marked spatial uncertainty (imprecision) that is strongest under conditions where normal observers perform best, that is, when the images are close together.²⁷³ It has yet to be clarified whether differences between strabismic and anisometropic amblyopia are due to differences in the time of onset of these conditions or in the quality of influence exerted on the visual system.²⁷³

The performance of strabismic amblyopes cannot be mimicked by optical blur. Strabismic but not anisometropic amblyopes frequently make large constant *partitionial errors*, not explainable with reduced acuity or unsteady or eccentric fixation, as pointed out, among others, by Bedell and coworkers.^{37–39, 42} These errors are attributed to local compressions and expansions of subjective space resulting from abnormal binocular interaction. It would also account for many of the oculomotor abnormalities and the difficulties experienced in using the amblyopic eye, which are typically worse than can be predicted by the level of reduced acuity. Based on the above findings, it was suggested that amblyopia be identified using associated conditions rather than simply on the basis of an arbitrarily defined reduction in visual acuity.¹⁴²

A decoupling takes place between grating and Vernier acuity in amblyopia. Among the complex changes in performance present in amblyopia are the lack of relationship between spatial imprecision and reduced contrast sensitivity,^{31, 32} the distorted perception of visual space,^{242, 410, 412} and the alterations in reaction time, not explainable simply by the fact that the patient uses an extrafoveal area for fixation.^{88, 228} Changes found in the vestibulo-ocular reflex suggest a probably secondary involvement of the extrageniculate pathways.^{401, 464}

An analysis of the literature related to altered space perception in amblyopia often reveals that patients used for experimentation are not properly classified clinically, and that the clinical evaluation cannot always be considered reliable. One com-

monly neglected factor is the presence of eccentric fixation.

CRITICAL FLICKER FREQUENCY. Whether an intermittent light stimulus appears as a flicker or as a continuous sensation depends on the frequency of light pulse presentation. The rate at which flicker just disappears is termed the critical flicker frequency (CFF). The CFF is a measure of retinal sensitivity and in general parallels other visual functions. The values obtained from the CFF depend on many parameters: luminance and area of the stimulus, its retinal location, luminance of background against which the flickering stimulus is seen, state of adaptation of the eye, ratio of light to dark intervals, and many others. An enormous amount of work has been done in this field, and many of the results appear contradictory, particularly the results of the investigations of retinal location and CFF, which is of special interest in amblyopia studies. Brown⁵⁵ ascribed these contradictory findings to the interaction of luminance and area with retinal location. Differences in instrumentation and technique undoubtedly further contribute to it.

The CFF of amblyopic eyes was investigated as long ago as 1908 by Lohmann²⁸⁵ and in 1934 by Teräskeli.⁴³⁴ Both of them found in some amblyopic patients an elevation of the CFF in the macular region relative to a peripheral area. On the other hand, Weekers, Lavergne, and Deprez-Binot found normal CFF values in amblyopic eyes or differences that were not statistically significant.^{259, 461, 462} Much of the older work on CFF in the literature suffered from lack of control of the pupil size.^{7, 137} Jacobson and coworkers²³¹ measured foveal CCF, a method that is independent of pupil size, and reported that there were no differences between an amblyopic eye and its fellow. However, they also found that the CFF was significantly faster in amblyopic eyes that fixated eccentrically than in those with foveal fixation. Jacobsen and coworkers suggested that stimulation of a greater proportion of magnocellular retinal ganglion cells in the retinal periphery may account for the enhanced CFF performance. Manny and Levi²⁹⁴ investigated the sensitivity of eyes with strabismic, anisometropic, and stimulus deprivation amblyopia to uniform field flicker. Sensitivity of the amblyopic eye was reduced in only half of their patients, and when differences between the normal and amblyopic eye existed they were more marked at low and middle tempo-

ral frequencies and were small in comparison with those in the spatial domain.

The significance of these findings with regard to the mechanism of amblyopia is not at all clear. Of practical clinical use may be the observations of Junghardt and coworkers²³⁵ according to which examination of the CFF with a simplified apparatus is a helpful tool to distinguish reduced visual acuity in maculopathies from amblyopia. In the former the thresholds are below normal.

PUPILLARY RESPONSES. The first to observe pupillary abnormalities in amblyopia was Harms. Stimulated by an incidental clinical observation, Harms¹⁸³ compared the pupillomotor responses obtained by stimulation of central and peripheral retinal areas. He confirmed that in normal eyes pupillomotor sensitivity is highest in the macular area, whereas in amblyopic eyes pupillomotor sensitivity is greater peripherally than centrally. Harms concluded that this inversion of the “pupillomotor ratio” indicated that the seat of the suppressive mechanism had to be in the retinal synapses. In a later publication, Harms¹⁸⁴ revised this opinion. He stated that although his observations about the pupillary responses were correct, they were not valid with regard to the seat of suppression, since he had found meanwhile that pupillary anomalies may arise from interruptions anywhere in the visual pathway.

An afferent pupillary defect of amblyopic eyes has been reported by several authors and the prevalence of this defect, according to different studies, varied from 9% to 93%.^{140, 172, 377, 440} Dolének¹¹⁴ made pupillographic measurements on the eyes of amblyopic children and found that on average the pupil of the amblyopic eye was 0.5 mm larger than the pupil of the normal eye in the natural state and 0.3 mm larger in miosis induced by a light stimulus (see also Krüger²⁴⁹). He also found an increase in latencies of contraction and dilation of the pupil and a decrease in contraction time of the pupil of the amblyopic eye, but there was no difference in the speed of contraction of the two pupils. Kase and coworkers²³⁹ reached similar conclusions by using infrared electropupillography and pointed out that there is no relationship between the delay in the pupillary light reflex and the visual acuity of amblyopic eyes. In contrast to Dolének and to Kase and coworkers, Morone and Matteucci,³¹⁷ using pupillography, found no anomaly in pupil size or dynamics. Harms¹⁸⁴ objected to the validity of the studies of all these authors

because they were not made with perimetric stimuli. Donahue and coworkers¹¹⁸ performed automated pupil perimetry in amblyopes and found a global depression of focal pupillary responses across the entire central 30° field. They concluded that amblyopia affects focal light perception diffusely and irrespective of perimetric location. Amblyopia therefore disturbs pupillary function in a different manner than other visual functions, such as contrast sensitivity, Snellen visual acuity, and spatial frequency, where the maximal deficit is at the center of the visual field.

INTEROCULAR INHIBITORY EFFECTS. In normal binocular vision the functioning of one eye depends on the functioning of the fellow eye. An obvious example is retinal rivalry. In 1967 Aulhorn²⁰ described the so-called extinction phenomenon that occurs when a visual stimulus is presented to one eye and then, in brief succession, to corresponding retinal elements of the fellow eye. Perception of the first stimulus is extinguished by presentation of the second. This extinction affects not only elements corresponding to those stimulated but also an area around these elements. The more eccentric the stimulation, the larger the size of this area, which depends also on the size and luminance of the stimulus and the state of adaptation. The size of the retinal area in which extinction occurs is subject to considerable interindividual and intraindividual differences, but is definitely larger than Panum’s area. In amblyopic eyes the extinction area was found to be larger than in normal eyes.

The effect of the fixating eye on the amblyopic eye is evident also in testing visual acuity. Using the major amblyoscope, Pugh³⁸⁰ found that in many cases vision of the amblyopic eyes was lower when the sound eye was open and higher when it was patched. The strength of the inhibiting effect of the normal eye varied widely. The monocular level of vision could be restored to the amblyopic eye by reducing the luminance of the stimulus reaching the normal eye by 1/100 to 1/10,000 with the use of neutral density filters.

Von Noorden and Leffler³⁵⁵ tested visual acuity in amblyopes with isolated optotypes under monocular and binocular conditions. Visual acuity improved in 8 of 41 patients when the sound eye was occluded. This decrease of visual acuity of amblyopic eyes under binocular conditions, which has been confirmed by other investigators,^{26, 270, 400} was more common in esotropes and hypermetro-

pic anisometropes than in exotropes and myopic anisometropes. Visual acuity in patients with organic macular lesions remained the same under monocular and binocular conditions.²⁵ Pigassou and coworkers³⁷⁴ reported that the inhibitory effect of the fixating eye persists even after treatment has brought the amblyopic eye up to standard acuity in monocular vision. This effect is said to last for 12 to 18 months after a cure has been achieved. It is obvious that their finding, if confirmed, is of major significance from a therapeutic viewpoint.

Flynn and coworkers¹⁵⁰ have shown that an interocular effect reaches down to fundamental visual functions. Providing contour stimulation to the sound eye caused a marked increase in the luminance requirement of the amblyopic eye. Mackensen²⁹⁰ and Aulhorn¹⁹ demonstrated a substantial increase in the relative light threshold of the fovea of amblyopic eyes when static perimetry was performed under binocular conditions (Fig. 14–17).

The findings that the visual function of amblyopic eyes occasionally recovers partially or even completely in adults after functional loss of the good eye^{46, 451} or in strabismic monkeys after enucleation of the sound eye¹⁹³ further emphasize the

importance of interocular factors in the origin and maintenance of amblyopia. Moreover, these findings indicate that even in long-standing and deep amblyopia *the retinostriate connections of an amblyopic eye are not irrevocably destroyed but merely dormant*. One would hope that future research will find ways to reactivate the visual functions of an amblyopic eye by less draconian means.

These findings, together with the other data cited, provide strong support for the presence of abnormal binocular interaction in amblyopia. If amblyopia were a purely monocular phenomenon, as proposed by Ikeda and Wright,²²⁷ one would expect to find an elevation of the contrast threshold in the amblyopic eye alone.

Higher Nervous Center Activities

Mackensen²⁸⁹ and later von Noorden³²⁸ showed that the *reaction time* was significantly longer when measured through the amblyopic eye than when measured through the normal eye. The reaction time may be defined as the time elapsed between the presentation of a sensory stimulus and an associated volitional response.¹³³ Mackensen's and von Noorden's observations were con-

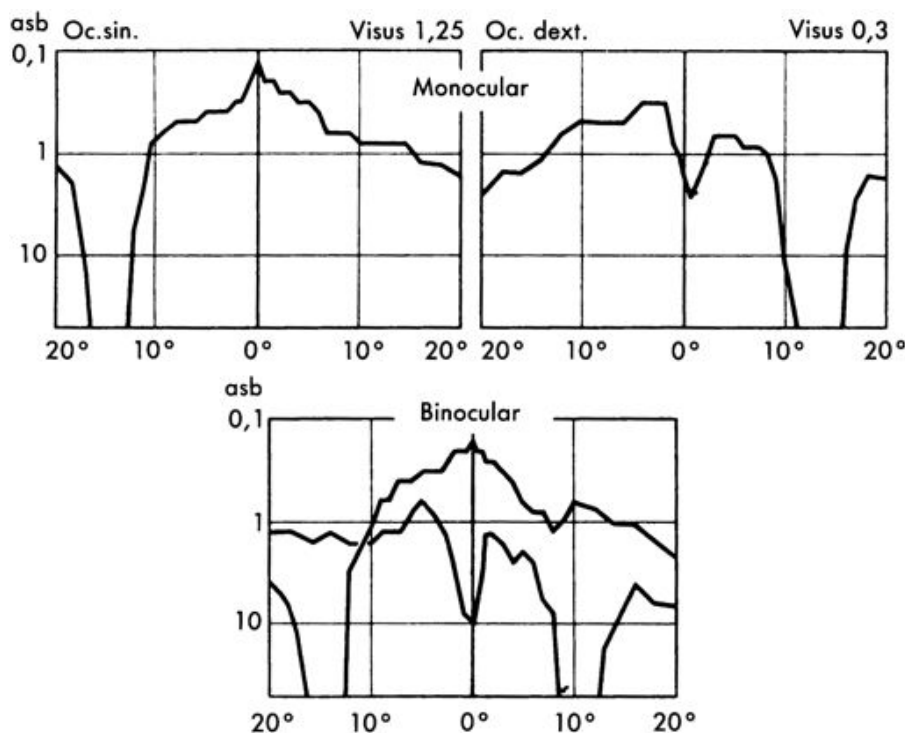


FIGURE 14–17. Monocular and binocular static perimetry in an amblyope with parafoveolar fixation. Note decrease of sensitivity at the fixation point of the right eye when tested under binocular conditions. (From Mackensen G: Monokulare und binokulare statische Perimetrie zur Untersuchung der Hemmungsvorgänge beim Schielen. *Graefes Arch Clin Exp Ophthalmol* 160:573, 1959.)

firmed by Hamasaki and Flynn,¹⁸¹ who were able to correlate the delay in reaction time with the decrease in visual acuity, and by Ciuffreda and coworkers,⁹¹ who demonstrated increased saccadic latencies when the stimulus was presented to the amblyopic eye. Levi and coworkers²⁷⁷ reported that the reaction time for detecting a low contrast grating was longer when the amblyopic eye was used (see also Teping and coworkers⁴³⁴).

The reaction time consists of two phases, the sensation time and the motor response time. Exhaustive studies have shown that sensation time is subject to considerable interindividual variability and depends on several parameters,¹⁵⁹ whereas the motor response time has great stability. Therefore it is reasonable to attribute the prolonged reaction time in amblyopia to an extension of the sensation time. This view is supported by a study of *perceptual blanking* in amblyopia.³⁴⁵ The information contained in a tachistoscopically presented stimulus will be either correctly perceived or partially or completely eliminated from perception if it is followed by a brief flash of light. Perception or nonperception depends on the time interval between the informative and blanking flash and on the intensity of either flash. The critical time interval at which the blanking flash no longer interferes with perception of the information delivered by the first flash has been termed *perception time*. The process of extinguishing information by subsequent interference of a light stimulus is known as blanking time. These matters have been extensively investigated since the early studies of Helmholtz,¹⁹⁷ Baxt,³⁵ and Exner.¹³³ All authors concur with the opinion that the perceptual interference in blanking involves cortical levels. Lindsley and Emmons²⁸² have related perceptual blanking to electrophysiologic events, such as latency, duration, and form of evoked cortical potentials. It was clearly of interest to study perceptual blanking through normal and amblyopic eyes. In their study of a group of normal subjects, von Noorden and Burian³⁴⁵ found the perception time to be around 30 ms and the blanking time around 23 ms. The average times for six patients were significantly longer in the amblyopic eye than in the sound fellow eye.

Studies of reaction time and blanking time hint that cortical centers are involved in the mechanism of "intrinsic inhibition," which in Tschermak-Seysenegg's view⁴⁴⁴ is responsible for suppression and, by extension, amblyopia.

The possibility that the amblyopia may be un-

able to integrate a form sensed through the amblyopic eye into a meaningful percept was voiced first by von Hofe,²¹⁶ who tested visual acuity of amblyopic eyes with various simple geometric forms. He reported that some patients were unable to recognize geometric forms, in spite of their sufficient size, unless they traced them with their fingers. Goldmann¹⁶⁵ suggested much later that amblyopia may share some characteristics of visual agnosia. Cüppers¹⁰⁰ took a similar view. However, a study of the *visual cognitive functions* in strabismic amblyopia revealed that functional amblyopia could not be classified in the group of agnosias.⁶⁶ A battery of tests for visual agnosia, consisting of embedded figures, fragmented figures, tactile visual matching, and a test for visual memory, was presented to a group of amblyopes. No differences in performance levels were found between the normal and the amblyopic eye. If the object was large enough so that the amblyopic eye could see it, it was equally well integrated, interpreted, and remembered with either eye. Thomas-Decortis⁴³⁸ had already found this to be true for visual memory. The only abnormality noted in this study was a statistically significant prolongation of the time required to make a judgment when the form was sensed through the amblyopic eye.⁹⁰ These performance characteristics of amblyopes are quite different from those in patients with visual agnosia whose failure to recognize objects or representations is independent of the duration of visual inspection. This prolongation of the time required by the amblyopic eye is analogous to the prolonged reaction and blanking times mentioned earlier.

The protraction of reaction, sensation, blanking, and recognition times established by these studies may be attributable to a prolongation of the *retinocortical time*. The finding that anisometropic amblyopes may have a spontaneous *Pulfrich effect* has been interpreted in a similar manner.⁴⁴³

The questions of *handedness* and *eyedness* assume some importance in connection with the functioning of the higher nervous centers in amblyopia. These are complex questions in general and no less so in relation to strabismus and amblyopia. It is particularly difficult to equate eyedness and ocular dominance with the fixating and nonfixating eye in amblyopia. The assumption that the fixating eye is also the dominant eye is not necessarily correct, as Pigassou and coworkers³⁷⁴ pointed out.

Burian⁶⁵ put the question somewhat differently.

In a group of 400 patients with amblyopia he found that 161 (39%) had an amblyopia of the right eye and 188 (61%) had an amblyopia of the left eye. This agrees in general with the findings of other workers.²⁸⁴ In the general population, left-eyedness is variously estimated at 30% to 34%. Burian argued that since the figure 30% to 34% agrees rather well with that found for right amblyopia (left eye—fixating), there is a good probability that the nondominant eye is more easily suppressed. This would explain why left amblyopia (right eye—fixating) is more frequently encountered. Shipley,⁴⁰⁵ without offering data, also stated that in his experience amblyopia is more common in the eye on the nondominant side, sinistrals tending to be amblyopic in the right eye and vice versa.

In the general population there is a possible correlation between handedness and eyedness. Right-handed persons show a preference for the right eye in about 80% of cases, and left-handed persons show a preference for the left eye in 70% of cases.¹⁹⁶ In Burian's patients,⁶⁵ 62% of the right-handed amblyopes had left amblyopia and 82% of the left-handed amblyopes had right amblyopia. The relation between handedness and eyedness in this population was statistically significant ($P = .01$), as determined by a chi-square test, raising the possibility that the factors causing the laterality of the amblyopia and those responsible for handedness are not independent of each other.

Eye Movements in Amblyopia

The unsteadiness in fixation present in normal eyes is vastly exaggerated in amblyopia, whatever its cause. This unsteadiness was recorded electro-oculographically^{288, 342} for fixation and saccadic movements. The increased tendency of amblyopic eyes to drift while fixating a stationary visual target was also recorded with a photoelectric eye movement technique.^{93, 204} Von Noorden and Burian³⁴² reported an improvement of motor unsteadiness in dark-adapted amblyopic eyes, which did not occur in patients whose vision was reduced from organic macular lesions. However, Mackensen²⁹¹ could not confirm this observation.

In another study, von Noorden and Mackensen³⁵⁶ recorded pursuit movements of amblyopic and normal eyes with the patients following a target moving horizontally at varying frequencies. The amblyopic eye made irregular, jerky movements at all target frequencies, and the movements

disintegrated into gross, jerky saccades at much lower target frequencies than did those of the normal eye. Dark adaptation did not have a consistent effect on this anomaly. A direct correlation between the depth of amblyopia and the performance of pursuit movements could not be established; however, such a correlation did exist between anomalies of the fixation behavior and the quality of motor performance. Schor³⁹⁸ and Ciuffreda and coworkers⁹² confirmed these findings. Schor noted more accurate pursuit and saccadic movements for temporal than for nasal retinal image motion. A delay in information processing by amblyopic eyes (reaction time; see p. 277) was thought to be the cause of increased saccadic latencies demonstrated by Ciuffreda and coworkers.⁹¹ Such a delay, although of smaller magnitude, also had been noted by Mackensen²⁸⁷ but not by Schor.³⁹⁸

Bedell and Flom³⁷ and Bedell and coworkers⁴⁰ explained the motor deficits of amblyopic eyes, such as unsteady fixation, inaccurate tracking, and the sensory difficulties in discriminating supra-threshold targets, on the basis of a *distorted spatial sense* (see p. 274).

In their study of *pursuit movements* in amblyopic eyes, von Noorden and Mackensen³⁵⁶ observed that tracking of the sound eyes of their patients was often less precise than in a control group of normal observers. This observation has been confirmed by several more recent studies^{39, 42, 399} and further specified as a centrally generated nasal drift bias involving both eyes in amblyopia.^{39, 42} The question remains open whether this nasal drift bias is specific for the normal eyes of strabismic amblyopes or occurs also in nonamblyopic strabismic subjects. Fukai and coworkers^{160a} reported that abnormal tracking occurs more frequently in amblyopes with strabismus than in those without. However, these authors failed to mention whether the strabismus in the control group was of the same type as in the amblyopic group. Without adequate controls, no conclusions can be drawn about whether motor anomalies of the sound eye in amblyopes are specific for amblyopia or for the underlying strabismus.

Electrophysiologic Studies

Studies using electrophysiologic methods of investigation are objective. Responses are recorded without reference to any judgment on the part of the patient, whose collaboration, as a rule, is

restricted to attentive fixation. Responses from the retina and central nervous system are registered, usually following the stimulation by light. In principle, electrophysiologic methods should differentiate more readily between abnormalities in retinal and cortical functions than do psychophysical methods, which involve an overt response by the individual and necessarily include the whole visual system.

ELECTRORETINOGRAPHY. The ERG mirrors responses of the retina to stimulation by light. Defects in retinal function are expressed in abnormal ERG responses. The hope of having a direct method of determining the seat of the process responsible for amblyopia stimulated many investigators to record the ERG from amblyopic eyes. It soon became clear that the theoretical and technical aspects of the available methods were inadequate to uncover subtle, localized abnormalities in amblyopic eyes, if such were present. Nevertheless, attempts were made to investigate amblyopic eyes with single light stimuli. No significant differences in the electric responses of the normal and amblyopic eyes were found.^{152, 236, 314, 322, 429} Other authors did notice certain differences in the electric responses of normal and amblyopic eyes. Increased b-wave amplitudes,³⁹⁴ increased a-wave amplitudes,¹⁵⁷ decreased b-wave amplitudes,¹⁵⁶ decreased a-wave and b-wave amplitudes,³⁷⁰ anomalies in the shape of the b wave,^{370, 395} and anomalies of the flicker ERG^{370, 455} have all been reported in amblyopic eyes.

The reason for these contradictory results is to be found in the nature of the ERG test. For one thing, the ERG is a mass response. Furthermore, results depend in large measure on the techniques and procedures used and on the manner in which ERGs are evaluated. The older literature on the subject was reviewed by Burian.⁶⁴ Most important, it is not readily possible to elicit responses from discrete retinal areas because of stray light.

Even the advent of improved elaborate techniques to ensure proper fixation of the amblyopic eye did not guarantee a focal ERG.⁶⁸ However, bar pattern stimuli³⁸² prevent stray illuminance; by applying such stimuli to the study of amblyopic eyes, it has been shown that there is no consistent difference in the waveforms of the ERG between normal and amblyopic eyes.⁴⁴⁷ This finding was challenged, however, by Sokol⁴²³ and by Sokol and Nadler⁴²⁶ who reported decreased amplitude of the b wave and of the afterpotential in the

ERG of an amblyopic eye in response to patterned stimuli. Using pattern-reversing checkerboard squares, similar results were obtained by some^{13, 14, 371, 426, 460} but not all workers in the field.^{170, 208} Thus, and despite an enormous accumulation of data, the question of whether the ERG in amblyopia is normal or abnormal has not been definitively answered.

A temporary reduction of the ERG following occlusion was reported by Hamasaki and Flynn¹⁸⁰ in the sound eye of patients treated for amblyopia.

ELECTRO-OCULOGRAPHY. The EOG is another indicator of retinal function. Williams and Papakostopoulos⁴⁶⁹ found EOG anomalies in 12 adult amblyopes. These results are interpreted as evidence for a retinal abnormality in amblyopia and implicate the retinal pigment epithelium. Obviously, these results do not suggest a primary retinal anomaly in amblyopia and the changes described in this paper are likely to be secondary in nature. Nonetheless, these data and the possible role of the dopaminergic system in treating amblyopia pharmacologically (Chapter 24) deserve further analysis. A limitation of this and similar studies is that the EOG depends on the normalcy of eye movements, yet the latter are notoriously abnormal in many amblyopia patients.

CENTRAL CEREBRAL RESPONSES (EEG AND VER). Anomalies of the resting electroencephalogram (EEG) of amblyopic patients were reported by some investigators,^{125, 281, 428} whereas others reported negative findings.^{72, 119, 152} All these findings were related to spontaneous waves and were difficult to interpret.

It appeared more rewarding to investigate the effect of photic stimulation in the EEG of the normal and amblyopic eyes. Burian and Watson⁷⁰ found in 55 amblyopic patients that the alpha rhythm was always promptly blocked when the normal eye was exposed to a stroboscopic light stimulus, whereas it continued undisturbed if the amblyopic eye alone was exposed, provided the acuity was below 6/21. Also, photic driving was produced less easily through stimulation of the amblyopic eye. When driving was obtained at all, it was less regular, often occurred only momentarily, and was of lower voltage than driving from the amblyopic eye. These findings were not confirmed by other investigators,^{119, 369} but JE Miller and coworkers³¹¹ made the remarkable observation that in amblyopic eyes, under binocular conditions of stimulation, significantly less photic driving

was found in the range of 8 to 18 flashes per second and significantly more in the range of 3 to 7 flashes per second than in normal eyes.

At the time Burian and Watson did their work, the techniques of superimposition or of computer averaging of VERs from the cortex had not been developed. These techniques now have been applied to investigations of suppression and amblyopia. The studies in connection with suppression are mentioned in Chapter 14. The overall impression gained from them is that in suppression the VERs are reduced in amplitude and, as some workers found, are delayed in appearance. It was therefore to be predicted that similar findings would be made in amblyopia, and indeed such findings have been made with the use of various stimulus techniques.^{322, 362, 405, 447, 475} The literature on VERs was reviewed in 1976 by Sokol.⁴²² Lombroso and coworkers²⁸⁶ used unpatterned and patterned (checkerboard) stimuli and in several patients found no difference in the VER when unpatterned stimuli were used, whereas there was a degradation of both amplitude and waveform complexity with patterned stimulation of the amblyopic eye. Lombroso and coworkers believed that this finding tended to confirm the concept of Wald and Burian⁴⁵⁷ of a dissociation of form sense and light perception in amblyopia. Several investigators have reported similar findings using patterned visual stimuli, especially with a field size of 12° or larger.^{105, 424, 425, 475} The amplitude of VERs usually is smaller in amblyopic eyes than in normal eyes, and the latency may be increased; however, with smaller field sizes the results of patterned VERs in amblyopia become controversial, and some authors report no difference between normal and amblyopic eyes, whereas others claim that such a difference does exist.^{12, 33, 345, 421, 422, 426, 427, 459} Teping and coworkers⁴³³ explored whether retinal conduction delays in amblyopia contribute to the increased VER latency by simultaneously recording pattern-evoked ERGs with VERs. The authors were unable to record a significant peak latency in the ERG. Since a conduction delay of visual information thus appears unlikely to occur on a retinal level, they concluded that the total latency delay in the VER in amblyopia must be caused by a prolongation of the retino-cortical time.

Tsutsui and coworkers⁴⁴⁶ found a significant reduction in amplitude of VER in cases of severe amblyopia. These findings are interpreted as a

reduction of evoked potentials from the retina and stations of transmission along the optic pathway.

It is interesting that the reduction of VER amplitude in amblyopic eyes cannot be consistently correlated with the degree of amblyopia^{272, 425} and that during the treatment of amblyopia VER changes may actually precede an improvement in visual acuity.³³ The latency of VER was also used as a prognostic factor for the treatment of strabismic amblyopia.²²⁸ VER latency was increased in eccentric as compared to central fixation.

van Balen and Henkes⁴⁴⁸ noted a reduction in the first component (C1) of the main positive wave of the VER, attributed by these authors to the activity of the foveal system, or a relative preponderance of its second component (C2) for which the extrafoveal system was believed to be responsible. This behavior of the amblyopic eye corresponded to the visually inattentive state of normal eyes. When visual attention was induced by the presence of reading matter, the C1 wave predominated in the VER of the normal eye. Therefore, van Balen and Henkes reasoned that the physiologic basis of visual attention consisted of activation of the foveal system. They located the point at which attention intervenes in the horizontal connections of the retinal bipolar and ganglion cell layers. Apkarian and coworkers¹¹ studied binocular interaction in the VER of amblyopic patients. Whereas some strabismic amblyopes showed binocular inhibition (binocular response lower than mean monocular response), others had facilitation. Since they obtained a similar variety of responses from normal observers, caution must be exercised in using the VER to differentiate normal from abnormal binocular vision.

Since the recordings in amblyopia corresponded to those found in normal eyes in the inattentive state, van Balen and Henkes concluded that amblyopia probably should be regarded as a result of inattentiveness rather than suppression. One is reminded of the interesting work of Goldmann and Favre¹⁶⁶ who could produce a "physiologic amblyopia" by a shift of attention.

VERs have also been widely used to compare subjective and objective responses to various visual stimuli in amblyopia. Particularly, it has been attempted to differentiate strabismic from anisometropic amblyopia by means of a VER modulation transfer function,⁸² by the use of pattern-reversal VERs, and by motor reaction time measurements.³⁰⁴ Yu and coworkers⁴⁷⁶ investigated the variation of VER function at different eccen-

tricies of the visual field in esotropic and anisometropic amblyopes. They found a greater foveal deficit and a greater visual loss in the temporal field than in the nasal field in esotropic amblyopia. Finally, Shawkat and coworkers⁴⁰⁴ confirmed with pattern-onset, pattern-reversal, and pattern-offset VERs alterations in the amblyopic eye of patients previously treated with occlusion of the sound eye. They also showed subnormal VERs of the previously patched eye, if compared to the VERs obtained in normal controls. These authors concluded that occlusion may have a long-standing functional effect on the patched eye that is not clinically apparent. One cannot exclude, however, that the so-called normal eyes of amblyopes have functional alterations that precede and are independent of occlusion therapy.

Amblyopia vs. Suppression

The belief is widely held that suppression and amblyopia are qualitatively similar but quantitatively different adaptive mechanisms to eliminate visual confusion and diplopia resulting from dissimilar retinal images on corresponding retinal points. Visual acuity is reduced in both the suppressed and amblyopic states, but suppression occurs only under binocular conditions, whereas amblyopia persists after closing the fixating eye. Amblyopia occurs after long-standing unilateral suppression in the nondominant eye of patients who fail to develop an alternating fixation behavior or, as can so often be observed in infantile esotropia, after initial alternation changes spontaneously into monocular fixation preference.

That quantitative differences should exist between suppression and amblyopia in terms of the degree of decreased retinal function is not surprising. Indeed, it has been shown that the functional deficit of the fovea is greater in alternating strabismus and suppression than in strabismus with amblyopia.^{218, 410} The more efficient antidiplopic mechanism in suppression is also borne out by the observation that postoperative diplopia occurs less commonly in patients with suppression than in amblyopes.⁷⁸ These quantitative differences between suppression and amblyopia should not lead to the conclusion that different neural mechanisms are involved. The etiology (inhibition evoked by cortical competition between dissimilar images) is the same in both conditions. Moreover, as previously stated, there is abundant clinical evidence

that this interocular inhibition (suppression) may persist in amblyopia and be enhanced by visual demands made on the fixating eye (see p. 276).

Many unanswered questions exist about the relationship between suppression and amblyopia. One of them is a finding discussed earlier, that there can be absence of suppression of the image of the fovea of the amblyopic eye under binocular conditions. In such cases more complex inhibitional or disuse mechanisms or both could be responsible for the reduced visual acuity.

Experimental Amblyopia in Animal Models and Histologic Abnormalities in Brains of Human Amblyopes

Inherent limitations of psychophysical and electrophysiologic methods of investigation have precluded identification of the nature of functional and structural anomalies within the central aspects of the visual system of amblyopes. Microelectrode techniques have made it possible to record directly from single neurons within the animal visual system and to study their responses to retinal excitation with stimuli of different shapes and orientation (receptive fields). Hubel and Wiesel²²⁴ and Wiesel and Hubel^{466, 469} pioneered the application of these methods in studying the effects of normal and abnormal visual experience early in life in visually immature kittens, and this research has provided a great impetus to laboratories all over the world. This book is not the place to discuss the results of these studies to which many investigators have contributed and the reader is referred to several reviews.^{52, 296, 336, 341, 449}

The essence of these experiments may be summarized as follows. Amblyopia can be produced in kittens and infant monkeys by suturing the lids of one eye,^{190, 191, 361, 466} by experimental anisometropia,^{346, 418} and by surgically induced³⁵⁰ or optically induced¹³⁶ esotropia. Adult monkeys are immune to these experimental manipulations. The behavioral aspects of experimental amblyopia are similar to amblyopia in humans in terms of severity, reversibility,^{334, 347} and limitation of onset during infancy and early childhood.³⁵⁰ Extracellular recordings from striate neurons in monkeys with strabismic, anisometropic, and visual deprivation amblyopia showed anomalies similar to those reported by Wiesel and Hubel⁴⁶⁷ in unilaterally lid-

sutured kittens: a decimation of binocularly driven cells and of cells receiving input from the amblyopic eye^{27, 99} (Fig. 14–18). The loss of binocularly innervated striate neurons is not specific to amblyopia, occurs after any brief disruption of binocular input early in life (see also Chapter 2), and has been correlated with a loss of stereopsis.^{137, 138} On the other hand, the decrease in cells responding to stimulation of the amblyopic eye is highly specific to amblyopia, regardless of the etiology, and correlates quantitatively with the decrease in visual acuity.^{34, 357}

During the sensitive period only 1 week of experimentally produced esotropia or monocular lid closure in infant monkeys suffices to decimate the binocular neurons, as well as those connected with the amblyopic eye (Fig. 14–19). However, brief periods of “treatment” by suturing the formerly fixating eye or alignment of the eyes before

normal binocular exposure brings about a functional recovery of striate neurons connected with the amblyopic eye¹³⁵ (Fig. 14–20). The clinical equivalent of these findings is the so-called occlusion amblyopia of the formerly fixating eye developing rapidly in children up to 4 years old under the influence of patching (see Chapter 24).

Impairment of the binocular cells, on the other hand, appears to be permanent, at least in the monkey, after disruption of binocular vision early in life and is comparable to the clinical experience that normal stereoacuity is never recoverable in children who develop constant esotropia shortly after birth (see Chapter 16).

Histologic study of the lateral geniculate nucleus (LGN) of monkeys with strabismic, anisometropic, and visual deprivation amblyopia has shown marked shrinkage of cells that receive input from the amblyopic eye^{195, 335, 359} (Fig. 14–21). The

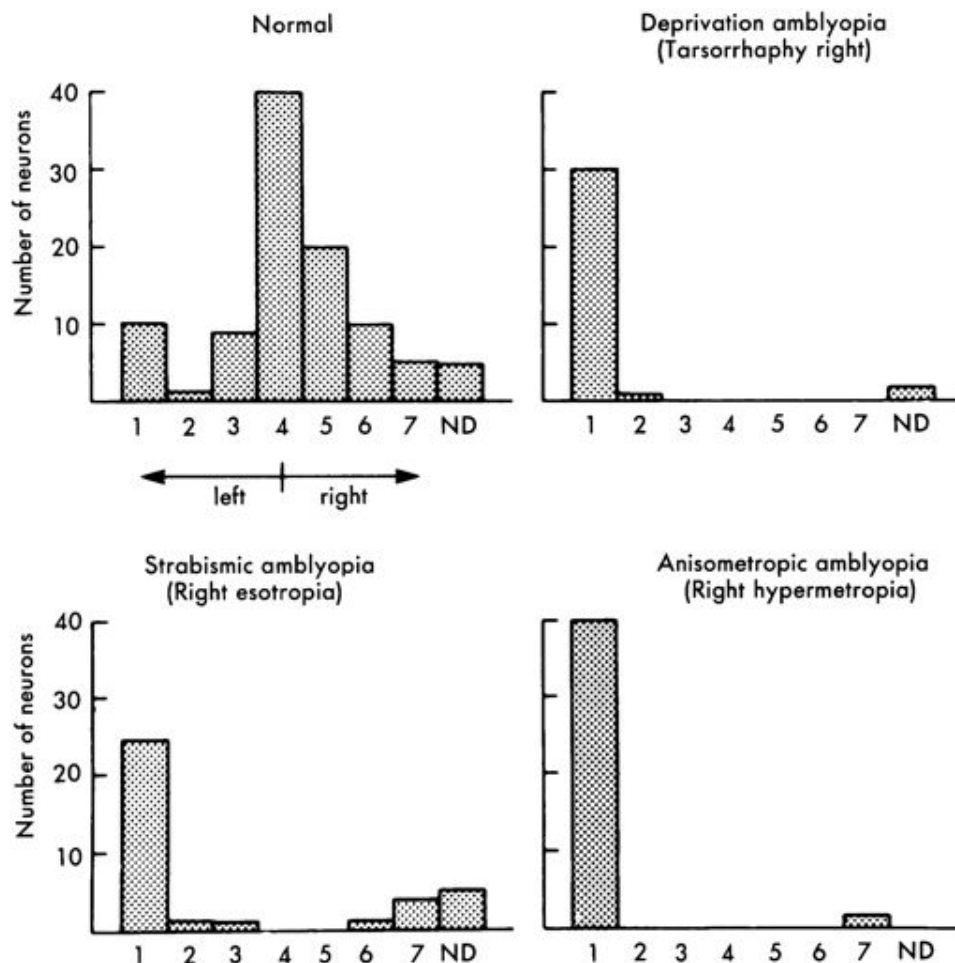


FIGURE 14–18. Frequency distribution of cells in macaque striate cortex according to eye dominance in different types of amblyopia. Categories 1 and 7 contain neurons that were driven only through the left or right eye, respectively. Remaining categories represent graded degrees of binocular influence, with neurons in 4 being equally influenced by both eyes. ND, number of cells not influenced by visual stimulation. (Modified from Noorden GK von: Amblyopia: A multidisciplinary approach [Proctor Lecture]. Invest Ophthalmol Vis Sci 26:1704, 1985.)

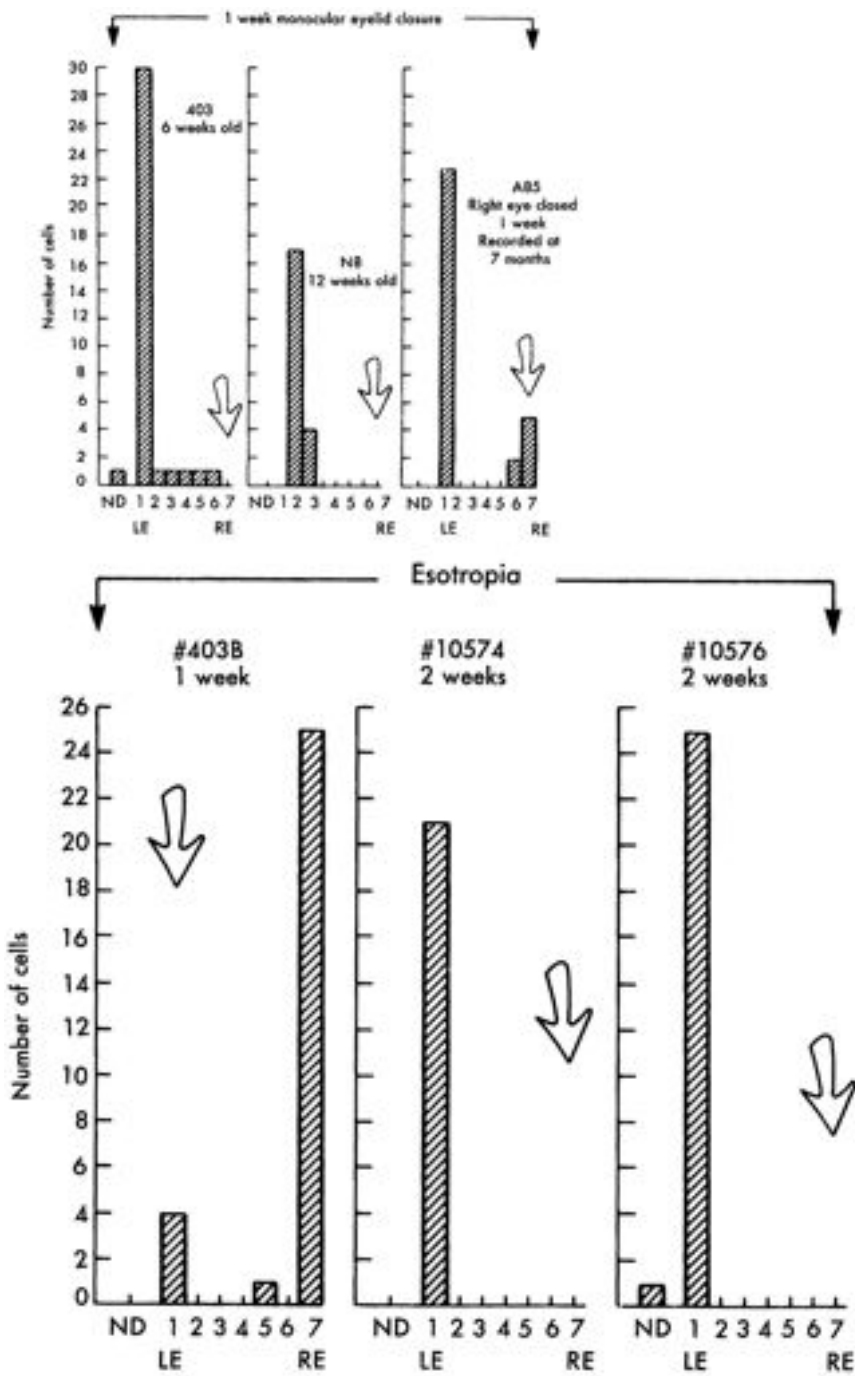


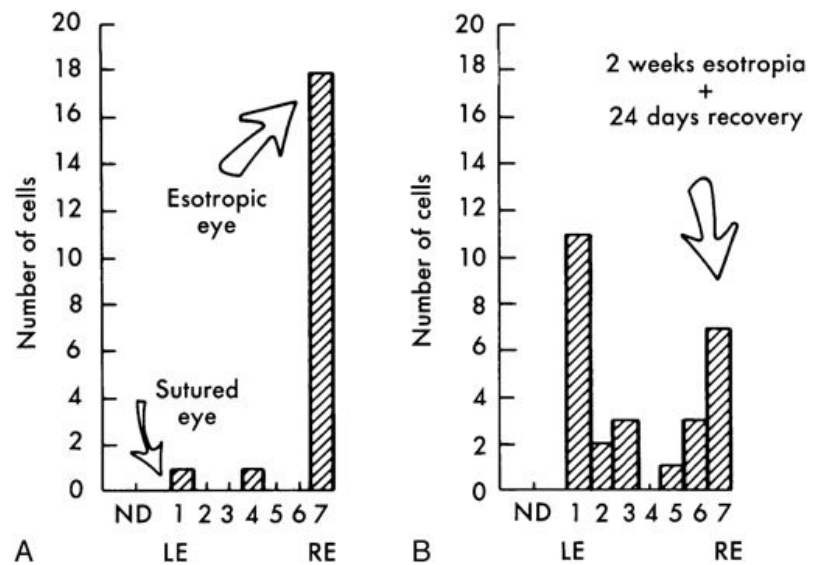
FIGURE 14-19. Cortical neuronal eye dominance histograms for young rhesus monkeys. *Below*, Histogram comparing monkeys subjected to surgical strabismus of various durations. *Above*, Histogram comparing similar data from three monkeys that had monocular lid closure for 1 week. *Arrows* indicate treated eye. ND, nondriven neurons. (From Cravford MLJ, Noorden GK von: The effects of short-term experimental strabismus on the visual system in *Macaca mulatta*. Invest Ophthalmol Vis Sci 18:496, 1979.)

validity of the monkey as an animal model for study of amblyopia was considerably enhanced when similar findings became available from the LGN of a human anisometric³⁴⁹ and strabismic amblyope.³⁴⁸ Table 14-3 shows cell size area measurements from each layer of the right and left LGN from a patient with strabismic amblyopia of the left eye that had a visual acuity of 6/60. Cell sizes in layers 2, 3, and 5 of the left LGN that received input via uncrossed fibers from the amblyopic eye were significantly smaller than in the respective layers connected with the normal right

eye. This apparently increased sensitivity of the ipsilateral vs. contralateral LGN layers had been previously noted by us in amblyopic monkeys^{335, 359} and is of special interest with regard to the findings of Herzau and coworkers.²⁰¹ These authors found a consistent threshold elevation in the nasal field when measuring the differential light thresholds in the nasal and temporal visual field of patients with strabismic amblyopia. The nasal field corresponds to the temporal retina, which is connected to the ipsilateral LGN layers.

It is of special interest for the etiology of am-

FIGURE 14-20. Cortical eye dominance histograms for two young monkeys showing reversal of cortical dominance shift by eyelid suture of normal eye. *A*, Effect of reverse eyelid suture following strabismus. *B*, Effect of a period of normal visual experience following realignment of the visual axes. ND, nondriven neurons. (From Crawford MLJ, Noorden GK von: The effects of short-term experimental strabismus on the visual system in *Macaca mulatta*. Invest Ophthalmol Vis Sci 18:496, 1979.)



amblyopia that in anisometric and visual deprivation amblyopia, both the monocularly and binocularly innervated portions of the monkey LGN shrink, whereas in strabismic amblyopia shrinkage was limited to the binocularly innervated part.^{346, 359} From these and other findings³⁴¹ one may assume that disuse, which affects both the monocular and

binocular aspects of the afferent visual pathways, plays no significant role in strabismic amblyopia.

Wiesel and coworkers⁴⁶⁸ described the columnar arrangement of geniculocortical terminals in layer IVc, and Hubel and coworkers²²⁵ noted expansion of one set of columns at the expense of a deprived column after unilateral lid suture in

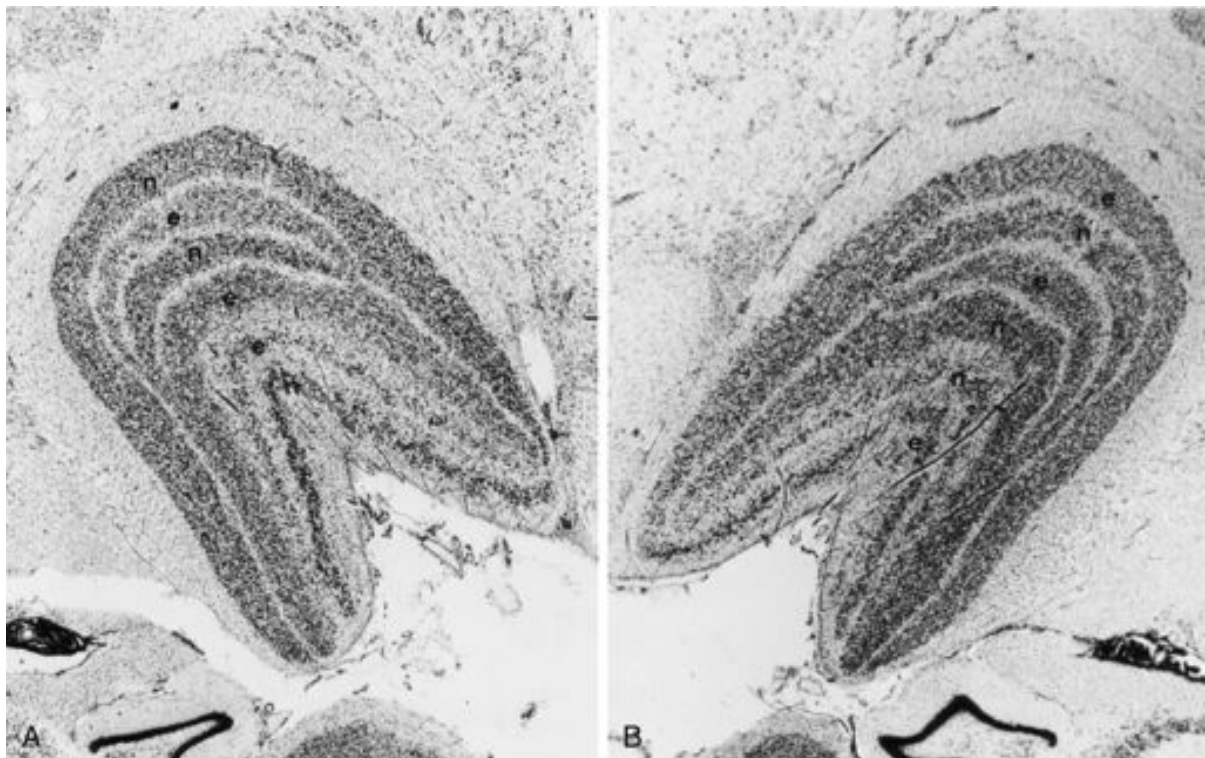


FIGURE 14-21. *A*, Right and *B*, left lateral geniculate nucleus of a monkey with strabismic amblyopia caused by a right esotropia of 50°, surgically induced at the age of 7 days. Reduced cell sizes cause decreased staining in all layers connected with the esotropic eye (*e*) when compared with those from the normal eye (*n*). (From Noorden GK von: Histological studies of the visual system in monkeys with experimental amblyopia. Invest Ophthalmol 12:727, 1973.)

TABLE 14-3. Comparisons of the Means of Lateral Geniculate Nucleus (LGN) Cell Area Sizes from a Human Patient with Strabismic Amblyopia of the Left Eye

Layer	Left LGN (μm^2)	LE/RE (%)	Right LGN (μm^2)
1	258 SD 58	NS	278 SD 58
2	235 SD 54	-18	286 SD 49
3	142 SD 33	-18	171 SD 34
4	143 SD 32	NS	144 SD 33
5	126 SD 32	-25	168 SD 35
6	121 SD 32	NS	142 SD 42

LE/RE; left eye/right eye; SD standard deviation; NS, not significant.

Data from Noorden GK von, Crawford MLS: The lateral geniculate nucleus in human strabismic amblyopia. Invest Ophthalmol Vis Sci 33:2729, 1992.

monkeys. It remains to be seen whether these structural alterations in the visual cortex occur also with strabismic and anisometropic amblyopia.

Recent research data from studies in rats and cats with strabismic and visual deprivation amblyopia indicate that the shift in the cortical dominance pattern^{43, 115, 117, 292} and the cell shrinkage in the LGN¹¹⁶ can be prevented by application of NGF, a neurotrophin, directly to the visual cortex. Once the validity of this effect can be established for the primate visual system these findings may some day be of interest in the prevention of human amblyopia.

Animal experiments have clearly identified two amblyopiogenic factors, *visual deprivation* and *abnormal binocular interaction between unequal visual input*, and have shown to what extent certain parts of the afferent visual pathways may be functionally and structurally affected in clinically different forms of amblyopia. The question remains whether the human amblyopic visual system reacts similarly. With respect to histologic changes in the LGN, this question can now be answered affirmatively, at least as far as anisometropic and strabismic amblyopia are concerned.^{348, 349} With regard to the decrease in cortical neuronal activity shown by invasive methods in amblyopic animal models, a demonstration of similar changes in human amblyopic brains was, for obvious reasons, not feasible until recently. However, with the advent of new noninvasive imaging techniques, a reduction in neuronal activity has also been demonstrated in the visual cortex of human amblyopes. Positron emission tomography (PET) scans permit noninvasive assessment of relative cortical blood flow and glucose metabolism during visual activity. Applying this technique to human

subjects with visual deprivation, anisometropic, and strabismic amblyopia, Demer and coworkers^{109, 110} could show a significant reduction in relative cortical blood flow and glucose metabolism during visual stimulation of the amblyopic eye as compared with the sound eye. (See Color Plates 1 and 2.) These findings have confirmed in humans what has been established with invasive techniques in animal models and have opened new avenues for amblyopia research. They suggest that the visual cortex is the primary site of amblyopia. The decrease in LGN cell sizes may be caused by retrograde inhibition originating in the striate cortex in strabismic and anisometropic amblyopia. In pattern vision deprivation amblyopia, on the other hand, lack of afference may reduce metabolic activity and thus cause the cell shrinkage.

Demer and coworkers also correlated PET with visual acuity, contrast sensitivity, horizontal optokinetic nystagmus, and visual evoked potentials in amblyopic subjects.^{107, 108} There was good correlation between letter acuity loss in the amblyopic eye and activation of blood flow in the calcarine cortex during visual stimulation with an alternating phase checkerboard. These authors also demonstrated different features in the PET of anisometropic and strabismic amblyopes.

The Essence of Amblyopia

The clinical features and laboratory findings in eyes with amblyopia permit certain conclusions for understanding the nature of the processes underlying amblyopia and its treatment.

Strabismic amblyopia represents a loss of the physiologic superiority of the fovea. This superiority is characteristic of the photopic state. The amblyopic eye is functionally at its worst at photopic luminance levels, at which point the foveae of these eyes display certain characteristics of the dark-adapted state. There is justification for postulating that the amblyopic eye behaves in a manner similar to that of a dark-adapted normal eye. The range of disturbance of visual function in amblyopia is extraordinarily wide and, as pointed out in the preceding pages, includes a large variety of sensory and motor functions. Decreased visual acuity, although clinically the most tangible defect, is but one of the many disturbances associated with amblyopia regardless of its etiology. Differences exist in psychophysical functions between the fovea and the retinal periph-

ery in human strabismic amblyopia on the one hand and in anisometropic and visual deprivation amblyopia on the other hand. There are also differences in the severity and reversibility of the various types of amblyopia. However, the structural and neurophysiologic anomalies of the afferent visual pathways in animal models with different forms of experimental amblyopia are similar, as is the sensitive period during which amblyopia occurs, regardless of its etiology. Rather than postulate a different neural basis for different types of amblyopia, we believe that the basic amblyopogenic mechanisms are the same even though their contribution to each type of amblyopia varies (see Table 14–2). These mechanisms are (1) disuse from lack of adequate foveal or peripheral retinal stimulation and (2) abnormal binocular interaction between conflicting visual input from the two foveae. Decreased usage may affect the afferent visual system at any point between the retina and visual cortex, whereas abnormal binocular interaction can become effective only where such interaction is anatomically possible, that is, in the striate cortex.

REFERENCES

1. Abraham SV: Accommodation in the amblyopic eye. *Am J Ophthalmol* 52:197, 1961.
2. Abrahamsson M, Fabian G, Andersson AK, Sjöstrand J: A longitudinal study of a population based sample of astigmatic children. I. Refraction and amblyopia. *Acta Ophthalmol (Scand)* 68:428, 1990.
3. Abrahamsson M, Fabian G, Sjöstrand J: A longitudinal study of a population based sample of astigmatic children. II. The changeability of anisometropia. *Acta Ophthalmol Scand* 68:435, 1990.
4. Abrahamsson M, Sjöstrand J: Natural history of infantile anisometropia. *Br J Ophthalmol* 80:860, 1996.
5. Accardi V: La soglia dell'eccitamento luminoso in condizioni normali e patologiche e sotto l'azione di alcuni farmaci. *Ann Ottalmol* 61:481, 1933.
6. Aggarwal DP, Verma G: Static perimetry in the study of amblyopia scotomata. *Br J Ophthalmol* 64:713, 1980.
7. Alpern M, Flitman DB, Joseph RH: Centrally fixed flicker thresholds in amblyopia. *Am J Ophthalmol* 49:1194, 1960.
8. Ammann E: Einige Beobachtungen bei den Funktionsprüfungen in der Sprechstunde: "Zentrales" Sehen—Sehen der Glaukomatösen. Sehen der Amblyopen. *Klin Monatsbl Augenheilkd* 67:564, 1921.
9. Anderson RL, Baumgartner SA: Amblyopia in ptosis. *Arch Ophthalmol* 98:1068, 1980.
10. Api S, Mena JI, Vasquez AF, et al: Perdida del ojo fijador en adulto con ambliopia estrabica. *Anal Soc Mex Oftalmol* 56:445, 1982.
11. Apkarian P, Levi D, Tyler CW: Binocular facilitation in the visual-evoked potential of strabismic amblyopia. *Am J Optom Physiol Opt* 56:820, 1981.
12. Arden GB, Barnard WM, Mushin AS: Visually evoked responses in amblyopia. *Br J Ophthalmol* 58:183, 1974.
13. Arden GB, Wooding SL: Pattern ERG in amblyopia. *Invest Ophthalmol Vis Sci* 26:88, 1985.
14. Arden GB, Veagan, Hogg CR: Pattern ERGs are abnormal in many amblyopes. *Trans Ophthalmol Soc UK* 100:453, 1980.
15. Arruga A: *Diagnostico y Tratamiento del Estrabismo*, vol 2. Madrid, Bermejo y Morato, 1962, p 472.
16. Assaf AA: The sensitive period: Transfer of fixation after occlusion for strabismic amblyopia. *Br J Ophthalmol* 66:64, 1982.
17. Atkinson J, Braddick O, Bobier B, et al: Two infant vision screening programmes: Prediction and prevention of strabismus and amblyopia from photo- and videorefractive screening. *Eye* 10:189, 1996.
18. Attebo K, Mitchell P, Cumming R, et al: Prevalence and causes of amblyopia in an adult population. *Ophthalmology* 105:154, 1998.
19. Aulhorn E: *Perimetrische Befunde beim Zentralskotom*. III. Postgraduate Course for Ophthalmologists, Giessen, Germany, 1961.
20. Aulhorn E: Die gegenseitige Beeinflussung abbildungsgleicher Netzhautstellen bei normalem und gestörtem Binocularsehen. *Doc Ophthalmol* 23:26, 1967.
21. Aulhorn E, Lichtenberg C: Central and peripheral visual acuity of eyes suffering from strabismus amblyopia. In Mein J, Bierlaagh JJM, Brummelkamp-Dons TEA, eds: *Orthoptics*. Amsterdam, Excerpta Medica, 1972, p 153.
22. Avetisov ES: Visual acuity and contrast sensitivity of the amblyopic eye as a function of the stimulated region of the retina. *Am J Optom Physiol Opt* 56:465, 1979.
23. Avilla CW, Noorden GK von: Clinical observations in anisometropic amblyopia. In Lenk-Schäfer M, Calcutt C, Doyle M, Moore S, eds: *Orthoptic Horizons*. Transactions of the Sixth International Orthoptic Congress, Harrogate, England, LIPS, 1987, p 113.
24. Awaya S, Miyake Y, Imaizumi Y, et al: Amblyopia in man, suggestive of stimulus, deprivation. *Jpn J Ophthalmol* 17:69, 1973.
25. Awaya S, Noorden GK von: Visual acuity of amblyopic eyes under monocular and binocular conditions: Further observations. In Mein J, Bierlaagh JJM, Brummelkamp-Dons TEA, eds: *Orthoptics*. Amsterdam, Excerpta Medica, 1972, p 146.
26. Awaya S, Tanabe S, Ueda W: On visual acuity of amblyopic eye under binocular condition. (1) Anisometropic hypermetropic amblyopia. *Acta Soc Ophthalmol Jpn* 72:535, 1968.
27. Baker FH, Grigg P, Noorden GK von: Effects of visual deprivation and strabismus on the response of neurons in the visual cortex of the monkey, including studies on the striate and prestriate cortex in the normal animal. *Brain Res* 66:185, 1974.
28. Bangerter A: *Amblyopiebehandlung*, ed 2. Basel, S Karger, 1955.
29. Bárány EH, Halldén U: Phasic inhibition of the light reflex of the pupil during retinal rivalry. *J Neurophysiol* 11:25, 1948.
30. Bárány EH, Halldén U: Experiments aiming at the treatment of squint amblyopia with medicaments. *Acta Ophthalmol* 27:138, 1949.
31. Barbeito R, Bedell HE, Flom MC: Does impaired contrast sensitivity explain the spatial uncertainty of amblyopes? *Invest Ophthalmol Vis Sci* 29:323, 1988.
32. Barbeito R, Bedell HE, Flom MC, Simpson TL: Effects of luminance on the visual acuity of strabismic and anisometropic amblyopes and optically blurred normals. *Vision Res* 27:1543, 1987.
33. Barnard WM, Kelsey JH: Changes in the visually evoked response during treatment for amblyopia in a uni-ocular patient. *Trans Ophthalmol Soc UK* 100:472, 1980.
34. Baumgartner G: Indirekte Größenbestimmung der rezeptiven Felder der Retina beim Menschen mittels der Hermannschen Gittertäuschung. *Pflugers Arch* 272:24, 1962.

35. Baxt N: Über die Zeit, welche nötig ist, damit ein Gesichtseindruck zum Bewusstsein kommt und über die Grösse (Extension) der bewussten Wahrnehmung bei einem Gesichtseindruck von gegebener Dauer. *Arch Ges Physiol* 4:325, 1871.
36. Bedell HE: Central and peripheral retinal photoreceptor orientation in amblyopic eyes as assessed by the psychophysical Stiles-Crawford function. *Invest Ophthalmol Vis Sci* 19:49, 1980.
37. Bedell HE, Flom MC: Monocular spatial distortion in strabismic amblyopia. *Invest Ophthalmol Vis Sci* 20:263, 1981.
38. Bedell HE, Flom MC: Normal and abnormal space perception. *Am J Optom Physiol Opt* 60:426, 1983.
39. Bedell HE, Flom MC: Bilateral oculomotor abnormalities in strabismic amblyopes: Evidence for a common central mechanism. *Doc Ophthalmol* 59:309, 1985.
40. Bedell HE, Flom MC, Barbeito R: Spatial aberrations and acuity in strabismus and amblyopia. *Invest Ophthalmol Vis Sci* 26:909, 1985.
41. Bedell HE, Kandel GL: Experimentally induced variations in the dark adaptation functions of a severe strabismic amblyope. *Doc Ophthalmol* 41:129, 1976.
42. Bedell HE, Yap YL, Flom M: Fixation drift and nasal-temporal pursuit asymmetries in strabismic amblyopia. *Invest Ophthalmol Vis Sci* 31:968, 1990.
43. Berardi N, Domenici L, Parisi V, et al: Monocular deprivation effects in the rat visual cortex and lateral geniculate nucleus are prevented by nerve growth factor (NGF). I. Visual cortex. *Proc R Soc Lond B Biol Sci* 251:17, 1993.
44. Best W, Bohnen K: Beziehungen zwischen Sehschärfe und zentralem Gesichtsfeld. *Bericht Dtsch Ophthalmol Ges* 59:305, 1956.
45. Bielik M, Friedman Z, Peleg B, Neumann E: Changes in refraction over a period of 3–5 years in 212 strabismic children aged one to two and a half. *Metab Ophthalmol* 2:115, 1978.
46. Bielschowsky A: Über monoculäre Diplopie ohne physikalische Grundlage, nebst Bemerkungen über das Sehen Schielender. *Graefes Arch Clin Exp Ophthalmol* 46:143, 1898.
47. Bietti GB: Sur la possibilité d'un traitement médicamenteux des phénomènes suppressifs en vision binoculaire dans le strabisme. *Probl Actuels Ophthalmol* 1:391, 1957.
48. Bietti GB, Scorsonelli M: Azione dell'O₂ su i fenomeni di soppressione in visione binoculare degli strabici. *Riv Med Aeronaut* 18:23, 1955.
49. Bjerrum J: Untersuchungen über den Lichtsinn und den Raumsinn bei verschiedenen Augenkrankheiten. *Arch Ophthalmol* 30:201, 1884.
50. Böhme G: Zur Kenntnis der exzentrischen Fixation im Hinblick auf die Behandlung der Amblyopie. *Klin Monatsbl Augenheilkd* 126:694, 1955.
51. Bonamour G: Le pronostic cloigne des hémorragies rétiennes du nouveau-né. *Bull Soc Ophthalmol* 62:277, 1949.
52. Boothe RG, Dobson V, Teller DY: Postnatal development of vision in human and nonhuman primates. *Annu Rev Neurosci* 8:495, 1985.
53. Bowering ER, Maurer D, Lewis TL, Brent HP: Constriction of the visual field of children after early visual deprivation. *J Pediatr Ophthalmol Strabismus* 34:347, 1997.
54. Bradley A, Freeman RD: Contrast sensitivity in anisometric amblyopia. *Invest Ophthalmol Vis Sci* 21:467, 1981.
55. Brown JL: Flicker and intermittent stimulation. In Graham CH, ed: *Vision and Visual Perception*. New York, John Wiley & Sons, 1965.
56. Brown JL, Mueller CG: Brightness discrimination and brightness contrast. In Graham CH, ed: *Vision and Visual Perception*. New York, John Wiley & Sons, 1965.
57. Burchfield JL, Duffy FH: Role of intracortical inhibition in deprivation amblyopia: Reversal by microionophoretic bicuculline. *Brain Res* 206:479, 1981.
58. Burian HM: Thoughts on the nature of amblyopia ex anopsia. *Am Orthopt J* 6:5, 1956.
59. Burian HM: Remarks on amblyopia and retinal correspondence in strabismus. In *II Curso International de Oftalmologia*, vol 1. Barcelona, Publicaciones del Instituto Barranquer, 1958, p 412.
60. Burian HM: Discussion of paper by Enoch JM: Receptor amblyopia. *Am J Ophthalmol* 48:262, 1959.
61. Burian HM: Über neuere Erklärungsversuche der monokularen Diplopie bei Schielenden. *Klin Monatsbl Augenheilkd* 140:813, 1962.
62. Burian HM: Occlusion amblyopia and the development of eccentric fixation in occluded eyes. *Am J Ophthalmol* 62:853, 1966.
63. Burian HM: The behavior of the amblyopic eye under reduced illumination and the theory of functional amblyopia. *Doc Ophthalmol* 23:189, 1967.
64. Burian HM: The electroretinogram in strabismic amblyopia. *Doc Ophthalmol* 23:332, 1967.
65. Burian HM: Eyedness, handedness and refractive error in relation to strabismic amblyopia. *Wiss Z Univ Leipzig Math Naturwissenschaft R* 18:236, 1969.
66. Burian HM, Benton AL, Lipsius RC: Visual cognitive functions in patients with strabismic amblyopia. *Arch Ophthalmol* 68:785, 1962.
67. Burian HM, Cortimiglia RM: Visual acuity and fixation pattern in patients with strabismic amblyopia. *Am Orthopt J* 12:169, 1962.
68. Burian HM, Lawwill T: Electroretinographic studies in strabismic amblyopia. *Am J Ophthalmol* 61:422, 1966.
69. Burian HM, Mazow ML, cited by Burian HM: The behavior of the amblyopic eye under reduced illumination and the theory of functional amblyopia. *Doc Ophthalmol* 23:189, 1967.
70. Burian HM, Watson CW: Cerebral electric responses to intermittent photic stimulation in amblyopia ex anopsia. *Arch Ophthalmol* 48:137, 1952.
71. Calcutt C, Murray ADN: Untreated essential infantile esotropia: Factors affecting the development of amblyopia. *Eye* 12:167, 1998.
72. Callahan A, Redlich F: Electroencephalography and ophthalmology. *Am J Ophthalmol* 29:1522, 1946.
73. Caloroso E, Flom MC: Influence of luminance on visual acuity in amblyopia. *Am J Optom* 46:189, 1969.
74. Campbell FW: Why do we measure contrast sensitivity? *Behav Brain Res* 10:87, 1983.
75. Campos EC: Major review. Amblyopia. *Surv Ophthalmol* 40:23, 1995.
76. Campos EC: Future directions in the treatment of amblyopia. *Lancet* 349:1190, 1997.
77. Campos EC, Bolzani R, Schiavi C, et al: Cytidine-5'-diphosphocholine enhances the effect of part-time occlusion in amblyopia. *Doc Ophthalmol* 93:247, 1997.
78. Campos EC, Cavallini GM, Codeluppi R: Weakness of antidiplopic mechanisms favours postoperative diplopia in adult patients with esotropia and amblyopia. In Murube J, ed: *Acta XVII Concilii Europae Strabologicae Associationis*, Madrid, 1988, p 65.
79. Campos EC, Gulli R: Lack of alternation in patients treated for strabismic amblyopia. *Am J Ophthalmol* 99:63, 1985.
80. Campos EC, Gulli R, Bolzani R, et al: Objective assessment of the discrepancy between line and single Es visual acuity in amblyopia by means of visually evoked

- responses. In Gregersen E, ed: Transactions of the European Strabismological Association, Copenhagen, Jencodan Tryk, 1984, p 245.
81. Campos E, Inzillo G: Functional differences between free alternators and non-alternators successfully treated for strabismic amblyopia. *Int Ophthalmol* 9:191, 1986.
 82. Campos EC, Prampoplino M, Gulli R: Contrast sensitivity differences between strabismic and anisometropic amblyopia: Objective correlate by means of visually evoked responses. *Doc Ophthalmol* 58:45, 1984.
 83. Campos EC, Schiavi C, Baldi A: Does amblyopia protect against age-related maculopathy? *Am Orthopt J* 47:86, 1997.
 84. Campos EC, Schiavi C, Benedetti P, Porciatti V: Effect of citicoline on visual acuity in amblyopia: Preliminary results. *Graefes Arch Clin Exp Ophthalmol* 233:307, 1995.
 85. Cascairo MA, Mazow ML, Holladay JT, Prager T: Contrast visual acuity in treated amblyopia. *Binocular Vision Strabismus Q* 12:167, 1997.
 86. Cavazos H, Haase W, Meyer E: Anisometropic amblyopia. *Strabismus* 1:63, 1993.
 87. Chavasse BF: Worth's Squint or the Binocular Reflexes and the Treatment of Strabismus. Philadelphia, P. Blakiston's Son & Co, 1939.
 88. Chelazzi L, Marzi CA, Panozzo G, et al: Hemiretinal differences in speed of light detection in esotropic amblyopes. *Vision Res* 28:95, 1988.
 89. Cibis L, Hurtt J, Rasicovici A: A clinical study of separation difficulty in organic and functional amblyopia. *Am Orthopt J* 18:66, 1968.
 90. Ciuffreda KJ, Hokoda SC, Hung GK, Semmlow JL: Accommodative stimulus/response function in human amblyopia. *Doc Ophthalmol* 56:303, 1984.
 91. Ciuffreda KJ, Kenyon RV, Stark L: Increased saccadic latencies in amblyopic eyes. *Invest Ophthalmol Vis Sci* 17:697, 1978.
 92. Ciuffreda KJ, Kenyon RV, Stark L: Abnormal saccadic substitution during small-amplitude pursuit tracking in amblyopic eyes. *Invest Ophthalmol Vis Sci* 18:506, 1979.
 93. Ciuffreda KJ, Kenyon RV, Stark L: Increased drift in amblyopic eyes. *Br J Ophthalmol* 64:7, 1980.
 94. Cole RBW: The problems of unilateral amblyopia. A preliminary study of 10,000 national health patients. *BMJ* 1 (5116):202, 1959.
 95. Conreur L, Danis P, Gilson M, et al: Physiopathologie de l'amblyopie fonctionnelle, *Bull Soc Belge Ophtalmol* 151:301, 1969.
 96. Coppes LA: Vision in anisometropia. *Am J Ophthalmol* 27:641, 1944.
 97. Cordella M: Sul valore del deficit morfoscopico nell'ambliopia strabica. *Atti Soc Oftalmol Lomb* 1:55, 1961.
 98. Costenbader FD, Blair D, McPhail A: Vision in strabismus. A preliminary report. *Arch Ophthalmol* 40:438, 1948.
 99. Crawford MLJ, Blake R, Cool SJ, Noorden GK von: Physiological consequences of unilateral and bilateral eye closure in macaque monkeys: Some further observations. *Brain Res* 84:150, 1975.
 100. Cüppers C: Moderne Schielbehandlung. *Klin Monatsbl Augenheilkd* 129:579, 1956.
 101. Cüppers C: Grenzen und Möglichkeiten der pleoptischen Therapie. In *Schielen-Pleoptik-Orthoptik-Operation: Bücherei des Augenarztes*, No. 38. Stuttgart, Ferdinand Enke Verlag, 1961, p 1.
 102. Cüppers C: Some reflections on the possibility of influencing the pathological fixation act. *Ann R Coll Surg Engl* 38:308, 1966.
 103. DaCunha D, Jenkins EM: Amblyopia in three year olds. *Med Officer* 106:146, 1961.
 104. Daw NW: Critical periods and amblyopia. *Arch Ophthalmol* 116:502, 1998.
 105. Dawson WW, Perry NW, Childers DG: Variation in human cortical response to patterns and image quality. *Invest Ophthalmol* 11:789, 1972.
 106. Demanins R, Wang Y-Z, Hess RF: The neural deficit in strabismic amblyopia: Sampling considerations. *Vision Res* 39:3575, 1999.
 107. Demer JL: Positron emission tomographic studies of cortical function in human amblyopia. *Neurosci Biobehav Rev* 17:469, 1993.
 108. Demer JL, Grafton S, Marg E, et al: Positron-emission tomographic study of human amblyopia with use of defined visual stimuli. *J AAPOS* 1:158, 1997.
 109. Demer JL, Noorden GK von, Volkow ND, Gould KL: Imaging of cerebral blood flow and metabolism in amblyopia by positron emission tomography. *Am J Ophthalmol* 105:337, 1988.
 110. Demer JL, Noorden GK von, Volkow ND, Gould KL: Brain activity in amblyopia. *Am Orthopt J* 41:56, 1991.
 111. de Roeth A: Statistical analysis of 1,000 consecutive new eye patients. *Am J Ophthalmol* 28:1329, 1945.
 112. Dickey CF, Scott WE: Amblyopia—the prevalence in congenital esotropia versus partially accommodative esotropia. In Lenk-Schäfer M, ed: *Orthoptic Horizons*. Transactions of the Sixth International Orthoptic Congress, Harrogate, England, 1987, p 106.
 113. Dickey SF, Metz H, Stewart S, Scott WE: The diagnosis of amblyopia in cross-fixation. *J Pediatr Ophthalmol Strabismus* 28:171, 1991.
 114. Dolének A: Beitrag zur Pupillographie. *Ophthalmologica* 139:77, 1960.
 115. Domenici L, Berardi N, Carmignoto G, et al: Nerve growth factor prevents the amblyopic effects of monocular deprivation. *Proc Natl Acad Sci USA* 88:8811, 1991.
 116. Domenici L, Cellerino A, Maffei L: Monocular deprivation effects in the rat visual cortex and lateral geniculate nucleus are prevented by nerve growth factor (NGF). II. Lateral geniculate nucleus. *Proc R Soc Lond B Biol Sci* 251:25, 1993.
 117. Domenici L, Parisi V, Maffei L: Exogenous supply of nerve growth factor prevents the effects of strabismus in the rat. *Neuroscience* 51:10, 1992.
 118. Donahue SP, Moore P, Kardon RH: Automated pupil perimetry in amblyopia. *Ophthalmology* 104:2161, 1997.
 119. Donahue SP, Wall M, Kutzko KE, Kardon RH: Automated perimetry in amblyopia: A generalized depression. *Am J Ophthalmol* 127:312, 1999.
 120. Donahue SP, Wall M, Stanek KE: Motion perimetry in anisometropic amblyopia: Elevated size thresholds extend into the midperiphery. *J AAPOS* 2:94, 1998.
 121. Downing AH: Ocular defects in sixty thousand selectees. *Arch Ophthalmol* 33:137, 1945.
 122. Duffy FH, Burchfield JL, Mower GD, et al: Comparative pharmacological effects on visual cortical neurons in monocularly deprived cats. *Brain Res* 339:257, 1985.
 123. Duffy FH, Burchfield JL, Snodgrass SR: The pharmacology of amblyopia. *Ophthalmology* 85:489, 1978.
 124. Duffy FH, Snodgrass SR, Burchfield JL, Conway JL: Bicuculline reversal of deprivation amblyopia in the cat. *Nature* 260:256, 1976.
 125. Dyer D, Bierman EO: Cortical potential changes in suppression amblyopia. *Am J Ophthalmol* 35:66, 1952.
 126. Ehlers H: Clinical testing of visual acuity. *Arch Ophthalmol* 49:431, 1953.
 127. Enoch JM: Receptor amblyopia. *Am J Ophthalmol* 48:262, 1959.
 128. Enoch JM: The current status of receptor amblyopia. *Doc Ophthalmol* 23:130, 1967.
 129. Enoch JM: Use of inverted telescopic corrections incor-

- porating soft contact lenses in the (partial) correction of aniseikonia in cases of unilateral aphakia. *Adv Ophthalmol* 32:54, 1976.
130. Enoch JM: A comment on "photoreceptor function in unilateral amblyopia." *Vision Res* 39:2311, 1999.
 131. Epelbaum M, Milleret C, Buisseret P, Dufier JL: The sensitive period for strabismic amblyopia in humans. *Ophthalmology* 100:323, 1993.
 132. Evens L, Kuypers C: Fréquence de l'amblyopie en Belgique. *Bull Soc Belge Ophtalmol* 147:445, 1967.
 133. Exner S, quoted by Frölich W: Die Empfindungszeit. Jena, Gustav Fischer, 1929, p 14.
 134. Fahle M: Naso-temporal asymmetry of binocular inhibition. *Invest Ophthalmol Vis Sci* 28:1016, 1987.
 135. Fahle M, Bachmann G: Better performance through amblyopic than through normal eyes. *Vision Res* 36:1939, 1996.
 136. Fankhauser F, Röhler R: The physical stimulus, the quality of the retinal image and foveal brightness discrimination in one amblyopic and two normal eyes. *Doc Ophthalmol* 23:149, 1967.
 137. Feinberg I: Critical flicker frequency in amblyopia ex anopsia. *Am J Ophthalmol* 42:473, 1956.
 138. Fells P: Richardson Cross Lecture 1989. Amblyopia—an historical perspective. *Eye* 4:775, 1990.
 139. Ferris FL, Bresnick GH, Bailey I: New visual acuity charts for clinical research. *Am J Ophthalmol* 94:91, 1982.
 140. Firth AY: Pupillary responses in amblyopia. *Br J Ophthalmol* 74:676, 1990.
 141. Firth AY, Davis H: Idiopathic amblyopia: The role of anisometropia in etiology. A case report. *Binocular Vision Eye Muscle Surg Q* 9:129, 1994.
 142. Fletcher MC, Silverman SJ, Boyd J, Callahan M: Biostatistical studies: Comparison of the management of suppression amblyopia by conventional patching, intensive hospital pleoptics, and intermittent office pleoptics. *Am Orthopt J* 19:40, 1969.
 143. Flom MC, Bedell HE: Identifying amblyopia using associated conditions, acuity and nonacuity features. *Am J Optom Physiol Opt* 62:153, 1985.
 144. Flom MC, Bedell H, Barbeito R: Spatial uncertainty and acuity in anisometric amblyopia. *Invest Ophthalmol Vis Sci* 26(suppl):80, 1985.
 145. Flom MC, Neumaier RW: Prevalence of amblyopia. *Public Health Rep* 81:329, 1966.
 146. Flom MC, Weymouth FW: Centricity of Maxwell's spot in strabismus and amblyopia. *Arch Ophthalmol* 66:260, 1961.
 147. Flom MC, Weymouth FW, Kahneman D: Visual resolution and contour interaction. *J Opt Soc Am* 53:1026, 1963.
 148. Flynn JT: Spatial summation in amblyopia. *Arch Ophthalmol* 78:470, 1967.
 149. Flynn JT: Amblyopia revisited (17th Annual Costenbader Lecture). *J Pediatr Ophthalmol Strabismus* 28:183, 1991.
 150. Flynn JT, McKenney SG, Dannheim E: Brightness matching in strabismic amblyopia. *Am Orthopt J* 21:38, 1971.
 151. France TD: Amblyopia update: Diagnosis and therapy. *Am Orthopt J* 34:4, 1984.
 152. François J: Discussion of paper by Burian HM: The electroretinogram in strabismic amblyopia. *Doc Ophthalmol* 23:332, 1967.
 153. François J, Verriest G: La discrimination chromatique dans l'amblyopie strabique. *Doc Ophthalmol* 23:318, 1967.
 154. Frandsen AD: Occurrence of Squint. Dissertation, University of Copenhagen, 1960.
 155. Frank JW: The clinical usefulness of the induced tropia test in amblyopia. *Am Orthopt J* 33:60, 1983.
 156. Freeman RD: Contrast sensitivity in meridional amblyopia. *Invest Ophthalmol Vis Sci* 14:78, 1975.
 157. Frezzotti R, Nucci E: Osservazioni elettroretinografiche nell'ambliopia. *G Ital Oftalmol* 11:199, 1958.
 158. Friedman Z, Neumann E, Hyams SW, Peleg B: Ophthalmic screening of 38,000 children, age 1 to 2½ years, in child welfare clinics. *J Pediatr Ophthalmol Strabismus* 17:261, 1980.
 159. Fröhlich W: Die Empfindungszeit. Jena, Germany Gustav Fischer, 1929, p 14.
 160. Fronius M, Sireteneau R: Monocular geometry is selectively distorted in the central visual field of strabismic amblyopes. *Invest Ophthalmol Vis Sci* 30:2034, 1989.
 - 160a. Fukai S, Tsutsui J, Nakamura Y: Abnormal pursuit movements of the fellow eye in amblyopia with strabismus. In Moore, S, Mein J, Stockbridge L (eds): *Orthoptics, Past, Present, Future*. Miami, FL, Symposia Specialists Medical Books, 1976, p. 75.
 161. Gallois J: Amblyopie strabique et vasodilatateurs. *Bull Soc Ophtalmol Fr* 714, 1951. [Quoted by Conreur L, Danis P, Gilson M, et al: *Physiopathologie de l'amblyopie fonctionnelle*. Brussels, Imprimerie Médicale et Scientifique, 1969, p 279.]
 162. Giaschi DE, Regan D, Kraft SP, Hong XH: Defective processing of motion-defined form in the fellow eye of patients with unilateral amblyopia. *Invest Ophthalmol Vis Sci* 33:2483, 1992.
 163. Gilson M, Lemmes G, Brouhon-Massillon L: Étude comparative de l'acuité visuelle mesurée à l'aide de différents tests chez les amblyopes. *Ann Ocul* 199:172, 1966.
 164. Glover LP, Brewster WR: Ophthalmologic review of more than 20,000 men at the Altoona induction center. *Am J Ophthalmol* 27:346, 1944.
 165. Goldmann H: Discussion of paper by Müller P: Über das Sehen der Amblyopen. *Ophthalmologica*, 121:243, 1951.
 166. Goldmann H, Favre M: Physiologische Amblyopie. *Ophthalmologica* 139:358, 1960.
 167. Goodman G, Ripps H, Siegel IM: Cone dysfunction syndromes. *Arch Ophthalmol* 70:214, 1963.
 168. Gottlob I, Charlier J, Reinecke RD: Visual acuities and scotomas after one week of levodopa administration in human amblyopia. *Invest Ophthalmol Vis Sci* 33:2722, 1992.
 169. Gottlob I, Stangler-Zuschrott E: Effect of levodopa on contrast sensitivity and scotomas in human amblyopia. *Invest Ophthalmol Vis Sci* 31:776, 1990.
 170. Gottlob I, Welge-Lüssen L: Normal pattern electroretinograms in amblyopia. *Invest Ophthalmol Vis Sci* 28:187, 1987.
 171. Graefe A von: Über das Doppelsehen nach Schiel-Operationen und Incongruenz der Netzhäute. *Arch Ophthalmol* 1:44, 1854.
 172. Greenwald MJ, Folk ER: Afferent pupillary defects in amblyopia. *J Pediatr Ophthalmol Strabismus* 20:63, 1983.
 173. Gregerson E, Rindziunski E: Conventional occlusion in the treatment of squint amblyopia. *Acta Ophthalmol* 52:60, 1965.
 174. Grosvenor T: The effect of duration and background luminance upon the brightness discrimination of the amblyope. *Am J Optom* 31:639, 1954.
 175. Haase W, Über die ophthalmologische Fixationsprüfung bei Kindern bis zu einem Alter von 2 Jahren. *Klin Monatsbl Augenheilkd* 211:113, 1997.
 176. Haase W, Fuisting B, Giesswein S, Steinhorst U: Trennschwierigkeiten—Ausdruck gestörter relativer Lokalisation? *Fortschr Ophthalmol* 88:64, 1991.
 177. Haase W, Fuisting B, Graefe S, Drobnic J: Disturbances of monocular localization in amblyopia and its relation to visual acuity. *Arch Chil Ofta* 50:156, 1993.
 178. Haase W, Hohmann A: Ein neuer Test (C-test) zur quanti-

- tativen Prüfung der Trennschwierigkeiten ("crowding"). Ergebnisse bei Amblyopie und Ametropie. *Klin Monatsbl Augenheilkd* 180:210, 1982.
179. Hagemans KH, Wildt GJ vd: The influence of the stimulus width on the contrast sensitivity function in amblyopia. *Invest Ophthalmol Vis Sci* 18:842, 1979.
 180. Hamasaki DI, Flynn JT: Depression of ERG after patching. *Arch Ophthalmol* 89:472, 1973.
 181. Hamasaki DI, Flynn JT: Amblyopic eyes have longer reaction times. *Invest Ophthalmol Vis Sci* 21:846, 1981.
 182. Hardesty HH: Occlusion amblyopia case reports. *Arch Ophthalmol* 62:314, 1959.
 183. Harms H: Ort und Wesen der Bildhemmung bei Schielenden. *Graefes Arch Clin Exp Ophthalmol* 138:149, 1938.
 184. Harms H: Stellungnahme zur Arbeit: Ort und Wesen der Bildhemmung bei Schielenden. *Bericht Dtsch Ophthalmol Ges* 66:202, 1965.
 185. Harrad RA, Graham CM, Collin JR: Amblyopia and strabismus in congenital ptosis. *Eye* 2:625, 1988.
 186. Harris JP, Calvert JE, Leendertz JA, Phillipson OT: The influence of dopamine on spatial vision. *Eye* 4:806, 1990.
 187. Hartline HK: The receptive fields of optic nerve fibers. *Am J Physiol* 130:690, 1940.
 188. Hartwig H, Kanther A, Kaufmann H: Zur Frage der Deprivations-Amblyopie. *Klin Monatsbl Augenheilkd* 168:414, 1976.
 189. Harwerth RS, Levi DM: Increment threshold spectral sensitivity in anisometropic amblyopia. *Vision Res* 17:585, 1977.
 190. Harwerth RS, Smith EL III, Boltz RL, et al: Behavioral studies on the effect of abnormal early visual experience in monkeys: Spatial modulation sensitivity. *Vision Res* 23:1501, 1983.
 191. Harwerth RS, Smith EL III, Boltz RL, et al: Behavioral studies on the effect of abnormal early visual experience in monkeys: Temporal modulation sensitivity. *Vision Res* 23:1511, 1983.
 192. Harwerth RS, Smith EL III, Crawford MLJ, Noorden GK von: Effects of enucleation of the nondeprived eye on stimulus deprivation amblyopia in monkeys. *Invest Ophthalmol Vis Sci* 25:10, 1984.
 193. Harwerth RS, Smith EL III, Duncan GC, et al: Effects of enucleation of the fixating eye on strabismic amblyopia in monkeys. *Invest Ophthalmol Vis Sci* 27:246, 1986.
 194. Hatsukawa Y, Otori T: A study of accommodation of amblyopic eye by simultaneous measurement of refraction of both eyes. In Campos E, ed: *Proceedings of the Fifth International Strabismological Association Congress, Rome, ETA, 1986* p 131.
 195. Headon MP, Powell TS: Cellular changes in the lateral geniculate nucleus of infant monkeys after suture of the eyelids. *J Anat* 116:135, 1973.
 196. Hécaen H, Ajuriaguerra J de: *Left-Handedness: Manual Superiority and Cerebral Dominance*. New York, Grune & Stratton, 1964.
 197. Helmholtz H von: Über die Zeit welche nötig ist, damit ein Gesichtseindruck zum Bewusstsein kommt. *Monatsbericht Berl Akad* 333, 1871.
 198. Helveston EM: The incidence of amblyopia ex anopsia in young adult males in Minnesota in 1962–1963. *Am J Ophthalmol* 60:75, 1965.
 199. Helveston EM: Relationship between degree of anisometropia and depth of amblyopia. *Am J Ophthalmol* 62:757, 1966.
 200. Hering E: *Zur Lehre vom Ortssinn der Netzhaut*. Beiträge zur Physiologie, vol 3. Leipzig, Wilhelm Engelmann, 1861, p 182.
 201. Herzau V, Girschbach C, Roth A: Nasal-temporal asymmetry of the differential light threshold in strabismic amblyopia. In Kaufmann H, ed: *Transactions of the 20th Meeting of the European Strabismological Association*, Brussels, Gahmig Druck, 1992, p 107.
 202. Herzau V, Girschbach C, Roth A: Evaluation of the Ammann test in the clinical routine. In Kaufmann H, ed: *Transactions of the 21st Meeting of the European Strabismological Association, Salzburg, Austria 1993*, p 15.
 203. Hess RF: On the assessment of contrast threshold functions for anomalous vision. *Br Orthopt J* 41:1, 1974.
 204. Hess RF: Eye movements and grating acuity in strabismic amblyopia. *Ophthalmol Res* 9:225, 1977.
 205. Hess RF: On the relationship between strabismic amblyopia and eccentric fixation. *Br J Ophthalmol* 61:767, 1977.
 206. Hess RF: The site and nature of suppression in squint amblyopia. *Vision Res* 31:111, 1991.
 207. Hess RF: Is amblyopia an impediment to binocular function? *Eye* 10:245, 1996.
 208. Hess RF, Baker CL, Verhoeve JN, et al: The pattern evoked electroretinogram: Its variability in normals and its relationship in amblyopia. *Invest Ophthalmol Vis Sci* 26:1610, 1985.
 209. Hess RF, Campbell FW, Creenhalgh T: On the nature of the neural abnormality in human amblyopia: Neural aberrations and neural sensitivity loss. *Pflugers Arch* 377:201, 1978.
 210. Hess RF, Dakin SC, Kapoor N: The foveal "crowding" effect: Physics or physiology. *Vision Res* 40:365, 2000.
 211. Hess RF, France TD, Tulunay-Keesey V: Residual vision in humans who have been monocularly deprived of pattern stimulation in early life. *Exp Brain Res* 44:295, 1981.
 212. Hess RF, Howell ER: The luminance-dependent nature of the visual abnormality in strabismic amblyopia. *Vision Res* 18:931, 1978.
 213. Hess RF, Holliday IE: The spatial localization deficit in amblyopia. *Vision Res* 32:1319, 1992.
 214. Hess RF, Pointer JS: Differences in the neural basis of human amblyopia: The distribution of the anomaly across the visual field. *Vision Res* 25:1577, 1985.
 215. Hippel A von: Über Heilwirkung des Strychnins auf Amaurosen. *Sitzungsbericht des Vereins für Wissenschaft und Heilkunde, Königsberg*. *Berl Klin Wochenschr* 9:45, 1872.
 216. Hofe K von: Untersuchungen über das Sehen in Fällen von Schielamblyopie. *Klin Monatsbl Augenheilkd* 85:79, 1930.
 217. Hohmann A, Haase W: Effective vision screening can decrease the rate of amblyopia. *Ophthalmologie* 90:2, 1993.
 218. Holopigian K, Blake R, Greenwald MJ: Clinical suppression and amblyopia. *Invest Ophthalmol Vis Sci* 29:444, 1988.
 219. Hommer K, Schubert G: The absolute size of foveal receptive field centres and Panum's areas. *Graefes Arch Clin Exp Ophthalmol* 166:205, 1963.
 220. Hopkinson B, Clarke JR, Oelman BJ: Residual amblyopia in recruits to the British Army. *BMJ* 285:6346, 1982.
 221. Horwich H: Anisometropic amblyopia. *Am Orthopt J* 14:99, 1964.
 222. Howell ER, Mitchell DE, Keith CG: Contrast thresholds for sine gratings of children with amblyopia. *Invest Ophthalmol Vis Sci* 24:782, 1983.
 223. Hubel DH, Wiesel TN: Receptive fields of optic nerve fibres in the spider monkey. *J Physiol* 154:572, 1960.
 224. Hubel DH, Wiesel TN: Receptive fields of cells in striate cortex of very young inexperienced kittens. *J Neurophysiol* 26:994, 1963.
 225. Hubel DH, Wiesel TN, LeVay S: Plasticity of ocular dominance columns in monkey striate cortex. *Philos Trans R Soc Lond B Biol Sci* 278:377, 1977.
 226. Ikeda H, Tremain KE: Amblyopia occurs in retinal gan-

- gion cells in cats reared with convergent squint without alternating fixation. *Exp Brain Res* 35:559, 1979.
227. Ikeda H, Wright MJ: Is amblyopia due to inappropriate stimulation of "sustained" visual pathways during development? *Br J Ophthalmol* 58:165, 1974.
 228. Iliakis E, Moschos M, Hontos N, et al: The prognostic value of visual evoked response latency in the treatment of amblyopia caused by strabismus. *Doc Ophthalmol* 92:223, 1996.
 229. Ingram RM, Traynar MJ, Walker C, Wilson JM: Screening for refractive errors at age one year: A pilot study. *Br J Ophthalmol* 63:243, 1979.
 230. Irvine RA: Amblyopia ex anopsia: Observations on retinal inhibition, scotoma, projection, light difference, discrimination and visual acuity. *Trans Am Ophthalmol Soc* 66:527, 1945.
 231. Jacobson DM, Olson KA, Digre KB, Lam BL: Dissociation between visual acuity and critical flicker frequency in amblyopia. *Neuro Ophthalmology* 14:189, 1994.
 232. Jampolsky A, Flom BC, Weymouth FW, Moses LE: Uncorrected visual acuity as related to anisometropia. *Arch Ophthalmol* 54:893, 1955.
 233. Jayle G, Ourgaud AG: *La vision nocturne et ses troubles*. Paris, Masson, 1950, p 705.
 234. Jung R: Discussion of paper by Harms, H: Stellungnahme zur Arbeit: Ort und Wesen der Bildhemmungen Bei Schielenden. *Ber Dtsch Ophthalmol Ges* 66:202, 1965.
 235. Junghardt A, Wildberger H, Neetens A, Ende P van dem: Subjective critical flicker fusion (CFF) helps to separate amblyopia from organic disease. *Neuro Ophthalmology* 14:199, 1994.
 236. Karpe G: The basis of clinical electroretinography. *Acta Ophthalmol Scand Suppl* 24:1, 1945.
 237. Kasamatsu T: Enhancement of neuronal plasticity by activating the norepinephrine system in the brain: A remedy for amblyopia. *Hum Neurobiol* 1:49, 1982.
 238. Kasamatsu T, Pettigrew JD: Depletion of catecholamines: Failure of ocular dominance shift after monocular occlusion in kittens. *Science* 194:206, 1976.
 239. Kase M, Nagata R, Yoshida A, Hanada I: Pupillary light reflex in amblyopia. *Invest Ophthalmol Vis Sci* 25:467, 1984.
 240. Kávássy A, Kaufmann H: Untersuchungen über die hemmende Wirkung der Konturinteraktion als Teilaspekt der Pathophysiologie der Schielamblyopie. *Spektrum Augenheilkd* 6:281, 1992.
 241. Katsumi O, Uemura Y: The comparative study of the incidence of unilateral amblyopia during the past ten years. In Reinecke RD, ed: *Strabismus: Proceedings of the Third International Strabismological Association*. New York, Grune & Stratton, 1978.
 242. Katz LM, Levi DM, Bedell HE: Central and peripheral contrast sensitivity in amblyopia with varying field size. *Doc Ophthalmol* 58:351, 1984.
 243. Keech RV, Kutschke PJ: Upper age limit for the development of amblyopia. *J Pediatr Ophthalmol Strabismus* 32:89, 1995.
 244. Kelly SL, Buckingham TJ: Movement hyperacuity in childhood amblyopia. *Br J Ophthalmol* 82:991, 1998.
 245. Kiorpes L, Wallman J: Does experimentally-induced amblyopia cause hyperopia in monkeys? *Vision Res* 35:1289, 1995.
 246. Klaeger-Manzanell C, Hoyt CS, Good WV: Two step recovery of vision in the amblyopic eye after visual loss and enucleation of the fixating eye. *Br J Ophthalmol* 78:506, 1994.
 247. Knapp P, Moore S: Diagnostic procedures in an orthoptic examination. *Am Orthopt J* 12:63, 1962.
 248. Köhler L, Stigmar G: Vision screening in four year old children. *Acta Paediatr Scand* 62:17, 1973.
 249. Krüger K: Pupillenstörungen und Amblyopie. *Bericht Dtsch Ophthalmol Ges* 63:275, 1961.
 250. Krumpaszký HG, Klauss V: Epidemiology of blindness and eye disease. *Ophthalmologica* 210:1, 1996.
 251. Kuffler SW: Discharge patterns and functional organization of mammalian retina. *J Neurophysiol* 16:37, 1953.
 252. Kushner BJ: Functional amblyopia associated with organic disease. *Am J Ophthalmol* 91:39, 1981.
 253. Kushner BJ: Functional amblyopia associated with abnormalities of the optic nerve. *Arch Ophthalmol* 102:683, 1984.
 254. Kushner BJ: Successful treatment of functional amblyopia associated with juvenile glaucoma. *Graefes Arch Clin Exp Ophthalmol* 226:150, 1988.
 255. Kvarnstrom G, Jakobsson P, Lennerstrand G.: Screening for visual and ocular disorders in children. Evaluation of the system in Sweden. *Acta Paediatr* 87:1173, 1998.
 256. Lagreze WD, Sireteanu R: Two-dimensional spatial distortions in human strabismic amblyopia. *Vision Res* 31:1271, 1991.
 257. Latvala M-L, Paloheimo M, Karma A: Screening of amblyopic children and long-term follow-up. *Acta Ophthalmol Scand* 74:488, 1996.
 258. Laverne G: Étude de l'adaptation à l'obscurité des cônes de l'oeil amblyope. *Bull Soc Belge Ophtalmol* 126:1121, 1961.
 259. Laverne G, Deprez-Binot MR: Étude comparative de la fréquence critique de fusion et de la sensibilité lumineuse différentielle dans la région centrale du champ visuel de l'oeil amblyope. *Bull Soc Belge Ophtalmol* 137:385, 1964.
 260. Lawwill T: The fixation pattern of the light adapted and dark adapted amblyopic eyes. *Am J Ophthalmol* 61:1416, 1966.
 261. Lawwill T: Local adaptation in functional amblyopia. *Am J Ophthalmol* 65:903, 1968.
 262. Lawwill T, Burian HM: Luminance, contrast function and visual acuity in functional amblyopia. *Am J Ophthalmol* 62:511, 1966.
 263. Lawwill T, Muer G, Howard CW: Lateral inhibition in the central visual field of an amblyopic subject. *Am J Ophthalmol* 76:225, 1973.
 264. Lazich BM: Amblyopia ex anopsia. *Arch Ophthalmol* 39:183, 1948.
 265. Leffertstra LJ: Vergleichende Untersuchungen auf unterschiedliche Refraktionsänderungen beider Augen bei Patienten mit Strabismus convergens. *Klin Monatsbl Augenheilkd* 170:74, 1977.
 266. Leguire IE, Rogers GL, Bremer DL: Amblyopia: The normal eye is not normal. *J Pediatr Ophthalmol Strabismus* 27:32, 1990.
 267. Leguire LE, Rogers GL, Bremer DL, et al: Levodopa/carbidopa for childhood amblyopia. *Invest Ophthalmol Vis Sci* 34:3090, 1993.
 268. Leguire LE, Walson PD, Rogers GL, et al: Levodopa/carbidopa treatment for amblyopia in older children. *J Pediatr Ophthalmol Strabismus* 32:143, 1995.
 269. Lennerstrand G, Hauffman M, Jakobsson P, Kvarnstrom G: Screening methods and results in Sweden. Presented at the meeting, Paediatric Ophthalmology and Strabismus in the 21st Century, London, January 2000, organized by the Institute of Child Health of London in conjunction with the Smith Kettlewell Foundation of San Francisco.
 270. Leonards U, Sireteanu R: Interocular suppression in normal and amblyopic subjects: The effect of unilateral attenuation with neutral density filters. *Percept Psychophys* 54:65, 1993.
 271. Lepard CW: Comparative changes in the error of refraction between fixing and amblyopic eyes during growth and development. *Am J Ophthalmol* 80:485, 1975.

272. Levi DM: Patterned and unpatterned visual evoked responses in strabismus and anisometropic amblyopia. *Am J Optom Physiol Opt* 52:455, 1975.
273. Levi DM: The Glenn A. Fry Award Lecture: The "spatial grain" of the amblyopic visual system. *Am J Optom Physiol Opt* 65:767, 1988.
274. Levi DM: Spatial vision in amblyopia. In Reagan D, ed: *Vision and Visual Dysfunction*, vol 10. Spatial Vision. Houndmills, UK, Macmillan, 1991, p 212.
275. Levi DM, Harwerth RS: Spatio-temporal interactions in anisometropic and strabismic amblyopia. *Invest Ophthalmol* 16:90, 1977.
276. Levi DM, Harwerth RS: Contrast sensitivity in amblyopia due to stimulus deprivation. *Br J Ophthalmol* 64:15, 1980.
277. Levi DM, Harwerth RS, Manny RE: Supra-threshold spatial frequency detection and binocular interaction in strabismic and anisometropic amblyopia. *Invest Ophthalmol Vis Sci* 18:747, 1979.
278. Levi DM, Klein SA: Hyperacuity and amblyopia. *Nature* 298:268, 1982.
279. Levi DM, Klein SA: Vernier acuity, crowding and amblyopia. *Vision Res* 25:979, 1985.
280. Levi DM, Klein SA: Sampling in spatial vision. *Nature* 320:360, 1986.
281. Levinson JD, Gibbs EL, Stillerman ML, Perlstein MA: Electroencephalogram and eye disorders: Clinical correlation. *Pediatrics* 7:422, 1951.
282. Lindsley DB, Emmons WH: Perception time and evoked potentials (abstract). *Science* 127:1061, 1958.
283. Linksz A: *Physiology of the Eye* vol 2. Vision. New York, Grune & Stratton, 1952, pp 534 hr ff.
284. Lippmann O: Die Entartungszeichen und die Überwertigkeit einer Körperhälfte in ihrer Bedeutung für das Sehen. *Klin Monatsbl Augenheilkd* 92:370, 1934.
285. Lohmann W: Über die lokalen Unterschiede der Verschmelzungsfrequenz auf der Retina und ihr abweichendes Verhalten bei congenita. *Graefes Arch Clin Exp Ophthalmol* 68:395, 1908.
286. Lombroso CT, Duffy FH, Robb RM: Selective suppression of cerebral evoked potentials to patterned light in amblyopia ex anopsia. *Electroencephalogr Clin Neurophysiol* 27:238, 1969.
287. Lowes M, Ehlers N, Jensen IK: Visual functions after perinatal macular haemorrhage. *Acta Ophthalmol* 54:227, 1976.
288. Mackensen G: Das Fixationsverhalten amblyopischer Augen (elektro-oculographische Untersuchungen). *Graefes Arch Clin Exp Ophthalmol* 159:212, 1957.
289. Mackensen G: Reaktionszeitbestimmungen bei Amblyopie. *Graefes Arch Clin Exp Ophthalmol* 159:636, 1958.
290. Mackensen G: Monokuläre und binokuläre statische Perimetrie zur Untersuchung der Hemmungsvorgänge beim Schielen. *Graefes Arch Clin Exp Ophthalmol* 160:573, 1959.
291. Mackensen G: Discussion of paper by Burian HM: The behavior of the amblyopic eye under reduced illumination and the theory of functional amblyopia. *Doc Ophthalmol* 23:189, 1967.
292. Maffei, Berardi N, Domenici L, et al: Nerve growth factor (NGF) prevents the shift in ocular dominance distribution of visual cortical neurons in monocularly deprived rats. *J Neurosci* 12:4651, 1992.
293. Mangelschots E, Beerlandt N, Janssens H, Spileers W: Colour contrast thresholds are normal in functional amblyopia. *Eye* 10:479, 1996.
294. Manny RE, Levi DM: Psychophysical investigations of the temporal modulation sensitivity function in amblyopia: Uniform field flicker. *Invest Ophthalmol Vis Sci* 22:515, 1982.
295. Maraini G, Cordella M: Il comportamento dell'occhio ambliopico strabico dopo abbagliamento maculare. *Rassegna Ital Ottalmol* 10:30, 1961.
296. Marg E: Prentice Memorial Lecture: Is the animal model for stimulus deprivation amblyopia in children valid or useful? *Am J Optom Physiol Opt* 59:451, 1982.
297. Marré M, Marré E: Colour vision in squint amblyopia. *Mod Probl Ophthalmol* 19:308, 1978.
298. Martin G: Théorie et clinique de l'amblyopie astigmatique. *Ann Ocul* 104:101, 1890.
299. Matteucci P: Les troubles moteurs de l'amblyopie strabique. *Ann Ocul* 193:641, 1960.
300. Mayer D, Gross RD: Modified Allen pictures to assess amblyopia in young children. *Ophthalmology* 97:827, 1990.
301. Mayer L, Fulton A, Rodier D: Grating and recognition acuities of pediatric patients. *Ophthalmology* 91:947, 1984.
302. McDonald M, Dobson V, Sebris SL, et al: The acuity card procedure: A rapid test of infant visual acuity. *Invest Ophthalmol Vis Sci* 26:1158, 1985.
303. McKee SP, Schor CM, Steinman SB, et al: The classification of amblyopia on the basis of visual and oculomotor performance. *Trans Am Ophthalmol Soc* 90:123, 1992.
304. McKerall M, Plomeno RC, Leporé F, Lachapelle P: Can interocular pattern reversal visual evoked potential and motor reaction time differences distinguish anisometropic from strabismic amblyopia? *Acta Ophthalmol Scand* 77:40, 1999.
305. McMullen WH: Some points in anisometropia in discussion on problems in refraction. *Trans Ophthalmol Soc UK* 59:119, 1939.
306. McNeil NL: Patterns of visual defects in children. *Br J Ophthalmol* 39:688, 1955.
307. Meur G: Etude des sommations spatiales rétinienne dans les amblyopies fonctionnelles. *Bull Soc Belge Ophtalmol* 137:377, 1964.
308. Meur G, Payan M, Vola J: Détermination indirecte de la dimension des champs réceptifs rétinien de l'amblyope au moyen des grilles de Hermann (note préliminaire). *Bull Soc Belge Ophtalmol* 150:615, 1968.
309. Miller EF: The nature and cause of impaired vision in the amblyopic eye of a squinter. *Am J Optom* 31:615, 1954.
310. Miller EF: Investigation of the nature and cause of impaired acuity in amblyopia. *Am J Optom* 32:10, 1955.
311. Miller JE, Johnson LC, Ulett GA, Hartstein J: Photic driving in amblyopia ex anopsia. *Am J Ophthalmol* 51:463, 1961.
312. Mimura O, Inui T, Kani K, Ohmi E: Retinal sensitivity and spatial summation in amblyopia. *Jpn J Ophthalmol* 28:389, 1984.
313. Mitchell DE, Freeman RD, Millodot M, Haegerstrom G: Meridional amblyopia: Evidence for modification of the human visual system by early visual experience. *Vision Res.* 13:535, 1973.
314. Miyake Y, Awaya S: Stimulus deprivation amblyopia. Simultaneous recording of local macular electroretinogram and visual evoked response. *Arch Ophthalmol* 102:998, 1984.
315. Mohindra I, Held R, Gwiazda J, Brill S: Astigmatism in infants. *Science* 202:329, 1978.
316. Morad Y, Werker K, Nemet P: Visual acuity tests using chart, line, and single optotype in healthy and amblyopic children. *J AAPOS* 3:94, 1999.
317. Morone G, Matteucci P: Studio sull'inibizione nell'occhio affetto da ambliopia strabica. Prime ricerche di pupillografia. *Rassegna Ital Ottalmol* 27:161, 1958.
318. Moseley MJ, Fielder AR, Thompson JR, et al: Grating and recognition acuities of young amblyopes. *Br J Ophthalmol* 72:50, 1988.

319. Müller P: Über das Sehen der Amblyopen. *Ophthalmologica*. 121:143, 1951.
320. Nagel A: Die Behandlung der Amaurosen und Amblyopien mit Strychnin. *Klin Monatsbl Augenheilkd* 9:261, 1871.
321. Nastro G, Caccia Perugini G, Savastano S, et al: The evolution of refraction in the fixing and amblyopic eye. *Doc Ophthalmol* 56:265, 1984.
322. Nawratzki I, Auerbach E, Rowe H: Amblyopia ex anopsia. The electrical response in retina and occipital cortex following photic stimulation of normal and amblyopic eyes. *Am J Ophthalmol* 61:430, 1966.
323. Newman DK, East MM: Preschool vision screening: Negative predictive value for amblyopia. *Br J Ophthalmol* 83:676, 1999.
324. Niemann F, Dodt E: VECF (Musterschwelle, Amplitude, Latenz) bei verschiedener Leuchtdichte. Ein Vergleich zwischen Augengesunden, organisch und funktionellen Amblyopen. *Fortschr Ophthalmol* 88:191, 1991.
325. Noorden GK von: Modification of an ophthalmoscope for diagnosis of fixation behavior. *Am J Ophthalmol* 48 (pt 1):672, 1959.
326. Noorden GK von: Pathophysiology of amblyopia: Diagnostic and therapeutic principles of pleoptics. *Am Orthopt J* 10:7, 1960.
327. Noorden GK von: Reaction time in normal and amblyopic eyes. *Arch Ophthalmol* 66:695, 1961.
328. Noorden GK von: Bilateral eccentric fixation. *Arch Ophthalmol* 69:25, 1963.
329. Noorden GK von: Peripheral viewing in scotopic vision. *Arch Ophthalmol* 69:547, 1963.
330. Noorden GK von: Classification of amblyopia. *Am J Ophthalmol* 63:238, 1967.
331. Noorden GK von: Pathogenesis of eccentric fixation. *Doc Ophthalmol* 23:263, 1967.
332. Noorden GK von: Discussion of paper by François J, Verrist G: La discrimination chromatique dans l'amblyopie strabique. *Doc Ophthalmol* 23:318, 1967.
333. Noorden GK von: The etiology and pathogenesis of fixation anomalies in strabismus. *Trans Am Ophthalmol Soc* 67:698, 1969.
334. Noorden GK von: Experimental amblyopia in monkeys. Further behavioral observations and clinical evaluations. *Invest Ophthalmol* 12:721, 1973.
335. Noorden GK von: Histological studies of the visual system in monkeys with experimental amblyopia. *Invest Ophthalmol* 12:727, 1973.
336. Noorden GK von: Mechanisms of amblyopia. *Doc Ophthalmol* 34:93, 1977.
337. Noorden GK von: Oculomotor effects on vision—clinical aspects. In Lennerstrand G, Bach-y-Rita P, eds: *Basic Mechanisms of Ocular Motility and Their Clinical Implications*. Oxford, Pergamon Press, 1977, p 417.
338. Noorden GK von: Amblyopia: Basic concepts and current treatment. In *Symposium on Strabismus: Transactions of the New Orleans Academy of Ophthalmology*. St Louis, Mosby-Year Book, 1978, p 1.
339. Noorden GK von: New clinical aspects of stimulus deprivation amblyopia. *Am J Ophthalmol* 92:416, 1981.
340. Noorden GK von: Idiopathic amblyopia. *Am J Ophthalmol* 100:214, 1985.
341. Noorden GK von: Amblyopia: A multidisciplinary approach (Proctor Lecture). *Invest Ophthalmol Vis Sci* 26:1704, 1985.
342. Noorden GK von, Burian HM: An electrophthalmographic study of the behavior of the fixation of amblyopic eyes in light and dark adapted state. *Am J Ophthalmol* 46:68, 1958.
343. Noorden GK von, Burian HM: Visual acuity in normal and amblyopic patients under reduced illumination. I. Behavior of visual acuity with and without neutral density filter. *Arch Ophthalmol* 61:533, 1959.
344. Noorden GK von, Burian HM: Visual acuity in normal and amblyopic patients under reduced illumination. II. The visual acuity at various levels of illumination. *Arch Ophthalmol* 62:396, 1959.
345. Noorden GK von, Burian HM: Perceptual blanking in normal and amblyopic eyes. *Arch Ophthalmol* 64:817, 1960.
346. Noorden GK von, Crawford MLJ: From vision deprivation without light deprivation produces the visual deprivation syndrome in *Macaca mulatta*. *Brain Res* 129:37, 1977.
347. Noorden GK von, Crawford MLJ: Morphological and physiological changes in the monkey visual system after short-term lid suture. *Invest Ophthalmol Vis Sci* 17:762, 1978.
348. Noorden GK von, Crawford MLJ: The lateral geniculate nucleus in human strabismic amblyopia. *Invest Ophthalmol Vis Sci* 33:2729, 1992.
349. Noorden GK von, Crawford ML, Levacy RA: The lateral geniculate nucleus in human anisometropic amblyopia. *Invest Ophthalmol Vis Sci* 24:788, 1983.
350. Noorden GK von, Dowling JE: Experimental amblyopia in monkeys. II. Behavioral studies in strabismic amblyopia. *Arch Ophthalmol* 84:215, 1970.
351. Noorden GK von, Frank JW: Relationship between amblyopia and the angle of strabismus. *Am Orthopt J* 26:31, 1976.
352. Noorden GK von, Helveston EM: Influence of eye position on fixation behavior and visual acuity. *Am J Ophthalmol* 70:199, 1970.
353. Noorden GK von, Helveston EM: *Strabismus: A Decision-Making Approach*. St Louis, Mosby-Year Book, 1994, p 81.
354. Noorden GK von, Khodadoust A: Retinal hemorrhage in newborns and organic amblyopia. *Arch Ophthalmol* 89:91, 1973.
355. Noorden GK von, Leffler MB: Visual acuity in strabismic amblyopia under monocular and binocular conditions. *Arch Ophthalmol* 71:172, 1966.
356. Noorden GK von, Mackensen G: Pursuit movements in normal and amblyopic eyes. An electro-ophthalmographic study. II. Pursuit movements in amblyopic patients. *Am J Ophthalmol* 53:477, 1962.
357. Noorden GK von, Mackensen G: Phenomenology of eccentric fixation. *Am J Ophthalmol* 53:642, 1962.
358. Noorden GK von, Maumenee AE: Clinical observations on stimulus deprivation amblyopia (amblyopia ex anopsia). *Am J Ophthalmol* 65:220, 1968.
359. Noorden GK von, Middleditch PR: Histology of the monkey lateral geniculate nucleus after unilateral lid closure and experimental strabismus: Further observations. *Invest Ophthalmol* 14:674, 1975.
360. Noorden GK von, Milam J: Penalization in the treatment of amblyopia: Preliminary experiences. *Am J Ophthalmol* 88:511, 1979.
361. Noorden GK von, Dowling JE, Ferguson DC: Experimental amblyopia in monkeys. I. Behavioral studies of stimulus deprivation amblyopia. *Arch Ophthalmol* 84:206, 1970.
362. Oettel O: Zur Phänomenologie der exzentrischen Fixation. *Klin Monatsbl Augenheilkd* 141:161, 1962.
363. Oettel O, Jorde W: Über Untersuchungen der Sehschärfe in verschiedenen Gesichtsfeldbereichen bei Amblyopien mit exzentrischer Fixation unter besonderer Berücksichtigung des Gesichtsfeldzentrums. *Graefes Arch Clin Exp Ophthalmol* 164:235, 1962.
364. Oettel O, Kranke D: Vergleichende Untersuchungen über das Verhalten der Dunkeladaptation normaler and schiel-

- amblyoper Augen. Graefes Arch Clin Exp Ophthalmol 159:486, 1958.
365. Ottar WL, Scott WE, Holgado SI: Photoscreening for amblyogenic factors. *J. Pediatr Ophthalmol Strabismus* 32:289, 1995.
 366. Otto J, Safra D: Ergebnisse objektiver Akkommodationsmessungen an Augen mit organisch bedingtem Zentralskotom. *Graefes Arch Clin Exp Ophthalmol* 192:49, 1974.
 367. Packwood EA, Cruz OA, Rychwalski PJ, Keech RV: The psychosocial effects of amblyopia study. *J AAPOS* 3:15, 1999.
 368. Paliaga GP: Major review: Controversies in functional amblyopia. *Binocular Vision Strabismus* 12:155, 1997.
 369. Parsons-Smith G: Activity of the cerebral cortex in amblyopia. *Br J Ophthalmol* 37:424, 1953.
 370. Perdriel G, Lods F: L'électro-rétinographie dans l'amblyopia ex anopsia. *Ann Ocul* 196:485, 1963.
 371. Persson HE, Wanger P: Pattern-reversal electroretinograms in squint amblyopia, artificial anisometropia, and simulated eccentric fixation. *Acta Ophthalmol* 60:123, 1982.
 372. Pettigrew JD, Kasamatsu T: Local perfusion of noradrenaline maintains visual cortical plasticity. *Nature* 271:761, 1978.
 373. Pfandl E: Ein neuer Weg zur Verhinderung der Ausbildung einer anomalen retinalen Korrespondenz bei Strabismus convergens concomitans. *Acta 18th Concilium Ophthalmol Belgica* 1:202, 1958.
 374. Pigassou R, Garipuy J, Gorda M, Sforzin P: Amblyopie fonctionnelle. *Ann Ocul* 202:39, 1969.
 375. Pilgrim A, Turner S: A survey of cases of eccentric fixation in children up to 10 years of age, seen during the last 10 years. *Br Orthopt J* 31:59, 1974.
 376. Porciatti V, Schiavi C, Benedetti P, et al: Cytidine-5'-diphosphocholine improves visual acuity, contrast sensitivity and visually-evoked potentials of amblyopic subjects. *Curr Eye Res* 17:141, 1998.
 377. Portnoy JZ, Thompson HS, Lennarson L, Corbett JT: Pupillary defects in amblyopia. *Am J Ophthalmol* 96:609, 1983.
 378. Pouliquen MP: Variation de la fixation monoculaire de l'oeil strabique. *Bull Soc Ophtalmol Fr* 69, 1958.
 379. Pugh M: Visual distortion in amblyopia. *Br J Ophthalmol* 42:449, 1958.
 380. Pugh MA: Foveal vision in amblyopia. *Br J Ophthalmol* 38:321, 1954.
 381. Revell MJ: *Strabismus. A History of Orthoptic Techniques*. London, Barrie & Jenkins, 1971 p 164.
 382. Riggs LA, Johnson E, Schick A: Electrical response of the human eye to moving stimulus patterns. *Science* 144:567, 1964.
 383. Rigoulet M, Guerin B, Cohadon F, Vandendriessche M: Unilateral brain injury in the rabbit: Reversible and irreversible damage of the membranal ATP-ase. *J Neurochem* 32:535, 1979.
 384. Rogers GL, Bremer DL, Leguire LE: The contrast sensitivity function and childhood amblyopia. *Am J Ophthalmol* 104:64, 1987.
 385. Rubino A, Pereyra L: Occhio e diencefalo. IV. Comportamento della sensibilità luminosa in occhi ambliopici comparativamente agli occhi normali e sul ritmo giorno-notte. *Riv Otoneurooftalmol* 23:221, 1948.
 386. Russell EL, Kada JM, Hufhines DM: Orange County vision screening project. II. Ophthalmologic evaluation. *Sight Saving Rev* 31:215, 1961.
 387. Ruttum M, Lewandowski M: Lack of alternation in strabismic patients without amblyopia. *Am Orthopt J* 37:65, 1987.
 388. Rydberg A: Assessment of visual acuity in adult patients with strabismic amblyopia: A comparison between the preferential looking method and different acuity charts. *Acta Ophthalmol Scand* 75:611, 1997.
 389. Sachsenweger R: *Prophylaxe und Frühbehandlung der Schielschwachsichtigkeit*. Berlin, VEB Verlag Volk und Gesundheit, 1996, p 10.
 390. Sachsenweger R: Problems of organic lesions in functional amblyopia. In Arruga A, ed: *International Strabismus Symposium (University of Giessen, 1966)*. Basel, S Karger, 1968, p 63.
 391. Schiavi C, Benedetti P, Scorolli L, Campos EC: Is there a cause-effect relationship between suppression and amblyopia in strabismus? In Kaufmann H, ed: *Transactions of the 21st Meeting of the European Strabismological Association, Salzburg, Austria, 1993*, p 45.
 392. Schlossman A: Prognosis, management and results of pleoptic treatment. *Int Ophthalmol Clin* 1:8, 1961.
 393. Schmidt T: Der Ammann-Test. Versuch einer elektrophysiologischen Verifizierung. *Klin Monatsbl Augenheilkd* 192:216, 1988.
 394. Schmöger E: Der variable Lichtblitz in der klinischen Elektroretinographie. In *Elektroretinographie Symposium (Hamburg, 1956)*. *Bibl Ophthalmol* 48:48, 1957.
 395. Schmöger E, Müller W: Das Elektroretinogramm und die corticale Überleitungszeit bei Schielamblyopen. *Graefes Arch Clin Exp Ophthalmol* 167:299, 1964.
 396. Schoenleber DB, Crouch ER: Bilateral hypermetropic amblyopia. *J Pediatr Ophthalmol Strabismus* 24:75, 1987.
 397. Scholz R, Guyton D: The importance of refractive correction of amblyopia during occlusion treatment for amblyopia. *Invest Ophthalmol Vis Sci* 25 (suppl):218, 1984.
 398. Schor CM: A directional impairment of eye movement control in strabismus amblyopia. *Invest Ophthalmol* 14:692, 1975.
 399. Schor CM, Hallmark W: Slow control of eye position in strabismic amblyopia. *Invest Ophthalmol Vis Sci* 17:577, 1978.
 400. Schor C, Terell M, Peterson D: Contour interaction and temporal masking in strabismus and amblyopia. *Am J Optom Physiol Opt* 53:217, 1976.
 401. Schor CM, Westall C: Visual and vestibular sources of fixation instabilities in amblyopia. *Invest Ophthalmol Vis Sci* 25:729, 1984.
 402. Schworm HD, Kau C, Reindl B, et al: Photoscreening zur Früherkennung amblyopieauslösender Augenveränderungen. *Klin Monatsbl Augenheilkd* 210:158, 1997.
 403. Sharma V, Levi DM, Coletta NJ: Sparse-sampling of gradings in the visual cortex of strabismic amblyopes. *Vision Res* 39:3526, 1999.
 404. Shawkat FS, Kriss A, Timms C, Taylor SI.: Comparison of pattern-onset, -reversal and -offset VEPs in treated amblyopia. *Eye* 12:863, 1998.
 405. Shipley T: The visually evoked occipitogram in strabismic amblyopia under direct-view ophthalmoscopy. *J Pediatr Ophthalmol* 6:97, 1969.
 406. Silex P: Eigenartige Sehstörungen nach Blepharospasmus. *Arch Psychiatrie* 30:270, 1898.
 407. Simmers AJ, Gray LS, McGraw PV, Winn B: Functional loss in amblyopia and the effect of occlusion therapy. *Invest Ophthalmol Vis Sci* 40:2859, 1999.
 408. Singh G, Das PN: Pattern of amblyopia and fixation after keratoplasty. *Br J Ophthalmol* 62:29, 1978.
 409. Sireteanu R, Fronius M: Naso-temporal asymmetries in human amblyopia: Consequences of long-term interocular suppression. *Vision Res* 21:1055, 1981.
 410. Sireteanu R, Fronius M: Human amblyopia. Structure of the visual field. *Exp Brain Res* 79:603, 1990.
 411. Sireteanu R, Lagreze WD: Distortions in two-dimensional visual space perception in strabismic observers. *Vision Res* 33:677, 1993.

412. Sireteanu R, Singer W: The "vertical effect" in human squint amblyopia. *Exp Brain Res* 40:354, 1980.
413. Sjöstrand J: Contrast sensitivity in children with strabismic and anisometric amblyopia. A study of the effect of treatment. *Acta Ophthalmol* 59:25, 1981.
414. Sjostrand J, Abrahamsson M: Können wir Risikogruppen für die Entstehung von Amblyopie und Strabismus identifizieren? *Klin Monatsbl Augenheilk* 208:208, 1996.
415. Skottun BC, Bradley A, Freeman RD: Orientation discrimination in amblyopia. *Invest Ophthalmol Vis Sci* 27:532, 1986.
416. Sloan L: Variations in acuity with luminance in ocular disease and anomalies. *Doc Ophthalmol* 26:384, 1969.
417. Snellen H: Probebuchstaben zur Bestimmung der Sehschärfe, ed 4. 1873, Berlin, Peters. [Cited by Kávássy A, Kaufmann H: Untersuchungen über die hemmende Wirkung der Konturinteraktion als Teilsaspekt der Pathophysiologie der Schielamblyopie. *Spektrum Augenheilkd* 6:281, 1992.]
418. Smith EL, Harwerth RS, Crawford MLJ: Spatial contrast sensitivity deficits in monkeys produced by optically induced anisometropia. *Invest Ophthalmol Vis Sci* 26:330, 1985.
419. Smith JL, Flynn JT, Spiro HJ: Monocular vertical oscillations of amblyopia. The Heimann-Bielschowsky phenomenon. *J Clin Neuro Ophthalmol* 2:85, 1982.
420. Snowdon SK, Stewart-Brown SL: Amblyopia and Disability. A Qualitative Study. Health Services Research Unit, Oxford University, May 1997.
421. Sokol S: Visual evoked potentials to checkerboard pattern stimuli in strabismic amblyopia. In Desmedt J, ed: *Cerebral Evoked Potentials in Man*. Oxford, Oxford University Press, 1976.
422. Sokol S: Visually evoked potentials: Theory, techniques and clinical applications. *Surv Ophthalmol* 21:18, 1976.
423. Sokol S: Patterned elicited ERGs and VECs in amblyopia and infant vision. In Armington JC, Krauskopf J, Wooten BR, eds: *Visual Psychophysics: Its Physiological Basis*. New York, Academic Press, 1978.
424. Sokol S: Abnormal evoked potential latencies in amblyopia. *Br J Ophthalmol* 67:310, 1983.
425. Sokol S, Bloom B: Visually evoked cortical responses of amblyopes to a spatially alternating stimulus. *Invest Ophthalmol* 12:936, 1973.
426. Sokol S, Nadler D: Simultaneous electroretinograms and visually evoked potentials from adult amblyopes in response to a pattern stimulus. *Invest Ophthalmol Vis Sci* 18:848, 1975.
427. Spekrijse H, Khoe LH, Vander Tweel LH: A case of amblyopia: Electrophysiology and psychophysics of luminance and contrast. In Arden G, ed: *The Visual System Neurophysiology, Biophysics, and Their Clinical Applications: Recent Advances in Experimental Biology and Medicine*, vol 24. New York, Plenum Press, 1972, p 141.
428. Stillerman M, Gibbs E, Perlstein M: Electroencephalographic changes in strabismus. *Am J Ophthalmol* 35:54, 1952.
429. Straub W: *Das Elektroretinogramm*. Experimentelle und klinische Beobachtungen. Stuttgart, Ferdinand Enke Verlag, 1961, p 190.
430. Stuart JA, Burian HM: A study of separation difficulty: Its relationship to visual acuity in normal and amblyopic eyes. *Am J Ophthalmol* 53:471, 1962.
431. Suzuki Y, Awaya S: Long-term observation of infants with macular hemorrhage in the neonatal period. *Jpn J Ophthalmol* 42:124, 1997.
432. Tavolara L: Potere di separazione e possibilità di ricupero visivo nell'ambliopia degli strabici. *Boll Ocul* 37:508, 1958.
433. Teping C, Kamps I, Silny J: Retinale und retinocorticale Leistungszeiten bei Musterstimulation amblyoper Kinder. *Fortschr Ophthalmol* 84:496, 1987.
434. Teräskeli H: Untersuchungen über die Amblyopie ohne Spiegelbefund bei schielenden und nichtschielenden Augen mittels der Flimmermethode. *Acta Soc Med Duodecim* 19B:1, 1934.
435. Theodore FH, Johnson RM, Miles NE, Bonser WH: Causes of impaired vision in recently inducted soldiers. *Arch Ophthalmol* 31:309, 1946.
436. Thomas C, Spielmann A: A propos du test de Ammann-Burian-von Noorden. *Bull Soc Ophtalmol Fr* 63:9, 1963.
437. Thomas J: Normal and amblyopic contrast sensitivity functions in central and peripheral retinas. *Invest Ophthalmol Vis Sci* 17:746, 1978.
438. Thomas-Decortis G: Acuité visuelle angulaire et acuité visuelle morphoscopique dans l'amblyopie ex anopsia. *Bull Soc Belge Ophtalmol* 123:488, 1959.
439. Thompson AM, Nawrot M: Abnormal depth perception from motion parallax in amblyopic observers. *Vision Res* 39:1407, 1999.
440. Thompson HS: Afferent pupillary defects (pupillary findings associated with defects of the afferent arm of the pupillary light reflex arc). *Am J Ophthalmol* 62:860, 1966.
441. Tommila V, Tarkkanen A: Incidence of loss of vision in the healthy eye in amblyopia. *Br J Ophthalmol* 65:575, 1981.
442. Trauzettel-Klosinski S: Eccentric fixation with hemianopic field defects. *Neuro Ophthalmology* 18:117, 1997.
443. Tredici TD, Noorden GK von: The Pulfrich effect in anisometric amblyopia and strabismus. *Am J Ophthalmol* 98:499, 1984.
444. Tschermak-Seysenegg A von: *Introduction to Physiological Optics*. Translated by Boeder P. Springfield, IL, Charles C Thomas, 1952.
445. Tsuchiya S: Changes in contrast sensitivity of an amblyopic eye after losing the other. *Tokai J Exp Clin Med* 11:145, 1986.
446. Tsutsui J, Kawashima S, Fukai S: Short latency visual evoked potentials in functional amblyopia shown using moving topography. *Graefes Arch Clin Exp Ophthalmol* 226:301, 1988.
447. Tuttle DR: *Electrophysiological Studies of Functional Amblyopia Utilizing Pattern Reversal Techniques*. Thesis, University of Louisville, Louisville, Kentucky, 1973.
448. van Balen ATM, Henkes HE: Attention and amblyopia: Electroencephalographic approach to an ophthalmological problem. *Br J Ophthalmol* 46:12, 1962.
449. Veagan, Arden GB, Fells P: Amblyopia: Some possible relations between experimental models and clinical experience. In Wybar K, Taylor D, eds: *Pediatric Ophthalmology: Current Aspects*. New York, Marcel Dekker, 1983, p 291.
450. Venturi G, Guzzinati GC: Sulla determinazione oggettiva dell'acuità visiva negli strabici con ambliopia. *Boll Ocul* 36:113, 1957.
451. Vereecken EP, Brabant P: Prognosis for vision in amblyopia after loss of the good eye. *Arch Ophthalmol* 102:220, 1984.
452. Vereecken E, Feron A, Evens L: Importance de la détection précoce du strabisme et de l'amblyopie. *Bull Soc Belge Ophtalmol* 143:729, 1966.
453. Viehfuß TK, Künhardt G: Die objektive Prüfung der Sehschärfe bei Schielenden. *Graefes Arch Clin Exp Ophthalmol* 160:263, 1958.
454. Vinding T, Gregersen E, Jensen A, Rindziunski E: Prevalence of amblyopia in old people without previous screening and treatment. *Acta Ophthalmol* 69:796, 1991.
455. Wadensten L: The use of flicker electro-retinography in the human eye. *Acta Ophthalmol* 34:311, 1956.

456. Wald G: Discussion of paper by Harms H: Stellungnahme zur Arbeit: Ort und Wesen der Bildhemmung bei Schielenden. *Bericht Dtsch Ophthalmol Ges* 16:202, 1965.
457. Wald G, Burian HM: The dissociation of form vision and light perception in strabismic amblyopia. *Am J Ophthalmol* 27:950, 1944.
458. Wang H, Levi DM, Klein SA: Spatial uncertainty and sampling efficiency in amblyopic position acuity. *Vision Res* 38:1239, 1998.
459. Wanger P, Nilsson BY: Visual evoked responses to pattern-reversal stimulation in patients with amblyopia and/or defective binocular functions. *Acta Ophthalmol Scand* 56:617, 1977.
460. Wanger P, Person HE: Oscillatory potentials, flash and pattern-reversal electroretinograms in amblyopia. *Acta Ophthalmol Scand* 62:643, 1984.
461. Weekers R: Critical frequency of fusion. *Clinical applications. Mod Trends Ophthalmol* 3:93, 1955.
462. Weekers R, Lavergne G: Applications cliniques de la périmétrie statique. *Bull Soc Belge Ophthalmol* 119:418, 1958.
463. Weingeist L, France T, Portnoy J, Scott W: A comparison of distance and near vision in amblyopia. In Ravault A, Lenk M, eds: *Transactions of the Fifth International Orthoptic Congress*. Lyon, LIPS, 1984, p 329.
464. Westall C, Schor CM: Adaptation of the vestibulo-ocular reflex in amblyopia. *Invest Ophthalmol Vis Sci* 26:1724, 1985.
465. Westheimer G: Visual acuity and hyperacuity. *Invest Ophthalmol Vis Sci* 14:570, 1975.
466. Wiesel TN, Hubel DH: Effects of visual deprivation on morphology and physiology of cells in the cat's lateral geniculate body. *J Neurophysiol* 26:978, 1963.
467. Wiesel TN, Hubel DH: Single-cell responses in striate cortex of kittens deprived of vision in one eye. *J Neurophysiol* 26:1003, 1963.
468. Wiesel TN, Hubel DH, Lam DNK: Autoradiographic demonstration of ocular dominance columns in the monkey striate cortex by means of transneuronal transport. *Brain Res* 79:227, 1974.
469. Williams C, Papakostopoulos D: Electro-oculographic abnormalities in amblyopia. *Br J Ophthalmol* 79:218, 1995.
470. Wilson ME: Adult amblyopia reversed by contralateral cataract formation. *J Pediatr Ophthalmol Strabismus* 29:100, 1992.
471. Wood KJ, Fox JA, Stephensen MG: Contrast threshold of random-dot stereograms in anisometric amblyopia: A clinical investigation. *Br J Ophthalmol* 62:34, 1978.
472. Worth C: *Squint, Its Causes, Pathology and Treatment*, ed 6. London, Baillière, Tindall & Cox, 1929.
473. Wright K, Edelman PM, Walonker F, Yiu S: Reliability of fixation preference testing in diagnosing amblyopia. *Arch Ophthalmol* 104:549, 1986.
474. Wright KW, Kalonker F, Edelman P: 10-Diopter fixation test for amblyopia. *Arch Ophthalmol* 99:1242, 1981.
475. Yinon U, Jakobovitz L, Auerbach E: The visual evoked response to stationary checkerboard patterns in children with strabismic amblyopia. *Invest Ophthalmol* 13:293, 1974.
476. Yu M, Brown B, Edwards MH: Investigation of multifocal visual evoked potential in anisometric and esotropic amblyopes. *Invest Ophthalmol Vis Sci* 39:2033, 1998.
477. Zipf R: Binocular fixation pattern. *Arch Ophthalmol* 94:401, 1976.

Examination of the Patient—V

DEPTH PERCEPTION

Stereopsis is an epiphenomenon of normal binocular vision (see Chapter 2). Its presence or absence is an important indicator of the state of binocularity in patients with ocular motility disorders. Barring a few notable exceptions (see Chapter 16), patients with essential infantile esotropia are stereoblind or, at best, have markedly reduced stereopsis, and the potential for regaining it is practically nil. In childhood strabismus with a later onset or in adults with acquired strabismus it is an important therapeutic goal to reestablish stereopsis. Whether this can be accomplished depends on many variables, among them the age of onset and the duration of the strabismus and the completeness of ocular realignment.

Development of Stereopsis

Depth perception on the basis of binocular disparity is not fully developed at birth. Several studies using different paradigms such as line stereograms and a preferential looking procedure, random dots with a forced-choice preferential looking technique, and random dots with visually evoked responses have shown remarkably consistent findings: *stereopsis is absent in almost all infants less than 3 months old, after which it rapidly develops*

to normal levels which are reached by the sixth month of life. Interestingly, this rapid rate of maturation far exceeds that of visual acuity.¹¹ The duration of the plasticity period of stereopsis in humans still needs to be established. For a review of the literature, see Teller³¹ and Birch.⁵

Stereopsis and Strabismus

Patients with a large manifest deviation do not have useful stereopsis in casual seeing. Nevertheless, they can function quite well in space, making use of nonstereoscopic clues to depth perception, especially if the strabismus is of early origin. They may have trouble with fast-moving objects, such as flying balls, and this experience may be frustrating to young children. However, when the strabismus is acquired later in life the loss of stereopsis is felt acutely and may present a real handicap. It appears as if stereopsis is useful in the comprehension of complex visual presentations and those requiring good hand-eye coordination. Although the importance of stereopsis is often stressed, studies addressing the functional effects of stereoscopic deficits are sparse.⁸

It is always interesting and useful to determine whether a patient with strabismus has stereopsis

or the potential for such. Some patients may respond to disparate stimulations with a degree of stereopsis if the targets are placed at the objective angle, as in a major amblyoscope. Some patients (e.g., intermittent exotropes) may respond with good stereoscopic acuity even when a stereoscope is used, although they seemingly may be unable to superimpose dissimilar targets. Such patients require strong fusional stimuli to keep their eyes aligned and to fuse. When they do, they gain motor and sensory fusion, often with a high degree of stereopsis.

Some ophthalmologists use stereoscopic tests to determine whether patients with small or intermittent deviations have foveal suppression. If the stereoscopic threshold is low enough, they conclude that there is no foveal suppression.²⁷ A positive result is certainly conclusive, but a negative result does not necessarily mean that foveal images are completely suppressed. There are patients who fuse all but disparate retinal stimuli, which are selectively suppressed.

A positive stereoscopic response of a patient with a neuromuscular anomaly of the eyes at any fixation distance and in any part of the binocular field is of paramount importance prognostically and in directing treatment. This finding makes it mandatory that every effort be made, both nonsurgically and surgically, to restore to the patient full binocular cooperation with stereopsis at all fixation distances and in every part of the field.

Testing for stereopsis should always be done after operations have properly aligned the eyes. The findings may give indications whether and how to follow up the operation by nonsurgical treatment.

Testing for Stereopsis

Equipment for testing stereopsis ranges from simple equipment to complex laboratory apparatus. Only tests that the ophthalmologist can conveniently apply in the office are discussed in this section. A test for stereopsis must incorporate two essential features. The two eyes must be dissociated; that is, each eye must be presented with a separate field of view, and each of the two fields or targets must contain elements imaged on corresponding retinal areas. Thus a frame of reference is provided, and disparately imaged elements can be fused and seen stereoscopically. In addition,

there should be fiducial marks that permit the examiner to check whether both eyes are used simultaneously.

Major Amblyoscope or Stereoscope

The targets may be opaque or transparent and may be used in a major amblyoscope or stereoscope. Both devices have mechanically separated fields of view, are set optically at infinity, and use exchangeable targets. The advantage of the major amblyoscope is that its arms can be set at the patient's angle of deviation, thus allowing control of the retinal area being stimulated. Similarly the stereoscope may be used with prisms, but this procedure may not be accurate, and the distortions induced by prisms may become bothersome.

The number and variety of targets are limited only by the ingenuity of the designer and user, but standard sets of targets and cards are commercially available for the different major amblyoscopes and stereoscopes. Targets of special interest in the present context are those that contain objects with differing amounts of disparity (e.g., the Keystone DB6 card), so that they appear at different relative depth distances. The object seen in depth, which has the least disparity, denotes the patient's stereoscopic threshold.

Stereogram

A useful clinical application can be made of the simple stereogram consisting of eccentric circles, one set seen with each eye (see Fig. 2–15). If the patient reports that two fiducial marks and two circles are seen, but not in depth, one should inquire whether the two circles are concentric. They cannot be seen concentrically unless they are also seen stereoscopically. If they are seen eccentrically, one may now ask whether the inner circles are closer to the right or left of the outer circle. The patient's answer determines whether the disparate elements are suppressed in the right or the left eye.

Titmus Stereo Test

Vectograph cards dissociate the eyes optically. A vectograph consists of Polaroid material on which the two targets are imprinted so that each target is polarized at 90° with respect to the other. When the patient is provided with properly oriented Po-




FIGURE 15-1. The Titmus Stereo Test.

laroid spectacles, each target is seen separately with the two eyes. This principle is used in the Titmus Stereo Test (Fig. 15-1). In this test a gross stereoscopic pattern representing a housefly is provided to orient the patient and to establish whether there is gross stereopsis (threshold: 3000 seconds of arc). In testing young children, one must ask questions the child will understand. For example, one may ask the child to take hold of the wings of the fly. If the child sees them stereoscopically, the child will reach above the plate. It is amusing to watch the child's startled look when he or she does so. It is indeed an eerie feeling not to have a tactile sensation of a seen object. Some children, though they have stereopsis, will touch the wings on the plate because they "know" they are there. The examiner must explain to these children that he or she does not inquire about what they know, but what they see.

The Polaroid test also contains three rows of animals, one animal in each row imaged disparately (thresholds: 100, 200, and 400 seconds of arc, respectively). The child is asked which one of the animals stands out. The animal figures contain a misleading clue. In each row one of the animals, correspondingly imaged in two eyes, is printed heavily black. A child without stereopsis will name this animal as the one that stands out.

Last, the Titmus test contains nine sets of four circles arranged in the form of a lozenge. In this sequence the upper, lower, left, or right circle is disparately imaged at random with thresholds ranging from 800 to 40 seconds of arc. If the child has passed the other tests, he or she is now asked to "push down" the circle that stands out, beginning with the first set. When the child makes mistakes or finds no circle to push down, the limits of stereopsis are presumably reached.

If there is doubt whether the patient actually does see stereoscopically, one may occlude one eye and inquire whether there is a difference in appearance, say, of the housefly, with one or both eyes open. And since only horizontal disparity produces stereopsis, one can also turn the plate 90°, which should block out the stereoscopic effect.

Because of its simplicity, the Titmus Stereo Test is widely used. On the basis of this test alone, however, one is not always justified in stating simply that "the patient has no stereopsis," that is, that there is no sensitivity for disparate stimuli. One must keep in mind that the vectograph test is used for testing near vision. Some patients suppress disparate stimuli at near but respond to them in distance fixation, or vice versa, usually when the deviation is intermittent at one fixation dis-

tance and constant at the other. If such a pattern is suspected, it is always wise to supplement the vectograph test with a projected vectograph test at distance fixation (Polaroid Vectographic Project-O-Chart, American Optical Reichert) or with the B-VAT (Mentor) projection device.

In recent years much emphasis has been placed on the use of stereoacuity testing as a screening method to detect anomalies of binocular function.^{9, 29, 30} Normal stereoacuity is said to preclude suppression, amblyopia, or heterotropia, and a subnormal test result may indicate the presence of such anomalies. In applying the Titmus test as a screening device, Simons and Reinecke²⁹ found that, with the exception of the fine stereoacuity circles 5 to 9, this test often is unreliable in differentiating patients with amblyopia and heterotropia from those with normal vision. Moreover, the Titmus test is capable of indicating an artifactual stereocapability when none actually exists (see also Köhler and Stigmar¹⁴). *Some of the circles of the Titmus test may be selected even by stereoblind observers because they look "different" and not because they are seen stereoscopically.* Some patients notice an image jump in the disparate portions of the test target (e.g., the wings of the fly)

when fixating alternately and utilize this clue to pass the Titmus test despite the fact that they may be stereoblind on any of the tests using random dots.²⁹ Archer¹ described a test based on dynamic circles designed to mimic the Titmus circles as closely as possible, while eliminating lateral displacement cues as well as the possibility of passing the test by alternation.

Random-Dot Stereograms

To avoid any such visual clues, two tests are available that use random-dot stereograms.² The physiologic principle underlying these tests has been discussed in Chapter 2. Random-dot stereograms are devoid of any monocular clues, and the patient has no way of guessing what the stereofigure is and where it is located on the test plate.¹³ Reinecke and Simons²⁸ introduced the *random-dot E test (RDT)* (Fig. 15-2), which contains three cards and Polaroid spectacles. One card is a bas-relief model of the stereotest figure and is used to show the child what to look for. One of the two other test cards contains the E stereo figure, and the other is stereoblank with an identical random-dot background. The test is performed


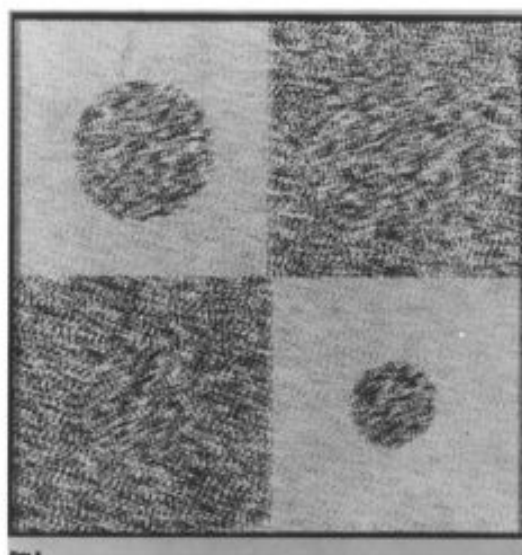


FIGURE 15-2. Random-dot E test set. (From Simons K, Reinecke RD: Amblyopia screening and stereopsis. In Symposium on strabismus: Transactions of the New Orleans Academy of Ophthalmology. St. Louis, Mosby-Year Book, 1978, p 15.)



A



B

FIGURE 15-3. A, The TNO test. B, The random-dot stereogram offers no monocular clues as to the presence of a large circle in the center of the upper right quadrant and a smaller circle in the center of the lower left quadrant. (From Noorden GK von: Present status of sensory testing in strabismus. In Symposium on Strabismus: Transactions of the New Orleans Academy of Ophthalmology. St. Louis, Mosby-Year Book, 1978, p 51.)

by holding both test cards 50 cm in front of the patient, who is then requested to indicate which card contains the letter E. The test is simple to perform, and the patient will give a “pass” or “fail” response. It can be quantitated by increasing the testing distance from the patient. Many modifications of the RDT have become available in the meantime.⁶ Random-dot stereopsis can be measured also for distance with the Mentor B-VAT II-SG computerized testing system (Mentor O & O, Norwell, MA). This is particularly useful in intermittent exotropia.³²

TNO Test

Another procedure, the TNO test, is based on a similar principle but has the advantage of eliciting quantitative responses without changing the testing distance. This test uses a pair of red-green spectacles and a test booklet (Fig. 15-3). Each test plate in the booklet consists of a stereogram in which the half-images have been superimposed and printed in complementary colors (anaglyphs). The test plates, when viewed binocularly with red-green spectacles by a normal subject, will elicit

perception of an image in depth. The TNO test is graded to provide retinal disparities ranging from 15 to 480 seconds of arc. Comparative studies have shown that this test compares favorably with the Titmus test when used as a screening device.^{26, 33} Together with the Lang test (see below) it is the preferred test in our clinic. It must be emphasized, however, that even random-dot testing of stereopsis is not a fail-safe method to assess visual acuity and binocular function in preschool and school-age children, since normal levels of stereoacuity have been observed in anisometropic and visual deprivation amblyopia.^{3, 7, 21} How should stereopsis, determined with any of the tests, be recorded? Cards and vectographs that attempt to qualify stereopsis are graded in different ways. Some use artificial scales (such as the Sheppard scale); many speak of percentage of stereopsis, assuming a certain threshold to mean 100%. All this is misleading and arbitrary. The only proper way to record stereopsis is by the amount of disparity incorporated into the target. It is unequivocal, and it should be generally understood when it is stated that a patient has stereopsis with a threshold of 400 or 100 or 40 seconds of arc or whatever the threshold may be.

Lam and coworkers¹⁵ evaluated the response of normal subjects to various visual function tests, including stereopsis. They found a wide range of responses in completely normal subjects, thus raising the question which level of stereopsis reflects normalcy (see also Fisher⁹). It appears as a difficult task to identify a cutoff value separating

normals from abnormals. These authors further stated that because of the fact that more than 40% of normal children demonstrate stereoacuity of less than 40 seconds of arc, random-dot testing is not a real measure of a biological function.

Awaya et al.⁴ studied the effects of aniseikonia on stereopsis measurements. With their aniseikonia test, they found that aniseikonia of 7% to 13% is still compatible with binocular fusion. However, aniseikonia of greater than 5% is incompatible with testing higher levels of stereoacuity with the Titmus and TNO tests.

Lang Test

Occasionally, young children will refuse to wear Polaroid or red-green spectacles, and observing the position of the eyes while the patient is being tested for stereopsis may be desirable. To overcome these difficulties, Lang^{17, 18} reported a new test (the Lang test) based on panographic presentation of a random-dot pattern. Glasses are not needed to recognize the stereoscopic images of a star, a car, and a cat (Fig. 15-4) embedded in random dots on the test card. A separate image is provided to each eye through cylindrical lenses imprinted on the surface lamination of the test card (Fig. 15-5) When held at a testing distance of 40 cm in the frontoparallel plane in front of the patient (Fig. 15-6), the disparity of the car and star is 600 seconds and of the cat 1200 seconds of arc.¹⁷ A revised version of this test (Lang II test)¹⁹ with smaller disparities and a less dense




FIGURE 15-4. Stereoscopic images embedded in random dots of the Lang test. (From Lang J: A new stereotest. *J Pediatr Ophthalmol Strabismus* 20:72, 1983.)

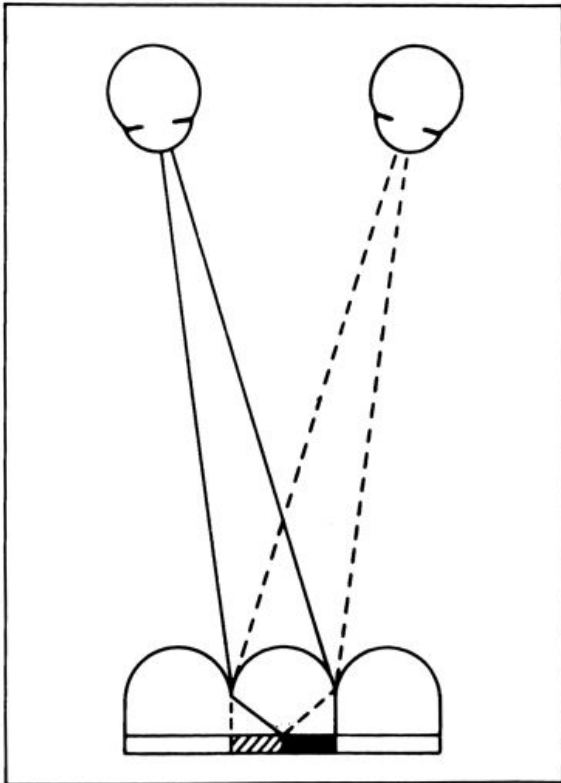


FIGURE 15-5. Cylinder gratings provide separate images for each eye. (From Lang J: A near stereotest. *J Pediatr Ophthalmol Strabismus* 20:72, 1983.)

arrangement of random dots has become available. One of the stimuli in the Lang II test is perceived binocularly and serves as a control mark. The subject can see it also in the absence of stereopsis. Test results obtained with the older and newer version of the Lang test have been reported to be comparable.²⁵ The advantage of the Lang I test is that it can be performed in children as young as 6 months of age. If the baby stares for a few seconds at the card one can infer the presence of stereopsis, following the same reasoning underlying the preferential looking testing technique.

Stereo tests that use random dots are an accurate and established method to measure stereoacuity; however, the results obtained with different tests will vary widely.²¹ As stated in Chapter 2, testing based on random dots exposes the child to visual demands that are different from and more difficult than those prevailing under more casual conditions of seeing. For instance, random-dot tests contain no information about the shape or nature of the object hidden in the visual noise of random dots. Only when the images from the right and left eye are combined at the neural level

and the object is seen in depth does recognition take place.

Two-Pencil Test

The two-pencil test, though somewhat crude, indicates how well a child is able to cope with a simple visual-motor task that is at least partially based on intact stereopsis. The two-pencil test was popularized by Lang but must have been known at least 388 years ago (1613) as shown by a sketch by Peter Paul Rubens to illustrate Aguilonius' textbook on optics¹² (Fig. 15-7). In this illustration, perhaps the oldest one available that shows the superiority of binocular over monocular vision, the cherub teasingly holds a vertical rod in front of the scholar who tries to touch the rod with his index finger from the side while keeping his left eye closed. He will not accomplish this task easily, of course, because his stereopsis cannot function with one eye closed, and the three cherubs anticipate the scholar's apparent lack of skill with great merriment.

We agree with Lang¹⁶ that the test is better performed by approaching the rod from above, since this makes better use of horizontal disparity detectors and approximates daily manual tasks that require good stereopsis, such as pouring milk into a glass or hitting a nail with a hammer. There is no question that monocular clues to depth perception (see p. 25) also are involved in completing this test. However, the drastic change of performance when one eye is covered or, for instance, when a child is fusing through bifocals but has a manifest deviation when looking through the upper segments suggests that stereopsis must be involved to a large extent in this visual task. The test is performed as shown in Figure 15-8. Its threshold values have been estimated to be between 3000 and 5000 seconds of arc, depending on the subject's interpupillary distance and arm length.²⁰

Finally, we must mention recent developments aimed at testing stereopsis objectively in infants. With the current emphasis on early diagnosis and treatment of strabismus, such efforts are of more than theoretical interest. The principle of such tests is based on the ability to elicit optokinetic nystagmus^{2, 10} or saccadic eye movements²² by electronically generated stereograms moving back and forth on a television screen. Although such methods are still largely confined to the laboratory,



FIGURE 15-6. The Lang test. The child points to the stereoscopic image. (From Lang. J: A new stereotest. *J Pediatr Ophthalmol Strabismus* 20-72, 1983.)



FIGURE 15-7. Illustration by Peter Paul Rubens in Aguilonius' textbook on optics. (From Jaeger W: Die Illustrationen von Peter Paul Rubens zum Lehrbuch der Optik des Franciscus Aguilonius/1613. Heidelberg, Verlag Brausdruck, 1976, p 36.)

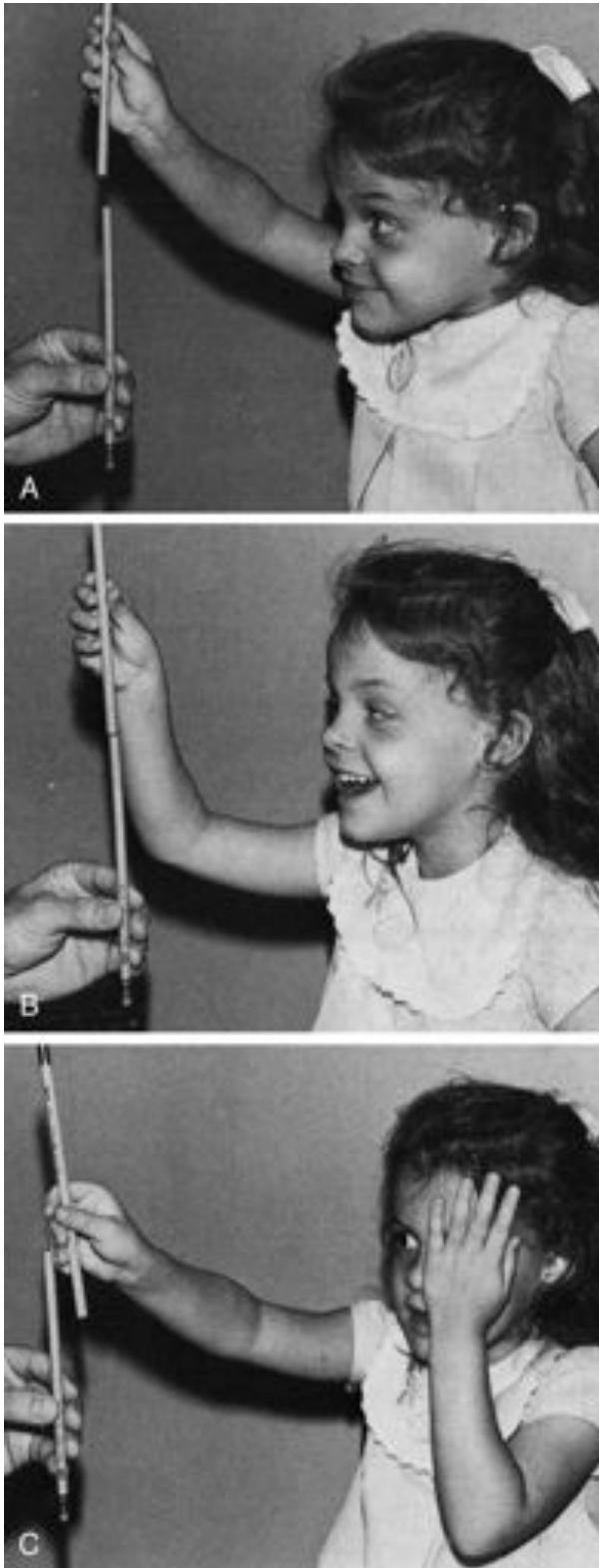


FIGURE 15-8. The two-pencil test. *A*, Examiner holds pencil vertically in front of the patient. The patient's task is to touch the upper tip of the examiner's pencil with one swift movement from above. *B*, Patient passes the test with both eyes open. *C*, Patient fails the test with one eye closed (or when both eyes are open but stereopsis is absent). (From Noorden GK von: *Atlas of Strabismus*, ed 4. St Louis, Mosby-Year Book, 1983.)

one would hope that simplified equipment will eventually become available for use in a clinical environment.

REFERENCES

1. Archer SM: Stereotest artifacts and the strabismus patient. *Graefes Arch Clin Exp Ophthalmol* 226:313, 1988.
2. Archer SM, Miller KK, Helveston EM: Stereoscopic contours and optokinetic nystagmus in normal and stereoblind subjects. *Vision Res* 27:841, 1987.
3. Avilla C, Noorden GK von: Limitation of the TNO random dot stereo test for visual screening. *Am Orthopt J* 31:87, 1981.
4. Awaya S, Sugawara M, Horibe F, et al: Studies on aniseikonia and stereopsis with the "new aniseikonia test." In Reinecke RD, ed: *Proceedings of the Fourth Meeting of the International Strabismological Association*. New York, Grune & Stratton, 1984, p 549.
5. Birch EE: Stereopsis in infants and its developmental relation to visual acuity. In Simons K, ed: *Early Visual Development, Normal and Abnormal*. New York, Oxford University Press, 1993, p 224.
6. Birch EE, Salamao S: Infant random dot stereoacuity cards. *J Pediatr Ophthalmol Strabismus* 35:86, 1998.
7. Campos E, Enoch JM: Amount of aniseikonia compatible with fine binocular vision: Some old and new concepts. *J Pediatr Ophthalmol Strabismus* 17:44, 1980.
8. Fiedler AR, Moseley MJ: Does stereopsis matter in humans? *Eye* 10:233, 1996.
9. Fisher NF: Stereopsis revisited. *J Pediatr Ophthalmol Strabismus* 34:76, 1997.
10. Fox R, Lehmkuhle S, Leguire LE: Stereoscopic contours induce optokinetic nystagmus. *Vision Res* 18:1189, 1978.
11. Held R: What can rates of development tell us about underlying mechanisms? In Granud C, ed: *Visual Perception and Cognition in Infancy*. Hillsdale, NJ, Erlbaum, 1993, p 75.
12. Jaeger W: *Die Illustrationen von Peter Paul Rubens zum Lehrbuch der Optik des Franciscus Aguilonius/1613*. Heidelberg, Verlag Brausdruck, 1976, p 36.
13. Julesz B: *Foundations of Cyclopean Perception*. Chicago, University of Chicago Press, 1971.
14. Köhler L, Stigmar G: Vision screening in four year old children. *Acta Paediatr Scand* 62:17, 1973.
15. Lam S, LaRoche GR, De Backer I, Macpherson H: The range and variability of ophthalmological parameters in normal children aged 4½ to 5½ years. *J Pediatr Ophthalmol Strabismus* 33:251, 1996.
16. Lang J: Der Treffversuch zur Prüfung des stereoskopischen Sehens. *Klin Monatsbl Augenheilkd* 165:895, 1974.
17. Lang J: New stereotests. In Boschi MC, Frosini R, eds: *Proceedings of the International Symposium on Strabismus*, Florence, Italy, June 21–23, 1982, p 177.
18. Lang J: A new stereotest. *J Pediatr Ophthalmol Strabismus* 20:72, 1983.
19. Lang J: Nine years' experience with the Lang stereotest. In Tillson G, ed: *Transactions of the Seventh International Orthoptic Congress*. Nuremberg, June 2–6, 1991, p 163.
20. LaRoche R, Noorden GK von: Theoretical and practical evaluation of a simple stereotest (abstract). *Invest Ophthalmol Vis Sci* 22 (suppl):266, 1982.
21. Marsh WR, Rawlings SC, Mumma JV: Evaluation of clinical stereoacuity tests. *Ophthalmology* 87:1265, 1980.
22. Mizukami Y, Awaya S, Koizumi E, Kamiya A: The investigation of stereoacuity in infants by the new TV random dot stereotest. *Folia Ophthalmol Jpn* 38:1182, 1987.

23. Noorden GK von: Present status of sensory testing in strabismus. In Symposium on Strabismus: Transactions of the New Orleans Academy of Ophthalmology. St Louis, Mosby-Year Book, 1978, p 51.
24. Noorden GK von: Atlas of Strabismus, ed 4. St Louis, Mosby-Year Book, 1983.
25. Nüssgens Z, Czerwonka B, Roggenkämper P: Examination of the new Lang test. *Strabismus* 1:69, 1993.
26. Okuda F, Apt L, Wanter B: Evaluation of the TNO random-dot stereogram test. *Am Orthopt J* 27:124, 1977.
27. Parks MM: Stereoacuity as an indicator of bifixation. In Arruga A, ed: International Strabismus Symposium, University of Giessen, Germany 1966. Basel, S Karger, 1968, p 258.
28. Reinecke R, Simons K: A new stereoscopic test for amblyopia screening. *Am J Ophthalmol* 78:714, 1974.
29. Simons K, Reinecke RD: A reconsideration of amblyopia screening and stereopsis. *Am J Ophthalmol* 78:707, 1974.
30. Simons K, Reinecke RD: Amblyopia screening and stereopsis. In Symposium on Strabismus: Transactions of the New Orleans Academy of Ophthalmology. St Louis, Mosby-Year Book, 1978, p 15.
31. Teller DY: First glances: The vision of infants (Friedenwald lecture). *Invest Ophthalmol Vis Sci* 38:2183, 1997.
32. Yildirim C, Altinsoy I, Yakut E: Distance stereoacuity norms for the mentor B-VAT II-SG video acuity tester in young children and young adults. *J AAPOS* 2:26, 1998.
33. Walraven J: Amblyopia screening with random-dot stereogram. *Am J Ophthalmol* 80:893, 1975.

P A R T

three

***Clinical
Characteristics of
Neuromuscular
Anomalies of the
Eye***

Esodeviations

Esodeviations are caused by innervational or mechanical factors or a combination of both. The various theories for the etiology of strabismus are reviewed in Chapter 9. As is true with other forms of strabismus, an esodeviation may be controlled by fusional divergence (esophoria), intermittently controlled (intermittent esotropia), or manifest (esotropia). In addition to the differences in etiology, other variable characteristics of esodeviations include their state of comitance, the presence of sensorial adaptations, the age of the patient at the onset, the mode of onset, the size of the angle of strabismus, and the state of fixation behavior (unilateral or alternating). Thus, esodeviations are difficult to classify and are never entirely accurately classified, since the various characteristics may overlap in a single group of esotropes. For instance, it is an accepted fact that the characteristics of infantile esotropia are fairly uniform in most patients and are different in those with accommodative esotropia. Yet, accommodative factors may become superimposed in patients with essential infantile esotropia. These reservations notwithstanding, we have found the classification of esodeviations shown in Table 16–1 to be useful for clinical purposes and as a guideline for the student.

Not all forms of esodeviations listed in Table 16–1 are discussed in this chapter. Esotropia associated with *A and V patterns* is covered in Chapter 19, and the reader is referred to Chapter 20 for a discussion of *paralytic esotropia*, to Chapter 21 for descriptions of *cyclic esotropia* and *esotropia caused by entrapment of the medial rectus muscle*

or as part of the *Duane retraction syndrome*, to Chapter 22 for *divergence insufficiency*, and to Chapter 23 for a discussion of the *nystagmus blockage syndrome*.

Esophoria and Intermittent Esotropia

Etiology

The etiology of latent or intermittent deviations is not qualitatively different from that of manifest deviations (see Chapter 9). Accommodative, non-accommodative, and other innervational (dynamic) factors may be involved.

Clinical Signs

As pointed out in Chapter 8, true orthophoria (i.e., the absence of heterophoria at any fixation distance and in any gaze position) is a rarity. Esophoria of a small degree is in fact a common finding in a normal population. Scobee²⁵⁴ stated that the average normal degree of heterophoria at infinity, as determined with a Maddox rod, is 1.4^Δ and also noted reduced stereoacuity in patients with intermittent esotropia, exotropia, and esophoria. In our experience, this symptom is frequently associated with the intermittency of a deviation, but it is rarely a prominent clinical symptom in patients with a well-compensated heterophoria. The signs and symptoms of heterophoria are discussed in Chapter 10.

TABLE 16-1. Classification of Esodeviations

- | |
|--|
| I. Comitant esodeviations |
| A. Accommodative esotropia |
| 1. Refractive accommodative esotropia (normal AC/A) |
| 2. Nonrefractive accommodative esotropia (high AC/A) |
| 3. Hypoaccommodative esotropia (reduced NPA) |
| 4. Partially accommodative esotropia |
| B. Nonaccommodative esotropia |
| 1. Infantile esotropia |
| 2. Nonaccommodative convergence excess (normal AC/A) |
| 3. Acquired (basic) esotropia |
| 4. Acute-onset esotropia |
| 5. Divergence insufficiency or paralysis* |
| 6. Cyclic esotropia* |
| 7. Recurrent esotropia |
| C. Microtropia |
| 1. Primary microtropia |
| 2. Secondary microtropia |
| D. Nystagmus "blockage" syndrome* |
| II. Incomitant esotropia* |
| A. Paralytic |
| B. Nonparalytic |
| 1. A- and V-pattern esotropia |
| 2. Retraction syndrome |
| 3. Mechanical-restrictive esodeviations |
| a. Congenital fibrosis of extraocular muscles |
| b. Acquired restriction (endocrine myopathy, trauma to orbital wall, excessive resection of medial rectus muscle(s), myositis, strabismus fixus) |
| III. Secondary esodeviations |
| A. Sensory |
| B. Consecutive |

AC/A, accommodative convergence/accommodation ratio; NPA, reduced near point of accommodation.

*Forms of esotropia discussed in other chapters of this book.

Symptoms

Unless a heterophoria is *intermittent*, in which case the patient may be aware of periodic double vision, the symptoms are mainly asthenopic (see Chapter 10) and related to visual demands made on the eyes. In other words, asthenopic complaints occurring in the morning or after periods of rest are rarely caused by heterophorias. Whether a heterophoria becomes symptomatic or is well tolerated by the patient depends largely on the fusional reserve (i.e., in the case of esophoria, on the amplitude of fusional divergence). The point has been made (see p. 206) that the heterophoric position must be taken into account when measuring fusional vergences with rotary prisms.

Sensorial Adaptation

Sensorial adaptation is not difficult to explain in heterophoric subjects with *intermittent* deviations.

Suppression or anomalous retinal correspondence develops in young patients as an adaptation to diplopia that is present during periods when the ocular deviation is manifest.

Flynn and coworkers⁹³ reported on foveal suppression under binocular conditions of viewing in patients with heterophorias and intermittent heterotropias. Using entoptic images (Haidinger's brushes and afterimages), they demonstrated in their patients not only foveal suppression but also what must be interpreted as instability of foveal visual directions. In fact, in several instances a minute angle of anomalous retinal correspondence was demonstrated. These authors emphasized that suppression in heterophoria may present a real obstacle to a functional cure. Stangler's²⁷³ observation that heterophoric patients were unsuccessful in superimposing a vertical afterimage produced in one eye on a real object fixated by the other eye also indicates an instability of foveal visual directions in this condition.

The question must be asked, Why do heterophoric subjects develop suppression or even anomalous retinal correspondence if the deviation is controlled by fusion, and what is the purpose of sensorial adaptation under such circumstances? There are two possible answers. First, the deviation in such patients at times and under certain circumstances may become manifest (intermittent strabismus), making sensorial adaptation necessary to avoid diplopia. If fusion is artificially disrupted, as shown in the tests used by Flynn and coworkers and by Stangler, suppression and anomalous retinal correspondence will become manifest. Second, in heterophoric patients with suppression, an intermittent heterotropia may be on the verge of developing. It is possible that suppression may then prevail to avoid foveal diplopia, and fusion is maintained by peripheral retinal stimulation only. We believe that deficient stereopsis in heterophoric patients may be explained on the basis of this suppression since it is known that foveal suppression of one eye under binocular conditions of viewing will cause a decrease in stereoacuity. Shippman and Cohen²⁶⁰ suggested that in patients with esophoria, stereoacuity is better with uncrossed than with crossed disparity as determined by means of the Wirt stereotest.

Diagnosis

The diagnosis of heterophoria is discussed in Chapter 12, and only a few additional comments

need to be made here. The clinician must be aware that heterophorias can be measured with only approximate accuracy. For instance, the Maddox rod test measures the *basic deviations* when fusion is disrupted, but it does not determine that part of the deviation caused by *dynamic factors* such as accommodative convergence. Thus, in a symptomatic patient with esophoria, the deviation must be measured with the prism cover test at 33 cm while the patient reads letters of an appropriate small size at random. In fact, failure to control accommodation at near fixation may lead to an erroneous diagnosis, as illustrated by the following case.

CASE 16-1

A 27-year-old woman who had suffered a mild concussion in an automobile accident 6 months earlier complained of intermittent diplopia at distance and blurred vision when trying to read and related these complaints to the injury. Litigation of this case involving a considerable sum of money was pending. Examination by another ophthalmologist had revealed a visual acuity of 6/6 OU and entirely normal ocular findings except for an intermittent esotropia of 20^Δ at distance fixation. She was reported to have orthophoria at near fixation. Ductions and versions were normal. A diagnosis of "divergence paralysis," probably related to the trauma, was made. An extensive radiographic survey of the skull and a neurologic examination were ordered. When this patient was seen by us in consultation, the same measurements (20^Δ intermittent esotropia) were obtained at distance fixation. At near fixation the alternate cover test failed to reveal a shift; however, the patient indicated that the fixation target held at 33 cm before her eyes appeared blurred. When she was asked to identify small letters at that distance, vision suddenly cleared and an intermittent esotropia of 25^Δ appeared. On further questioning, the patient admitted that she sometimes saw double at both distance and near fixation and that she had learned to avoid diplopia at near vision by "relaxing her eyes." The diagnosis of divergence paralysis could no longer be supported. We believed that the patient had an esophoria and that the deviation at near was initially missed because the patient was not accommodating on the fixation target. She was treated with base-out prisms, which almost instantly eliminated her complaint, and a resection of both lateral rectus muscles eventually brought a good result.

Case 16-1 illustrates that some patients prefer to see blurred and single by relaxing their accommodation rather than sharp and double. When

measuring heterophoria with the prism and cover test, it is important to repeatedly cover each eye for several seconds and to switch the cover rapidly from eye to eye to suspend completely the influence of fusional vergence (see Chapter 12). This technique will often reveal larger amounts of basic esodeviation than originally suspected. In doubtful cases, prolonged monocular occlusion for days or even weeks has been advocated¹⁸⁴ to disclose heterophorias that are not at once evident during the alternate cover test. *It is erroneous to assume that momentary disruption of fusion by covering each eye in a rapid fashion will totally exclude a strong innervational tonus such as the one elicited by the compulsion to fuse.*

Once the type and size of a heterophoria have been determined, the patient's ability to cope with an ocular imbalance must be evaluated by measuring fusional amplitudes (see Chapter 12).

Therapy

The principle of treating esophoria and intermittent esotropia is the same as for all other forms of latent and intermittent deviations, that is, to create conditions that will allow the patient to enjoy comfortable and functionally complete binocular vision. Depending on the individual case, this goal can be approached by using one of several modes of therapy. Before discussing these methods, we would again like to stress that esophoria per se requires no therapy unless asthenopia or evidence of deterioration of binocular functions also is present.

A symptomatic esophoric patient in whom refraction reveals a significant amount of hypermetropia (at least +1.25D sph) is treated by full correction of the hypermetropic refractive error in the same manner as in an esotropic patient. Patients with a high accommodative convergence/accommodation (AC/A) ratio and a symptomatic esophoria without hypermetropia may be considered for bifocal lenses or miotics. For details regarding this mode of therapy, see Chapter 24.

Prisms base-out may be helpful as a "crutch" in regaining visual comfort in patients with nonaccommodative esophoria. When prescribing prisms for esophoria, however, one must clearly understand that this mode of therapy does not cure the ocular imbalance; it only creates temporary conditions that enable the patient to cope more comfortably with the deviation. Correction of only one half to one third of the angle of deviation

with prisms is advisable to prevent total inactivity of the fusional divergence mechanism. Since partial or complete correction of esophoria with prisms will place fewer or no demands on fusional divergence, such patients may become increasingly dependent on their prisms. The use of correcting prisms, particularly in patients with esodeviations of dynamic origin, will result eventually in an increase of the esophoria, and prisms of increasing power will be required to create visual comfort. These objections notwithstanding, there is a place for prismatic correction in elderly patients with symptomatic esophoria who do not respond to orthoptics. In younger patients, we use prisms occasionally in those in whom fusion must be maintained until surgery can be performed (prismatic orthophorization).

Surgery should be considered only when the size of the deviation in a patient with esophoria or intermittent esotropia falls within the range (at least 12^Δ) that can be corrected without fear of overcorrection. Prerequisites for planning surgery are stability of the deviation after full correction of the hypermetropic refractive error and the presence of muscular asthenopia. When the decision has been made to operate, the surgeon should determine the extent of surgery necessary and select the muscles to be operated on in the usual manner and as outlined in Chapter 26.

On numerous occasions, we have witnessed unwarranted timidity in the surgical approach to latent or intermittent esodeviations (or exodeviation, for that matter), apparently based on the misconception that such patients have “just” a heterophoria (as opposed to a heterotropia), and therefore lesser amounts of surgery are required. This attitude is erroneous, of course, and causes undercorrections that, because of their small size, may be difficult to control by additional surgery. *The amount of surgery must be aimed at the basic deviation and on the goal to align the eyes, regardless of whether it is a latent, intermittent, or manifest deviation!* It is preferable to establish a secondary exophoria rather than be left with a residual esophoria. Convergence fusional movements and also voluntary convergence are more effective than the divergence mechanism in keeping such a residual heterophoria in check.

A conservative approach is indicated when considering surgery for esophoric patients beyond the age of 50 years. In younger patients, small surgical overcorrections present no problem and usually are easily compensated for by fusional

convergence. On the other hand, a consecutive exodeviation, regardless of how small, can cause considerable and often insurmountable difficulties in older persons. The elasticity of the fusional apparatus in overcoming motor obstacles in binocular vision tends to decline with advancing age. Experience has taught us to treat such patients with prisms; surgery should be contemplated only reluctantly and after all other therapeutic possibilities have been exhausted.

Accommodative Esotropia

An esotropia caused by an increased accommodative effort or an abnormally high AC/A ratio is referred to as “accommodative” esotropia. However, several subgroups of accommodative esotropia exist and must be clearly differentiated as each requires different clinical management.

Refractive Accommodative Esotropia (Normal AC/A Ratio)

Definition

Refractive accommodative esotropia is defined as an esotropia that is restored to orthotropia at all fixation distances and in all gaze positions by optical correction of the underlying hypermetropic refractive error.

Etiology

The relationship between accommodation and convergence and the role of an uncorrected hypermetropic refractive error in causing a comitant esodeviation was discussed earlier (see p. 139). At this juncture it is useful to summarize the etiologic components and to mention why some patients with uncorrected hypermetropia do and others do not develop esotropia (Fig. 16–1). Most patients with uncorrected hypermetropia will attempt to clear the image blur by increasing accommodative effort that will, in turn, cause excessive accommodative convergence. If fusional divergence is insufficient to compensate for this impulse to converge the eyes (Fig. 16–1A) and in the presence of a normal or high AC/A ratio, esotropia will develop. If fusional divergence amplitudes are sufficient to cope with the induced esodeviation, an esophoria will be produced (Fig. 16–1B). In the presence of a low or flat AC/A

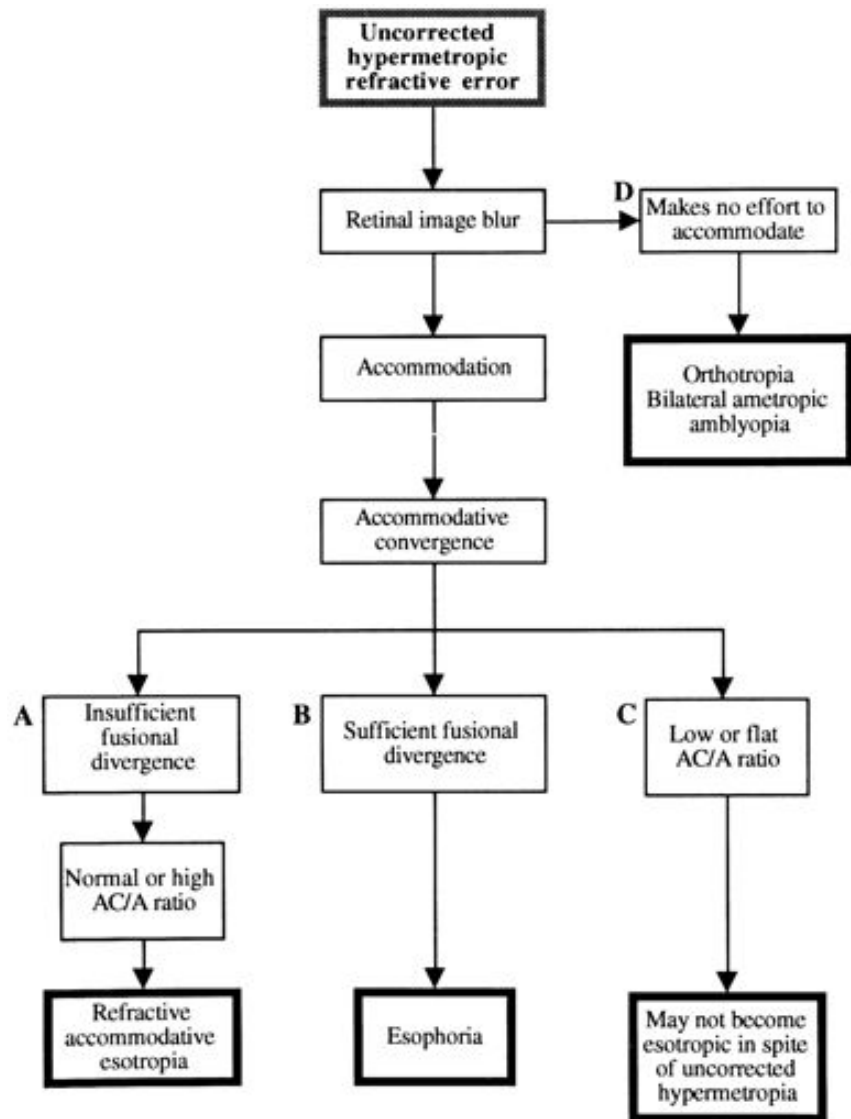


FIGURE 16-1. Consequences of uncorrected high hypermetropia. AC/A, accommodative convergence–accommodation ratio. For explanation, see text. (Modified from Noorden GK von, Helveston EM: *Strabismus: A Decision Making Approach*. St Louis, Mosby–Year Book, 1994, p 95.)

ratio, the patient may remain orthotropic since the convergence induced by excessive accommodation is normal or even subnormal²⁰⁹ (Fig. 16-1C). Finally, some patients with uncorrected high hypermetropia may remain orthotropic because they prefer blurred vision over the constant effort to accommodate excessively. Such patients may develop a mild form of pattern deprivation amblyopia in both eyes (ametropic amblyopia; see p. 252) or an accommodative deficiency with a reduced near point of accommodation,²⁰⁹ or both (Fig. 16-1D). Whether the visual system reacts with esotropia and clear vision or with orthophoria and blurred vision may depend less on the degree of hypermetropia than on the child's personality. It is our impression, which needs to be substantiated by an appropriate study, that the former group often encompasses fastidious and exacting chil-

dren and that the latter group is more relaxed and easygoing, as highlighted by Case 16-2.

CASE 16-2

An 8-year-old girl and her 6-year-old brother were brought to our office for an eye examination. The girl had a history of a gradual onset of esotropia at the age of 3 years and had worn glasses since that time. The boy had no apparent strabismus, but had failed a school vision screening test. The girl had an esotropia of 35^Δ at near and distance fixation without glasses. She was wearing a hypermetropic correction of +5.00 sph in both eyes, which fully corrected her esotropia. Her corrected visual acuity was 6/6 in each eye. The boy had the same refractive error (confirmed by cycloplegic refraction in both children), but was orthophoric with and without glasses.

His best corrected visual acuity was 6/15 in each eye, which improved to 6/9 after wearing glasses for 6 weeks. His AC/A ratio, determined by the gradient method over a range of 6D was 0. The girl was a keen observer and asked numerous questions during the examination. The boy remained silent and rather passive. When we asked the mother to describe the most pertinent personality traits of her children, she replied, "She is the absolute perfectionist, meticulous in every respect. He is completely relaxed, quite sloppy, and does not care about a thing in the world."

Clinical Characteristics

As a rule, the onset of accommodative esotropia, whether refractive or nonrefractive, is between the ages of 2 and 3 years. The onset also may be delayed until adolescence or even adulthood, when it is often precipitated by a brief period of occlusion (see acute strabismus, p. 338). We have also seen children of 1 year or less with all the clinical features of accommodative esotropia, and Pollard²³⁷ reported two infants with hypermetropia in whom esotropia developed at 4½ and 5 months of age (see also Coats and coworkers⁴⁹ and Haver-tape and coworkers¹¹¹) and whose eyes became completely aligned following correction of the refractive error. Baker and Parks¹⁴ reported additional cases and pointed out that after initial control of esotropia by means of glasses, approximately 50% of these patients developed nonaccommodative esotropia. In such cases, surgical intervention may become necessary. These authors also reported that bifoveal fusion does not develop in patients with refractive accommodative esotropia of early onset (monofixation syndrome; see p. 341) and that their ocular deviation is similar to that in patients with essential infantile esotropia. Whether this sensory deficit can be related to how long the esotropia had been present before correction with glasses is unclear. *The observations of these investigators show that the earlier viewpoint, that accommodation is inactive during infancy, can no longer be upheld.* In fact, Haynes and coworkers¹¹³ showed that accommodation may reach the adult level by the fourth month of life.

When refractive accommodative esotropia is present, the ocular deviation is usually variable and larger at near than at distance fixation. The variability of the angle of deviation depends on the general state of the patient (alert or fatigued

and on the amount of accommodation exerted at a given moment. The evolution of accommodative esotropia usually is gradual, and most patients pass through a stage of intermittent strabismus. Asthenopic symptoms, complaints about intermittent diplopia, or closure of one eye when doing close work commonly occurs during development of the disease.

Therapy

The prognosis for restoration of normal binocular function in refractive accommodative esotropia is usually excellent if normal binocular functions existed before the onset of the deviation. Full correction of the hypermetropic refractive error, determined by cycloplegic refraction, is usually all that is required initially for rehabilitation. Patients who have never worn glasses may initially complain about blurring of vision with their optical correction. In this instance a brief period of atropinization to relax accommodation may be required before the glasses are tolerated. The cycloplegic refraction is repeated annually, and the glasses are adjusted when necessary. Although there is a tendency for hypermetropia to decrease as a child gets older the majority of patients require glasses well into adolescence²⁸³ and beyond.

If the distance deviation is reduced or eliminated by glasses and esotropia remains at near fixation, the AC/A ratio is higher than normal (nonrefractive accommodative esotropia), or the patient has a nonaccommodative convergence excess. If the glasses only partially reduce the angle of strabismus at near and distance fixation, then the strabismus is not purely refractive-accommodative in nature (partially accommodative esotropia).

Abraham¹ has recommended that *miotics* be substituted for glasses in certain patients with refractive accommodative esotropia. We ordinarily do not advocate prolonged miotic therapy for this condition except in hyperactive or extremely uncooperative children for whom the incessant replacement of broken or lost spectacles imposes an unbearable financial burden on the parents. We have found it useful, however, to prescribe miotics in lieu of glasses for limited periods during the summer months for children who spend the holidays at the beach or long hours in or near a swimming pool. (For a general discussion of the

use and action of miotics in strabismus, see Chapter 24.)

Dyer⁸³ advocated *surgery* in lieu of glasses or to reduce a strong correction. He stated that “at times the risk of a subsequent exodeviation is worthwhile when the patient can enjoy years of straight eyes without glasses or much weaker correction in the glasses.” This controversial philosophy never found a following in this country but has been reendorsed in recent years by Gobin,^{100, 101} Bérard and coworkers,¹⁷ and others in Europe.⁴¹ Under the influence of these authors it has become common practice in some countries to operate for fully refractive accommodative esotropia, that is, an esodeviation that is fully offset by the appropriate optical correction. Gobin¹⁰¹ stated that he no longer believes “that hypermetropia is the cause of convergent squint” and that “the accommodative component of the squint disappears” after surgical restoration of binocular vision. Among the reasons given by the proponents of surgery is that many patients corrected with glasses will show a progressive deterioration of binocular vision.⁸⁸ It has also been claimed that cyclovertical incomitances such as A and V patterns and dysfunctions of the oblique muscles occur frequently in patients with refractive accommodative esotropia, present significant obstacles to fusion, and must be corrected by surgical desagittalization of the oblique muscles.⁹⁰ However, no data have been presented to substantiate these claims. On the contrary, several independent studies have established that functional deterioration of fully refractive accommodative esotropia occurs infrequently^{76, 210, 270} and that the diagnoses of dysfunctions of the oblique muscles and of A and V patterns in these patients are caused by inadequate diagnostic and measurement techniques.²¹⁰

Moreover, Schiavi and coworkers²⁵³ have shown that inferior oblique overaction is not a common sign of refractive accommodative esotropia. When present, it does not necessarily herald a negative prognosis for preservation of normal binocularity through glasses. Inferior oblique overaction can develop after loss of alignment in some but not all the decompensated patients. No evidence can be found for a cause-effect relationship between oblique muscle dysfunction and loss of binocularity in refractive accommodative esotropia.

In view of the foregoing we conclude, there-

fore, that the case for surgery in this condition has not been proved.^{90, 145, 210} We reject this therapeutic approach, which is contrary to physiologic principles and clinical experience and may be harmful, as shown by the following case.

CASE 16-3

A 25-year-old female schoolteacher consulted us with severe asthenopic complaints. She had worn glasses since early childhood to correct for an esotropia, which was well controlled with spectacles correction. She gave no history of having suffered visual discomfort in the past except when taking her glasses off, which caused her to see double and forced her to close one eye. She went to a “strabismus center” 6 months ago where she was offered surgery as an alternative to her glasses. The patient was not advised of the possible unfavorable consequences of such an operation and enthusiastically agreed to have the procedure done. After muscle surgery her eyes were aligned and she no longer saw double without glasses. However, soon afterward she developed severe visual discomfort consisting of headaches, tearing, and nausea after reading without glasses for longer than 10 minutes. Her old glasses relieved these symptoms, but she had to close one eye since she now saw double with her spectacles. Because of her visual difficulties, she was unable to continue teaching school, an occupation that she had enjoyed very much. Her cycloplegic refraction was +4.75 sph in each eye. She was orthotropic without glasses and developed 18^A exotropia at near and distance fixation with her glasses.

We predict that the woman in Case 16-3 is but one of numerous unhappy patients likely to populate the waiting rooms of ophthalmologists in the future if the practice of operating for esotropia that has already been fully corrected with glasses or contact lenses continues.

The use of excimer laser photokeratectomy and particularly LASIK (*laser-assisted in situ keratomileusis*) in the treatment of accommodative strabismus is being discussed with increasing frequency. At this stage of our knowledge and in view of the lack of long-term results with this and other keratorefractive procedures we are opposed to this treatment in the pediatric age group.

In the rare event of deterioration despite a satisfactory initial response to optical correction of the hypermetropia, a recession of both medial rectus muscles will restore fusion in most instances.

Nonrefractive Accommodative Esotropia (High AC/A Ratio)

Definition

Nonrefractive accommodative esotropia is defined as an esotropia greater at near than at distance fixation, unrelated to an uncorrected refractive error, and caused by an abnormally high AC/A ratio in the presence of a normal near point of accommodation.

Clinical Characteristics

Nonrefractive accommodative esotropia occurs in patients with emmetropia, hypermetropia, or myopia; however, moderate degrees of hypermetropia are encountered most frequently. The etiology is unrelated to the underlying refractive error but is closely linked with an *abnormal synkinesis between accommodation and accommodative convergence*—the effort to accommodate elicits an abnormally high accommodative convergence response. If motor fusion can cope with the increased convergence tonus at near fixation, an esophoria results. If motor fusion is insufficient, nonrefractive accommodative esotropia will become manifest. Unlike *hypoaccommodative esotropia*, discussed in the next section, the near point of accommodation is normal for the age of the patient.

Parks²²³ reported an abnormally high AC/A ratio in 46% of 897 children with comitant esotropia. The age of onset of accommodative esotropia in this series ranged from 8 months to 7 years, with an average of 30 months. However, Parks based the diagnosis of a high AC/A ratio on the heterophoria rather than on the gradient method. As pointed out earlier (see p. 91), the widely used and, in our opinion, inadequate heterophoria method to determine the AC/A ratio does not distinguish between a high AC/A ratio and nonaccommodative convergence excess. Thus, the patient group reported by Parks is not clearly defined. It is our clinical impression that most patients with nonrefractive accommodative esotropia present between the ages of 6 months and 3 years.

The *diagnosis* of nonrefractive accommodative esotropia is based on the presence of a significant esodeviation at near fixation on an accommodative fixation target (see Chapter 11) with the refractive error fully corrected and the presence of a high AC/A ratio as established with the *gradient*

method to distinguish this condition from *nonaccommodative convergence excess* (see below). The necessity of measuring the angle of deviation at near fixation with accommodation *fully* controlled in patients with all types of strabismus, especially in this group of patients, cannot be overemphasized. The reason is that children with accommodative esotropia may manage to keep their eyes aligned at near fixation by accommodating only partially or not at all (see Case 16–1). The use of a fixation target that requires full accommodation to identify small details will eliminate this frequent cause of diagnostic error.

Confusion may arise when diagnosing an esotropia with a high AC/A ratio and an esotropia with a V pattern (see Chapter 19) if the angle of strabismus is measured at distance fixation with the eyes in primary position and at near fixation with the gaze lowered. In esotropia with the V pattern, the deviation increases characteristically only in downward gaze regardless of whether the patient fixates at near or distance. With an accommodative esotropia, the deviation will increase at near fixation regardless of the position of the eyes in which the angle of strabismus is measured.

Therapy

Since the near deviation is the primary obstacle to normal binocular vision in patients with nonrefractive accommodative esotropia, the conditions for treatment with bifocal lenses are ideal. For details regarding this therapy see Chapter 24.

Attempts have been made to substitute *progressive lenses* for bifocal lenses. However, unless the patient looks maximally downward, the add in the lower portion of the lens is too low and accommodation is still being employed in downward gaze. Children may not be inclined to look maximally downward during visual activities at near and although cosmetically preferable, we feel that progressive lenses should not be prescribed for the treatment of accommodative esotropia.

Long-acting *anticholinesterase drops* have also been advocated but because of side effects are sive lenses for bifocal lenses. However, unless the The principles of bifocal therapy are discussed in Chapter 24. The majority of patients with nonredaction is still being employed in downward gaze. bifocals; however, we also have observed a slow deteriorating course of the disease.²¹⁷ In such instances and after a patient has initially regained fusion and stereopsis at near fixation with bifocal

correction, the near deviation may increase without obvious cause, becoming first intermittent and eventually manifest in the course of several years.

Cycloplegic refraction performed at that point must exclude the possibility of an increase of the hypermetropic refractive error. In that case, stronger lenses should be prescribed. If this does not correct the deviation, then such patients respond well to a recession or posterior fixation of both medial rectus muscles or a combination of both.^{176, 234, 272, 275} The amount of surgery should be based on the near deviation without fear of causing an overcorrection at distance fixation. Most studies of the results achieved with either of these procedures do not distinguish between accommodative and nonaccommodative convergence excess (see below), making it somewhat difficult to evaluate such reports. We have been satisfied with the results of recession of both medial rectus muscles and no longer use retroequatorial myopexy for this condition.

Hypoaccommodative Esotropia

Definition

Hypoaccommodative esotropia is defined as an esotropia greater at near than at distance fixation, unrelated to an uncorrected hypermetropic refractive error and caused by excessive convergence from an increased accommodative effort to overcome a primary or secondary weakness of accommodation.

Clinical Characteristics

Costenbader⁵² drew attention to this special form of esotropia for which he suggested the descriptive term *hypoaccommodative*. This form is characterized by a small refractive error, a remote near point of accommodation, a small deviation at distance fixation, but a large esotropia at near fixation. He stated that routine testing of the near point of accommodation in strabismic patients revealed a surprisingly large number in whom the near point was recessed farther than one would expect from the patient's age. According to Costenbader, such patients must exert an excessive accommodative effort to clear their vision at near and, in so doing, exhibit excessive and undesirable convergence. Clearly, this form of esotropia is accommodative, even though its mechanism differs from that discussed above in connection with

refractive accommodative and nonrefractive accommodative esotropia.

Mühlendyck^{192, 193} confirmed Costenbader's concept of hypoaccommodative esotropia and reported patients with reduced accommodative range, an esotropia at near fixation, asthenopia after prolonged periods of reading, and temporary blurring of vision after switching from near to distance vision. Mühlendyck pointed out that this condition may be one of the causes of reading difficulties in schoolchildren and recommended plus lenses for near vision. According to Mühlendyck, the prevalence of hypoaccommodative esotropia was 3.7% in 3929 patients with strabismus. With the exception of Mühlendyck's work, hypoaccommodative esotropia has received no attention since Costenbader's original description.

For many years we were skeptical of the existence of this entity until we became aware that children with an accommodative esotropia who had been treated with bifocals for a long time may have an abnormally low near point of accommodation.²⁰⁸ It may be argued that this accommodative weakness may have been caused by prolonged bifocal wear but, alerted by this finding, we since have identified children with an esotropia at near fixation who had a reduced near point of accommodation prior to bifocal therapy. Moreover, Mühlendyck and Goerdts¹⁹⁴ reported the near point of accommodation unchanged in children with hypoaccommodation after bifocal wear of 6 years or longer. On the basis of these observations we believe that Costenbader's original concept needs to be reinvestigated because it may well deserve its proper place in a classification of esodeviations. The findings that not all children with a remote near point of accommodation become esotropic at near, that a reduced near point of accommodation may actually be associated with convergence insufficiency and exophoria,^{214, 215} and that the increased accommodative effort associated with beginning presbyopia rarely produces a manifest esodeviation do not necessarily present arguments against the validity of Costenbader's theory.

Partially Accommodative Esotropia

Definition

An esotropia is partially accommodative when accommodative factors contribute to but do not account for the entire deviation.

Clinical Characteristics

Esodeviations of refractive or nonrefractive accommodative etiology do not always occur in their “pure” forms. A residual esotropia may exist despite full correction of a hypermetropic refractive error or prescription of bifocal lenses or miotics or both. As a matter of fact, the majority of patients with esotropia have a mixed type that is partially accommodative and partially nonaccommodative. This is especially so in essential infantile esotropia.^{123, 242}

Few comments are necessary concerning this form of esotropia, but two points should be made. First, at times in a child with essential infantile esotropia an accommodative element becomes superimposed on the deviation as the child grows older, often accompanied by a larger hypermetropia than was first measured. Indeed, it may be the rule that the nonaccommodative element occurred early in infancy or was connatal, whereas the accommodative component is a later acquisition. Second, the presence of a nonaccommodative element should always raise the question that the basic refractive error is not fully corrected; cycloplegic refraction should be done to rule out this possibility.

Thus it appears that the nonaccommodative element in accommodative esotropia resists etiologic classification. In most instances the deviation is probably congenital with an accommodative element becoming superimposed as the child grows older, but in other cases a nonaccommodative element develops after initial alignment of the eyes with glasses or bifocal lenses. With our present knowledge, we can only postulate that increased convergence tonus or mechanical factors such as secondary contractures of the medial rectus muscles, conjunctiva, or Tenon’s capsule may play a role.

Therapy

Amblyopia must be eliminated by appropriate therapy (see Chapter 24), and a full hypermetropic correction should be prescribed. Bifocals or miotics, or a combination of both, are useless since the deviation is only reduced but not eradicated. If it is warranted by the size of the nonaccommodative angle of strabismus, which must be determined while the patient is wearing full correction, surgery should be performed to align the eyes. Conservatism is indicated in hypermetropes of

+4.00D sph or more (see p. 324). We want to reemphasize that only the nonaccommodative component of the strabismus should be corrected surgically. Special care must be taken to explain this in great detail to parents, who otherwise may expect that glasses will not be required after the operation.

Nonaccommodative Esotropia

Essential Infantile Esotropia

Definition

We define *infantile esotropia* as a manifest esodeviation with an onset between birth and 6 months of age, and following the suggestion of the Hugoniers^{134, p.208} add the modifier *essential* to emphasize the obscure etiology of this condition and to distinguish it from other forms of esodeviation with an onset at about that time.²⁰³ Because infantile esotropia is commonly accompanied by a set of other clinical findings (Table 16–2) it is justified to speak of the essential infantile esotropia syndrome.¹⁶⁷

Terminology, Prevalence, Etiology

We prefer the term *essential infantile esotropia* over the older term *congenital esotropia* but have no objection to using both terms interchangeably.

TABLE 16–2. Clinical Characteristics of Essential Infantile Esotropia

Consistent Findings

- Onset from birth–6 mo
- Large angle ($\geq 30^\circ$)
- Stable angle which may increase with time
- Initial alternation with crossed fixation
- Occasionally also very early fixation preference
- No clinically apparent CNS involvement
- Asymmetrical optokinetic nystagmus

Variable Findings

- Amblyopia
- Apparently defective abduction
- Apparently excessive adduction
- Up- or downshoot on adduction
- A or V pattern
- DVD/DHD
- Manifest-latent nystagmus
- Manifest nystagmus (rare)
- Anomalous head posture
- Heredity

CNS, central nervous system; DVD, dissociated horizontal deviation; DHD, dissociated horizontal deviation.

The reason for this preference, which has not gone unchallenged,^{172, 231} is the following. *Congenital* is defined as “existing at or dating from birth.”²⁹⁶ The fact is that esotropia is rarely present at birth even though many parents may insist that this was the case. Comprehensive and independent studies of a total of 2200 newborns have shown that exotropia and, to a much lesser degree, esotropia occur commonly in the neonatal period but are, as a rule, transient and disappear by the age of 3 months.^{98, 197, 265, 290} Children who eventually develop the essential infantile esotropia syndrome may actually have been exotropic or orthotropic at birth.¹⁹⁷ A congenital onset according to the definition, if it occurs at all, must be exceedingly rare. It is of historical interest that the English surgeon Edward W. Duffin commented as early as 1840 that he had “not met with a single case of congenital strabismus, though in many instances the deformity has been reported to have supervened a few days after birth. Even children of parents who are affected with strabismus and in whom we might conclude it would be hereditary, do not exhibit any appearance of the deformity for months or perhaps years after birth.”⁸²

This should not distract from the probability that hereditary factors play a role in the etiology of this disorder. However, a hereditary component does not make a condition “congenital.” Esotropia with an onset after 6 months of age is referred to as *early acquired esotropia*.

The *prevalence* of essential infantile esotropia was once estimated to be 1% of the population.^{97, 104} However, the recent comprehensive longitudinal studies of Helveston and his coworkers have established this number to be closer to 0.1%.¹⁹⁷ Even with this reduced prevalence, essential infantile esotropia is the most common form of strabismus.

The *etiology* of essential infantile esotropia is unknown, and the various theories have been discussed in Chapter 9. We favor a hypothesis according to which various strabismogenic forces impinge on a sensorially normal but immature and therefore functionally imperfect visual system. A normally functioning vergence mechanism is capable of overcoming these forces; delayed development or a defect of the vergence system is not capable of overcoming these forces and esotropia ensues.²⁰⁶ This view is shared by other authors.^{114, 118, 285} This hypothesis is summarized in Figure 16–2. It must be emphasized, however, that this is merely a working hypothesis that may have to be

modified or even abandoned as new information becomes available. Several reports,^{24, 85, 303} according to which normal binocular vision with random-dot stereopsis may occasionally be restored by early surgical alignment (even in some patients who do not undergo operation⁸⁵), support our assumption that there is no underlying congenital sensory defect preventing a functional cure in these patients.

Differential Diagnosis

Essential infantile esotropia is not the only form of esodeviation with an onset during the first 6 months of life. There are other conditions, some truly congenital, that is, present at birth, and others acquired during the first few months of life, like essential infantile esotropia. Among the congenital defects are bilateral abducens paralysis (Chapter 20), Duane syndrome type I, and Möbius syndrome (Chapter 21). Conditions acquired during the first few months of life may be sensory esotropia (see p. 345), refractive accommodative esotropia (see p. 314), the nystagmus compensation (blockage) syndrome (Chapter 23), or esotropia in association with other central nervous system manifestations, such as Down syndrome, albinism, cerebral palsy, mental retardation, and so on. The latter group deserves to be separated from essential infantile esotropia in otherwise normal children because the surgical outcome, in our experience and that of others, is less predictable.²³⁶

Clinical Characteristics

Some disagreement exists among current authors as to the significance of the clinical characteristics and their prevalence in patients with essential infantile esotropia. These variations can sometimes be explained by differences in examination techniques or by geographic differences. Table 16–2 lists what we consider to be the most typical characteristics of this condition, some of which are more or less consistent; others are variable. Ciancia⁴² described a group of patients with essential infantile esotropia, latent nystagmus, a head turn toward the adducting eye, and apparently limited abduction in both eyes. This has been referred to as the *Ciancia syndrome*. Lang¹⁶⁵ emphasized the frequent association between early-onset esotropia, dissociated vertical deviation, exocycloduction of the nonfixating eye, and abnormal

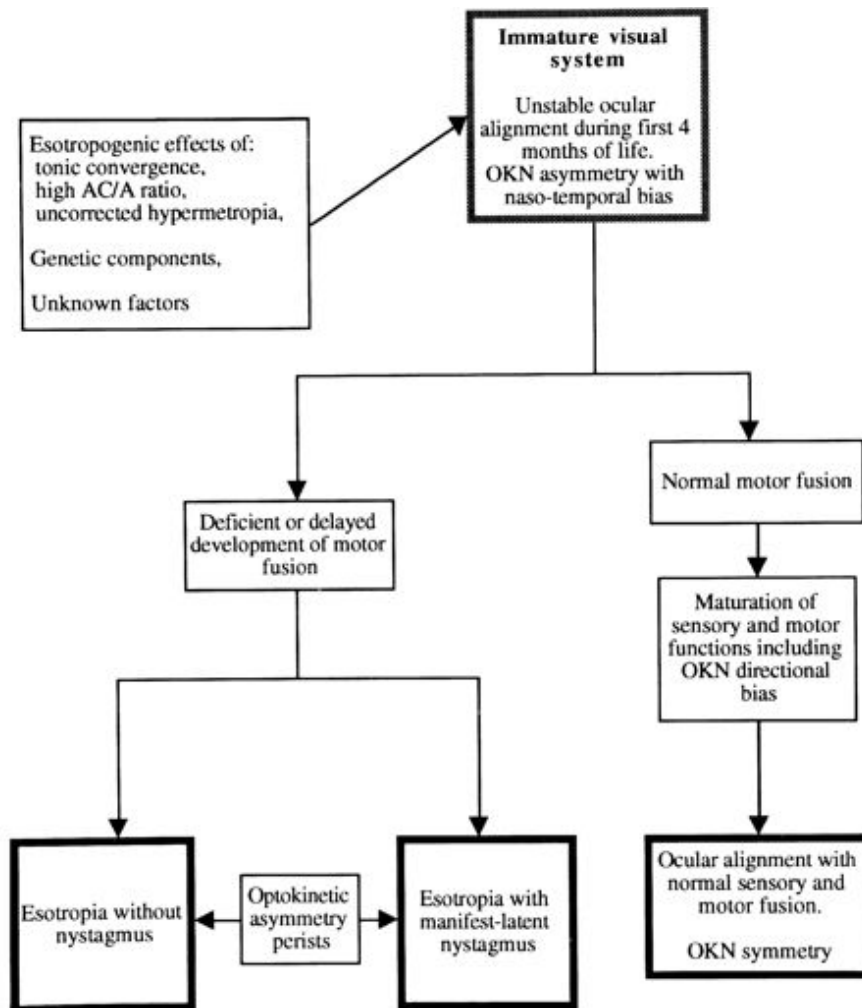

FIGURE 16-2. Hypothesis of the pathogenesis of essential infantile esotropia. OKN, optokinetic nystagmus. (Modified from von Noorden GK von, Helveston EM: *Strabismus: A Decision Making Approach*. St Louis, Mosby-Year Book, 1994, p 95.)

head posture. In the European literature essential infantile esotropia is therefore frequently referred to as *Lang syndrome*. Both of these contributions are important because they focused attention on previously neglected aspects of essential infantile esotropia. It is questionable, however, whether these syndromes represent separate entities and we believe that they emphasize some of the more variable features of the infantile esotropia syndrome (see also Helveston¹¹⁸).

AGE AT ONSET. The age of a child at the onset of esotropia must be established by history during clinical examination since children rarely are brought to an ophthalmologist before 6 months of age. In evaluating the validity of the history given by the parents, one should remember that mothers often tend to overlook strabismus in their child because they do not want to believe their baby has a defect. It is characteristic for the mother to

report that relatives, often the mother-in-law(!), or friends first remarked on the ocular deviation, although she herself had not noticed it. In other cases the onset actually may have occurred later in life than the history given by the parents indicates.

Costenbader⁵⁴ noted the high prevalence of pseudostrabismus in a group of children with a primary diagnosis of strabismus (352 of 753 patients) and postulated that children at first may have pseudostrabismus that subsequently develops into an esotropia. In such cases, the history given by the parents indicates that the onset of esotropia was at birth rather than at a later date. In this group the prognosis for normalization of binocular functions may be significantly better than in patients with a true congenital esotropia since the former group of patients had an opportunity to acquire binocular single vision before the deviation occurred. If the reliability of the history obtained from the parents is doubtful, photographs

of the patient are useful in determining whether strabismus was present at an earlier age than indicated by the parents. Careful investigation for other frequently associated features of essential infantile esotropia in most instances will allow one to arrive at the correct diagnosis, even in patients whose histories are doubtful or in whom a history cannot be obtained, such as adopted children.

SIZE OF DEVIATION. Unlike esotropia of later onset, essential infantile esotropia is usually characterized by a large deviation of 30^Δ or more.^{54, 57, 205} Deviations of less than 30^Δ also occur but are less common. The angle of deviation is usually quite stable if stability of the angle is defined as insignificant changes in its size in the course of the examination and on subsequent reexaminations. Exceptions do occur, especially in patients with smaller angles of deviation in whom spontaneous resolution of esotropia may occur²⁵ and in those with the nystagmus blockage syndrome in whom the angle is quite variable (see Chapter 23). The concept of a stable angle in patients with essential infantile esotropia is not shared by all ophthalmologists.^{69, 123, 165} Clark and Noel⁴⁶ and Hiles and coworkers¹²³ described cases of large angle essential infantile esotropia with spontaneous regression of the angle over 3 years. Such events are rare, however, and Birch and coworkers²⁵ reported stability of the angle in 66 children with essential infantile esotropia of 40^Δ or more who were fol-

lowed from infancy until the age of $4\frac{1}{2}$ years or older.

As a rule, there is no significant difference in the angle at near and distance fixation, which indicates a normal AC/A ratio. The widely held concept that essential infantile esotropia is essentially nonaccommodative has been challenged by some authors.^{50, 244, 245} The ophthalmologist must be aware that an accommodative component may occasionally be superimposed upon the basic condition and require optical correction in case of an uncorrected hypermetropia or bifocals in case of a high AC/A ratio.

REFRACTIVE ERRORS. Costenbader,⁵⁴ in a survey of 500 children with essential infantile esotropia, described the distribution of refractive errors: 5.6% myopes, 46.4% mild hyperopes (emmetropia to +2.00D sph), 41.8% moderate hyperopes (+2.25D to +5.00D sph), and 6.4% high hypermetropes (+5.25D sph, and more). It is of interest in this series of patients that the size of the deviation was unrelated to the size and type of refractive error. We have analyzed the refractive errors in 408 patients with the diagnosis of essential infantile esotropia who were treated at our clinic and found a distribution similar to that reported by Costenbader (Fig. 16-3).

The amount of hypermetropia present at the first examination may depend, of course, on the age at which the child is first seen, since numerous studies have shown that at 1 to 2 years of age

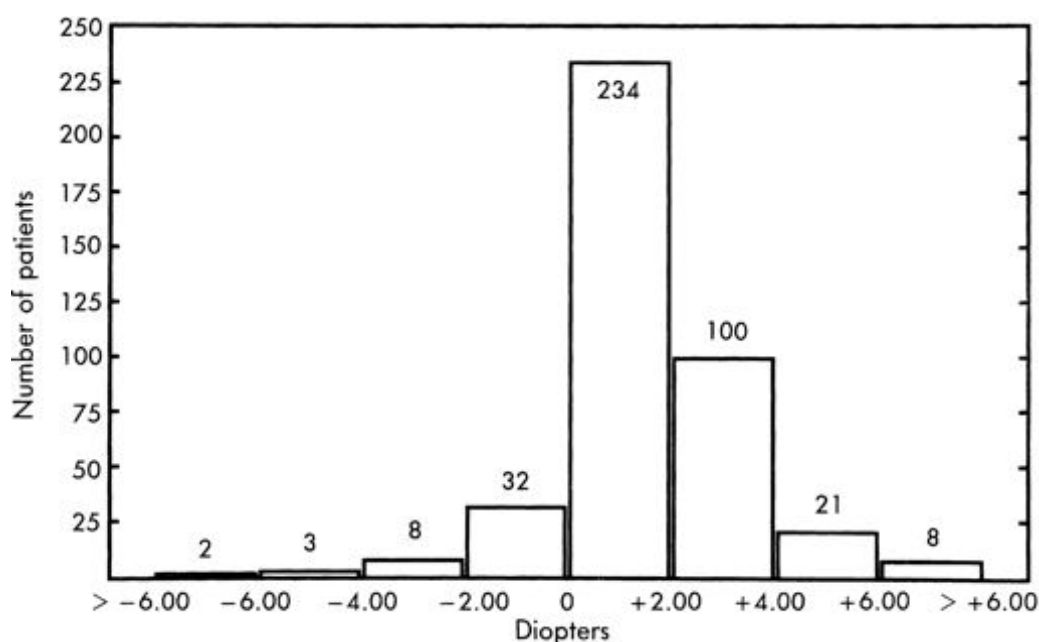


FIGURE 16-3. Distribution of refractive errors (spherical equivalent) in 408 patients with essential infantile esotropia.

both emmetropia and hypermetropia up to 3D can be considered as being within normal limits (see Molnar¹⁹⁰ and many others; see also Chapter 7). The generally held view that this “physiologic” hypermetropia diminishes as the child grows older was challenged by Brown and Kronfeld.³¹ These authors monitored the refractive error in a group of children during the first 5 years of life and found either an increase of hypermetropia or no change. In a later study, Brown³⁰ reported an increase of hypermetropia until the end of the seventh year.

Burian³⁴ emphasized that in high hypermetropes (+ 4.00D sph or more) the esodeviation has a tendency to decrease with passage of time. In fact, 10% to 20% of these patients will eventually develop an exotropia. This observation justifies conservatism with respect to early surgical treatment in such patients (see also (Clark and Noel,⁴⁶ Moore,¹⁹¹ and Stangler-Zuschrott²⁷⁴).

DUCTIONS AND VERSIONS. Most children with essential infantile esotropia exhibit apparent defective abduction or excessive adduction or both. This is often mistaken for bilateral paresis or paralysis of the lateral rectus muscles. If amblyopia is present, the defective abduction often is more prominent in the amblyopic eye. If abduction is apparently restricted, one cannot be sure whether the child is *unwilling* or *unable* to abduct fully. Examination of ocular rotations in extreme positions of gaze is not easy in young infants. Even older children and some adults may find it difficult to move the eyes into extreme positions of levoversion or dextroversion. One reason why it may be difficult to get children with essential infantile esotropia to abduct fully when the fellow eye is converged is manifest-latent nystagmus. Such patients habitually fixate with one eye in adduction, a position in which the nystagmus is least pronounced or even absent and visual acuity is at its best.

In our experience a true abducens paresis is very rare in early infancy. The vast majority of patients with infantile esotropia and apparently limited abduction are either unwilling to abduct fully or are unable to do so because of secondary contracture of the medial rectus muscle(s), conjunctive, or both. In the former condition the *doll's head maneuver* or a few hours of occlusion of either eye will readily differentiate a true from a pseudoparesis of the lateral rectus muscle(s). In the latter, a forced duction test may become neces-

sary to diagnose contracture. Recession of the tight medial rectus muscles in such patients will normalize the action of the seemingly deficient lateral rectus muscle.

The role of the *nystagmus blockage syndrome* in simulating an abducens paralysis is discussed in Chapter 23.

AMBLYOPIA. Amblyopia is a commonly associated factor in essential infantile esotropia. It was found in 35% of 408 patients with essential infantile esotropia treated in our clinic.²⁰⁵ Costenbader⁵⁴ reported a prevalence of 41% in his series of 500 cases and Shauly and coworkers²⁵⁹ diagnosed amblyopia in 48% of their 103 patients. It is generally agreed that amblyopia, unless treated and cured early in life, is a severe obstacle to the return of normal binocular functions. Curiously, the prevalence of amblyopia in patients with essential infantile esotropia not operated on is much lower (14% to 19%).^{36, 97} The reason for this difference is not clear. However it is unlikely that a large angle esotropia protects a patient from amblyopia, as proposed by Good and coworkers,¹⁰² since there is no apparent relationship between amblyopia and the size of the deviation.²¹¹

ASSOCIATED VERTICAL DEVIATIONS. To distinguish clearly between an elevation in adduction caused by an *overacting inferior oblique* and a *dissociated vertical deviation* may be difficult in infants. We suspect that many patients with essential infantile esotropia in whom a diagnosis of inferior oblique overaction was made in the past actually had a dissociated vertical deviation. The differential diagnosis between these conditions is discussed in Chapter 18. Attention has also been drawn to the fact that an apparent over- or underaction of an oblique muscle may be simulated by atopic muscle pulleys⁴⁵ or by cyclotropia (see Chapter 18). It is for these and other reasons (see Chapter 18) that in recent years we have discouraged the indiscriminate use of the diagnostic label *inferior* or *superior oblique overaction* in patients with elevation or depression of the adducting eye and prefer the generic terms of *elevation* or “upshoot” *in adduction* and *depression* or “downshoot” *in adduction* instead.

Elevation or depression in adduction, often associated with a V or A pattern, and dissociated vertical or horizontal deviations are common components of the essential infantile esotropia syndrome. We found elevation in adduction in 68% of 408 cases.²⁰⁵ The point is often made that up-

and downshoot in adduction and dissociated deviations are infrequently found in children with essential infantile esotropia who are under 1 year of age,^{122; 229 p.107} and do not emerge until the horizontal deviation has been surgically corrected. This has certainly also been our impression. However, it must also be considered that because of the difficulties encountered in performing a complete motility analysis in infants these conditions are already present before surgical correction of the esotropia but are not diagnosed because of the masking effect of a large horizontal deviation. Campos³⁸ observed that dissociated vertical deviations present before surgery may actually resolve after early horizontal alignment with chemodeneration.

The age at surgical correction of the esotropia is unrelated to the occurrence of dissociated vertical deviations.¹²² In fact, this condition occurred also in 60% of 113 patients with essential infantile esotropia who remained untreated until visual adulthood.³⁶

The prevalence of dissociated vertical deviation, which often has a horizontal component (see Chapter 18), in patients with essential infantile esotropia is high. We have diagnosed this condition in 51% of 408 patients with essential infantile esotropia.²⁰⁵ Other authors have reported an even higher prevalence, for example, Lang (90%),¹⁶⁵ Parks (76%),²²⁷ Helveston (70% to 90%),¹¹⁶ and Calcutt and Murray (60%).³⁶ A possible reason for these differences in the reported prevalence of dissociated vertical deviations is that some authors restrict the diagnosis to the presence of a manifest dissociated deviation whereas others include cases with a latent dissociated deviation, which can only be elicited by covering one eye.

Parks²²⁹ believes that a dissociated vertical deviation is indirect evidence for the onset of esotropia at the time of birth. We do not agree with this view since a dissociated vertical deviation is an entity *sui generis*. Although it occurs commonly in association with essential infantile esotropia, this form of deviation also may accompany acquired esotropia or exotropia (see Chapter 18). Even patients in whom no other form of strabismus is present may have this type of anomaly. Evidence is lacking to support the belief that the presence of this anomaly is proof of the congenital nature of an associated horizontal strabismus.

Lang¹⁶⁵ commented on the common occurrence (65%) of excyclotropia of the nonfixating eye in his patients with infantile strabismus. Rather than

considering excyclotropia of the nonfixating eye as an isolated associated anomaly in the essential infantile esotropia syndrome, we prefer to regard it as a component of the dissociated vertical deviation syndrome (see Chapter 18).

NYSTAGMUS. The clinical characteristics of the various congenital nystagmus forms, including the differentiation between manifest-latent and manifest nystagmus, are discussed in Chapter 23. We will consider nystagmus in this section only as it pertains to essential infantile esotropia.

LATENT OR MANIFEST-LATENT NYSTAGMUS. These types of congenital nystagmus occur commonly in essential infantile esotropia and must be distinguished from manifest congenital nystagmus, a less commonly associated oculomotor anomaly. Latent nystagmus is characterized by a nasally directed drift of the nonfixating eye, followed by a fast corrective saccade in the temporal direction. Upon changing fixation to the fellow eye the direction of the nystagmus reverses. True latent nystagmus that is present only with one eye occluded is rare and in most patients a manifest nystagmus, albeit of lesser amplitude, is present with both eyes open; hence the somewhat awkward term *manifest-latent nystagmus*.

We have suggested²⁰⁶ that infantile esotropia, when associated with manifest-latent nystagmus, may well represent a special subgroup within the essential infantile esotropia syndrome. In this connection a recent study is of interest according to which nystagmus when associated with infantile esotropia may increase the risk of requiring additional operations for overcorrection of residual deviation.²⁷¹

Since differentiation between manifest-latent and manifest nystagmus is often not possible on clinical grounds alone and reliable electronystagmographic recordings are difficult to obtain in small children, both conditions are easily confused. This may explain the large differences in the prevalence of latent nystagmus reported by different authors. For instance, Ciancia⁴² observed latent nystagmus that increased in abduction and decreased in adduction in 33% of patients with essential infantile esotropia, whereas Lang¹⁶⁵ made this diagnosis in 43 (52%) of 82 patients. Electronystagmographic studies in a small number of patients have even indicated a prevalence of 95%. We have diagnosed nystagmus without the benefit of nystagmographic recordings in only 25% of 408 patients with essential infantile esotropia and

were able to recognize the latent variety in only 10%.²⁰⁵ As pointed out by Ciancia,⁴² many of these patients have an abnormal head posture and turn their face in the direction of the fixating eye. The nystagmus is less pronounced or even absent in adduction, and improvement of visual acuity in this position explains the anomalous head posture (see Chapter 23). Spielmann and Spielmann²⁶⁹ emphasized that this condition is not to be confused with the blocking of manifest congenital nystagmus by convergence.

Earlier studies had led some investigators to propose that a disturbance of coordination between vestibular and optic control of the oculomotor system may be of etiologic significance in causing latent nystagmus and dissociated vertical deviation.^{80, 81, 165} Doden and Adams⁸¹ described involuntary rhythmic, conjugate, pendular deviations of the eyes on vestibular testing in 23% of 150 strabismic subjects. They interpreted these anomalies as expressions of a central disturbance of coordination, possibly caused by lesions of the brain stem involving the vestibular nuclei and the substantia reticularis. Hoyt¹³¹ reported abnormalities of the vestibulo-ocular response in infantile esotropes without nystagmus. For more recent views of a causal relationship between manifest-latent nystagmus and optokinetic asymmetry (Kommerell¹⁵⁵) and a hypothesis linking latent nystagmus etiologically with infantile esotropia (Lang¹⁷⁰), see Chapter 9.

MANIFEST NYSTAGMUS. Most authors report that manifest nystagmus occurs less commonly with essential infantile esotropia than do latent and manifest-latent nystagmus.^{78, 205, 218} However, it is commonly encountered when essential infantile esotropia is associated with other conditions, such as Down syndrome, ocular albinism, cerebral palsy, and hydrocephalus. Under certain conditions patients learn to dampen the nystagmus by convergence, and this sustained convergence may cause a secondary esotropia (nystagmus blocking syndrome), which is discussed in Chapter 23. In this context it must be underscored that only the mechanism of this esotropia is distinctly different from essentially essential infantile esotropia. Other patients may dampen the nystagmus in a lateral gaze position.

ASYMMETRICAL OPTOKINETIC NYSTAGMUS. A common association between optokinetic asymmetry and essential infantile esotropia has been established.^{28, 79, 92, 154, 186, 289, 290} In normal subjects the optokinetic response elicited by a

rotating nystagmus drum (Fig. 16–4) consists of a smooth pursuit movement in the direction of the moving stripes or pictures, followed by a corrective saccade in the opposite direction. This pursuit movement occurs with equal facility, regardless of whether the stripes move from a nasal to a temporal or from a temporal to a nasal direction.

However, in many esotropic patients this symmetry is grossly disturbed (Fig. 16–5) and pursuit movements are irregular or are difficult to elicit when the drum moves in a nasotemporal direction (optokinetic asymmetry). This phenomenon has been interpreted as a defect in visual motion processing: the visual cortex fails to acquire the ability to transmit temporally directed object motion to the nucleus of the optic tract (NOT), although not affecting object motion from the retina to the cortex.^{124, 154} However, this asymmetry is not a pathognomonic feature of essential infantile esotropia but occurs also in normal, visually immature infants,^{9, 125} in nonstrabismic patients with deficient binocular input because of anisometropia, and in various other forms of monocular visual deprivation early in life,^{105, 125, 178} after enucleation,²⁴⁶ and in the Duane type I syndrome.¹⁰⁵ Its presence is merely evidence for disruption of binocular vision during visual immaturity before the age of 3 to 4 months, regardless of its cause. Normal and equal binocular visual input is required during infancy for maturation of the optokinetic reflex and the state of immaturity (asymmetry) persists in the absence of such input. Thus, *optokinetic asymmetry must be considered a con-*

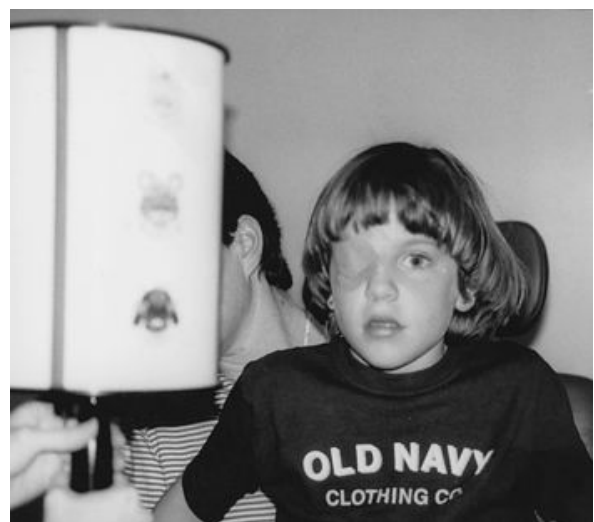

FIGURE 16–4. Use of a pediatric nystagmus drum to elicit optokinetic nystagmus in children. (Courtesy of Dr. D. Coats, Houston, Texas.)

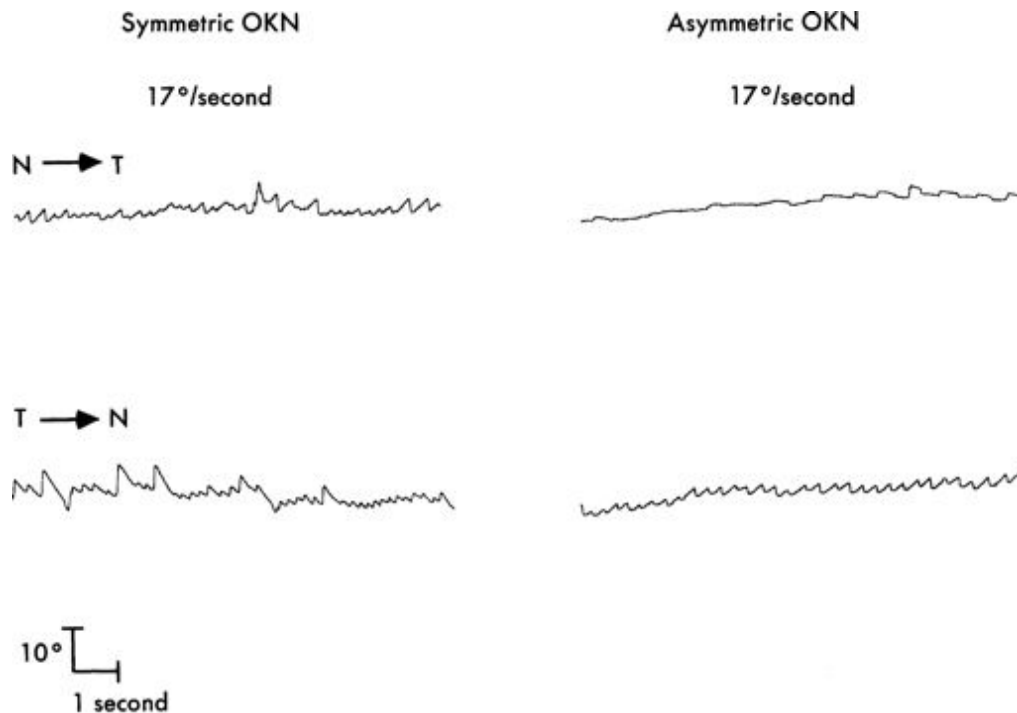


FIGURE 16-5. Binocular nystagmogram during optokinetic stimulation from nasal to temporal (*upper tracings*) and temporal to nasal (*lower tracings*) in a normal subject (*left*) and a patient with essential infantile esotropia (*right*). Note poor optokinetic response when the drum is moved in a nasotemporal direction in the esotropic patient. (From Noorden GK von: Current concepts of essential infantile esotropia (Bowman Lecture). Eye 2:343, 1988.)

sequence of essential infantile esotropia rather than, as has been suggested,^{288, 289} the manifestation of a primary motion-processing defect in the visual pathway. In support of a primary motion-processing defect in these patients it has been reported that their nonstrabismic first-degree relatives demonstrate significant motion-processing asymmetries. However, this finding could not be confirmed in a study performed by us.⁸⁸

Westfall and coworkers²⁹⁸ confirmed the existence of asymmetrical optokinetic nystagmus in patients with essential infantile esotropia. In some of these patients sensory fusion could be detected by means of dynamic random-dots visual evoked response (VER). These authors argued therefore that optokinetic asymmetry is not associated with a deficit in the cortical fusion facility, but rather with deficits in binocular pathways projecting to monocular optokinetic nystagmus centers. These deficits may be associated with abnormal processing subsequent to sensory fusion or with abnormal processing in motion pathways, which run parallel to sensory fusion pathways.

Optokinetic asymmetry is, with certain limitations, a useful clinical sign to date the onset of strabismus since it occurs more commonly in children with an onset before the age of 6 months

than in those with a later onset^{28, 79, 289, 290} (Fig. 16-6). Care must be taken, however, in interpreting optokinetic responses obtained with a nystagmus drum in children since the asymmetry may be subtle and not recognizable unless nystagmography can be performed.

As mentioned in Chapter 9 the common association between *optokinetic asymmetry* and *latent nystagmus* in essential infantile esotropia has led to speculations regarding a causal relationship.¹⁵³⁻¹⁵⁶ The reportedly high correlation between the severity of pursuit asymmetry and the intensity of latent nystagmus²⁹⁰ seems to be in accord with this hypothesis. In further support of it we would also expect an *invariable* linkage between optokinetic asymmetry and latent nystagmus. However, latent nystagmus is not consistently associated with asymmetry of the optokinetic response⁷⁹ or with motion detection deficits.²⁵⁷

MOTION-PROCESSING DEFICITS. The nasotemporal motion defect is not limited to the pursuit system and a similar response bias exists for *motion processing*, as shown by monocularly recorded VEPs (visual evoked potentials).^{219, 220} As with optokinetic asymmetry this bias is a normal feature in infants but persists into adulthood in

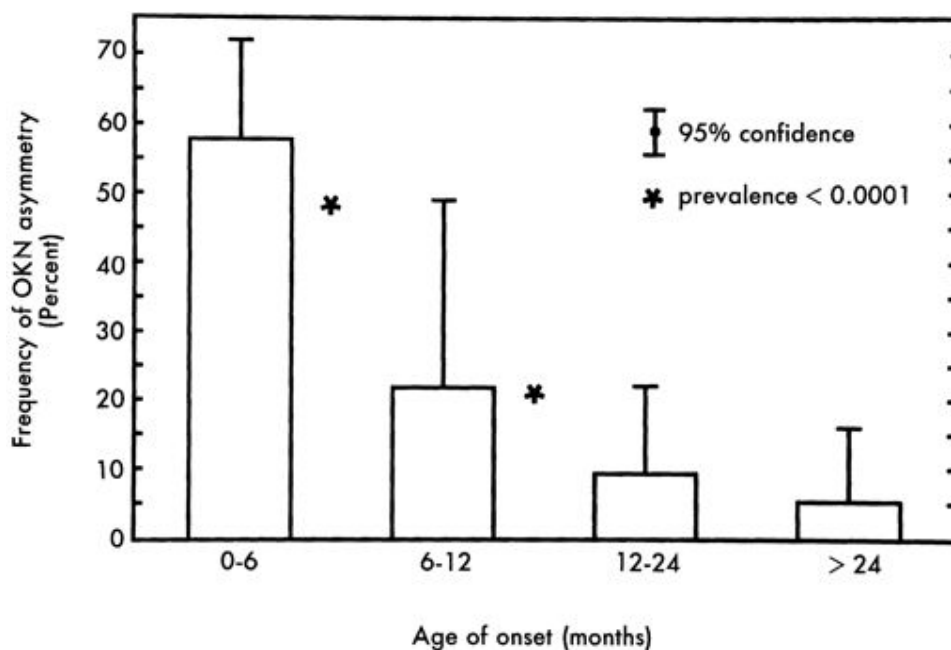


FIGURE 16-6. Histogram showing the prevalence of clinical monocular optokinetic nystagmus (OKN) asymmetry in esotropic patients with various ages of onset of strabismus. The asterisks indicate statistically significant differences in prevalence between adjacent columns, and the error bars indicate 95% confidence intervals for mean prevalence. There was a significantly greater prevalence of asymmetry in esotropic patients with onset before the age of 6 months than in those with onset between 6 and 12 months, and these, in turn, had a significantly greater prevalence than those with later onset. (From Demer JL, Noorden GK von: Optokinetic asymmetry in esotropia. *J Pediatr Ophthalmol Strabismus* 25:286, 1988.)

infantile esotropia. The results of studies on motion perception (reviewed by Fawcett and coworkers⁸⁹) are contradictory with regard to the presence of a deficit and the direction of monocular asymmetries in infantile esotropia. Kommerell and coworkers¹⁵⁷ questioned whether optokinetic asymmetry and motion asymmetries are caused by the same central defect as they found no significant correlation between these disturbances. Fawcett and coworkers⁸⁹ compared motion perception in stereoblind infantile esotropes and patients with acquired esotropia and normal stereopsis and found similar anomalies in both groups. These authors concluded that interruption of binocularity cannot be the underlying cause of abnormal motion processing in essential infantile esotropia.

ANOMALOUS HEAD POSTURE. Lang¹⁶⁵ reported an anomalous head posture in 57 (70%) of 82 patients with essential infantile esotropia, and others have commented on the high rate of occurrence of this association.⁴² The head and face are said to be tilted toward the shoulder of the fixating eye.¹⁶⁷ We cannot confirm this high rate of occurrence, which we have observed in only 6% of 408 patients with essential infantile esotropia.²⁰⁵ De Decker and Dannheim-de Decker⁷³ observed a

conspicuous anomalous head posture in only 2% of their patients and noted a head tilt toward the side of the fixating eye in most instances. However, patients with a head tilt toward the side of the nondominant eye often had a dissociated vertical deviation with strong unilateral preponderance. In some patients the anomalous head posture is associated with latent or manifest-latent nystagmus and the patient turns the head toward the side of the fixating eye (Ciancia syndrome). However, as pointed out by de Decker⁷¹ and in our experience as well, this correlation is by no means consistent.

Crone⁶¹ has stated that the torticollis compensates for an incyclotropia of the fixating eye, a view shared by other authors.^{4, 266} However, an incycloduction of the fixating eye is not a consistent feature of dissociated vertical deviations and one also wonders why a head tilt is not more common considering that dissociated vertical deviations occur at least in one half of all patients with essential infantile esotropia.²⁰⁵

The prevalence of various components of the essential infantile esotropia syndrome encountered in our patient population is summarized in Table 16-3.

TABLE 16-3. Prevalence of Characteristics of Essential Infantile Esotropia* (*N* = 408)

Characteristic	<i>n</i>	Percent
Amblyopia	144	35
Anomalous head posture	26	6
Dissociated vertical deviation (DVD)	208	51
Overaction of inferior obliques (OAIO)	277	68
DVD and OAIO (combined)	171	42
Manifest nystagmus	62	15
Manifest-latent nystagmus	41	10

*Mean deviation at distance, 44 Δ (range, 5 Δ –100 Δ); mean deviation at near, 49 Δ (range, 10 Δ –95 Δ).

From Noorden GK von: A reassessment of essential infantile esotropia (XLIV) Edward Jackson Memorial Lecture. *Am J Ophthalmol* 105:1, 1988.

Therapy

It is a tragic fallacy for parents of strabismic children to be told by their family physician that the problem will need no medical attention until the child reaches preschool age or that in time the eyes will straighten out spontaneously. The truth is that strabismus neglected in early childhood may cause severe, irreversible sensory anomalies and that secondary changes in the extraocular muscles, conjunctiva, and Tenon's capsule that develop as a result of long-standing strabismus will make the results of surgical correction at a later age less predictable. It also behooves the primary care physician to remember that strabismus may develop secondary to reduced visual acuity and may well be the second most common sign of retinoblastoma.⁸⁶

We insist therefore that every child whose eyes are not aligned by 3 months of age be given a complete ophthalmologic examination. Although treatment may not be possible or even necessary on the first visit, a baseline of clinical information can be established that will be helpful in the future management of the patient.

The treatment of choice for essential infantile esotropia is surgical alignment of the eyes. Nonsurgical treatment is directed toward correction of a significant refractive error, elimination of amblyopia during the preoperative phase, and treatment of a residual angle of esotropia during the postoperative period.

GOALS OF TREATMENT. A *cure of strabismus* may be defined as a restoration of single binocular vision in the practical field of gaze, that is, orthotropia or asymptomatic heterophoria; normal visual acuity in each eye; normal stereoacuity on

random-dot testing; normal retinal correspondence; and stable sensory (bifoveal) and motor fusion. The isolated case of Parks²³⁰ in which bifixation was restored, and the cases of Wright and coworkers³⁰³ in which normal random-dot stereopsis was achieved notwithstanding, there is universal agreement among strabismologists that complete restoration of normal binocular vision with normal random-dot stereopsis is unattainable in essential infantile esotropia except in the rarest of circumstances. However, this conclusion need not lead to capitulation before a seemingly incurable anomaly in which surgery produces at best an improved cosmetic appearance. Stereopsis, while essential for a certain, though limited number of occupations, is not indispensable in the presence of monocular clues for depth perception. Moreover, stable sensory and motor fusion may occur in the absence of stereopsis.

A cure is not absolute, but consists of several grades of subnormal or abnormal binocular vision. We must ask: What is the nature of these less than ideal forms of binocular vision? Of what functional benefit are they for the patient? How often do they occur in a group of surgically treated patients with essential infantile esotropia? Does their occurrence depend on the age at which the eyes are surgically aligned?

NONSURGICAL TREATMENT. We stated in the beginning of this chapter that hypermetropic refractive errors not exceeding 2D to 3D are physiologic variants in infants. The question arises with respect to essential infantile esotropia whether correction of a small hypermetropic refractive error is indicated. Essential infantile esotropia generally is nonaccommodative; that is, the AC/A ratio is usually normal, high hypermetropic refractive errors are rare (see Table 16-3), and little if any difference exists between the angle of deviation measured at distance and near fixation. However, as mentioned earlier, exceptions do occur, and refractive and nonrefractive accommodative esotropia can have their onset in early infancy.

We have observed on occasion a high AC/A ratio in patients with essential infantile esotropia without a refractive error. In such cases, the esotropia increases significantly at near fixation and little if any deviation is present at distance fixation. Before this diagnosis can be established in infants, one must, of course, rule out interference with steady fixation at distance through lack of attention during the measurement.

It has become our policy to correct all hypermetropic refractive errors in excess of +2.50D sph before considering surgery. In uncooperative infants, a trial of miotics may be considered in lieu of glasses. In most patients with essential infantile esotropia, however, correction of the "physiologic" low-degree hypermetropia has little, if any, effect on the deviation.

The view that essential infantile esotropia in most instances is nonaccommodative was challenged by Réthy and Gál,²⁴⁵ Réthy,²⁴⁴ and Kettesy.¹⁵⁰ These authors rejected the concept of congenital nonaccommodative esotropia and claimed that in a high percentage of cases the deviation is accommodative in origin. Réthy noted that after correction of the full hypermetropic refractive error in esotropic children and repetition of cycloplegic refraction a month or two later, retinoscopy revealed a higher refractive error than was found on the first examination. After increasing the prescription and overcorrecting the hypermetropia by 0.5D to 1.0D, he noted reduction of the angle of deviation. Such patients were atropinized to facilitate acceptance of the overcorrection. When the procedure was repeated several times, latent hypermetropia became increasingly manifest and was corrected or overcorrected until the accommodative effort was decreased to the point where the associated accommodative convergence no longer caused esotropia. Réthy claimed that unless this therapy is instituted in early infancy, the increased accommodative tonus and the associated increased accommodative convergence will stabilize and become refractory to belated therapeutic measures. According to this author, such cases are then erroneously referred to by strabismologists as "nonaccommodative." Réthy claimed that surgery can be avoided in 90% [sic] of esotropic patients if his method of treatment is followed.²⁴⁴

We are in full agreement with Réthy and Kettesy concerning the validity of Donders' theory whenever it is applicable. We also stress the often neglected need for full correction of a hypermetropic refractive error and for frequent refractions in patients with accommodative esotropia, in view of the findings of Brown and Kronfeld³¹ and those of Brown.³⁰ Furthermore, the effectiveness of atropinization in causing complete cycloplegia varies in different patients, and latent hypermetropia may initially go undetected⁶⁶ and become only gradually manifest as corrective lenses are worn for some time. On the other hand, the angle of deviation

in essential infantile esotropia as a rule is not consistent with the excess of accommodation required to overcome hypermetropia. In most instances there is no relationship between the angle of strabismus and the size or type of refractive error in essential infantile esotropia.⁵⁴ The deviation usually is considerably greater than it would be if the excess convergence were related to the increased accommodative effort. Moreover, a prospective study by Ingram and coworkers¹⁴⁰ has shown that a prophylactic correction of hypermetropic refractive errors in excess of 2.00D did not prevent development of strabismus. Thus the extension of Donders' doctrine by Réthy and Kettesy to include the vast majority of patients with essential infantile esotropia is not justified in our opinion, which should not detract from the fact that the theory of Donders remains the best substantiated explanation for accommodative strabismus (see Chapter 9).

Amblyopia should be treated rigorously *before* and not, as advocated by some authors,^{162, 294} after surgery for the following reasons: (1) The earlier in life the treatment is begun, the shorter the duration of treatment. (2) The diagnosis of amblyopia and the monitoring of the fixation preference during treatment are more difficult once the eyes are aligned or nearly aligned by surgery than in the presence of a large angle esodeviation.^{37, 207} (3) Once the eyes are aligned some parents may be lulled into thinking that all problems are over and become negligent in keeping their follow-up appointments. We have repeatedly seen children with deep amblyopia who had early surgery and who, in spite of our instructions, did not return to our office until years later. (4) The outcome of surgery is less favorable in patients who remain amblyopic at the time of surgery.^{148, 258, 259} The time for surgery has come when the child alternates freely or can hold fixation with the formerly amblyopic eye through a blink.

Some investigators have recommended the use of prisms in the preoperative treatment of essential infantile esotropia.^{77, 292} However, this treatment has never become popular and is not used by us. Prismatic therapy and the *prism adaptation test* are discussed in Chapter 24.

SURGICAL TREATMENT

TIMING OF SURGERY AND RESULTS. Much discussion has centered on the optimal time at which to operate on children with essential infantile esotropia. Several schools of thought have

evolved, some advocating surgery as early as 3 months and others as late as 4 years of age. Fifty years ago an operation at 4 or 5 years of age was considered early and in most instances surgery was not contemplated until the child was ready for school. There has been a general tendency among ophthalmologists to operate on children younger than was customary then. Improved safety of anesthetic procedures has reduced the surgical risk to an almost negligible minimum. A steadily growing group of surgeons now believe that an operation for essential infantile esotropia is advisable before completion of the first 24 months of life and some prefer to complete surgery during the first 12 months or even earlier.^{25, 53, 136, 138, 277, 279-282, 303, 305} The arguments for this reasoning are that early surgical treatment provides a better chance for functional improvement, is desirable for psychological reasons, and that secondary changes occur in the extraocular muscles, the conjunctiva, and Tenon's capsule—all of which make a correction at a later date more difficult and less predictable.

Early surgery was pioneered by the late Frank Costenbader who in 1958 stated:

I feel strongly that we should, first, regain and maintain vision in each eye from early childhood, and, second, regain binocular alignment as early in infancy and childhood as possible and to maintain it thereafter.^{53, p. 331}

Costenbader's plea for early surgical alignment of the eyes was undoubtedly influenced by Chavasse,^{40, p. 519} who, in turn, was influenced by the Pavlovian thinking of his time. Chavasse stated that the opportunity for early single binocular vision is of paramount importance for development of normal binocular reflexes. Sporadic reports in the literature of normal or near-normal random-dot stereopsis after surgical alignment before 6 months of age seemed to support this view.^{53, 138, 303}

Other eye surgeons advocated operating when the child is about 2 years of age^{6, 16, 72, 180} or even older.^{10, 134, 146, 179} Many clinicians believe that examination during early infancy cannot be sufficiently complete for careful surgical planning; that associated vertical anomalies, including the A and V patterns, overaction of the inferior oblique muscles, or dissociated vertical deviations may be overlooked; and that the deviation at distance fixation cannot be evaluated reliably before 2 years of age.

The older literature is replete with a pessimistic outlook regarding the functional outcome follow-

ing surgery in patients with infantile strabismus that is based on Worth's assumption that a congenital defect of the fusion faculty is the cause of squint.³⁰¹ Indeed, the view was common that normal binocular functions are obtained rarely, if ever, when the deviation dates from birth.^{18, 174, 175}

The beneficial effect of surgical alignment of the eyes by the age of 24 months was first discussed in the frequently quoted paper by Ing.¹³⁶ Other studies⁶ came to the same conclusion. The major problem in evaluating much of this work involves the interpretation of tests used to determine the presence of binocularity. We find it erroneous to assume, as is frequently done,^{57, 139, 277, 280, 305} that gross stereopsis, a positive Worth four-dot test, or visibility of the two stripes during the Bagolini striated glasses test are indicators of fusion when in fact any or all of these responses can be elicited when a manifest residual esodeviation is present along with anomalous retinal correspondence.^{202, 203} The binocular cooperation on the basis of anomalous retinal correspondence between the fovea of the fixating eye and a peripheral retinal area in the eye with a residual eso- or exodeviation is functionally not equivalent to stable normal binocular vision at all fixation distances with fusional amplitudes! *Unless a clear distinction is made between normal and anomalous binocular vision in evaluating the results of patients operated on and aligned at different ages, no conclusions regarding the therapeutic superiority of operating at an early age can be drawn.*

A second problem with many studies on the results of surgery in essential infantile esotropia is that contemporary authors, too numerous to cite here, consider a residual deviation of 10^Δ a satisfactory surgical outcome. Must it be emphasized that orthotropia, eso- and exophoria, intermittent heterophoria, and eso- and exotropias of 10^Δ are functionally not the same? If no distinction is made on the basis of the cover and the cover-uncover tests that this residual deviation is a heterophoria or a heterotropia at all fixation distances, the criterion of 10^Δ for surgical success is misleading and therefore useless. At best, it tells whether the patient has been cosmetically improved by the surgery.

A third problem with many of the older studies is that no distinction is made between the age at the first operation and the age at which alignment was accomplished. Clearly, only the latter is relevant to this discussion.

In an effort to improve communication between clinical investigators and with the shortcomings, mentioned above, of previously used outcome criteria in mind, we suggested the following classification of the results of surgery in essential infantile esotropia: (1) *subnormal binocular vision*, (2) *microtropia*, (3) *small angle esotropia or exotropia*, and (4) *large angle esotropia or exotropia*.²⁰⁵ Some of the clinical features of these conditions are summarized in Table 16–4, and the tests employed for their diagnosis have been discussed in Chapter 12 (see also von Noorden²⁰³). Table 16–4 has been modified from previous editions in response to questions raised regarding its clarity.²⁵⁰

We consider *subnormal binocular vision*, a term introduced by Lyle and Foley¹⁸¹ and also used by de Decker and Haase,⁷⁴ as an *optimal* treatment outcome and have never seen a result better than that in infantile esotropia. Unlike in microtropia, the patient fixates centrally, has normal visual acuity in each eye, and behaves in all other respects like someone with normal binocular vision, except for reduced stereopsis and a foveal suppression scotoma in one eye that is only present under binocular conditions. As will be discussed later in this chapter, microtropes are often mildly amblyopic with parafoveal fixation and have anomalous retinal correspondence with identity of the angle of anomaly and the degree of fixation eccentricity. Microtropes with foveolar fixation in each eye may be difficult to distinguish from patients with subnormal binocular vision and we readily admit that this is a transitional zone in the classification of outcomes presented here. Clearly, however, a microtropia because of the

amblyopia is less advantageous from a functional point of view than is subnormal binocular vision and must therefore be considered a less than optimal but *acceptable* outcome.

Subnormal binocular vision and microtropia are often thought of as favoring motor stability, that is, being protective against a recurrence of strabismus. However, several studies have shown that whereas the stability of alignment is significantly better when these conditions are present as opposed to when they are not, deterioration does occur.^{7, 123, 291} Residual small angle eso- or exotropias of less than 20^Δ do not interfere with the normal appearance in most patients and in this case require no further treatment, except for a still existing or recurrent amblyopia. As in microtropia we speak of a less than optimal but still acceptable outcome when a residual but small deviation remains. Residual esotropia or consecutive exotropia requiring surgery is clearly an *unacceptable* outcome.

Using these criteria we have analyzed results of surgical attempts to align the eyes to an orthotropic position as closely as possible by one or multiple operations in 358 patients with a documented onset of esotropia before the age of 6 months.²⁰⁵ Figure 16–7 lists the prevalence of the various functional endstages of therapy according to whether surgical treatment was completed between 4 months and 2 years, 2 to 4 years, or older than 4 years after a mean follow-up of 39 months. This analysis shows that as age at completion of surgical therapy increases, the probability of an optimal outcome (subnormal binocular vision) decreases. Increasing age at the completion of treat-

TABLE 16–4. Classification of Surgical Outcomes in Essential Infantile Esotropia

Subnormal Binocular Vision	Microtropia	Small Angle ET/XT (<20^Δ)	Large Angle ET/XT (>20^Δ)
Orthotropia or asymptomatic heterophoria	Inconspicuous shift or no shift on cover test	Appearance improved; most parents are happy with outcome	Conspicuous residual angle
Normal VA in each eye	Mild amblyopia is common		Amblyopia may be present
NRC	Usually ARC	ARC is common	ARC or suppression
Fusion with amplitudes		Anomalous fusion on the basis of ARC	No fusion
Reduced stereopsis		Stereopsis reduced or absent	Absence of stereopsis
Stable alignment	Some stability	Less stability	May be unstable
No further treatment		No treatment except for amblyopia	Additional surgery may be required
Optimal outcome		Less than optimal but still acceptable	Unacceptable outcome

ARC, abnormal retinal correspondence; ET, esotropia; NRC, normal retinal correspondence; VA, visual acuity; XT, exotropia.

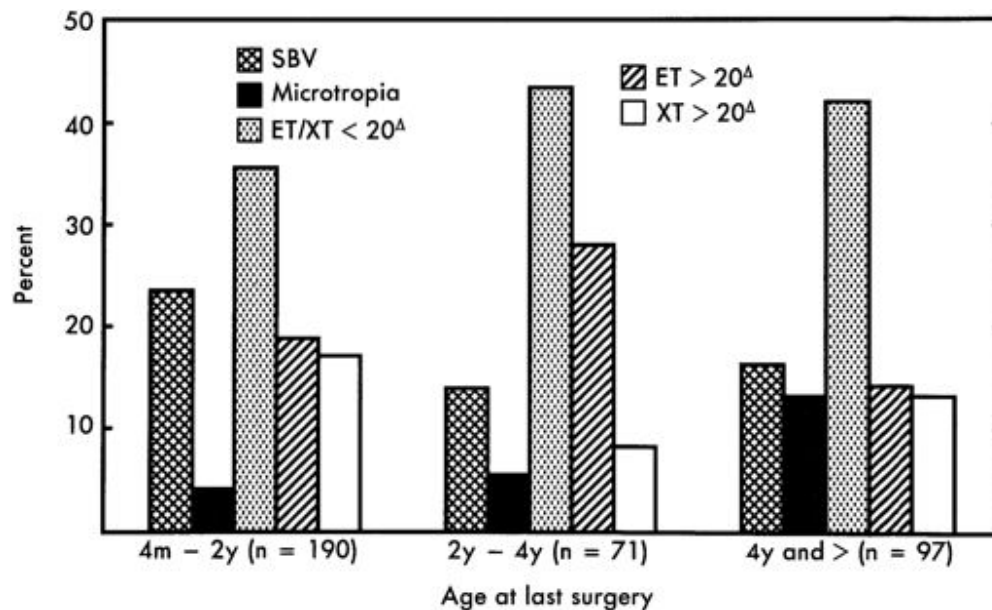


FIGURE 16-7. Prevalence of functional state in 358 patients according to age at alignment. SBV, subnormal binocular vision; ET, esotropia; XT, exotropia. (From Noorden GK von: A reassessment of essential infantile esotropia (XLIV Edward Jackson Memorial Lecture). *Am J Ophthalmol* 105:1, 1988.)

ment tends to move the patient away from subnormal binocular vision and into the functionally inferior microtropia and small angle esotropia or exotropia group. These data, although based on evaluation criteria quite different from those used by previous investigators, are in support of the current view that surgery completed before the age of 2 years yields superior results. They have been confirmed by Shauly and coworkers²⁵⁹ who have adopted our classification of surgical results. However, they are at variance with the admonition that unless surgery is completed before that time, a functionally useful form of binocular vision cannot be expected.²⁸¹ In fact, many of our patients achieved such results when surgical treatment was concluded after the age of 2 or even 4 years. De Decker has confirmed these findings.⁷²

Although these results are far from perfect, they are not nearly as dismal as one must conclude from the older literature,^{18, 174, 175, 301} especially since we have learned to consider anomalous correspondence in a more favorable light (see Chapter 13). Some form of binocular cooperation ranging from near-normal (subnormal binocular vision) to anomalous (microtropia and small angle esotropia or exotropia) existed in 66% of our patients. To the mother who asks, "Is this operation done for cosmetic reasons or will my child ever learn to use the eyes together?," we can answer, "There is an above-average chance for some form of binocular cooperation after surgery,

although normal depth perception cannot be expected."

Until such time that new information becomes available that may require modification of this approach we advocate surgery when the following criteria are met: (1) demonstration of a stable and sufficiently large deviation, (2) absence of an accommodative factor, (3) alternating fixation behavior after treatment of amblyopia, and (4) identification of the nature of associated vertical deviations or of vertical incomitance (A or V patterns). As soon as this information is unequivocally available, we see no reason to delay surgery. In addition to functional and psychological benefits (see Chapter 10) there is some evidence that the child's motor development improves after surgery.²⁴⁹ Although controlled studies are needed to validate this point, it is certainly astonishing, and perhaps more than just a coincidence, how often parents will report spontaneously during postoperative visits that the child stumbles and runs into walls less often. In this connection it may be of interest that expansion of the binocular field of vision has been reported in adults after surgery for esotropia.^{159, 302}

The completeness with which all necessary preoperative information can be obtained depends largely on the cooperation of the child as well as the patience and understanding of the examiner. In some patients, these data can be obtained by 6 months of age or earlier,⁵⁵ whereas in others the

surgeon may be forced to procrastinate until the child is 2 years of age or older.

Of special significance with regard to *outcome expectations* is the fact that normal stereoacuity remains such an elusive therapeutic goal in the overwhelming majority of patients with essential infantile esotropia. In view of the extraordinary sensitivity to conflicting visual input of cortical binocular neurons mediating stereopsis in infant kittens¹³² or infant monkeys,⁵⁸⁻⁶⁰ the question arose whether surgery even at the age of 6 months may be too late to preserve stereopsis. Several recent studies have addressed this point and the results are controversial. Birch and coworkers²⁵ reported better random-dot stereopsis in children operated upon between the ages of 5 and 12 months than in another group who had surgery at 13 to 18 months. Wright and coworkers³⁰³ operated on seven patients between the ages of 13 and 19 weeks and achieved normal stereopsis (Titmus test) in two cases. However, Ing¹³⁸ examined 16 patients who were surgically aligned by other ophthalmologists at a mean age of 4.2 months but was able to identify only one patient with refined stereoacuity of 40 seconds of arc (Titmus test) and 20 seconds of arc (Randot test). Likewise, Helveston and coworkers¹²² who operated on 10 patients aged 4 months found stereopsis of 140 seconds (Titmus) in only one instance.

We do not believe that the evidence thus far presented in favor of operating *before* the age of 6 months is sufficient to advocate this approach on a general basis. Long-term follow up studies are essential to improve our knowledge as to the functional benefits to be derived from operating that early in life. *The longitudinal study of patients thus treated by Helveston and coworkers*¹²² showed subsequent deterioration after initial ocular alignment in many instances.

The observations that normal or near-normal stereopsis can be restored at all in isolated instances after surgical alignment before the age of 6 months is of interest with regard to the etiology of infantile esotropia. Stereopsis has been demonstrated by objective means, at least transiently, in esotropic infants corrected with prisms¹⁸⁹ or immediately after surgical alignment and before a residual strabismus established itself.^{5, 248} On the other hand, we have learned that artificial strabismus produced in infant monkeys for as briefly as 1 week decimates the number of striate neurons that normally receive input from both eyes^{12, 58} and

that are linked to stereopsis.^{15, 59, 60} This loss of binocular neurons is irreversible in monkeys even after realignment of the eyes and subsequent exposure to a normal visual environment for as long as 2 years. In view of the great functional and anatomical similarity of the visual system in monkeys and humans it is reasonable to conclude that defective stereopsis in infantile esotropes, similar to optokinetic asymmetry, is an irreversible *consequence* of strabismus early in infancy rather than, as has been stated, the manifestation of a genetic sensory defect²³² in the afferent visual pathway that precludes complete functional recovery.

Presuming that the sensory substrate before onset of the esotropia was normal, we must ask why only such a small number of patients recover normal or near-normal stereopsis in spite of very early surgery? Among the possibilities to be considered are that surgery as early as 3 to 4 months was already too late and that the destruction of cortical binocularity had already occurred before alignment was accomplished. The minimal duration of incongruous visual stimulation necessary to permanently impair cortical binocular cells is unknown in humans, and interindividual differences in susceptibility may well exist. Second, the degree of functional recovery may depend on the duration of a brief period of normal binocular visual input or of intermittency of the deviation *prior* to the onset of constant esotropia. We know that essential infantile esotropia has its onset usually during the first 3 months of life and is rarely, if ever, present at birth (see p. 321). Thus, a brief period or, in the case of early intermittency, periods of normal binocular stimulation may well have been present prior to the onset of esotropia and stabilized binocular connections to the point where they may be recoverable after alignment. Third, a residual angle of esotropia after surgery may preclude normal stereopsis.

In addition to defective stereopsis, a second and perhaps etiologically related residual sensory defect persists even in patients with optimal or desirable surgical outcome. This consists of a foveal suppression scotoma in one eye of a patient with subnormal binocular vision and microstrabismus. This scotoma, to which Parks²²⁶ and von Noorden and coworkers²¹⁶ drew attention, measures 2^Δ or less in diameter and may be present only under binocular conditions of seeing. It usually occurs in the nondominant eye but may switch rapidly from one eye to the other (alternating

foveal suppression). The scotoma is diagnosed with the 4^Δ base-out prism test (see p. 218) or by a decrease of visual acuity in one eye when acuity is determined under binocular conditions of seeing with a polarized projected chart.²⁰⁴ Thus postoperative alignment in patients with essential infantile esotropia is maintained by peripheral fusion alone and is not dependent on normal bifoveal interaction. Few will disagree that this state of binocular cooperation, although not perfect, is of functional benefit to the patient.

Although an etiologic and pathophysiologic relationship may exist between a binocular foveal suppression scotoma and reduced stereoacuity, to use the degree of stereoacuity as an indicator for suppression of bifoveal fusion, as proposed by Parks,²²⁶ is not justified. Normal stereoacuity (15 to 60 seconds of arc on any of the random-dot stereograms) is indisputably the hallmark of normal binocular function. On the other hand, subnormal stereoacuity or even stereoblindness can be present in orthotropic subjects with stable fusion. *The mere reduction of stereoacuity alone is insufficient proof of foveal suppression.*

In summarizing the ongoing discussion as to the optimal age at which to operate, it is fair to state this has yet to be established. Normal stereopsis has been restored only in isolated cases after surgical alignment prior to the sixth month of life. There is evidence from many independent studies that surgery completed before the second year of life improves the chances for recovery of limited binocularity. However, it has also been shown that such recovery may occur if surgery is delayed up to or beyond the age of 4 years. Strabismologists are awaiting eagerly the outcomes of two ongoing prospective multicenter trials in the United States and in Europe^{188, 284} that address this important issue.

TYPE OF OPERATION. Our surgical approach to treatment of essential infantile esotropia has undergone periodic changes over the years. Initially, we favored a recession-resection operation on the nondominant eye, combined with inferior oblique myectomies, if indicated, to be followed, if necessary, by a recession-resection on the fellow eye. The amount of surgery varied according to the size of the deviation and on the basis of observations made during examination of the deviations of the eyes and ranged from 3- to 5-mm recessions and 5- to 8-mm resections.²¹⁶ However, the number of reoperations required to gain or

maintain alignment was discouraging. In 1972 we reported that an average of 2.1 operations per patient was required to align the eyes.²¹⁶ Ing and coworkers,¹³⁹ who used 3- to 5-mm recessions of both medial recti, required as many as 2.6 operations per patient to achieve this goal. In recent years we have changed our method and now employ *recessions of the medial recti ranging from 5 to 8 mm*, provided the deviation measures 30^Δ or more at near fixation.²³⁹ This more aggressive approach has decreased the need for additional surgery and, contrary to our initial concern, does not cause limitation of adduction. Initial reports show that by doing these unconventionally large recessions of both medial recti, 73% to 84% of the patients are successfully aligned with one operation.^{121, 160, 240, 295} In the presence of a significantly large residual deviation, we resect both lateral rectus muscles in a second procedure. It has been advocated that the conventional amount of surgery in myopia be increased because of a higher percentage of unacceptable undercorrections.²⁵⁸

At this time we use a *unilateral recession-resection* operation on the nondominant eye infrequently to treat essential infantile esotropia and only in patients who have failed to respond to amblyopia treatment.

The use of *posterior fixation sutures* in lieu of large bimedial recessions of the medial rectus muscles in the treatment of essential infantile esotropia is enjoying greater popularity in Europe, especially in Germany, than elsewhere. This approach is preferred by some because it is said to reduce the prevalence of consecutive exotropia. Seventy-five percent of patients thus operated on achieve an alignment between 2^Δ exodeviation and 10^Δ esodeviation,^{70, 107, 147} which is comparable to what can be accomplished with large recession of both medial rectus muscles (see above).

POSTOPERATIVE TREATMENT

Postoperative care should be concerned primarily with the prevention of strabismic amblyopia (see Chapter 24) and correction of a hypermetropic refractive error.¹³ Since most postoperative patients have a small angle esotropia and a deep-seated anomalous retinal correspondence, subjective complaints about diplopia or other types of visual discomfort are practically never encountered. Although from time to time the suggestion has been made, with varying degrees of enthusi-

asm, that such patients should be treated orthoptically, we have not found this treatment of much value (see Chapter 24).

CHEMODENERVATION

Injection of the extraocular muscles with botulinum toxin, type A (Botox) has been suggested as a viable alternative in the treatment of infantile esotropia. For further discussion, see Chapter 25.

Nonaccommodative Convergence Excess Esotropia (Normal AC/A Ratio)

Definition

Nonaccommodative convergence excess esotropia is defined as an esotropia that is larger at near (at least 15^{Δ}) than at distance fixation in an optically fully corrected patient whose AC/A ratio is normal when determined with the gradient method.²⁰⁸

Clinical Characteristics

As is the case in accommodative esotropia, the onset is early in life, occurring as a rule between 2 and 3 years of age, but we have also seen patients in whom the onset was shortly after birth. Such patients are characteristically orthotropic or have a small angle esotropia at distance fixation and a larger esotropia (20^{Δ} to 40^{Δ}) at near fixation. In contradistinction to esotropia with a high AC/A ratio, however, relaxation of accommodation by bifocals or its facilitation by miotics has little if any effect on the near deviation. The AC/A ratio, if determined with the gradient method, may be normal or abnormally low.²⁰⁸ This condition differs from the “hypoaccommodative” esotropia of Costenbader⁵³ (see above) inasmuch as the near point of accommodation is within the normal range. Obviously, excessive convergence in such patients must occur on a basis other than accommodation, perhaps from *tonic innervation*, which is the reason we suggested the term nonaccommodative convergence excess for this entity.²⁰⁸ Clearly, an abnormal distance-near relationship in the angle of esotropia is not always caused, as has been assumed,^{229, p.60} by a high AC/A ratio. The widespread and, in our opinion, unsound practice of determining the AC/A ratio by comparing the distance and near deviation (heterophoria method; see Chapter 5) is likely to miss the diagnosis of nonaccommodative convergence excess and to

subject such patients to bifocal therapy to which they will not respond.^{187, 208} Case 16–4 illustrates the features of this form of esotropia.

CASE 16–4

A 5½-year-old girl was first noted to intermittently cross her eyes when she was 2 years of age. Amblyopia of OD was diagnosed by her local ophthalmologist, and she responded well to occlusion treatment begun at 4 years of age. On examination, her uncorrected visual acuity was 20/40 + 1 OD and 20/25 + 2 OS. The prism and cover test showed 12^{Δ} esotropia at distance and 30^{Δ} at near. When the measurement was repeated on several occasions with the patient looking through +3.00 spherical lenses, the near deviation still measured 22^{Δ} . The patient manifested a slight A pattern with minimal overaction of both superior oblique muscles. Cycloplegic refraction indicated the presence of mild hypermetropia of +0.75 sph OD and +1.00 sph OS. The remainder of the examination, including the fundus examination, was normal. Clearly, the persistent increased near deviation after relaxation of accommodation with +3.00 spherical lenses must have been caused by factors other than accommodative convergence.

Treatment

Since bifocals or miotics are ineffective in controlling the deviation at near, surgery must be considered for the nonaccommodative element of the anomaly. In our hands, a conventional recession procedure of both medial rectus muscles (4 to 5 mm) alone or combined with posterior fixation sutures has been surprisingly ineffective in significantly reducing the near deviation. In fact, this combined operation performed in the patient described in Case 16–4 reduced the near deviation from 30^{Δ} to 25^{Δ} esotropia! We feel that unconventionally large recessions of both medial rectus muscles (5 to 8 mm) may be more effective, but more clinical experience must be accumulated before recommendations regarding the most effective management can be made.

Acquired or Basic Esotropia

Definition

We define acquired nonaccommodative esotropia as a comitant esotropia with a gradual onset after 6 months of age but usually limited to childhood and a near deviation that approximately equals the

distance deviation. Unlike in refractive accommodative esotropia a significant uncorrected hypermetropic refractive error is absent and unlike in nonrefractive accommodative esotropia the AC/A ratio is normal.

Clinical Characteristics

Costenbader⁵³ referred to this type of deviation as “acquired tonic esotropia,” and the Hugonniers called it “essential esotropia of late onset.”^{134, p. 210} At the onset the angle of strabismus generally is smaller than in patients with essential infantile esotropia, but the angle tends to increase to a magnitude of 30^Δ to 70^Δ. Since the eyes usually straighten out or even become divergent under general anesthesia and since the forced duction tests are, as a rule, negative, we are inclined to implicate an innervational anomaly rather than mechanical factors as the cause of this form of strabismus. Because parents frequently associate onset of the deviation with injury, illness, or emotional upset of the child, Costenbader⁵³ postulated that such patients have an excessive convergence tonus that is controlled initially by fusional divergence but is disrupted easily by exogenous factors.

The clinician should always keep in mind the possibility of an underlying lesion or malformation in the central nervous system in a young patient with acquired nonaccommodative esotropia, the onset of which need not always be acute.^{3, 8, 26, 171, 235, 293, 299} Many of these patients receive treatment for their esotropia and some even undergo strabismus surgery^{3, 171, 304} before the correct diagnosis, which may include a brain tumor or other life-threatening condition, is made. It behooves the ophthalmologist to search for signs of increased intracranial pressure in all patients with an acquired esotropia.¹⁷¹ Special vigilance is called for when the esodeviation is greater at distance than at near fixation (divergence paralysis; see Chapter 22), which has been described in a tumor of the corpus callosum³ and in Arnold-Chiari malformation.^{26, 235}

The importance of a fundus examination to rule out papilledema or optic atrophy in every patient with strabismus is convincingly demonstrated by the case report of a patient with a gradually acquired esotropia who turned out to have an underlying life-threatening condition.

CASE 16-5

A 5-year-old boy who had gradually developed esotropia 6 months before our seeing him was referred for treatment of amblyopia. The referring physician had performed a cycloplegic refraction (+3.50 sph OU) and prescribed glasses. On examination, the best corrected visual acuity was 6/30 OD and 6/9 OS. The prism cover test showed a comitant esotropia of 40^Δ at distance and 50^Δ at near fixation. Examination of the ductions and versions revealed minimal underaction of the right lateral rectus muscle and minimal overaction of the right superior oblique muscle. The patient suppressed OD at near and distance with the Worth four-dot test. Fundus examination showed massive choking of the optic nerve head in both eyes. Computed tomography revealed a midline posterior fossa tumor, which was successfully removed 2 days later and identified as an astrocytoma. The papilledema receded postoperatively, and visual acuity OD improved to 6/9 after 1 month of occlusion therapy. The esotropia remained unchanged, however, and 4 months after brain surgery the right medial rectus muscle was recessed 4 mm and the right lateral rectus muscle resected 7 mm. Six months after muscle surgery the patient had a best corrected visual acuity of 6/9 OD and 6/6 OS. The patient was orthophoric at near and distance fixation, and he had 60 seconds of arc stereoacuity while wearing his glasses. Without glasses he had a residual esotropia of 4^Δ at distance and 10^Δ at near fixation. Fundus examination revealed postpapillitic gliosis but no atrophic discoloration of the nerve heads.

Therapy

Therapy consisting of elimination of amblyopia followed by surgical correction should be started *as soon as possible* after the onset of the deviation. Since a period of normal binocular vision has existed for at least 6 months or longer before the onset of the disease, the prognosis for normalization of binocular functions is better than in those with essential infantile esotropia, provided treatment is started without delay. Lang¹⁷¹ reported that if onset occurs after the age of 1½ years a complete cure as defined by orthotropia and random-dot stereopsis becomes possible after surgical alignment and he referred to this form of strabismus as *normosensorial late-onset esotropia*. Dankner and coworkers⁶⁷ reported that a consecutive exotropia in these patients during the immediate postoperative period resulted in a higher incidence of fusion than in those who were initially orthophoric or undercorrected.

Esotropia in Myopia

It is well established that myopia is present in 3% to 5% of patients with nonaccommodative esotropia, and most clinical characteristics of this esotropia are no different from those associated with emmetropia or hypermetropia. There are, however, two special forms of esotropia occurring with myopia that, in view of their unusual features, deserve separate discussion. Von Graefe¹⁰³ recognized the first type, and Bielschowsky²⁰ later described it in detail. The esotropia is accompanied by diplopia first only at distance and eventually also at near fixation, mild limitation of abduction in both eyes, and normal adduction. It occurs predominantly in young myopic adults. The explanation given by von Graefe and Bielschowsky for the etiology of this entity is speculative. Bielschowsky advised resection and advancement of both lateral rectus muscles to treat these patients. This condition must be very rare since we have encountered it only once in 35 years of a practice, in a 19-year-old Asian man who had a myopia of $-6D$ in both eyes.

The second type is caused by restrictive factors and will be discussed in Chapter 21.

The treatment of *unrestrictive esotropia* with myopia is not different from the treatment of hypermetropic esotropes. However, special precautions are in order in a patient with a thin sclera. To avoid any scleral suturing we have successfully treated a highly myopic esotropic patient with a history of retinal detachment by performing a marginal myotomy of the medial rectus and a resection followed by end-to-end suturing of the lateral rectus muscle.²⁰¹ Coats and Paysse⁴⁸ reported a technical modification of the classic recession and resection procedure to avoid scleral sutures in such cases.

Acute Acquired Comitant Esotropia

The onset of acute acquired comitant strabismus is always an alarming event for both the patient and the physician. In young children and infants the acute mode of onset can rarely be determined with certainty and voluntary closure of one eye may often be the only sign. In older children or adults with acute strabismus, sudden diplopia is of immediate concern and the onset of the disease often can be traced to a precise hour of a particular day. In patients with acute strabismus, regardless of how obvious the etiology might be, an espe-

cially careful motility analysis is always necessary to rule out a paretic deviation.

Unilateral or bilateral paresis of the abducens nerve, commonly the first manifestation of a central nervous system disorder or of a medical problem, may cause an acute esotropia with an angle greater at distance than at near fixation (see also divergence paralysis, Chapter 22). This deviation may quickly become comitant, in which case it will be difficult to recognize the paretic element. Thus any acute esotropia with the prominent complaint of diplopia of sudden onset calls for increased vigilance and may require a neurologic evaluation even though its cause may be quite harmless.

We distinguish three forms of acute comitant strabismus: (1) that occurring after artificial interruption of binocular vision; (2) that occurring without interruption of binocular vision as a result of a decompensated esophoria; and (3) that caused by an intracranial pathologic process.

Acute Strabismus After Artificial Interruption of Fusion

By far the most commonly encountered form of acute strabismus in clinical practice is that which occurs after temporary occlusion of one eye in patients with no previous history of disturbance of binocular vision or in the course of treatment of amblyopia in patients without strabismus (anisometropic amblyopia). When the patch is removed, the occluded eye will be in an esotropic position or, in adults with large angle exophoria, occasionally in an exotropic position. This disturbing event has been reported when one eye has been bandaged for several days, after a perforating corneal injury,¹²⁸ after excision of a chalazion,²¹ or, as in Case 16-6, after swelling of the lids following blunt trauma. Swan²⁷⁸ reported a group of patients in whom a large angle esotropia developed in the course of occlusion therapy for amblyopia. In several of them, surgery was necessary to straighten the eyes.

CASE 16-6

Age: 5 years
 March 17, 1971
 Routine eye examination, no visual complaints

Visual acuity: OD 6/4.5 OS 6/4.5
 Refraction: OD + 1.50D sph OS + 1.25D sph
 Distance deviation: 8^Δ esophoria
 Near deviation: 10^Δ esophoria

September 30, 1971

The patient was struck in the OS with a shovel 2 days before the examination; the OS was swollen and shut. When swelling subsided, the patient noted diplopia. Slit-lamp examination revealed mild traumatic iritis OS.

Distance deviation: 18^Δ esotropia (comitant)
 Near deviation: 45^Δ esotropia (comitant).

The OS was atropinized because of traumatic iritis.

October 12, 1971

Esotropia is unchanged. Iritis has subsided. Glasses with refractive findings as per visit on March 17 were prescribed.

November 23, 1971

The patient has worn glasses well, and diplopia has disappeared.

Distance deviation (c \bar{c}): 4^Δ esophoria
 Near deviation (c \bar{c}): 4^Δ esophoria
 Distance deviation (s \bar{c}): 8^Δ esophoria
 Near deviation (s \bar{c}): 16^Δ intermittent esotropia
 Rx: Continue to wear glasses

June 9, 1972

No complaints

Distance deviation (c \bar{c}): orthophoria
 Near deviation (s \bar{c}): 6^Δ esophoria
 Distance deviation (s \bar{c}): 6^Δ esophoria
 Near deviation (s \bar{c}): 14^Δ esophoria

Glasses were removed, and the patient has been visually comfortable without correction since this last examination.

The child in Case 16-6 had an esophoria that decompensated and became manifest after artificial disruption of fusion. The deviation was readily controlled with glasses, and eventually fusional amplitudes recovered sufficiently to control the deviation without glasses.

Occlusion of one eye presents an obstacle to binocular vision since it disrupts fusion. Once fusion is disrupted and the compensatory mechanism is thus suspended, a formerly latent esodeviation will become manifest. In some patients, correction of the underlying refractive error will straighten the eyes. In others, the deviation is of a temporary nature and will disappear spontaneously. In another group, surgery may be indicated. The prognosis for restoration of normal binocular vision is excellent, although improvement is not always so spontaneous, and in some patients surgery may become necessary. It is prudent to perform a refraction before considering patching one

eye for whatever reason. In the presence of a significant uncorrected hypermetropic refractive error, the patient should be warned that an esotropia may ensue from wearing the patch.

Acute Esotropia Without Preceding Disruption of Fusion (Burian-Franceschetti Type)

This form of strabismus is characterized by an acute onset with diplopia, a relatively large angle esotropia, absence of signs of paralysis, and a good potential for binocular cooperation. The refractive error, as a rule, is insignificant and the accommodative element is minimal. Disruption of fusion is not an etiologic factor, and in most instances the deviation apparently occurs spontaneously. However, in some patients a debilitating illness or physical or emotional stress may precede the onset of the deviation.

This form of acute strabismus was first described by Burian,³³ who reported on four patients ranging in age from 11 to 72 years who had esotropia of acute onset and diplopia. All had low hypermetropic refractive errors, and the angle of strabismus ranged from 20^Δ to 60^Δ. In all patients there was good binocular cooperation with the angle of strabismus corrected, and the functional results following surgery were excellent. Additional cases were reported by Franceschetti,⁹⁵ and Franceschetti and Bischler⁹⁶ and this form of strabismus has become associated with Franceschetti's name in the European literature. Several additional cases have been reported,⁴⁴ and the literature was reviewed by Burian and Miller.³⁵ It appears that such patients have an asymptomatic esophoria with only a slim reserve of fusional amplitude that maintains alignment of the eyes over the years but that may become lost under the influence of physical or emotional strain. In addition to a favorable outcome after surgical management of this condition³³ good results have also been obtained after chemodenervation.⁶⁸ We feel that surgical correction of acute-onset comitant esotropia in children under 5 years of age who are neurologically normal should not be delayed for longer than a few months to avoid the development of suppression and amblyopia. In visually mature children and adults this risk no longer exists and a longer delay of surgery is tolerated.²²²

Acute Esotropia of Neurologic Origin

This potentially threatening event is fortunately rare but should always be kept in mind when

encountering acute-onset comitant esotropia. As mentioned earlier in this chapter, a comitant esotropia with a gradual onset may occur in conjunction with Arnold-Chiari malformation,^{2, 6, 177, 235} hydrocephalus,¹⁰⁷ intracranial astrocytoma, and other brain tumors,^{3, 263, 264, 299} but the onset may also be sudden in any of these conditions. In the case of craniocervical junction anomalies, suboccipital decompression should precede strabismus surgery since otherwise recurrence of the esotropia is common.²⁹⁷ Unlike in the two former forms of acute esotropia, the functional results after surgical alignment of the eyes are not always favorable in acute esotropia of neurologic origin.^{43, 297}

Unless the cause of acute-onset esotropia is obvious, such as after artificial interruption of binocular vision or uncorrected hypermetropia, an underlying neurologic condition should always be considered. Hoyt¹²⁶ suggests that the presence of nystagmus in such patients or failure to restore normal binocular vision with surgery should be sufficient cause to proceed with a neurologic evaluation.

Microtropia

Ultrasmall angles of strabismus may escape diagnosis by ordinary methods of examination and are frequently overlooked. The cover test may be negative, or the fixation movement of the deviated eye may be absent or so small that it defies detection by the examiner when the sound eye is covered. Since amblyopia is a regular feature of microtropia, such patients often are subjected to an extensive, costly, and quite unnecessary neurologic evaluation in an effort to establish the cause of reduced visual acuity in one eye.¹²⁷

Thus microtropias are of considerable clinical significance. In view of the confusion with respect to the terminology and clinical characteristics of microtropias, a discussion of this entity must be quite detailed.

The ophthalmic literature has become redundant with descriptions of numerous forms of ultrasmall angles of strabismus. Many authors have introduced their own definitions and terms for what often appear to be similar, overlapping, or even identical clinical entities. Parks²²⁶ rightfully comments on the monstrous semantic structure that has evolved, including, among others, the terms *retinal slip*, *fixation disparity*, *fusion disparity*, *retinal flicker*, *monofixational esophoria*,

monofixational syndrome, *strabismus spurius*, *microtropia unilateralis anomalo-fusionalis*, *microstrabismus*, and *minisquint*. At the present stage of our knowledge, it may be difficult and even impossible to bring order into this system. Before attempting to do so, a brief historical review of ultrasmall angle deviations is in order.

Historical Review

Irvine¹⁴¹ reported detailed studies on 16 apparently nonstrabismic, anisometric amblyopes in whom the 4^A base-out test elicited positive scotoma responses and in whom close observation of the corneal reflex revealed “only reasonably good fixation.” This combination of amblyopia, anisometropia, and unsteady or possibly nonfoveal fixation may have been one of the first descriptions of what is currently recognized as microstrabismus.

Irvine’s study was followed by several reports on small angle deviations characterized by foveal suppression of the deviated eye and normal or near-normal peripheral fusional amplitudes. These forms were referred to as “retinal slip” by Pugh,²⁴² “esophoria with fixation disparity” by Gittoes-Davies,⁹⁹ “flicker cases” by Bryer,³² and “fusion disparity” by Jampolsky.^{143, 145} The term *fixation disparity* entered the discussion of small angle strabismus, adding further to the confusion in terminology. Jampolsky, who uses the term fixation disparity interchangeably with fusion disparity, defines this as a heterophoria in which there is no exact bifoveal fixation. In his opinion, fusion (fixation) disparity occupies an intermediate state between heterophoria and heterotropia.^{143, 145} Crone⁶³ pointed out that gradual transitions exist between orthophoria and microstrabismus; he considers fixation disparity a manifestation of abnormal binocular vision. Ogle and coworkers²²¹ had previously used the term fixation disparity to describe a long-known minute maladjustment of the visual axis ranging in magnitude from several minutes to maximally 20 minutes of arc. It occurs in subjects with heterotropia but also in those with normal binocular functions, equal visual acuity in each eye, and absence of suppression scotomas. Martens,¹⁸⁵ a former coworker of Ogle, deplored the usurping of this term by clinicians in reference to anomalies of binocular vision and microstrabismus and stressed the fact that fixation disparity is a part of normal binocular vision.

Parks and Eustis²³³ and Parks²²⁴ applied the

term *monofixational phoria* to patients with esodeviations in whom the angle of strabismus was larger on the alternate cover than on the cover test. Parks believed that the deviation in this group was kept partially latent by peripheral fusion and that macular suppression, normal retinal correspondence, mild degrees of amblyopia, gross stereopsis, and normal fusional vergences were other features of this entity. Peripheral fusion with normal retinal correspondence was thought to be possible in such cases on the basis of a "stretched Panum's area."

In a later paper, Parks²²⁶ presented his most recent thinking on the *monofixational syndrome*—to replace all terminology previously introduced by him. Patients with this syndrome are those in whom a "macular" scotoma in one eye (monofixation), good peripheral fusion with fusional amplitudes, and gross stereopsis are present consistently. Variable features associated with the monofixational syndrome are a history of strabismus, anisometropia, organic unilateral macular lesions, amblyopia, nonfoveal fixation, orthophoria, small angle heterotropia, and possibly a deviation that is larger on the alternate cover test than on the cover test. The monofixational syndrome may occur (1) primarily because of inability to fuse similar macular images, (2) secondary to treatment of large angle strabismus, (3) secondary to anisometropia, and (4) secondary to a unilateral macular lesion.

Lang¹⁶⁶ introduced the terms *microstrabismus* and *microtropia* to describe small angle heterotropias of less than 5° associated with harmonious anomalous retinal correspondence, partial stereopsis, and mild amblyopia. He had reported this form of heterotropia earlier in conjunction with an inconspicuous angle of the deviating eye¹⁶³ and summarized his studies on microtropia in a monograph.¹⁶⁹ According to Lang's concept, microtropia occurs in a *primary* and *consecutive* form. The primary form may remain constant during life, or the angle of heterotropia may increase (*decompensating primary microtropia*). Lang¹⁷³ recently proposed that primary microtropia may be related to the strong dominance of the fixating eye. The nondominant eye fails to track precisely in unison with the dominant eye, the binocular connection is loosened, and microstrabismus with anomalous correspondence develops. Consecutive microtropias are caused by surgical or optical correction of a large angle heterotropia and are a

common finding after surgical alignment of essential infantile esotropia.

Three types of microstrabismus can be differentiated according to the fixation behavior: (1) central fixation; (2) eccentric fixation and anomalous retinal correspondence, the angle of the anomaly being larger than the degree of eccentricity of fixation; and (3) an angle of anomaly identical to the degree of eccentricity of the monocular fixation (*microtropia with identity*). Lang thus includes patients in whom the cover test is positive, (1) and (2), and those in whom it is negative, (3). Lang¹⁶⁵ also stressed the frequent occurrence of familial microtropia and drew the interesting but unsupported conclusion that anomalous correspondence in these patients is a primary and hereditary defect, but revised this opinion recently.¹⁷³ Holland¹²⁹ and Richter²⁴⁷ had previously discussed this possibility in connection with small angle deviations. Cantolino and von Noorden³⁹ reported an uncommonly high prevalence of sensory, motor, and refractive anomalies in families with microtropic propositi, but rejected the concept that microtropia is a primary congenital defect. Rather, they believe that microtropia is the result of multiple and independently inherited refractive, sensory, or motor anomalies.

Helveston and von Noorden¹²⁰ questioned whether some of the strabismus forms that Lang had placed in the category of microtropia are sufficiently specific or different from those long known and accepted by ophthalmologists as "small angle deviations" to deserve a special classification. They suggested that the term *microtropia* be reserved to describe a unique form of sensorial adaptation in which the cover test is negative and amblyopia, eccentric fixation, and harmonious anomalous retinal correspondence are present (type 3 of Lang). In these cases, the angle of heterotropia equals the distance between the fovea and the area of eccentric fixation. The eccentric area is used for binocular as well as for monocular fixation; therefore the cover test will be negative because a fixation movement is not required when the fixating eye is covered. Peripheral fusion with fusional amplitudes and gross stereopsis are usually present. The functional completeness of sensorial adaptation in microtropia, as defined by Helveston and von Noorden,¹²⁰ is emphasized further by their finding that heterophorias may be present in a direction opposite that of microtropia (exophoria with microesotropia). Cüppers⁶⁵ had previously pointed out that there

are patients with eccentric fixation in whom the degree of eccentricity of fixation under monocular conditions and the angle of anomaly under binocular conditions are identical. Holland¹²⁷ described cases of amblyopia, an inconspicuous angle of esotropia, and anomalous retinal correspondence that were identical to those currently being classified as microtropia.

The high incidence of anisometropia in patients with microtropia suggests a possible etiologic relationship.^{120, 158, 256} Von Noorden²⁰⁰ assumed that, unlike other forms of strabismus in which suppression occurs secondary to the motor anomaly, microstrabismus may develop secondary to a foveal scotoma caused by uncorrected anisometropia during early infancy. With foveal function thus diminished early in life and before the fixation reflex is fully developed, he postulated that the fixation reflex may become adjusted to extrafoveal retinal elements having a higher visual function than the fovea. Such an event may lead eventually to eccentric fixation under monocular conditions and to anomalous retinal correspondence under binocular conditions.

Lang¹⁶⁸ argued against Helveston and von Noorden's restricting the definition of microtropia. He pointed out that although fixation may be eccentric in persons having microtropia, the degree of eccentricity need not necessarily coincide with the angle of anomaly. Thus he continues to group together patients with central fixation (positive cover test), eccentric fixation without identity with the angle of anomaly (positive cover test), and those in whom identity exists (negative cover test).

Epstein and Tredici⁸⁷ pointed out that microtropias do not occur exclusively with esodeviations but that there are also microexotropias that can be diagnosed only by using the 4^A test base-in.

Current Concepts and Clinical Significance

From the foregoing reports and observations, it is obvious that a large spectrum of strabismus forms exist with inconspicuously small angles and various degrees of sensorial adaptations. Whether additional attempts to further categorize such deviations are clinically useful is debatable. On theoretical grounds, one could conceive of a spectrum that ranges from normal binocular vision with bifixation at one end, to fixation disparity as defined by Ogle and coworkers,²²¹ the various manifestations of microtropia, and small-angle es-

otropia at the other end. (See also de Decker and Haase.⁷⁴) However, to force biological phenomena into an orderly and rigid scheme that satisfies the human intellect is not always possible. A certain amount of overlap and variance is more in accordance with nature's ways and will defy all such attempts. We agree with Crone⁶³ that it is more important to analyze the binocular mechanism in each patient than to set up artificial barriers by a multiplicity of terms and classifications.

For these reasons, none of the definitions and classifications of ultrasmall angles of strabismus currently in use is without flaw. For instance, the monofixational syndrome of Parks²²⁶ includes patients without manifest strabismus and with no sensory anomalies other than a unilateral foveal scotoma. Strictly speaking, this latter entity would have no place in a discussion of strabismus were it not for the fact that, in patients with essential infantile esotropia, unilateral foveal suppression under binocular conditions occurs invariably as an end state after complete surgical alignment is achieved.^{205, 225} The term *monofixation* is somewhat misleading since fixation may occur with each fovea in spite of the fact that a foveal suppression scotoma may be present. Also, the term *fixation* refers to seemingly steady maintenance of the image of the object of attention on the fovea, that is, to a motor rather than to a sensory process. Lang includes heterotropias as large as 5° in his classification of microtropia, although there are no obvious pathophysiologic or clinical differences between an esotropia of 5° or, say, 10°. Thus the borderline between microtropia as defined by Lang and a small angle esotropia is poorly defined. A small angle esotropia is said to be present when the deviation is cosmetically noticeable but not disfiguring.¹⁶⁹ Whether strabismus presents a cosmetic problem depends, among other factors, on the facial configuration of the patient since a certain angle of strabismus can be inconspicuous in one patient and cause a significant cosmetic disfigurement in another. It is therefore somewhat arbitrary when Lang refers to small angle esotropia when the deviation is between 5° and 12° and large angle strabismus when the deviation exceeds 12°.

The group singled out by Helveston and von Noorden¹²⁰ is unique in regard to completeness of sensorial adaptation, but the relationship between the degree of eccentricity of unilateral fixation and the angle of anomaly under binocular conditions cannot always be established unequivocally.¹⁹⁹

Anisometropia, though often associated with microtropia as defined by these and other authors,^{158, 256} is not a consistent finding and anisometropic amblyopia may occur without microtropia.¹¹⁰ On the other hand, the anisometropia may no longer be present when the diagnosis of microtropia is made.¹⁹⁸ The patient material published by Lang,¹⁶⁹ the patient in Case 16–7 (see below), and several other patients with *primary microtropia* and emmetropia observed by us add support to Lang's contention that primary microtropia, unrelated to anisometropia, is a distinct entity. In view of the clinical importance of ultrasmall heterotropias and the confusion in the literature to which almost everyone writing on this subject has added a share, the following synthesis appears useful.

In addition to large and small angle esodeviations with specific sensory and motor characteristics, manifest esodeviations with inconspicuously small angles also exist. We have adopted Lang's microstrabismus or microtropia as an appropriate term to describe these deviations. *Consistent findings* in such patients are amblyopia; abnormal retinal correspondence (as determined with the Bagolini striated glasses or the foveo-foveal test of Cüppers); relative scotoma on the fovea or, in the case of parafoveal fixation, the fixation point of the deviated eye (as determined with the 4^Δ base-out or base-in prism tests, the Bagolini test, or with binocular perimetry); normal or near-normal peripheral fusion with amplitudes; and defective stereoacuity (see Table 16–4). *Variable findings* include the size of the deviation, foveal or nonfoveal fixation behavior, identity between the degree of eccentric fixation and the angle of anomaly, the presence or absence of anisometropia, and positive or negative cover test results.

Microtropia is a stable condition in most patients but not a guarantee against subsequent deterioration into larger deviation as shown by many studies.^{7, 123, 291}

Diagnosis

When the cover test is negative or the fixation movement of the deviated eye is inconspicuously small so that it escapes detection by the examiner, the diagnosis of microtropia may be difficult. In all other cases the diagnosis is clearly established by a very small fixation movement (flick) of the deviated eye upon covering the fixating eye. When the cover test is negative, however, special diagnostic procedures must be used to differentiate

a microtropia with identity from nonstrabismic abnormalities causing decreased visual acuity in one eye. A cycloplegic refraction should be carried out at the beginning of such an examination since microtropia occurs frequently with anisometropic amblyopia. Examination of the fixation pattern (see Chapter 15) will establish whether foveolar or parafoveal fixation is present. The finding of nonfoveal fixation in the amblyopic eye clearly establishes the diagnosis of microtropia (Fig. 16–8). Identification of microtropia is more difficult in isometropic patients and in those with minute degrees of fixation anomalies, for the mere presence of a fixation spot scotoma, diagnosed with the Bagolini striated glasses (see p. 228), polarized visual acuity charts, or the 4^Δ base-out (see p. 218) or base-in prism cover test does not establish unequivocally whether the underlying cause is functional, as in microtropia, or organic. Likewise, stereoacuity is reduced not only with functional amblyopia but also when foveal function is reduced by organic lesions. In such patients, the foveo-foveal test of Cüppers (see p. 230) may be helpful (see Chapter 15). The finding of a minute angle of anomalous retinal correspondence clearly identifies the patient as having microtropia, even if the results of the cover test are negative or the amplitude of the fixation movement of the amblyopic eye is too small to detect when the sound eye is covered. Fusional amplitudes (on the basis of anomalous retinal correspondence) can be elicited with rotary prisms or on the amblyoscope and recordings of binocular VEPs are consistent with the presence of peripheral fusion.²⁷⁶

A microtropia should always be suspected in unilateral decrease of visual acuity for which no organic cause can be found in patients without apparent strabismus or a history of such and without significant refractive errors or anisometropia. Extensive neuro-ophthalmologic evaluations and parental fears of an intracranial lesion can be avoided by making the correct diagnosis, as shown in Case 16–7.

CASE 16–7

A 6-year-old boy was examined for a second opinion. During a routine eye examination about 1 year ago visual acuity OS was found to be decreased. Another ophthalmologist found no cause for this problem and suggested a neurologic consultation and

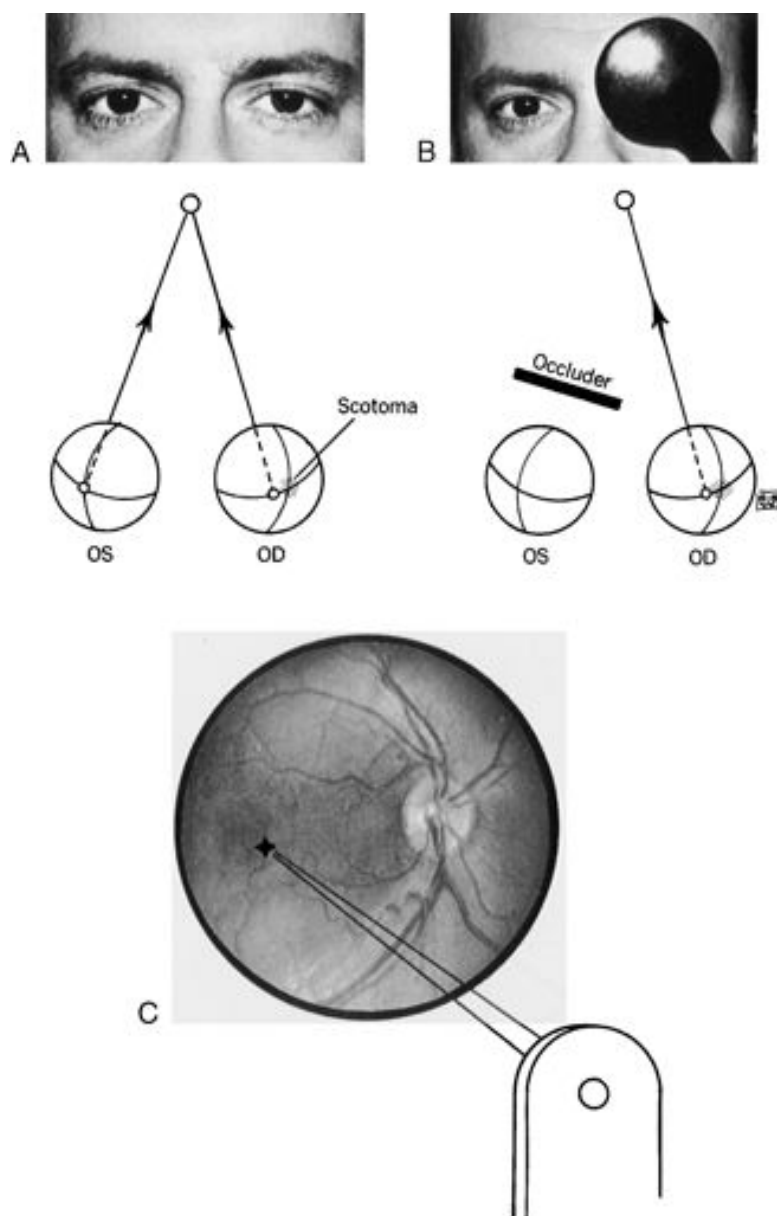


FIGURE 16-8. Microtropia with identity. *A*, Eyes appear straight. Mild amblyopia OD. The central suppression scotoma OD has led to parafoveal fixation. *B*, Cover test fails to reveal a fixation movement. OD continues to fixate with the same extrafoveal elements used for fixation when both eyes were open. *C*, Visuscope reveals fixation OD 2° to 3° nasal to and 1° below the foveola. (From Noorden GK von: *Atlas of Strabismus*, ed 4. St Louis, Mosby-Year Book, 1983.)

computed tomography scan of the skull. There was no history of strabismus. The medical history was negative. One maternal aunt had strabismus in childhood for which surgery had been performed. On examination visual acuity was 6/9 OD and 6/60 OS when tested with Snellen letters. The cover and cover-uncover tests were negative at near and distance fixation. The 4th prism test gave a scotoma response OS. Cycloplegic refraction was +1.00 sph OU. Anterior segments and fundi were normal. Examination of the fixation behavior by direct ophthalmoscopy showed steady foveolar fixation OD and unsteady parafoveal fixation with an area 2° above and nasal to the foveola OS. There was anomalous retinal correspondence with the Bagolini and foveofoveal test of Cüppers. The patient had no stereopsis on random-dot tests, and his fusional amplitudes were normal. We diagnosed a primary microtropia

and since the child had never been treated and visual acuity OS was very low, ordered total occlusion of OD for 2 months. The patient returned 2½ months later with a visual acuity of 6/9 OD and 6/15 OS. Continued occlusion treatment for another 4½ months resulted in a final visual acuity of 6½ OS.

Therapy

Microtropia in the older child or adult does not require therapy. On the contrary, we feel that treatment in such patients is ill advised, for elimination of the central scotoma may cause intractable diplopia. Such patients have comfortable and nearly normal binocular vision with good peripheral fusional amplitudes. In young children up to 6 years

of age, however, attempts should be made to treat the amblyopia. If significant anisometropia is present, we occlude the fixating eye and prescribe the full refractive correction. We have observed many patients in whom the microtropia disappeared under energetic occlusion therapy. Fixation of the amblyopic eye changed from parafoveal to central and steady, visual acuity reached a level of 6/6, retinal correspondence became normal, and stereoacuity improved from 100 to 40 seconds of arc. Other authors have made similar observations.^{47, 115, 130, 149}

The fact that microtropia, if diagnosed and treated in the young child, can be cured refutes the concept of an underlying primary congenital defect of retinal correspondence, as proposed by several authors.^{129, 163–168, 247}

Recurrent Esotropia

An unusual form of esotropia which recurs relentlessly to the same angle despite multiple operations but is fortunately rare was identified by von Noorden and Munoz²¹⁴ in 19 of 3000 patients who underwent surgery for esotropia of the essential infantile type or with an onset in early childhood. Among the factors that could conceivably cause such a condition one must consider an increase of uncorrected hypermetropia, a deep-seated anomalous retinal correspondence, nystagmus blockage by convergence, an unstable AC/A ratio, or a blind spot syndrome. None of these factors could be implicated in the patients we studied and the cause of recurrent esotropia for which we used the clinical jargon “malignant” esotropia remains unknown.

Secondary Esotropia

Sensory Esotropia

Etiology and Clinical Characteristics

Reduced visual acuity in one eye presents a severe obstacle to sensory fusion and in fact may abolish the fusion mechanism altogether. The ensuing strabismus is the direct consequence of a primary sensory deficit, and in such cases the term *sensory heterotropia* is used. Obviously, the origins of sensory esotropia are numerous, limited only by the number of pathologic conditions that can affect visual acuity in one eye. The most common

causes are anisometropia, injuries, corneal opacities, congenital or traumatic unilateral cataracts, macular lesions, and optic atrophy.

In the past it was thought that whether or not a sensory esotropia or exotropia developed depended on the age of the patient at the time of visual acuity decrease in one eye. For instance, Chavasse⁴⁰ stated that eyes that are congenitally blind or have lost vision shortly after birth diverge. Hamburger,¹⁰⁶ on the other hand, wrote that most eyes with congenital unilateral blindness or severe visual impairment in early childhood converge. There is similar disagreement in the literature as to the direction of strabismus when the onset of visual impairment occurs during later childhood or adolescence. We have analyzed the records of 121 patients with sensory heterotropia and have encountered esotropia and exotropia of almost equal frequency when the onset of visual impairment occurred at birth or between birth and 5 years of age.²⁶¹ Exotropia predominated in older children and adults (Fig. 16–9), and there was no correlation between the degree of visual impairment and the development of esotropia or exotropia. Similar observations were reported by Bielschowsky¹⁹ and by Broendstrup.²⁹ We also encountered a strikingly high prevalence of overacting inferior and superior oblique muscles in patients with sensory esodeviations or exodeviations.²⁶¹ This association, which has also been noted by other investigators,^{144, 249} does not have a satisfactory explanation at this time. A prevalence of dissociated vertical deviations in 12.5% of patients with sensory heterotropias may be explained on the basis of loss of fusion.¹⁶¹

Several authors have commented on the frequent association between unilateral visual loss from birth or with onset in early infancy, with esotropia, manifest latent nystagmus with a null in adduction, fixation preference in adduction, and a head turn toward the side of the fixating eye.^{27, 109, 117} Spielmann^{266–268} coined the term *functional monophthalmic syndrome* for this entity and suggested that these signs, together with optokinetic asymmetry, are manifestations of optomotor immaturity from lack of normal binocular input during early infancy.

It is not entirely clear why some patients become esotropic and others exotropic when they lose sight in one eye. Bielschowsky¹⁹ explained the increased incidence of sensory exotropia with advancing age as a gradual change of topographic-anatomical orbital factors in adolescence, favoring

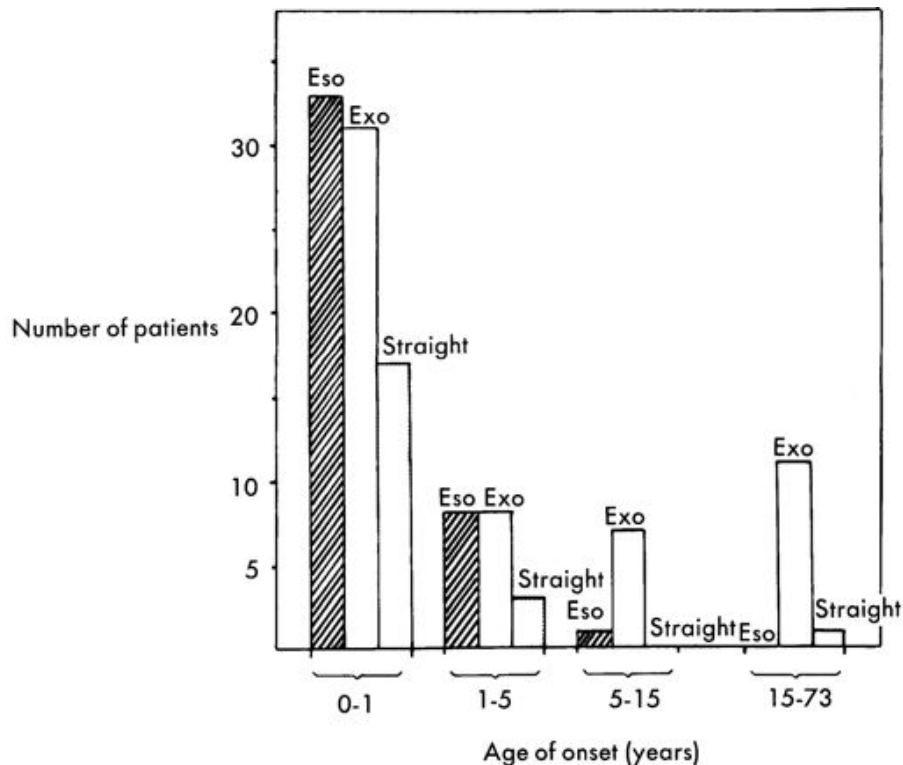


FIGURE 16-9. Frequency distribution of the type of sensory deviation as a function of the age of onset of visual loss. ESO, esotropia; EXO, exotropia. (From Sidikaro Y, Noorden GK von: Observations in sensory heterotropia. *J Pediatr Ophthalmol Strabismus* 19:12, 1982.)

divergence rather than convergence. This explanation is difficult to reconcile with the fact that the orbital axes actually converge slightly between birth and adulthood.¹⁸³ The notion that the visually impaired eye, suspended from fusional innervation, drifts into a relative position of rest determined by anatomical factors also does not explain why this position should be one of esotropia in one patient and of exotropia in another in the same age group.

Worth³⁰¹ speculated that the direction of a sensory heterotropia is determined by the refractive error of the sound eye; that is, the blind eye will diverge if the sound eye is ametropic or myopic and will converge if the sound eye is hypermetropic. This assumption was not supported by our data, which showed an equal distribution of refractive errors in various patient groups.²⁶¹ Possibly, various degrees of tonic convergence during early childhood and perhaps less forceful tonic convergence during adulthood contribute to the direction of a sensory heterotropia.⁴⁰ Sensory esotropia is usually comitant; however, we have examined patients with a long-standing sensory esotropia in whom limitation of abduction and excessive adduction were present. Forced duction tests in such patients reveal restriction of passive abduction, a

finding that must be interpreted as evidence for contracture of the medial rectus or the conjunctiva, or both, and Tenon's capsule.

The clinician must never forget that any type of esotropia, whether diagnosed early in life or at a later stage, may be sensory and could be the first clinical sign of poor visual acuity or even blindness in one eye. For this reason, we consider examination of the entire globe to be an absolutely essential part of the evaluation of all strabismic patients, regardless of how transparent the clinical situation appears. For instance, Costenbader and O'Rourke⁵⁶ described a number of children with optic atrophy in whom the chief complaint when first seen was strabismus. Ellsworth⁸⁶ reported esotropia to be the second most common presenting sign of retinoblastoma.

Therapy

Treatment usually is directed toward improving the cosmetic appearance by means of surgical correction since, in most instances, the very nature of sensory esotropia precludes restoration of binocular function. An exception to this is children with unilateral congenital or traumatic cataracts of postnatal development. In such patients, the grad-

ual onset of an esotropia heralds disruption of fusion, and cataract surgery should be performed without delay, followed by contact lens correction, occlusion treatment for the amblyopia, and eventually by strabismus surgery. The longer the deviation is allowed to persist, the less likelihood there is of binocular vision being restored after successful cataract surgery, especially in adults with acquired cataracts.²⁸⁶

When the patient is blind in one eye and therapy is aimed only at improving the cosmetic appearance, a base-out prism before the blind eye may be tried to make the deviation seem less obvious. However, most patients require surgery, and an operation should not be discouraged because of the remote chance that the eye may eventually straighten spontaneously or even become exotropic. If that occurs, additional surgery can be performed. There is no need for a patient to go through adolescence with a severe cosmetic handicap that will invariably have a negative psychological effect. In the presence of a head turn toward the side of the fixating eye (functional monophthalmic syndrome of Spielmann^{266–268}), surgery must be performed on the normal eye to normalize the head position.

Depending on the size of the deviation, we prefer to operate on the deviated eye and to perform a recession of the medial rectus muscle which may be combined with resection of the lateral rectus muscle and with an inferior oblique myectomy if this muscle is found to be overacting. An esotropia that is present only at near fixation responds well to posterior fixation of the medial rectus muscle at least 13 mm behind its insertion. If the forced duction tests are positive, a bare scleral recession of the nasal conjunctiva and Tenon's capsule should be carried out. The surgical result in sensory esotropia is less predictable than when visual acuity is normal in each eye, and adjustable sutures are helpful in improving the alignment postoperatively. Even though surgical alignment of a sensory deviation may create a stable result in many patients,⁸⁴ the esotropia may recur or a consecutive exotropia may develop years after the first operation. The surgeon is advised to inform patients of this possibility.

Consecutive Esotropia

Consecutive esotropia occurs almost exclusively iatrogenically after surgical overcorrection of an exodeviation. This complication and its manage-

ment are discussed in Chapter 17. A spontaneous consecutive esotropia, that is, a change from exotropia into esotropia without exogenous mechanical factors or an acquired paralytic component, is a most extraordinary occurrence indeed. To our knowledge only one case has been reported.⁹¹

Management of Surgical Overcorrections

The etiology, management, and prevention of overcorrections after strabismus surgery are discussed in Chapter 26. Overcorrections can sometimes be related to inadequate diagnosis and subsequent inappropriate surgical procedures. In the case of an esotropic patient, this applies specifically to disregard of an accommodative element, a high hypermetropic error, or vertical incomitance (**A** or **V** pattern). In other instances they occur without obvious cause and in spite of an appropriate amount of surgery.

The prevalence of consecutive exotropia is surprisingly low and, according to several large surveys, ranges between only 2% and 8% of all esotropes on whom surgery was performed.^{50, 300} Our own experience is in accordance with these observations.²¹⁶ These figures contrast sharply with the reported incidence of undercorrections.^{205, 259}

Except for large overcorrections with severe restriction of ocular motility, in which case disinsertion of a muscle must be considered (see Chapter 26), the treatment of consecutive exotropia is one of watchful waiting. From a functional point of view, recent data show that a surgical overcorrection actually may be more beneficial than an undercorrection. The effect of strabismus surgery on sensory adaptations, especially on the normalization of retinal correspondence, is well-known.^{151, 287} It seems that this effect can be enhanced if consecutive exotropia is allowed to persist for some time; this has led some ophthalmologists to strive intentionally for an overcorrection.^{67, 75, 133, 142, 252, 300} Even though a consecutive exotropia is far from being universally accepted as a desirable outcome of surgery for esotropia, these data show that waiting does no harm and may even be beneficial before a reoperation is considered.

The nonsurgical management of consecutive exotropia consists mainly of reduction of the spectacles correction if the patient is hypermetropic.

Although such measures may temporarily straighten the eyes, they do not eliminate the basic problem and may lead to accommodative asthenopia in older children, depending on the degree of undercorrection. Prisms base-in may be considered in older patients to eliminate diplopia.

Alternate occlusion, immediately after surgery, is sometimes effective in reducing the exotropia provided that ocular motility is normal, that is, the exotropia is not caused by excessive recession of the medial rectus muscles. We have used this approach for many years and have been moderately successful, particularly in patients without hypermetropia. As a rule, consecutive exotropia decreases with time, and should reoperation become necessary we prefer to wait at least 6 months before proceeding with it. The reader is referred to Chapter 26 for other aspects of the surgical management of overcorrections.

Esotropia Associated with Vertical Deviations

Hyperdeviations frequently are found in association with esotropia. Symptoms in each patient must be analyzed carefully since the clinical neglect of associated vertical deviations may severely jeopardize attempts to restore binocular vision. The clinical manifestations of vertical deviations are numerous. They may be comitant in all directions of gaze, incomitant and with all other characteristics of a paretic deviation, absent in primary position, manifest in lateral gaze only, or present as a dissociated vertical deviation. In each instance, one must consider whether the hyperdeviation is primary or secondary in relation to the underlying esodeviation.

Clinical Characteristics and Diagnosis

A small angle comitant hypertropia of not more than 3^Δ occurs in 50% of patients with constant esotropia and in 25% of all those with heterotropia.²⁵⁴ Ductions and versions may be essentially normal with no evidence of a paretic cyclovertical muscle. The etiology of this deviation is unknown; however, during the prism and cover test, the physician must rule out artifacts induced by oblique positioning of the prism.

Incomitant associated hyperdeviations can be placed in two categories: (1) those caused by

paresis of one of the cyclovertical muscles and (2) those caused by primary or secondary overaction of one or both inferior or superior oblique muscles. A deviation of the first type is greatest when fixating with the paretic eye in the field of action of the paretic muscle and will exhibit all characteristics consistent with a cyclovertical paresis (see Chapter 18). The degree of esotropia often is small, and in such instances the vertical deviation is primary while the esotropia is secondary to disruption of fusion by the hypertropia. We pointed out earlier in this chapter that during childhood an esodeviation is a common response to interruption of fusion.

Deviations of the second type are characterized by overaction of one or both inferior oblique muscles, usually associated with a V pattern (see Chapter 19). Such patients exhibit the characteristic elevation of the adducted eye (*strabismus sursoadductorius*; see Chapter 18), and when the involvement is bilateral, they have a large right hypertropia in levoversion and a large left hypertropia in dextroversion. With the eyes in primary position, the hypertropia may be small or nonexistent. Overaction of the superior oblique muscles, usually associated with an A pattern, is less common in esotropes. Overaction of one or both inferior or superior oblique muscles may be secondary to weakness of their ipsilateral antagonists, or apparently primary if dysfunction of the antagonists cannot be established, in which case the generic term *elevation* or *depression in adduction* is preferable. As pointed out earlier in this chapter apparent overaction of the inferior obliques, encountered frequently in patients with essential infantile esotropia, must be distinguished from a dissociated deviation.

The etiology and differential diagnosis of elevation in adduction is discussed in Chapter 18. In this chapter it is necessary to say only that some investigators have interpreted the apparently primary overaction of the inferior oblique muscles in patients with horizontal strabismus as being secondary to the horizontal deviation since the oblique dysfunction may disappear after horizontal surgery.^{21, 51}

Brief mention must be made of the hyperdeviations that occur, often to the great chagrin of the surgeon, after surgery for esotropia has been performed. In such cases, it is commonly believed that while reinserting one or both of the horizontal rectus muscles the surgeon inadvertently selected a new site either above or below the horizontal

meridian of the globe. Foster and Pemberton,⁹⁴ however, reported that purposely raising or lowering the insertion of the horizontal rectus muscles produces only a relatively small hyperdeviation (up to 11^A). Many surgeons actually use this effect of vertical transposition of the horizontal muscles to correct small degrees of associated hyperdeviation (see Chapter 25).

Scobee²⁵⁴, p. 387 also mentioned the possibility that hypertropia, when occurring postoperatively, actually may have been present before surgery but was not apparent on routine examination. He postulated that a hyperdeviation in association with an esodeviation is a manifestation of mechanical superiority of the inferior over the superior oblique muscle when the eye is in extreme adduction and cannot fixate, the fixation object being hidden by the nose. Against this view one may argue that the inferior or superior oblique muscles do not necessarily overact when the fixation object is no longer visible.

Finally, when large degrees of hypertropia occur postoperatively, consideration must always be given to the fact that surgery may have been performed erroneously on a vertical rather than on a horizontal muscle. How to avoid this very perturbing but by no means unprecedented complication is discussed in Chapter 26.

Therapy

In patients with primary paretic vertical deviations in whom esotropia develops secondary to disruption of fusion, therapy is nonsurgical (prisms) or surgical, depending on the amount and type of deviation (see Chapter 20). In such cases, we prefer first to correct the vertical deviation and after surgery to reevaluate the need for additional correction of the horizontal deviation.

In patients in whom one or both inferior oblique muscles are overacting, myectomy of the oblique(s) is combined with horizontal muscle surgery (see also therapy of V esotropia, Chapter 19).

REFERENCES

1. Abraham S: Present status of miotic therapy in nonparalytic convergent strabismus. *Am J Ophthalmol* 51:1249, 1961.
2. Akman A, Dayanur V, Sanac A, Kansu T: Acquired esotropia as presenting sign of craniocervical junction anomalies. *Neuro Ophthalmol* 15:311, 1995.
3. Anderson WD, Lubow M: Astrocytoma of the corpus callosum presenting with acute comitant esotropia. *Am J Ophthalmol* 69:594, 1970.
4. Apers R: Réponse à M. von Noorden. *Bull Soc Belge Ophthalmol* 221/222:269, 1987.
5. Archer SM, Helveston EM, Miller KK, Ellis FD: Stereopsis in normal infants and infants with congenital esotropia. *Am J Ophthalmol* 101:591, 1986.
6. Arruga A: The time factor in strabismus surgery. In Luntz HM, ed: *Proceedings of the First South African International Ophthalmological Symposium*. London, Butterworths, 1969, p 67.
7. Arthur BW, Smith JT, Scott WE: Long-term stability of alignment in the monofixation syndrome. *J Pediatr Ophthalmol Strabismus* 26:224, 1989.
8. Astle WF, Miller SJ: Acute esotropia: A sign of intracranial disease. *Jpn J Ophthalmol* 29:151, 1994.
9. Atkinson J: Development of optokinetic nystagmus in the human infant and monkey infant. In Freeman RD, ed: *Developmental Neurobiology of Vision*. New York, Plenum Press, 1979, p 277.
10. Aust W: Indikationen zur Frühbehandlung schielender Kinder. *Klin Monatsbl Augenheilkd* 154:686, 1959.
11. Baekeland L, Boschi A, Hoffmann D, Spiritus M: Ocular torticollis without normal binocular vision-head tilts. In Lenk-Schäfer M, ed: *Orthoptic Horizons. Transactions of the Sixth International Orthoptic Congress*, Harrogate, England, LIPS 1987, p 184.
12. Baker FH, Grigg P, Noorden GK. von: Effects of visual deprivation and strabismus on the response of neurons in the visual cortex of the monkey including studies on the striate and prestriate cortex in the normal animal. *Brain Res* 66:185, 1974.
13. Baker JD, De Young-Smith M: Accommodative esotropia following surgical correction of congenital esotropia, frequency and characteristics. *Graefes Arch Clin Exp Ophthalmol* 226:175, 1988.
14. Baker JD, Parks MM: Early onset accommodative esotropia. *Am J Ophthalmol* 90:11, 1980.
15. Barlow HB, Blakemore C, Pettigrew JD: The neural mechanism of binocular depth discrimination. *J Physiol (Lond)* 193:327, 1967.
16. Bérard PV: "Early-delayed" treatment of strabismus versus late treatment. In Ferrer ON, ed: *Ocular Motility*. *Int Ophthalmol Clin* 11:103, 1971.
17. Bérard PV, Reydy R, Bérard P V Jr: Surgery of accommodative esotropia. In Lenk-Schäfer M, ed: *Orthoptic Horizons, Transactions of the Sixth International Orthoptic Congress*, Harrogate, England, LIPS, 1987, p 396.
18. Berke RN: Requisites for postoperative third degree fusion. *Trans Am Acad Ophthalmol Otolaryngol* 62:38, 1958.
19. Bielschowsky A: Über die relative Ruhelage der Augen. *Ber Vers Dtsch Ophthalmol Ges.* 34:67, 1913.
20. Bielschowsky A: Das Einwärtsschielen der Myopen. *Ber Dtsch Ophthalmol Ges* 43:245, 1922.
21. Bielschowsky A: *Lectures on Motor Anomalies*. Hanover, NH, Dartmouth College Publications, 1943/1956.
22. Biglan AW, Gan XL: Experience with botulinum A toxin (oculinum) in the treatment of strabismus. *Contemp Ophthalmol. Forum* 5:230, 1987.
23. Birch EE, Stager DR: Monocular acuity and stereopsis in essential infantile esotropia. *Invest Ophthalmol Vis Sci* 26:1624, 1985.
24. Birch E, Stager D, Everett MMF: Random dot stereoacuity following surgical correction of infantile esotropia. *J Pediatr Ophthalmol Strabismus* 32:231, 1995.
25. Birch E, Stager D, Wright K, Beck R: The natural history of infantile esotropia during the first six months of life. *J Pediatr Ophthalmol Strabismus* 2:325, 1998.
26. Bixenman WW, Laguna JF: Acquired esotropia as initial manifestation of Arnold-Chiari malformation. *J Pediatr Ophthalmol Strabismus* 24:83, 1987.
27. Bourron-Madignier M: Unilateral congenital organic amblyopia and manifest-latent nystagmus. In Kaufmann H,

- ed: Transactions of the 16th Meeting of the European Strabismological Association, Giessen, Germany, 1987, p 235.
28. Bourron-Madignier M, Ardoin ML, Cyprès C, Vettard S: Study of optokinetic nystagmus in children. In Lenk-Schäfer M, ed: *Orthoptic Horizons*, Transactions of the Sixth International Orthoptic Congress, Harrogate, England, LIPS, 1987, p 134.
 29. Broendstrup P: The squinting position of weak-sighted eyes. *Acta Ophthalmol* 20:386, 1944.
 30. Brown EVL: Net average yearly changes in refraction of atropinized eyes from birth to beyond middle life. *Arch Ophthalmol* 19:719, 1938.
 31. Brown EVL, Kronfeld PC: Refractive curve in the U.S.A. with special reference to changes in the first two decades. *C R Concilium Ophthalmol* 13:87, 1929.
 32. Bryer J: Aetiology and treatment of small convergent deviations associated with a low degree of hypermetropia (letter). *Br Orthopt J* 10:85, 1953.
 33. Burian HM: Motility clinic: Sudden onset of comitant convergent strabismus. *Am J Ophthalmol* 28:407, 1945.
 34. Burian HM: Hypermetropia and esotropia. *J Pediatr Ophthalmol* 9:135, 1972.
 35. Burian HM, Miller JE: Comitant convergent strabismus with acute onset. *Am J Ophthalmol* 45:55, 1958.
 36. Calcutt C, Murray ADN: Untreated essential infantile esotropia: Factors affecting the development of amblyopia. *Eye* 12:167-172, 1998.
 37. Campos EC: Eradicating amblyopia before surgery (letter). *J Pediatr Ophthalmol Strabismus* 35:6, 1998.
 38. Campos EC: Essential infantile esotropia (ESA Lecture). In Spiritus M, ed: *Transactions of the 25th Meeting of the European Strabismological Association*. Buren, The Netherlands, Aeolus Press, 2000, p. 4.
 39. Cantolino SJ, Noorden GK von: Heredity in microtropia. *Arch Ophthalmol* 81:753, 1969.
 40. Chavasse FB: *Worth's Squint or the Binocular Reflexes and the Treatment of Strabismus*, ed 7. London, Baillière Tindall & Cox, 1939, p 519.
 41. Chettibi A, Berkani M: Traitement chirurgical du strabisme accommodatif. A propos de 100 cas de ésoptropie. *Ophthalmologie* 2:303, 1988.
 42. Ciancia A: La esotropia en el lactante, diagnostico y tratamiento. *Arch Chil Oftalmol* 9:117, 1962.
 43. Ciancia A: On infantile esotropia with nystagmus in abduction. *J Pediatr Ophthalmol Strabismus* 32:280, 1995.
 44. Clark AC, Nelson LB, Simon JW, et al: Acute acquired comitant esotropia. *Br J Ophthalmol* 73:636, 1989.
 45. Clark RA, Miller JM, Rosenbaum AL, Demer JL: Heterotonic rectus muscle pulleys or oblique muscle dysfunction? *Am Assoc Pediatr Ophthalmol Strabismus* 2:17-25, 1998.
 46. Clark WN, Noel LP: Vanishing essential infantile esotropia. *Can J Ophthalmol* 17:100, 1982.
 47. Cleary M, Houston CA, McFazdean R, Dutton GN: Recovery of microtropia: Implications for etiology and neurophysiology. *Br J Ophthalmol* 82:225, 1998.
 48. Coats DK, Paysse EA: Rectus muscle recession and resection without scleral sutures. *J Am Assoc Pediatr Ophthalmol Strabismus* 2:230, 1998.
 49. Coats DK, Avilla CW, Paysse E, et al: Early onset refractive accommodative esotropia. *J Am Assoc Pediatr Ophthalmol Strabismus* 2:275, 1998.
 50. Cooper E: The surgical management of secondary exotropia. *Trans Am Acad Ophthalmol Otolaryngol* 65:595, 1961.
 51. Cords R: Strabismus surso-adductorius. *Ber Dtsch Ophthalmol Ges* 43:158, 1922.
 52. Costenbader FD: Management of convergent strabismus. In Allen JH, ed: *Strabismus Ophthalmic Symposium I*. St Louis, Mosby-Year Book, 1950, p 339.
 53. Costenbader FD: Clinical course and management of esotropia. In Allen JH, ed: *Strabismus Ophthalmic Symposium II*. St Louis, Mosby-Year Book, 1958, p 331.
 54. Costenbader FD: Essential infantile esotropia. *Trans Am Ophthalmol Soc* 59:397, 1961.
 55. Costenbader FD: Sensorimotor examination of infants. In Arruga A, ed: *International Strabismus Symposium*. University of Giessen, Germany, 1966. Basel, S Karger 1968, p 134.
 56. Costenbader FD, O'Rourke TR: Optic atrophy in childhood. *J Pediatr Ophthalmol* 5:77, 1968.
 57. Costenbader FD, Ing M, Bair RV, Parks MM: Symposium: Essential infantile esotropia. *Am Orthopt J* 18:5, 1968.
 58. Crawford MLJ, Noorden GK von: The effects of short-term experimental strabismus on the visual system in *Macaca mulatta*. *Invest Ophthalmol Vis Sci* 18:496, 1979.
 59. Crawford MLJ, Smith EL, Harwerth RS, Noorden GK von: Stereoblind monkeys have few binocular neurons. *Invest Ophthalmol Vis Sci* 25:779, 1984.
 60. Crawford MLJ, Noorden GK von, Meharg LS et al: Binocular neurons and binocular function in monkeys and children. *Invest Ophthalmol Vis Sci* 24:491, 1983.
 61. Crone RA: Alternating hyperphoria. *Br J Ophthalmol* 38:591, 1954.
 62. Crone RA: Heterophoria. II. Fusion and convergence. *Graefes Arch Clin Exp Ophthalmol* 177:66, 1969.
 63. Crone RA: From orthophoria to microtropia. *Br Orthopt J* 26:45, 1969.
 64. Crone RA: A new theory about heterophoria. *Ophthalmologica* 162:199, 1971.
 65. Cüppers C: Grenzen und Möglichkeiten der pleoptischen Therapie. In Hollwich F, ed: *Schielen-Pleoptik-Orthoptik-Operation*. Stuttgart, Ferdinand Enke Verlag, 1961, p 32.
 66. Cüppers C: Die Penalisation. *Schielbehandlung* 3:126, 1971.
 67. Dankner SR, Mash AJ, Jampolsky, A: Intentional surgical overcorrection of acquired esotropia. *Arch Ophthalmol* 96:1848, 1978.
 68. Dawson ELM, Marshman WE, Adams GGW: The role of botulinum toxin A in acute-onset esotropia. *Ophthalmology* 106:1727, 1999.
 69. de Decker W: Constant or apparently congenital esotropia? *Invest Ophthalmol* 6:61, 1982.
 70. de Decker W: The Fadenoperation. In Lennerstrand G, Zee DS, Keller EL, eds: *Functional Basis of Ocular Motility Disorders*. Wenner-Gren Symposium Series, vol 37. Oxford, Pergamon Press, 1982, p 173.
 71. de Decker W: Heterotropie (manifest strabismus). In Kaufmann H, ed: *Strabismus*. Stuttgart, Ferdinand Enke Verlag, 1986, p 141.
 72. de Decker W: Langzeitresultate früher Fadenoperationen bei frühkindlichem Innenschielen. *Z Prakt Augenheilkd* 18:257, 1997.
 73. de Decker W, Dannheim-de Decker E: Unbeachtete Zwangshaltungen beim frühkindlichen Schielsyndrom. *Klin Monatsbl Augenheilkd* 215:95, 1999.
 74. de Decker W, Haase W: Subnormales Binokularsehen—Versuch einer Einteilung des Mikrostrabismus. *Klin Monatsbl Augenheilkd* 169:182, 1976.
 75. de Decker W, Holzki U, Lauber V: Behandlung der anomalen Korrespondenz durch artifizielle Sekundärdivergenz. *Ophthalmologica* 157:142, 1969.
 76. Deller M: Surgery of fully accommodative esotropia: Treatment, alternative or imposture? In Kaufmann H, ed: *Transactions of the 20th Meeting of the European Strabismological Association*. Brussels, Gahmig Press, 1992, p 167.

77. Deller M, Brack B: Erste Bilanz der modernen Schielbehandlung. *Klin Monatsbl Augenheilkd* 155:712, 1969.
78. Dell'Osso LF: Congenital, latent or manifest-latent nystagmus. Similarities, difference and relation to strabismus. *Jpn J Ophthalmol* 29:351, 1985.
79. Demer JL, Noorden GK von: Optokinetic asymmetry in esotropia. *J Pediatr. Ophthalmol Strabismus* 25:286, 1988.
80. Doden W: Neue Gesichtspunkte zur Ätiologie des Schielens. *Klin Monatsbl Augenheilkd* 132:892, 1958.
81. Doden W, Adams W: Elektronystagmographische Ergebnisse der Prüfung des optisch-vestibulären Systems bei Schielenden. *Ber Dtsch Ophthalmol Ges* 60:316, 1957.
82. Duffin EW: Practical Remarks on the New Operation for the Cure of Strabismus or Squinting. London, John Churchill, 1840, p 77.
83. Dyer JA: Nonsurgical treatment of esotropia. In Symposium on Strabismus. Transactions of the New Orleans Academy of Ophthalmology. St. Louis, Mosby-Year Book, 1971, p. 154.
84. Edelman PM, Brown M: The stability of surgical results in patients with deep amblyopia. *Am Orthopt J* 27:103, 1977.
85. Eizenman M, Westall CA, Geer I et al: Electrophysiological evidence of cortical fusion in children with early-onset esotropia. *Invest Ophthalmol Vis Sci* 40:354, 1999.
86. Ellsworth RM: The practical management of retinoblastoma. *Trans Am Ophthalmol Soc* 78:478, 1969.
87. Epstein DL, Tredici TJ: Use of the four-diopter base-in prism test in microexotropia. *Am J Ophthalmol* 73:340, 1972.
88. Esswein MB, Noorden GK von, Avilla CW: Hereditary maldevelopment of visual motion pathway not found. *Invest Ophthalmol Vis Sci* 35(suppl):1829, 1994.
89. Fawcett S, Raymond JE, Astle WF, Skov CM: Anomalies of motion perception in infantile esotropia. *Invest Ophthalmol Vis Sci* 39:724, 1998.
90. Fells P, Bérard PV, Gobin M, et al: Symposium on the management of fully accommodative esotropia. In Campos C, ed: Strabismus and Ocular Motility Disorders. Proceedings of the Sixth Meeting of the International Strabismological Association (ISA), Surfer's Paradise, Australia. London, Macmillan, 1991, p 269.
91. Fitton MH, Jampolsky A: A case report of spontaneous consecutive esotropia. *Am Orthopt J* 14:144, 1964.
92. Flynn JT: Vestibulo-optokinetic interaction in strabismus. *Am Orthopt J* 32:36, 1982.
93. Flynn JT, Grundmann S, Mashikian M: Binocular suppression of scotoma: Its role in phorias and intermittent tropias. *Am Orthopt J* 20:54, 1970.
94. Foster J, Pemberton EC: The effect of operative alterations in the height of the external rectus insertion. *Br J Ophthalmol* 30:88, 1946.
95. Franceschetti A: Le strabisme concomitant aigu. *Ophthalmologica* 123:219, 1952.
96. Franceschetti A, Bischler V: Strabisme convergent concomitant aigu chez l'adulte. *Confinia Neurol* 8:380. 1947/1948.
97. Friedman Z, Neumann E, Hyams SW, Peleg B: Ophthalmic screening of 38,000 children age 1 to 2½ years in child welfare clinics. *J Pediatr Ophthalmol Strabismus* 17:261, 1980.
98. Friedrich D, de Decker W: Prospective study of the development of strabismus during the first 6 months of life. In Lenk-Schäfer M, ed: Orthoptic Horizons, Transactions of the Sixth International Orthoptic Congress, Harrogate, England, LIPS 1987, p 21.
99. Gittoes-Davies R: An examination of the aetiology and treatment of small convergent deviations, associated with a low degree of hypermetropia. *Br Orthopt J* 8:71, 1951.
100. Gobin MH: La vision binoculaire après correction chirurgicale du strabisme accommodatif. *Bull Mem Soc. Fr Ophthalmol* 96:95, 1985.
101. Gobin MH: Longterm results of the surgical correction of accommodative squint. In Lenk-Schäfer M, ed: Orthoptic horizons. Transactions of the Sixth International Orthoptic Congress, Harrogate, England, LIPS, 1987, p 403.
102. Good WV, da Sa LC, Lyons CJ, Hoyt CS: Monocular visual outcome in untreated early onset esotropia. *Br J Ophthalmol* 77:492, 1993.
103. Graefe A von: Über die von Myopie abhängige Form convergirenden Schielens und deren Heilung. *Graefes Arch Clin Exp Ophthalmol* 10:156, 1864.
104. Graham RA: Epidemiology of strabismus. *Br J Ophthalmol* 58:224, 1974.
105. Gross SA, Esswein MB, Goldberg J, Noorden GK von: Asymmetric optokinetic nystagmus and pursuit in monocular patients. *Invest Ophthalmol Vis Sci* 35(suppl):1829, 1993.
106. Hamburger FA: Stellungsanomalien. In Velhagen K, ed: *Der Augenarzt*, vol 3. Stuttgart, Georg Thieme, 1960, p 88.
107. Happe W: Long-term results after bimedial posterior fixation sutures for infantile esotropia. *Strabismus* 5:117, 1997.
108. Harcourt B: Ophthalmic complications of meningomyelocele and hydrocephalus in children. *Br J Ophthalmol* 52:670, 1968.
109. Harcourt B, Spencer F: Manifest latent nystagmus affecting patients with unioocular congenital nystagmus. In Gregersen E, ed: Transactions of the European Strabismological Association, Copenhagen, 1984, p 259.
110. Hardman Lea SJ, Snead MP, Loades J, Rubinstein MP: Microtropia versus bifoveal fixation in anisometropic amblyopia. *Eye* 5:576, 1991.
111. Havertape SA, Whitfill CR, Cruz OA: Early-onset accommodative esotropia. *J Pediatr Ophthalmol Strabismus* 36:69, 1999.
112. Hayashi T, Iwashige H, Maruo T: Clinical features and surgery for acquired progressive esotropia associated with severe myopia. *Acta Ophthalmol Scand* 77:66, 1999.
113. Haynes H, White B, Held R: Visual accommodation in human infants. *Science* 148:528, 1965.
114. Held R: Normal visual development and its deviations. In Lennerstrand G, Noorden GK von, Campos E, eds: Strabismus and Amblyopia. Experimental Basis for Advances in Clinical management. London, Macmillan, 1988, p 247.
115. Helveston EM: Personal communication, 1973.
116. Helveston EM: Dissociated vertical deviation: A clinical and laboratory study. *Trans Am Ophthalmol Soc* 78:734, 1981.
117. Helveston EM: Unilateral esotropia after enucleation in infancy. *Am J Ophthalmol* 100:96, 1985.
118. Helveston EM: The 19th Annual Frank Costenbader Lecture—The origins of congenital esotropia. *J Pediatr Ophthalmol Strabismus* 30:215, 1993.
119. Helveston EM: The etiology of essential infantile (congenital) esotropia, In Lennerstrand G, Ygge J (eds:) Advances in Strabismus Research. Basic and Clinical Aspects. London, Portland Press, 2000, p 135.
120. Helveston EM, Noorden GK von: Microtropia: A newly defined entity. *Arch Ophthalmol* 78:272, 1967.
121. Helveston EM, Ellis FD, Schott J, et al: Surgical treatment of congenital esotropia. *Am J Ophthalmol* 96:218, 1983.
122. Helveston EM, Neely DF, Stidham DB, et al: Results of early alignment of congenital esotropia. *Ophthalmology* 106:1716, 1999.
123. Hiles DA, Watson A, Biglan AW: Characteristics of es-

- sential infantile esotropia following early bimedial rectus recession. *Arch Ophthalmol* 98:697, 1980.
124. Hoffman KP: Neural basis for changes of the optokinetic reflex in animals and men with strabismus and amblyopia. In Lennerstrand G, Noorden GK von, Campos E, eds: *Strabismus and Amblyopia*, London, Macmillan, 1988, p 89.
 125. Hoff-van Duin J van: Early and permanent effects of monocular deprivation on pattern discrimination and visomotor behavior in cats. *Brain Res* 111:261, 1976.
 126. Hoyt CS: Acute onset concomitant esotropia: When is it a sign of serious neurological disease? *Br J Ophthalmol* 79:498, 1995.
 127. Holland G: Fehldiagnose bei bestehender Schielamblyopie. *Klin Monatsbl Augenheilkd* 139:287, 1961.
 128. Holland G: Über den akuten Strabismus convergens concomitans. *Klin Monatsbl Augenheilkd* 140:373, 1962.
 129. Holland G: Die anomale Korrespondenz als erworbene, bzw. angeborene, zum Teil familiär auftretende Anomalie. *Ber Dtsch Ophthalmol Ges* 65:471, 1964.
 130. Houston CA, Cleary M, Dutton G, McFadzean RM: Clinical characteristics of microtropia—is microtropia a fixed phenomenon? *Br J Ophthalmol* 823:219, 1998.
 131. Hoyt CS: Abnormalities of the vestibulo-ocular response in congenital esotropia. *Am J Ophthalmol* 93:704, 1982.
 132. Hubel DH, Wiesel TN: Binocular interaction in striate cortex of kittens reared with artificial squint. *J Neurophysiol* 28:1041, 1965.
 133. Hugonnier R: The influence of the operative overcorrection of an esotropia on abnormal retinal correspondence. In Arruga A, ed: *International Strabismus Symposium*. University of Giessen, Germany, 1966. Basel, S Karger, 1968, p 307.
 134. Hugonnier R, Clayette-Hugonnier S: Strabismus, Heterophoria, Ocular Motor Paralysis, Clinical Ocular Muscle Imbalance. Translated and edited by Véronneau-Troutman S. St Louis, Mosby-Year Book, 1969.
 135. Hugonnier R, Magnard P: Les déséquilibres oculomoteur observés en cas de myopie forte. *Ann Ocul* 202:713, 1969.
 136. Ing MR: Early surgical alignment for congenital esotropia. *Ophthalmology* 90:132, 1983.
 137. Ing MR: Botulinum alignment for congenital esotropia. *Ophthalmology* 100:318, 1993.
 138. Ing MR: Outcome study of surgical alignment before six months of age for congenital esotropia. *Ophthalmology* 102:2041, 1995.
 139. Ing M, Costenbader FD, Parks MM, Albert DG: Early surgery for congenital esotropia. *Am J Ophthalmol* 61:1419, 1966.
 140. Ingram RM, Walker C, Wilson JM, et al: A first attempt to prevent amblyopia and squint by spectacle correction of abnormal refractions from age 1 year. *Br J Ophthalmol* 69:851, 1985.
 141. Irvine SR: Amblyopia ex anopsia. *Trans Am Ophthalmol Soc* 46:527, 1948.
 142. Jacobi KW: Das Verhalten der Netzhautkorrespondenz bei sekundärem Strabismus divergens. *Klin Monatsbl Augenheilkd*. 154:193, 1969.
 143. Jampolsky A: Differential diagnosis and management of small degree esotropia and convergent fixation disparity. *Am J Ophthalmol* 41:825, 1956.
 144. Jampolsky A: Bilateral anomalies of the oblique muscles. *Trans Am Acad Ophthalmol Otolaryngol* 61:689, 1957.
 145. Jampolsky A, Noorden GK von, Spiritus M.: Chirurgie inutile pratiquée en cas d'esotropie réfractive accommodative pure (letter). *J Fr Ophtalmol* 14:1, 1991.
 146. Kaufmann H: Augenmuskeloperationen. In Kaufmann H, de Decker W, Friedburg D, et al, eds: *Strabismus*. Stuttgart, Ferdinand Enke Verlag, 1995, p 634.
 147. Kaufmann H, and Kolling HG: Ergebnisse der Fadenoperation nach Cüppers. *Klin Monatsbl Augenheilkd* 180:37, 1982.
 148. Keenan JM, Willshaw HE: Outcome of strabismus surgery in congenital esotropia. *Br J Ophthalmol* 76:342, 1992.
 149. Keiner EC: Spontaneous recovery in microstrabismus. *Ophthalmologica* 177:280, 1978.
 150. Kettesy A: Die Brille als Heilmittel des Schielens. *Klin Monatsbl Augenheilkd* 161:160, 1972.
 151. Knapp P: Surgical orthophoria. In Arruga A, ed: *International Strabismus Symposium*. University of Giessen, Germany 1966. Basel, S Karger 1968, p 302.
 152. Knapp P: Personal communication, 1978.
 153. Kommerell G: Beziehung zwischen Strabismus und Nystagmus. In *Augenbewegungsstörungen, Neurophysiologie und Klinik*. Munich, JF Bergmann, 1978, p 377.
 154. Kommerell G: The pathophysiology of infantile strabismus. In Kaufmann H, ed: *Transactions of the 16th Meeting of the European Strabismological Association*, Giessen, Germany, 1987, p 47.
 155. Kommerell G: The relationship between infantile strabismus and latent nystagmus. *Eye* 10:274, 1996.
 156. Kommerell G, Mehdorn E: Is an optokinetic defect the cause of congenital nystagmus? In Lennerstrand G, Zee DS, Keller EL, eds: *Functional Basis of Ocular Motility Disorders*, Oxford, Pergamon Press, 1982, p 159.
 157. Kommerell G, Ullrich D, Gilles U, Bach M: Asymmetry of motion VEP in infantile strabismus and in central vestibular nystagmus. *Doc Ophthalmol* 89:373, 1995.
 158. Krzystkova K, Mirkiewicz-Sieradzka M: Niedowidzenie bez zesa. *Klin Oczna* 37:227, 1967.
 159. Kushner BJ: Binocular field expansion in adults after surgery for esotropia. *Arch Ophthalmol* 112:639, 1994.
 160. Kushner BJ, Morton GV: A randomized comparison of surgical procedures for essential infantile esotropia. *Am J Ophthalmol* 98:50, 1984.
 161. Kutluk S, Avilla CW, Noorden GK von: The prevalence of dissociated vertical deviation in patients with sensory heterotropia. *Am J Ophthalmol* 119:744, 1995.
 162. Lam GC, Repka MX, Guyton DL: Timing of amblyopia therapy relative to strabismus surgery. *Ophthalmology* 100:1751, 1993.
 163. Lang J: Über die Amblyopie ohne Schielen und bei unauffälligem Schielwinkel. *Ophthalmologica* 141:429, 1961.
 164. Lang J: Die Bedeutung des primären Mikrostrabismus für die Entstehung des Schielens. *Klin Monatsbl Augenheilkd* 151:352, 1967.
 165. Lang J: Der kongenitale oder frühkindliche Strabismus. *Ophthalmologica* 154:201, 1967.
 166. Lang J: Evaluation in small angle strabismus or microtropia. In Arruga A, ed: *International Strabismus Symposium*, University of Giessen, Germany 1966. Basel, S. Karger, 1968, p 219.
 167. Lang J: Squint dating from birth or with early onset. *The First International Congress of Orthoptists*. St Louis, Mosby-Year Book, 1968, p 231.
 168. Lang J: Microtropia. *Arch Ophthalmol* 81:758, 1969.
 169. Lang J: Mikrostrabismus, ed 2. Bücherei des Augenarztes, No. 62. Stuttgart, Ferdinand Enke Verlag, 1982.
 170. Lang J: A new hypothesis on latent nystagmus and on the congenital squint syndrome. *Doc Ophthalmol* 32:83, 1982.
 171. Lang J: Normosensorial late convergent strabismus. In Campos E, ed: *Transactions of the Fifth Meeting of the International Strabismological Association (ISA)*, Rome, 1986, p 536.
 172. Lang J: Congenital or infantile, that is the question, *Binocular Vision* 3:116, 1988.

173. Lang J: Historische und aktuelle Aspekte der Stereopsis (Goldmann Lecture). *Klin Monatsbl Augenheilkd* 218:280, 2001.
174. Law FW: Squint operations and binocular function. *Trans Am Acad Ophthalmol Otolaryngol* 58:546, 1954.
175. Leahey BD: Criteria for early surgical correction of concomitant esotropia in infants and children. *Trans Am Acad Ophthalmol Otolaryngol* 58:106, 1960.
176. Leitch RJ, Burke JP, Strachan IM: Convergence excess esotropia treated surgically with fadenoperation and medial rectus muscle recessions. *Br J Ophthalmol* 74:278, 1990.
177. Lewis A, Kline LB, Sharpe JA: Acquired esotropia due to Arnold-Chiari I malformation. *J Neuro Ophthalmol* 16:49, 1996
178. Lewis TL, Maurer D, Brent HP: Optokinetic nystagmus in children treated for bilateral cataracts. In Groner R, McConkie GW, Menz C, eds: *Eye Movements and Human Information Processing*. Amsterdam, Elsevier, 1985, p 85.
179. Lobstein-Henry Y: Avantages et inconvénients du traitement chirurgical différé. *Doc Ophthalmol* 23:625, 1967.
180. Lyle TK: The time to operate. In *First international Congress of Orthoptists*. St Louis, Mosby-Year Book, 1968, p 129.
181. Lyle KT, Foley J: Subnormal binocular vision with special reference to peripheral fusion. *Br J Ophthalmol* 39:474, 1959.
182. Magoon EH, Scott AB: Botulinum toxin chemotherapy in infants and children: An alternative to incisional strabismus surgery. *J Pediatr Ophthalmol Strabismus* 110:119, 1987.
183. Mann I: *The Development of the Human Eye*. London, British Medical Association, 1949, p 274.
184. Marlow FW: Prolonged monocular occlusion as a test for the muscle balance. *Am J Ophthalmol* 4:238, 1921.
185. Martens TG: Remarks on fixation disparity. *Am Orthopt J* 20:68, 1970.
186. Mein J: The optokinetic nystagmus response in early onset strabismus. In Boschi MC, Frosini R, eds: *Strabismus. Proceedings of the International Symposium on Strabismus*, Florence, Italy, 1982, pp 21–23.
187. Meltzer U, Romem M: Nonaccommodative convergence excess. In Nemet P, Weiss JB, eds: *International Symposium on Strabismus and Amblyopia*, Tel Aviv, 1985. *Acta Strabologica CERES* 31,
188. Meyer K, Breitschwerdt H, Kolling GH, Simonsz HJ: The early vs late infantile strabismus surgery study: Do sources for bias exist in this non-randomized trial? *Br J Ophthalmol* 82:934, 1998.
189. Mohindra O, Zwaan J, Held R, et al: Development of acuity and stereopsis in infants with esotropia. *Ophthalmology* 92:691, 1985.
190. Molnar S: Some remarks on “antistrabismic preventive action” by Karpowicz on the ground of mass determination of refractive power in prematures and babies. *Szemeszet* 98:157, 1961. [Abstracted *Am J Ophthalmol* 53:180, 1962.]
191. Moore S: The natural course of esotropia. *Am Orthopt J* 21:80, 1971.
192. Mühlendyck H: Symptoms and treatment in hypoaccommodation cases. In Nemet P, Weiss JB, eds: *International Symposium on Strabismus and Amblyopia*, Tel Aviv, 1985, *Acta Strabologica, CERES* 25.
193. Mühlendyck H: Reading disorders in the case of juvenile accommodation disturbance. Presented at the 18th Conference of Reading and Reading Disorders, Rodin Remediation, Bern, August 26–29, 1991.
194. Mühlendyck H, Goerd J: Effect of bifocals on accommodation rate in hypoaccommodatives, In Spiritus M, ed: *Transactions of the 22nd Meeting of the European Strabismological Association*. Buren, The Netherlands, Aelius Press, 1996, p 101.
195. Murray ADN, Calcutt C: The incidence of amblyopia in longstanding untreated essential infantile esotropia. In Campos E, ed: *Strabismus and Ocular Motility Disorders*. London, Macmillan, 1990, p 45.
196. Naegele JR, Held R: The postnatal development of monocular optokinetic nystagmus in infants. *Vision Res* 22:341, 1982.
197. Nixon RB, Helveston EM, Miller K, et al: Incidence of strabismus in neonates. *Am J Ophthalmol* 100:798, 1985.
198. Noorden GK von: Mikrostrabismus. *Wiss Z Karl-Marx-Universität Leipzig* 18:242, 1969.
199. Noorden GK von: The etiology and pathogenesis of fixation anomalies in strabismus. *Trans Am Ophthalmol Soc* 67:698 1969.
200. Noorden GK von: The etiology and pathogenesis of fixation anomalies in strabismus. IV. Roles of suppression scotoma and of motor factors. *Am J Ophthalmol* 69:236, 1970.
201. Noorden GK von: Muscle surgery without scleral sutures. *Ophthalmic Surg* 13:113, 1982.
202. Noorden GK von: Tests of binocular function after surgery for essential infantile esotropia (letter). *Can J Ophthalmol* 18:205, 1983.
203. Noorden GK von: Essential infantile esotropia: A continuing riddle (Richard C. Scobee Memorial Lecture). *Am Orthopt J* 34:52, 1984.
204. Noorden GK von: Round table conference: What do we investigate with the four-prism diopter test? In Gregersen E, ed: *Transactions of the European Strabismological Association*, Copenhagen, 1984.
205. Noorden GK von: A reassessment of essential infantile esotropia (XLIV Edward Jackson Memorial Lecture). *Am J Ophthalmol* 105:1, 1988.
206. Noorden GK von: Current concepts of essential infantile esotropia (Bowman Lecture). *Eye* 2:343, 1988.
207. Noorden GK von: Treatment of amblyopia and surgical outcome (letter). *J Pediatr Ophthalmol Strabismus* 35:5, 1998.
208. Noorden GK von, Avilla CW: Nonaccommodative convergence excess. *Am J Ophthalmol* 101:70, 1986.
209. Noorden GK von, Avilla CW: Accommodative convergence in hypermetropia. *Am J Ophthalmol* 110:287, 1990.
210. Noorden GK von, Avilla CW: Refractive accommodative esotropia: A surgical problem? *Int Ophthalmol* 16:45, 1992.
211. Noorden GK von, Frank JW: Relationship between amblyopia and the angle of strabismus. *Am Orthopt J* 26:31, 1976.
212. Noorden GK von, Helveston EM: Strabismus: A Decision Making Approach. St Louis, Mosby-Year Book, 1994, p 95.
213. Noorden GK von, Jenkins RH: Accommodative amplitude in children wearing bifocals. In Lennerstrand G, ed: *Transactions of the Sixth Meeting of the International Strabismological Association*, Vancouver, 1994. Boca Raton, FL, CRC Press, 1995, p 201.
214. Noorden GK von, Munoz M: Recurrent esotropia. *J Pediatr Ophthalmol Strabismus* 25:275–279, 1988.
215. Noorden GK von, Brown DJ, Parks MM: Associated convergence and accommodative insufficiency. *Doc Ophthalmol* 34:393, 1973.
216. Noorden GK von, Isaza A, Parks MM: Surgical treatment of congenital esotropia. *Trans Am Acad Ophthalmol Otolaryngol* 76:1465, 1972.
217. Noorden GK von, Morris J, Edelman P: Efficacy of bifocals in the treatment of accommodative esotropia. *Am J Ophthalmol* 85:830, 1978.

218. Noorden GK von, Munoz M, Wong S: Compensatory mechanisms in congenital nystagmus. *Am J Ophthalmol* 104:387, 1987.
219. Norcia AM: Abnormal motion processing and binocularity: Infantile esotropia as a model system for effects of early interruptions of binocularity. *Eye* 10:259, 1996.
220. Norcia AM, Garcia H, Humphry R, et al: Anomalous motion VEPs in infants and in infantile esotropia. *Invest Ophthalmol Vis Sci* 32:436, 1991.
221. Ogle K N, Mussey F, Prangen A de H: Fixation disparity and fusional processes in binocular single vision. *Am J Ophthalmol* 32:1069, 1949.
222. Ohtsuki H, Hasebe S, Kobashi R, et al: Critical period for restoration of normal stereoacuity in acute-onset comitant esotropia. *Am J Ophthalmol* 118:502, 1994.
223. Parks M M: Abnormal accommodative convergence in squint. *Arch Ophthalmol* 59:364, 1958.
224. Parks M M: Second thoughts about the pathophysiology of monofixational phoria. *Am Orthopt J* 14:159, 1964.
225. Parks M M: Summary and conclusion. Symposium: Essential infantile esotropia. *Am Orthopt J* 18:19, 1968.
226. Parks M M: Stereo-acuity as an indicator of bifixation. In Arruga A, ed: *International Strabismus Symposium*, University of Giessen, Germany 1966. Basel, S Karger, 1968, p 258.
227. Parks M M: The monofixational syndrome. *Trans Am Ophthalmol Soc* 67:609, 1969.
228. Parks M M: Discussion of paper by Noorden GK von, Isaza A, Parks M M: Surgical treatment of congenital esotropia. *Trans Am Acad Ophthalmol Otolaryngol* 76:1465, 1972.
229. Parks M M: *Ocular Motility and Strabismus*. Hagerstown, MD, Harper & Row, 1975.
230. Parks M M: Congenital esotropia with a bifixation result. Report of a case. *Doc Ophthalmol* 58:109, 1984.
231. Parks M M: Congenital esotropia vs. essential infantile esotropia. *Graefes Arch Clin Exp Ophthalmol* 226:106, 1988.
232. Parks M M: Stereopsis in congenital esotropia. *Am Orthopt J* 47:99, 1997.
233. Parks M M, Eustis A T: Monofixational phoria. *Am Orthopt J* 11:38, 1961.
234. Pertseim M M W, Bickley E: Medial rectus fadenoperation for esotropia only at near fixation. *J Am Assoc Pediatr Ophthalmol Strabismus* 1:129, 1997.
235. Passo M, Shults W T, Talbot T, Palmer E A: Acquired esotropia—a manifestation of Chiari I malformation. *J Clin Neuro Ophthalmol* 4:151, 1984.
236. Pickering J D, Simon J W, Ratliff D D, et al: Alignment success following medial rectus recessions in normal and delayed children. *J Pediatr Ophthalmol Strabismus* 32:225, 1995.
237. Pollard Z F: Accommodative esotropia during the first year of life. *Arch Ophthalmol* 94:1912, 1976.
238. Pollard Z F: Accommodative esotropia after ocular and head injury. *Am J Ophthalmol* 109:195, 1990.
239. Prieto-Diaz J: Large bilateral medial rectus recession in early esotropia with bilateral limitation of abduction. *J Pediatr Ophthalmol Strabismus* 17:101, 1980.
240. Prieto-Diaz J: Five year follow-up of “large” (6–9) bimedial recession in the management of early onset, essential infantile esotropia with Ciancia syndrome. *Binocular Vision* 1:209, 1985.
241. Prieto-Diaz J, Prieto-Diaz I: Long term outcome of treated congenital/infantile esotropia: Does early surgical binocular alignment restoring subnormal binocular vision guarantee stability? *Binocular Vision Strabismus Q* 13:249, 1998.
242. Pugh MA: *Squint Training*. New York, Oxford University Press, 1936, p 81.
243. Raab EL: Etiologic factors in accommodative esotropia. *Trans Am Ophthalmol Soc* 80:657, 1982.
244. Réthy I: Neue Prinzipien in der Behandlung von ½ bis 3 jährigen Schielkindern. *Ophthalmologica* 157:285, 1969.
245. Réthy I, Gál Z: Results and principles of a new method of optical correction of hypermetropia in cases of esotropia. *Acta Ophthalmol* 46:757, 1968.
246. Reed MJ, Steinbach MJ, Anstis SM, et al: The development of optokinetic nystagmus in strabismic and monocularly enucleated subjects. *Behav Brain Res* 46:31, 1991.
247. Richter S: Untersuchungen über die Heredität des Strabismus concomitans. Leipzig, VEB Georg Thieme, 1967.
248. Rogers GL, Bremer DL, Leguire LE, Fellows R R: Clinical assessment of visual function in the young child. A prospective study of binocular vision. *J Pediatr Ophthalmol Strabismus* 23:233, 1986.
249. Rogers G L, Chazan S, Fellows R, Tsou B H: Strabismus surgery and its effect upon infant development in congenital esotropia. *Ophthalmology* 89:479, 1982.
250. Romano P E: Strabismus surgery dosage and timing; outcomes: microtropias and minitropias; sterotests for screening (editorial). *Binocul Strabismus Q* 15:207, 2000.
251. Round table discussion on the long-term significance of sensory anomalies of squint. In *Strabismus '69*; Transactions of the Consilium Europaeum Strabismi Studio Deditum Congress, London, 1969. St Louis, Mosby-Year Book, 1970.
252. Santori M: Influenza della ipercorrezione chirurgica di uno strabismo convergente sulle condizioni della corrispondenza retinica. *Ann Ottalmol* 91:480, 1965.
253. Schiavi C, Bellusci C, Gasparrini E, Campos E: Prognostic value of primary inferior oblique muscles overaction in refractive accommodative esotropia. In Lennerstrand G, ed: *Advances in Strabismology*. Buren, The Netherlands, Aeolus Press, 1999, p 339.
254. Scobee RG: *The Oculomotor Muscles*, ed 2. St Louis, Mosby-Year Book, 1952.
255. Scott AB, Magoon EH, McNeer KW, Stager DR: Botulinum treatment of childhood strabismus. *Ophthalmology* 97:1434, 1990.
256. Setayesh AR, Khodadoust AA, Daryani SM: Microtropia. *Arch Ophthalmol* 96:1842, 1978.
257. Shallo-Hoffmann J, Faldon M, Hague S, et al: Motion detection deficits in infantile esotropia without nystagmus. *Invest Ophthalmol Vis Sci* 38:219, 1997.
258. Shauly Y, Miller M, Meyer E: Clinical characteristics and long-term postoperative results of infantile esotropia and myopia. *J Pediatr Ophthalmol Strabismus* 34:357, 1997.
259. Shauly Y, Prager TC, Mazow ML: Clinical characteristics and long-term postoperative results of essential infantile esotropia. *Am J Ophthalmol* 117:183, 1994.
260. Shippman S, Cohen KR: Relationship of heterophoria to stereopsis. *Arch Ophthalmol* 101:609, 1983.
261. Sidikaro Y, Noorden GK von: Observations in sensory heterotropia. *J Pediatr Ophthalmol Strabismus* 19:12, 1982.
262. Simon AL, Borchert M: Etiology and prognosis of acute, late-onset esotropia. *Ophthalmology* 104:1348, 1997.
263. Simon JW, Waldman JB, Courture KC: Cerebellar astrocytoma manifesting as isolated, comitant esotropia in childhood. *Am J Ophthalmol* 121:584, 1996.
264. Smith MD, Baker JD: Esotropia as the presenting sign of brain tumor. *Am Orthopt J* 40:72, 1990.
265. Sondhi N, Archer SM, Helveston EM: Development of normal ocular alignment. *J Pediatr Ophthalmol Strabismus* 25:210, 1988.
266. Spielmann A: Adduction, latent nystagmus, infantile strabismus and the opto-motor syndrome of congenital unilateral organic amblyopia. In Kaufmann H, ed: *Transac-*

- tions of the 16th Meeting of the European Strabismological Association, Giessen, Germany, 1987, p 291.
267. Spielmann A: Les soi-disant syndromes de blocage: Éso-déviation, élévation, et adduction dans les strabismes précoces (ou le syndrome opto-moteur des monophthalmes congénitaux). Presented at Société française ophtalmologie meeting, May 1987.
 268. Spielmann A: Les soi-disant syndromes de blocage: Ad-duction, ésodéviation et élévation dans les strabismes précoces. *Ophthalmologie* 2:1, 1988.
 269. Spielmann A, Spielmann AC: Idées reçues et erreurs d'interprétation des signes cliniques chez le nourrisson strabique. *Ophthalmologie* 8:42, 1994.
 270. Spiritus M: In Controverses et concepts inhabituels dans le traitement chirurgical des strabismes, Perpignan, France, 1991, p 135.
 271. Sprunger DT, Wassermann B, Stidham DB: The relationship between nystagmus and surgical outcome in congenital esotropia. *J Am Assoc Pediatr Ophthalmol Strabismus* 4:21, 2000.
 272. Stärk N, Vanselow K, Stahl E, Zuncov AA: Behandlung der Esotropie mit akkommodativem und nichtakkommodativem Konvergenzexzess. Fadenoperation mit beidseitiger Rücklagerung. *Klin Monatsbl Augenheilkd* 96:513, 1999.
 273. Stangler E: Das Nachbildverhalten bei Heterophorie. *Klin Monatsbl Augenheilkd* 160:207, 1972.
 274. Stangler-Zuschrott E: Strabismus convergens bei höhergradiger Hypermetropie. *Klin Monatsbl Augenheilkd* 167:469, 1975.
 275. Steffen H, Auffahrt GU, Kolling GH: Posterior fixation suture and convergence excess esotropia. *Strabismus* 6:117, 1998.
 276. Struck MC, Ver Hoeuve J, France T: Binocular cortical interaction in the monofixational syndrome. *J Pediatr Ophthalmol Strabismus* 33:291, 1996.
 277. Stumpf F: Is early surgery really necessary? In Mein J, Bierlaagh JJM, Brummelkamp-Dons TEA, eds: *Orthoptics: Proceedings of the Second International Orthoptic Congress*. Amsterdam, Excerpta Medica, 1971, p 220.
 278. Swan KC: Esotropia following occlusion. *Arch Ophthalmol* 37:444, 1947.
 279. Taylor DM: How early is early surgery in the management of strabismus? *Arch Ophthalmol* 70:752, 1963.
 280. Taylor DM: Congenital strabismus: The common sense approach. *Arch Ophthalmol* 77:478, 1967.
 281. Taylor DM: Is congenital esotropia functionally curable? *Trans Am Ophthalmol Soc* 70:529, 1972.
 282. Taylor DM: *Congenital Esotropia. Management and Prognosis*. New York, Intercontinental Medical Book, 1973, pp 14, 87, 89.
 283. Taylor RH, Armitage IM, Burke JP: Fully accommodative esotropia in adolescence. *Br Orthopt J* 52:25, 1995.
 284. The fourth monitoring report of the early vs. late infantile strabismus surgery study group. *Strabismus* 5:133, 1997.
 285. Thorn F, Gwiazda J, Cruz AAV, et al. The development of eye alignment, convergence, and sensory binocularity in young infants. *Invest Ophthalmol Vis Sci* 35:544, 1994.
 286. Tillson G, Pratt-Johnson JA: Fusion loss from longstanding unilateral cataracts in adults. In Lenk-Schäfer M, ed: *Orthoptic Horizons*. Transactions of the Sixth International Orthoptic Congress, Harrogate, England, LIPS, 1987, p 327.
 287. Travers TAB: The practical importance of abnormal retinal correspondence. *Trans Am Acad Ophthalmol Otolaryngol* 54:561, 1950.
 288. Tychsen L: Visual cortex maldevelopment as a cause of esotropic strabismus (letter). *Arch Ophthalmol* 105:457, 1987.
 289. Tychsen L, Lisberger SG: Maldevelopment of visual motion processing in humans who had strabismus with onset in infancy. *J Neurosci* 6:2495, 1986.
 290. Tychsen L, Hurtig RR, Scott WE: Pursuit is impaired but the vestibulo-ocular reflex is normal in infantile strabismus. *Arch Ophthalmol* 103:536, 1985.
 291. Vasquez R, Calhoun JH, Harley RD: Development of monofixation syndrome in congenital esotropia. *J Pediatr Ophthalmol Strabismus* 18:42, 1981.
 292. Véronneau-Troutman S: Fresnel prism membrane in the treatment of strabismus. *Can J Ophthalmol* 6:249, 1971.
 293. Vollrath-Junger C, Lang J: Akuter Strabismus convergens bei erhöhtem Hirndruck. *Klin Monatsbl Augenheilkd* 190:359, 1987.
 294. Weakley DR, Holland DR: Effect of ongoing treatment of amblyopia on surgical treatment in esotropia. *J Pediatr Ophthalmol Strabismus* 34:275, 1997.
 295. Weakley DR, Stager DR, Everett ME: Seven-millimeter bilateral medial rectus recessions in essential infantile esotropia. *J Pediatr Ophthalmol Strabismus* 28:113, 1991.
 296. Webster's Ninth New College Dictionary, Springfield, MA, Merriam-Webster, 1985, p 276.
 297. Weeks CL, Hamed LM: Treatment of acute comitant esotropia in Chiari I malformation. *Ophthalmology* 106:2368, 1999.
 298. Westfall CA, Eizenman M, Kraft SP, et al: Cortical binocularity and monocular optokinetic asymmetry in early-onset esotropia. *Invest Ophthalmol Vis Sci* 39:1352, 1998.
 299. Williams AS, Hoyt CS: Acute comitant esotropia in children with brain tumors. *Arch Ophthalmol* 107:376, 1989.
 300. Windsor CE: Surgically overcorrected esotropia: A study of its cause, sensory anomalies, fusional results, and management. *Am Orthopt J* 16:8, 1966.
 301. Worth C, cited in Chavasse FB: *Worth's squint or the binocular reflexes and the treatment of strabismus*, ed 7. London, Baillière, Tindall & Cox, 1939 p 289.
 302. Worthan E, Greenwald MJ: Expanded binocular peripheral visual fields following surgery for esotropia. *J Pediatr Ophthalmol Strabismus* 26:109, 1989.
 303. Wright KW, Edelman PM, McVey JH, et al: High-grade stereo acuity after early surgery for congenital esotropia. *Arch Ophthalmol* 112:913, 1994.
 304. Wybar K: The significance of squint in certain forms of malignant disease. *Br Orthopt J* 24:47, 1967.
 305. Zak TA, Morin JD: Early surgery for essential infantile esotropia: Results and influence of age upon results. *Can J Ophthalmol* 17:213, 1983.

Exodeviations

Classification and Etiology

Even though the classification and etiology of strabismus are discussed in Chapters 8 and 9, a few specific remarks regarding exodeviations are in order in this chapter. Although fair agreement has been reached with respect to the classification and etiology of esodeviations, the same cannot be said for exodeviations.

Most current classifications of exodeviations are derived from Duane,⁴⁹ who championed the view that exodeviations are caused by an innervational imbalance that upsets the reciprocal relationship between active convergence and divergence mechanisms. According to Duane, an exodeviation greater at distance than at near fixation is caused by hypertonicity of divergence (*excess*), a deviation greater at near than at distance is caused by *convergence insufficiency*, and a deviation at distance equal to that at near fixation (*basic exotropia*) is caused by a divergence excess combined with a convergence insufficiency.

Some have argued against the etiologic concept Duane implied by this terminology; however, his classification has survived and is in current usage by many strabismologists.

Duane's classification is based on the assumption that divergence is an active process rather than relaxation of convergence with a return of the eyes to parallelism or a divergent position by mechanical or elastic forces. Most modern investigators share this view, which has been confirmed by electromyographic studies^{18–20, 122, 170} (see Chapter 22). Bielschowsky,¹⁴ on the other hand, al-

though not denying the existence of an active divergence mechanism, questioned Duane's claim that the majority of exodeviations are based on hyperactive tonic divergence. He argued that Duane's theory did not take into account the abnormal position of rest associated with exodeviations. This abnormal position is determined by anatomical and mechanical factors such as topographic and physical properties of the extrabulbar tissues, the shape and axis of the orbits, the interpupillary distance, and the size of the globe. As early as 1896, Weiss¹⁷⁸ had shown how the growth and depth of the orbit, as well as the length and insertion of the horizontal rectus muscles, may influence the functional equilibrium between medial and lateral rectus muscle actions. That orbital factors indeed may have etiologic significance in causing exodeviations is a view also supported by the high prevalence of exodeviations in patients with craniofacial dysostosis (Crouzon's disease) in whom shallow and laterally directed orbits are prominent clinical findings.

Bielschowsky,^{14, 15} in support of his theory that an anomalous position of rest contributes to the occurrence of exodeviations, cited the high incidence of sensory exotropia after disruption of fusion by unilateral blindness (see also Chavasse³⁹ and p. 345). He also pointed out that development of divergence excess secondary to convergence insufficiency is an untenable concept in view of the fact that patients with defective convergence are frequently orthophoric or even esophoric at distance fixation.

Most current theories on the etiology of exode-

viations combine the ideas of Duane and Bielschowsky and revolve around the concept that exodeviations are caused by a *combination of mechanical and innervational factors*,^{28: 44, p. 349; 98: 146} the innervational factors consisting of variation of convergence innervation or disturbed equilibrium between convergence and divergence.

Burian²⁸ summarized this thinking by stating that patients with exodeviations have a basic misalignment of the eyes caused by mechanical and anatomical (*static*) factors, the nature of which must remain speculative at the present stage of our knowledge. This basic exotropia may be defined as the relative position of the visual axes when there is no stimulus to fusion, when the refractive errors of the eyes are corrected, and when the dominant eye is fixating on a distant object with the eyes in primary position.¹⁶⁹ To this basic deviation are added innervational (*dynamic*) factors that tend to maintain ocular alignment by convergence or to impair it by divergence. Normal interplay between these innervational influences provides for gross alignment of the eyes, and any abnormality in this interplay is the primary factor in the pathogenesis of exodeviations. Burian further pointed out that during childhood, “exuberant” (Chavasse³⁹) functioning of the convergence mechanism may obscure a basic exodeviation at near fixation (*simulated divergence excess*) and that special tests are needed to elicit the true deviation.

In addition to interplay between the convergence and divergence mechanisms, refractive errors may further modify the innervational pattern that influences the position of the eyes. For instance, in a patient with uncorrected myopia, less than normal accommodative effort is required during near vision, thus causing decreased accommodative convergence. According to Donders,⁴⁸ this constant understimulation of convergence may cause an exodeviation to develop. It must be emphasized, however, that the role of myopia in the etiology of exodeviations is far less prominent than that of hypermetropia in esodeviations.

A similar mechanism prevails in patients with a hypermetropia. If a high degree of hypermetropia is uncorrected, such patients make no effort to overcome the refractive error by an accommodative effort, and clear vision is unattainable.¹⁴¹ As in the previous case, an exodeviation may develop on the basis of an understimulated and thus underactive convergence mechanism that causes the accommodative convergence–accommodation (AC/

A) ratio to remain low or even flat. In moderate degrees of hypermetropia, spectacles correction will decrease the accommodative demand and an underlying exodeviation, previously controlled by accommodative convergence, will increase and may require treatment.

Jampolsky and coworkers⁹³ emphasized that although an equal degree of myopia in both eyes cannot be correlated with exodeviations, anisomyopia and anisoastigmatism bear distinct relationships to exodeviations. Unequal clarity of retinal images may present an obstacle to fusion, facilitate suppression, and therefore contribute to the pathogenesis of exotropia.

The view that tonic convergence is a factor in masking exodeviations at near fixation and that excessive divergence may cause an exodeviation at distance fixation has been challenged by Jampolsky,⁹² who refutes the existence of convergence and divergence innervation other than that caused by fusional or accommodative stimuli (see Chapters 5 and 22). Although we cannot accept this reasoning unequivocally, we are aware that at this time no clinical or laboratory evidence exists for excessive tonic divergence innervation in exodeviations. Thus the term *divergence excess* introduced by Duane may well be a misnomer. Likewise, Duane’s term *convergence insufficiency* for describing exodeviations that are greater at near than at distance fixation is not identical with a synonymous condition (see Chapter 22) which may or may not be accompanied by an exodeviation. In fact, a patient with convergence insufficiency may have orthophoria or even esophoria at near fixation. On the other hand, a “convergence insufficiency *type or pattern*” exodeviation may be associated with a normal near point of convergence and normal or even excessive fusional convergence amplitudes. Thus we use Duane’s classification merely in a descriptive sense without accepting all its etiologic implications. With this reservation in mind, we classify exodeviations into the following patterns:

1. *Divergence excess pattern*. The exodeviation is at least 15^Δ larger at distance than at near fixation.
2. *Basic exodeviation*. The distance deviation is approximately equal to the near deviation.
3. *Convergence insufficiency pattern*. The near deviation is at least 15^Δ greater than the distance deviation.
4. *Simulated divergence excess pattern*. The prism and cover test will show an exodevia-

tion that is significantly larger at distance than at near fixation. However, a larger, static deviation at near fixation is obscured by dynamic factors such as persistent convergence innervation (vergence aftereffect; see p. 202), and special tests are required to reveal the deviation at near fixation, which will then often equal or even exceed that at distance fixation. It is necessary to distinguish between the contributions. As will be pointed out later in this chapter, it is necessary to distinguish between a reduction of the near deviation caused by a fusional convergence aftereffect (Burian's pseudodivergence excess type) or by the addition of plus lenses.^{76, 106, 137}

In terms of the state of fusion, exodeviations can be classified further as exophoria (X), intermittent exotropia (X[T]), and exotropia (XT) (see Chapter 8).

In addition to classic theories regarding the etiology of exodeviations discussed in the preceding paragraphs, an interesting and unconventional possibility was introduced by Mitsui.¹²³ He noted that in exotropia a slight adductive force applied to the fixating eye with a fixation forceps causes the deviated eye to adduct (magician's forceps phenomenon). Mitsui concluded from this and other observations¹²⁴ that abnormal proprioceptive impulses originating from the dominant eye are the cause of the exodeviation. However, this phenomenon can be explained on the basis of a visually elicited refixation reflex; that is, by adducting the fixating eye with a forceps, the retinal image is displaced nasally. The patient now attempts to refixate with an abduction saccade, but this movement cannot be executed because the eye is mechanically stabilized. The impulse to abduct will be transmitted to the deviated eye as an abduction impulse (Hering's law).^{102, 138} As one may expect, this phenomenon cannot be elicited when the fixating eye is prevented, by means of a translucent occluder, from registering the image displacement.¹³⁸ Thus, it is unlikely that a mechanism other than a visually elicited fixation reflex accounts for the phenomenon described by Mitsui.

Exodeviations also may be associated with vertical anomalies, and the angle of deviation may change in upward or downward gaze (A and V patterns). In this respect, they do not differ from esodeviations; this type of strabismus is discussed in Chapter 19.

Primary Exodeviations

Clinical Characteristics

Exotropia differs from esotropia not only in direction and size of the deviation but also with respect to prevalence, sex predilection, age of the patient at onset, progression of the disease, prognosis, nature of the underlying sensorial adaptation, and the etiologic significance of associated refractive errors. Also, exodeviations are much more common in a latent or intermittent form than are esodeviations. A patient may exhibit a manifest exotropia during one examination, and at another time an exophoria or intermittent exotropia. Indeed, it is common to observe rapid switching from one phase to the other during the same examination. Mechanisms responsible for these variations include the degree of fusional control with varying levels of alertness, the convergence-accommodation relationship, and the change of the angle of deviation at different fixation distances. For this reason, it is often impossible to distinguish clearly between exophoria and exotropia or, from a clinical point of view, to consider them as different entities. Therefore exophoria, intermittent exotropia, and exotropia will be discussed together, but efforts will be made to point out distinguishing features among these conditions. We should point out, however, that these three entities present with differential clinical features. A decompensation of exophoria is noticed quite soon as it is always accompanied by diplopia. Children will often close one eye and complain about visual disturbances. On the other hand, monocular eye closure in intermittent exotropia has a different explanation, as will be discussed later in this chapter. Subjective symptoms are usually absent and this condition may not be readily recognized by the parents. In constant exotropia, binocular vision is absent and no symptoms are present.

PREVALENCE. Exodeviations occur less frequently than esodeviations. During ophthalmic screening of 38,000 children aged 1 to 2½ years and observed at child welfare clinics in Israel, Friedmann and coworkers⁶² detected strabismus in 498 infants, of whom 72.2% had esotropia and 23% exotropia. This ratio of approximately 1:3 in the prevalence of exotropia and esotropia has also been established in surveys from Scandinavia,^{61, 134} Great Britain,⁶⁶ western Canada,¹⁰³ and the United States.^{43, 161} We have the distinct impression, based

on having been involved in the screening of populations in other parts of the world, that exodeviations occur more commonly in the Middle East, subequatorial Africa, and the Orient than in the United States. They appear to occur least commonly in central Europe. On the other hand, Chew and coworkers⁴³ reported no difference in the frequency of exodeviations in white and African-American children in the United States.

In comparing the prevalences reported from different countries, Jenkins⁹⁴ made the interesting observation that the nearer a country is to the equator, the higher the prevalence of exodeviations. A comprehensive epidemiologic study in which ethnic population differences⁸⁷ and even climatic and heliotropic⁵⁴ factors are considered is needed to explore the significance of these observations. The implication of a recent report that the prevalence of systemic and ocular disease is higher during the first year of life in children with exotropia than in those with esotropia⁸² is not at once obvious.

AGE OF ONSET AND NATURAL HISTORY. Contrary to common belief, onset of the majority of exodeviations is shortly after birth. In Costenbader's^{44, p. 353} series of 472 patients with intermittent exotropia of the divergence excess type, the deviation was present at birth in 204 and appeared in 16 at 6 months of age and in 72 between 6 and 12 months of age. In only 24 of his patients did exotropia develop after 5 years of age. Krzystkova and Pajakowa¹⁰⁵ reported the age of onset to be before 2 years of age in 34.5% of their patients; Hall,⁷⁰ in 37%; and Holland,⁸⁰ in 70%. In a more recent study, the mean age at diagnosis was 7.8 months.¹⁶

It is not always possible to ascertain by history alone whether a constant exotropia was present at birth or occurred shortly thereafter or was preceded by a period of intermittency. Yet such information would be important in assessing the prognosis. In the latter instance the chances for restoring normal binocular functions are better than in the former. Moore and Cohen¹²⁸ reported that fusion was unattainable after surgical alignment in patients with a genuine "congenital" exotropia.

Jampolsky⁹¹ made the point that, with rare exceptions, exodeviations begin as an exophoria that may deteriorate into intermittent and constant exotropia as suppression develops. He considered suppression to be the key that unlocks the fusion

mechanism. Such deviations usually occur first at distance and later at near fixation. Obviously, the prognosis for recovery of normal binocular function is infinitely better in patients who experience a long phase of intermittency than in those with a manifest deviation since early childhood.

Factors that may influence progression are the decrease in tonic convergence with advancing age, development of suppression, gradual lessening of accommodative power, and increased divergence of the orbits with advancing age. Progression may take several forms. The deviation may increase at near or at distance fixation,^{97, 130} exophoria may become intermittent or change to manifest exotropia, or suppression may develop.

Burian²⁷ observed that the divergence excess type of deviation tends to remain more or less stable, whereas with simulated divergence excess the near deviation tends to increase. In patients with the convergence insufficiency type of deviation, binocular function degenerates rapidly and progressively, and in those with a basic exotropia there is a tendency for the deviation to increase or for secondary convergence insufficiency to develop.

The generally progressive nature of the disease has important therapeutic implications in regard to indications for and timing of surgery. At this point, therefore, it is necessary to emphasize that not all exodeviations are progressive and that some remain unchanged over many years of observation; in fact, some improve without therapy.^{57, 78} Von Noorden¹³⁵ followed for an average of 3.5 years 51 patients ranging from 5 to 10 years of age with intermittent exotropia who, for one reason or another, were not operated on. One or more signs of progression, as defined above, were present in 75%, no change occurred in 9%, and 16% improved without therapy. From these studies, it follows that patients with intermittent exodeviations need to be evaluated over a period of time to ascertain whether progression is taking place and surgery is warranted, particularly those in whom a constant deviation is present less than 50% of the time.

Constant, infantile exotropia with an onset shortly after birth and with a large angle deviation that does not change at near and distance fixation may also occur and its clinical characteristics are said to be similar to those in infantile esotropia.¹⁵⁸ An association between early-onset exotropia with a large angle and delayed visual maturation has been reported.¹⁸⁴

SEX DISTRIBUTION. Several authors have commented on the preponderance of women in a population of patients with exodeviations. Cass³⁷ reported a prevalence of 62 (70%) women in 88 patients; Gregersen,⁶⁷ 61% women in 231 patients; and Krzystkova and Pajakowa,¹⁰⁵ 67% women in 620 patients with exodeviations.

REFRACTIVE ERRORS. The prevalence of refractive errors associated with exodeviations varies according to different investigators. Donders⁴⁸ found 70% of “comparatively high” myopes in a group of 100 patients with exotropia and concluded that reduction of accommodation in such patients is pivotal in the etiology of exodeviations. From more recent studies,^{28, 67, 105, 161} it appears, however, that distribution of refractive errors in exotropes resembles that in the nonstrabismic population and that the etiology usually is unrelated to the underlying refractive error.

SIGNS AND SYMPTOMS. Generally, signs and symptoms of exodeviations are no different from those observed in patients with other forms of strabismus, as discussed in Chapter 10. Patients with exophoria commonly complain of eyestrain, blurring of vision, difficulties with prolonged periods of reading, headaches, and diplopia. Children with intermittent or constant exodeviations are less frequently symptomatic because, unless the deviation is of recent onset, a well-developed suppression mechanism eliminates diplopia.⁹⁵ On the other hand, adults with intermittent exotropia are commonly symptomatic, and their complaints are not different from those with inadequately compensated exophorias.

PHOTOPHOBIA. One symptom that deserves special comment is photophobia, for it occurs commonly in association with intermittent exodeviations. In spite of the frequency of its occurrence,^{81, p. 219; 100, p. 234; 113; 146} little if any attempt has been made in the literature to satisfactorily explain photophobia in connection with exodeviations. It has been assumed that when a child is outdoors and looking at infinity, there are no near clues to stimulate convergence and that bright sunlight dazzles the retinas so that fusion is somehow disrupted, causing the deviation to become manifest.¹¹⁸ These explanations imply that one eye is closed to avoid diplopia and visual confusion. This view is held, for instance, by Wang and Chryssanthou,⁷⁵ who found that patients with anomalous retinal correspondence are less apt to complain about photophobia than those with nor-

mal correspondence. Jampolsky⁸⁹ assumes that the intermittent exotrope shuts one eye in bright light to avoid the many perceptual visual field changes that take place in bright light diffusion, which in turn may trigger the “hemiretinal suppression mechanism” (see pp. 218, 365).

Wirtschafter and von Noorden¹⁸³ demonstrated that bright light adversely affects the amplitude of fusional convergence in patients who maintain a delicate balance between exophoria and intermittent exotropia (see also Campos and Cipolli³⁶). Orthophoric patients, those with exophoria and adequate fusional amplitudes, and those with well-established intermittent exotropia were not affected in this manner. Eustace and coworkers⁵⁴ also noted that bright light causes exophoria to become manifest and suggested the use of photochromatic lenses to relieve photophobia in such patients. Graefe⁶⁵ reported an increase in the deviation at near fixation under the influence of bright light in patients with exophoria.

It is a common misconception that habitual monocular eye closure in bright sunlight is limited to intermittent exotropes and that eye closure is triggered by diplopia. Wiggins and von Noorden¹⁸⁰ observed photophobia predominantly in intermittent exotropes but also in constant exotropia, esotropia, and normal subjects. None of the subjects was aware of diplopia before closing one eye or under any other circumstances. The common factor in these patients was a significantly decreased binocular photophobia threshold, which was measured by exposure to an intense artificial illumination. This finding was unrelated to the presence or absence of anomalous correspondence as proposed by Wang and Chryssanthou.¹⁷⁵ The significance of these results and the reason for the highest incidence of photophobia in the intermittent esotropia group remains elusive at this time.

MICROPSIA. Another less well-known symptom of intermittent exodeviations is micropsia. We have seen several patients with this anomaly since we first became aware of it through the patient in Case 17–1.

CASE 17–1

This 21-year-old woman has had intermittent exotropia since childhood. Her right eye had been operated on by another ophthalmologist. She described her current problem as follows: “When I look in the distance, things go in and out of focus and then get

much smaller, like looking through the wrong end of binoculars." Examination revealed an intermittent exotropia of 22^Δ at distance and 18^Δ at near fixation. The deviation was fused at distance but changed from exophoria to exotropia, and the angle increased as soon as the patient was asked to read the 6/6 line on the acuity chart.

Clearly, the patient in Case 17–1 used accommodative convergence to control her exodeviation at distance. Since convergence and accommodation are associated with objects appearing smaller and closer, micropsia was experienced whenever these mechanisms were involved.

EXAMINATION AND SPECIAL TESTS. In addition to the testing procedures outlined in Chapters 12 and 13, several comments need to be made regarding tests specifically applicable to patients with exodeviations.

OCCCLUSION TEST OF SCOBEE-BURIAN. The occlusion test for differentiation between true and simulated divergence excess patterns is important because, as discussed under surgical management on page 368, the outcome of this test determines our choice of surgical procedure. Scobee¹⁶³, p. 172 pointed out that in patients with intermittent exodeviations the angle of exotropia elicited by the alternate cover test is greater at distance more often than at near fixation. By unilaterally occluding the eyes of such patients for 24 hours or by teaching them voluntary relaxation of convergence, he found that exotropia would increase at near fixation and become greater than at distance fixation. He explained control of the near deviation on the basis of the greater fusional stimuli provided by an object at near, such as the larger size of the retinal images, the increased brightness and proximity of the object, and the effect of accommodative convergence. Burian²⁶ reported independently that in many patients with an apparent divergence excess type of deviation, only brief periods of unilateral occlusion (30 to 45 minutes) are sufficient to cause an increase in the near deviation so that it equals or even exceeds that at distance fixation. He described such patients as having *simulated divergence excess* and distinguished this group from those in whom the near deviation is not influenced by brief periods of occlusion (*true divergence excess type*).

In addition to the factors enumerated by Scobee to explain this phenomenon, we believe that extremely active convergence tonus during childhood may be a factor in obscuring the exodevia-

tion at near fixation. This mechanism enables patients with a basic deviation to keep their eyes aligned for near vision but not for distance vision, where convergence is less active. Momentary disruption of fusion by alternately covering each eye in a rapid fashion, as during the prism and cover test, is obviously insufficient to disrupt this powerful compensatory mechanism that may have been exerted during all waking hours for years (vergence aftereffect, p. 202). Kushner introduced the term "tenacious proximal fusion" for the persistent convergence innervation that hides the exodeviation at near fixation.^{109, 110} This term seems awkward and does not add to the clarification of the issue. The term "convergence aftereffect" is a more appropriate description of this phenomenon.

One of the reasons why most patients with intermittent exotropia do not use fusional convergence also to overcome the exodeviation at distance fixation may be that the basic exodeviation is larger at distance than at near fixation and exceeds the limits of the fusional convergence amplitude. Other factors to be considered are the lack of proximal stimuli at distance fixation and the unaccustomed and difficult task of converging upon visual objects at infinity.

The patch test is illustrated in Figure 17–1. Momentary binocular stimulation may reinstate the mechanism by which the patient controls the deviation at near fixation. Thus before the measurement after the patching period, the fellow eye must be occluded before the patch is removed; one may then proceed in the usual manner with the prism cover test. Whether the dominant or nondominant eye is occluded does not seem to influence the results of this test.¹³² Publications in the European literature frequently and unjustifiably refer to the patch test as "Marlow occlusion." Marlow¹¹⁹ used unilateral occlusion of the dominant eye for as long as 1 to 2 weeks in nonstrabismic patients to "relax the muscles" and unmask horizontal or vertical heterophorias of a magnitude not exceeding a few prism diopters. If an eponym is to be attached to the patch test, which is different from the Marlow test in purpose and execution, it would be more appropriate to name the test after Scobee and Burian.

In a group of 46 patients in whom the exodeviation was greater at distance than at near fixation, von Noorden¹³⁶ found a true divergence excess pattern in only 14; in the remainder the occlusion test revealed simulated divergence excess. In 237 consecutive patients with exodeviations, Burian




FIGURE 17-1. The patch test. A–C, Alternate cover test has revealed an exotropia that is significantly (15^{Δ}) smaller at near than at distance fixation. D, Patch is placed over one eye for 1 hour to thoroughly dissociate the eyes. E, Before removal of the patch the fellow eye is covered with an occluder. After the patch has been removed, it is important to prevent the patient from using the eyes together, even momentarily, since only a brief binocular exposure may be sufficient to again obscure the near deviation by fusional convergence. F, Patch has been removed. G and H, If simulated divergence excess (basic exotropia) is present, rapid alternate covering will reveal a markedly increased near deviation that may match or even exceed the distance deviation, whereas with true divergence excess the near deviation will remain unchanged. (From Noorden GK von: Atlas of Strabismus, ed 4. St Louis, Mosby-Year Book, 1983.)

and Franceschetti²⁹ found only 10 with a true divergence excess pattern. Thus it seems that the majority of patients with exodeviations in whom the deviation at distance fixation exceeds that at near belong in the simulated divergence excess category.

+3.00 SPHERICAL LENS TEST. The effect of brief periods of unilateral occlusion on an exodeviation at near fixation must not be confused with the effect of +3.00D spherical lenses. Occlusion removes the vergence aftereffect, whereas +3.00 lenses suspend accommodation and thus accommodative convergence. Elimination of the accommodative requirement at near fixation will have little influence on the positions of the eyes in a patient with an exodeviation and a low AC/A ratio; the angle of strabismus will increase only slightly when measured through +3.00 lenses. On

the other hand, with a high AC/A ratio, if the deviation is measured through +3.00 lenses, it will increase substantially at near fixation and under certain circumstances may equal that at distance.

This information may be clinically important for several reasons. Brown²² suggested that preoperative determination of the AC/A ratio may be helpful in predicting the extent to which a patient may respond to plus lenses when surgical overcorrection is obtained. Also, a patient with a high AC/A ratio and a basic exodeviation will manage to keep the eyes aligned when exerting normal accommodative effort at near fixation. Such a patient will respond well to minus lenses prescribed to reduce the distance deviation. Brown²³ and Jampolsky⁹² have commented on the high incidence of high AC/A ratios in patients with exodevi-

ations. On the other hand, von Noorden,¹³⁶ who determined the AC/A ratio over a range of 6D with +3.00 and -3.00 lenses in 46 patients with an apparent divergence excess, found that the AC/A ratio ranged from 3.3 to 9.

The purpose and interpretation of the Scobee-Burian and the +3.00 spherical lens tests are frequently confused in the literature. It must be understood that plus lenses do not uncover a deviation that is held in check by accommodative convergence, similar to uncovering by occlusion a deviation that is kept latent by the vergence aftereffect. The increase of the exodeviation under the influence of plus lenses is triggered by optically reducing the accommodative demand, a situation that is *artificially* induced by the examiner and different from ordinary conditions of seeing. Since different mechanisms are involved in the occlusion and +3.00 lens tests, it can be expected that patients with an apparent divergence excess type of deviation may respond differently to each test. That this is indeed so was shown by Burian and Franceschetti.²⁹ With respect to the choice of surgical procedure, we rely primarily on the occlusion test.

MEASUREMENT OF THE DEVIATION. Methods for determining the angle of strabismus are described in Chapter 12, and only a few special comments need be made in this chapter in connection with exodeviations. We have mentioned that young patients with an exodeviation may use voluntary convergence to overcome the deviation at near fixation, and in certain cases this compensatory mechanism may extend so as to control the deviation at distance fixation as well. Voluntary convergence then is enlisted to maintain single binocular vision at distance fixation. These patients obviously put up with the induced myopia and prefer blurred and single vision over sharp and double vision. Unless the target used for distance fixation forces patients to relax accommodation, and with it convergence, true deviation of the eyes at distance fixation may remain concealed. Therefore, we prefer to measure the angle of strabismus at distance while a patient reads the 6/9 line on the visual acuity chart. To recognize these letters, the patient must relax accommodation. When a patient with an exodeviation complains about intermittent blurred vision at distance, an accommodative spasm based on this mechanism must be considered. This situation may be confusing to the inexperienced ophthalmologist, who

finds visual acuity at distance to be decreased but who on refraction is unable to detect myopia in spite of the patient's complaints. Determination of binocular visual acuity is a simple method of detecting *accommodative spasm* in patients with exodeviations.^{15, 24, 165} When accommodative spasm is present, binocular visual acuity will be significantly reduced in comparison with unilaterally obtained visual acuity (see Chapter 22).

Another important aspect to be considered when measuring the angle of deviation in patients with exodeviations is the *testing distance*. White¹⁷⁹ was the first to point out that to elicit the maximal deviation, measurements should be performed at fixation distances greater than 6 m. Many investigators agree with this modification of testing procedure^{38; 92; 98, p. 364; 107} since a larger angle of deviation may be detected and, more important, the fusional state of the patient may be revealed under a more natural visual condition than within the confines of an examination lane. Burian and Smith³⁰ noted the exodeviation to increase significantly in 31 of 105 patients when measured at 30 m.

Mention should be made also about the *variability of fusional control in patients* with intermittent exotropia. The extent to which an exodeviation is controlled by fusion depends not only on the size of the angle but also to a large extent on the general health, alertness, attention span, and level of anxiety of the patient at the time of examination. Considerable variation in the degree of fusional control from one examination to another is not a surprising finding. Repeated examinations, preferably at different times during the day, are required to assess the clinical situation thoroughly. For instance, a child who, when seen in the morning, may fuse steadily at near and distance fixation in spite of a large exophoria may exhibit manifest exotropia without fusional recovery in the late afternoon. The opposite also may be observed. For instance, a patient with unstable fusion in whom the deviation is mostly intermittent or manifest on repeated examinations may exhibit transient improvement of fusional control when admitted for surgery. Obviously, anxiety associated with the impending operation releases extra energy, permitting the patient to keep the eyes aligned. This should not deter the experienced surgeon from proceeding as planned with the operation. We have observed on several occasions that a less experienced physician may become intimidated by this apparent improvement

and send a patient home without surgery who will then have to be readmitted at a later date.

Finally, attention must be paid to the *angle of deviation in lateral gaze*. Parks¹⁴⁶ recommended decreasing the amount of recession of the lateral rectus muscles ordinarily done for an exodeviation in primary position when the measurements in right and left gaze show less exodeviation than in the primary position. This impression was confirmed by Moore,¹²⁷ who reported that surgical overcorrection is likely to occur in patients with intermittent exotropia whose deviation decreases in lateroversion as compared with the primary position (lateral gaze incomitance). This was true regardless of the type of intermittent exodeviation or type of surgery used. A 20% or greater decrease in the lateral gaze deviation is considered to be significant.¹⁰⁰ Moore did not mention whether, as might be expected, her patients with lateral gaze incomitance had limitation of abduction. However, her findings are in accordance with our philosophy that it is not advisable to perform a conventional amount of recession on an already underacting muscle. We confirmed the occurrence of lateral gaze incomitance in 55 of 92 exotropic patients and found that the decrease in the deviation in lateral gaze was asymmetrical in most instances.¹²¹ Caldeira³² reported similar findings. Reduction of the surgical dosage is advisable when the decrease in the deviation in lateral gaze is significant.^{121, 127} To avoid false measurements in lateral gaze, care must be taken not to rotate a loose plastic prism but to keep its back surface perpendicular to the optical axis of the eye.¹⁵⁵

SENSORIAL ADAPTATIONS. The sensory behavior associated with exodeviations differs in several respects from that in patients with esodeviations, which may be caused partly by differences in evolution of the disease. Anatomical and possibly physiologic variances between nasal and temporal retina are other factors held responsible for differences in the characteristics of sensorial adaptations in these two conditions.^{55, 131} In patients with the divergence excess type of exodeviation, a latent strabismus at near fixation often coexists with a manifest strabismus at distance fixation. Thus, normal binocular vision is constantly being reinforced, and sensorial adaptations are infrequent or, when present, are only superficially established. Deep amblyopia with eccentric fixation is a rare finding with an exodeviation and limited to unilateral deviations, usually caused by partial or com-

plete oculomotor paralysis. Likewise, deep-seated anomalous retinal correspondence occurs primarily with unilateral constant exotropia.⁷⁹ The majority of patients have an alternating type of strabismus with normal visual acuity in each eye and suppression of the nonfixating eye. In patients with intermittent exotropia, normal and anomalous retinal correspondence may coexist (see Chapter 13), and the afterimage test may indicate abnormal correspondence with one eye deviated and normal retinal correspondence with the eyes aligned.^{25; 81, p.198}

In certain patients with a large angle constant exotropia the results of sensory testing with a red glass may reveal a most puzzling finding. The patient will report paradoxical, that is, uncrossed, diplopia.^{1, 17, 37, 45, 47, 60} Homonymous localization of all binocularly perceived images is present. This confusing situation, which has been referred to as *panoramic vision*, seems to indicate a lack of any retinal correspondence, normal or abnormal, as though each eye functioned independently of the other. Indeed, it has been suggested that such patients may have regressed to a latently present, lower phylogenetic level at which the visual messages from each eye are independently received in the visual cortex.⁴⁷ Tests for retinal correspondence yield confusing results since some patients seem to be unable to relate one afterimage to the other.⁶⁰ Abraham¹ suggested that such patients suffer from a congenital absence of binocular function. However, we have occasionally observed recovery of normal binocular vision after surgical alignment (see also Forrer⁶⁰). We have been unable thus far to find a satisfactory explanation for this phenomenon, but have been impressed by the functional benefit some exotropic patients derive from panoramic vision, as shown in the following case.

CASE 17-2

A 46-year-old mailman servicing a rural mail route came for surgical correction of an exotropia that had been present since childhood. He was concerned about his appearance, but had no visual complaints. His uncorrected visual acuity was 6/6 OU, and he had a constant exotropia of 50^a at near and distance fixation. He strongly preferred OS for fixation. The afterimage test showed suppression of OD. With a dark-red glass the patient indicated homonymous diplopia. After surgical alignment the patient regained peripheral fusion without stereopsis. However, he was most displeased with the result. Be-

fore surgery he had been able to keep his left eye on the road when driving his truck while scanning the mailboxes with his right eye. After surgery he found his field of vision substantially reduced, and it took several months of adjustment before he was able to resume his occupation.

While enlargement of the field of vision may be experienced as a functional advantage by some patients with a large exodeviation, the opposite is true for esotropia where the field of vision is restricted and enlarges after surgery (see p. 333).

Jampolsky⁸⁸ and Pratt-Johnson and Wee¹⁵⁰ showed that suppression in patients with exodeviations may be regional; that is, the scotoma extends from the fovea into the temporal retinal periphery (Jampolsky⁸⁸) or, in the case of alternating constant exotropia, may include the entire temporal and nasal retina of the deviated eye.¹⁵⁰ Campos³⁵ pointed out that the hemianopic suppression scotoma reported by Jampolsky can be found only when putting a dense red filter before the fixating eye. When using a less dissociating method (e.g., Bagolini striated lenses), the scotoma extended well beyond the midline into the nasal retina (Fig. 17–2).

In view of these findings (see also Chapter 13) the concept of “hemiretinal suppression” becomes untenable. The great variations in location and size of suppression scotomas in patients with intermittent or manifest exodeviations was emphasized also in the studies of Herzau⁷⁷ and of Awaya and coworkers.⁴

Stereoacuity deteriorates concomitantly with loss of fusional control in patients who have inter-

mittent exodeviations.¹⁶⁸ Awaya and coworkers⁵ and Ikeyama and Awaya⁸⁵ made the astonishing observation that some patients with exotropia may preserve normal stereoacuity by rapid alternation.

Therapy

As stated on page 358, fundamental differences exist between exodeviations and esodeviations in terms of many clinical characteristics. Since fusion can be restored in a substantial number of patients and since normal binocular function may be present even in the preoperative stage during the exophoria period of intermittent exotropia, the less experienced ophthalmologist is inclined to approach treatment of this condition with brazen optimism—a functional cure seems to be just around the corner. However, as experience grows, it will become apparent to most that treatment of intermittent exotropia may be quite difficult and frustrating. Because functional restoration of binocular vision is apparently within easy reach, a partial or perhaps temporary improvement by surgery followed by subsequent deterioration of binocular function is doubly disappointing to the surgeon and patient.

NONSURGICAL TREATMENT. Therapy is not required for patients who have exophoria without muscular asthenopia. The treatment of symptomatic exophoria and intermittent and constant exodeviations is generally surgical. However, certain nonsurgical measures may be indicated to create optimal sensory conditions before surgery or, when surgery must be postponed, to reinforce fusion during the waiting interval. The functional

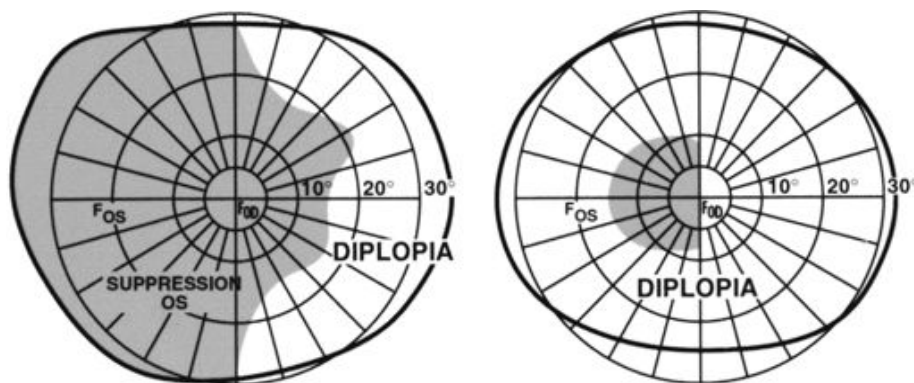


FIGURE 17–2. *Left*, Binocular visual field of a patient with right exotropia of 50 prism diopters. The suppression scotoma in the left eye overrides the midline and extends well into the nasal field when the binocular visual field is tested with a nondissociating technique consisting of a fixation light and striated glasses before both eyes of the patient. *Right*, When plotting the field with a dissociating dark-red filter over the left eye and a striated glass before both eyes, a hemianopic scotoma is detected which must be considered an artifact.

prognosis is poor when constant exotropia occurs in early infancy and when there is no history of intermittency. Preoperative treatment is not required.

CORRECTION OF THE REFRACTIVE ERROR AND THE USE OF MINUS LENSES. Significant refractive errors, especially astigmatism and anisometropic differences, should be corrected in patients with intermittent exodeviations to create sharp retinal images, which in turn increase the stimulus to fuse. Full correction is advisable in myopic patients to maintain active accommodative convergence. Whether hypermetropia should be fully corrected, partially corrected, or corrected at all depends entirely on its degree, the age of the patient, and the AC/A ratio. Since correction of any hypermetropic refractive error will decrease the demand on accommodative convergence and thus increase the exodeviation, each patient should be evaluated on an individual basis. As a rule, we do not correct a hypermetropia of less than +2.00D sph in children with exodeviations. In the older patient, correction of the hypermetropia is usually necessary to avoid refractive asthenopia, even though an underlying exophoria that was previously controlled by accommodative convergence then may become manifest and require therapy.

An exophoric patient with beginning presbyopia presents a special problem. As the accommodative range decreases, the exodeviation will increase and cause symptoms. Before one assesses the increased exodeviation in such patients, it is important to correct any underlying hypermetropia as well as prescribe the weakest bifocal lens that will permit comfortable near vision. If this fails to alleviate the patient's visual discomfort, we prescribe prisms base-in for near vision. Only about half of the exodeviation should be corrected prismatically to stimulate rather than relax accommodative convergence.

If the AC/A ratio is sufficiently high, minus lenses may be used to decrease an exodeviation by stimulating accommodative convergence.¹¹² In younger children with the convergence insufficiency type of exodeviation, minus lenses prescribed as lower segment bifocals may be of functional benefit as a temporizing measure, and in those with the divergence excess type of exodeviation, minus lenses prescribed as upper segment bifocals may be beneficial. Thus normal binocular stimulation can be reinforced while the child is awaiting surgery. Jampolsky^{90, p.150} makes the point

that 3D to 5D of accommodation stimulation with minus lenses is well tolerated by many children. He also observed that patients with orthophoria at near fixation and intermittent exotropia at distance fixation may become exophoric at near fixation under the influence of minus lenses.⁹¹ It is of interest that this initial esophoria is replaced by orthophoria within a matter of weeks. When the minus lenses are removed, an exodeviation may then be present at near fixation, indicating a transient change in the AC/A ratio. Jampolsky believes that surgical alignment of the eyes is facilitated by this change and advocates operating during this period. Caltrider and Jampolsky³⁴ reported that a significant number of patients from a group with intermittent exotropia treated by means of overcorrecting minus lenses manifested improved fusion as well as a decrease in their original deviation. This response persisted for as long as 1 year after therapy was discontinued in 70% of those who showed improvement. We use this form of therapy sparingly and, at most, only as a temporizing measure in patients with a high AC/A ratio. Stimulation of accommodation with minus lenses is tolerated well by younger children, does not cause myopia,¹¹¹ but may cause accommodative asthenopia as the child grows older and the amount of near work increases.⁶⁴

PRISMS. Although most ophthalmologists advocate the use of prisms in the surgically overcorrected exotropia (see consecutive esotropia, p. 372), some use prisms preoperatively to improve fusional control.^{148, 174, 177} Bérard¹¹ corrects one half to one third of the deviation in a preoperative trial to enforce bifoveal stimulation. Ravault and coworkers¹⁵³ claimed that surgery may be avoided in certain patients in whom a satisfactory functional result is obtained by means of full prismatic correction of the deviation, followed by gradual reduction of the prismatic power. Following surgery, Jampolsky⁸⁸ recommended overcorrection of a residual exodeviation with prisms to elicit diplopia and to stimulate fusion (see also Hardesty^{71, 72}). We do not use prisms preoperatively.

ORTHOPTICS. Knapp^{98, p.368} summarized the opinion of most strabismologists by stating that orthoptics should not be used as a substitute for surgery but rather as a supplement. With the exception of energetic preoperative treatment for amblyopia, we rarely use orthoptics before surgery. Even though some authors advocate such therapy, especially for suppression in patients with

intermittent deviations^{42, 83, 117, 160} and anomalous retinal correspondence,⁴⁰ it has not been proved that surgical results are functionally superior to those in patients who have not received orthoptics^{2, 126, 173} or that surgery can be avoided altogether by using this form of treatment. Flynn and coworkers⁵⁹ observed an improved sensory state and better motor control in a group of patients with intermittent exotropia who were treated with alternating occlusion. The dominant eye received occlusion more frequently than the non-dominant eye (see also Knapp⁹⁹ and Iacobucci and Henderson⁸⁴). We have occasionally found it beneficial to use alternating occlusion in lieu of surgery in patients with small angle intermittent exodeviations, as shown in Case 17-3.

CASE 17-3

A 5-year-old girl presented with a history of intermittent exotropia at distance fixation. Measurements showed orthotropia at near and an exophoria of 10^Δ distance fixation. The distance deviation was easily dissociated and the patient did not spontaneously re-fuse. The patch test was negative. An insignificant hypermetropic refractive error was present. Stereopsis at near was 60 seconds of arc on the Titmus test and no stereopsis could be elicited at distance with the Mentor B-VAT. In view of the small deviation at distance we decided against surgery for fear of causing an overcorrection. We ordered alternating occlusion instead and after 3 months the patient fused at near and distance. She had an esophoria of 3^Δ at near and distance. Stereopsis had improved to 15 seconds of arc at near and 60 seconds of arc at distance fixation. After 3 months without treatment the findings were the same.

Intensive orthoptic treatment may be indicated postoperatively when suppression persists or if a convergence insufficiency type of exodeviation is present. Inagaki and coworkers⁸⁶ reported abolishment of suppression and development of sensory and motor fusion by treatment consisting of preoperative simultaneous bifoveal stimulation with a checkerboard pattern in patients with constant and intermittent exotropia.

Surgical Treatment

INDICATIONS FOR SURGERY. The need for surgery is determined by the state of fusional control, the angle size of deviation, and the age of the patient. In patients with *manifest exotropia* present

at or shortly after birth with no history of intermittency, surgery should be performed as soon as reliable and constant measurements can be obtained, the patient can alternate freely, and the angle of deviation measures at least 15^Δ. We usually operate on such children when they are between 1 and 2 years of age. In adults with a large angle constant exodeviation, surgery is performed as soon as the diagnosis has been established. The prognosis for return of normal binocular function in such cases is poor when the deviation has been present since early childhood. Such patients usually retain a residual small angle exotropia with alternating fixation. However, exceptions to this rule do occur, and we have seen several patients who had a history of manifest exotropia for many years in whom unexpected and fortuitous return of normal binocular vision with stereopsis occurred after surgical alignment of the eyes (see also Ball and coworkers⁹).

Surgical treatment of *intermittent exotropia* or of constant exotropia preceded by a long period of intermittency is directed at normalization of binocular function. There is good evidence for an improvement of distance stereoacuity after surgery.^{144, 186} Unless there is definite evidence of existing defective binocular vision, surgery should be preceded by several months of observation since the disease does not progress in all patients^{68, 128, 135} (see p. 359). Signs of progression include gradual loss of fusional control as evidenced by increasing frequency of the manifest phase of the strabismus. A patient whose eyes turn outward only occasionally and who is asymptomatic does not need surgery. However, when the exotropia occurs during more than 50% of waking hours or causes asthenopic problems, surgery should be performed. Other signs of progression are development of a secondary convergence insufficiency, an increase in size of the basic deviation, development of suppression as evidenced by absence of diplopia during the manifest phase of the strabismus, or decrease of stereoacuity. If one or several of these signs or symptoms are present when the patient is first examined or if they develop while the patient is under observation, surgery must be considered. An asthenopic patient with exophoria may require surgery if the deviation cannot be controlled with prisms.

The most desirable age at which surgery should be performed for intermittent exodeviations has been a matter of some dispute. Jampolsky⁹⁰ prefers to delay surgery in visually immature infants to

avoid overcorrection. In the interval, he reinforces fusion with minus lenses or prevents development of suppression by means of alternating occlusion. On the other hand, Knapp⁹⁸ is an advocate of early surgery for treatment of intermittent exotropia, a view shared by other authors.^{3, 50, 146, 151, 156} More recently, however, Baker and coworkers⁸ found in a comparative study that patients operated on after the age of 4 years had better functional results.

We prefer to delay surgical intervention for *intermittent* exotropia in young children, since we share Jampolsky's concern about the effects of a consecutive esotropia in a visually immature child. Unfortunately, in such patients, good preoperative visual acuity in each eye with normal stereoacuity may have been exchanged for persistent monocular esotropia with amblyopia, loss of stereopsis, and the development of anomalous retinal correspondence. Edelman and coworkers⁵² reported that 5 of 24 children who developed consecutive esotropia after surgery for exotropia before the age of 4 years became amblyopic. Even when surgery was delayed until the age of 4 to 6 years, amblyopia still occurred in 3 of 39 patients.

Although the prevalence of consecutive constant esotropia in patients under 5 years of age has been reported to be only 10%,^{96, 120, 151} we have witnessed this unfortunate event in a sufficient number of our patients to advocate delaying surgery until the child has reached at least 4 years of age. In the interim, binocular vision should be reinforced with prisms base-in or minus lenses. Surgery at an earlier age should be considered only if there is a rapid functional deterioration of fusional control in spite of nonsurgical therapy or if the deviation is constant.

Finally, the size of the deviation determines the decision to operate. The angle of primary exodeviations generally exceeds 20^Δ, and unlike the situation in esotropia, small angle exodeviations are rare. If for functional reasons surgery is indicated, the deviation should measure at least 15^Δ at distance or near fixation before a procedure is carried out. Patients are seldom self-conscious or embarrassed by strabismus of this magnitude and surgery usually is not performed unless the deviation measures at least 20^Δ to 25^Δ.

GOALS OF SURGERY. Although the aim of most operations for strabismus is to align the eyes as nearly as possible, many ophthalmologists have proposed that for intermittent exodeviations a small surgical overcorrection is desirable, since it

appears that functional results will be more stable.^{12; 41; 53; 64; 81, p. 645; 90; 98; 152; 154; 164; 185} Raab and Parks¹⁵² proposed that the surgeon should strive for an overcorrection of 10^Δ to 20^Δ. Lesser degrees of overcorrection have been associated with recurrence of the exodeviations after some time has elapsed. A higher degree of overcorrection will necessitate further surgery for consecutive esotropia. Proponents of deliberate overcorrection cite the therapeutic value of postoperative diplopia in stimulating development of fusional vergences and thus in stabilizing eventual alignment of the eyes. On the other hand, it has also been shown that an initial overcorrection does not guarantee a desirable final outcome.¹⁵⁹ Dunlap⁵¹ observed that the difficult element in striving for overcorrection is knowing how to produce some, but not too much of it. In one series of his patients the prevalence of unintended overcorrection was 40%, whereas Cooper,⁴¹ who deliberately attempted to overcorrect his patients, reported a prevalence of only 37%. Since introduction of adjustable sutures this unpredictability has become less of a problem.

We are in agreement with those who believe that a small angle of consecutive esotropia in the immediate postoperative phase is desirable and tends to stabilize a functional result, even though such deviations occasionally may persist for a long time and cause problems of management (see Case 17-4). However, we have been unable to accomplish this goal other than by pure chance or by postoperative suture adjustment.

As pointed out above, surgical overcorrection, as beneficial as it may be in the older child or adult, must be avoided under all circumstances in visually immature children in view of the disastrous consequences of a small angle esotropia in this age group. On the other hand, Schlossman and coworkers¹⁶² concluded from their data that adult patients do better with slight undercorrection rather than overcorrection after surgery, provided the residual exodeviation remains under 15^Δ.

Although it may be difficult or even impossible to plan surgery to achieve a small, beneficial amount of overcorrection, there may be ways to avoid overcorrection in cases in which it is undesirable. The importance of including lateral gaze incomitance into the surgical planning has been mentioned.

CHOICE OF PROCEDURE. Burian^{26, 31} emphasized that correct differentiation between the true and simulated divergence excess patterns is essential

for proper choice of surgical procedures. We have followed his suggestions and still advocate for exotropia of the *true divergence excess type* a recession of both lateral rectus muscles and for *basic exotropia* or the *simulated divergence excess pattern* a recession of the lateral rectus muscle with resection of the ipsilateral medial rectus muscle on the nondominant eye. This approach has worked well in our hands.¹³⁶ However, a recent study by Kushner¹⁰⁸ has shown that bilateral lateral rectus recessions may be equally effective in simulated divergence excess and in basic exotropia. Others have reported that there are no differences between the results of asymmetrical (recession of the lateral rectus muscle and resection of the medial rectus muscle of one eye) and symmetrical (recession of both lateral rectus muscles) surgery in intermittent exotropia even though the immediate postoperative results seemed better with asymmetrical surgery.¹⁸⁷ Some authors¹¹⁴ prefer a resection of both medial rectus muscles for most forms of exotropia. Others have reported satisfactory results after recession of only one lateral rectus muscle.^{56, 133, 143, 176} We reserve this procedure for patients with a dissociated exodeviation (see Chapter 18).

Further long-term prospective studies comparing these different surgical methods in the treatment of the various manifestations of exotropia are necessary to define the real advantages of one procedure over the other. Until the time that such data become available we see no reason to deviate from Burian's recommendations, which have served us well thus far.

For an exodeviation larger at near than at distance fixation (*convergence insufficiency type*) we resect both medial rectus muscles, a procedure that is often followed by a temporary overcorrection of which the patient must be apprised. The amount of resection ranges from 3 to 6 mm, depending on the size of the deviation. Others have proposed asymmetrical surgery for this condition, placing the emphasis of the operation on the resection of one medial rectus and performing lesser amounts of recession on its antagonist, the lateral rectus muscle.¹⁰⁴ This method has been reported to collapse the near-distance differences and as having a low risk of postoperative diplopia. A different approach was taken by Snir and coworkers,¹⁶⁶ who use slanted recessions of the lateral rectus muscles in patients with an exodeviation greater at distance than at near. The upper edge of the muscle insertion was recessed according to the distance exode-

viation and the lower edge according to the near deviation. These authors claim that this procedure is superior to standard recessions in reducing the exodeviation at distance and near fixation and in collapsing the difference between them.

A special surgical approach has been proposed for *intermittent exotropia with a high AC/A ratio*.²¹ It consists of a bilateral lateral rectus muscle recession combined with a posterior fixation suture on both medial rectus muscles. Although theoretically interesting, this procedure may not be without its risks in the long term for patients with normal binocularity.

Weakening procedures on all four oblique muscles, which are frequently found to be apparently overacting in large angle exotropia have been advocated⁹² but are not used by us. We find that such overaction of all oblique muscles is not a true overaction and often disappears after treating the exotropia by conventional surgery of the horizontal rectus muscles.

In the case of asymmetrical surgery we prefer to operate on the nondominant eye. It has been suggested by Mitsui and coworkers¹²⁵ that better surgical results are obtained when the operation is done on the dominant eye. However, Lennerstrand¹¹⁶ was unable to confirm the superiority of this over the conventional approach to do surgery on the nondominant eye or on both lateral rectus muscles.

An adult patient with a *large angle exotropia* of an amblyopic eye may require special management. Rayner and Jampolsky¹⁵⁴ recommended surgery on the amblyopic eye consisting of recession of the lateral rectus muscle to the equator, recession or T-closure of the temporal conjunctiva to release its restrictions, and maximal resection of the medial rectus muscle up to 14 mm to hold the eye in alignment. According to these authors, the disadvantage of postoperative limitation of abduction, created by the excessive amount of resection of the medial rectus muscle, may be viewed as an advantage in such cases since it prevents recurrence of the deviation.

Surgery on one eye consisting of recession of the lateral rectus muscle and resection of the medial rectus muscle has been supplemented with intraoperative injection of 10 units of botulinum toxin, type A (Botox) into the lateral rectus muscle.¹⁴⁵ More cases and longer follow-up are required before this procedure can be recommended. Botulinum toxin injection into the lateral rectus muscles has also been advocated as an alternative

to surgery in intermittent exotropia.¹⁶⁷ The long-term stability of the results seem questionable to us.

For reasons that are discussed further in Chapter 26, we are not convinced of the values of dose-response curves and tables. However, provided there is no incomitance in lateral gaze and visual acuity is equal in both eyes, we use amounts of recession of the lateral rectus muscles that are similar to those used by other strabismologists here and abroad^{12, 147, 157} (Table 17-1). In large angle exotropia (greater than 50^Δ) it may be necessary to recess both lateral rectus muscles maximally and resect one or both medial rectus muscles in one session.^{6, 13, 68, 89, 171} The *prism adaptation test* (PAT) is of little help in deciding how much surgery to do to each muscle for exodeviations since no differences in surgical results were found between responders to this test, in whom the surgical dosage was increased, and non-responders.¹⁴²

We have found *adjustable sutures* helpful in patients with large angle exotropia but rarely use them in intermittent exotropia. In this condition motor fusion may tend to mask a residual deviation during adjustment. The result is a patient with surgical undercorrection who would have benefited from a postoperative adjustment. Intraoperative adjustment has also been suggested.³³ However, we believe that the eye position under general anesthesia is too variable to rely on this information for modification of the original surgical plan.

RESULTS OF SURGERY. Surgical results, in terms of restoration of binocular function and conversion of a deviation from constant heterotropia to heterophoria, vary according to the binocular state before surgery. Table 17-2 lists results reported

TABLE 17-1. Surgical Dosage of Recession of Both Lateral Rectus Muscles*

Deviation (Δ)	Recession (mm)
15	4
20	5
25	6
30	7
35	7
40	8
≥ 50	7 + Resection of one medial rectus

*Modified from Parks MM, Mitchell P: Concomitant exodeviations. In Duane TD ed: *Clinical Ophthalmology*, Vol 1. Philadelphia, JB Lippincott, 1988, p 1.

TABLE 17-2. Effect of Surgery on Binocular Function in Exodeviations

Authors	n	Satisfactory Results* (%)
Beneish & Flanders ¹⁰	67	60
Burian & Spivey ³¹	200	40
Hardesty et al ⁷⁵	100	78
von Noorden ¹³⁶	49	77
Pratt-Johnson & Wee ¹⁵⁰	100	41
Raab & Parks ¹⁵²	145	52
Richard & Parks ¹⁵⁶	111	95
Windsor ¹⁸¹	115	58
Winter et al ¹⁸²	85	82

*Defined by most authors listed as fusion at near and distance.

by different authors. The variance of success rates shown in the table can be explained by different lengths of follow-up and criteria used for a cure. We define cure as restoration of stable fusion at near and distance fixation in an asymptomatic patient. As may be expected, in patients without suppression and preoperative diplopia in whom strabismus is manifest only occasionally, the prognosis is better than in those with constant exotropia of long duration. Although it is sufficient for practical purposes to define a cure as reestablishment of fusion, it is of interest and underlines the complex nature of exodeviations that more refined testing will reveal minor defects of normal binocular vision in a high percentage of patients with intermittent exodeviations after treatment. Baker and Davies⁷ reported defective stereopsis in most of their patients before and after surgical alignment of the eyes. Stimulated by this report, Haase and de Decker⁶⁹ studied 156 patients with intermittent exotropia in whom a wide array of sensory tests had been performed. Their findings are astonishing indeed. Microexotropia occurred in 32%, subnormal binocular vision (see Chapter 16) in 50%, and a complete sensory cure in only 17% of their patients.

Since becoming aware of these studies, we have reexamined a group of patients who were orthotropic or slightly esophoric at 33 cm and 6 m fixation distances and had formerly been classified as surgical cures. The examination involved fixation maintained on a red light at the end of a 25-m-long corridor.¹³⁹ In most instances a small constant exotropia was present under these circumstances, a finding that is incompatible with a complete cure. These observations have reinforced our opinion that complete restoration of normal

and stable binocular vision in patients with intermittent exotropia presents a major challenge and that the results of treatment are often frustrating for the ophthalmologist.

In conclusion, exotropia is a condition which can be improved and, in many instances, controlled by surgery. However, the prognosis for a long-term cure must be guarded since recurrences are common. In this respect the condition is quite different from normosensorial esotropia where timely diagnosis and treatment may result in a complete and permanent cure.

MANAGEMENT OF UNDERCORRECTIONS.

Most patients with persistent intermittent exotropia require additional surgery. The residual deviation is apparent in some of them immediately after the operation. In others it does not appear until months or even years after an initially satisfactory result. Use of base-in membrane prisms of a power greater than the residual deviation has been advocated to provoke convergence and thus lessen the exodeviation.^{73, 74, 101, 129} Hardesty and coworkers⁷⁵ emphasized the need to restore fusion with prisms that equal the deviation as a means of improving fusional amplitudes before the second operation.

MANAGEMENT OF OVERCORRECTIONS (CONSECUTIVE ESOTROPIA). The reported prevalence of surgical overcorrections in patients with exodeviations varies according to different authors (6%,⁷⁵ 8%,⁵⁸ 10%,³¹ 11%,¹³⁶ 17%,¹¹⁵ and 20%⁵¹). A large overcorrection with gross limitation of ocular motility of the surgically treated eye on the day after surgery may require immediate surgical intervention. Mechanical factors, such as excessive resection of the medial rectus or disinsertion of the lateral rectus, may be responsible for causing this complication, which is discussed further in Chapter 26.

Therapy for smaller degrees of esotropia, which are usually comitant in nature, is one of watchful waiting. A postoperative esodeviation of 10^Δ to 15^Δ may disappear completely with time and is, as stated above, desirable, but larger deviations tend to increase. In any case, a second operation should not be performed until at least 6 months have elapsed, except when there are significant limitations of ductions that cause incomitance in lateral gaze.¹²¹ During the waiting period several nonsurgical therapeutic measures may be carried out that will decrease the postoperative deviation

or, if this is not possible, maintain fusion and keep the patient comfortable.

No therapy is advocated for the first 2 weeks after surgery for small degrees of overcorrection. Should diplopia persist after this time, miotics or a temporary prescription for a hypermetropic refractive error may decrease the deviation to the point where the patient will fuse. Patients with a high AC/A ratio will respond well to slight overcorrection of the hypermetropic refractive error; if the deviation is larger at near fixation, the prescription of additional plus lenses in the form of bifocals may be beneficial.

If this therapy is unsuccessful, alternating occlusion not only will eliminate diplopia but also will tend to decrease the angle of the consecutive esotropia. A great deal of patience is required by the physician in treating persistent consecutive esodeviations since spontaneous reduction of the postoperative angle may require a considerable length of time, as illustrated by case 17-4.

CASE 17-4. Age: 9 years

August 1964

Distance: 35^Δ XT

Near: 18^Δ X(T)

Visual acuity: OD 6/7.5

OS 6/7.5

Refraction: OD - 1.50 D sph + 0.50 cyl ax 180°

OS - 1.50 D sph + 0.62 cyl ax 180°

After 1 hour of occlusion: 50^Δ XT at near

Diagnosis: simulated divergence excess

October 1964

Operation: 7 mm recession lateral rectus muscle OU

December 1964

Distance: 6^Δ ET

Near: 7^Δ ET

Complains about uncrossed diplopia at distance and near fixation

Rx: 0.125% echothiophate iodide (Phospholine Iodide) OU every other night

June 1965

Distance: 5^Δ ET

Near: 8^Δ E(T)

Complains about diplopia or distance fixation interfering with school work

November 1965

Measurements unchanged

Still has diplopia at distance

Rx: discontinue miotics

Start alternating occlusion (OD one day, OS one day)

December 1966

Distance: 2^Δ exophoria

Near: 4^Δ exophoria
 Rx: Discontinue alternating occlusion
 April 1967
 Distance: orthophoria
 Near: orthophoria
 Stereoacuity: 80 seconds of arc

When fusion must be maintained under all circumstances, as in visually immature children or for occupational reasons in adults, prisms base-out are the preferable treatment.^{72, 115} Press-on Fresnel membrane prisms have eliminated many difficulties previously encountered with this form of therapy. Frequent adjustments to adapt the prismatic correction to the changing postoperative angle can now be made at nominal cost to the patient. Hardy and coworkers⁷⁵ reported that a consecutive esotropia of less than 15^Δ can be cured with prism therapy alone, whereas surgery usually becomes necessary for larger esodeviations. Our criteria for reoperation depend on the following factors: nonacceptance of conservative treatment by a patient, lack of improvement of the basic deviation in spite of prisms, increase of the deviation in spite of prisms, persistence of diplopia because of incomitance, and limitation of ductions.¹²¹ In fact, persistent limitation of ductions during the postoperative period in an overcorrected patient mitigates against delay of reoperation for a 6-month period, since, for example, a surgical overcorrection caused by a tight medial rectus or excessively recessed lateral rectus muscle does not improve with time. Botulinum toxin injections in the medial rectus muscle have also been shown to be effective in treating consecutive esotropia in patients with retained motor fusion.⁴⁶

Dissociated Exodeviations

Dissociated exodeviations are discussed together with dissociated vertical deviations in Chapter 18.

Secondary Exodeviations

Sensory Exotropia

Sensory exotropia occurs as a result of primary sensory deficit such as anisometropia, unilateral aphakia, and unilateral visual impairment brought about by organic causes, followed by partial or complete disruption of fusion. Recently, vitreous hemorrhage has been reported as a cause of sen-

sory exotropia.⁶³ Development of a sensory exotropia or esotropia under these circumstances is discussed on page 346. Characteristically, the deviation is unilateral and involves the amblyopic eye. Surgery is usually required to restore normal facial configuration; surgical management is discussed on page 369.

Consecutive Exotropia

Consecutive exotropia arises either spontaneously in a formerly esotropic patient or iatrogenically after surgical overcorrection. Spontaneous change from esotropia to exotropia usually can be associated with poor vision of the deviating eye (sensory exotropia), even though all cases cannot be explained on this basis. High hypermetropia in an esotropic patient may be another contributing factor since consecutive exotropia is not uncommon in this group of patients (see Chapter 16). Treatment is surgical and indications for surgery are cosmetic.

Consecutive exotropia after surgical overcorrection of an esodeviation is discussed in Chapter 16.

REFERENCES

1. Abraham SV: Nonparalytic Strabismus, Amblyopia and Heterophoria. Los Angeles, Pan American, 1966, p 155.
2. Altizer LB: The nonsurgical treatment of exotropia. *Am Orthopt J* 22:71, 1972.
3. Asbury T: The role of orthoptics in the evaluation and treatment of intermittent esotropia. In Arruga A, ed: *International Strabismus Symposium*, University of Gießen, Germany 1966. Basel, S Karger, 1968, p 331.
4. Awaya S, Nozaki H, Itoh T, Hanada K: Studies of suppression in alternating constant exotropia and intermittent exotropia with reference to fusional background. In Moore S, Mein J, Stockbridge L, eds: *Orthoptics: Past, Present, Future*. Miami, Symposia Specialists, 1976, p 531.
5. Awaya S, Sugawara M, Komiyama K, Ikeyama K: Studies on stereoacuity in four constant exotropes with good stereoacuity, with a special reference to the Titmus stereo test and EOG analysis. *Acta Soc Ophthalmol Jpn* 83:425, 1979.
6. Azar RF: Surgical management of exotropia exceeding 70 prism diopters. *Ann Ophthalmol* 3:159, 1971.
7. Baker JD, Davies GT: Monofixational intermittent esotropia. *Arch Ophthalmol* 97:93, 1979.
8. Baker JD, Schweers M, Petrunak J: Is earlier surgery a sensory benefit in the treatment of intermittent exotropia? In Lennerstrand G, ed: *Advances in Strabismology*. Proceedings of the Eighth Meeting of the International Strabismological Association, Maastricht, Dept. 10–12, 1998. Buren, The Netherlands, Aeolus Press, 1999, p 289.
9. Ball A, Drummond GT, Pearce WG: Unexpected stereoacuity following surgical correction of long-standing horizontal strabismus. *Can J Ophthalmol* 28:217, 1993.
10. Beneish R, Flanders M: The role of stereopsis and early postoperative alignment in long-term results of intermittent exotropia. *Can J Ophthalmol* 29:119, 1994.

11. Bérard PV: Prisms—their therapeutic use in concomitant strabismus with normal correspondence. In Feels P, ed: First International Congress of Orthoptists. St Louis, Mosby—Year Book, 1968, p 77.
12. Berland JE, Wilson ME, Saunders RA: Results of large (8–9 mm) bilateral lateral rectus muscle recession for exotropia. *Binocular Vision. Strabismus Q* 13:97, 1998.
13. Berke R: Principles, technique and complications of horizontal nonparalytic nonaccommodative strabismus. In *Strabismus. Symposium of the New Orleans Academy of Ophthalmology*. St Louis, Mosby—Year Book, 1962, p 178.
14. Bielschowsky A: Divergence excess. *Arch Ophthalmol* 12:157, 1934.
15. Bielschowsky A: Exophorie und “Divergenzexzess.” *Klin Monatsbl Augenheilkd* 92:11, 1934.
16. Biglan AW, Davis JS, Cheng KP, Pettapiece MC: Infantile exotropia. *J Pediatr Ophthalmol Strabismus* 33:79, 1996.
17. Binder HF, Arndt CL: Binocularity in anomalous retinal correspondence. *Acta Ophthalmol* 41:653, 1963.
18. Blodi FC, Van Allen M: Electromyography in intermittent esotropia; recordings before, during and after corrective operation. *Doc Ophthalmol* 26:21, 1962.
19. Breinin GM: The nature of vergence revealed by electromyography. *Arch Ophthalmol* 58:623, 1957.
20. Breinin GM, Moldaver J: Electromyography of the human extraocular muscles. *Arch Ophthalmol* 54:200, 1955.
21. Brodsky MC, Fray KJ: Surgical management of intermittent exotropia with high AC/A ratio. *J Am Assoc Pediatr Ophthalmol Strabismus* 2:330, 1998.
22. Brown HW: Aids in the diagnosis of strabismus. In *Strabismus. Symposium of the New Orleans Academy of Ophthalmology*. St Louis, Mosby—Year Book, 1962, p 231.
23. Brown HW: Discussion of paper by Burian HM, Franceschetti AT: Evaluation of diagnostic methods for the classification of exodeviations. *Trans Am Ophthalmol Soc* 68:56, 1970.
24. Burian HM: Intermittent (facultative) divergent strabismus. Its influence on visual acuity and the binocular visual act. *Am J Ophthalmol* 28:525, 1945.
25. Burian HM: The sensorial retinal relationship in comitant strabismus. *Arch Ophthalmol* 37:336,504,648, 1947.
26. Burian HM: Selected problems in the diagnosis and treatment of the neuromuscular anomalies of the eyes. In *II Curso Internacional de Oftalmologia*. Barcelona, Publicaciones del Instituto Barranquer, 1958, p 25.
27. Burian HM: Exodeviations: Their classification, diagnosis, and treatment. *Am J Ophthalmol* 62:1161, 1966.
28. Burian HM: Pathophysiology of exodeviations. In Manley DR, ed: *Symposium on Horizontal Ocular Deviations*. St Louis, Mosby—Year Book, 1971, p 119.
29. Burian HM, Franceschetti AT: Evaluation of diagnostic methods for the classification of exodeviations. *Trans Am Ophthalmol Soc* 68:56, 1970.
30. Burian HM, Smith DR: Comparative measurement of exodeviations at twenty and one hundred feet. *Trans Am Ophthalmol Soc* 69:188, 1971.
31. Burian HM, Spivey BE: The surgical management of exodeviations. *Am J Ophthalmol* 59:603, 1965.
32. Caldeira JA: Lateral gaze incommittance in surgical exodeviations: Clinical features. *Binocular Vision Strabismus Q* 7:75, 1992.
33. Caldeira JAF: Stage I intraoperative adjustment of eye muscle surgery for exodeviations based on eye position during general anesthesia: A prospective study of 35 patients. *Binocular Vision Strabismus Q* 12:253, 1997.
34. Caltrider N, Jampolsky A: Overcorrecting minus lens therapy for treatment of intermittent exotropia. *Ophthalmology* 90:1160, 1983.
35. Campos EC: Binocularity in comitant strabismus: Binocular visual field studies. *Doc Ophthalmol* 53:249, 1982.
36. Campos EC, Cipolli C: Binocularity and photophobia in intermittent exotropia. *Percept Mot Skills* 74:1168, 1992.
37. Cass EE: Divergent strabismus. *Br J Ophthalmol* 21:538, 1937.
38. Chamberlain W: Discussion of paper by Burian HM, Franceschetti AT: Evaluation of diagnostic methods for the classification of exodeviations. *Trans Am Ophthalmol Soc* 68:56, 1970.
39. Chavasse FE: *Worth's Squint or the Binocular Reflexes and the Treatment of Strabismus*. London, Baillière, Tindall & Cox, 1939.
40. Ciancia AO, Melek N: A new treatment of anomalous retinal correspondence in intermittent esotropia. In Fells P, ed: *The First Congress of the International Strabismological Association*. St Louis, Mosby—Year Book, 1971, p 106.
41. Cooper EL: Purposeful overcorrection in exotropia. In Arruga A, ed: *International Strabismus Symposium*, University of Giessen, Germany, 1966. Basel, S Karger, 1968, p 311.
42. Cooper EL, Leyman IA: The management of intermittent exotropia. A comparison of the results of surgical and nonsurgical treatment. In Moore S, Mein J, Stockbridge L, eds: *Orthoptics: Past, Present, Future*. Transactions of the Third International Orthoptic Congress, New York, Stratton Intercontinental, 1976, p 563.
43. Chew E, Remaley NA, Tamboli A, et al: Risk factors for esotropia and exotropia. *Arch Ophthalmol* 112:1349, 1994.
44. Costenbader FD: The physiology and management of divergent strabismus. In Allen JH, ed: *Strabismic Ophthalmic Symposium I*. St Louis, Mosby—Year Book, 1950.
45. Dannheim E: *Panoramasehen bei Strabismus divergens*. *Orthopt Pleopt* 6:17, 1978.
46. Dawson ELM, Marshman WE, Lee JP: Role of botulinum toxin A in surgically overcorrected exotropia. *J Am Assoc Pediatr Ophthalmol Strabismus* 3:269, 1999.
47. de Decker W: Heterotropie (manifeste Strabismus). In Kaufmann H, ed: *Strabismus*. Stuttgart, Ferdinand Enke Verlag, 1986, p 139.
48. Donders FC: An essay on the nature and the consequences of anomalies of refraction. Oliver CA, ed: Philadelphia, P Blakiston's Son & Co, 1899, p 59.
49. Duane A: A new classification of the motor anomalies of the eyes based upon physiological principles, together with their symptoms, diagnosis and treatment. *Ann Ophthalmol Otolaryngol* 5:969, 1896; 6:84,247, 1897.
50. Dunlap EA: Overcorrections in esotropia surgery. In Arruga A, ed: *International Strabismus Symposium*, University of Giessen, Germany, 1966. Basel, S Karger, 1968, p 319.
51. Dunlap EA: Overcorrections in horizontal strabismus surgery. In *Symposium on Strabismus*. Transactions of the New Orleans Academy of Ophthalmology. St Louis, Mosby—Year Book, 1971, p 255.
52. Edelman PM, Brown MH, Murphree AL, Wright KW: Consecutive esotropia . . . then what? *Am Orthopt J* 38:111, 1988.
53. Eino D, Kraft SP: Postoperative drifts after adjustable-suture strabismus surgery. *Can J Ophthalmol* 32:163, 1997.
54. Eustace P, Wesson ME, Druby DJ: The effect of illumination on intermittent divergent squint of the divergence excess type. *Trans Ophthalmol Soc UK* 93:559, 1973.
55. Fahle M: Naso-temporal asymmetry of binocular inhibition. *Invest Ophthalmol Vis Sci* 28:1016, 1987.
56. Feretis D, Mela E, Vasilopoulos G: Excessive single lateral rectus muscle recession in the treatment of inter-

- mittent exotropia. *J Pediatr Ophthalmol Strabismus* 27:315, 1990.
57. Fletcher M: Natural history of idiopathic strabismus. In Symposium on Strabismus. Transactions of the New Orleans Academy of Ophthalmology. St Louis, Mosby-Year Book, 1971, p 15.
 58. Fletcher MC, Silverman SJ: Strabismus. I. A summary of 1110 consecutive cases. *Am J Ophthalmol* 61:86, 1966.
 59. Flynn JT, McKenney S, Rosenhouse M: Eine Behandlungsform des intermittierenden Begleitschielens. *Klin Monatsbl Augenheilkd* 167:185, 1975.
 60. Forrer HT: Retinal correspondence in intermittent exotropia. In Moore S, Mein J, Stockbridge L, eds: Orthoptics: Past, Present, Future, Transactions of the Third International Orthoptic Congress. New York, Stratton Intercontinental, 1976, p 547.
 61. Frandsen AD: Occurrence of squint. A clinical-statistical study on the prevalence of squint and associated signs in different groups and ages of the Danish population. *Acta Ophthalmol (kbb) Suppl* 62:1, 1960.
 62. Friedman Z, Neumann E, Hyams SW, Peleg B: Ophthalmic screening of 38,000 children, age 1 to 2½ years, in child welfare clinics. *J Pediatr Ophthalmol Strabismus* 17:261, 1980.
 63. Fujikado T, Ohmi G, Ikeda T, et al: Exotropia secondary to vitreous hemorrhage. *Graefes Arch Clin Exp Ophthalmol* 235:143, 1997.
 64. Graefe A von: Über musculäre Asthenopie. *Graefes Arch Clin Exp Ophthalmol* 8:314, 1862.
 65. Graefe E: Messungen von Heterophorien unter verschiedenen Umfeldleuchtdichten. Dissertation, University Eye Clinic, Hamburg-Eppendorf, Hamburg, 1967.
 66. Graham PA: Epidemiology of strabismus. *Br J Ophthalmol* 58:224, 1974.
 67. Gregersen E: The polymorphous exo patient. Analysis of 231 consecutive cases. *Acta Ophthalmol* 47:579, 1969.
 68. Guibor G: The surgical treatment of exotropia resulting from anterior internuclear ophthalmoplegia. *Am J Ophthalmol* 33:1840, 1950.
 69. Haase W, Decker W de: Binokulare sensorische Defekte beim Strabismus divergens intermittens. *Klin Monatsbl Augenheilkd* 179:81, 1981.
 70. Hall IB: Primary divergent strabismus. Analysis of aetiological factors. *Br Orthopt J* 18:106, 1961.
 71. Hardesty HH: Treatment of recurrent intermittent exotropia. *Am J Ophthalmol* 60:1036, 1965.
 72. Hardesty HH: Treatment of overcorrected intermittent exotropia. *Am J Ophthalmol* 66:80, 1968.
 73. Hardesty HH: Treatment of under- and over-corrected intermittent exotropia with prism glasses. *Am Orthopt J* 19:110, 1969.
 74. Hardesty HH: Prisms in the management of intermittent exotropia. *Am Orthopt J* 22:22, 1972.
 75. Hardesty HH, Boynton JR, Keenan JP: Treatment of intermittent exotropia. *Arch Ophthalmol* 96:268, 1978.
 76. Helveston EM: The use and "abuse" of the +3.00 D lenses (editorial). *J Pediatr Ophthalmol Strabismus* 11:175, 1974.
 77. Herzau V: Untersuchungen über das binokulare Gesichtsfeld Schielender. *Doc Ophthalmol* 49:221, 1980.
 78. Hiles DA, Davies GT, Costenbader FD: Long-term observations on unoperated intermittent exotropia. *Arch Ophthalmol* 80:436, 1968.
 79. Holland G: Häufigkeit und Vorkommen der anomalen Netzhautkorrespondenz. *Graefes Arch Clin Exp Ophthalmol* 166:559, 1964.
 80. Holland G: Über Zeitpunkt und Ursache des frühkindlichen Schielens. *Klin Monatsbl Augenheilkd* 147:498, 1965.
 81. Hugonnier R, Crayette-Hugonnier S: Strabismus, Hetero-
phoria, Ocular Motor Paralysis. *Clinical Ocular Muscle Imbalance*. Translated and edited by Véronneau-Troutman S. St Louis, Mosby-Year Book, 1969, p 201.
 82. Hunter DG, Ellis FJ: Prevalence of systemic and ocular disease in infantile exotropia. *Ophthalmology* 106:1951, 1999.
 83. Hurtt J: The selection of cases for orthoptics and pleoptics in the United States. In First International Congress of Orthoptists. St Louis, Mosby-Year Book, 1968, p 83.
 84. Iacubucci I, Henderson JW: Occlusion in the preoperative treatment of exodeviations. *Am Orthopt J* 15:42, 1965.
 85. Ikeyama K, Awaya S: Studies on stereoacuity by the Titmus stereotest with alternate presentation to each eye through the liquid crystal shutter. *Acta Soc Ophthalmol Jpn* 83:2021, 1979.
 86. Inagaki Y, Awaya S, Yagasaki T, Sato M: Effect of the checkerboard pattern stimulator on sensory fusion in exotropia. *Folia Ophthalmol Jpn* 44:825, 1993.
 87. Ing MR, Stephanie W, Pang L: The racial distribution of strabismus. In Reinecke RD, ed: Strabismus. Third Congress of the International Strabismological Association, Kyoto, Japan. New York, Grune & Stratton, 1978, p 107.
 88. Jampolsky A: Characteristics of suppression in strabismus. *Arch Ophthalmol* 54:683, 1955.
 89. Jampolsky A: Surgical management of exotropia. *Am J Ophthalmol* 46:646, 1958.
 90. Jampolsky A: Management of exodeviations. In Strabismus. Symposium of the New Orleans Academy of Ophthalmology. St Louis, Mosby-Year Book, 1962.
 91. Jampolsky A: Ocular deviations. *Int Ophthalmol Clin* 4:567, 1964.
 92. Jampolsky A: Ocular divergence mechanisms. *Trans Am Ophthalmol Soc* 65:730, 1970.
 93. Jampolsky A, Flom BC, Weymouth FS, Moses LE: Unequal corrected visual acuity as related to anisometropia. *Arch Ophthalmol* 54:893, 1955.
 94. Jenkins R: Demographics: Geographic variations in the prevalence and management of exotropia. *Am Orthopt J* 42:82, 1992.
 95. Joose MV, Simonsz HJ, van Minderhout EM, et al: Quantitative visual fields under binocular viewing conditions in primary and consecutive divergent strabismus. *Graefes Arch Clin Exp Ophthalmol* 237:535, 1999.
 96. Keech RV, Stewart SA: The surgical overcorrection of intermittent exotropia. *J Pediatr Ophthalmol Strabismus* 27:218, 1990.
 97. Kii T, Nakagawa T: Natural history of intermittent exotropia—statistical study of preoperative strabismic angle in different age groups. *Acta Soc Ophthalmol Jpn* 96:904, 1992.
 98. Knapp P: Divergent deviations. In Allen JH, ed: Strabismic Ophthalmic Symposium II. St Louis, Mosby-Year Book, 1958, p 354.
 99. Knapp P: Treatment of divergent deviations. In Allen JH, ed: Strabismic Ophthalmic Symposium II. St Louis, Mosby-Year Book, 1958, p 364.
 100. Knapp P: Management of exotropia. In Symposium on Strabismus. Transactions of the New Orleans Academy of Ophthalmology. St Louis, Mosby-Year Book, 1971, p 233.
 101. Knapp P: Use of membrane prisms. *Trans Am Acad Ophthalmol Otolaryngol* 79:718, 1975.
 102. Kommerell G: In discussion of Mitsui Y, Tamura O, Bérard PV, Reydy R: Optomotor effect in esotropia. In Reinecke RD, ed: Strabismus II. Proceedings of the Fourth Meeting of the International Strabismological Association, Asilomar. New York, Grune & Stratton, 1982, p 439.
 103. Kornder LD, Nursey JN, Pratt-Johnson JA, Beattie A:

- Detection of manifest strabismus in young children. 2. A retrospective study. *Am J Ophthalmol* 77:211, 1974.
104. Kraft SP, Levin AV, Enzenauer RW: Unilateral surgery for exotropia with convergence weakness. *J Pediatr Ophthalmol Strabismus* 32:183, 1995.
 105. Krzystkova K, Pajakowa J: The sensorial state in divergent strabismus. In *Orthoptics. Proceedings of the Second International Orthoptics Congress*. Amsterdam, Excerpta Medica, 1972, p 72.
 106. Kushner BJ: Exotropic deviations: A functional classification and approach to treatment. *Am Orthopt J* 38:81, 1988.
 107. Kushner BJ: The distance angle to target in surgery for intermittent exotropia. *Arch Ophthalmol* 116:189, 1998.
 108. Kushner BJ: Selective surgery for intermittent exotropia based on distance/near differences. *Arch Ophthalmol* 116:324, 1998.
 109. Kushner BJ: Distance/near differences in intermittent exotropia. *Arch Ophthalmol* 116:478, 1998.
 110. Kushner BJ: Diagnosis and treatment of exotropia with a high accommodation convergence-accommodation ratio. *Arch Ophthalmol* 117:221, 1999.
 111. Kushner BJ: Does overcorrecting minus lens therapy for intermittent exotropia cause myopia? *Arch Ophthalmol* 117:638, 1999.
 112. Landolt H: Behandlung der Divergenz durch überkorrigierende Konkavgläser. *Klin Monatsbl Augenheilkd* 51:47, 1913.
 113. Lang J: Strabismus. Diagnostik, Schielformen, Therapie. Bern, Hans Huber, 1971, p 129.
 114. Lange W, Decker W de: Two therapeutic concepts in intermittent divergent squint. *Doc Ophthalmol* 84:187, 1993.
 115. Laws HW: An evaluation of the use of prisms in the postoperative orthoptic care of divergence strabismus. In Arruga A, ed: *International Strabismus Symposium*. University of Giessen, Germany, 1966. Basel, S Karger, 1968, p 324.
 116. Lennerstrand G: Effects of surgery on the dominant eye in exodeviations. *Acta Ophthalmol* 64:391, 1986.
 117. Luke NE: Antisuppression techniques in exodeviations. *Am Orthopt J* 20:100, 1970.
 118. Manley DR: Classification of the exodeviations. In Manley D, ed: *Symposium on Horizontal Ocular Deviations*. St Louis, Mosby-Year Book, 1971, p 128.
 119. Marlow FW: Prolonged monocular occlusion as a test for the muscle balance. *Am J Ophthalmol* 4:238, 1921.
 120. McDonald RJ: Secondary esotropia. *Am Orthopt J* 20:91, 1970.
 121. Meyer E, Noorden GK von, Avilla CW: Management of consecutive esotropia. In Mein J, Moore S, eds: *Orthoptics: Research and Practice*. London, H Kimpton, 1981, p 236.
 122. Miller JE: The electromyography of vergence movement. *Arch Ophthalmol* 62:790, 1959.
 123. Mitsui Y: Etiology and treatment of strabismus. *Ophthalmic Pract* 49:1151, 1978.
 124. Mitsui Y: Strabismus and the Sensorimotor Reflex. Amsterdam, Excerpta Medica, 1986.
 125. Mitsui Y, Tamura O, Hirai K, et al: Effect on master eye surgery in exodeviations. *Jpn J Ophthalmol* 24:221, 1980.
 126. Moore S: Orthoptic treatment for intermittent exotropia. *Am Orthopt J* 13:14, 1963.
 127. Moore S: The prognostic value of lateral gaze measurements in intermittent exotropia. *Am Orthopt J* 19:69, 1969.
 128. Moore S, Cohen RL: Congenital exotropia. *Am Orthopt J* 35:68, 1985.
 129. Moore S, Stockbridge L: An evaluation of the use of Fresnel press-on prisms in childhood strabismus. *Am Orthopt J* 25:62, 1975.
 130. Nakagawa T, Kii T: Natural history of exodeviation. In Kaufmann H, ed: *Transactions of the 21st Meeting of the European Strabismological Association*, Salzburg, Gies-sen, Gahmig Press, 1993, p 241.
 131. Nawratzki I, Jampolsky A: A regional hemiretinal difference in amblyopia. *Am J Ophthalmol* 46:339, 1958.
 132. Neitker B: Effects of diagnostic occlusion of the deviated and the dominant eye in intermittent exotropia. *Strabismus* 3:1, 1995.
 133. Nelson LB, Bacal DA, Burke MJ: An alternative approach to the surgical management of exotropia—the unilateral lateral rectus recession. *J Pediatr Ophthalmol Strabismus* 29:357, 1992.
 134. Nordlow W: Squint—the frequency of onset at different ages and the incidence of some defects in a Swedish population. *Acta Ophthalmol Scand* 42:1015, 1964.
 135. Noorden GK von: Some aspects of exotropia. Presented at Wilmer Residents' Association, Johns Hopkins Hospital, Baltimore, April 26, 1966.
 136. Noorden GK von: Divergence excess and simulated divergence excess: Diagnosis and surgical management. *Ophthalmologica* 26:719, 1969.
 137. Noorden GK von: The patch test and plus lenses in the diagnosis of exodeviation. *The Prism*, October-November 1982.
 138. Noorden GK von: Discussion: Oculomotor control and strabismus. In Lennerstrand G, Noorden GK von, Campos E, eds: *Strabismus and Amblyopia*. London, Macmillan, 1988, p 147.
 139. Noorden GK von: Unpublished observations, 1987.
 140. Noorden GK von: Unpublished observations, 1988.
 141. Noorden GK von, Avilla CW: Accommodative convergence in hypermetropia. *Am J Ophthalmol* 110:287, 1990.
 142. Ohtsuki H, Hasebe S, Okano M, Furuse T: Comparison of surgical results of responders and non-responders to the prism adaptation test in intermittent exotropia. *Acta Ophthalmol Scand* 75:528, 1997.
 143. Oliitsky SE: Early and late postoperative alignment following unilateral lateral rectus recession for intermittent exotropia. *J Pediatr Ophthalmol Strabismus* 35:146, 1998.
 144. O'Neal TD, Rosenbaum AL, Stathacopoulos RA: Distance stereoacuity improvement in intermittent exotropic patients following strabismus surgery. *J Pediatr Ophthalmol Strabismus* 32:353, 1995.
 145. Owens PL, Strominger MB, Rubin PA, Veronneau-Troutman S: Large-angle exotropia corrected by intraoperative botulinum toxin A and monocular recession resection surgery. *J Am Assoc Pediatr Ophthalmol Strabismus* 2:144, 1998.
 146. Parks MM: Comitant exodeviations in children. In Strabismus. Symposium of the New Orleans Academy of Ophthalmology. St Louis, Mosby-Year Book, 1962, p 45.
 147. Parks MM, Mitchell P: Concomitant exodeviations. In Duane TD, ed: *Clinical Ophthalmology*, vol 1. Philadelphia, JB Lippincott, 1988, p 1.
 148. Pigassou R: Prisms in strabismus. *Int Ophthalmol Clin* 6:519, 1966.
 149. Piper HF: Über verschiedene Formen des Schielens, ihre Entstehung und Behandlung. In Velhagen K, ed: *Abhandlungen auf dem Gebiet der Augenheilkunde*, vol 26. Leipzig, Georg Thieme VEB 1961.
 150. Pratt-Johnson J, Wee HS: Suppression associated with exotropia. *Can J Ophthalmol* 4:136, 1969.
 151. Pratt-Johnson JA, Barlow JM, Tilson G: Early surgery for intermittent exotropia. *Am J Ophthalmol* 84:689, 1977.
 152. Raab EL, Parks MM: Recession of the lateral recti. *Arch Ophthalmol* 82:203, 1969.
 153. Ravault AP, Bongrand M, Bonamour G: The utilization of prisms in the treatment of divergent strabismus. In

- Orthoptics. Proceedings of the Second International Orthoptics Congress. Amsterdam, Excerpta Medica, 1972, p 77.
154. Rayner JW, Jampolsky A: Management of adult patients with large angle exotropia. *Ann Ophthalmol* 5:95, 1973.
 155. Repka MX, Arnoldi KA: Lateral incomitance in exotropia: Fact or artifact? *J Pediatr Ophthalmol Strabismus* 28:125, 1991.
 156. Richard JM, Parks MM: Intermittent exotropia: Surgical results in different age groups. *Ophthalmology* 90:1172, 1983.
 157. Romano PE, Wilson MF, Robinson JA: World-wide surveys of current management of intermittent exotropia by MD strabologists. *Binocular Vision Strabismus Q* 8:167, 1993.
 158. Rubin SE, Nelson LB, Wagner RS, et al: Infantile exotropia in healthy children. *Ophthalmic Surg* 19:792, 1988.
 159. Rutum MS: Initial versus subsequent postoperative motor alignment in intermittent exotropia. *J Am Assoc Pediatr Ophthalmol Strabismus* 1:88, 1997.
 160. Sanfilippo S, Clahane AC: The immediate and long-term results of orthoptics in exodeviations. In *First International Congress of Orthoptists*. St Louis, Mosby-Year Book, 1968, p 300.
 161. Schlossman A, Boruchoff SA: Correlation between physiologic and clinical aspects of exotropia. *Am J Ophthalmol* 40:53, 1955.
 162. Schlossman A, Muchnick RS, Stern K: The surgical management of intermittent exotropia in adults. *Ophthalmology* 90:1166, 1983.
 163. Scobee RG: *The Oculorotary Muscles*, ed 2. St Louis, Mosby-Year Book, 1952.
 164. Scott WE, Mash AJ: The postoperative results and stability of exodeviations. *Arch Ophthalmol* 99:1814, 1981.
 165. Seaber JH: Pseudomyopia in exodeviations. *Am Orthopt J* 16:67, 1966.
 166. Snir M, Axer-Siegel R, Shalev B, et al: Slanted lateral rectus recession for exotropia with convergence weakness. *Ophthalmology* 106:992, 1999.
 167. Spencer RF, Tucker MG, Choi RY, McNeer KW: Botulinum toxin management of childhood intermittent exotropia. *Ophthalmology* 104:1762, 1997.
 168. Stathacopoulos RA, Rosenbaum AL, Zanoni D, et al: Distance stereoacuity—Assessing control in intermittent exotropia. *Ophthalmology* 100:495, 1993.
 169. Swan KC: Problems of exotropia. *J Pediatr Ophthalmol* 2:25, 1965.
 170. Tamler E, Jampolsky A: Is divergence active? An electromyographic study. *Am J Ophthalmol* 63:452, 1967.
 171. Urist MJ: Right angle exotropia. *Am J Ophthalmol* 58:987, 1964.
 172. Van den Berg AV, van Rijn LJ, de Faber JT: Excess cyclovergence in patients with intermittent exotropia. *Vision Res* 35:3265, 1995.
 173. Velez G: Results in intermittent exotropia. In Moore S, Mein J, Stockbridge L, eds: *Orthoptics: Past, Present, Future*. Transactions of the Third International Orthoptic Congress. New York, Stratton Intercontinental, 1976, p 559.
 174. Véronneau-Troutman S: Fresnel prism membrane in the treatment of strabismus. *Can J Ophthalmol* 6:249, 1971.
 175. Wang FM, Chryssanthou G: Monocular eye closure in 172. Van den Berg AV, van Rijn LJ, de Faber JT: Excess 176. Weakley DR, Stager DR: Unilateral lateral rectus recession *Res* 35:3265, 1995.
 177. Weiss JB, Rouchy JP, Ruellan YM, Teliques JP: Utilisation des prismes compensateurs provisoires pour rompre le cercle vicieux “déviation diplopie.” *Bull Soc Ophthalmol Fr* 69:303, 1969.
 178. Weiss L: Upon the relation between the internal and external recti as affected by increasing divergence of the orbits. *Arch Ophthalmol* 25:341, 1896.
 179. White JW: Discussion of paper by Bielschowsky A: Divergence excess. *Arch Ophthalmol* 12:157, 1934.
 180. Wiggins RE, Noorden GK von: Monocular eye closure in sunlight. *J Pediatr Ophthalmol* 27:16, 1990.
 181. Windsor CE: Surgery, fusion, and accommodative convergence in esotropia. *J Pediatr Ophthalmol Strabismus* 8:166, 1971.
 182. Winter R, Winter M, de Decker W: Langzeitergebnisse nach operativer Behandlung des Strabismus divergens intermittens. *Ber Vers Dtsch Ophthalmol Ges* 76:683, 1979.
 183. Wirtschafter JD, Noorden GK von: The effect of increasing luminance on exodeviations. *Invest Ophthalmol* 3:549, 1964.
 184. Wittebol-Pol D, Graaf M de: Early onset exotropia. In Kaufmann H, ed: *Transactions of the 20th Meeting of the European Strabismological Association*, Brussels, 1992, p 203.
 185. Wygnanski-Jaffe T, Wyanbeek Y, Bessler E, Spierer A: Strabismus surgery using the adjustable suture technique. *J Pediatr Ophthalmol Strabismus* 36:184, 1999.
 186. Yildirim C, Mutlu FM, Chen Y, Altinsoy HI: Assessment of central and peripheral fusion and near and distance stereoacuity in intermittent exotropic patients before and after strabismus surgery. *Am J Ophthalmol* 128:222, 1999.
 187. Yuksel D, Spiritus M, Vandelannoitte S: Chirurgie symétrique comme traitement initial de l'exotropie intermittente de base. *Bull Soc Belge Ophthalmol* 268:195, 1998.

Cyclovertical Deviations

The diagnosis and management of cyclovertical deviations are special challenges to the ophthalmologist. There are several disorders that on first glance appear similar clinically but differ widely in etiology and management. As in no other aspect of strabismology, correct diagnosis is of utmost importance, since an operation performed on the basis of an erroneous interpretation of the underlying problem may cause disastrous and permanent consequences with respect to the patient's binocular function. Once the correct diagnosis has been made, medical and surgical management of such deviations does not present any special problems, and the therapeutic results can be the most gratifying in the field of strabismus.

Cyclovertical deviations differ from horizontal deviations in several aspects. Sensorial adaptations in the form of amblyopia or anomalous retinal correspondence are noted far less frequently with this type of deviation than with horizontal strabismus. Comitance is rare, and the deviation is generally smaller in magnitude, yet the size of a cyclovertical deviation is not an indication of the extent of the problem caused for the patient. Although some patients with well-developed binocular functions often are able, by motor fusion, to overcome surprisingly large vertical deviations, the low fusional reserve in the vertical directions in most others precludes this compensatory mechanism. Consequently, a hyperdeviation of only 1^Δ or 2^Δ can cause diplopia or blurring of vision, especially during reading. Such small residual hyperdeviations following surgical alignment of horizontal strabismus are of special clinical significance, for

they may present insurmountable obstacles to a functional cure.

The prevalence of cyclovertical deviations in association with horizontal deviations or as isolated anomalies is high. White and Brown¹²⁸ observed that in patients with motility disorders, approximately half had isolated vertical anomalies and another third had combined horizontal and vertical muscle problems. Scobee¹⁰³ found a vertical component in 43% of 457 patients with esotropia.

Bielschowsky⁷ classified cyclovertical deviations into five groups: (1) purely comitant vertical deviations, (2) vertical deviations of parietic origin, (3) deviations with unilateral overaction of the inferior oblique muscles, (4) dissociated vertical deviations, and (5) vertical deviations combined with features of several of the other groups. This classification is still of some usefulness today even though we have learned since Bielschowsky that elevation in adduction is not exclusively caused by an overacting inferior oblique muscle.

In this chapter nonparalytic and nonmechanical cyclodeviations are described. Paralytic deviations are discussed in Chapter 20, and hyperdeviations caused by mechanical factors (endocrine myopathy, congenital fibrosis, and orbital floor fractures) are described in Chapter 21.

Comitant Hyperdeviations

Etiology and Clinical Characteristics

Truly comitant hyperdeviations occur infrequently. To find a patient with a significant vertical devia-

tion of the same magnitude in all positions of gaze with either eye fixating and with the head tilted to either shoulder is indeed unusual. Anderson,^{2, p.12} in a survey of 600 patients with cyclovertical anomalies, was unable to find a single truly comitant deviation. Repeated measurements in the diagnostic positions of gaze in the majority of patients may reveal a paretic component or an apparently primary overaction of one or several cyclovertical muscles. The etiology of truly comitant deviations of a magnitude rarely exceeding a few prism diopters is not clear. At one point, some of the patients may have had a paretic deviation that became comitant with the passage of time (see Chapter 20). In others, an anomalous position of rest caused by anatomical or mechanical factors or abnormal innervation may be a causative mechanism.

Therapy

The very nature of comitant cyclovertical deviations means that prisms are ideally suited for relief of the patient. They should be distributed evenly before the two eyes (base-down before the hypertropic eye), and the prescription should be based on the minimal prismatic power that provides comfortable single binocular vision. When performing surgery to correct a coexisting horizontal deviation, comitant hyperdeviations can be eliminated by lowering the horizontal muscle insertions of the hypertropic eye or raising the insertions of the hypotropic eye (see Chapter 26).

Dissociated Vertical Deviations

Dissociated vertical deviation (DVD) is among the most intriguing and least understood of all forms of strabismus. Even though the unique clinical features of this anomaly clearly distinguish it from other forms of vertical motor disturbance, the diagnosis may be difficult when associated with other forms of strabismus, especially with cyclovertical deviations. Although Bielschowsky^{8, p.34} credited Schweigger (1894),¹⁰² Stevens (1895), and Duane (1896) for the first reports of this entity, it was he who provided the first comprehensive description and minute clinical analysis of DVD.⁶

Terminology

The lack of precise etiologic information about DVD is reflected by the plethora of terms in use at one time or another: *anopia*, *alternating hyperphoria* or *hypertropia*, *double hypertropia*, *occlusion hypertropia*, *alternating sursumduction*, *dissociated double hypertropia*, *dissociated alternating hyperphoria*, and *dissociated vertical divergence*. To speak in this context of *alternating*, *dissociated*, *double*, or *occlusion hyperphoria* or *hypertropia*, as many authors (including Bielschowsky⁶) have, is incorrect, because DVD is different from ordinary hyperdeviations. For instance, in a patient with right hypertropia, either the right eye is elevated when the left eye is fixating or the left eye is depressed when the right eye is fixating. On the other hand, in DVD, either eye elevates when the fellow eye is fixating. *Alternating sursumduction*, a term introduced by Lancaster⁶⁵ and Swan¹²¹ emphasizes the monocular nature of the movement (a duction and not a version or vergence), and its use has become rather widespread. Nevertheless, this description is not completely accurate because the movements are not limited exclusively to sursumduction but contain substantial elements of excycloduction and sometimes abduction. Moreover, the deviation does not always alternate but may be restricted to one eye. For these reasons, we prefer the generic term *dissociated vertical deviation*, which carries no implications with regard to the etiology of the condition and for which the abbreviation DVD has become widely accepted. Although no great friends of medical abbreviations, we will use DVD during the remainder of this discussion.

Clinical Characteristics

DVD is characterized by the spontaneous drifting of either eye upward when the patient is fatigued or daydreaming or when fusion is artificially interrupted by covering one eye (Fig. 18-1). When the elevated eye is covered, it may perform pendular, vertical movements. When the cover is removed, the elevated eye will move slowly downward and settle in the primary position.

The amount of elevation when the eye is covered is variable, tending to increase after prolonged occlusion, and often differing between the two eyes. According to Bielschowsky⁶ several other features are present in most patients with

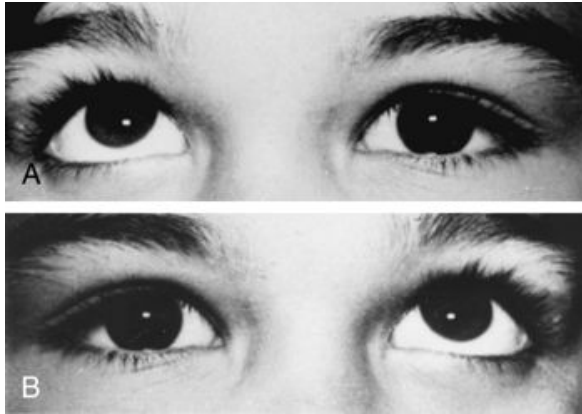


FIGURE 18-1. Dissociated vertical deviation. *A*, Left eye fixating. *B*, Right eye fixating.

DVD. These include *excycloduction of the elevated eye* and *incycloduction of the fixating eye*. As the elevated eye returns to the primary position it incycloducts. This torsional movement of the globe is often easily detected without magnification by the observer. *Latent nystagmus*, which often but not always has a cyclovertical component, may be associated with DVD.⁶

These additional symptoms justify consideration of DVDs as a syndrome. Observation of the iris pattern and the conjunctival vessels will nearly always reveal incycloduction as the elevated eye returns to the midline, indicating that it was excycloducted while in the dissociated position. The excycloduction of the elevating eye may be accompanied by a synchronous incycloduction of the fixating eye (cycloversion).⁵⁴ Occasionally, excycloduction of each eye under cover or spontaneously and latent nystagmus may be the only manifestation of a dissociated deviation. In such cases we speak of a *dissociated torsional deviation (DTD)*. In other cases, the full syndrome with its vertical component may involve one eye only

while it manifests itself as an isolated excycloduction in the other.

Anderson² and Lyle and Bridgeman⁶⁹ drew attention to the association of a head tilt with DVD. The prevalence of anomalous head posture in this condition has been reported to range between 23%¹⁹ and 35%.⁵ Most authors reported the head to be tilted away from the eye with the larger vertical deviation^{19, 101} but the opposite has also been observed.^{5, 23} Passive tilting of the head toward the opposite of the side of the habitual posture increases the vertical deviation, which has led to the conclusion that the anomalous head posture decreases the magnitude and thus improves the motor control of the type of alternating hyperphoria investigated by these authors. De Decker and Dannheim de-Decker²³ reported chin depression in patients with bilateral dissociated deviations. Surgical correction of DVD improves the head posture.^{23, 101}

DVD occurs in patients with and without *overaction of the inferior oblique muscles* and may also be associated with *overaction of the superior oblique muscles* and an A-pattern exodeviation in downward gaze^{45, 71} (Fig. 18-2). The vertical angle of dissociated deviations is usually somewhat less in abduction than in adduction; however, it may also be larger in abduction.⁴⁶ Latent nystagmus occurs in approximately half the patients with DVD and, in fact, is seldom encountered in the absence of this anomaly (see Anderson², p.16).

If a photometric neutral filter wedge is placed before the fixating eye while the other eye is occluded and elevated, the eye behind the cover will make a gradual downward movement, and may even move below the primary position as the visual input to the fixating eye is progressively decreased by the filter wedge. When the wedge is moved from positions of greater to lesser filter

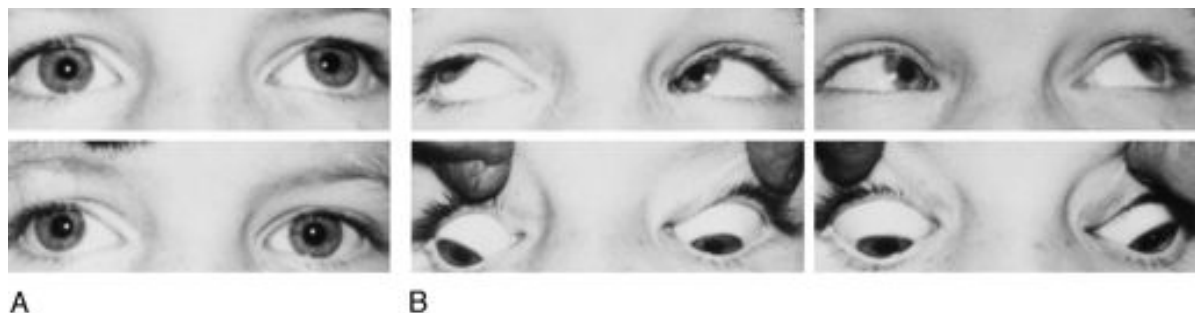

FIGURE 18-2. Dissociated vertical deviation with overaction of both superior oblique muscles. *A*, Left hypertropia with the right eye fixating and right hypertropia with the left eye fixating. *B*, Underaction of both inferior oblique and overaction of both superior oblique muscles.

density, the eye behind the cover will elevate. This intriguing observation was first reported by Bielschowsky⁶ and has become known as the *Bielschowsky phenomenon*. Bielschowsky explained the phenomenon that bears his name in the following manner: When the visual input to the fixating, say, the right eye is decreased by holding filters of increasing density before it, the effort to maintain fixation triggers an abnormal innervation to the elevators. The effort to maintain fixation with the right eye against this innervation elicits a compensatory innervation to the depressors. The left eye follows this innervation under cover and returns to the primary position or even below it.

A DVD may occasionally occur as an isolated phenomenon in patients in whom binocular functions are apparently normal, but is found often in association with infantile esotropia and less often with accommodative acquired esotropia, exotropia, and heterotropia of sensory origin.^{64, 72, 109, 132} An association with Duane's syndrome has also been described.^{17, 95} The high prevalence of DVD in essential infantile esotropia has been discussed in Chapter 16 and it is of interest that a similarly high rate of occurrence has been reported in infantile exotropia.⁷³ In spite of a careful search the condition is rarely diagnosed in infancy. In our experience the diagnosis is most commonly made between the ages of 2 and 5 years and often years after surgical alignment of the horizontal deviation. The age at surgical alignment could not be correlated with the manifestation of DVD.⁴⁷

DVD is usually bilateral and asymmetrical. Of the 170 cases observed by us⁸⁰ in a group of 408 children with essential infantile esotropia, only 24 (14%) were unilateral and only 13 (9%) were symmetrical. However, unilateral occurrence is often observed in deeply amblyopic eyes⁶ and in sensory heterotropia.^{96, 109} The commonly occurring asymmetry between the two eyes is reversed in the supine position with the head tilted back: the eye with a larger deviation in the upright position has a smaller one with the patient supine and the head tilted back.³⁹ This observation suggests a possible effect of inputs from otolithic and possibly neck muscle sensors on the amplitude of a DVD.

An active suppression mechanism usually will eliminate diplopia in patients with a spontaneous DVD. Exceptions to this rule are rare but do occur as shown in Case 18-1.

CASE 18-1

This 26-year-old man has had crossed eyes since infancy. Surgery was performed on the eye muscles when he was 3 years of age. For the past 13 years he has experienced intermittent double vision. Examination showed corrected visual acuity of 6/4.5 OD and 6/6 OS. He wore prescription glasses to correct a mild compound myopic astigmatism. The patient had fairly pronounced latent nystagmus and an esotropia of 14^Δ at near and distance fixation. In addition he had 18^Δ right hypertropia with the OS fixating and 10^Δ left hypertropia with the OD fixating. He exhibited characteristic incycloduction as each elevated eye took up fixation in primary position. A V pattern was absent, and there was no inhibitional palsy of the contralateral superior rectus when he fixated with the adducted elevated eye. As soon as the eyes were dissociated, the patient became aware of diplopia. The red-glass test established that the diplopia was in accord with the deviation; that is, the images were uncrossed and had a vertical component, the laterality of which depended on which eye was fixating. The diagnosis was residual esotropia with a DVD and absence of suppression. No treatment was advocated.

Campos and coworkers¹⁴ pointed out that suppression is not the only mechanism that accounts for absence of diplopia in this condition by showing that a binocular vertical perceptual adaptation may exist in these patients.

Diplopia can be elicited in most patients with a dark-red glass, and the amount of separation between the images is used to measure the amplitude of elevation of each eye (see Chapter 12). The fact that the patient will localize the red image below the fixation light, regardless of whether the red glass is held before the right or left eye, clearly differentiates a DVD from other forms of cyclovertical anomalies in which the red image is localized below or above the fixation light, depending on which eye fixates.

Measurement

An accurate quantitative assessment of DVD may be obtained provided visual acuity in each eye is sufficient to visualize the fixation target, using a modification of the prism and cover test. As the patient focuses on the fixation target at 6 m distance, the occluder is quickly shifted to the fixating eye, allowing the previously dissociated and elevated eye to take up fixation. The cover is then returned to the nonfixating eye. As the alternate cover test is continued, increasing amounts of

base-down prisms are held under the occluder in front of the nonfixating eye until the downward fixation movement of that eye is neutralized. The procedure is then repeated with the fellow eye fixating.

Etiology

Of the numerous theories advanced to explain the mechanism of this intriguing anomaly in the past, only a few will be mentioned in this chapter. Elastic preponderance of the elevator or the depressor muscles¹⁰²; paretic factors²⁵ especially bilateral paresis of the depressor muscles^{104, p. 183}; and imbalances between the amount of innervation originating from each vestibular organ⁸⁷ have been cited as causes in the older literature. For other explanations, see White,¹²⁷ Verhoeff,¹²⁵ Posner,⁹¹ Crone,¹⁹ Helveston,⁴⁶ and Houtman and coworkers.⁵³ It has even been reported that DVD may be caused by an abnormal visual pathway routing similar to that described in albinism³⁵ (see Chapter 9). However, as one may have expected, this finding could not be reproduced.^{3, 10, 62, 135}

The results of more recent investigations^{11, 15, 41, 93, 94, 133} are in basic agreement with what Bielschowsky⁶ so lucidly described in 1931 and in his later publications^{7, 8}: DVD is caused by a vertical vergence signal that elevates the occluded eye and would depress the fixating eye if it were not for a simultaneous supraversion impulse that cancels the innervation to depress the fixating eye while at the same time, according to Hering's law, increasing the innervation flowing to the elevators of the occluded eye. Bielschowsky arrived at this explanation by meticulous clinical observation, sound reasoning, and without the benefit of modern search coil recording techniques that have essentially confirmed the validity of this innervational pattern and sequence^{41, 93, 133}

The origin of the vertical vergence innervation is still a matter of dispute. Bielschowsky⁶ suspected an alternating and intermittent excitation of both subcortical centers that govern vertically divergent eye movements. He cited as examples for such movements and support for the existence of such centers skew deviation and seesaw nystagmus and felt that the unilaterality of the condition in some cases is "based on the coincidence of the voluntary fixation impulse with the involuntary action of one of the vertical divergence centers."^{8, p. 35} The reason for this abnormal excitation of hypothetical vertical divergence centers remains

unknown. There is no question, however, that the *impulse for a DVD must originate in the fixating eye*. Bielschowsky^{8, p. 36} emphasized the need to differentiate between a hyperdeviation based on anatomical conditions, that is, an anomalous position of rest, and the dissociated deviations of innervational origin. Spielmann¹¹⁶ convincingly confirmed this difference by showing that DVD does not occur when fixation is prevented by covering both eyes with translucent occluders (Fig. 18–3). Spielmann^{111–113} assumed that DVD is caused by an imbalance of binocular stimulation. Although this may explain the frequent occurrence of DVD in essential infantile esotropia and the occasional occurrence with sensory heterotropias, it does not account for DVD in patients with otherwise normal binocular functions.

Several additional explanations were proposed in recent years. From the direction of the cyclorotation of the elevating eye (extorsion) and the fixating eye (intorsion) several investigators^{31, 41, 93} have concluded that the vertical vergence movement must be predominantly mediated by the oblique muscles because the vertical rectus muscle would produce a cyclorotation in the opposite direction. Guyton⁴¹ and Cheeseman and Guyton¹⁵ believe that this oblique muscle-generated cyclorotation is a purposeful eye movement that damps latent cyclovertical nystagmus to improve visual acuity. The accompanying elevation of the nonfixating eye, the DVD, is seen as an unavoidable

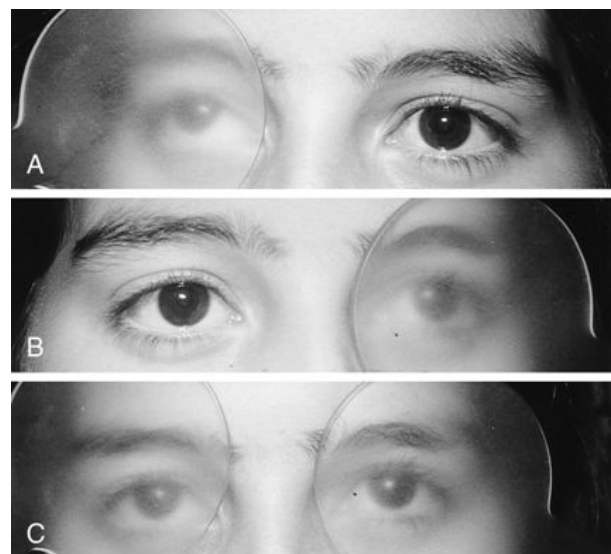


FIGURE 18–3. Combined vertical and horizontal dissociated deviation in the right eye (A) and predominantly vertical dissociated deviation in the left eye (B). C, Absence of dissociated vertical deviation in the fixation-free position when both eyes are covered with translucent Spielmann occluders. For details, see text.

and undesirable byproduct of this *nystagmus damping mechanism* (see Chapter 23). There are a number of observations that are difficult to reconcile with this theory,⁸² which is based on the concept of the inferior oblique muscle being the primary elevator in vertical vergences. In DVD the dissociated eye elevates not only in adduction but also in primary position and abduction (Fig. 18-4). In fact, in some cases the elevation in abduction is greater than in adduction. Clearly, these are gaze positions in which the inferior oblique muscle has little or no elevating power and the superior rectus muscle *must* be the principal elevator. While it is indisputable that excyclo-duction of an elevating eye can only be caused by the inferior oblique muscle, it does not inescapably follow that this muscle is also the predominant elevator. One must also consider the possibility that both the superior rectus and inferior oblique muscles co-contract during elevation but that the stronger excyclotorsional effect of the inferior oblique overrides the weaker incyclotorsional effect of the superior rectus muscle. Moreover, in our experience and that of others⁴⁵ a DVD continues unabated after a myectomy of the ipsilateral inferior oblique muscle. Also, a nystagmus dampening purpose of the vertical

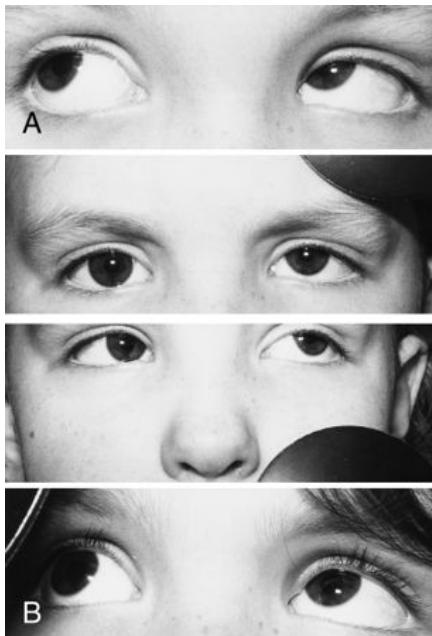


FIGURE 18-4. Dissociated vertical deviation in different gaze positions. *A*, In the case of a dissociated vertical deviation of the left eye, elevation occurs in adduction, primary position, and, to a lesser degree, in abduction. *B*, When the elevated adducted left eye takes up fixation, the covered right eye will be elevated to an equal degree. (From Noorden GK von: *Atlas of Strabismus*, ed 4. St Louis, Mosby-Year Book, 1983.)

vergence is difficult to accept in view of the fact that a latent cyclovertical nystagmus is not a consistent feature of DVD.^{6, 46, 56, 93} Finally, if DVD were elicited to dampen a latent nystagmus we would expect the nonfixating eye of a patient with DVD to elevate each time a patient with latent nystagmus reads his or her threshold acuity line on the office chart. Not only is this not the case but, on the contrary, DVD manifests itself typically when patients are daydreaming and uninvolved in active visual activities.

Van Rijn and coworkers⁹⁴ felt that DVD represents a form of *asymmetrical vertical heterophoria* and could be considered as enhancement of a phenomenon that is present in normal subjects as well. They showed in patients with alternating hyperphoria, who have a right hyperphoria with the left eye fixating and a left hyperphoria with the right eye fixating, asymmetries of the vertical heterophoria angles, depending on which eye was fixating. It is true that alternating hyperphoria, which, incidentally, is an extremely rare clinical finding, bears a superficial resemblance to DVD. However, it is debatable whether these conditions are as closely related as assumed by these authors. A vertical heterophoria becomes manifest as soon as fusion is disrupted and the eye drifts into its anomalous position of rest. In DVD, the vertical movement is caused by an active vergence innervation and fusion is not a factor in controlling the deviation because it may occur in patients without the ability to fuse.

Some authors have speculated that DVD is a manifestation of *atavistic oculomotor reflexes* that are present in birds and fish.^{11, 14, 20, 41, 46, 94} Crone²⁰ considered that DVD may represent a phylogenetic residuum of monocular vertical movements present in birds and inhibited in normal humans. Brodsky¹¹ suggested that DVD is a primitive dorsal light reflex in which asymmetrical visual input to the eyes evokes a vertical divergence movement. In lateral-eyed animals this reflex serves as a primitive visual-vestibular righting response. Suppressed in normal humans, it is thought to manifest itself when early-onset strabismus precludes normal binocular development. Can the stimulus for the dorsal reflex in fish be compared to the stimulus situation in a human strabismic infant? A fish illuminated from one side depresses the eye ipsilateral to the light source and elevates the contralateral eye. The stimulus for this reflex eye movement, which does indeed resemble a vertical vergence response, is a difference in illu-

mination between the two eyes. However, such differences do not occur in strabismus, as each eye receives the same amount of light. In strabismus, the asymmetry of visual input that disrupts binocularity is caused instead by the incongruity of the retinal images formed in each eye.

To summarize, it is fair to state that despite numerous attempts to clarify it, the etiology of DVD is still obscure. Bielschowsky's original explanation of this form of strabismus, confirmed by modern eye movement recording techniques, has established indisputably that *DVD is a vertical vergence eye movement*. However, the stimulus for this movement and its relationship to various forms of strabismus, especially to essential infantile esotropia, have yet to be convincingly identified.

Differential Diagnosis

Even though the pattern of the deviation and the results of the red-glass test are clearly different in DVD from those in other cyclovertical anomalies, clinicians sometimes confuse this condition with upshoot in adduction caused by overaction of the inferior oblique muscles (see p. 386). To be sure, overaction of the inferior oblique muscle may occur in patients with DVD, but such overaction cannot be held responsible for this anomaly. *Several clinical findings clearly distinguish DVD from overaction of the inferior oblique muscle.*

First, in DVD the covered eye becomes elevated in abduction, primary position, and adduction (Fig. 18-4). Conversely, with overaction of the inferior oblique muscles, each eye becomes elevated primarily in adduction and never in abduction unless there is coexisting contracture of the ipsilateral superior rectus muscle. Unlike DVD, overaction of the inferior obliques is commonly associated with a V-pattern esotropia. The reason for elevation in adduction in a DVD is that the adducted eye becomes occluded by the nasal bridge and fusion is suspended. In children under the age of 2 to 3 years the nasal bridge has not yet fully developed and the upshoot in adduction is rarely seen.

Second, DVD is found also in patients in whom there is no noticeable overaction of the inferior oblique muscles and actually occurs frequently in those with underacting inferior oblique and overacting superior oblique muscles^{45, 71} (see Fig. 18-1).

Third, when a patient with an overacting inferior oblique muscle fixates with the involved eye in the field of action of that muscle (elevation and adduction), the contralateral superior rectus muscle will underact (see Fig. 20-1). This apparent paresis of the superior rectus muscle has been discussed under inhibitional palsy (Chapter 20). Conversely, in patients with DVD who are tested in the same manner, underaction of the contralateral yoke muscle does not occur (Fig. 18-4, B).

Fourth, in patients with inferior oblique overaction, the speed of the refixation movement of the eye after covering the fellow eye is rapid (200° to 400°/s) compared with the much slower infraduction movements in patients with DVD, which are usually between 10° and 200°/s.⁴⁶

Fifth, the characteristic slow, tonic incycloduction of the eye as it returns from the dissociated to the primary position cannot be observed with equal facility when overaction of the inferior oblique is present. In that case refixation after covering the fixating eye is also accompanied by incycloduction but this movement is so fast that it often escapes observation.

The differential diagnosis between these two conditions is summarized in Table 18-1 in which additional distinguishing findings are listed. Clear distinction between them is clinically important; for example, a recession or myectomy of the inferior oblique will have *no* effect on upshoot in adduction if the patient actually has a DVD.

When associated with comitant or parietic cyclovertical anomalies the diagnosis of DVD is more difficult. When evaluating such patients, one must take into account the starting position of each eye before the cover is applied. For instance, if a right hypertropia is associated with a DVD, the right eye will become further elevated under the cover, and the fellow left hypotropic eye when covered will move upward the same amount but may only reach the midline, since it began its movement from a depressed position. Careful observation of each eye before, during, and after the cover has been applied is essential to detecting a dissociated vertical component in a patient with a comitant or parietic cyclovertical deviation.

Therapy

During the first half of the twentieth century clinicians took a rather passive attitude toward treatment of DVD. This conservatism probably finds its roots in Bielschowsky's⁶ teachings that this

TABLE 18-1. Differential Diagnosis: Dissociated Vertical Deviation vs. Inferior Oblique Overaction

	Dissociated Vertical Deviation	Inferior Oblique Overaction
Elevation	From primary position, adduction and abduction	Maximal in adduction, never in abduction
Superior oblique action	May overact	Usually underaction
V pattern	Absent	Often present
Pseudoparesis of contralateral superior rectus	Absent	Present
Incycloduction on refixation	Present	Absent
Saccadic velocity of refixation movement	10°–200°/s	200°–400°/s
Latent nystagmus	Often present	Absent
Bielschowsky phenomenon	Often present	Absent

condition does not lend itself to optical or operative therapy as do comitant or paretic deviations. Bielschowsky cited cases of torsional diplopia produced by surgery on the superior rectus muscles, and stated that therapy, if contemplated at all, should be directed toward strengthening the fusional mechanism.

Patients with DVD usually are asymptomatic, and complaints of diplopia have been an infrequent problem in our experience; however, when the patient is daydreaming or tired, the elevated position of either eye may become conspicuous and a source of embarrassment to the patient. In that case surgery may be considered. We have not observed DVD in adults as often as we have in children, and were, perhaps erroneously, under the impression that this disorder tends to improve with time. However, Harcourt and coworkers⁴⁴ followed 100 patients with DVD for as long as 7.3 years and found no significant decrease in the deviation during this period of observation.

Surgical procedures preferred by various authors are (1) recession of the superior combined with resection of the inferior rectus muscles,⁵⁹ (2) resection of the inferior recti,⁹⁰ (3) retroequatorial myopexy (posterior fixation) of the superior recti combined with^{27, 46, 58, 117} or without^{68, 76, 77} a recession of these muscles, (4) unconventionally large recessions (7 to 10 mm) of the superior recti,^{32, 68, 70, 124} and (5) anterior displacement of the inferior oblique insertion, which may be combined with superior rectus recession.^{9, 13, 61, 97, 108, 119, 123}

Our initial enthusiasm for using a conventional (4 to 5 mm) recession of the superior recti combined with a retroequatorial myopexy 12 to 15 mm behind the original insertion²⁷ has waned because of many recurrences occurring as late as several years after an initial satisfactory result. Currently, we prefer 7- to 9-mm recessions of the superior recti and vary the amount of surgery in

the two eyes when the deviation is asymmetrical. This approach has yielded a cure or significant improvement (defined as a cosmetically insignificant residual angle) in 23 (72%) of 32 patients after a follow-up of at least 3 years.³² Contrary to our earlier concern that such an extensive weakening procedure would produce a paresis of the superior rectus, we have not observed this complication. The effectiveness of superior rectus muscle recession in terms of correction of a deviation in prism diopters per millimeter of recession in other forms of vertical strabismus and the lesser effect of this procedure in a DVD of the same magnitude emphasize the unique position of this anomaly among other forms of strabismus.

Several authors have in recent years reported good results with anterior displacement of the inferior oblique muscle^{9, 13, 61, 97, 108, 119, 123} and this treatment has become the procedure of choice for some. However, we prefer recession of the superior rectus muscle(s), which is less likely to cause some of the complications reported after surgery on the inferior oblique insertion (see Chapter 26).

The question has been debated whether surgery should always be performed in both eyes even though the deviation may be present preoperatively only in one eye. It is not uncommon and quite disappointing to have a patient return after surgery in one eye with a DVD in the fellow eye. However, since in our experience this does not happen in every instance of asymmetrical occurrence we operate on both eyes only when a deviation can be diagnosed preoperatively in both eyes.

Recurrences are not uncommon even after unconventionally large recessions of the superior recti and require additional surgery consisting of a 4- to 5-mm resection of the inferior rectus muscle. Full correction or improvement, as defined above, can in our experience be achieved in 92% of the patients after this operation.³³

Although in most patients with a conspicuous DVD surgery is the recommended treatment, the possible effectiveness of a conservative approach should not be ignored. This is especially true in patients with asymmetrical involvement or those accustomed to wearing glasses. For example, a patient without binocular vision (after horizontal surgical alignment in infantile esotropia) may exhibit a significant DVD of the left eye when fixating with the right eye, but only an insignificant deviation of the right eye may occur with the left eye fixating. A slight optical blur induced by increasing the power of the lens over the right eye (+2.00 sph usually is sufficient) or a contact lens (see Case 24-1, p 538) will switch fixation preference to the left eye, and the DVD is no longer a cosmetic problem. Simon and coworkers¹¹⁰ have confirmed the efficacy of this approach in selected cases but have used atropine rather than optical penalization.

Dissociated Horizontal Deviations

It has only recently been recognized that DVD may also have a horizontal component. Raab⁹² mentioned in 1970 that the vertical movement in DVD may be accompanied by abduction. Little attention was paid to this observation until the term *dissociated horizontal deviations* (DHDs) became established in the literature.^{30, 113, 130, 134}

The condition is characterized by intermittent, asymmetrical abduction and elevation of the dissociated eye (see Fig. 18-2A). Occasionally, DHD occurs in an isolated form, not accompanied by a vertical deviation. As with DVD, latent nystagmus and excyclotropia of the deviated eye are frequently associated findings. Interestingly, and perhaps significantly, Wilson and coworkers¹³² found that only two of six patients with a prominent DHD had a history of essential infantile esotropia. The remainder had accommodative esotropia, a condition that is only infrequently associated with DVD. These authors also reported that when DHD is associated with esotropia the patient may become exotropic during periods of visual inattention.

In an earlier report Wilson and McClatchey¹³⁰ had pointed out that unlike in ordinary intermittent exotropia, the alternate cover test reveals less exodeviation than when the eye abducts spontaneously or under cover, that the fixating eye may

adduct during attempts to neutralize the horizontal deviation with base-in prisms, and that the exodeviation may be strictly unilateral. Moreover, they described what is similar to the Bielschowsky phenomenon in DVD: when neutral density filters are placed before the fixating eye the abducted dissociated eye returns to the primary position and may even adduct. Since we became aware of this condition we have observed several patients with a pure dissociated horizontal deviation in one eye and a pure DVD in the fellow eye.

For dissociated exodeviations a 5- to 7-mm recession of the lateral rectus muscle of the involved eye is recommended when the size of the deviation is such that the patient or his or her parents desire correction. Satisfactory results have been reported using this approach.¹³¹

This may be combined with recession of the superior rectus when associated with a vertical component. In patients whose dissociated deviation is predominantly vertical with only a small horizontal component, we have found a large recession of the superior rectus is usually sufficient to correct both problems.

Spielmann¹¹⁵ described *dissociated esodeviations* that occur when either eye is covered with the semiopaque occluder. When both eyes are occluded (fixation-free position) the eyes remain aligned, which distinguishes this condition from esophoria. In our experience dissociated esodeviations occur much less frequently than dissociated exodeviations. If the deviation becomes intermittent and a cosmetic consideration, a posterior fixation of the medial rectus muscle of the involved eye 14 mm behind its insertion is effective. Observation rather than surgery has been advocated when the esotropia changes to exotropia during visual inattention.¹³²

In view of the great clinical similarity of dissociated vertical, torsional, and horizontal deviations, we agree with those who consider these strabismus forms as variations on the same theme rather than as different entities sui generis.^{114, 134}

Elevation in Adduction (Strabismus Sursoadductorius)

Clinical Characteristics

When examining the versions, one may find elevation of an eye as it moves toward adduction (Fig.

18–5). Once in a position of maximal elevation in adduction, the eye will be elevated further than a normal eye. This anomaly may be unilateral or bilateral and has been termed *strabismus sursoadductorius* or, if the opposite situation occurs, that is, the eye shows depression in adduction, *strabismus deorsoadductorius*. These Latin terms have never become popular in the English strabismologic literature where they are used in their translated forms, *elevation (or upshoot) in adduction* and *depression (or downshoot) in adduction*. Upshoot in adduction in its bilateral form is characterized by left hypertropia in dextroversion and right hypertropia in levoversion (double or alternating hypertropia), but a vertical deviation is present infrequently in primary position. Upshoot in adduction is an isolated phenomenon or occurs with esotropia or exotropia, often associated with a V pattern (see Chapter 19). It is frequently observed in infantile esotropia. *It is often automatically and erroneously assumed that elevation in adduction is caused by inferior oblique overaction, that is, by excessive innervation flowing to that muscle.* While this is often the case, we shall see that there are other causes for this condition.

Etiology

OVERACTION OF THE INFERIOR OBLIQUE MUSCLE. It has been customary to distinguish between primary and secondary overactions of this muscle. *Primary overaction* of the inferior oblique muscle in which there is no evidence for a past or present ipsilateral superior oblique paralysis or paresis is difficult to explain. A V-pattern type of strabismus is often present in such patients and, typically, the Bielschowsky head tilt test is negative. This condition occurs frequently in essential infantile esotropia.

The explanations given for apparent primary overaction in the older literature are vague, to say the least. Duane,²⁵ for instance, suggested that there is normally an upshoot of the adducted eye because of the greater mechanical advantage of the inferior oblique muscle of the adducted eye

over the superior rectus muscle of the abducted eye. It is of interest in this connection that Lisch and Simonsz⁶⁶ have reported in normal subjects up- and downshoot in adduction after prolonged monocular patching. This may suggest that there is a natural tendency for elevation and depression in adduction to occur but that under normal conditions such eye movements are controlled by fusion.⁶⁶ Scobee^{104, p.378} agreed that overaction of the inferior oblique muscle is normal because of the increased impulse required by the mechanically disadvantaged superior rectus muscle. This strong impulse is communicated to its yoke muscle, the inferior oblique of the adducted eye hidden behind the nose. He also stated that the elevating action of the inferior oblique muscle in adduction is greater than the depressing action of the superior oblique muscle. Therefore there would be an imbalance if the eyes should be dissociated by the nose, and the result would be an upshoot of the adducted eye. Lancaster⁶⁵ agreed with this view. Guibor⁴⁰ suggested that inferior oblique overactions could be caused by a synkinesis of that muscle with the ipsilateral medial rectus muscle owing to an impulse spread within the central nervous system.

None of these older explanations are convincing and it remains quite doubtful whether a true primary overaction of an oblique muscle on an innervational basis exists at all. The discovery of *muscle pulleys* (see below) has directed our attention to other etiologic possibilities for this apparent overaction. We are in agreement with Clark and coworkers¹⁶ who lamented the use of diagnosis-laden terms for ocular motility disorders except in cases where the etiology is clear. For this reason and because there are several causes for elevation in adduction that are unrelated to excessive inferior oblique muscle contraction, we recommend that the terms *primary overaction of the inferior oblique* (or, for that matter, of the superior oblique muscle) should be abandoned in favor of the more generic *elevation (or upshoot) in adduction* or *depression (or downshoot) in adduction*.

Secondary overaction of the inferior oblique

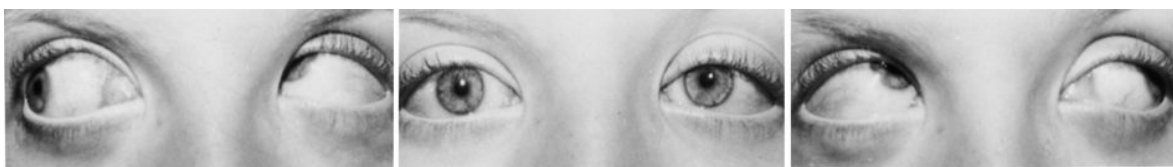

FIGURE 18–5. Elevation in adduction. Marked left hypertropia in dextroversion and right hypertropia in levoversion. No vertical deviation in primary position.

muscle is easier to understand and is caused by paresis or paralysis of the ipsilateral superior oblique muscle or by paresis or paralysis of the contralateral superior rectus muscle when the patient fixates with the paretic eye. In the latter situation the upshoot in adduction is actually caused by increased innervation flowing to the inferior oblique muscle, according to Hering's law. However, in the former condition the upshoot in adduction is not caused by excessive innervation of the inferior oblique muscle but by a lack of tonus of its paralyzed antagonist. In this situation a normal innervational impulse will suffice to cause the eye to overshoot in the field of action of the inferior oblique.

A similar situation exists when the balance of forces between superior and inferior oblique muscles is offset by anatomical rather than innervational causes, as in *plagiocephaly* (see Chapter 19). Here, the recessed trochlea has changed the plane of the superior oblique tendon, which places the inferior oblique at a functional advantage over the superior oblique, which causes an upshoot in adduction.

In the following discussion we shall see that elevation in adduction may be caused by a number of other factors.

HETEROTOPIA OF RECTUS MUSCLE PULLEYS.

Recent work by Clark and coworkers¹⁶ has provided evidence that what appears as primary overaction of an oblique muscle may actually be a secondary overaction of both elevators caused by heterotopia of muscle pulleys (see Chapter 3). Because of the significance of these findings with respect to the etiology of A and V patterns they will be discussed in Chapter 19

OCULAR AND ORBITAL TORSION. For a discussion of the roles of ocular and orbital torsion in producing upshoot in adduction, the reader is directed to Chapter 19, where this mechanism is discussed in connection with the etiology of A- and V-pattern strabismus. It will suffice to say here that excyclotropia of an eye may cause elevation in adduction and depression in abduction in the absence of increased innervation of the oblique muscles (Fig. 18–6). When the eye is excyclotorted the medial rectus muscle will no longer act as a pure adductor but will gain elevating action as well. Thus, medial rectus contraction will not only adduct but will also elevate the eye (upshoot) under these circumstances. Likewise, the lateral rectus muscle will no longer be a pure abductor

but abduct and depress the eye (downshoot). The elevation in adduction is usually more prominent than the depression in abduction, which may even be absent. This may be due to structural differences between the medial and lateral aspects of the orbit. It is of historical interest in this connection that Bielschowsky^{8, p.169} documented a case of an exotropic patient in whom a right hypertropia caused by an apparently overacting inferior oblique muscle disappeared after merely advancing and lowering the insertion of the medial rectus muscle.

DUANE SYNDROME. Another cause of elevation in adduction, unrelated to inferior oblique overaction, is the result of co-contraction of the horizontal rectus muscle in Duane's syndrome (see Chapter 21).

DISSOCIATED VERTICAL DEVIATION. Elevation in adduction caused by DVD when fusion is interrupted by the nasal bridge has been mentioned above.

Therapy

When elevation in adduction is caused by an overacting inferior oblique muscle, treatment, when indicated, is surgical and should consist of a weakening procedure on that muscle. In view of the different etiologies for upshoot in adduction discussed above, Spielmann¹¹⁵ warned against the indiscriminate use of inferior oblique weakening procedures for this condition. It seldom presents a cosmetic problem, considering that the eyes rarely move from primary position more than 15° to either side under casual conditions of seeing. Surgery is done mostly for functional reasons, that is, when the hypertropia in adduction presents an obstacle to fusion in lateral gaze or a V pattern exists that disrupts fusion in upward (V exotropia) or downward (V esotropia) gaze.

In apparently unilateral overaction of the inferior oblique muscle, a careful search should always be made in the fellow eye. After myectomy or recession of an overacting inferior oblique muscle, it is not unusual for overaction in the fellow eye to become manifest.¹²⁹

Depression in Adduction (Strabismus Deorsoadductorius)

As mentioned in the preceding paragraph in connection with elevation, a depression in adduction

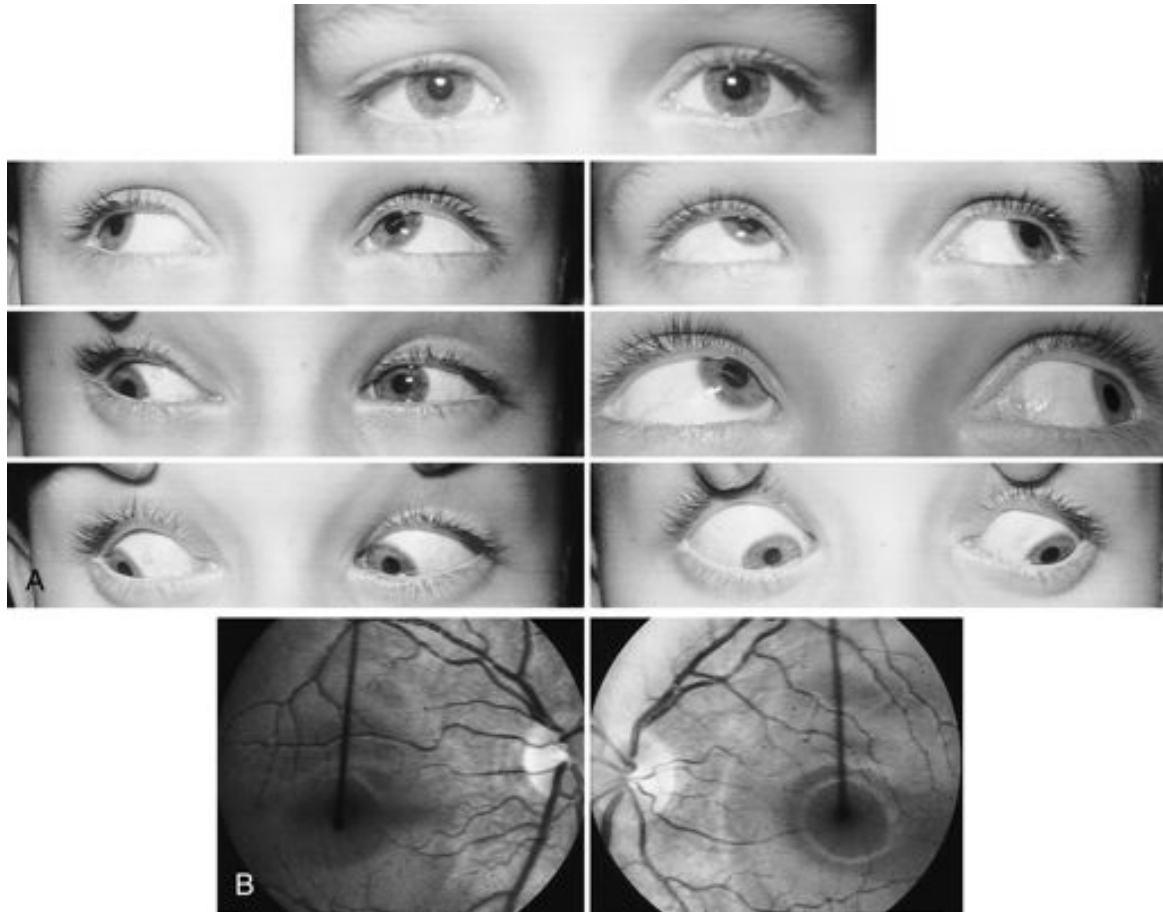


FIGURE 18-6. A, Elevation of the adducted and depression of the abducted and right eye in a patient who was orthotropic in primary position and had otherwise normal ductions and versions. B, Fundus photographs show a large right exocyclotropia of the right eye.

(Fig. 18-7) may have more than one cause. Again, we must distinguish between *primary* and *secondary* forms. Secondary overaction is well understood and may occur on the basis of paresis or paralysis of the ipsilateral inferior oblique muscle or of the contralateral inferior rectus muscle. Another cause of secondary overaction is contracture of the contralateral superior rectus muscle, which is occasionally seen in conjunction with long-

standing paralysis of the contralateral superior oblique muscle (see p. 435). In view of the relative frequency of superior oblique paralyses when compared with paralysis of the inferior oblique and inferior rectus muscles, it is not surprising that depression in adduction occurs less frequently than elevation.

As in the case of so-called primary overaction of the inferior oblique muscle the etiology of



FIGURE 18-7. Left, Depression of either eye in adduction. Center, Fusion in primary position. Right, Apparent overaction of both superior oblique muscles with marked exodeviation (A pattern) in downward gaze. (From Noorden GK von: Atlas of Strabismus, ed 4. St Louis, Mosby-Year Book, 1983.)

apparently primary overaction of the superior oblique is obscure and, analogously to the former, we prefer the more generic term *depression in adduction* for this condition. The recent findings of heterotopic muscle pulleys to explain a downshoot on adduction on a mechanical basis has been mentioned (see p. 387). Ocular or orbital incyclotropion may also cause depression in adduction, similar to the elevation produced by ex-cyclotropion. Duane's syndrome with co-contraction of the horizontal rectus muscles and Brown's syndrome are other causes.

Cyclodeviations

In cyclotropia the eyes are misaligned around the anteroposterior axis either as an isolated disturbance of ocular motility or, more frequently, in association with any other form of strabismus. In most instances, cyclodeviations are caused by an imbalance between the muscle pair affecting intorsion (superior oblique and superior rectus muscles) and the muscle pair producing extorsion of the globe (inferior oblique and inferior rectus muscles). Consequently, such deviations are associated almost invariably with paretic or paralytic cyclovertical muscle problems, particularly those caused by dysfunction of the oblique muscles. On the other hand, cyclodeviations also occur in association with DVD, in the A and V patterns of strabismus without an obvious paretic component, in endocrine ophthalmopathy, myasthenia gravis,¹²² plagiocephaly,⁵⁵ after surgery for retinal detachment,⁷² and in heterotopia of the macula, secondary to retinal traction.¹⁰⁵

In recent years iatrogenic cyclodeviations have been produced surgically as a consequence of *macular rotation for age-related macular degeneration*.

Diagnosis

The diagnosis of cyclodeviations is discussed in Chapter 12.

Clinical Characteristics

No studies are available that reflect the prevalence of cyclodeviations. Most ophthalmologists do not routinely test for such anomalies unless the patient specifically complains about torsional diplopia. In the absence of a cyclovertical muscle imbalance

such complaints are easily misinterpreted, as pointed out by Kushner.⁶³ The results of fundus photography (see Fig. 18–6), the Maddox double rod test, and scotometry⁶⁷ show that *cyclodeviations occur with great regularity and frequency* with any disturbance of the oblique and, to a somewhat lesser degree, vertical rectus muscles. Curiously, however, with the exception of paretic conditions of *recent* onset,⁴² particularly traumatic unilateral or bilateral superior oblique paralysis, symptoms related to cyclotropia—such as torsional diplopia, dizziness, and difficulties in negotiating stairways, steps, and street curbs—are seldom encountered in clinical practice.

There are several reasons why patients with cyclodeviations are commonly asymptomatic.^{43, 79} First, we must consider that cyclodeviations remain compensated for by *cyclofusion* through cyclovergences.^{21, 52, 57, 86} In such patients the Maddox rods (see Chapter 12) will show various degrees of cyclotropia. However, when tested with Bagolini lenses and the coexisting vertical or horizontal deviations are prismatically corrected, cyclotropia will be absent.⁹⁹ This discrepancy in testing results is explained by the fact that Maddox rods disrupt fusion, whereas Bagolini lenses do not. Ruttum and von Noorden⁹⁹ pointed out that whereas the Maddox test is of value in substantiating and measuring cyclotropia, it addresses the position of the eye only under dissociated viewing conditions. The Bagolini test result, on the other hand, predicts how a patient will handle a cyclotropia by cyclofusion when coexisting vertical and horizontal deviations are surgically eliminated.

The question whether cyclofusion occurs purely on a sensory basis or has a motor component has been discussed in Chapter 4. It has been claimed in the literature that in cyclophoria the involved eye realigns itself around its anteroposterior axis under the influence of cyclofusion.^{1, 26} However, we have been unable to ascertain the presence of such a corrective cycloduction by direct observation (see also Jampel and coworkers⁵⁷) or by comparison of fundus photographs taken under monocular and binocular viewing conditions.^{42, 78, 79} Likewise, Locke⁶⁷ found no change in the position of the vertically displaced blind spot of cyclotropic patients when perimetry was performed under monocular and binocular conditions. On the other hand, Herzau and Joos⁴⁸ noted variations in position of the blind spot during monocular and binocular perimetry on the phase difference haploscope in patients with cyclovertical

strabismus and concluded that cyclofusional movements must exist after all (see also Kolling⁶⁰). However, the velocity of such movements is slow and their amplitudes are small so that they may easily escape detection with the naked eye.⁴⁹

SENSORIAL ADAPTATIONS. Many patients are unaware of image tilting because of *suppression*, *anomalous retinal correspondence*,⁴ or, in rare instances, a *compensatory anomalous head posture*.⁸⁵ However, these mechanisms do not explain the common and puzzling finding that a patient whose eye is found to be rotated around the anteroposterior axis on ophthalmoscopy or fundus photography (see Chapter 12) fails to see a tilted visual environment when the nonparalyzed eye is occluded. The reason for this frequent finding, for instance, in patients with congenital superior oblique palsy, is that adaptations have developed that are quite unique to cyclodeviations.

The older literature contains references to the fact that the spatial response of retinal elements can be reordered along new vertical and horizontal meridians,^{50, 51} and the famous case of Sachs and Meller¹⁰⁰ is cited often in this connection. Ruttum and von Noorden⁹⁸ and Olivier and von Noorden⁸⁹ reinvestigated this phenomenon and confirmed that a spatial reorientation of the horizontal and vertical retinal meridians occurs in certain patients with congenital or early acquired cyclodeviations. This spatial adaptation compensates for the image tilt that would otherwise be perceived (Fig. 18-8). It explains why patients with objective cyclotorsion of one eye continue to see a vertical line as vertical and a horizontal line as horizontal in the absence of all other visual clues.⁹⁸ This adaptation is not irreversible. Patients with a congenital cyclotropia may temporarily note a tilting of the environment in the opposite direction after surgical correction of the cyclotropia before normal, innate spatial orientation of the retinal meridians reestablishes itself.^{78, 83} The practical implication of this finding in connection with postoperative adjustment of a Harada-Ito procedure is mentioned at the end of this chapter.

Even in normal subjects there exists a certain degree of spatial adaptability of the vertical and horizontal retinal meridians and their central connection as demonstrated in the famous "tilt after-effect" experiment of Vernon¹²⁶ and Gibson and Radner.³⁷ This experiment may be easily repeated by the interested reader: monocular observation for a few minutes of a fixation mark bisecting a

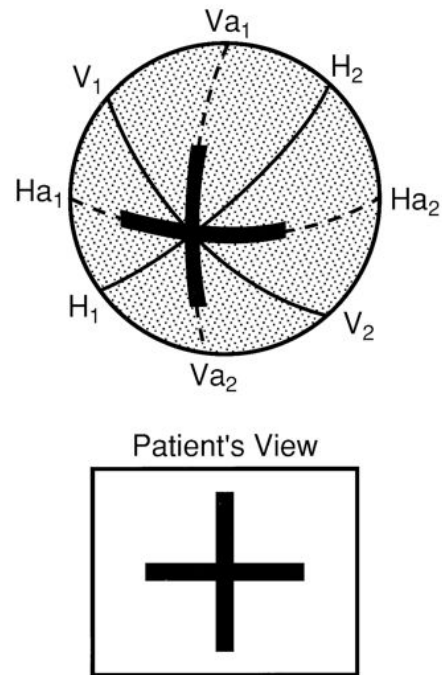


FIGURE 18-8. Reorientation of the retinal meridians in a left eye with excyclotropia (view from behind the globe). The image of a cross will no longer be imaged on the normal vertical (V_1 - V_2) and horizontal (H_1 - H_2) retinal meridians but on the new vertical (V_{a1} - V_{a2}) and horizontal (H_{a1} - H_{a2}) meridians. Despite the objective excyclotorsion, a cross imaged on these new retinal meridians will not be seen as tilted by the patient.

line inclined 45° will cause a subsequently viewed vertical line to appear inclined in the opposite direction. Adaptation to a tilted environment probably has a neurophysiologic basis in terms of a change in orientation tuning of the striate cortical neurons¹² and suggests a certain degree of cortical plasticity even in visually mature adults.

PSYCHOLOGICAL ADAPTATION. Some cyclo-tropic patients may be unaware of a tilted environment because of empirical spatial clues. Experience has taught us that familiar objects such as doors, windows, houses, and trees have a consistent vertical or horizontal orientation in physical space. Such spatial clues from an orderly visual environment are used to correct for image tilting.⁵⁰ As soon as this normal frame of visual reference is no longer available, for instance, in complete darkness, these patients become aware of cyclotropia. Ruttum and von Noorden⁹⁸ confirmed this by measuring the so-called subjective horizontal in cyclotropic subjects. The *subjective horizontal* is defined as a subject's perception of a horizontal plane as opposed to its actual position in physical space. Its determination was once a popular diagnostic procedure in the diagnosis of cyclovertical

strabismus. Asymptomatic patients with cyclotropia as diagnosed by fundus photography and Maddox rods may perceive a faintly illuminated horizontal line as tilted when no other visual clues are available.⁹⁸

There is no uniformity in the utilization of these physiologic and psychological mechanisms that enable a cyclotropic patient to live in relative visual comfort despite a potentially disabling anomaly of ocular motility.^{48, 60, 98, 118, 120} The various adaptations to cyclodeviations are employed either exclusively or in combination with each other. This explains the often confusing variety of results obtained with different tests and the objective finding of cyclotropia in the absence of symptoms. A spectrum of effectiveness of these adaptations exists that includes incomplete adaptation with constant or intermittent torsional diplopia, complete but easily dissociated adaptations in those with acquired cyclotropia, and deep-seated adaptations that are effective under monocular and binocular conditions in patients with congenital cyclotropia.

Therapy

The use of cylindrical lenses with their axis placed so as to offset the cyclotropia has been advocated, but the value of this therapy is highly questionable. The treatment of symptomatic cyclotropia is *surgical*. When the action of the oblique muscles is abnormal, cyclotropia usually occurs in association with a clinically significant hyperdeviation; thus the choice of muscles on which to operate presents no difficulties, *since elimination of the hyperdeviation also will correct the cyclodeviation*. For instance, in a patient with paralysis of the homolateral superior oblique muscle, excyclotropia caused by unopposed action of the inferior oblique muscle can be eliminated by a weakening procedure on the inferior oblique muscle that will correct both the hyperdeviation and the cyclodeviation. Likewise, if the inferior oblique muscles are not overacting and the vertical deviation occurs only in the field of action of the paretic muscle, tucking of the tendon of the paretic superior oblique muscle is similarly effective in eliminating the hyperdeviation and the excyclotropia.

Management of *isolated cyclodeviations* in patients without a significant associated vertical deviation presents a special problem. The most frequent cause for an isolated symptomatic cyclotropia is a residual excyclotropia after trau-

matic trochlear paralysis. A conventional weakening or strengthening procedure on offending cyclovertical muscles may correct the cyclodeviation in such cases, but it will also produce an undesired vertical effect. A procedure is required that affects the cyclodeviation exclusively. This requirement is met by several operations. The advancement and lateralization of the superior oblique tendon for excyclotropia according to Harada and Ito⁴³ (see Chapter 26) and its many variations has become firmly established in our surgical armamentarium. However, this procedure cannot be performed when the superior oblique tendon is congenitally absent or has been previously tenotomized. In that case nasal transposition of the inferior rectus muscle^{74, 84} is an effective surgical alternative to correct excyclotropia in downward gaze. When excyclotropia is also present in primary position we add a temporal transposition of the superior rectus muscle.⁸⁴ For incyclotropia, which occurs much less frequently than excyclotropia, the inferior rectus is shifted templeward and the superior rectus nasalward.⁸⁴ In our hands, the average effect of these operations in terms of rotating the eye around the anteroposterior axis is 10°, ranging from 8° to 12°. Ohmi and coworkers⁸⁸ reported similar results. Other procedures to correct cyclotropia without producing vertical or horizontal strabismus include slanting of the insertion of all rectus muscles,^{34, 113} vertical transposition of the horizontal rectus muscles,²² and transpositions of the anterior aspects of the inferior and superior oblique tendons.¹⁸ The surgical technique for these procedures, as well as surgical induction of cyclotropia to counteract a compensatory head tilt in patients with congenital nystagmus,⁸¹ is discussed in Chapters 23 and 26.

An overcorrection after surgery for cyclotropia (e.g., excyclotropia changing to incyclotropia) usually is only temporary and can be explained by the persistence of sensory adaptation to image tilting.^{42, 78} The surgeon should keep this in mind and not be too hasty in planning a reoperation or adjusting the sutures on the first postoperative day if adjustable sutures are used for the Harada-Ito procedure. In fact, a slight overcorrection after the Harada-Ito procedure is desirable since the effect of surgery tends to decrease with time.

A special challenge exists in patients who had *vertical macular translocation* for improvement of visual acuity of an eye with *age-related macular degeneration*. This operation invariably causes horizontal and vertical strabismus in addition to

cyclotropia. The magnitude of this iatrogenic incyclotropia is formidable indeed if compared to what is usually encountered in cyclovertical strabismus and may range from as much as 33 degrees^{28, 29, 36} to 45 degrees.¹⁰⁶ It is all the more surprising that spontaneous adaptations have been reported in such patients^{106, 107} but most will complain about an intolerable shift of the visual environment. Conventional surgery consisting of an advancement and transposition of the inferior oblique and a recession of the superior oblique muscle, as advocated by Conrad and de Decker¹⁸ and as employed by others,³⁶ or horizontal transposition as used by us, does not suffice to correct a cyclodeviation of this magnitude. Eckardt and Eckardt,^{28, 29} recently recommended adding to the surgery on the oblique muscles (according to Conrad and de Decker¹⁸) a transposition of strips from two or from all four rectus muscles to the insertion of the adjoining rectus muscles, similar to a Hummelsheim procedure. This nearly doubled the cyclorotational effect of the operation to a total of 30° to 40°, which about compensated for the cyclotropia produced by macular translocation. Freedman and coworkers³⁶ advocated combined superior oblique muscle recession and inferior oblique advancement for incyclotropia following macular translocation. A rotation of only a retinal flap rather than the entire retina apparently causes less of a postoperative image tilt, since patients operated on in this fashion adjusted to the tilt without muscle surgery.^{24, 75} Perhaps this modification, if proved to be as effective as total retinal rotation, will eventually eliminate the need for muscle surgery in conjunction with or following macular translocation.

REFERENCES

- Alpern M: Muscular mechanisms. In Davson H, ed: *The Eye*. New York, Academic Press, 1962, p 177.
- Anderson JR: *Ocular Vertical Deviations and the Treatment of Nystagmus*, ed 2. London, British Medical Association, 1959.
- Bach M, Kommerell G: Albino-type misrouting of the optic nerve fibers not found in dissociated vertical deviation. *Graefes Arch Clin Exp Ophthalmol* 230:158, 1992.
- Bagolini B, Campos E, Chiesi C: Plagiocephaly causing superior oblique deficiency and ocular torticollis. *Arch Ophthalmol* 100:1093, 1982.
- Bechtel RT, Kushner BJ, Morton GV: The relationship between dissociated vertical divergence (DVD) and head tilts. *J Pediatr Ophthalmol Strabismus* 33:303, 1996.
- Bielschowsky A: Die einseitigen und gegensinnigen ("dissoziierten") Vertikalbewegungen der Augen. *Graefes Arch Clin Exp Ophthalmol* 125:493, 1931.
- Bielschowsky A: Disturbances of the vertical motor muscles of the eyes. *Arch Ophthalmol* 20:175, 1938.
- Bielschowsky A: *Lectures on Motor Anomalies*. Hanover, NH, Dartmouth Publishing Co, 1943/1956.
- Black BC: Results of anterior transposition of the inferior oblique muscle in incomitant dissociated vertical deviation. *J Am Assoc Pediatr Ophthalmol Strabismus* 1:83, 1997.
- Boylan C, Clement RA, Howrie A: Normal visual pathway routing in dissociated vertical deviation. *Invest Ophthalmol Vis Sci* 29:1165, 1988.
- Brodsky MC: Dissociated vertical divergence, a righting reflex gone wrong. *Arch Ophthalmol* 117:1216, 1996.
- Bruce CJ, Isley MR, Shinkman PG: Visual experience and development of interocular orientation disparity in visual cortex. *J Neurophysiol* 46:215, 1981.
- Burke JP, Scott WE, Kutschke PJ: Anterior transposition of the inferior oblique muscle for dissociated vertical deviation. *Ophthalmology* 100:245, 1993.
- Campos E, Schiavi C, Bolzani R, Cipolli C: Binocular vertical perceptual adaptation in essential infantile esotropia. *Perceptual Mot skills* 87:1211, 1998.
- Cheeseman EW, Guyton DL: Vertical fusional vergence. The key to dissociated vertical deviation. *Arch Ophthalmol* 117: 1188, 1999.
- Clark RA, Miller JM, Rosenbaum AL, Demer JL: Heterotopic muscle pulleys or oblique muscle dysfunction? *J Am Assoc Pediatr Ophthalmol Strabismus* 2:17, 1998.
- Clarke M, Johnson FM, Harcourt B: Left Duane's retraction syndrome associated with dissociated vertical divergence—a case report. *Br Orthopt J* 45:78, 1988.
- Conrad HG, Decker W de: "Rotatorischer Kestenbaum." Umlagerungschirurgie bei Kopfzwangshaltungen zur Schulter. *Klin Monatsbl Augenheilkd* 173:681, 1978.
- Crone RA: Alternating hyperphoria. *Br J Ophthalmol* 38:592, 1954.
- Crone RA: Diplopia. Amsterdam, Excerpta Medica, 1973, p 75.
- Crone RA, Everhard-Halm Y: Optically induced eye torsion. I. Fusional cyclovergence. *Graefes Arch Clin Exp Ophthalmol* 195:231, 1975.
- de Decker W: Rotatorischer Kestenbaum an den geraden Augenmuskeln. *Z Prakt Augenheilkd* 11:11, 1990.
- de Decker W, Dannheim-de Decker E: Unbeachtete Zwangshaltungen beim frühkindlichen Schielsyndrom. *Klin Monatsbl Augenheilkd* 215:95, 1999.
- De Juan E, Loewenstein A, Bressler NM, Alexander A: Limited retinal translocation of the retina for management of subfoveal choroidal neovascularization. II. A preliminary report in humans. *Am J Ophthalmol* 125:635, 1998.
- Duane A: Binocular movements. *Arch Ophthalmol* 9:579, 1933.
- Duke-Elder S, Wybar K: *System of Ophthalmology*, vol 6: *Ocular Motility and Strabismus*. St Louis, Mosby-Year Book, 1973, p 252.
- Duncan L, Noorden GK von: Surgical results in dissociated vertical deviations. *J Pediatr Ophthalmol Strabismus* 21:25, 1984.
- Eckardt U, Eckardt C: Macular rotation with and without counter rotation of the globe in patients with age related macular degeneration. *Graefes Arch Clin Exp Ophthalmol* 237:313, 1999.
- Eckardt U, Eckardt C: Orthoptische Probleme nach Makularrotation mit und ohne Muskelchirurgie. *Klin Monatsbl Augenheilkd*; 212:212, 1998.
- Enke ES, Stewart SA, Scott WE, Wheeler DT: The prevalence of dissociated horizontal deviations in congenital esotropia. *Am Orthopt J* 44:109, 1994.
- Enright JT: Unexpected role of the oblique muscles in the human vertical fusional reflex. *J Physiol (Lond)* 451:279, 1992.
- Esswein MB, Noorden GK von, Coburn A: Comparison

- of surgical methods in the treatment of dissociated vertical deviation. *Am J Ophthalmol* 113:287, 1992.
33. Esswein Kapp MB, Noorden GK von: Treatment of residual dissociated vertical deviation with inferior rectus resection. *J Pediatr Ophthalmol Strabismus* 31:262, 1994.
 34. Fink WH: Surgery of the Vertical Muscles of the Eye, ed 2. Springfield, IL, Charles C Thomas, 1962, p 369.
 35. Fitzgerald BA, Billson FA: Dissociated vertical deviation: Evidence of abnormal visual pathway projection. *Br J Ophthalmol* 68:801, 1984.
 36. Freedman SF, Seaber JH, Buckley EG, et al: Combined superior oblique muscle recession and inferior oblique advancement and transposition for cyclotorsion associated with macula translocation surgery. *J Am Assoc Pediatr Ophthalmol Strabismus* 4:75 2000.
 37. Gibson JJ, Radner M: Adaptation, aftereffect and contrast in the perception of titled lines. I. Quantitative studies. *J Exp Psychol* 20:453, 1937.
 38. Gobin, M.H.: Sagittalization of the oblique muscles as a possible cause for the "A," "V," and "X" phenomena. *Br J Ophthalmol* 52:13, 1968.
 39. Goltz HC, Irving EL, Hill JA, et al: Dissociated vertical deviation: Head and body orientation affect the amplitude and velocity of the vertical drift. *J Pediatr Ophthalmol Strabismus* 33:307, 1996.
 40. Guibor GP: Synkinetic overaction of the inferior oblique muscle. *Am J Ophthalmol* 32:100, 1949.
 41. Guyton D: Dissociated vertical deviation: An exaggerated normal eye movement used to damp cyclovertical nystagmus. *Trans Am Ophthalmol Soc* 96:389, 1998.
 42. Guyton DL, Noorden GK von: Sensory adaptations to cyclodeviations. In Reinecke RD, ed: *Strabismus*. New York, Grune & Stratton, 1978.
 43. Harada M, Ito Y: Surgical correction of cyclotropia. *Jpn J Ophthalmol* 8:88, 1964.
 44. Harcourt B, Mein J, Johnson F: Natural history and associations of dissociated vertical divergence. *Trans Ophthalmol Soc UK* 100:495, 1980.
 45. Helveston EM: A-exotropia, alternating sursumduction and superior oblique overaction. *Am J Ophthalmol* 67:377, 1969.
 46. Helveston EM: Dissociated vertical deviation: A clinical and laboratory study. *Trans Am Ophthalmol Soc* 78:734, 1980.
 47. Helveston EM, Neely DF, Stidham DB, et al: Results of early alignment of congenital esotropia. *Ophthalmology* 106:1716, 1999.
 48. Herzau V, Joos E: Untersuchungen von Bewegungen und Stellungsfehlern der Augen um ihre sagittale Achse *Z Prakt Augenheilkd* 4:270, 1983.
 49. Herzau V, Joos-Kratsch E: Objective and subjective evaluation of cyclovergence and cyclofusion. *Doc Ophthalmol* 58:85, 1984.
 50. Herzau W: Bestimmung der Medianabweichung des Auges. *Klin Monatsbl Augenheilkd* 86:406, 1931.
 51. Hofmann FB, Bielschowsky A: Über die Einstellung der scheinbaren Horizontalen und Vertikalen bei Betrachtung eines von schrägen Konturen erfüllten Gesichtsfeldes. *Arch Ges Physiol* 126:453, 1909.
 52. Hooten K, Myers E, Worall R, Stark L: Cyclovergence: The motor response to cyclodisparity. *Graefes Arch Clin Exp Ophthalmol* 210:65, 1979.
 53. Houtman WA, Roze JH, De Vries B, Letsch MC: Alternating hyperphoria. Dissociated vertical deviation (DVD) occlusion hyperphoria. *Doc Ophthalmol* 78:135, 1991.
 54. Inoue M, Kita Y: Eye movements in dissociated vertical deviation. *Acta Soc Ophthalmol Jpn* 97:1312, 1993.
 55. Ioannakis K, Herzau V: Cyclodeviation in plagiocephaly. In Kaufmann H, ed: *Transactions of the 16th Meeting of the European Strabismological Association*, Giessen, Germany, 1987, p 297.
 56. Irving EL, Goltz HC, Steinbach MJ, Kraft SP: Vertical latent nystagmus component and vertical saccadic asymmetries in subjects with dissociated vertical deviation. *J Am Assoc Pediatr Ophthalmol Strabismus* 2:344, 1998.
 57. Jampel RS, Sterns AB, Bugola J: Cyclophoria or cyclovergence: Illusion or reality. In Moore S, Mein J, Stockbridge L, eds: *Orthoptics: Past, Present, Future: Transactions of the Third International Orthoptic Congress*. New York, Stratton Intercontinental, 1976, p 403.
 58. Kii T, Ogasawara K, Ohba M, et al: The effectiveness of the Faden operation on the superior rectus muscle combined with recession of the muscle for the treatment of dissociated vertical deviation. *Acta Soc Ophthalmol Jpn* 98:98, 1994.
 59. Knapp P: Dissociated vertical deviations. In Fells P, ed: *Second Congress of the International Strabismological Association*. Marseilles, Diffusion Générale de Librairie, 1976, p 185.
 60. Kolling G: Möglichkeiten und Grenzen der Messung von Zyklodeviationen unter besonderer Berücksichtigung des Deviometers nach Cüppers. *Klin Monatsbl Augenheilkd* 178:89, 1981.
 61. Kratz RE, Rogers GL, Bremer DL, Leguire LE: Anterior tendon displacement of the inferior oblique for DVD. *J Pediatr Ophthalmol Strabismus* 26:212, 1989.
 62. Kriss A, Timms C, Elston J, et al: Visual evoked potentials in dissociated vertical deviation: A reappraisal. *Br J Ophthalmol* 73:265, 1989.
 63. Kushner BJ: Unexpected cyclotropia simulating disruption of fusion. *Arch Ophthalmol* 110:1415, 1992.
 64. Kutluk S, Avilla CW, Noorden GK von: The prevalence of dissociated vertical deviation in patients with sensory heterotropia. *Am J Ophthalmol* 119:744, 1995.
 65. Lancaster WB: Factors underestimated, features overemphasized, and comments on classification. In Allen JE, ed: *Strabismus Ophthalmic Symposium, II*. St Louis, Mosby-Year Book, 1958, p 430.
 66. Lisch A, Simonsz HJ: Up- and downshoot in adduction after monocular patching in normal volunteers. *Strabismus* 1:25, 1993.
 67. Locke JC: Heterotopia of the blind spot in ocular vertical muscle imbalance. *Am J Ophthalmol* 65:362, 1968.
 68. Lorenz B, Raab I, Boergen KP: Dissociated vertical deviation: What is the most effective surgical approach? *J Pediatr Ophthalmol Strabismus* 29:21, 1992.
 69. Lyle TK, Bridgeman GJO: Worth and Chavasse's Squint. *The Biocular Reflexes and the Treatment of Strabismus*. London, Baillière, Tindall & Cox, 1959, p 350.
 70. Magoon E, Cruciger M, Jampolsky A: Dissociated vertical deviation: An asymmetric condition treated with large bilateral superior rectus recession. *J Pediatr Ophthalmol Strabismus* 19:152, 1982.
 71. McCall LC, Rosenbaum AL: Incomitant dissociated vertical deviation and superior oblique overaction. *Ophthalmology* 98:911, 1991.
 72. Metz HS, Norris H: Cyclotorsional diplopia following retinal detachment surgery. *J Pediatr Ophthalmol Strabismus* 24:287, 1987.
 73. Moore S, Cohen RT: Congenital exotropia. *Am Orthopt J* 35:68, 1985.
 74. Mumma JV: Surgical procedure for congenital absence of the superior oblique. *Arch Ophthalmol* 92:221, 1974.
 75. Ninomiya Y, Lewis JM, Hasegawa T, Tano Y: Retinotomy and foveal translocation for surgical management of subfoveal choroidal neovascular membranes. *Am J Ophthalmol* 122:613-621, 1996.
 76. Noorden GK von: Indications of the posterior fixation operation in strabismus. *Ophthalmology* 85:512, 1978.
 77. Noorden GK von: Posterior fixation suture in strabismus surgery. In *Symposium on Strabismus: Transactions of*

- the New Orleans Academy of Ophthalmology. St Louis, Mosby-Year Book, 1978, p 307.
78. Noorden GK von: Clinical observations in cyclodeviations. *Ophthalmology* 86:1451, 1979.
 79. Noorden GK von: Cyclotropia: Theoretical and practical aspects (Costenbader lecture). *J Pediatr Ophthalmol Strabismus* 21:126, 1984.
 80. Noorden GK von: Current concepts of infantile esotropia (Bowman Lecture). *Eye* 2:343, 1988.
 81. Noorden GK von: Horizontal transposition of the vertical rectus muscles for treatment of ocular torticollis. *J Pediatr Ophthalmol Strabismus* 30:8, 1993.
 82. Noorden GK von: Discussion of paper by Guyton D: Dissociated vertical deviation: An exaggerated normal eye movement used to damp cyclovertical nystagmus. *Trans Am Ophthalmol Soc* 46:389, 1998.
 83. Noorden GK von, Brown DJ, Parks M: Clinical observations in cyclotropia. Presented at the American Orthoptic Council—American Association of Certified Orthoptists Symposium at the American Academy of Ophthalmology and Otolaryngology, Dallas, Sept 16, 1973.
 84. Noorden GK von, Chu MW: Surgical treatment options in cyclotropia. *J Pediatr Ophthalmol Strabismus* 27:291, 1990.
 85. Noorden GK von, Ruttum M: Torticollis in paralysis of the trochlear nerve. *Am Orthopt J* 33:16, 1983.
 86. Ogle KN, Ellerbrock VJ: Cyclofusional movements. *Arch Ophthalmol* 36:700, 1946.
 87. Ohm J: Schrägschielen. *Arch Augenheilkd* 39:619, 1928.
 88. Ohmi G, Fujukado T, Ohji M, et al: Horizontal transposition of vertical rectus muscles for treatment of excyclotropia. *Graefes Arch Clin Exp Ophthalmol* 235:1, 1997.
 89. Olivier P, Noorden GK von: Excyclotropia of the nonparetic eye in unilateral superior oblique muscle paralysis. *Am J Ophthalmol* 93:30, 1982.
 90. Parks MM: Personal communication, Oct 5, 1973.
 91. Posner A: Noncomitant hyperphorias considered as aberrations of the postural tonus of the muscular apparatus. *Am J Ophthalmol* 27:1275, 1944.
 92. Raab E: Dissociative vertical deviation. *J Pediatr Ophthalmol Strabismus* 7:146, 1970.
 93. Rijn LJ van, Collewijn H: Eye torsion associated with disparity-induced vertical vergences in humans. *Vision Res* 17:2307, 1994.
 94. Rijn LJ van, ten Tusscher MPM, Jong I de, Hendrikse F: Asymmetrical vertical phorias indicating dissociated vertical deviation in subjects with normal binocular vision. *Vision Res* 38:2973, 1998.
 95. Rimmer S, Katz B: Dissociated vertical deviation in a patient with Duane's retraction syndrome. *J Clin Neuro Ophthalmol* 10:38, 1990.
 96. Romero-Apis D: Comportamiento clínico de los estrabismos secundarios. *Anal Soc Mex Oftalmol* 54:153, 1980.
 97. Ruttum MS: Anterior transposition of the inferior oblique muscles. *Am Orthop J* 47:118, 1997.
 98. Ruttum M, Noorden GK von: Adaptation to tilting of the visual environment in cyclotropia. *Am J Ophthalmol* 96:229, 1983.
 99. Ruttum M, Noorden GK von: The Bagolini striated glass test for cyclotropia. *Doc Ophthalmol* 58:131, 1984.
 100. Sachs M, Meller J: Über einige eigentümliche Lokalisationsphänomene in einem Falle von hochgradiger Netzhautinkongruenz. *Graefes Arch Clin Exp Ophthalmol* 57:1, 1904.
 101. Santiago AP, Rosenbaum AL: Dissociated vertical deviation and head tilt. *Am Assoc Pediatr Ophthalmol Strabismus* 2:5, 1998.
 102. Schweigger C: Die Erfolge der Schieloperation. *Arch Augenheilkd* 30:165, 1895.
 103. Scobee RG: Esotropia: Incidence, etiology and results of therapy. *Am J Ophthalmol* 34:817, 1951.
 104. Scobee RG: *The Oculorotary Muscles*, ed 2. St Louis, Mosby-Year Book, 1952.
 105. Schroeder B, Krzizok T, Kaufmann H, Kroll P: Störung des Binokularsehens bei Makulaheterotropie. *Klin Monatsbl Augenheilkd* 215:135, 1999.
 106. Seaber JH, Macheimer R: Adaptation to monocular torsion after macular translocation. *Graefes Arch Clin Exp Ophthalmol* 235:76, 1997.
 107. Seaber JH, Freedman SF, Toth C: Adaptation to torsion after macular translocation surgery. In *Orthoptics in Focus-Vision for the New Millennium*. Transactions of the Ninth International Orthoptic Congress, Stockholm, 1999, p 25.
 108. Seawright AA, Gole GA: Results of anterior transposition of the inferior oblique. *Aust N Z J Ophthalmol* 24:339, 1996.
 109. Sidikaro Y, Noorden GK von: Observations in sensory heterotropia. *J Pediatr Ophthalmol Strabismus* 19:12, 1982.
 110. Simon JW, Bayramlar H, Kamath S: Atropine penalization therapy of dissociated vertical deviations. *Binocular Vision Strabismus* 11:263, 1996.
 111. Spielmann A: A translucent occluder for studying eye position under unilateral or bilateral cover test. *Am Orthopt J* 36:65, 1986.
 112. Spielmann A: Les divergences verticales dissociées: Excès de sursumversion lié à la fixation. *Ophtalmologie* 1:457, 1987.
 113. Spielmann A: The oblique Kestenbaum procedure revisited (sloped recession of the recti). In *Lenk-Schäfer M, ed: Orthoptic Horizons*. Transactions of the Sixth International Orthoptic Congress, Harrogate, England, 1987, p 433.
 114. Spielmann A: Déséquilibres verticaux et torsionnels dans le strabisme précoce. *Bull Soc Ophtalmol Fr* 90: 373,381, 1990.
 115. Spielmann A: *Les strabismes*. De l'analyse clinique à la synthèse chirurgicale, ed 2. Paris, Masson, 1991, p 204.
 116. Spielmann A: Les élévation en adduction: Contre une chirurgie systématique du muscle petit oblique. *Ophtalmologie* 5:427, 1991.
 117. Sprague JB, Moore S, Eggers H, Knapp P: Dissociated vertical deviation: Treatment with the fadenoperation of Cüppers. *Arch Ophthalmol* 98:465, 1980.
 118. Sradj H: *Rollungsschielen*. Physiologie. Instrumentarium. Therapie. Giessen, Germany, Köhler, 1979.
 119. Stager DR, Weakley DR Jr, Stager D: Anterior transposition of the inferior oblique. Anatomic assessment of the neurovascular bundle. *Arch Ophthalmol* 110:360, 1992.
 120. Sullivan MJ, Kertesz A: Peripheral stimulation and human cyclofusional response. *Invest Ophthalmol Vis Sci* 18:1287, 1979.
 121. Swan K, cited by Lancaster WB: Factors underestimated, features overemphasized, and comments on classification. In *Allen, JE, ed: Strabismus Ophthalmic Symposium, II*. St Louis, Mosby-Year Book, 1958.
 122. Trobe JD: Cyclodeviations in acquired vertical strabismus. *Arch Ophthalmol* 102:717, 1984.
 123. Varn MM, Saunders RA, Wilson ME: Combined bilateral superior rectus muscle recession and inferior oblique muscle weakening for dissociated vertical deviation. *J Am Assoc Pediatr Ophthalmol Strabismus* 1:134, 1996.
 124. Velez G: Dissociated vertical deviation. *Graefes Arch Clin Exp Ophthalmol* 226:117, 1988.
 125. Verhoeff FH: Occlusion hypertropia. *Arch Ophthalmol* 25:780, 1941.
 126. Vernon MD: The perception of inclined lines. *Br J Psychol* 25:186, 1934–1935.

127. White JW: Hyperphoria. Diagnosis and treatment. *Arch Ophthalmol* 7:739, 1932.
128. White JW, Brown HW: Occurrence of vertical anomalies associated with convergent and divergent anomalies. *Arch Ophthalmol* 21:999, 1939.
129. Wieser D: Pseudoeinseitiger Strabismus sursoadductorius. *Ophthalmologica* 170:283, 1975.
130. Wilson ME, McClatchey SK: Dissociated horizontal deviation. *J Pediatr Ophthalmol Strabismus* 28:90, 1991.
131. Wilson ME, Hutchinson AK, Saunders R: Outcomes from surgical therapy for dissociated horizontal deviations. *J Am Assoc Pediatr Ophthalmol Strabismus* 4:94, 2000.
132. Wilson ME, Saunders RA, Berland JE: Dissociated horizontal deviation and accommodative esotropia: Treatment options when an eso- or exodeviation co-exists. *J Pediatr Ophthalmol Strabismus* 32:228, 1995.
133. Zubcov AA, Goldstein HP, Reinecke RD: Dissociated vertical deviation (DVD). The saccadic eye movements. *Strabismus* 2:1, 1994.
134. Zubcov A, Reinecke RD, Calhoun JH: Asymmetric horizontal tropias, DVD, and manifest latent nystagmus: An explanation of dissociated horizontal deviation. *J Pediatr Ophthalmol Strabismus* 27:59, 1990.
135. Zubcov AA, Fendick MG, Gottlob I, et al: Visual-evoked cortical potentials in dissociated vertical deviation. *Am J Ophthalmol* 112:714, 1991.

A and V Patterns

One of the most valuable contributions in the second part of the twentieth century to the field of strabismus was the emphasis on what has come to be known as the **A** and **V** patterns of strabismus. Recognition and proper evaluation of horizontal strabismus that becomes incomitant in vertical gaze are paramount in effectively managing the ocular deviation. How the existence of **A** or **V** patterns could have escaped the attention of ophthalmologists until so recently is almost inconceivable. In 1952 Scobee⁷⁴ wrote that “no information of value is gained from examining the eyes in supraversion and infraversion [sic].” We must assume that, in the past, countless surgical overcorrections and undercorrections in the physiologically important primary and downward positions of gaze must have occurred from failure to recognize **A** and **V** patterns. Astute observers in the past must have noted that a horizontal deviation may increase or decrease with the eyes in upward or downward gaze. Indeed, occasional reference to this phenomenon is found in the literature, usually in connection with paralysis of the cyclovertical muscles^{2, 3, 19, 50}; apparently, however, no further significance was attached to this finding.

It was not until 1948, when Urrets-Zavalía published the first of a series of papers,^{85, 86} that emphasis was placed on the importance of performing measurements of strabismic patients with the eyes in the straight upward and downward positions of gaze. He also called attention to the fact that oblique overactions and underactions are associated with increased or decreased conver-

gence or divergence in these positions. Urist⁸¹ introduced this concept to American literature in 1951, and Albert¹ suggested the excellent descriptive terms **A** and **V** patterns, which have now found worldwide acceptance.

Esotropia with a **V** pattern increases in downward gaze and decreases in upward gaze (Fig. 19–1). The deviation in **V** exotropia increases in upward gaze and decreases in downward gaze (Fig. 19–2). In **A** esotropia the deviation increases in upward gaze and decreases in downward gaze (Fig. 19–3), and in **A** exotropia the deviation increases in downward gaze and decreases in upward gaze (Fig. 19–4). This classification generally is sufficient for categorizing each patient with horizontal strabismus that becomes incomitant in vertical gaze. There are patients, however, who may have essentially no deviation or only a small one in primary position, although exotropia is present in upward or downward gaze (**X** pattern). Also, exotropia may occur only in upward gaze (**Y** pattern) or in downward gaze (inverted **Y** or λ pattern).^{37, p.232} These special forms of incomitance in vertical gaze consist of nothing more than modifications of the classic **A** or **V** patterns; therefore, they should not be regarded as separate entities. However, with these additions the terms **A** and **V** patterns no longer adequately describe the entire spectrum of horizontal strabismus with vertical incomitance. In the European literature it has become customary, therefore, to speak of strabismus with an *alphabetical pattern*.

With regard to binocular vision, patients with a **Y** pattern are especially privileged, for the devia-



FIGURE 19-1. V esotropia (ET). Upward gaze, orthotropia; primary position, 10^Δ intermittent ET; downward gaze, 35^Δ ET. Note bilateral elevation in adduction and slight limitation of depression of OD when looking down and to the left.

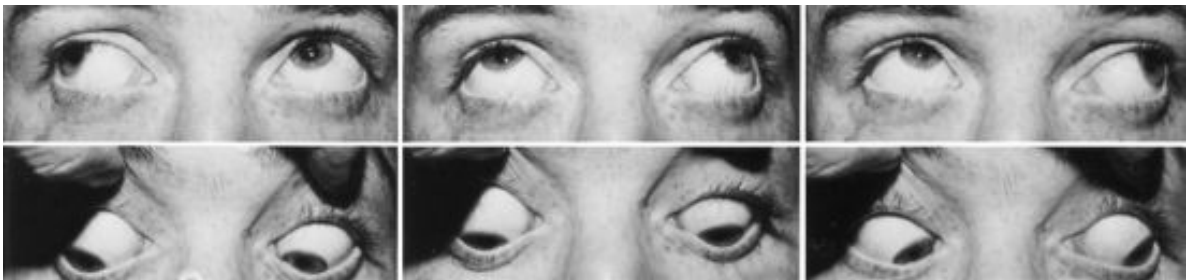

FIGURE 19-2. V exotropia (XT). Upward gaze, 45^Δ XT; downward gaze, 10^Δ XT. Note bilateral overelevation in adduction but no corresponding limitation of depression in adduction.

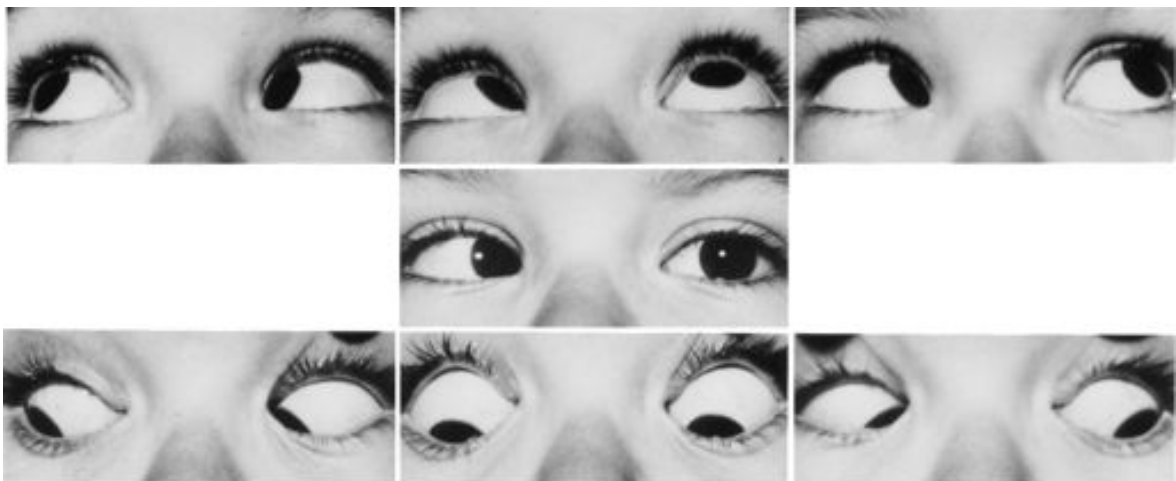

FIGURE 19-3. A esotropia (ET). Upward gaze, 50^Δ intermittent ET; primary position, 45^Δ ET; downward gaze, orthotropia. Note bilateral limitation of elevation in adduction.

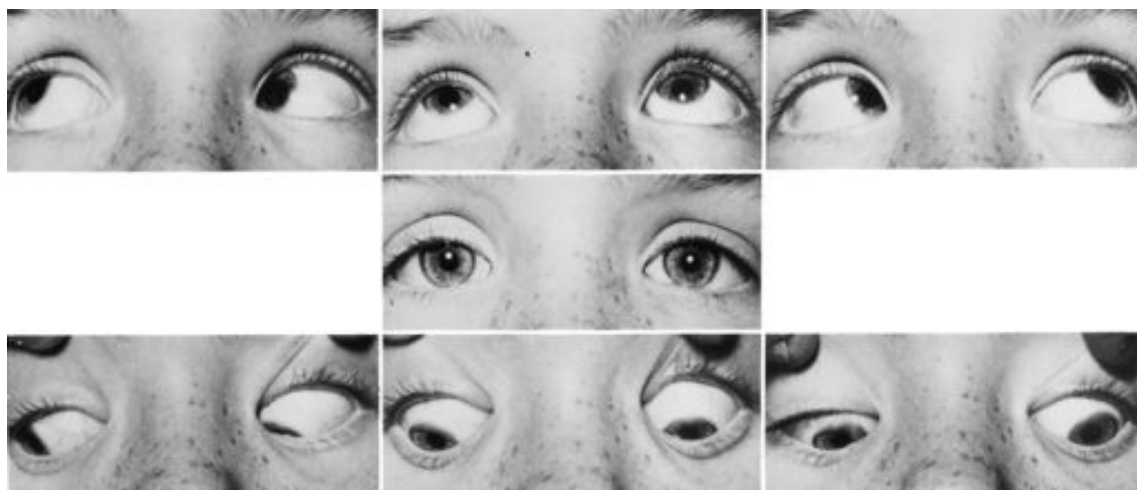


FIGURE 19-4. A exotropia (XT). Upward gaze, orthophoria; primary position, 10^Δ intermittent XT; downward gaze, 30^Δ XT. Note downshoot in adduction OS and slight limitation of elevation in adduction OS.

tion occurs only in upward gaze. The prognosis for restoration of binocular vision is better in such patients than in those in whom a manifest deviation is present in all positions of gaze.

Etiology

A great deal has been written about the role of horizontal, vertical, and oblique muscle dysfunctions, facial characteristics, and abnormal muscle insertions. At this time, however, there is no unanimity concerning the pathophysiology of A and V patterns. Several schools of thought have evolved. Some of these have become obsolete and are mentioned here for their historical interest only. The subject was reviewed by Folk.²⁸

Horizontal School

Urist,⁸⁰⁻⁸⁴ whose papers published between 1951 and 1968 marked the beginning in this country of concerted thinking about A and V patterns, was primarily concerned with elevation and depression in adduction in patients who manifested vertical incomitance of the horizontal deviation. His theory is currently mainly of historical interest. Urist believed that horizontal rectus muscles were responsible for this incomitance of horizontal deviation: in V esotropia overaction of the medial rectus muscles caused the increased convergence in downward gaze and overaction of the lateral rectus muscles was responsible for the increased divergence in upward gaze. Conversely, increased divergence in downward gaze in A exotropia was

thought to be caused by underacting medial rectus muscles and in A esotropia by underacting lateral rectus muscles. If this were true, one would invariably find an A-pattern esotropia in patients with bilateral abducens paresis. This is clearly not the case. Indeed, we have occasionally observed a V-pattern esotropia in this condition, which contradicts the mechanism championed by Urist.

Urist advocated horizontal surgery alone to alter A and V patterns. In one of his earlier papers,⁸⁰ he stated that elevation or depression of the adducted eye, a common feature in A and V patterns, is secondary to the horizontal deviation. On the other hand, in a later publication,⁸³ he conceded that anomalies of cyclovertical muscle action may be important factors in the production of A or V patterns, although he still emphasized the primary importance of horizontal muscle dysfunction.

This view was shared by Villaseca,⁸⁸ who argued against a primary vertical muscle defect on the basis that A and V patterns may occur without cyclovertical muscle dysfunction and that horizontal surgery can be successful in eliminating A and V patterns in spite of the presence of significant vertical elements. The observation that apparent overaction of the oblique muscles may occasionally disappear after horizontal surgery seems to support Urist's theory. However, a V pattern may be alleviated by horizontal surgery because the abductive action of the inferior obliques is decreased when horizontal alignment of the eyes is improved.^{7, 42} Breinin^{9, 10} concluded from his electromyographic data that the horizontal rectus muscles, although not solely causative, must play some part in the etiology of A and V patterns.

A.B. Scott⁷⁶ recorded co-contraction of both horizontal rectus muscles of the fixating eye and abnormal lateral rectus muscle activity of the deviating eye in a patient with V exotropia. In an earlier study,⁷⁵ he had reported the innervation of horizontal muscles to be normal in A and V exotropes.

In order for horizontal rectus muscles to cause an increase or decrease in the angle of horizontal strabismus in up- or downward gaze, a change of innervation flowing to these muscles or different actions of these muscles in different vertical gaze positions would have to be a prerequisite. No convincing evidence has been presented to explain A and V patterns exclusively as a dysfunction of the horizontal rectus muscles.

Vertical School

Brown¹² championed the opinion that A or V patterns may be caused by primary anomalies in the function of the vertical rectus muscles in which adduction is the tertiary action. For example, if the superior rectus muscles are primarily underacting, their adductive effect in upward gaze will diminish; in fact, the eyes will diverge in upward gaze because of secondary overaction of the inferior oblique muscles. In downward gaze, secondary underaction of the superior obliques will cause decreased abduction and secondary overaction of the inferior rectus muscles, resulting in increased adduction of the eyes, which, according to Brown, would produce a V pattern. Brown's view is supported by the observation that secondary horizontal deviations with A and V patterns may develop following acquired paresis of vertical rectus muscles. While there is no question that the vertical rectus muscles contribute to adduction in elevation and depression of the globe, their action is, as a rule, normal in patients with A- and V-pattern strabismus. Brown's concept has never gained a great deal of popularity.

Oblique School

Most current authors believe that dysfunction of the oblique muscles plays a major role in the etiology of A and V patterns since elevation in adduction is frequently associated with a V pattern and depression in adduction with an A pattern type of strabismus. This thinking is based on the fact that abduction is the tertiary action of the oblique muscles. If a superior oblique muscle is parietic, this tertiary action is weakened. The ab-

sence of the abducting factor will be most noticeable in depression—the direction of maximum action of the superior oblique muscle—along with a consequent increase in convergent position or a decrease in divergent position of the visual axis in downward gaze. A V pattern must result. Paresis of the superior oblique need not be pronounced. The vertical action of this muscle may be fully restored, but overaction of the inferior oblique may persist. The inferior oblique is an abductor also, and secondary or primary overaction of that muscle will result in a relatively less convergent or more divergent position in upward gaze, producing a V pattern (see Fig. 19–1). The opposite principle applies to weakness of inferior oblique muscles or overaction of superior oblique muscles. This combination would cause an A pattern to develop (see Fig. 19–4). The pronounced beneficial influence of surgery on oblique muscles for correction of A and V patterns lends much credence to this view.

Orbital Factors

Craniofacial Anomalies

An apparent dysfunction of the superior or inferior oblique muscles unrelated to paralysis or paresis of one of the cyclovertical muscles may occur on the basis of structural orbital anomalies. Urrets-Zavalía and coworkers,⁸⁷ in a study of Bolivian Indian children, called attention to the fact that anomalies in the action of cyclovertical muscles, which may cause variations of the horizontal deviation in upward and downward gaze, are manifested differently in patients with mongoloid and antimongoloid facies. They found that a *mongoloid* type of facial development was present, which consisted of hyperplasia of the malar bones, upward slanting of the palpebral fissures, and a straight lower lid margin. In this population, esotropia frequently was associated with underacting inferior oblique muscles (A esotropia) and exotropia with overacting inferior obliques (V exotropia). In white children with *antimongoloid* features (hypoplasia of the malar bones, downward slanting of the palpebral fissures, and S-shaped contour of the lower lid margin) the opposite was found. Esotropia often was associated with overacting inferior oblique muscles (V esotropia) and exotropia with underacting inferior oblique muscles (A exotropia).

This association of certain facial characteristics

with vertical incomitance and overactions and underactions of the oblique muscles needs to be further clarified. The observant clinician will be surprised how frequently *mongoloid* and *antimongoloid lid fissures* are present in patients with A and V patterns, although the lid fissures may also appear essentially normal in such patients or may be “abnormal” in patients with normal ocular motility. Moreover, we have observed “against-the-rule” cases in approximately 20% of our patients with A and V patterns; that is, antimongoloid fissures were present in association with A esotropia and V exotropia, and mongoloid fissures with V esotropia and A exotropia.⁵⁹ In a later study with Ruttam we performed orbital and facial anthropometry in a largely white population with A and V patterns.⁷¹ Although there was a small but significant difference between palpebral fissure obliquity in A and V esotropia, no such relation existed in patients with exotropia. We also were unable to establish a linear correlation between palpebral fissure obliquity and amount of vertical incomitance or a consistent relationship between these parameters and oblique muscle dysfunction. Finally, we were unable to find anthropometric differences related to external orbital and facial development between groups.⁷¹

These negative findings should not distract from the fact that orbital factors do produce oblique muscle dysfunction and, under certain circumstances, A and V patterns. Fink²⁶ has drawn attention to anomalies in the muscle planes of the superior oblique tendon and the inferior oblique muscle that were observed by him during anatomical dissection of orbits. Under normal circumstances the planes of these muscles are identical and form an angle of about 51° with the optical axis of the globe. However, pronounced variations from this pattern were observed in specimens from an apparently normal population. Fink pointed out that the resulting imbalance between the oblique muscles may produce an apparent overaction of the inferior oblique muscle with upshoot in adduction. Gobin³⁰ introduced the term *desagittalization* to describe this dysfunction of the oblique muscles caused by differences between the planes of the superior and inferior oblique muscles.

The desagittalization of the oblique muscles from posterior displacement of the trochlea in *plagiocephaly* can be the cause of pseudoparalysis of the superior oblique muscle and is discussed in Chapter 20. The reverse may occur in children with *hydrocephalus*. The enlargement of the head

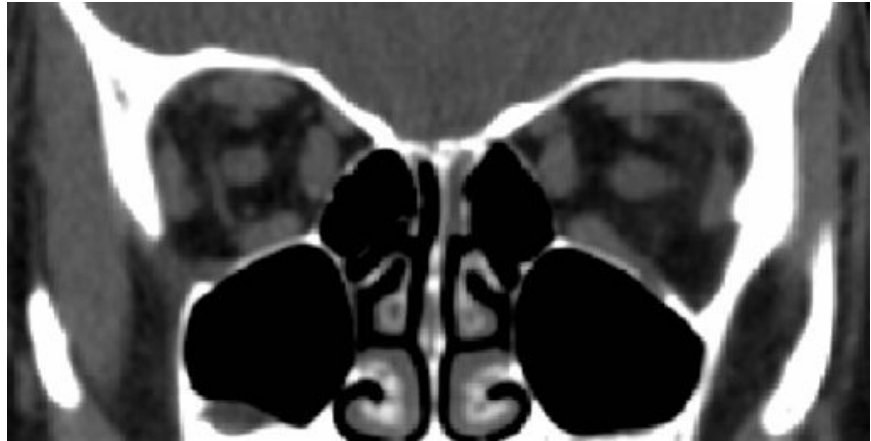
with frontal bossing could cause anterior displacement of the trochlea and thus a reverse relationship as described for *plagiocephaly* between the planes of the superior oblique tendon, the inferior oblique muscles, and the optic axis: the superior oblique muscles become more effective as depressors and increased abduction in downward gaze causes the A pattern exotropia seen so frequently in patients with *hydrocephalus*.^{22, 29} Systematic radiological studies in hydrocephalic patients with and without an A pattern must be performed to confirm the validity of this theory. An observation reported by Biglan^{5a} is of interest in this connection: The angle of the reflected superior oblique tendon measured on CT scans in a patient with *hydrocephalus* and A pattern exotropia was more acute (63°) than in a hydrocephalic patient who did not have strabismus (68°).

Heterotopia of Muscle Pulleys

In previous editions of this book we have stated that the role of orbital factors in producing A and V patterns should provide a fertile field for future investigation with advanced imaging techniques. We speculated in the past that a more rational explanation for apparently primary overaction or underaction of the oblique muscles could perhaps be found on the basis of orbital anomalies. This prediction has come true with the discovery of heterotopia of extraocular muscle pulleys by Demer and his group^{17, 21} as a cause of elevation and depression in adduction and of A and V patterns. A comparison of high-resolution magnetic resonance images scanning the orbits in normals and patients with apparently overacting inferior (or superior oblique) muscles revealed significant differences in the position of the lateral rectus muscle pulleys (see Chapter 3) in the latter group. This heterotopia alters the vertical positions of the pulley, thus changing the course and the action of the lateral rectus muscle, which in turn produces elevation or depression in adduction of the fellow eye, depending on whether the pulley is displaced inferiorly or superiorly.

For instance, in the case of inferior displacement of the lateral rectus pulley a V-pattern strabismus was observed with upshoot and underdepression of the adducting eye. The coronal computed tomography (CT) sections of the rectus muscles show inferior displacement of both lateral rectus muscles (Fig. 19-5). The mechanism suggested by Clark and coworkers¹⁷ for the upshoot

FIGURE 19-5. Coronal CT scan of the orbits in a patient with V esotropia shows inferior displacement of both lateral rectus muscles. (From Demer JL, Clark RA, Miller JM: Heterotopy of extraocular muscle pulleys causes incomitant strabismus. In Lennerstrand G, ed: *Advances in Strabismology*. Proceedings of the Eighth Meeting of the International Strabismological Association, Maastricht, Sept 10-12, 1998. Buren, The Netherlands, Aeolus Press, 1999.)



is as follows: a lateral rectus muscle inferiorly displaced will depress the globe when abducting it. To maintain fixation, the ipsilateral elevators will need to contract to maintain constant vertical eye position. According to Hering's law the contralateral elevators will receive equal innervation, elevating the contralateral eye as it is adducting. Thus, the upshoot in adduction of the nonfixating eye is caused by *secondary overaction* of both the inferior oblique and the superior rectus muscles of that eye. A similar situation exists with superior displacement of the pulley and thus of the lateral rectus muscle (Fig. 19-6). Abducting the involved eye causes elevation, counteracted by ipsilateral contraction of the depressors of the fixating eye, contralateral downshoot in adduction, and an A pattern.

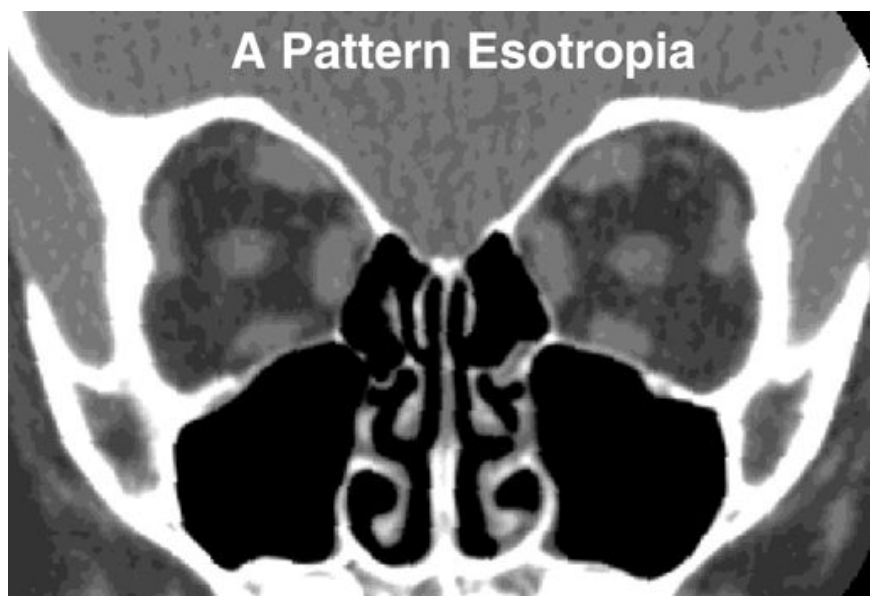
One may argue that this change in pulley position could be caused by primary ocular torsion (see below). However, in that case *all* extraocular

muscle pulleys should be displaced by equal amounts, which was not the case in the patients under study, who had displacement of isolated pulleys while the others were found in their normal position (see Figs. 19-5 and 19-6).

Anomalies of Muscle Insertions and Cyclotorsion

In 1922 Cords¹⁸ reported an elevated insertion of the medial rectus muscle at the time of surgery in patients with elevation in adduction. He concluded that the muscle thus displaced is no longer a pure adductor but gains an elevating action. When the medial rectus muscle was recessed, the elevation in adduction disappeared. This finding was later confirmed by Bielschowsky,^{3, p.169} who reported normalization of unilateral upshoot in adduction after infraplacement and advancement of the medial rectus muscle in an exotropic patient. Postic⁶⁶

FIGURE 19-6. Coronal CT scan of a 6-year-old with an A-pattern esotropia that increased by 60^Δ from depression to elevation. Note bilateral superior displacement of the lateral rectus muscles and nasal displacement of the superior rectus muscles. (From Demer JL, Clark RA, Miller JM: Heterotopy of extraocular muscle pulleys causes incomitant strabismus. In Lennerstrand G, ed: *Advances in Strabismology*. Proceedings of the Eighth Meeting of the International Strabismological Association, Maastricht, Sept 10-12, 1998. Buren, The Netherlands, Aeolus Press, 1999.)



reported anomalies of the rectus muscle insertions in patients with **A** and **V** patterns, especially in those with anomalies of the lid fissures as described by Urrets-Zavalía and coworkers.⁸⁷ In patients with **V** patterns the insertions of the medial rectus muscles were higher than normal and insertions of the lateral rectus muscles were lower than normal, resulting in increased abduction of the lateral rectus muscles on elevation and increased adduction of the medial rectus muscles on depression. In patients with **A** patterns the opposite displacements were found (see also Nakamura and coworkers⁵⁵).

The cardinal question that must be asked here is whether the insertions were truly displaced or whether this displacement was only an apparent one, because of cyclotorsion of the globes. Piper^{64, 65} reported the association of exocyclotropia with **V** patterns and incyclotropia with **A** patterns and reported vertical displacement of the macula consistent with the direction of the cyclotropia. Similar findings were published by Weiss,⁸⁹ who used campimetric measurements of the positions of the blind spots to confirm these findings by fundus photography. Weiss considered cyclotorsion of the globe to be the basic etiologic factor of the **A** and **V** patterns and attributed to it the apparent displacement of the insertions of all four rectus muscles. For instance, exocyclotorsion of the globe would increase the abducting effect of the superior rectus in upward gaze and decrease the abducting effect of the inferior rectus muscle and thus cause a **V** pattern. Guyton and coworkers^{33, 34, 53} championed the view that *loss of fusion* predisposes the oculomotor system to cyclodeviations of the eyes which, in turn, cause **A** and **V** patterns according to the mechanism proposed by Weiss. Guyton and Weingarten³⁴ showed that formerly fusing patients with intermittent exotropia who lost fusion after surgical overcorrection may develop **A** or **V** patterns.

Limón de Brown and coworkers^{45, 46} have shown that in some patients with craniosynostoses and other craniofacial dysostoses *the entire orbit with its contents is rotated outward or inward*. These bony anomalies can be expected to change the action of the rectus muscles in the manner suggested above and cause **A**- and **V**-pattern types of strabismus (see also Cheng and coworkers¹⁵).

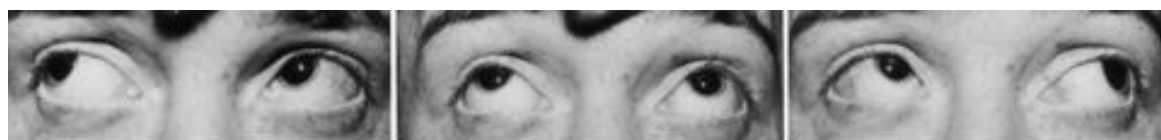The view that cyclotorsion of the globes may cause **A** and **V** patterns is not shared by all authors. Locke⁴⁷ undertook campimetric studies of the heterotopia of the blind spot in patients with

A and **V** patterns and obtained findings identical to those of Weiss. However, he did not agree with Weiss's interpretation. Locke's experience tended to support the conventional interpretation of the pathogenesis of these patterns—that they are caused principally by underactions and overactions of the vertically acting muscles, the torsion being a secondary and incidental finding (see also Arruga in discussion of Postic's paper⁶⁶). Saunders and Holgate⁷² concluded from CT scans in children with a **V** pattern that malpositioning of the rectus muscles, if present at all, is a function of age and cannot be implicated as a cause of the **V** pattern.

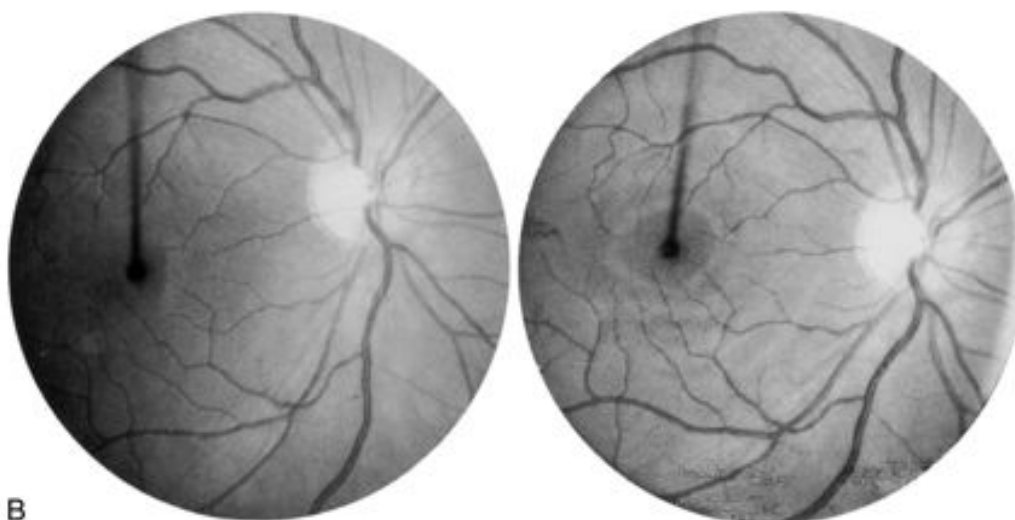
We believe that the evidence presented thus far supports either view. We find objective cyclotorsion, as demonstrated by indirect ophthalmoscopy or fundus photography, invariably associated with apparent oblique muscle overaction in patients with **A** and **V** patterns. This cyclotropia disappears, and the vertical topographic relationship between fovea and optic nerve head becomes normal once the elevation or depression in adduction has been eliminated by the appropriate surgical procedure on the oblique muscles (Fig. 19–7). On the other hand, up- or downshoot in adduction in patients with **A** and **V** patterns may have causes other than oblique muscle overaction (see p. 386). Primary cyclotorsion because of orbital anomalies, for instance heterotopia of muscle pulleys,¹⁷ abnormal insertions of the rectus muscles, or secondary cyclotorsion from cyclovertical muscle imbalances will change the action of the rectus muscles and thus favor the development of **A** or **V** patterns by enhancing adduction or abduction of the eyes in vertical gaze positions.

Conclusions

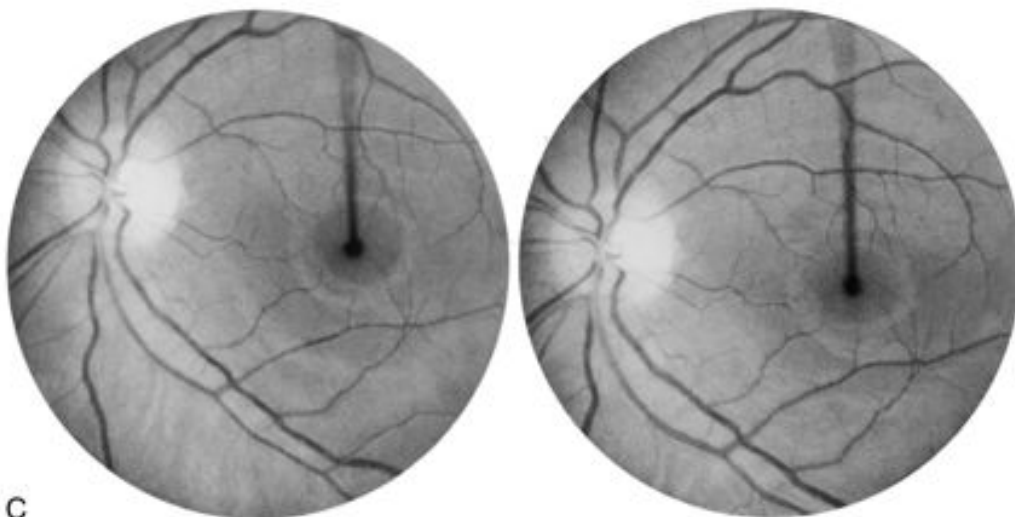
From the foregoing remarks, it seems reasonable to state that no single etiologic factor can explain all **A** and **V** patterns. An apparent overaction or underaction of oblique muscles is the most common clinical finding and surgery on these muscles has been eminently successful in the elimination of these patterns. Whether this dysfunction is innervational and due to primary or secondary overaction, or anatomical as in the case of desagittalization of the muscle planes, or only apparent as in the case of ocular or orbital torsion, seems to be of secondary importance with regard to the management of these conditions. The best way to reach a therapeutic decision is to carefully mea-



A



B



C

FIGURE 19-7. Normalization of foveal position following myectomy of both inferior oblique muscles of the patient shown in Figure 19-2. *A*, Postoperative versions show a marked decrease of overelevation in adduction compared with Figure 19-2. *B*, Preoperative infraplacement and postoperative normalization of foveal position in the right (*B*) and left (*C*) eyes.

sure the deviation and to search for apparently overacting or underacting oblique muscles. In the absence of such anomalies surgical alternatives are available and are discussed later in this chapter.

Prevalence

The prevalence of A and V patterns in the strabismic population has been variously assessed. The estimates range from 12.5%⁴¹ to 50% (Urist⁸³). Costenbader¹⁹ reported prevalence of 15% to 20%; Breinin,¹¹ 15%; Magee,⁴⁸ 35%; Holland,³⁶ 58.4%; and Maggi,⁴⁹ 87.7%. Our experience equals that of Costenbader: approximately one in five patients with strabismus may be expected to have an A or V pattern.

The relative frequency of the various types of patterns is not clearly established. According to the 1964 American Academy of Ophthalmology and Otolaryngology panel, during which A and V pattern strabismus was discussed for the first time comprehensively, V esotropia is by far the most common anomaly, followed in order of frequency by A esotropia, V exotropia, and A exotropia¹¹ (Table 19–1). Holland³⁶ reported a similar distribution of these patterns from Germany. A somewhat different distribution was reported by von Noorden and Olson,⁶⁰ who found in a predominantly African-American patient population, in order of frequency, V exotropia, A exotropia, V esotropia, and A esotropia. Ethnic differences in patients from various localities may account for these differences.

A and V patterns commonly occur in patients with infantile strabismus, but they also may develop secondary to bilateral lateral rectus and to cyclovertical muscle paralyses. In fact, the first description of what we now call V esotropia stems from Duane,²⁵ who reported orthophoria in upward gaze and esotropia in downward gaze in a patient with bilateral paresis of the superior oblique mus-

cles. With paresis of the superior rectus muscle, he noted exotropia in elevation (V exotropia), and with paresis of the inferior rectus muscle, exotropia in depression (A exotropia). Similar observations were made by Berke,² Bielschowsky,³ and McLean.⁵⁰ Thus, one would expect a V pattern to develop following paresis of one or both superior rectus or oblique muscles and an A pattern to develop following paresis of the inferior rectus or oblique muscles (see Chapter 20).

The following are some characteristics noted by Costenbader in 421 patients with A and V patterns¹⁹:

- Age at onset 12 months or less: 246 (58%)
- Abnormal head position: 46 (11%)
- Refractive error +2.0D or less: 275 (65%)
- Visual acuity 6/60 or less in one eye: 109 (26%)

Clinical Findings and Diagnosis

Asthenopia and diplopia are common complaints in patients with A and V patterns, since fusion may have to be maintained for a long time in certain positions of gaze. For instance, the increase in a deviation in downward gaze (with A exotropia or V esotropia) may cause acute visual discomfort during reading or other types of near work (see also Kushner⁴³). On the other hand, an increase in the deviation in upward gaze (with V exotropia) is best tolerated by most patients since little or no interference with binocular vision may occur in the functionally more important primary or downward positions of gaze. Measurements should be performed in the nine diagnostic positions of gaze using the technique routinely used in evaluating all types of strabismus of the eyes (see Chapter 12). It is important that the full refractive correction be worn and accommodation controlled with appropriate targets during the measurements of the deviation. Knapp⁴⁰ and von Noorden and Olson⁶⁰ demonstrated that, if required, high plus corrections are not worn during the measurements, or if a fixation light rather than an accommodative target is used, *pseudo A or V patterns* may appear or true patterns may be concealed (see also von Noorden and Avilla⁵⁸).

From these observations the question arose whether the accommodative convergence/accommodation (AC/A) ratio varied in upward or downward gaze in patients with A and V patterns, and if so, whether the change could be considered of

TABLE 19–1. Relative Frequency of A and V Patterns Among 421 Patients

	V	A	Total
Esotropia	171 (41%)	105 (25%)	276 (65.5%)
Exotropia	97 (23%)	48 (11%)	145 (34.5%)
Total	268 (64%)	153 (36%)	421 (100%)

From Costenbader FD: Introduction. In Symposium: The A and V patterns in strabismus. Trans Am Acad Ophthalmol Otolaryngol 68:354, 1964.

etiologic significance. Payne and von Noorden⁶² tested the AC/A ratio in upward and downward gaze in persons with normal vision and in patients with A and V patterns and could not demonstrate gaze-dependent differences.

Knapp⁴⁰ stressed the point that false measurements can be best avoided by measuring the deviation in different gaze positions at distance fixation and that it is mandatory to do so. The question also arose whether errors could be incurred by measuring the deviation with the head tilted backward and forward to obtain depression and elevation of the eyes or with the head fixed while the patient fixates above and below the horizontal plane. Magee⁴⁸ found no differences in half his patients tested with the head fixed or moved and in the other half the difference was 5^Δ or less. A.B. Scott and Stella⁷⁷ reported that the differences in measurement under both conditions are insignificant. The members of the 1964 American Academy of Ophthalmology and Otolaryngology roundtable concluded that the method of testing (whether at distance or at near fixation or with the patient's head steady or moved) appeared to be of little practical significance.¹¹ Members of the panel also supported the view held by Breinin that the eyes should not be rotated in extreme positions, since mechanical effects of the check ligaments and musculofascial system may alter the devia-

tion. The panel suggested therefore that measurements be made in the relatively physiologic position of 25° of upward gaze and 25° of downward gaze. Magee⁴⁸ reached similar conclusions.

Von Noorden and Olson⁶⁰ tested 60 patients with A and V patterns (15 each in the four groups) at varying angles of elevation and depression from 45° above the horizontal position to 55° below the horizontal position of gaze. They observed no significant increase in deviation beyond 25° of elevation, but average increases of 7^Δ to 12^Δ occurred in the range of 30° to 45° of downward gaze in all patients but those with V exotropia. They believed that the 25° limit in downward gaze was too restrictive.

On the basis of these findings, we recommend measurement of the deviation at 33-cm fixation distance, with the refractive error fully corrected and with the eyes in positions of 25° elevation and 35° depression while fixating on an accommodative target (Fig. 19-8).

The measurements are made in upward and downward gaze to establish whether an A or V pattern of fixation is present and if so whether it is clinically significant. Stuart and Burian⁷⁹ established that divergence of the visual lines in upward gaze and convergence in downward gaze are physiologic variants. Thus, only a V pattern in which the difference in deviation between upward and

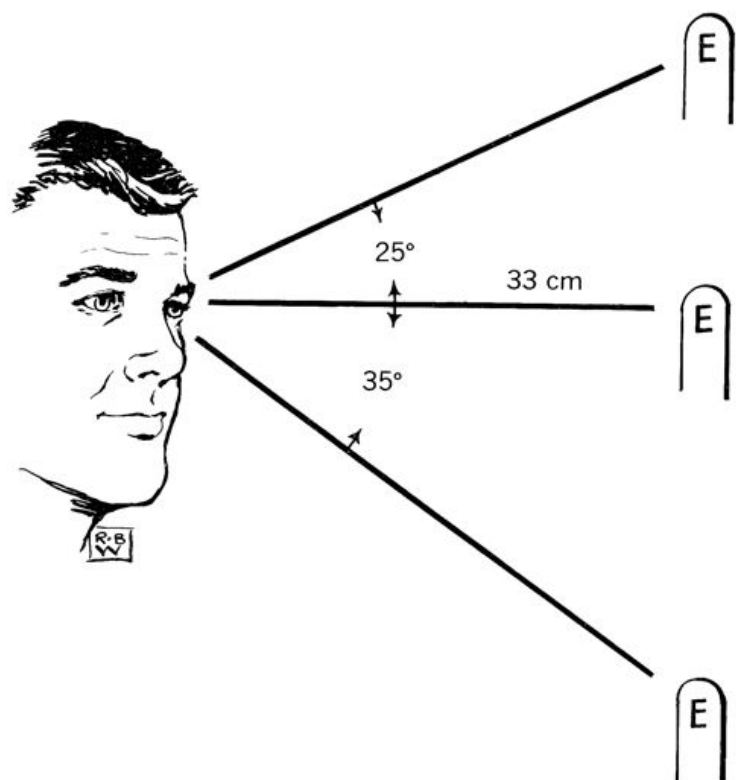


FIGURE 19-8. For explanation, see text. (From Noorden GK von: *Atlas of Strabismus*, ed 4. St Louis, Mosby-Year Book, 1983.)

downward gaze is 15^{Δ} or more should be considered a significant vertical incomitance. Since an A pattern is never found as a normal variant, a limit of 10^{Δ} has been set beyond which an A pattern is thought to be significant.

Here, significance applies only to the *diagnosis* of vertical incomitance. Whether the A or V pattern is also *functionally* significant depends on other factors that must be taken into account before therapeutic decisions can be made. Obviously, an asymptomatic patient with V exotropia of 15^{Δ} in upward gaze and orthotropia and normal binocular vision in downward gaze has a clinically insignificant V pattern. On the other hand, an A exotropia with only 15^{Δ} deviation in downward gaze and 5^{Δ} in primary position may interfere with normal binocular vision and require therapy. Thus, the clinical significance of vertical incomitance depends on the degree with which it interferes with normal binocular function in the physiologically important positions of gaze, that is, in the primary and downward (reading) positions.

It may be difficult to establish the presence of an A or V pattern in very young patients in whom a reliable prism cover test in various positions of gaze cannot be obtained. In this case we find it useful to move the head of the patient passively up and down, while keeping his or her attention directed at a distant fixation target. This makes it possible to dynamically evaluate differences in the horizontal deviation between upward and downward gaze and to establish with reasonable certainty that an A or V pattern is present.

Anomalous head posture is common in patients with A and V patterns. Chin elevation or depression with a horizontal deviation should immediately alert the physician to search for vertical incomitance. The patient with A esotropia and V exotropia and fusion in downward gaze may hold his or her chin in an elevated position. Conversely, V esotropia and A exotropia may cause chin depression (Fig. 19-9).

The prevalence of amblyopia and other forms of sensorial adaptation with A and V patterns was reported not to differ from that with other forms of strabismus.^{37, p. 233} Although this statement may hold true in general, it cannot be applied to patients with a Y- or λ -pattern exotropia who, as a rule, enjoy excellent binocularity except for one position of gaze. Sensorial adaptations are rare in such cases, and diplopia is a common complaint. Ciancia¹⁶ found an 89% prevalence of anomalous retinal correspondence in a group of 137 patients

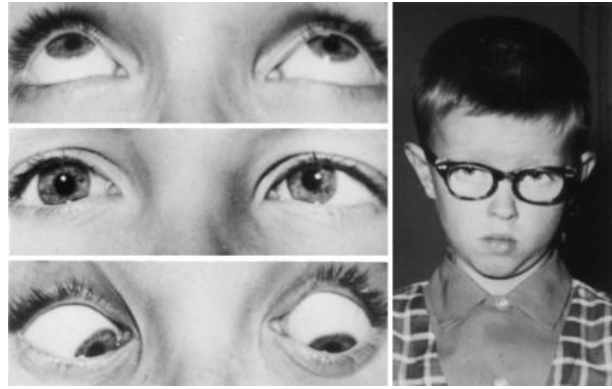


FIGURE 19-9. V esotropia with chin depression. Upward gaze, 8^{Δ} intermittent exotropia; primary position, 30^{Δ} esotropia (ET); downward gaze, 45^{Δ} ET.

with A and V patterns. He also pointed out that the angle of anomaly changed with the angle of deviation, so that correspondence was harmonious with the eyes in upward and downward gaze in spite of significant changes in the objective angle in these positions. This observation was confirmed by Helveston and coworkers,³⁵ who interpreted it as evidence that the fovea of the fixating eye may have a common visual direction with an infinite number of retinal points in the deviated eye. Obviously, this adaptation of retinal correspondence to vertical incomitant horizontal strabismus serves a useful purpose in creating a rudimentary form of binocular vision in spite of a constantly changing ocular deviation. In some cases, anomalous retinal correspondence is present only in those positions of gaze in which the horizontal deviation is minimal and suppression is found in the other positions. An abnormal head posture may be present in such patients to favor a gaze position in which anomalous binocular vision is present (see Chapter 13).

Treatment

Indications for Surgery

The surgical goals in patients with A and V patterns are not basically different from those for other forms of strabismus: to eliminate motor obstacles to maintaining, improving, or regaining comfortable single binocular vision and, when this is not possible, to restore the patient's normal facial configuration. Surgery may be necessary also to eliminate chin elevation or chin depression.

The clinical importance of A and V patterns notwithstanding, a surgeon should not be carried

away in attempting to create vertical comitance in all positions of gaze while disregarding the fact that the primary and downward positions are the most important functional levels of the eyes. As a matter of fact, we do not advocate surgery for the single purpose of decreasing an inconspicuous deviation in upward gaze in a patient who is asymptomatic with his or her eyes in primary position and downward gaze. Occasionally, an extreme upshoot of each eye in adduction may be associated with overaction of both inferior oblique muscles (strabismus sursoadductorius; see Chapter 18) and a large exodeviation in upward gaze. Such patients may have stable fusion in primary position and downward gaze, but a weakening procedure of both inferior oblique muscles may be indicated to improve their appearance.

If, for some reason, a symptomatic patient refuses surgery or if there are medical reasons for not doing surgery, a trial with oblique prisms has been advocated. Diamond^{23, 24} reported good results with this method in patients with a V esodeviation. Pigassou and Garipuy⁶³ used prisms in combination with partial occlusion in patients with A and V patterns and normal sensorial relationships between the two eyes. Prismatic treatment of A and V patterns has gained little popularity, and we do not advocate it.

Surgical Methods

Conventional unilateral or bilateral surgical procedures for horizontal strabismus combined, when indicated, with weakening or strengthening procedures on the oblique muscles have proved effective in most patients with A and V patterns. Other surgical procedures are used specifically to eliminate vertical incomitance in horizontal strabismus. Some of these techniques, such as vertical transposition of horizontal muscles and horizontal transposition of vertical muscles, have proved extremely useful and have been generally accepted. Certain other surgical procedures need to be evaluated further before their usefulness can be assessed. Before making recommendations about planning for surgery in a patient with an A or V pattern, we shall review briefly some procedures currently in use.

Surgery on the Horizontal Rectus Muscles

Surgery on the horizontal rectus muscles alone may effectively reduce vertical incomitance. Thus,

when dysfunction of the oblique muscles is not evident, a cosmetic result only is the aim; or if the vertical incomitance is minor and present only when the eyes are in extreme positions of elevation or depression, surgery may be restricted to the horizontal rectus muscles. In most patients, however, abnormal oblique muscle function is apparent and horizontal surgery should be combined with procedures on the oblique muscles.

Limón de Brown⁴⁴ reported good results with horizontal surgery only in patients with an X pattern in whom overaction of both superior and inferior oblique muscles was present. When horizontal strabismus was corrected, dysfunction of the oblique muscles disappeared. We have made similar observations after horizontal surgery and believe that in certain instances an oblique dysfunction may be secondary to horizontal strabismus. Jampolsky³⁸ agreed with this view.

Recession of the superior rectus muscles has been proposed to reduce an A pattern.⁵¹ During study of a possible horizontal effect of large superior rectus muscle recessions for DVD it became apparent that this procedure increased a V pattern and improved an A pattern. While it remains to be seen how this procedure compares with a more conventional approach it is useful to remember that large recessions of the superior rectus muscle for dissociated vertical deviation (DVD) may change a coexisting A or V pattern.

Surgery on the Oblique Muscles

Surgery on the oblique muscles is greatly effective in reducing or eliminating vertical incomitance. In view of the relatively high incidence of V esotropia, a weakening procedure on the inferior oblique muscles is performed most frequently. One of us (G.K.v.N.) prefers to perform a myectomy of the muscle close to the insertion (see Chapter 26) rather than a recession as recommended by Parks.⁶¹ A myectomy of both inferior obliques can be expected to improve vertical comitance by increasing the deviation in upward gaze in patients with V esotropia and by reducing it in those with V exotropia. Obviously, this procedure is of little value in treating V esotropia unless combined with horizontal surgery, since an isolated weakening procedure on the inferior oblique muscles will have no significant effect on the esotropia in primary position. The junior author of this book (E.C.C.) uses myectomy of the inferior oblique muscles in the absence of normal binocular vision

and performs a recession when normal binocularity is present. Others use routinely a recession of the inferior oblique muscles.²⁰

Unlike the effect that weakening procedures on the superior oblique tendons have on the position of the eyes in downward gaze, the results of weakening the inferior obliques in upward gaze are less predictable. In our experience, this operation increases esotropia and decreases exotropia from 15^Δ to 25^Δ in upward gaze (see also Knapp⁴¹). The return of apparently underacting superior oblique muscles to normal function is frequently observed after inferior oblique myectomy. There may be a slight and usually insignificant increase of the deviation in primary position in esotropia and a decrease in exotropia. To avoid postoperative hypertropia in the eye not operated on, one should perform unilateral inferior oblique weakening procedures only when it has been clearly established that this muscle in the fellow eye is not overacting. This well-known clinical observation was documented convincingly by Raab and Costenbader.⁶⁸

We are opposed to performing any weakening procedure on the inferior oblique muscle unless overaction of this muscle can be demonstrated, even though Billet and Freedman⁶ advocated this treatment. Finally, inferior oblique myectomies performed in the absence of superior oblique muscle underaction may convert a V into an A pattern.³⁹

Surgery on the superior oblique muscles in patients with the A pattern usually is highly effective and in A exotropia may be the only procedure required. When A esotropia is present, this operation usually is combined with horizontal surgery. The effect of removing a segment containing both tendon and sheath from both oblique muscles reduces the horizontal deviation from 25^Δ to 35^Δ in downward gaze. Similar results can be obtained by recessing the superior oblique tendons.¹⁴ To reduce an A pattern, it has recently been suggested to weaken the superior oblique muscles by means of a tenectomy involving only the posterior fibers of the tendon at its scleral insertion, with the idea of reducing the risk of a superior oblique palsy and unwanted cyclotorsion.⁷³ It would be interesting to compare data obtained with this procedure with those after a classic total tenectomy performed in the superior nasal quadrant.

It has been mentioned that *tenectomy of the superior oblique muscle* is potentially dangerous as it may result in torsional diplopia in downward gaze. This has not been our experience but then

we restrict this operation to patients with marked downshoot in adduction. Normally acting superior obliques should *never* be weakened. If this operation is performed when not indicated, excycloptropia may indeed develop in downward gaze and cause serious visual discomfort.

Unilateral tenectomy of the superior oblique is indicated only when the contralateral muscle does not overact. With only a slight overaction on one side and more overaction on the other, both superior oblique muscles should be weakened, since hypotropia almost invariably develops in the eye not operated on. Tenectomies of the superior oblique muscles performed in the absence of inferior oblique muscle underaction may convert an A into a V pattern.³⁹

Von Noorden and Olson,⁶⁰ in 1965, advocated horizontal and oblique surgery as separate procedures in patients with A or V patterns, rather than combining procedures, to learn more about the effect of each of these operations on vertical incomitance. This advice was given at a time when little was known about the effect of surgery on these patterns. As more knowledge became available and the effect of combined procedures could be better predicted, this "fractionated" approach was no longer recommended.

Another surgical method, which is used less commonly in the United States than in Europe, consists of advancing both underacting superior obliques in patients with the V pattern. This procedure tends to "open" the V pattern in downward gaze, thus eliminating the need for horizontal surgery when the deviation in primary position is insignificant or none exists. However, this procedure has not become popular in this country, since in the hands of the less experienced surgeon complications may occur, and its influence in changing the horizontal deviation in downward position of gaze is not sufficiently predictable.

Gobin³¹ recommended "desagittalization" of the superior oblique in A-pattern esotropia to enlarge the angle between its tendon and the visual axis. A tenotomy of the posterior insertion is combined with anteropositioning and suspension on a suture loop of the anterior insertion. This procedure is said to reduce the torsional effect of that muscle while at the same time enhancing its vertical effect. A tenotomy of the posterior insertion is also advocated by Prieto-Diaz⁶⁷ for treatment of A patterns of moderate severity. No studies are available that compare the effectiveness of these

procedures with a tenotomy, tenectomy, or recession of the entire insertion of the superior oblique.

Transposition of Horizontal or Vertical Rectus Muscles

The effect of horizontal surgery can be enhanced or decreased in upward or downward gaze by vertical transposition of the insertions of the horizontal rectus muscles, a technique that was described by Knapp⁴⁰ and later elaborated on by others.^{66, 78} The technique is based on the principle that with the eyes in elevation or depression, the muscle plane of the horizontal rectus muscle, determined by the center of rotation of the globe and the centers of origin and insertion, changes. Thus, a horizontal rectus muscle aids elevation in upward gaze and depression in downward gaze, and the horizontal action of the muscle decreases in these positions. This physiologic action can be enhanced by raising or lowering the muscle insertions. For instance, when the insertion of the medial rectus is lowered, its horizontal action further decreases in downward gaze in favor of its action as a depressor. On the other hand, when the insertion of the lateral rectus is raised, its horizontal action will be decreased in elevation in favor of its action as an elevator. It follows that the insertion of a muscle should be moved in the direction in which it is desirable to most decrease its horizontal action and in the direction opposite that in which one wishes its horizontal action to be more effective.

In a patient with a V pattern, recession (in esotropia) or resection (in exotropia) of the medial rectus muscle may be combined with lowering

of the insertion, and resection (in esotropia) or recession (in exotropia) of the lateral rectus may be combined with raising the insertion. When the A pattern is present, the opposite is carried out: the insertion of the medial rectus muscle is raised and that of the lateral rectus is lowered (Fig. 19–10). This procedure has been found to be effective not only in conjunction with symmetrical horizontal surgery but also with recession-resection operations on one eye.^{32, 54} A 5- to 8-mm displacement of the muscle usually is sufficient; lesser amounts are rarely effective. The torsional effect of lowering or raising the insertions of the horizontal rectus muscle in treating A and V patterns is well tolerated by the patient and probably compensated for by suppression or by cyclofusion (see p. 389).

Horizontal transposition of the vertical rectus muscles has been suggested as an alternative surgical approach and has proved effective for all forms of vertical incomitant horizontal strabismus except A exotropia.^{27, 52, 56} This procedure is based on the same principles as vertical transposition of the horizontal rectus muscles.

In surgery for A esotropia, the superior rectus muscle is transposed 7 mm temporally, thereby increasing the abductive action and decreasing the elevating action in upward gaze. When V esotropia is present, the inferior rectus muscles are transposed temporally to augment abduction in downward gaze. For V exotropia, the superior rectus muscles are shifted nasally. We usually transpose the insertion one full tendon width, taking care to maintain the distance from the medial and lateral aspects of the tendon to the limbus. However, since most patients with the A and V patterns also

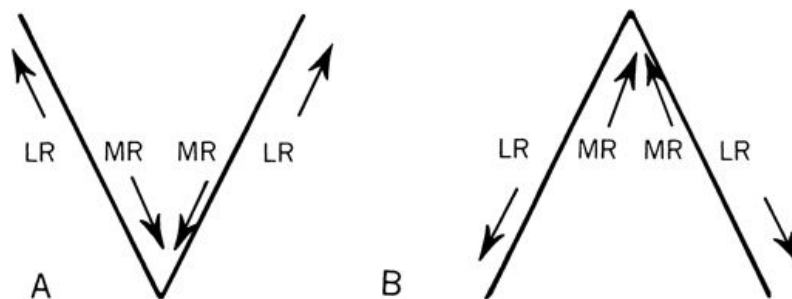


FIGURE 19–10. A, V pattern. It is easy to remember that the medial rectus (MR) should be transposed “toward the apex of the pattern.” It follows that the lateral rectus (LR) should be moved “away from the apex of the pattern.” In V esotropia (ET) the medial rectus is infraplaced (and recessed); the lateral rectus is supraplaced (and resected). In V exotropia (XT), lateral rectus recession is made more effective by moving the insertion upward; a medial rectus resection is made more effective by moving the insertion downward. B, A pattern. In A esotropia, perform upward displacement of the medial rectus muscle(s) toward the apex of the pattern with recession. With A exotropia, use downward displacement of the lateral rectus muscle or muscles with recession. (From Noorden GK von: *Atlas of Strabismus*, ed 4. St Louis, Mosby-Year Book, 1983.)

require horizontal surgery for correction of the deviation in primary position, most surgeons prefer to transpose the horizontal rectus muscles rather than risk anterior segment ischemia by operating on all four rectus muscles at the same session.

Slanting of the Horizontal Muscle Insertions

Bietti⁵ and others^{4, 8} have advocated “slanted” recession and resection of the horizontal rectus muscles. In patients with **V** esotropia, the lower margins of the medial rectus muscles are recessed further posteriorly than the upper margins to increase the effect of the operation on the horizontal deviation in downward gaze. Similarly, in patients with **V** exotropia, the upward margins of the lateral rectus muscles are recessed more than the lower margins to gain a greater effect on the horizontal deviation in upward gaze. In accordance with the same principle, in patients with **A** esotropia, more recession is required of the upper margins of the medial rectus muscles; in those with **A** exotropia, more recession of the lower margins of the lateral rectus muscles is necessary. Rüssman,⁷⁰ however, in 50 patients with **A** and **V** patterns, reported unpredictable results when slanting the muscle insertion. He concluded that surgery on the oblique muscles and vertical transposition of the rectus muscles are more effective.

We have no personal experience with these procedures, and in view of the predictability of conventional methods, we advocate surgical management of the **A** and **V** pattern according to the guidelines summarized in the following paragraphs.

Choice of Surgical Procedure

Following this review of various surgical approaches to the **A** and **V** patterns, we now outline the methods that in our hands have proved most successful.

V ESOTROPIA WITH ELEVATION IN ADDUCTION. This pattern is the most frequently encountered deviation. An inferior oblique weakening procedure merely “closes” the **V** pattern in upward gaze, and thus combined horizontal surgery becomes necessary. The amount of horizontal surgery should be planned according to the size of the deviation with the eyes in primary position.

V ESOTROPIA WITHOUT ELEVATION IN ADDUCTION. The inferior oblique muscles should not be weakened unless there is upshoot in adduction. If esotropia is present in downward gaze only, a patient usually keeps the chin depressed to maintain single binocular vision. In such cases, downward transposition of both medial rectus muscles is indicated, combined with recession of these muscles if the deviation is larger than 15^Δ in downward gaze. For larger deviations in primary position and downward gaze, we prefer recession of the medial rectus muscle(s) and resection of the lateral rectus muscle(s) with downward transposition of their insertions. If the medial rectus muscles have been operated on before, we transpose the inferior rectus muscles temporally one muscle width.

V EXOTROPIA WITH EXCESSIVE ELEVATION IN ADDUCTION. A weakening procedure on the inferior oblique muscles will decrease the deviation in upward gaze. In patients with orthophoria or a small exophoria in primary position or downward gaze, this procedure may be sufficient to create a satisfactory functional result. However, if clinically significant amounts of exodeviation in primary and downward positions of gaze are present, myectomy of the inferior obliques must be combined with horizontal surgery.

V EXOTROPIA WITHOUT ELEVATION IN ADDUCTION. A **V** exotropia without upshoot in adduction is uncommon, and careful and repeated testing of the versions will usually reveal some elevation; however, if this cannot be demonstrated, the inferior oblique muscles must be left intact. Horizontal surgery and, if the deviation is of significant magnitude in downward gaze, downward transposition of the medial rectus muscle(s) and upward transposition of the lateral rectus muscle(s) are indicated.

A ESOTROPIA WITH DEPRESSION IN ADDUCTION. In such cases bilateral tenectomy or recession of the superior oblique tendon is required. To counteract the predictable increase of the esotropia in downward gaze following superior oblique weakening, it is usual to combine horizontal surgery with this procedure.

A ESOTROPIA WITHOUT DEPRESSION IN ADDUCTION. To prevent overcorrection in the primary position and downward gaze, it is necessary to combine recession of the medial rectus muscle and resection of the lateral rectus muscle with

upward transposition of the medial rectus and downward transposition of the lateral rectus muscle(s).

A EXOTROPIA WITH DEPRESSION IN ADDUCTION. Tenectomy of both superior oblique tendons will lead to a predictable decrease of the deviation in downward gaze. If only a small exodeviation in primary position and upward gaze is present, this procedure may be sufficient. Otherwise, horizontal surgery must also be performed.

A EXOTROPIA WITHOUT DEPRESSION IN ADDUCTION. Downshoot in adduction or excessive depression in adduction can *almost always* be established in patients with A exotropia. Absence of this finding is very unusual indeed and repeated testing on several visits is essential to exclude the possibility that it may have been overlooked. However, if there is none, horizontal surgery with upward transposition of the medial rectus muscle(s) and downward transposition of the lateral rectus muscle(s) should be performed.

Y ESOTROPIA WITH ELEVATION IN ADDUCTION. If fusion is present in upward gaze the patient will usually depress the chin. Bilateral weakening of the inferior oblique muscles will close the Y pattern in upward gaze and must be combined with an operation on the horizontal rectus muscles to correct the esotropia.

Y EXOTROPIA WITHOUT ELEVATION IN ADDUCTION. No treatment is necessary when the patient fuses in primary position and downward gaze, has a normal head posture, and does not complain about double vision in upward gaze. When chin elevation is present, surgical weakening of both inferior oblique muscles will close the Y pattern.

Λ EXOTROPIA WITH DEPRESSION IN ADDUCTION. Patients with a lambda pattern will usually depress the chin to maintain fusion in primary position and upward gaze and to avoid the downward gaze position. A weakening of both superior oblique muscles will close the Λ pattern.

REFERENCES

1. Albert DG: Personal communication. In Parks MM: Annual review: Strabismus. Arch Ophthalmol 58:152, 1957.
2. Berke RN: Tenotomy of the superior oblique for hyperopia (preliminary report). Trans Am Ophthalmol Soc 44:304, 1946.
3. Bielschowsky A: Motilitätsstörungen der Augen. In Graefe A von, Saemisch T, eds: Handbuch der gesamten Augenheilkunde, ed 2, vol 8. Berlin, Springer-Verlag, 1939, p 164.
4. Biedner B, Rothkoff L: Treatment for "A" or "V" pattern esotropia by slanting muscle insertion. Br J Ophthalmol 79:807, 1995.
5. Bietti GB: Su un accorgimento tecnico (recessione e reinserzione obliqua a ventaglio dei muscoli retti orizzontali) per la correzione di atteggiamenti a V o A di grado modesto negli strabismi concomitanti. Boll Ocul 49:581, 1970.
- 5a. Biglan AW: Ophthalmological complications of meningo-myelocoele: A longitudinal study. Trans Am Ophthalmol Soc 88:389, 1990.
6. Billet E, Freedman M: Surgery of the inferior oblique muscles in V pattern exotropia. Arch Ophthalmol 82:21, 1969.
7. Boeder P: The cooperation of the extraocular muscles. Am J Ophthalmol 51:469, 1961.
8. Boyd TAS, Leitch GT, Budd GE: A new treatment for "A" and "V" patterns in strabismus by slanting muscle insertions: A preliminary report. Can J Ophthalmol 6:170, 1971.
9. Breinin GM: New aspects of ophthalmoneurologic diagnosis. Arch Ophthalmol 58:375, 1957.
10. Breinin GM: Vertically incomitant horizontal strabismus. The A-V syndromes. NY State J Med 61:2243, 1961.
11. Breinin G: The physiopathology of the A and V patterns. In Symposium: The A and V patterns in strabismus. Trans Am Acad Ophthalmol Otolaryngol 68:363, 1964.
12. Brown HW: Vertical deviations. In Symposium, Strabismus. Trans Am Acad Ophthalmol Otolaryngol 57:157, 1953.
13. Caldeira JA: Bilateral recession of the superior oblique in "A" pattern tropia. J Pediatr Ophthalmol Strabismus 15:306, 1978.
14. Caldeira JAF: Bilateral recession of the superior oblique graded according to the A pattern: A prospective study of 21 consecutive patients. Binocular Vision Strabismus Q 10:167, 1995.
15. Cheng H, Burdon MA, Shun-Shin GA, Czypionka S: Dissociated eye movements in craniosynostoses: A hypothesis revisited. Br J Ophthalmol 77:563, 1993.
16. Ciancia AO: La correspondencia sensorial en los sindromes en A y V. J Pediatr Ophthalmol 2:15, 1965.
17. Clark RA, Miller JM, Rosenbaum AL, Demer JL: Heterotopic muscle pulleys or oblique muscle dysfunction? J AAPOS 2:17, 1998.
18. Cords R: Strabismus surso-adductorius. Ber Dtsch Ophthalmol Ges 43:158, 1922.
19. Costenbader FD: Introduction. In Symposium: The A and V patterns in strabismus. Trans Am Acad Ophthalmol Otolaryngol 68:354, 1964.
20. de Ancos E, Strickler J, Klainguti G: Traitement des syndromes alphabetiques en "V." Klin Monatsbl Augenheilkd 206:347, 1995.
21. Demer JL, Clark RA, Miller JM: Heterotopy of extraocular muscle pulleys causes incomitant strabismus. In Lenners-trand G, ed: Advances in Strabismology. Proceedings of the Eighth Meeting of the International Strabismological Association, Maastricht, Sept 10-12, 1998. Buren, The Netherlands, Aeolus Press, 1999, p 91.
22. Diamond G: Myelomeningocele, hydrocephalus and "A" pattern esotropia with superior oblique overaction. Presented at the American Association of Pediatric Ophthalmology and Strabismus meeting, Vancouver, BC, August 3-6, 1983.
23. Diamond S: Conjugate and oblique prism correction for noncomitant ocular deviations. Am J Ophthalmol 58:89, 1964.
24. Diamond S: V-esotropia aided by conjugate oblique prism correction: Case report. Am J Ophthalmol 69:133, 1970.
25. Duane A: Isolated paralysis of the ocular muscles. Arch Ophthalmol 26:317, 1897.

26. Fink W: The role of developmental anomalies in vertical muscle deficits. *Am J Ophthalmol* 40:529, 1955.
27. Fink WH: The A and V syndromes. *Am Orthopt J* 9:105, 1959.
28. Folk ER: Costenbader Lecture. A and V syndrome: A historical perspective. *J Pediatr Ophthalmol Strabismus* 34:154, 1997.
29. France T: Strabismus in hydrocephalus. *Am Orthopt J* 25:101, 1975.
30. Gobin MH: Sagittalization of the oblique muscles as possible cause for the "A," "V," and "X" phenomena. *Br J Ophthalmol* 52:13, 1968.
31. Gobin MH: La désagittalization des grands obliques. In Ravault AP, Lenk M, eds: *Transactions of the Fifth International Orthoptic Congress, Lyons, LIPS, 1984*, p 553.
32. Goldstein JH: Monocular vertical displacement of the horizontal rectus muscles in the A and V patterns. *Am J Ophthalmol* 64:265, 1967.
33. Guyton DL: Ocular torsion: Sensorimotor principles. *Graefes Arch Clin Exp Ophthalmol* 26:241, 1988.
34. Guyton DL, Weingarten PE: Sensory torsion as the cause of primary oblique muscle overaction/underaction and A- and V-pattern strabismus. *Binocular Vision Eye Muscle Surg Q* 9 (suppl):209, 1994.
35. Helveston EM, Noorden GK von, Williams F: Retinal correspondence in the "A" or "V" patterns. *Am Orthopt J* 20:22, 1970.
36. Holland G: Bedeutung des A- und V-Syndroms beim frühkindlichen Schielen. *Klin Monatsbl Augenheilkd* 152:739, 1968.
37. Hugonnier R, Clayette-Hugonnier S: Strabismus, heterophoria, ocular motor paralysis. *Clinical ocular muscle balance*. Translated and edited by S. Véronneau-Troutman. St Louis, Mosby-Year Book, 1969.
38. Jampolsky A: Oblique muscle surgery of the A and V pattern. *J Pediatr Ophthalmol* 2:31, 1965.
39. Jenkins R, Noorden GK von: Surgical reversal of A and V patterns. In Tilson G, ed: *Advances in Amblyopia and Strabismus. Transactions of the Seventh International Orthoptic Congress, Nuremberg, June 2-6, 1991*.
40. Knapp P: Vertically incomitant horizontal strabismus: The so-called A and V syndrome. *Trans Am Ophthalmol Soc* 57:666, 1959.
41. Knapp P: A and V patterns. In *Symposium on Strabismus. Transactions of the New Orleans Academy of Ophthalmology*. St Louis, Mosby-Year Book, 1971, p 242.
42. Krewson WE: The action of the extraocular muscles. A method of vector-analysis with computations. *Trans Am Ophthalmol Soc* 48:443, 1950.
43. Kushner BJ: Management of diplopia limited to down gaze. *Arch Ophthalmol* 113:1426, 1995.
44. Limón de Brown E: High incidence of X syndrome in exotropia. In Fells P, ed: *The First Congress of the International Strabismological Association*. St Louis, Mosby-Year Book, 1971, p 101.
45. Limón de Brown E, Monasterio FO, Feldman MS: Strabismus in plagiocephaly. *J Pediatr Ophthalmol Strabismus* 25:180, 1988.
46. Limón de Brown E, Monasterio FO, de Saint Martin R, Feldman MS: Estrabismo en el síndrome de Treacher-Collins-Franceschetti. *Cir Cirujanos* 60:210, 1993.
47. Locke JC: Heterotopia of the blind spot in ocular vertical muscle imbalance. *Am J Ophthalmol* 65:362, 1968.
48. Magee AJ: Minimal values for the A and V syndromes. *Am J Ophthalmol* 50:753, 1960.
49. Maggi C: Sindromi A V e oftalmoplegie congenite. *Boll Ocul* 42:354, 1963.
50. McLean JM: Direct surgery of underacting oblique muscles. *Trans Am Ophthalmol Soc* 46:633, 1948.
51. Melek NB, Mendoza T, Ciancia AO: Bilateral recession of superior rectus muscles: Its influence on A and V pattern strabismus. *AAPOS* 2:333, 1998.
52. Miller JE: Vertical recti transplantation in the A and V syndromes. *Arch Ophthalmol* 64:175, 1960.
53. Miller MM, Guyton DL: Loss of fusion and the development of A or V patterns. *J Pediatr Ophthalmol Strabismus* 31:220, 1994.
54. Möller DE: Vertikale Transposition der horizontalen Musculi recti zur Beseitigung des Höhenschielens. *Klin Monatsbl Augenheilkd* 155:539, 1969.
55. Nakamura T, Awaya S, Miyake S: Insertion anomalies of the horizontal muscles and dysfunctions of the oblique muscles in the A-V patterns. *Acta Soc Ophthalmol Jpn* 95:698, 1991.
56. Noorden GK von: Temporal transplantation of the inferior rectus muscle in V-esotropia. *Am J Ophthalmol* 56:919, 1963.
57. Noorden GK von: *Atlas of Strabismus*, ed 4. St Louis, Mosby-Year Book, 1983.
58. Noorden GK von, Avilla CW: Refractive accommodative esotropia: A surgical problem? *Int Ophthalmol* 16:45-48, 1992.
59. Noorden GK von, Helveston EM: Unpublished observation, 1966.
60. Noorden GK von, Olson CL: Diagnosis and surgical management of vertically incomitant horizontal strabismus. *Am J Ophthalmol* 60:434, 1965.
61. Parks MM: The weakening surgical procedures for eliminating overaction of the inferior oblique muscles. *Am J Ophthalmol* 73:107, 1972.
62. Payne JW, Noorden GK von: The ratio of accommodative convergence to accommodation in strabismus with A- and V-patterns. *Arch Ophthalmol* 77:26, 1967.
63. Pigassou R, Garipuy J: Les syndromes A et V. *Ophthalmologica* 155:217, 1968.
64. Piper HF: Über die Bedeutung des V- und A-Phänomens beim Schielen. *Sitzungsbericht 107, Versammlung Rheinland Westfalen Augenärzte*, 1963, p 63.
65. Piper HF: Verlagerte Muskelansätze als eine Ursache des Schrägschielens (und ihre operative Korrektur). *Sitzungsbericht 109, Versammlung Rheinland Westfalen Augenärzte*, 1964, p 86.
66. Postic G: Étiopathogénie des syndromes A et V. *Bull Mem Soc Fr Ophtalmol* 78:240, 1965.
67. Prieto-Diaz J: Management of superior oblique overaction in A-pattern deviations. *Graefes Arch Clin Exp Ophthalmol* 226:126, 1988.
68. Raab EL, Costenbader FD: Contralateral inferior oblique overaction following unilateral weakening surgery. In Mein J, Bierlaagh JJM, Brumelkamp-Dons TEA, eds: *Orthoptics. Proceedings of the Second International Orthoptic Congress*. Amsterdam, Excerpta Medica, 1972, p 238.
69. Robb RM, Boger WP: Vertical strabismus associated with plagiocephaly. *J Pediatr Ophthalmol Strabismus* 20:58, 1983.
70. Rüssmann W: Erfahrungen mit schrägen Rücklagerungen und Resektionen von Horizontalmotoren bei A- und V-syndromen. *Klin Monatsbl Augenheilkd* 178:171, 1981.
71. Ruttam M, Noorden GK von: Orbital and facial anthropometry in A and V pattern strabismus. In Reinecke RD, ed: *Strabismus II*. New York, Grune & Stratton, 1984, p 363.
72. Saunders RA, Holgate RC: Rectus muscle position in V-pattern strabismus. A study with coronal computed tomography scanning. *Graefes Arch Clin Exp Ophthalmol* 226:183, 1988.
73. Shin GS, Elliott RL, Rosenbaum AL: Posterior superior oblique tenectomy at the scleral insertion for collapse of A-pattern strabismus. *J Pediatr Ophthalmol Strabismus* 33:211, 1996.

74. Scobee RG: The Oculorotary Muscles, ed 2. St Louis, Mosby-Year Book, 1952, p 55.
75. Scott AB: A and V patterns in exotropia. An electromyographic study of horizontal rectus muscles. *Am J Ophthalmol* 65:12, 1968.
76. Scott AB: V pattern exotropia. Electromyographic study of an unusual case. *Invest Ophthalmol* 12:232, 1973.
77. Scott AB, Stella SL: Measurement of A and V patterns. *J Pediatr Ophthalmol* 5:181, 1968.
78. Scott WE, Drummond GT, Keech RV: Vertical offsets of horizontal recti muscles in the management of A and V pattern strabismus. *Aust NZ J Ophthalmol* 17:281, 1989.
79. Stuart JA, Burian HM: Changes in horizontal heterophoria with elevation and depression of gaze. *Am J Ophthalmol* 53:274, 1962.
80. Urist MJ: Horizontal squint with secondary vertical deviations. *Arch Ophthalmol* 46:245, 1951.
81. Urist MJ: Surgical treatment of esotropia with bilateral elevation in adduction. *Arch Ophthalmol* 47:270, 1952.
82. Urist MJ: Exotropia with bilateral elevation in adduction. II. Surgery. *Am J Ophthalmol* 38:178, 1954.
83. Urist MJ: The etiology of the so-called A and V syndromes. *Am J Ophthalmol* 46:835, 1958.
84. Urist MJ: Recession and upward displacement of the medial rectus muscles in A-pattern esotropia. *Am J Ophthalmol* 65:769, 1968.
85. Urrets-Zavalía A: Abducción en la elevación. *Arch Ophthalmol B Aires* 22:1, 1948.
86. Urrets-Zavalía A: Parálisis bilateral congénita del musculo oblicuo inferior. *Arch Ophthalmol B Aires* 23:172, 1948.
87. Urrets-Zavalía A, Solares-Zamora J, Olmos HR: Anthropological studies on the nature of cyclovertical squint. *Br J Ophthalmol* 45:578, 1961.
88. Villaseca A: The A and V syndromes. *Am J Ophthalmol* 52:172, 1961.
89. Weiss JB: Ectopies et pseudoectopies maculaires par rotation. *Bull Mem Soc Fr Ophtalmol*. 79:329, 1966.

Paralytic Strabismus

A motor imbalance caused by paralysis of one or several extraocular muscles must be clearly distinguished from comitant forms of strabismus whenever possible because correct identification of a paretic muscle or muscle groups is of paramount importance for the success of therapy. Moreover, an acquired paralysis may signal a condition that can affect the patient's general health. Diagnosis of a paralysis of recent onset is not particularly difficult and is based on the presence of a motor deficiency in the field of action of the paralyzed muscle, diplopia, increase of the deviation when the patient fixates with the paralyzed eye, and in many instances, a compensatory anomaly of the head posture. However, diagnosis of a congenital or long-standing paralysis can present more of a clinical challenge.

The emphasis in this chapter is on the diagnostic and differential diagnostic aspects of paralytic strabismus. For information on the neuro-ophthalmologic implications of paralytic strabismus, refer to the standard texts on this subject.

The terms *paretic* and *paralytic* often are used interchangeably in clinical ophthalmology, even though paretic denotes only a partial or incomplete paralysis. The terms *paralysis* and *palsy* are synonyms. We distinguish between complete and partial paralysis whenever necessary in this chapter.

Diagnosis and Clinical Characteristics

Unlike nonparalytic comitant strabismus in which the deviation may remain fairly stable or change

only gradually in magnitude with time, paralytic strabismus is characterized by a more dynamic course of events. Onset is usually sudden and the patient immediately recognizes the problem as he or she becomes aware of diplopia. The clinical picture may change significantly, however, within a few weeks after the onset of either a paresis or paralysis, because of a profound effect on the innervational equilibrium of the entire oculomotor apparatus, which affects not only the paralyzed eye but also, under certain circumstances, the sound eye.

A paralytic deviation undergoes several stages. The first stage is characterized by weakness of the paralyzed muscle followed, as a rule, by overaction of its direct antagonist. During this stage the maximal deviation is still in the field of action of the paralyzed muscle; for example, in a patient with a right superior oblique paralysis of recent onset, the largest amount of right hypertropia will be in the left lower field of gaze. This stage is followed by one in which overaction of the antagonist of the paralyzed muscle is the principal clinical feature. For instance, with paralysis of the right superior oblique, hypertropia will not be restricted to the field of action of the paralyzed muscle but may reach equal proportions in the entire left field of gaze or even increase when the patient is looking up and to the left. One of the most characteristic features during this stage is the fact that overaction and subsequent contracture of an antagonist muscle may overshadow defective action of the paralyzed muscle and persist long after the paralysis has subsided.

The clinical application of the term *contracture* is with reference to increased resistance against passive stretching of the muscle. This loss of elasticity has been related to histologic alterations consisting of atrophy of muscle fibers and hyalinization of the normal muscle.^{1,2}

During the third stage the deviation will spread into all fields of gaze and become increasingly comitant. It may then no longer be possible to detect a parietic component, and the angle of strabismus may be of the same magnitude with either the paralyzed or sound eye fixating. This development has been referred to as *spread of comitance*. In a patient with right superior oblique paralysis, the right hypertropia would then be present in primary position and levoversion as well as in dextroversion.

A paralytic deviation does not necessarily progress from the first to the last stage. Occasionally, and for unknown reasons, the antagonist of the paralyzed muscle does not overact, and the deviation remains limited to the field of action of the paralyzed muscle. In most patients, however, comitance spreads within a few weeks, months, or even years.

Ductions and Versions

If the paralysis is of recent onset, a careful study of ductions and versions, as outlined in Chapter 12, will readily disclose the weak, paralyzed muscle. A paralyzed medial or lateral rectus muscle is identified by its deficient action in adduction or abduction. A paralytic hyperdeviation is slightly more difficult to diagnose because it is necessary to differentiate between a pair of elevators or depressors in each eye. Once it has been determined that a right or left hypertropia is present in primary position, it must be established whether the deviation increases on dextroversion or levoversion. An increase of a left hyperdeviation in dextroversion, for instance, may be caused by paralysis of the left superior oblique or the right superior rectus muscles. When the paralysis is of recent onset, the diagnosis is made on the basis of incomplete duction in the field of action of the respective rectus or oblique muscles. However, to restrict the examination to ductions may mask a paresis, since the patient may overcome the muscle weakness by maximal innervational effort when fixating with the parietic eye. More revealing is the examination of versions, for under these circumstances the patient will show marked over-

action of the yoke muscle of the parietic muscle in the contralateral eye (secondary deviation) when fixating with the parietic eye. In patients who have a paresis of longer standing, the head tilt test (see p. 416) may be used to differentiate between a parietic elevator muscle in one eye and a parietic depressor muscle in the other.

A *contracture of the antagonist* of the paralyzed muscle not only may obscure the nature of the primary defect in the paralyzed eye but also may affect motor balance of the fellow eye when the patient habitually fixates with the paralyzed eye. This is not an uncommon finding when the paralysis affects a strongly dominant eye. The antagonist of a paralyzed muscle will require less innervation to move the eye in its field of action since the normal tonus of its paralyzed opponent is decreased. Consequently, according to Hering's law of equal innervation, the yoke muscle of the antagonist of a parietic or paralyzed muscle will receive less innervation than required and will be apparently underacting. This phenomenon, which Chavasse^{45, p.232} somewhat awkwardly designated *inhibitional palsy of the contralateral antagonist*, may present difficulties in identifying the paralyzed eye. For instance, in a patient with a left superior oblique paralysis who habitually fixates with the parietic eye and in whom overaction of the homolateral inferior oblique muscle has developed, less than the normal amount of innervation will be required when he or she is looking up and to the right. Since the innervation flowing to the right normal eye is determined by the left inferior oblique muscle, the right superior rectus will seem parietic (Fig. 20-1). The head tilt test is then used to determine which of the two muscles, left superior oblique or right superior rectus, is parietic (see Figs. 20-3, 20-4).

Measurement of the Deviation

Although evaluation of ductions and versions is sufficient to identify gross defects of ocular motility, a quantitative study of the angle of deviation in diagnostic positions of gaze with either eye fixating will reveal more subtle forms of paralysis. This examination is essential in establishing severity of the disturbance and in assessing whether further deterioration will occur or recovery will take place. These measurements are obtained using objective (prism and cover test) or subjective (diplopia fields) methods, as outlined in Chapter 12. Such tests, with the patient fixating first with

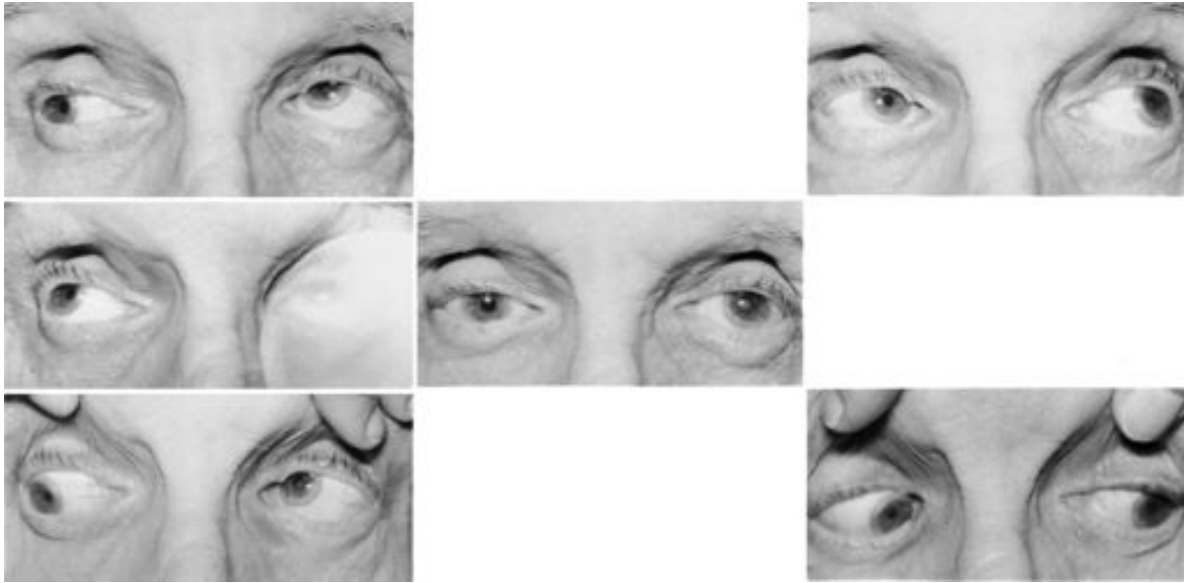

FIGURE 20-1. Inhibitional palsy of the right superior rectus (*upper left*) in a patient with left superior oblique palsy who fixates with the paralyzed eye. Note normal right superior rectus action and marked overaction of the left inferior oblique under the translucent cover when the right eye is fixating (*left*), and the left eye is covered with a Spielmann translucent occluder (see Chapter 12).

one eye and then the other, are of fundamental diagnostic importance, since a difference between a *primary deviation* (nonparetic eye fixating) and a *secondary deviation* (paretic eye fixating) clearly distinguishes paralytic from nonparalytic strabismus; *the secondary deviation is always greater than the primary deviation*. According to Hering's law of equal innervation (see Chapter 4), the innervation flowing to the yoke muscles of both eyes is always determined by the fixating eye. Thus the angle of deviation will vary depending on whether the patient fixates with the sound eye or the paretic eye. For instance, in a patient with a left superior rectus paralysis, when the right eye is fixating, the normal amount of innervation will maintain the right eye in primary position. A left hypotropia will be present, since the innervation flowing to the paretic eye is not sufficient to elevate it to the midline. If, however, the patient fixates with the left paretic eye, excess innervation will be required to move it into primary position and the same amount of innervation will flow to the yoke muscles of the right eye, causing it to elevate excessively (see Fig. 20-1).

The derivation of the term *yoke muscle* was discussed on page 63. To this discussion we should like to add a historical note. The first to use this term in reference to synergistic muscles in paralytic strabismus was the neurologist Gowers who in 1888 wrote "it is as if a rein acted equally on a hard-mouthed and a tender-mouthed

horse, yoked together; the effort to make the former deviate would cause an excessive deviation of the latter."⁸⁷

To assess the extent of functional impairment caused by double vision in patients with paralytic strabismus, it is helpful to chart the patient's field of binocular fixation by means of a perimeter (see Fig. 20-30). Such records are invaluable not only for documenting subtle changes in terms of progression or improvement of a paralyzed muscle²¹⁹ but also for medicolegal purposes as a record of the patient's disability.

Paralysis of the cyclovertical muscles invariably causes cyclotropia, and its diagnosis and measurement (see Chapters 12 and 18) provide important diagnostic clues. In patients who fixate with the paretic eye the cyclodeviation may appear in the normal eye—a phenomenon that occasionally causes confusion in diagnosis²⁰⁸ and has been referred to as *paradoxical cyclotropia*.

Head Tilt Test

The head tilt test is alluded to in Chapter 12. The physiologic basis of the head tilt test was explained by Hofmann and Bielschowsky¹¹² and it has become universally known as the "Bielschowsky head tilt test." However, 30 years before Hofmann and Bielschowsky, Nagel¹⁹¹ noted that the combined action of the superior rectus muscle and the superior oblique muscle of one eye and of the

inferior rectus and inferior oblique muscles in the fellow eye causes incycloduction and excycloduction. Nagel also hinted that with a cyclovertical paresis the deviation would be more noticeable with appropriate tipping of the head. This theory was fully confirmed on clinical grounds by Hofmann and Bielschowsky, who gave the following explanation for the head tilt phenomenon. If, for instance, in a patient with a right superior oblique paresis, the head is tilted to the right shoulder, nervous impulses will arise from the otolith apparatus and be sent to all muscles concerned when both eyes are rotating around their anteroposterior axis to the left. Thus excycloduction of the left eye is produced by co-contraction of both inferior muscles and incycloduction of the right eye by co-contraction of both superior muscles. However, since the paretic right superior oblique muscle is no longer capable of counteracting the elevating and adducting component of the right superior rectus muscle, the right eye will move upward (positive Bielschowsky test; Figs. 20–2, 20–3, 20–4, and 20–20). With the head tilted to the left, the cycloversional movement of both eyes to the right occurs without participation of the paretic muscle; hence, the visual axis will not become deviated. It goes without saying that owing to the orientation of the semicircular canals the test cannot be applied in the supine patient.

The head tilt test is applicable in paresis of any of the cyclovertical muscles. However, there is less vertical difference between the two eyes upon tilting the head with paresis of vertical rectus muscles than with paresis of the oblique muscles because the vertical action of the unopposed oblique muscles is considerably less than that of the unopposed vertical rectus muscles.

Following its original description by Hofmann and Bielschowsky¹¹² the head tilt test has become firmly established in our diagnostic armamentarium. Several modifications have evolved with which the examiner can arrive at the correct diagnosis of the offending muscle.^{78, 99, 100, 103, 212} The test is especially useful in distinguishing a true from a simulated superior rectus paralysis in a patient with a contralateral superior oblique paralysis who habitually fixates with the paralyzed eye (inhibitional palsy of the contralateral antagonist; see Fig. 20–1).

We follow the diagnostic scheme popularized by Parks²¹² by asking the following three questions: (1) Does the patient have a right or left hypertropia in primary position? (2) Does this

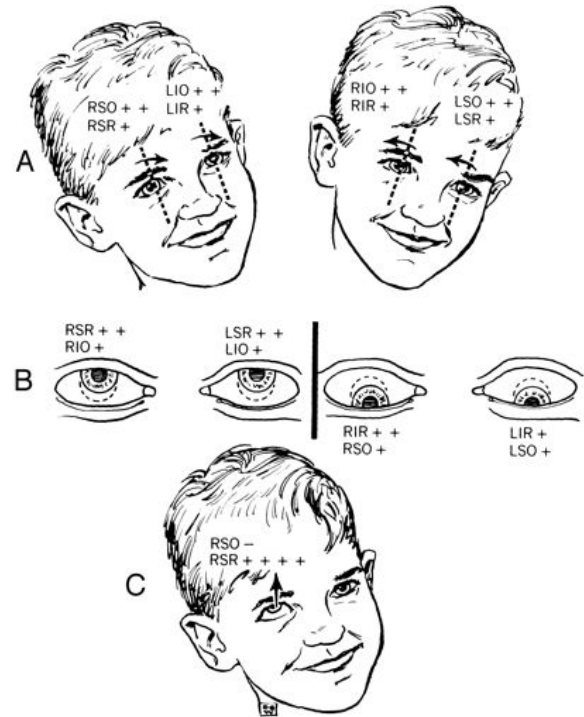


FIGURE 20–2. Physiologic basis of the Bielschowsky head tilt test. *A*, On tilting the head to either shoulder, reflex innervation of the cyclorotatory extraocular muscles occurs from stimulation of the otolith apparatus. Head inclination to the right shoulder causes incycloduction OD and excycloduction OS and inclination to the left shoulder elicits a cycloversion to the opposite (*right*) direction. The muscles involved in rotating the eyes around their anteroposterior axes are indicated by their initials. The compensation of the head inclination by cyclorotation of the eyes does not fully offset the angle of inclination. *B*, Muscles that act synergistically during cycloductions become antagonists when elevating and depressing the globes. Under normal conditions the vertical action of the rectus muscles exceeds that of the oblique muscles; conversely, the effect of the oblique muscles on cycloduction is greater than that of the vertical rectus muscles. *C*, When the head is tilted to the involved side in the case of a right superior oblique paralysis, the vertical and adducting action of the right superior rectus is unopposed. Contraction of this muscle in an attempt to incycloduct the eye results in elevation of that eye, thus increasing the vertical deviation (positive Bielschowsky test). (From Noorden GK von: *Atlas of Strabismus*, ed 4. St Louis, Mosby-Year Book, 1983.)

deviation increase in dextroversion or levover-
sion? (3) Does it increase with the head tilted to
the right or left shoulder? Using this three-step
method, one can distinguish a paretic oblique or
vertical rectus muscle in most instances. Figures
20–3 and 20–4 show the various responses that
may be encountered during the head tilt test.

Compensatory Anomalies of Head Position

Ocular torticollis was first described in 1873 by
Cuignet.⁵³ The various forms of anomalous head

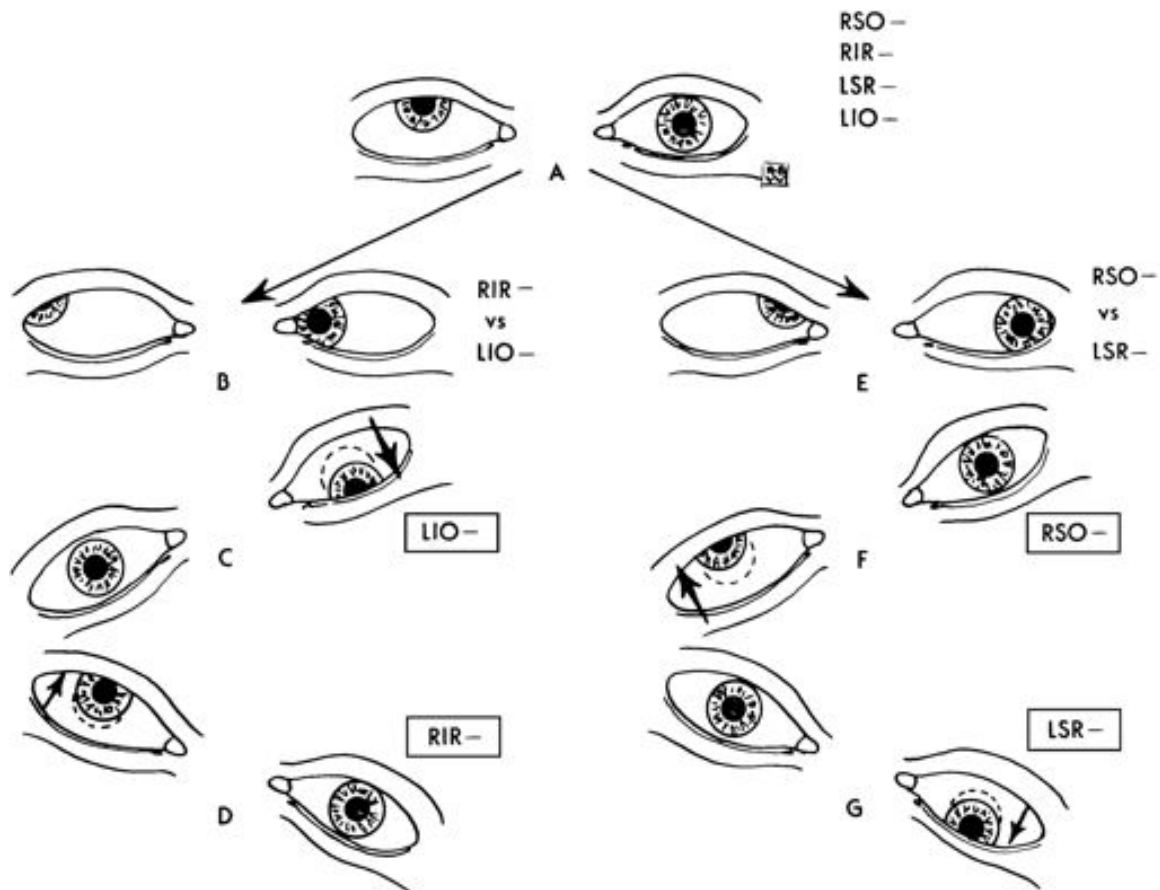


FIGURE 20-3. Diagnosis of the paretic muscle in a patient with right hypertropia (RHT). By comparing the position of the patient's eye with the drawing, one can identify the paretic muscle. A, RHT may be caused by paresis of the right superior oblique (RSO), right inferior rectus (RIR), left superior rectus (LSR), or left inferior oblique (LIO). Increased RHT in dextroversion (B), or levoersion (E), limits the number of possibly paretic muscles to two. The paretic muscle is identified by tilting the head to the right and left shoulders (C, D, F, and G). (From Noorden GK von: Atlas of Strabismus, ed 4. St Louis, Mosby-Year Book, 1983.)

posture, such as head turn, head tilt, and chin elevation or depression in patients with A and V patterns of strabismus or nystagmus, are discussed in Chapters 12, 19, and 23. In this chapter, it is necessary to mention only that most patients with paralytic strabismus habitually hold their heads in a position in which they can avoid the field of action of the paretic muscle. Horizontal, vertical, or torsional diplopia is thus eliminated and single binocular vision maintained. For instance, a head turn toward the side of the paralyzed eye will compensate for a right lateral rectus paralysis, and a head tilt to one shoulder with chin depression is characteristic of a superior oblique paralysis on the opposite side. Moses¹⁸⁶ stated that to avoid the tilt of the vertical meridian and the vertical deviation in superior oblique paralysis, "the head will be held in that position which brings the vertical meridian of the normal eye parallel with that of

the paralyzed eye," and that "this is accomplished by tilting the head toward the opposite shoulder."

One must keep in mind that the degree of "righting" of the eyes by tilting the head is much smaller than the degree of head tilt (see Chapter 4). Although it is true that the degree of cyclodeviation is greater with the head tilted to the shoulder on the side of the affected eye, the retinal meridians of the two eyes are by no means parallel with the head tilted to the opposite shoulder. Preferably, one should simply remember that *there is a head position in which the paretic muscle receives a minimum of impulses to contract. This is the position in which a patient with a paralyzed muscle habitually holds the head.*

Not all patients with paralytic strabismus, however, achieve single binocular vision with an anomalous head position. If this were so, the head posture would be expected to normalize when

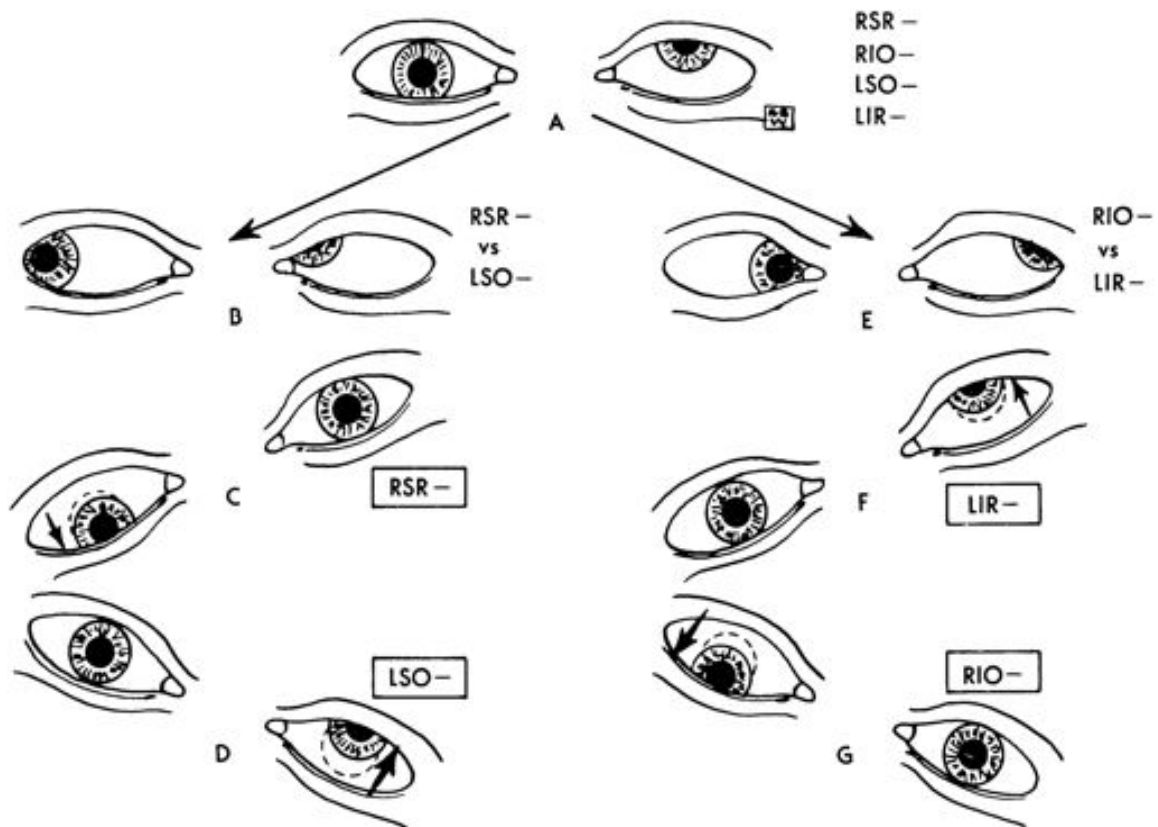


FIGURE 20-4. Diagnosis of the paretic muscle in a patient with left hypertropia (LHT). The three-step maneuver is performed as in Figure 20-3. (From Noorden GK von: Atlas of Strabismus, ed 4. St Louis, Mosby-Year Book, 1983.)

either eye is covered since diplopia is no longer present under such circumstances. The anomalous head posture often will persist when the fixating eye is covered and will disappear only by covering the paretic eye, which indicates that certain monocular benefits such as elimination of image disclination may accrue from an anomalous head posture.²⁰⁰ Furthermore, some patients unable to fuse by means of a compensatory head posture will turn or tilt their head in the opposite direction to increase the distance between the double images or to use their nose as an occluding device. It is also possible that the patient will assume an anomalous head posture to permit anomalous fusion on the basis of *anomalous retinal correspondence*.¹⁰

From the foregoing statements, it follows that even though anomalies of head posture should alert the ophthalmologist to the presence of paretic or paralytic strabismus, these signs are of limited significance in ascertaining the nature of the underlying condition. The direction of the head tilt is fairly consistent with paresis of the oblique muscles. The head is inclined toward the opposite side with involvement of the superior oblique and

toward the paretic side with involvement of the inferior oblique muscle, although a head tilt toward the paralyzed side (paradoxical torticollis) may occur occasionally with paralysis of the superior oblique muscle. The direction of compensatory head position varies more frequently with paralyzes of the vertical rectus muscles, when the head may be tilted toward the involved or noninvolved side.¹⁵⁰

It is important to distinguish between *congenital nonocular* and *ocular torticollis*. Congenital torticollis is caused by anomalous fusion or malformation of the cervical vertebrae or by fibrosis of the sternocleidomastoid muscle, possibly secondary to birth trauma. Needless to say, no amount of wearing collars, traction devices, or surgery on the sternocleidomastoid muscle can correct an ocular torticollis. It is disconcerting how often children undergo unnecessary physical therapy for many months and even orthopedic surgery in attempts to correct an ocular torticollis. We have seen children with classic congenital superior oblique paralysis who had scars over the sternocleidomastoid muscle from previous surgical attempts to correct the head tilt. A search of the

TABLE 20-1. Differential Diagnosis: Congenital vs. Ocular Torticollis

	Congenital	Ocular
Age	Onset during the first 6 mo after birth	Onset rarely before 18 mo of age
Head position	Passive or voluntary straightening of head is difficult or impossible	Head can easily be straightened passively or voluntarily and tipped to opposite side
Neck muscles	Palpation reveals hardening of sternocleidomastoid muscle	Palpation negative
Vision	No visual disturbances	Diplopia common on straightening of head or when tilting it to opposite side
Effect of occlusion	Torticollis not influenced by occlusion of either eye	Head straightens on occluding the paretic eye except when secondary skeletal changes have occurred

leading texts of orthopedic surgery in which the treatment of congenital torticollis is discussed revealed the disturbing finding that oculomotor paralyses are rarely mentioned in the differential diagnosis of abnormal head posture.

An unusual cause of nonocular torticollis is *hiatus hernia*.^{205, 257} Other sources of abnormal head positions (nystagmus, mechanical-restrictive forms of strabismus, uncorrected astigmatism, unilateral hearing loss) should always be kept in mind. Table 20-1 lists the principal differences between congenital and ocular torticollis.

A head tilt of long standing, whether it be caused by a tight sternocleidomastoid muscle or by a congenital cyclovertical muscle paralysis, is often accompanied by *facial asymmetry*. The face toward the side of the head tilt is vertically compressed and the orbit is lower than on the opposite side²⁷⁵ (Fig. 20-5). It has been suggested that the facial asymmetry is caused by positional molding of the face from persistence of the head tilt during sleep.⁸⁴ This is a possibility to be considered in nonocular congenital torticollis but we find it difficult to explain the facial asymmetry in patients with congenital paralysis of the superior oblique on the same basis. Clearly, there is as little need for an infant with a congenital superior oblique paralysis to maintain the head tilt during sleep as there is for the awake patient to tilt the head when vertical diplopia is eliminated by occluding one eye. Restriction of normal facial growth by persistent muscle pull on the facial bones toward one side¹¹⁵ appears to be a more plausible explanation for the asymmetry. The facial asymmetry caused by a head tilt must be differentiated from that occurring in plagiocephaly (see p. 438) where the forehead is flattened on the side opposite the head tilt.

The presence of facial asymmetry is an important clinical sign to distinguish a cyclovertical

muscle paralysis with an onset at birth or early in life from one recently acquired. It is likely that facial asymmetry can be avoided by early surgery of the underlying condition but whether facial asymmetry can be reversed by early surgery is debatable. Another reason for early surgery is that secondary scoliosis and contracture of the neck muscles may develop as a result of an abnormal

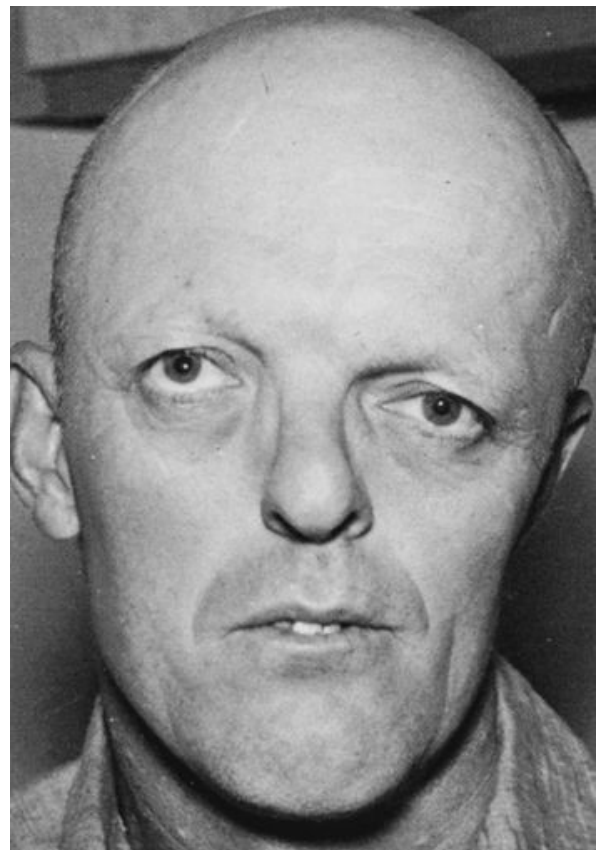


FIGURE 20-5. Marked facial asymmetry, vertical compression, and lowered orbit of the left side of the face in a patient with congenital right superior oblique paralysis. A marked head tilt to the left shoulder (more pronounced than shown on this photograph) was present since early childhood. (From Noorden GK von, Maumenee AE: Atlas of Strabismus. St Louis, Mosby-Year Book, 1967.)

head posture.^{15, 61, 225} In such instances the head tilt may persist even after the paralyzed eye has been occluded or after the underlying cause has been eliminated surgically.

Sensory Anomalies

Sensory anomalies do not occur in association with paralysis of the extraocular muscles as frequently as they do with comitant forms of strabismus. The fact that most patients are able to maintain simultaneous binocular vision in a direction of gaze opposite to the field of action of a paretic muscle precludes development of deep-seated sensorial anomalies although exceptions to this rule have been reported.¹⁴ The incomitance of the deviation is not consistent with a stable angle of strabismus—one of the prerequisites of the establishment of sensorial adaptations. Sensory anomalies in paralytic strabismus usually are restricted to patients with congenital paralysis or paralysis of onset during early childhood. As pointed out on page 415, with the passage of time a paralytic deviation may become increasingly comitant and create conditions favorable to development of sensory anomalies, provided, of course, onset is at an age at which such adaptations are likely to occur. Suppression, amblyopia, or anomalous retinal correspondence is as likely to develop in such patients as it is in patients with nonparalytic strabismus.

If the strabismus remains incomitant and onset is during childhood, diplopia in the paretic field of fixation may be prevented by *regional suppression* (see Chapter 13). Characteristically, this form of suppression will occur only when the patient moves the eyes into the paretic field of gaze and will be absent when the eyes are aligned. For instance, a patient with a right abducens paralysis acquired at 4 years of age and with esotropia may have perfectly normal binocular function in levoversion but suppress the right eye in primary position and dextroversion.

Amblyopia in paralytic strabismus occurs only in patients unable to maintain simultaneous binocular vision in any direction of gaze and in whom paralysis occurs early in life. Amblyopia may cause complications in diagnosing paralytic strabismus since some patients with congenital paralysis may *fixate with the paralyzed eye* to increase separation of the images (secondary deviation). In such instances the nonparalyzed deviated eye may become amblyopic; thus, *amblyopia in a patient*

with paralytic strabismus does not necessarily mean that the amblyopic eye is also the paralyzed eye. We have observed this pattern in several patients with congenital oculomotor paralysis who fixated with the paralyzed exotropic and hypotropic eye and, as a result, had developed a head turn and chin elevation of bizarre proportions (see also Kazarian and Flynn¹³²).

Under certain circumstances, limitation of ocular motility may influence visual acuity in different positions of gaze by changing the fixation behavior on a mechanical basis. For instance, in an eye with right abducens paralysis, visual acuity may be decreased when it is tested in abduction and be normal when tested in primary position or adduction (see Chapter 14). Obviously, the limitation of abduction prevents central fixation in that position, and visual acuity is limited by the functional capacity of that part of the retina in the nasal periphery with which the object is viewed. These motor influences on acuity and fixation behavior in strabismic patients were described first by von Graefe⁸⁹ and in more recent years have been studied by other investigators.^{1, 28, 54, 55, 66, 119, 139, 198} Such studies led to a specific surgical approach for treatment of eccentric fixation.

Past-Pointing

Von Graefe first described anomalies of egocentric localization, referred to as past-pointing or false orientation, in patients with paralytic strabismus. If the patient is asked to point to an object in the field of action of the paralyzed muscle while the sound eye is covered, his finger will point beyond the object toward the field of action of the paralyzed muscle. During this test, it is important that the patient point rapidly toward the object to avoid visual correction of the error of localization while the hand is still moving toward the object. Better still, it helps if the hand of the patient is covered by a piece of cardboard during the test (Fig. 20–6).

During the first part of the twentieth century the qualitative and quantitative study of this phenomenon was important in the diagnosis and differential diagnosis of paralytic strabismus. More recently, however, this test has become less popular and more reliable diagnostic methods have replaced it. However, since past-pointing occurs only with paralysis of the extraocular muscles of recent onset and tends to disappear gradually, this sign continues to be of clinical value in distin-

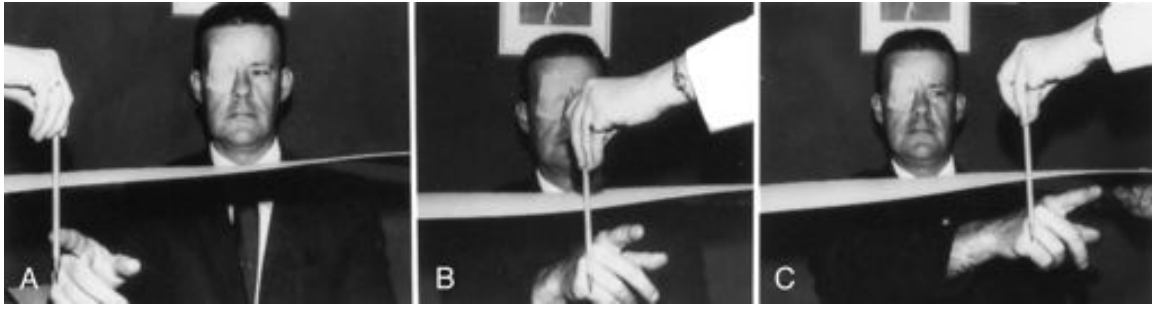


FIGURE 20-6. Past-pointing in a patient with left sixth nerve paresis. *A*, Normal egocentric localization in dextroversion. *B*, Past-pointing to the left when viewing an object in the median plane, and *C*, in the paretic field of gaze.

guishing between congenital and acquired paralysis.

The theoretical aspects of the past-pointing phenomenon are far more interesting than its usefulness as a diagnostic tool. Egocentric localization of objects in space (see Chapter 2) is approximately correct as long as there is no discrepancy between the innervational effort to move the eye and the amplitude of the executed eye movement. Errors of egocentric localization such as past-pointing occur when motor innervation and the elicited eye movement are disproportionate. With left abducens paralysis, for instance, excessive innervation is required to counteract the unopposed antagonistic medial rectus muscle when the patient is holding the paralyzed eye in primary position or moving it toward abduction. As a result, the subjective impression created by excessive abduction innervation is that the object to be fixated lies to the left of the median plane in primary position and even farther to the left on attempted abduction (see Fig. 20-5). This classic theory of the mechanism of past-pointing^{22, 88, 102, 111} has not gone unchallenged, and other explanations have been proposed.^{3, 211, 262} However, von Noorden and coworkers²⁰¹ confirmed experimentally that the classic theory of past-pointing as an error of subjective localization caused by disproportion between innervational input and motor output is still true. Interestingly, past-pointing is not limited to paralytic strabismus but has been described also in association with comitant deviations.^{7, 253, 258}

Electromyography

The works of Björk and Kugelberg,²⁵ Huber and Lehner,¹¹⁶ Esslen and Papst,⁷⁰ Breinin,³² Jampolsky,¹²³ and many others have established that electromyography is of limited value as a diagnostic tool in the field of paralytic strabismus. Electro-

myography is of value only in conjunction with other diagnostic methods in establishing whether a paralysis of the extraocular muscles is of *myogenic* or *neurogenic* origin. For instance, in myogenic processes such as endocrine myopathy or chronic progressive ophthalmoplegia (see Chapter 21), the electromyogram is characterized by a disproportion between massive recruitment of motor units and inability to move the eye. In patients with myasthenia gravis, a disorder of the neuromuscular junction (see Chapter 21), increased electromyographic activity during intravenous administration of edrophonium chloride (Tensilon) will establish the diagnosis even in patients who may not show clinically observable improvement of ocular motility after the drug has been injected. In those with peripheral neurogenic oculomotor paralysis, the electromyogram will show partial or complete loss of motor units in spite of maximal volitional innervation, thus clearly differentiating such problems from a myogenic process.

On the other hand, the electromyogram does not topographically differentiate between peripheral, nuclear, or supranuclear neurogenic lesions. In most instances, information obtained using other methods of examination, such as the forced duction test, and the specific clinical characteristics of the underlying disorder make electromyography unnecessary in the practice of clinical ophthalmology. However, electromyography is of value as a research tool and has added much to our knowledge of the physiology of vergence movements and of the Duane retraction syndrome (see Chapter 21).

Neurogenic Paralysis vs. Myogenic or Structural Restriction of Eye Movements

Differentiation between a neurogenic paralysis and the inability of the eye to move in certain

directions of gaze because of structural anomalies involving the extraocular muscles, the conjunctiva, Tenon's capsule, or all of these, is of pivotal diagnostic and therapeutic significance. For instance, paresis of the lateral rectus muscle may limit abduction of the eye. However, a mechanical restriction involving the medial rectus such as contracture; endocrine myopathy; fracture of the medial orbital wall with entrapment of the medial rectus muscle (see Chapter 21); contracture and scarring of the conjunctiva, Tenon's capsule, or the medial aspect of the globe from a previous surgical procedure; or retroequatorial adhesions between sclera and the lateral rectus muscle (reverse leash effect) will also cause limitation of abduction. There are fundamental differences in the therapeutic approach to any of these conditions; with paresis of the lateral rectus muscle not accompanied by medial rectus contracture, surgery directed at strengthening the function of the paralytic muscle combined with weakening the action of its antagonist is the preferable method of treatment. If, on the other hand, inability to abduct the eye is caused by structural anomalies involving the medial aspect of the globe, this operation is clearly contraindicated, for it would not only fail to improve abduction but would also cause retraction of the globe with narrowing of the palpebral fissure. The surgical aim in this situation must be primarily to remove the mechanical restriction of ocular motility. *This example demonstrates the unequivocal need to separate mechanical from neurogenic causes of a paralysis before deciding on appropriate surgical management.*

The electromyogram may be of limited diagnostic value in such situations, but the equipment is rarely available nor can it be applied in pediatric patients. Other more preferable tests that can be readily performed in the physician's office or under anesthesia will clearly indicate whether a deviation is caused by passive restriction of motility or by neurogenic paralysis.

Forced Duction Test

The forced duction test (referred to also as the *traction test*), although described early by Wolf²⁷⁶ (1900), Gifford⁸² (1924), and Jaensch¹²¹ (1929), has become popular only in our time as a simple and most useful method for diagnosing the presence of mechanical restriction of ocular motility. We anesthetize the conjunctiva with several drops of 4% lidocaine hydrochloride (Xylocaine). This

solution is prepared by a local pharmacy from the commercially available ampules for intravenous and intramuscular injection, sterilized, and dispensed in ophthalmic dropper bottles. Unlike other ophthalmic local anesthetics, this drug has no visible effect on the corneal epithelium. The eye is then moved with two-toothed forceps applied to the conjunctiva near the limbus *in the direction opposite that in which mechanical restriction is suspected*. For instance, to distinguish between lateral rectus paralysis and mechanical restriction involving the medial aspect of the globe, we apply the forceps at the 6- and 12-o'clock positions and move the eye passively into abduction. If no resistance is encountered, the motility defect is clearly caused by paralysis of the lateral rectus muscle. If resistance is encountered, mechanical restrictions do exist medially and contracture of the medial rectus muscle, conjunctiva, or Tenon's capsule or myositis of the medial rectus muscle must be considered (Fig. 20-7). Occasionally, a *reverse leash effect*¹²⁵ caused by retroequatorial adhesion of a rectus muscle may restrict passive ductions (Fig. 20-8). A reverse leash effect is also created by applying a posterior fixation suture to a muscle and will enhance the effect of this operation by weakening the muscle in its principal field of action.²⁰³ *It is important not to press the globe into the orbit during the test* since it may become negative and thus lead to wrong conclusions in the presence of mechanical restrictions. When topical anesthesia is used, the patient is requested to look at his or her hand held in the direction in which the eye is moved by the forceps. This will help control the influence of eye muscle innervation during the test, which otherwise might counteract passive movement of the globe and simulate mechanical restriction when none is present. In children and uncooperative adults the test must be performed under general anesthesia and before surgery.

Various instrumentation to determine the degree of restriction quantitatively has been developed,^{176, 222, 254, 256} but none of these methods have found general acceptance for routine clinical use.

Guyton⁹³ (see also Plager^{214, 215}) modified the forced duction test (exaggerated traction test) to allow an *estimation of superior and inferior oblique muscle tightness*. To check for tightness of the superior oblique muscle the eye is grasped with toothed forceps at the 6- and 9-o'clock positions. For this test the eye *must* be pushed in the orbit as it is then elevated, adducted, and rocked

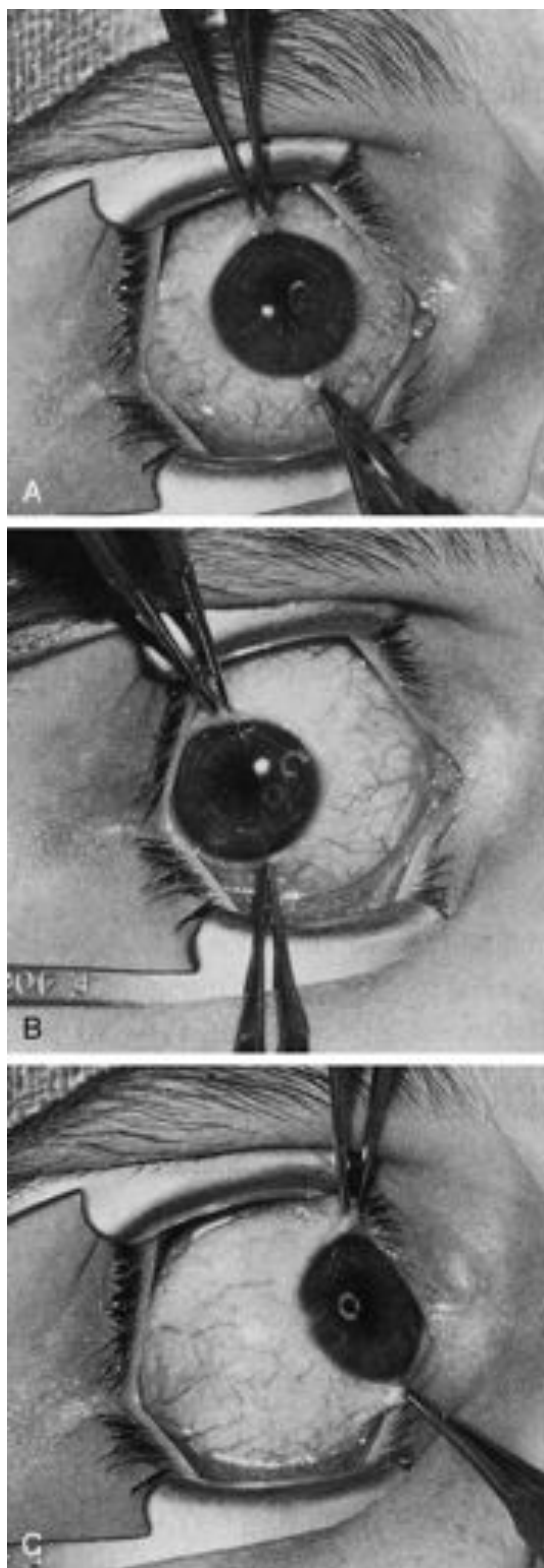


FIGURE 20-7. The forced duction test. *A*, Conjunctiva and episclera are grasped near the limbus with two fixation forceps. *B*, The eye is moved temporally and (*C*), nasally to test for mechanical restriction of ocular motility. Note that the eye must not be depressed into the orbit during the test to avoid false positives. (From von Noorden GK von: Atlas of Strabismus, ed 4. St Louis, Mosby-Year Book, 1983.)

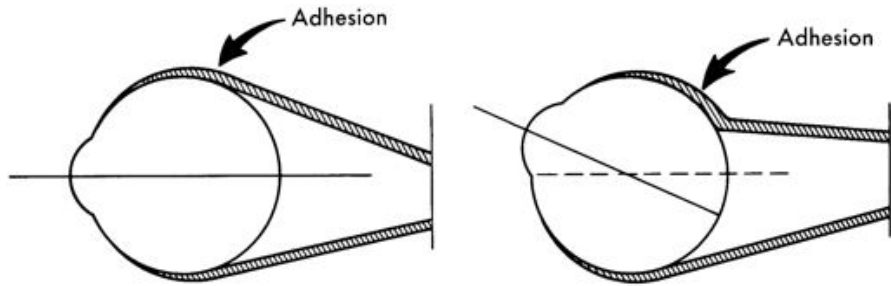


FIGURE 20-8. Reverse leash effect. Retroequatorial adhesion of superior rectus muscle causes a reverse leash effect with mechanical restriction of elevation as the ability of the muscle to stretch is limited. (Adapted from Jampolsky A: Surgical leashes and reverse leashes in strabismus surgical management. In Symposium on Strabismus: Transactions of the New Orleans Academy of Ophthalmology. St Louis, Mosby-Year Book, 1978, p 244.)

back and forth by extorting and intorting the globe across the tendon. Tightness of the tendon becomes apparent when the globe seems to “jump” across the tendon during this maneuver. The condition of the inferior oblique muscle is tested in an analogous manner by pushing the eye down and nasally.

The anesthesiologist is asked to avoid the use of succinylcholine chloride since generalized tightness of the extraocular muscles caused by this drug may simulate mechanical restriction of the globe.

Estimation of Generated Muscle Force

A. B. Scott²³⁷ has increased the scope of information to be gained from mechanical manipulation of the globe with forceps. He postulated that the active force generated by a contracting muscle can be estimated by stabilizing the eye with forceps while the patient tries to move the eye against this

obstacle. This concept had been used for many years by neurologists and orthopedists in assessing the function of other muscle systems (Fig. 20-9). Mechanical determination of muscle force can be useful in assessing the function of apparently paralytic muscles with contracture of their antagonists. For instance, with lateral rectus paresis and secondary contracture of the medial rectus muscle the movement that carries the eye from adduction toward the primary position may be merely a *passive* one, caused by relaxation of the medial rectus muscle rather than lateral rectus muscle contraction but may also be due to *active* albeit reduced innervation of the lateral rectus muscle. Since a different surgical approach is required for each condition, a simple estimate of the muscle force generated by the lateral rectus muscle can be made by stabilizing the eye in adduction with forceps while the patient attempts to abduct the eye. The presence or absence of a tug on the forceps indicates whether a contraction of the lateral rectus muscle takes place (Fig. 20-10). Scott

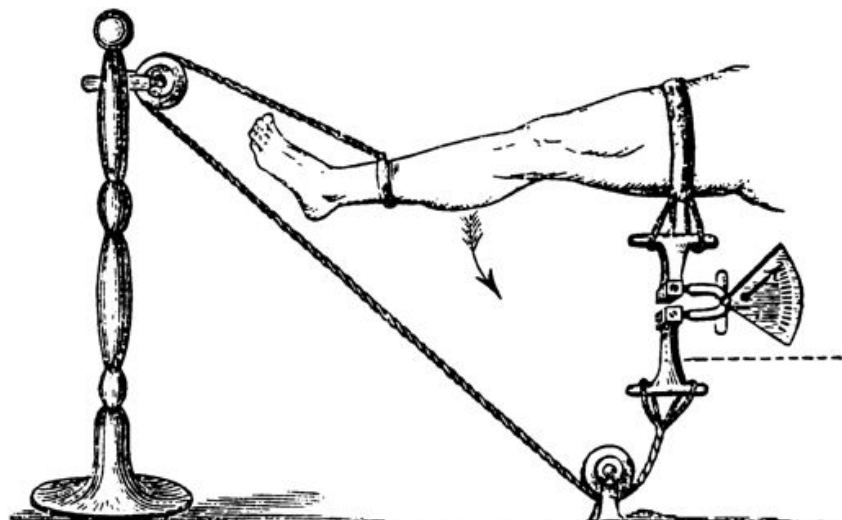


FIGURE 20-9. Illustration from Möbius' neurology textbook (1898),¹⁸⁵ showing a mechanical device for measuring the strength of flexor muscles in the leg against mechanical resistance. The same principle underlies the estimation of generated force of a paralytic extraocular muscle. (Courtesy of Dr. Amy Coburn, Houston, Texas.)

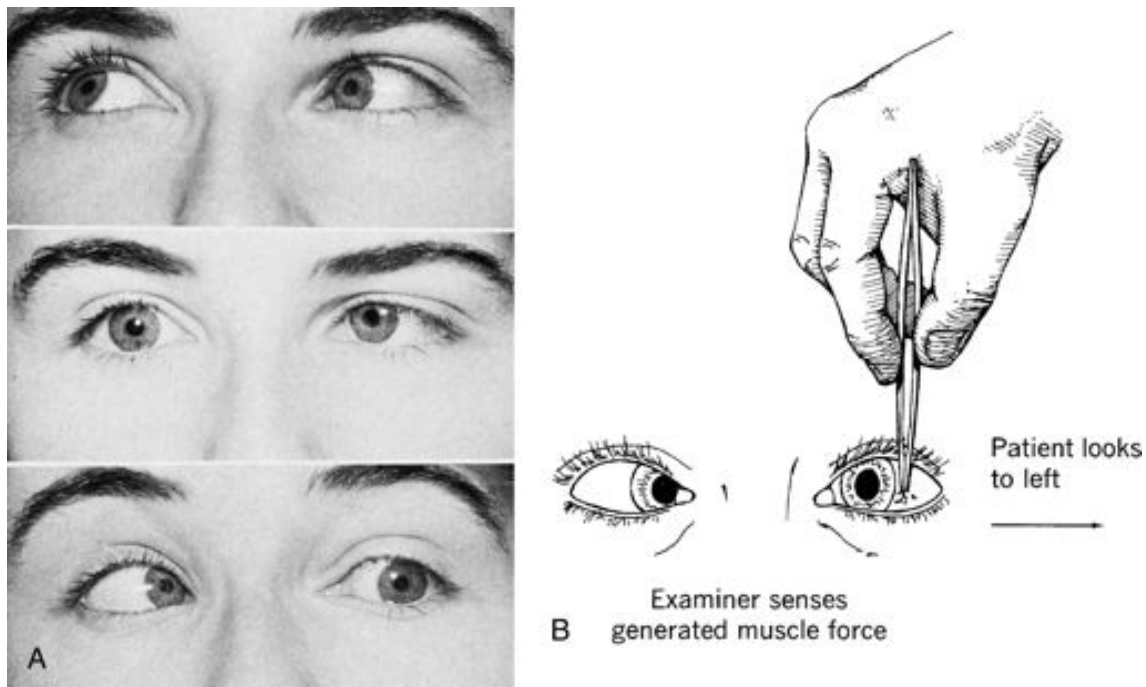


FIGURE 20-10. Estimation of generated muscle force. *A*, A patient with a left lateral rectus paresis shows movement of the left eye from adduction toward primary position on levoversion and slightly beyond. This movement may be active (residual lateral rectus innervation) or passive (medial rectus relaxation). In the first instance, maximal recession of the medial rectus and resection of the paretic lateral rectus may be indicated. In the second situation, a muscle transposition procedure may be considered. *B*, The examiner senses a tug on the forceps as the paretic eye moves from adduction toward primary position. The tug is a sign of residual innervation of the lateral rectus muscle and incomplete paralysis. Absence of the tug is a sign of complete paralysis. (From Noorden GK von: Atlas of Strabismus, ed 4. St Louis, Mosby-Year Book, 1983.)

mentions the possible use of this test in Duane's syndrome, congenital elevator paralysis, and myasthenia gravis, and attempts have been made to quantitate this test and the forced duction test using mechanical devices.^{237, 254}

Helveston and coworkers¹⁰⁵ suggested that the generated muscle force could be estimated by comparing *intraocular pressure* in various positions of gaze and reported pressure increases as high as 50 mm Hg from compression of the globe by a nonrelaxing stiff muscle when attempts were made to move the eye into the field of its antagonist.

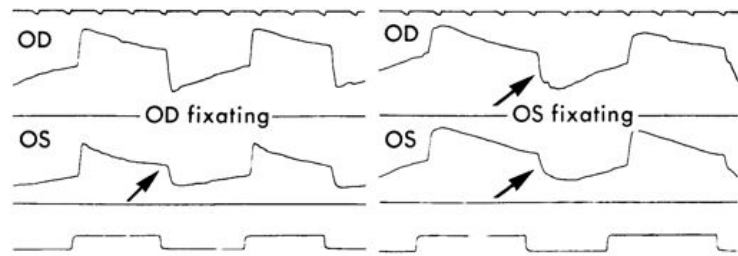
Eye Movement Velocity

The registration of eye movements by electro-oculography may be useful only as an auxiliary diagnostic method in evaluating a paralytic condition of the extraocular muscles. François and Derouck⁷⁹ were first to point out that the velocity of eye movements registered in this way may yield useful clinical information regarding severity of the paralysis and recognition of return of function during recovery. Similar studies were conducted

by Mackensen¹⁶⁶ and further pursued and applied to clinical ophthalmology by A. B. Scott and coworkers,²⁴⁰ Metz,¹⁷¹⁻¹⁷³ Metz and coworkers,¹⁷⁷⁻¹⁸⁰ W. E. Scott,²⁴² W. E. Scott and Nankin,²⁴⁵ and many others. These investigators showed that the systematic study of saccadic velocity may be useful in distinguishing between a mechanical and a paretic limitation of ocular motility. A study of saccadic velocity may be used also in conjunction with other diagnostic methods, such as the forced duction test or determination of generated muscle force, to assess the function of a paralyzed muscle. If paralysis exists, the velocity of eye movement into the field of action of the paralyzed muscle will be markedly decreased (Fig. 20-11), the normal rapid saccade being replaced by a slow, drifting eye movement. If the motility defect is caused by a mechanical obstacle, the saccadic velocity of an eye movement into the field of apparent paresis will be normal. Kirkham and coworkers¹³⁸ used saccadic velocity measurements to distinguish between bilateral abducens paralysis and divergence paralysis (see also Chapter 22).

An astute observer can detect the difference in eye movement velocities with the naked eye in

FIGURE 20-11. Electro-oculographic registration of eye movements in a patient with left cranial nerve VI paresis. Positive deflection, gaze to right. Negative deflection, gaze to left. Arrows denote decreased saccadic velocity upon gaze into the paretic field of gaze. (From Mackensen G: Okulographie. In Hamburger FA, Hollwich F, eds: Augenmuskellähmungen, vol 46. Stuttgart, Ferdinand Enke Verlag, 1966.)



many cases, thereby eliminating the need for registering eye movement.

Paralytic vs. Nonparalytic Strabismus

Throughout the preceding discussions we have emphasized features that distinguish paralytic from nonparalytic strabismus. In paralysis of recent onset, such differentiation rarely presents diagnostic problems but may become increasingly difficult and at times even be impossible with paralysis or paresis of long standing. For easy reference, the most important clinical properties of each condition are summarized in Table 20-2.

Congenital vs. Acquired Paralysis

Once the diagnosis of a paralytic deviation has been established, it is of clinical importance to determine whether it is of recent onset or has been present for many years, perhaps even since birth. If the paralysis is of recent onset, a diligent search for its cause by a complete medical and neuro-ophthalmologic evaluation is mandatory. If the strabismus has been present for many years, the

clinical management of the problem is clearly in the sphere of the ophthalmologist and a general medical evaluation usually is not indicated.

Determination of how long a paresis has been present is not always easy, since congenital or early acquired paralysis may be obscured by a compensatory head position or a strong fusion mechanism. Thus the patient may remain asymptomatic for decades before disturbing symptoms suddenly appear and medical help is sought. Old photographs are of great value, since they may reveal the presence of an anomalous head posture in early childhood (Fig. 20-12) and clearly eliminate the possibility that the paresis is of more recent onset (see Case 20-1). The most important clinical features used to distinguish congenital or old paralysis from one of more recent onset are summarized in Table 20-3.

CASE 20-1

A 45-year-old man experienced vertical diplopia of sudden onset 2 days before examination. He denied ever having seen double before. One week before

TABLE 20-2. Differential Diagnosis: Paralytic vs. Nonparalytic Strabismus

	Paralytic	Nonparalytic
Type of onset	Often sudden but may be gradual or congenital	Usually gradual or shortly after birth; rarely sudden
Age of onset	Any age	Usually during childhood
History of head trauma	Common	Uncommon
Difference between primary and secondary deviation	Characteristic finding	Absent
Diplopia	Common	Uncommon
Anomalous retinal correspondence or severe amblyopia or both	Uncommon	Common
Comitance	Only in late stages	Common
Head posture	Commonly abnormal	Rarely abnormal
Cyclotropia	Common with cyclovertical paresis	Uncommon except in A and V patterns
Neurologic findings or systemic disease	May be present	Usually absent
Past-pointing	Common with recent paralysis	Rare




FIGURE 20-12. Head tilt to the right shoulder in photographs taken at various ages of a patient with left superior oblique palsy identifies the congenital nature of the condition.

this episode he had a rather severe attack of influenza. The past medical history was otherwise negative. Examination of ocular motility revealed a right hypertropia of 25^Δ in the entire left field of gaze and 15^Δ in primary position. The patient carried his head tilted to the left shoulder, and the right hypertropia increased to 30^Δ on tilting it to the right shoulder. Examination of ductions and versions revealed marked overaction of the right inferior oblique and slight underaction of the right superior oblique muscles. These findings were compatible with a right superior oblique paresis and a secondary overaction

of the antagonist. At our request, on his return visit the patient brought a family photograph album. He was easily identified in his high-school class graduation picture as well as in several other group photographs because of his marked torticollis. Further examination revealed that he was able to overcome diplopia and to maintain comfortable single binocular vision with only 3^Δ base-down before the OD. During the ensuing months the amount of prismatic power required increased, and the patient eventually underwent surgery. The functional result was excellent, and the anomalous head posture disappeared. Head

TABLE 20-3. Differential Diagnosis: Congenital and Old Paralysis vs. Recent Paralysis

	Congenital and Old	Recent
Diplopia	Rare but may occur suddenly with decompensation	Always present but may be limited to paretic field
Image tilting	Absent	Common with cranial nerve IV palsies
Amblyopia	May be present	Absent
Comitance	Spread of comitance may obscure original paresis	Characteristically incomitant
Abnormal head posture	May persist on covering paretic eye because of secondary scoliosis and contracture of neck muscles	Disappears on covering paretic eye
Facial asymmetry	Common with torticollis of long standing	Absent
Contracture of antagonist with positive forced ductions	May be present	Absent
Past-pointing	Absent	Present
Old photographs	May show anomalous head posture	Negative

tilt early in life, the spread of comitance to the entire left field of gaze, and the highly developed vertical fusional amplitudes when the patient was first seen clearly indicated the presence of congenital or early acquired fourth cranial nerve (N IV) paresis that had recently decompensated, perhaps as a result of a reduction in general health following influenza. A neuro-ophthalmologic examination was not necessary in this circumstance.

Orbital Imaging Techniques

Demer and Miller⁶⁰ introduced quantitative magnetic resonance morphometry of extraocular muscles for use in diagnostically complex cases of paralytic strabismus. A comparison of the images from normals and patients with paralysis of the oblique and lateral rectus muscles revealed atrophy and lack of contractibility of the paralyzed muscles. The reduction in muscle size is interpreted as denervation atrophy and in the case of a lateral rectus paralysis began within 6 weeks after onset to reach a complete stage within 1 year.

Evaluation of Visual Impairment Caused by Diplopia

The reader is referred to the *Guides to the Evaluation of Permanent Impairment* published by the American Medical Association.²⁷¹

Paralysis of Individual Extraocular Muscles

If *paralysis* and *paresis* are to be defined, respectively, as a complete and partial impairment of motor function caused by a lesion of the neuromuscular mechanism, a multitude of etiologic factors must be considered in each case. The lesion may be in the muscle, at the neuromuscular junction, in the peripheral nerve, in the nuclear region, or in the supranuclear oculomotor pathways. Myogenic paralysis is caused by a disease of the muscle itself (myositis or fibrosis), by mechanical obstacles to ocular motility such as scar formation following repeated muscle surgery, or by orbital fractures with entrapment of fat, fascia, or muscle (see Chapter 21).

Impairment of motor function also may be caused by hypoplasia or congenital absence of an extraocular muscle. The literature is replete with numerous case reports.⁶³

A discussion of the prevalence and causes of paralysis of individual extraocular muscles or muscle groups is beyond the scope of this book. The reader is referred to recent textbooks on neuro-ophthalmology for detailed information. Noteworthy is the most recent and possibly largest study on the causes of paralysis of the oculomotor, trochlear, and abducens nerves, which includes 4373 acquired muscle paralyses from the Mayo Clinic.²¹⁷ According to this report (Table 20-4) paralysis of cranial nerve VI occurred most frequently (43.8%), followed in order of frequency by cranial nerves III (28%) and IV (15%). Multiple nerves were involved in 13% of the cases. In another recent study from Germany²⁰ that included 412 patients, palsies of the oculomotor nerve were most frequent, followed by cranial nerves VI and IV paralyses. In a pediatric population at the Mayo Clinic (160 cases) trauma was the leading cause of oculomotor, trochlear, and abducens paralysis, followed by neoplasm.¹⁴⁵ Data of this sort reflect the type of practice from which they were obtained. Neurologists see different types of ocular paralyses than do ophthalmologists, and pediatric ophthalmologists have different experiences in this regard than general ophthalmologists. In our practice, which is exclusively concerned with strabismus in children and adults, cranial nerve IV palsies are seen by far most commonly, followed in order of frequency by cranial nerves VI and III paralyses. This experience is exactly opposite to that reported from the Mayo Clinic¹⁴⁵ but practically identical to a recently published study of children in a defined population.¹¹⁴

Finally, it cannot be overemphasized that *any* paralysis of one or several extraocular muscles can be simulated by myasthenia gravis.

TABLE 20-4. Causes of Paralysis of Cranial Nerves III, IV, and VI (%)^{*}

Cause	N III (t = 1130)	N IV (t = 578)	N VI (t = 1918)
Undetermined	24	32	26
Head trauma	15	29	15
Neoplasm	12	5	21
Vascular	20	18	12
Aneurysm	16	0.8	0.3
Other	13	15	21

^{*}t indicates grand total.

Modified from Richards BW, Jones FR, Younge BR: Causes and prognosis in 4,278 cases of paralysis of the oculomotor, trochlear and abducens cranial nerves. *Am J Ophthalmol* 113:489, 1992.

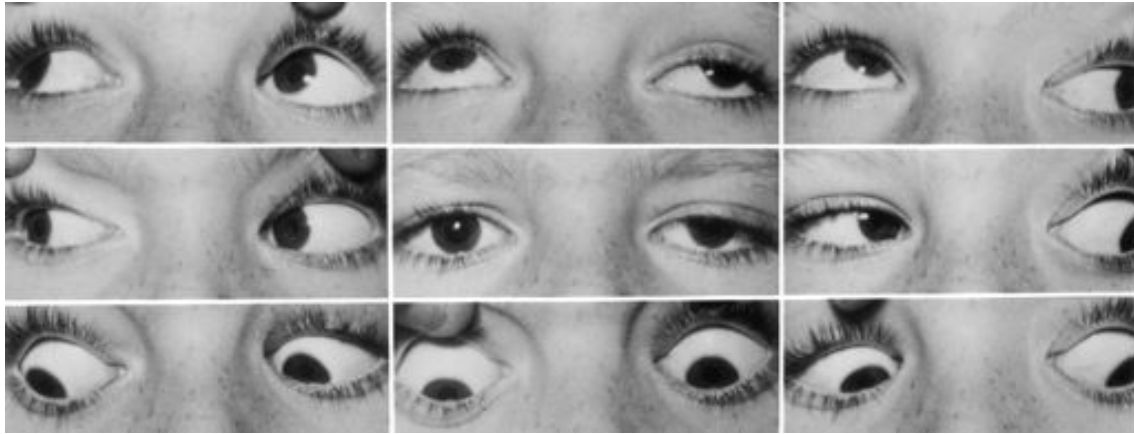


FIGURE 20-13. Paralysis of left superior rectus muscle. The patient fixates with the nonparetic eye. Note ptosis of the paralyzed eye and secondary overaction of the right inferior oblique in levoversion.

Cranial Nerve III Paralysis

SUPERIOR RECTUS MUSCLE. An isolated paralysis of the superior rectus muscle in our experience is most commonly of congenital origin. It may also be secondary to trauma, for instance, after a bridle suture during cataract surgery in which instance the elevation deficit is usually only temporary. The paralyzed eye is affected primarily in elevation and abduction. Elevation is normal in adduction. However, when superior rectus palsy has been present for long periods, elevation from primary position and adduction may also become limited (double elevator palsy; see p. 442). The ipsilateral inferior rectus and the contralateral inferior oblique muscles overact, and a small exocycloptropia usually is present. The paralyzed eye is hypotropic (Fig. 20-13) in primary position, and Bell's phenomenon is absent.

Ocular torticollis occurs frequently, but as mentioned, the position of the head is of little diagnostic significance. Even though in most patients the head is tilted toward the sound side, the opposite may occur. In persons with this type of muscle paralysis of recent onset, the face is turned upward, the chin is elevated, and the head usually is inclined toward the sound side.

Superior rectus muscle paralysis is frequently but not always associated with weakness of the homolateral levator palpebrae muscle, particularly if the paralysis is congenital. Since the upper lid elevates with elevation of the globe and droops when the eye moves downward, a true ptosis caused by levator weakness must be differentiated from *pseudoptosis* secondary to the hypotropic position of the globe. Figure 20-14 shows a patient with paralysis of the right superior rectus

and pronounced ptosis of the right eye with the nonparetic eye fixating. When the paralyzed eye fixated, the ptosis disappeared and a marked hypertropia of the nonparalyzed eye (secondary deviation) occurred.

The differential diagnosis of a superior rectus muscle paralysis includes mechanical causes that limit elevation of the eye, such as contracture, fibrosis, high myopia (heavy eye), myositis, endocrine orbitopathy, or a blow-out fracture of the orbital floor (see Chapter 21). Whenever elevation is restricted mechanically the forced duction test will be positive, and the restriction often involves the entire upper field of gaze. Rosenbaum and Metz²²⁰ reported an interesting structural anomaly simulating a superior rectus palsy. Surgical exploration revealed that the superior rectus tendon was inserted near the superior border of the lateral rectus muscle. Repositioning the superior rectus muscle to its normal anatomical position corrected the condition.

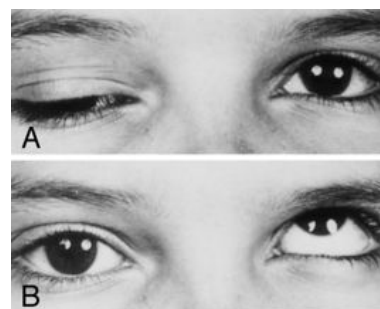


FIGURE 20-14. Pseudoptosis of the right eye in a patient with right superior rectus paresis. *A*, When the nonparetic eye fixates, the parietic eye is hypotropic and ptosis is present. *B*, The ptosis disappears, and a left hypertropia is present on change of fixation to the parietic eye.

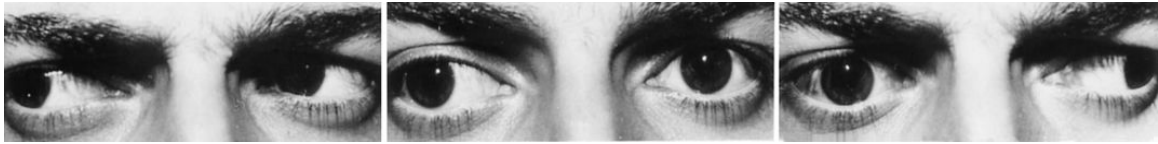

FIGURE 20-15. Right medial rectus paralysis. Exotropia in primary position and overaction of left lateral rectus muscle.

MEDIAL RECTUS MUSCLE. An isolated paralysis of the medial rectus muscle without involvement of other muscles supplied by cranial nerve III is very rare. With this type of paralysis the greatest defect of ocular motility occurs when the affected eye moves into adduction. Since the action of the antagonistic lateral rectus muscle is unopposed, an exotropia usually is present in primary position (Fig. 20-15). The patient's face turns toward the uninvolved side. The differential diagnosis of an isolated medial rectus paralysis includes *internuclear ophthalmoplegia* (see p. 441).

A rare, bizarre phenomenon referred to as *synergistic divergence*, which consists of a congenital adduction deficit with simultaneous abduction of each eye on attempted gaze into the field of action of the paralyzed medial rectus muscles, has been described in patients with congenital medial rectus paralysis.^{14; 36; 45, p.246; 280} The etiology is unknown although innervational anomalies similar to those found in Duane's syndrome have been implicated.^{52, 96} Extirpation of the ipsilateral lateral rectus muscle has been suggested to eliminate simultaneous abduction.

Other substitution phenomena in congenital and acquired supranuclear disorders of eye movements have been described.³⁹

INFERIOR RECTUS MUSCLE. An isolated paralysis of the inferior rectus muscle is often congenital in our experience. However, it may also occur following orbital trauma, especially after fracture of the orbital floor; from vascular disease; or in conjunction with myasthenia.¹⁹⁷ The diagnosis is made on the basis of the prism and cover test in the diagnostic positions and on examination of ductions and versions. The deviation is greatest on attempts to look downward with the affected eye in abduction (Fig. 20-16). The unopposed action of the antagonistic superior rectus muscle causes the paretic eye to be incyclotropic and hypertropic in primary position. When the patient fixates with the paretic eye in primary position, pseudoptosis may occur in the sound eye, creating diagnostic problems. Ocular torticollis is a frequent occurrence but is not of diagnostic value since the head may be tilted to either side.¹⁹⁷

INFERIOR OBLIQUE MUSCLE. Of all the extraocular muscles supplied by the oculomotor nerve, the inferior oblique muscle is least likely to become paralyzed. The onset is usually congenital but trauma has been mentioned as a cause. In primary position the affected eye may be hypotropic or the unaffected eye hypertropic, de-

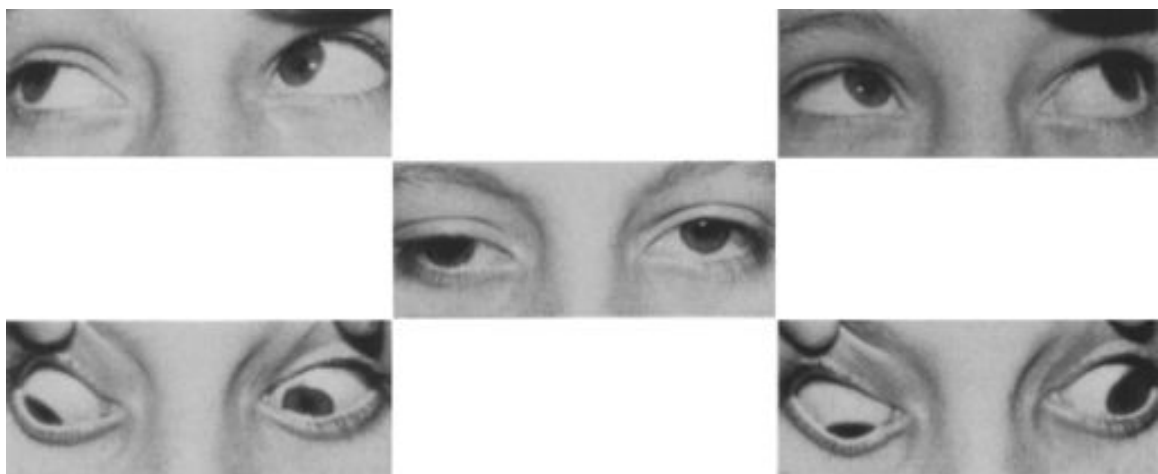

FIGURE 20-16. Left inferior rectus paralysis. The patient fixates with the paralyzed eye. Note right hypotropia and pseudoptosis in the primary position, and secondary overaction of the right superior oblique and left superior rectus muscles.

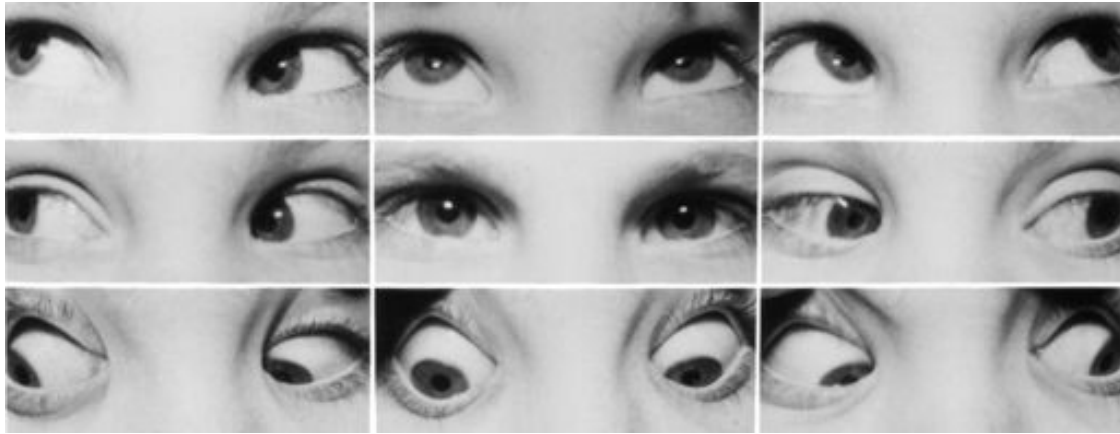

FIGURE 20-17. Left inferior oblique paralysis. Note secondary overaction of the left superior oblique and right superior rectus muscles. The forced duction test in this patient showed no restriction on attempts to elevate the left eye in adduction.

pending on whether the patient fixates with the nonparalyzed or paralyzed eye. The greatest deviation occurs when the patient attempts to elevate the adducted paretic eye³³ (Fig. 20-17). Overaction of the unopposed ipsilateral superior oblique muscle causes incyclotropia. In all patients whom we have evaluated, onset was congenital. As in the case of superior oblique paralysis, the anomalous head posture is more characteristic than in paralyzes of the vertical rectus muscles. As a rule the head is inclined toward the paralyzed side, and the face is turned toward the uninvolved side, but there are exceptions. The Bielschowsky head tilt test is positive on tilting the head toward the normal side.

The forced duction test is necessary in making this diagnosis, since the prevalence of Brown syndrome (see Chapter 21) is far greater than paralysis of the inferior oblique muscle and since the defect of ocular motility is clinically similar. However, with Brown syndrome the involved eye is frequently depressed more severely in adduction than it is with inferior oblique paralysis.

VERTICAL MUSCLE PARALYSES FOLLOWING CATARACT SURGERY. A sudden increase in vertical strabismus following cataract surgery has been reported only in recent years.^{42, 43, 59, 71, 91, 96, 118, 152, 189, 210} It consists of limitation of elevation or depression with diplopia with an onset on the day after surgery. This complication was exceedingly rare prior to the advent of local anesthesia with peribulbar injection and has occurred with increasing frequency shortly after introduction of this change in technique.⁷¹ Most authors agree that this sudden paralysis, sometimes accompanied by rapidly developing contracture of the antagonist

or segmental contracture of the paretic muscle,⁴² is caused by the myotoxic effect of the anesthetic agent or by accidental injection of the muscle belly or the nerve supplying the muscle. The *inferior rectus muscle* is most frequently involved, followed in order of frequency by the *superior rectus* and *inferior oblique muscles*. According to Esswein and von Noorden⁷¹ the following factors may contribute to this complication: the location of the injection, which is directly along the muscle belly⁵⁶; the 1.5-in. needle, which disperses the anesthetic directly over or underneath the muscle; the high concentration used by some surgeons; and repeated injections.⁷¹ To avoid this complication these authors advocated avoiding the muscle belly by injecting slightly medial or lateral to it, to use the smallest quantity and lowest concentration of the medication that is necessary to obtain anesthesia and akinesia, to inject with a short, blunt-tipped needle, and to wait for at least 30 minutes for an effect before repeating the injection. Fortunately, the results of corrective muscle surgery are excellent in these patients and complete rehabilitation can be achieved in all but a small number.^{71, 189}

Diplopia after cataract surgery caused by restriction of ocular motility in the immediate postoperative phase must be differentiated from double vision on account of sensory factors, such as loss of fusion from prolonged disruption of binocular vision in previously heterophoric patients or an increase in the angle of a preexisting strabismus.²³⁶

COMPLETE CRANIAL NERVE III PARALYSIS. When the oculomotor nerve is completely paralyzed, the position of the affected eye is deter-

mined by the function of the only two remaining intact muscles, the lateral rectus and the superior oblique muscles. Thus the paralyzed eye will be in a position of abduction, slight depression, and intorsion. Concurrent paralysis of the levator palpebrae and unopposed tonus of the orbicularis muscle will cause ptosis of the upper lid, and general relaxation of tonus of four of the six extraocular muscles may produce a small degree of proptosis. The motility of the affected eye will be limited to abduction, to small degrees of depression in abduction (which is limited by the minor contribution of the superior oblique muscle to depression in that position), to incycloduction, and to an adduction movement of the eye that does not go beyond the primary position (Fig. 20-18). With a complete cranial nerve III paralysis, the intrinsic muscles of the eye also are involved, causing the pupil to be dilated and nonreactive and a paralysis of accommodation.

During the recovery of acquired third nerve paralysis, aberrant regeneration of nerve fibers may result in failure of the upper lid to follow the eye as it moves downward or in retraction of the upper lid in downward gaze (Fig. 20-19) or adduction.

The retraction of the upper lid occasionally may be accompanied by contraction of the pupil. Because of its resemblance to Graefe's sign in thyrotoxicosis, this phenomenon, notwithstanding its entirely different nature, is referred to as the *pseudo-Graefe's sign*. The theory for this intriguing finding is that the nerve fibers originally connected with the inferior rectus muscle grow into the sheath of nerve fibers supplying the levator muscle so that the impulse to look down increases the tonus of the levator.²³ Aberrant regeneration can be congenital or acquired^{182, 227} and may occur without a preceding oculomotor paralysis in patients with a slowly growing intracavernous meningioma or with a carotid aneurysm.¹⁶⁰ Other abnormal connections between the various components of cranial nerve III have been observed during the recovery phase.²³ The reader is referred to neuro-ophthalmologic texts for further details.

One of the rarest and most interesting forms of cranial nerve III paralysis has been referred to as *cyclic oculomotor paralysis*. With this type of paralysis, some of the extraocular muscles over which the patient has lost all voluntary control contract spastically at more or less regular inter-

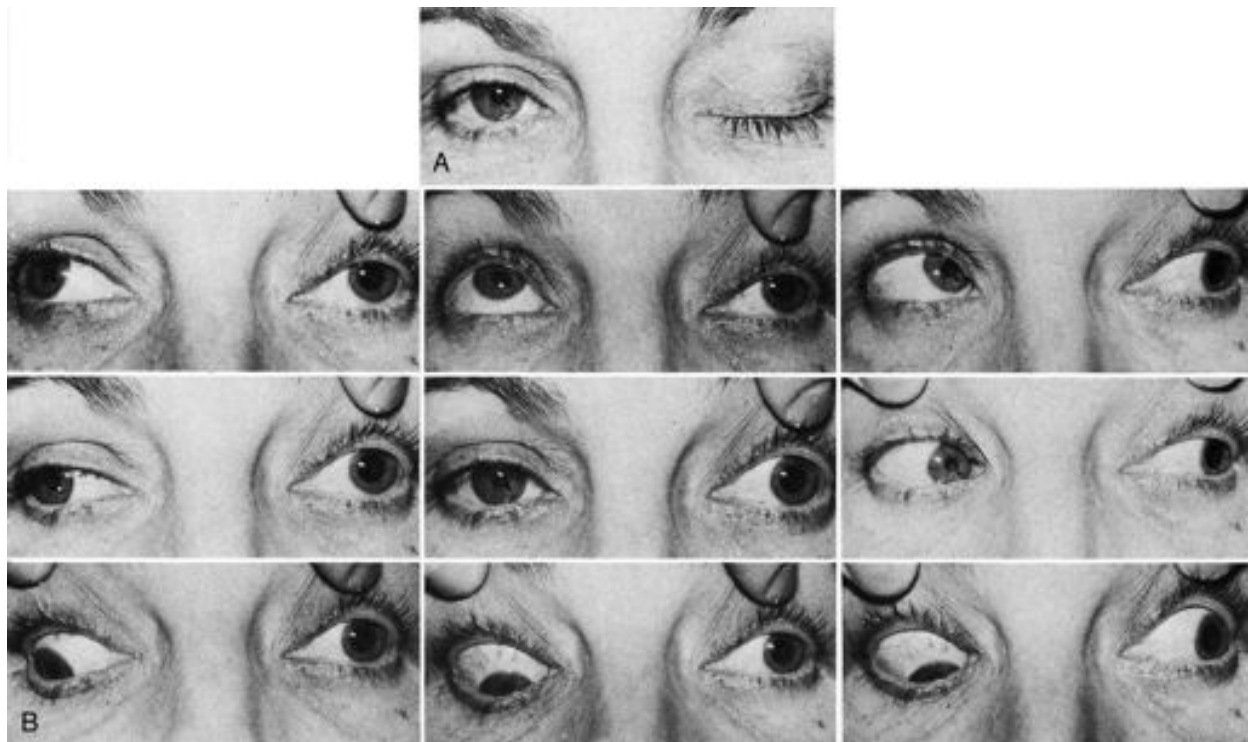


FIGURE 20-18. This patient suddenly developed a complete paralysis of the left cranial nerve III from an aneurysm of the posterior communicating artery. *A*, There is complete ptosis of the left eye and the patient was unaware of double vision unless the left upper lid was manually lifted. *B*, Note the abducted position of the left eye with the right eye in primary position; the inability to elevate, adduct, or depress the left eye; and the dilation of the left pupil. (From Noorden GK von: Atlas of Strabismus, ed 4. St Louis, Mosby-Year Book, 1983.)

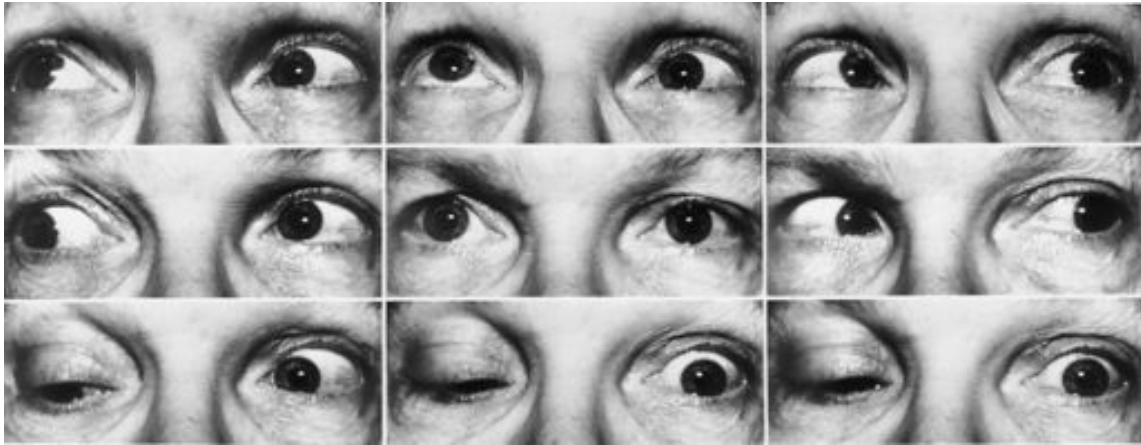

FIGURE 20-19. Aberrant regeneration in left third nerve paralysis. Note retraction of the left upper lid on downgaze and adduction. (Courtesy of Dr. John McCrary III, Austin, Texas.)

vals. The sphincter of the iris, which is essentially unresponsive to all physiologic stimuli, together with the paralyzed ciliary muscle contracts synchronously at regular intervals with the muscles supplied by the oculomotor nerve. Cyclic oculomotor paralysis usually is congenital, and the various theories for this anomaly as well as the literature have been reviewed.^{37, 38, 72, 165}

Several authors have drawn attention to the fact that congenital third nerve paralysis in children may be accompanied by diverse and often serious neurologic deficits.^{11, 94, 234, 263} Many of these can be associated with perinatal trauma. A neurologic evaluation is therefore advisable and an evaluation by neuroimaging to search for associated structural anomalies of the brain has been recommended by A. G. Lee and coworkers¹⁵⁶ who published a guide to the indications for neuroimaging in isolated and nonisolated congenital and acquired oculomotor paralysis.

Cranial Nerve IV Paralysis

ETIOLOGY. In our practice superior oblique paralysis is the most common form of paralytic strabismus. In a review of 270 patients with superior oblique paralysis treated by us during a 10-year period, a congenital paralysis was encountered most often (39.5%). This was followed in order of frequency by traumatic (34%), idiopathic (23.2%), and neurologic (2.9%) paralyzes.²⁰² This etiologic distribution is similar to that reported by other strabismologists,^{67, 136, 142} but differs in a neuroophthalmologic practice where trauma and vascular disorders predominate and congenital paralysis is only infrequently diagnosed.²¹⁷ Blunt head

trauma, often only a mild concussion without loss of consciousness, is among the most frequent causes, but direct injury to the trochlea^{143, 159} or to the tendon during blepharoplasty²⁷³ has also been reported. Congenital superior oblique paralysis may also follow an autosomal dominant mode of inheritance²⁹ but this occurrence is rare. It is of historical interest that in the preantibiotic era iatrogenic damage to the trochlea during ethmoidectomy was probably the most common cause of a cranial nerve IV palsy.

A superior oblique paralysis of sudden onset and without a history of trauma, while in most instances caused by spontaneous decompensation of a congenital paralysis, may also signal an intracranial process.^{17, 49, 151} Myasthenia gravis²²⁶ and multiple sclerosis¹²⁰ may present as an isolated unilateral superior oblique paralysis with an insidious onset and may, therefore, easily be confused with a congenital paralysis. Of 221 cases with trochlear paralysis 6 patients had a unilateral recently acquired cisternal schwannoma of the trochlear nerve as diagnosed with neural imaging.⁷² None developed additional symptoms or signs of cranial nerve or central nervous system involvement.

Helveston and coworkers¹⁰⁸ drew attention to the fact that *the superior oblique tendon is different in congenital as compared to acquired paralysis*. A redundancy of the tendon or an abnormal posterior insertion of the tendon into Tenon's capsule was noted in most congenital but not in acquired palsies, and Plager^{214, 215} confirmed the *laxity of the tendon in congenital cases* at the time of surgery by traction testing of the superior oblique. Slight ultrastructural differences in supe-

rior oblique tendons from patients with congenital and acquired paralyses have been observed¹⁰⁸ and the question arose whether patients with the congenital variety have a true paralysis of that muscle. This speculation gained further substance by the findings of Tian and Lennerstrand²⁶⁰ who reported that the peak saccadic velocity of the eye during downward movement in adduction was more reduced in acquired than in congenital paralysis.

On the other hand, magnetic resonance imaging (MRI) of the superior oblique muscle has shown a more pronounced volume reduction of the muscle in congenital vs. acquired cases.^{1, 231, 232} Whether this constitutes a denervation atrophy or represents a primary anomaly, as suggested by Sato,²³¹ is not clear at this time. Be this as it may, the recognition of differences in the physical characteristics of the tendon in congenital and acquired cases has important therapeutic implications (see p. 450).

We discussed in Chapter 18 that apparent oblique dysfunction, including decreased depression in adduction, may actually be caused by heterotopic muscle pulleys.⁴⁷ MRI may be of help in differentiating true from pseudoparalysis of the superior oblique muscle.⁶⁰ In the latter instance the volume and the contractile function of the muscle will be normal.

SYMPTOMS. The symptoms of superior oblique palsy may consist of *asthenopia*, *vertical diplopia*, *image tilting*, and an *anomalous head posture*. The question arises whether the presence or absence of diplopia, with or without image tilting, is a helpful symptom in distinguishing between recently acquired and congenital paralysis. It is essential to determine the age of onset whenever possible since a recently acquired superior oblique palsy of nontraumatic origin requires a medical workup. Conversely, when the onset is clearly congenital, treatment, if indicated, may commence without further evaluation of the patient by costly and unnecessary procedures. Although vertical diplopia occurred in our series more commonly in patients with acquired superior oblique palsy, 25% of patients with congenital palsy also complained about diplopia. Therefore, the presence or absence of diplopia is not a reliable sign in determining the onset. However, image tilting as an isolated symptom or combined with vertical diplopia occurred only in acquired paralysis and thus emerges as a valid differential diagnostic criterion.²⁰² We

do not know of one instance of congenital paralysis in which a patient was aware of image tilting under casual conditions of seeing. This should not distract from the fact that after dissociation of the eyes with Maddox rods, cyclotropia can be diagnosed in congenital cases as well because cyclofusion or other sensory or psychological mechanisms to eliminate image tilting under casual conditions of seeing are disrupted with this test (see Chapter 18).

Excyclotropia, when measured with the Maddox double rod test, may occur in the *nonparalyzed eye* in patients who habitually fixate with their paralyzed eye because of a monocular sensorial adaptation to the cyclodeviation that has taken place in that eye.²⁰⁸

DIAGNOSIS. Diagnosis of superior oblique paralysis is based on the presence of a hypertropia, usually greatest in the nasal field of the involved eye, but not necessarily in the field of action of the paralyzed muscle. Overaction of the unopposed antagonistic inferior oblique commonly causes the hypertropia to be greatest in the field of action of that muscle. Kommerell and coworkers¹⁴⁷ described two most unusual patients with the clinical signs of superior oblique palsy who were able to vary their vertical angle of strabismus at will.

In view of the difficulties encountered by the student of ocular motility in diagnosing a superior oblique paralysis and in view of its being confused with a superior rectus paralysis of the fellow eye and its high prevalence, the principal diagnostic and clinical features in a patient with a left superior oblique paralysis are shown in detail in Figure 20–20. With a spread of comitance and with secondary contracture of the ipsilateral superior rectus muscle, the hypertropia may involve the entire lower field of gaze. This contracture of the superior rectus is easily diagnosed with the forced duction test and may cause *pseudo-overaction of the superior oblique in the uninvolved eye* (secondary deviation).^{124, 202, 248} Knapp¹⁴² and Knapp and Moore¹⁴³ introduced a classification that describes the most common manifestations of superior oblique paralysis. Although modifications of this classification have been suggested^{108, 243, 244} we have adopted Knapp's as being the practical one. Depending on the magnitude of hypertropia in the diagnostic positions of gaze, seven classes are distinguished.

A description of each class and its prevalence

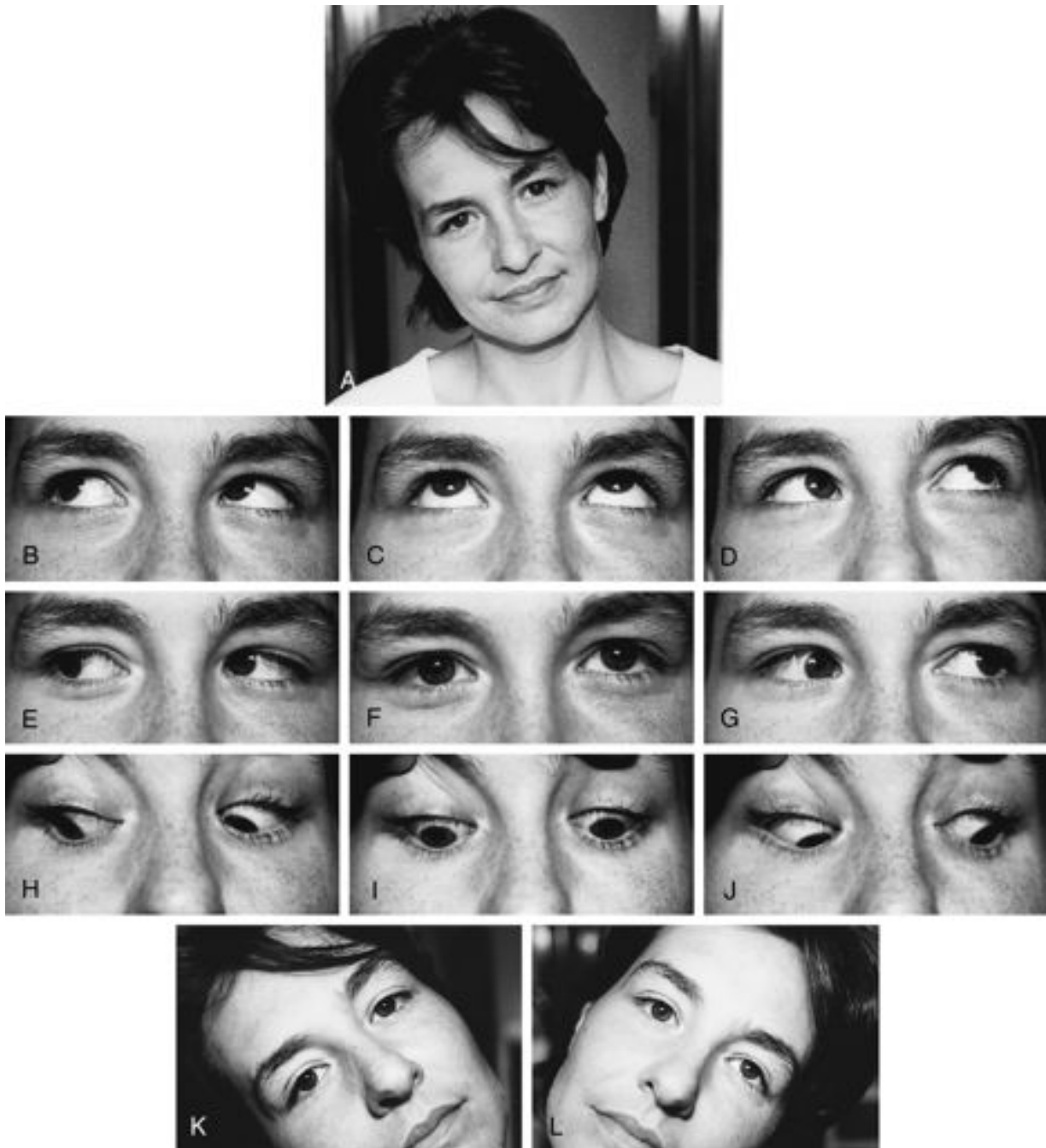


FIGURE 20-20. Clinical findings in a patient with a long-standing traumatic left superior oblique paralysis. The head is tilted to the right shoulder and the face is slightly turned to the right (A). In primary position this patient had a left hypertropia of 20 prism diopters (F), increasing to 30 prism diopters in dextroversion (E), with the greatest deviation (35 prism diopters) when the patient was looking up and to the right (B). The hyperdeviation was also present in the left field of gaze (D, G) where it measured 10 prism diopters (spread of comitance). Note secondary overaction of the left inferior oblique muscle (B, E) and only minimal limitation of depression when looking down and to the right (H). The Bielschowsky head tilt test is diagnostic for a left superior oblique paralysis with increase of the left hypertropia on tilting the head to the left shoulder (K, L).

in a group of 202 patients seen in our practice in whom preoperative diagnostic positions could be determined on the deviometer is presented in Table 20-5.²⁰² The right eye is used here as an example. Examples: in class 1 the hypertropia is greatest when the right eye is elevated and adducted (27% of our patients). The deviation is categorized as class 3 when it is of equal magnitude in the entire paralyzed field of gaze (21% of our patients).

Whereas the distribution of hypertropia in the different gaze positions may vary because of a spread of comitance, an exception exists in class 7. In these patients a classic superior oblique paralysis is associated with restriction of elevation in adduction (*pseudo-Brown syndrome*) and direct trochlear trauma is the cause. Knapp and Moore¹⁴³ mentioned dog bites as a common cause, to which we add frontal sinus surgery.

Auxiliary diagnostic features include a *positive Bielschowsky head tilt test*, which is nearly always present and a head tilt toward the nonparalyzed side, which is present in only approximately 70% of the patients.²⁰² Burian and coworkers³⁸ explained the absence of a head tilt by the patient's inability to obtain single binocular vision by any vicarious head position, by the presence of large fusional amplitudes, or by reduced visual acuity in one eye. However, we have been unable to confirm this since visual acuity of each eye, the ability to fuse in primary position, and the magnitude of hypertropia and cyclotropia were the same in patients with and without a head tilt.²⁰² Of







special interest are patients with a *paradoxical head tilt* toward the paralyzed side. Whereas this occurred in only 7 of 270 patients,²⁰² unawareness of the existence of a paradoxical head tilt may easily confound the diagnosis. A comparison of the clinical findings obtained in patients with a paradoxical head tilt and in those with a head tilt that "conformed to the rule" showed that in the former group intermittent and unstable fusion was present with the head tilted toward the uninvolved side, but alternating suppression and diplopia occurred when holding the head toward the paralyzed side.²⁰² Thus these patients preferred a head position that disrupted fusion, caused a wide separation of the double images, and thus eliminated the discomfort that may have been associated with the constant effort to maintain single binocular vision in the presence of a superior oblique weakness.

Unless a history of recent trauma or old photographs clearly establish the traumatic or congenital nature of a superior oblique paralysis, the clinician may be in a quandary in deciding whether to order neuroimaging. A recently established guide for the cost-effective evaluation of patients with superior oblique paralysis indicates that isolated congenital, old traumatic, or vasculopathic cases do not require neuroimaging.¹⁵⁵ Patients with nonisolated palsies require directed neuroimaging studies based upon the results of the nonocular symptomatology.

CONGENITAL ABSENCE OF THE SUPERIOR OBLIQUE MUSCLE. This mostly unexpected finding at the time of surgery presents a special challenge to the surgeon. Only in rare instances is this anomaly diagnosed prior to the operation. Helveston and coworkers¹⁰⁷ noted the association of amblyopia and of a horizontal deviation in these cases. To this we added a large hypertropia in primary position, spread of comitance, and pseudo-overaction of the contralateral superior oblique muscle as additional clinical features.²⁶⁸ Neural imaging may demonstrate congenital absence of the superior oblique muscle preoperatively and thus facilitate planning of effective surgical correction.

SPONTANEOUS LIMITATION OF ELEVATION (BROWN SYNDROME) FOLLOWING ACQUIRED SUPERIOR OBLIQUE PARALYSIS. The first patient with this intriguing anomaly following mostly traumatic superior oblique paralysis was described by Fox⁷⁷ in 1981 and not more than 12

TABLE 20-5. Classification According to Amount of Hypertropia in Diagnostic Positions (N = 202)

Class	Pattern	No. (%)
1		55 (27%)
2		62 (31%)
3		43 (21%)
4		7 (3%)
5		12 (6%)
6	Bilateral	22 (11%)
7		1 (0.5%)

other cases have been reported since.^{192, 235, 249} The onset of limitation of elevation in adduction is gradual, progressive, and may mimic Brown syndrome (see Chapter 21). The forced duction test was positive in some but not in all patients. The etiology is entirely speculative and fibrotic reaction of the superior oblique tendon or adjacent structures²³⁵ or a secondary contracture of the tendon¹⁹² have been mentioned.

UNILATERAL VS. BILATERAL PARALYSIS. It is most important to carefully examine the patient for involvement of the fellow eye when superior oblique paralysis is of traumatic origin. Bilateral involvement was present in 19 (21%) of 92 traumatic cases observed in our clinic,²⁰² which is in contrast to the 88% of cases reported by other observers.¹⁹³ The severity of the paralysis is often asymmetrical, and the involvement of the second eye may not become apparent until the eye with the more severe defect has been operated on (masked bilateral superior oblique paresis).^{109, 117, 148, 153, 264} A right hypertropia in left gaze and a left hypertropia in right gaze, as well as a positive Bielschowsky test with the head tilted to either side, are the only signs we consider *diagnostic* for bilateral involvement because neither occurred in unilateral cases.²⁰² However, absence of these two features does *not* exclude bilateral involvement.

Several authors have stated that when *excyclotropia* is in excess of 10° to 15° a bilateral paralysis should be suspected.^{67, 149, 183} However, in reviewing 203 patients with unilateral and bilateral paralysis we were unable to confirm this widely held view: the mean excyclotropia was 7° (range, 1° to 25°) in patients with unilateral and 8° (range, 3° to 20°) in patients with bilateral paralysis.²⁰² Kushner¹⁵³ added *bilateral objective excyclotropion of the globes* on fundus examination as another sign in distinguishing unilateral from bilateral paralysis. It has been claimed that bilaterality should be suspected when excyclotropia increases significantly in downward gaze.¹⁴⁰ However, it is our experience that this occurs also in unilateral cases. Since the etiology of bilaterality of the paralyzes is often traumatic the cyclotropia may be symptomatic.

A significant V pattern (15Δ or more difference between upward and downward gaze), commonly accompanied by chin depression, occurred in 48% of our patients with bilateral, but also in 5% of patients with unilateral paralysis.²⁰² The V pattern is caused by a decrease in the abducting effect of

the superior oblique(s) in depression and overaction of the inferior oblique muscle(s) and may be accompanied by chin depression.

Finally, in patients with bilateral paralysis the vertical deviation in primary position is usually smaller than with unilateral involvement since the loss of the depressing function in one eye tends to balance the same loss in the fellow eye.^{136, 202} The differential diagnostic points between unilateral and bilateral involvement are summarized in Table 20–6.

Ellis and coworkers⁶⁸ made the interesting observation that surgical overcorrection of a unilateral superior oblique paralysis may masquerade as an apparent contralateral superior oblique paresis.

PARALYSIS VS. PSEUDOPARALYSIS. Premature unilateral stenosis of the coronal sutures (*plagioccephaly*) may cause a pseudoparalysis of the superior oblique muscle with upshoot in adduction because of desagittalization of the planes of these muscles.^{10, 218a} The retroplacement of the trochlea in these cases increases the angle between the reflected part of the superior oblique tendon and the plane of the inferior oblique muscle (Fig. 20–21). This reduces the vertical effect of the superior oblique muscle while increasing its incyclotorsional effect and causes an imbalance of opposing muscle forces in favor of the inferior oblique muscle.

Figure 20–22 shows the rather characteristic appearance of a patient with premature closure of the left coronal suture and marked hypertropia of the left eye.

Limón de Brown and coworkers¹⁶³ studied with anthropometric methods the relationship between orbital malpositioning and strabismus in plagiocephalic children and established a quantitative

TABLE 20–6. Diagnosis of Bilateral Superior Oblique Paralysis

“Hard” Signs	“Soft” Signs
RHT in left gaze LHT in right gaze	Often of traumatic origin with symptomatic cyclotropia
Bielschowsky head tilt test positive to either side	Objective excyclotropia of both fundi V-pattern esotropia Chin depression Vertical deviation in primary position is usually smaller than in unilateral palsies

LHT, left hypertropia; RHT, right hypertropia.

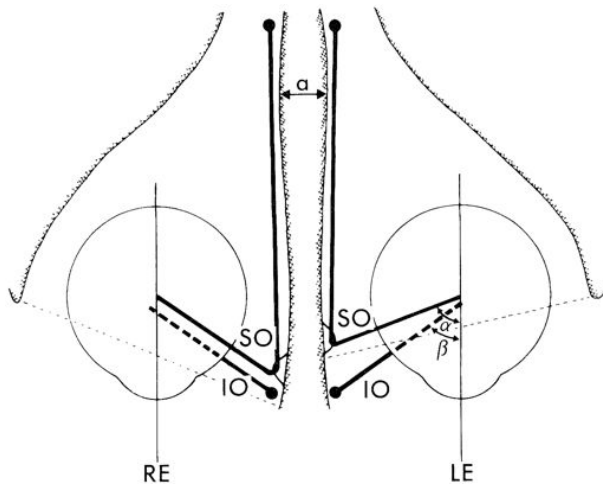


FIGURE 20-21. Left plagioccephaly. Recession of the left trochlea reduces the length of the unreflected part of the left superior oblique (SO) muscle thus decreasing its contracting power and causing imbalance in relation to the contracting power of the ipsilateral inferior oblique (IO). Angle alpha is greater than angle beta, causing diminished vertical effect of SO. RE, Right eye; LE, left eye; a, distance between the sagittal axis of two muscles in orbit. (From Bagolini B, Campos EC, Chiesi C: Plagioccephaly causing superior oblique deficiency and ocular torticollis. A new clinical entity. *Arch Ophthalmol* 100:1093, 1982.)

correlation between the degree of orbital anomalies (vertical displacement, intorsion, and fronto-disclination) and the hypertropia in the nasal field of the involved side.

Cranial Nerve VI Paralysis

The diagnosis of cranial nerve VI paralysis should not present any difficulties. The greatest esotropia occurs on attempts to abduct the paretic eye; with maximal innervational effort the palpebral fissure may widen in abduction. Most patients will com-

plain about double vision in lateral gaze and assume a compensatory face turn in the direction of the paralyzed muscle (Fig. 20-23). However, a face turn may be absent, and amblyopia presents a risk in young children with this condition.⁸ Because of the unopposed action of the antagonistic medial rectus muscle, esotropia will be present with the fixating eye in primary position. The differential diagnosis includes the Duane *retraction syndrome* (see p. 458) and, with congenital esotropia, pseudoabducens paralysis simulated by *crossed fixation* (see p. 200) and the *nystagmus blocking syndrome* (see p. 512). In *bilateral paralysis* both eyes may be in a position of adduction and the patient may have problems ambulating unless one eye is occluded (Fig. 20-24). Milder forms of bilateral cranial nerve VI paresis may occasionally be confused with *divergence paresis* (see p. 505). In the former the esotropia increases upon looking to the right or the left.

Several recent studies have addressed the natural history of acquired abducens paralysis. In a retrospective study of 213 nontraumatic unilateral cases 78% experienced spontaneous recovery, 73% having recovered by 24 weeks.¹³⁷

A prospective study investigated the natural history of acute traumatic unilateral and bilateral cranial nerve VI palsies.¹¹³ In a total of 33 patients spontaneous recovery occurred in 84% of the unilateral and in 25% of the bilateral palsies.

BENIGN AND RECURRENT ABDUCENS PALSY OF CHILDHOOD.

A benign and often recurrent^{24, 216, 255, 272} form of cranial nerve VI palsy occurs in children^{4, 144, 224, 266} (but has also been described in adults⁹⁸), usually following upper respiratory infections or other forms of mild viral illness,

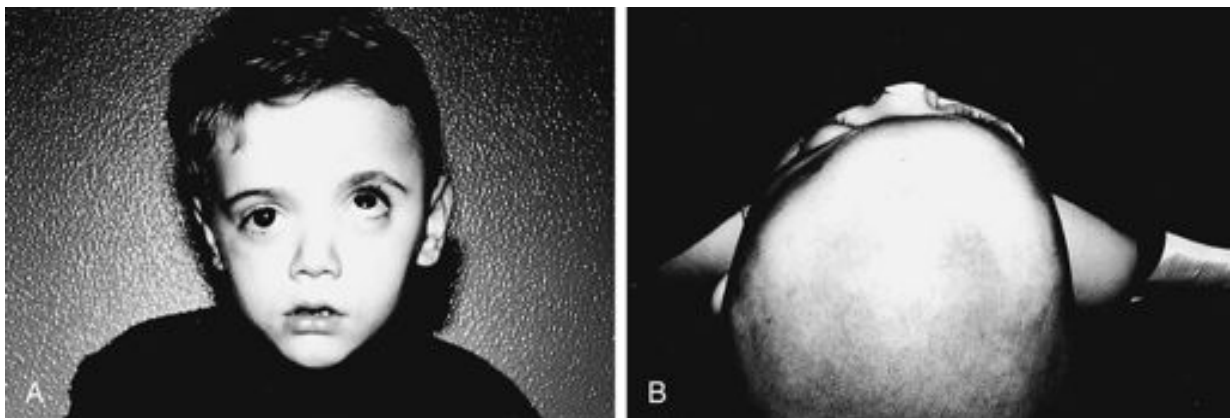


FIGURE 20-22. Left plagioccephaly. A, Note left hypertropia and facial asymmetry. B, View from above (photographed at an earlier age) shows recession of left frontal region and relative protusion of OS.

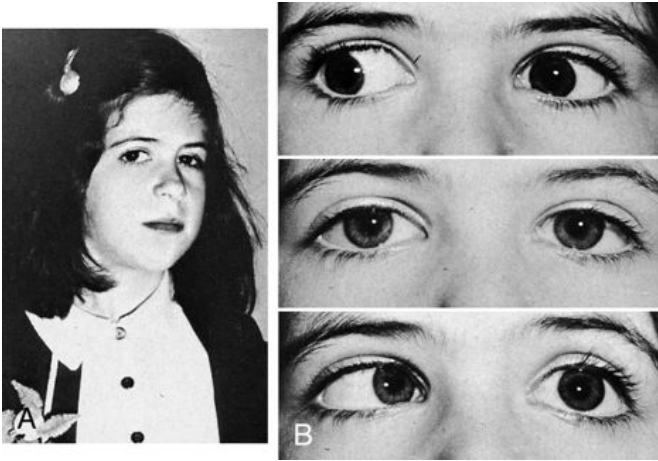


FIGURE 20-23. Paralysis of the left lateral rectus muscle. Note face turn to the left (A) and inability to abduct the left eye beyond the midline (B). This patient had orthotropia in right gaze and had an esotropia of 15 Δ in primary position which increased to 45 Δ in left lateral gaze. (From Noorden GK von: Atlas of Strabismus, ed 4. St Louis, Mosby-Year Book, 1983.)

immunizations, or impetigo.²⁶ The patients usually recover in 3 to 4 months without developing any other neurologic signs or symptoms. Amblyopia prophylaxis is essential in children up to 4 years of age who acquire this condition. When pondering the diagnosis of benign cranial nerve VI paralysis we must remember that spontaneous remission of cranial nerve paralysis may also occur in children and adults with skull base tumors.²⁶⁷

MÖBIUS SYNDROME. *Congenital bilateral abducens paralysis associated with facial diplegia and microglossia* (Fig. 20-25) constitutes a syndrome named after the German neurologist Paul J. Möbius to whom we owe the first description of this entity in 1888.¹⁸⁴ Unlike in the patient shown in the figure various degrees of esotropia may be present in primary position and the abducens paralysis may be incomplete or asymmetrical. The etiology seems to be multifactorial. An association with a midline defect,²¹³ pituitary dwarfism,¹⁰¹ and hypogonadic hypogonadism,³⁰ and a variety of *brain stem anomalies*^{80, 164} may exist that may be associated with involvement of other neural

structures.¹⁶¹ A *vascular insult* involving disruption of the embryonic subclavian artery supply during the sixth week of gestation presumably causing damage to the affected neural tissue has been proposed.²²⁹ Indeed, much evidence points toward a hypoxic or ischemic insult during early gestation and the syndrome has appeared in association with maternal benzodiazepine⁵¹ and thalidomide ingestion⁶⁹ during pregnancy. Of 23 patients with Möbius syndrome from the Royal Alexandra Hospital for Children in Sydney, Australia, 10 had a history of a potentially noxious event in utero⁸¹ (see also Miller and Strömland¹⁸¹).

However, *genetic factors* may also play a role, since autosomal dominant, autosomal recessive, and X-linked inheritance, as well as a deletion in chromosome 1317 have been reported in patients with the syndrome.^{57, 62, 229} *Acquired Möbius syndrome* was observed in a patient treated with surgery and radiation for a medulloblastoma of the rostral portion of the cerebellar vermis²³³ and a primary *mesodermal dysplasia of the extraocular musculature* has also been implicated.²⁶¹

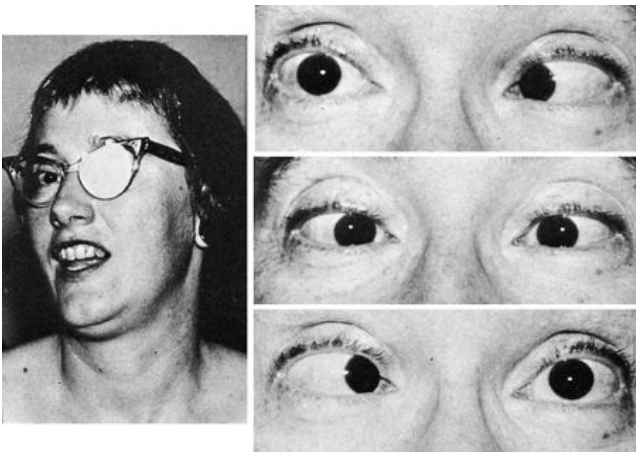

FIGURE 20-24. Bilateral sixth nerve (N VI) paralysis. This patient had a congenital right N VI palsy for which she had compensated with a face turn to the right. She then suffered a traumatic left N VI palsy and could no longer avoid diplopia by turning her head. Occlusion of the left eye enabled her to get around with a severe face turn until surgical correction was performed. (From Noorden GK von: Atlas of Strabismus, ed 4. St Louis, Mosby-Year Book, 1983.)

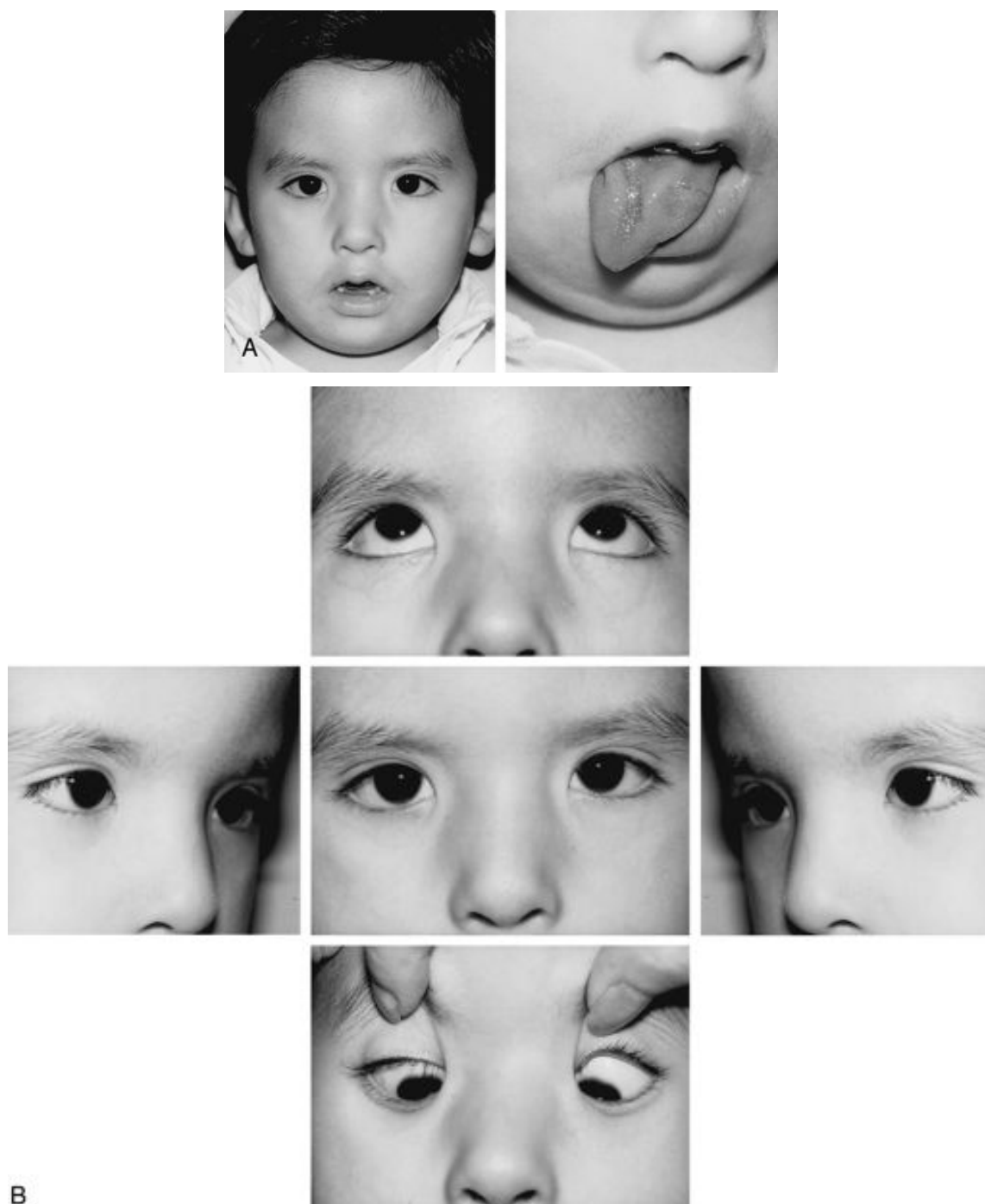


FIGURE 20-25. Möbius syndrome. *A*, Note lack of facial innervation causing a masklike expression of the face and hypoplasia of the left side of the tongue. *B*, Normal elevation and depression with V-pattern esotropia in downward gaze but inability to abduct either eye. (Courtesy of James W. Shigley, C.R.A., Cullen Eye Institute, Houston, TX.)

Miller and Strömmland have reviewed the recent literature on Möbius syndrome, which they feel is better described as *Möbius sequence*, the term *sequence* being defined as a “cascade of secondary events after an embryonic insult from heterogeneous causes.”¹⁸¹

Surgery is useful in some patients with esotropia in primary position. Large recessions of both medial rectus muscles,^{131, 251, 270} a combined recession-resection operation,¹⁷⁰ or muscle transpositions^{110, 170} have been recommended. For a more detailed discussion of the treatment of complete and partial abducens paralysis, see page 446.

Skew Deviation

A transient vertical divergence of the eyes, whereby one eye is elevated and the other depressed, may occur in association with brain stem, cerebellar, or vestibular disease. As a rule, the hypotropic eye is ipsilateral to the affected side; but variations occur, and this deviation has no consistent localizing or lateralizing value. Skew deviations are caused by damage to the tonic otolith-ocular pathways¹³³ of the brain stem tegmentum, the cervicomedullary junction, or both.⁹⁷ However, they can also be elicited in normal subjects by stimulation of the semicircular canals.¹²⁸ The presence of ocular torsion in skew deviations associated with brain stem infarctions has been emphasized.³¹ Skew deviations are not always comitant but may vary in different positions of gaze.⁹⁷ Upshoot of the adducted eye and downshoot of the abducted eye in skew deviation may easily be confused with overaction of the oblique muscles. The differentiation of skew deviations from a cyclovertical muscle palsy may be difficult and made possible only by associated signs of brain stem disease and the absence of midbrain and peripheral nerve disease.^{50, p.135} Lengthening of the superior oblique tendon¹⁶⁷ and extraocular muscle injection with botulinum toxin¹⁹⁴ have been reported to eliminate diplopia in skew deviations.

Double Elevator Paralysis

An apparent paralysis of both elevator muscles (superior rectus and inferior oblique muscles) is an unusual anomaly of ocular motility which was first described by Dunlap.⁶⁴ When the patient fix-

ates with the nonparetic eye, the paretic eye will take a hypotropic position and the upper lid may be slightly ptotic (Fig. 20–26). Fixation with the paretic eye will cause a hypertropia of the nonparetic eye, and ptosis may disappear, provided the levator palpebrae is not involved. Elevation of the paretic eye from any position of gaze is severely restricted, hence the term *double elevator palsy*. Bell’s phenomenon is usually preserved²⁰⁶ (see Fig. 20–26) but may also be absent. The ductions of the paretic eye are normal in all other positions of gaze. The chin is usually elevated. This anomaly is often congenital and has been reported in identical twins.¹⁸ However, Jampel and Fells¹²² observed seven patients with an acquired form. All were adults with rapid onset of paresis or paralysis of elevation of one eye unaccompanied by ptosis. Diplopia was present in upward gaze, and in some patients associated anomalies of the pupils and other extraocular muscles were present. These authors postulated that monocular elevation paresis could be attributed to a unilateral lesion in the pretectum, probably as a result of occlusion of one of the fine blood vessels supplying this area (see also Lessel¹⁶² and Ford and coworkers⁷⁶).

The findings of Ziffer and coworkers,²⁷⁹ who reported upgaze saccadic velocity to be normal below but not above the midline also suggests a *supranuclear elevation insufficiency*. Acquired monocular elevation deficiency has also been reported in a child with a pituitary mass lesion (pineocytoma).¹⁸⁹ These reports suggest that neuroimaging is advisable in all patients with acquired elevation deficiency of either eye.

The *etiology* of this condition is obscure, especially if one accepts the view of Warwick,²⁶⁹ that the nerve fibers to the superior rectus muscle are crossed and those to the inferior oblique muscle are not and that both muscles are innervated by different branches from the oculomotor nerve (see Chapter 3). Indeed, one must consider the distinct possibility that the frequently used term *double elevator paralysis* is a *misnomer* and that generalized weakness of elevation is caused by a *superior rectus palsy of long standing*, the deviation having spread throughout the entire upward field of gaze and the inferior rectus having become contracted. In support of this is the view¹²⁶ that the superior rectus muscle is the principal elevator not only in abduction and primary position but also in adduction.²⁷ Against this theory and more in accord with a supranuclear lesion would be the finding that *Bell’s phenomenon* is often preserved (see

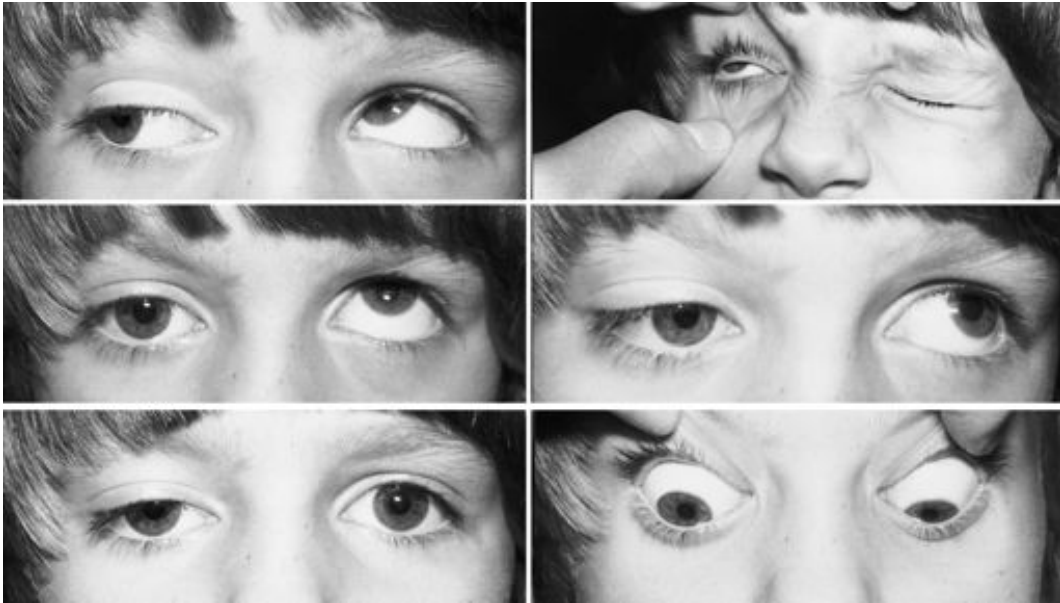

FIGURE 20-26. Apparent paralysis of both elevating muscles of the right eye. In the primary position the palsied eye is hypotropic, and there is pseudoptosis when the left eye is fixating. Large left hypertropia (secondary deviation) appears when the patient fixates with the right eye (*middle*). There is limitation of elevation in all fields of gaze. Intact Bell's phenomenon in this patient indicates the presence of superior rectus innervation. Forced ductions (*top*) were negative.

Fig. 20-26). This would indicate that the superior rectus muscle is not paralyzed. An absence of Bell's phenomenon could be explained on the basis of inferior rectus muscle tightness. The results of MRI of the extraocular muscles in patients with apparent paralysis of both elevating muscles have added little to clarify the etiology. While one group of authors reported normal superior rectus volume in their patients,²⁰⁶ another study⁴⁰ described the opposite: volume changes in that muscle that are characteristic of denervation atrophy. In the absence of information on the appearance of the inferior oblique muscles on MRI, the crucial question of whether this muscle is involved in the elevation deficiency has not been answered.

The *differential diagnosis* of a double elevator paralysis includes inability to elevate the eye because of mechanical restriction involving the inferior aspect of the globe caused by a blow-out fracture of the orbital floor, congenital or acquired fibrosis, endocrine myopathy, anomalous insertion of the inferior rectus muscle,¹⁶⁹ or an abnormal accessory muscle between the annulus of Zinn and the posterior part of the globe.²⁶⁵ A positive forced duction test and increased intraocular pressure in upward gaze may distinguish these conditions from double elevator palsy although it must also be considered that this muscle may become tight as a result of the elevation deficiency.

Double Depressor Paralysis

An apparent paralysis of both depressor muscles of one eye (inferior rectus and superior oblique) occurs only infrequently. We have encountered it only in the congenital form but an acquired form has also been described.⁸⁵ As with double elevator palsy, the etiology is obscure and is even more difficult to rationalize in terms of a central lesion, since both depressor muscles are innervated from different nuclei. Analogous to the mechanism of apparent double elevator palsy it is possible that so-called *double depressor* paralyses are caused by inferior rectus muscle paralysis of long standing and secondary superior rectus contracture. On the other hand, normal volume of the inferior rectus muscle was present on MRI in a patient with congenital double depressor paralysis who had a positive forced duction test on depressing the globe.²⁰⁷ Tightness of the superior rectus muscle on the basis of extraocular muscle fibrosis (see Chapter 21) may be another cause.

When the nonparetic eye is fixating, the paretic eye is hypertropic in primary position (Fig. 20-27). With the paretic eye fixating, the nonparetic eye may be hypertropic in primary position. Ductions are restricted in the entire lower field of gaze and normal in all other gaze positions. Mechanical causes that interfere with depression of the eye

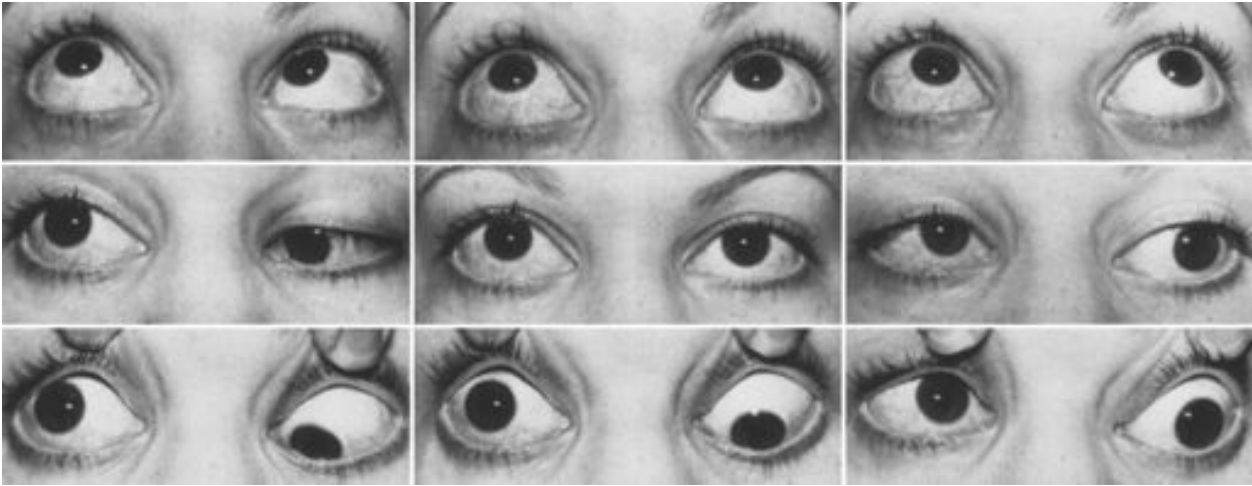


FIGURE 20-27. Apparent paralysis of the depressor muscles of the right eye. In the primary position the paralyzed eye is slightly hypertropic and there is inability to depress the eye from the primary position, adduction, or abduction.

must be excluded. We have seen one patient in whom an apparent double depressor paralysis developed on a mechanical basis following surgical exploration of a mucocele of the frontal sinus with subsequent extensive scarring of the upper fornix.

Supranuclear and Internuclear Paralysis

Lesions of the supranuclear oculomotor pathways or centers cause bilateral conjugate paralysis of associated muscle groups. Gaze paralyzes or spastic conjugate deviations may occur in dextroversion, levoversion, elevation, or depression, depending on the site of the lesion. A discussion of these anomalies is beyond the scope of this text, except that in longstanding cases surgery on yoke muscles may shift the eyes toward primary position and reduce a compensatory face turn.

Internuclear ophthalmoplegia must be considered in the differential diagnosis of isolated medial rectus paralysis. Internuclear ophthalmoplegia is caused by lesions in the medial longitudinal fasciculus. Adduction is abolished unilaterally or bilaterally (Fig. 20-28), and an asymmetrical nystagmus is present involving predominantly the

abducting eye. The nystagmus in these patients is a secondary response to the weakness of adduction and not caused directly by the central defect.^{203, 278}

Disseminated sclerosis is the most common cause of bilateral internuclear ophthalmoplegia, and the unilateral type nearly always is caused by an infarct of a small branch of the basilar artery.⁵⁰ Glaser⁸³ pointed out that limitation of adduction and nystagmus of the abducting eye can be caused also by *ocular myasthenia*. We have described pseudointernuclear ophthalmoplegia in patients with paresis of both medial rectus muscles and a jerking nystagmus of the abducting eye following recession and retroequatorial posterior fixation of both medial rectus muscles.²⁰³

Therapy of Paralytic Strabismus

In determining whether a patient with paralytic strabismus will require therapy, one must establish the extent to which the paralysis interferes with comfortable single binocular vision. The eyes rarely move more than 15° from the primary position during normal use, and diplopia in extreme positions of lateral or vertical gaze is tolerated by

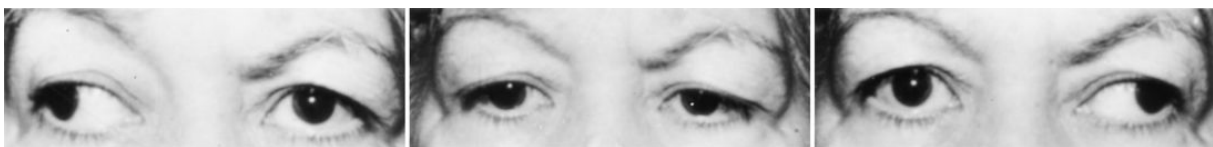

FIGURE 20-28. Bilateral internuclear paralysis in a patient with demyelinating disease. Note limitation of adduction in both eyes. (Courtesy of Dr. John McCrary III, Austin, Texas.)

most patients. For instance, a patient with a paretic right lateral rectus muscle may be comfortable with his eyes in primary position and in levoversion and experience diplopia only in dextroversion. A slight head turn toward the right may eliminate the need to move the eye into that position, in which case therapy obviously is not required. On the other hand, what is easily tolerated by one patient may not be acceptable to another. When one assesses a patient's disability and determines whether treatment is needed, the occupational visual requirements must be considered on an individual basis. In determining medical disability special consideration must be given to construction workers and others working at great heights. Diplopia in a peripheral gaze position that may be easily tolerated by, for example, an office worker may prove to be a hazard in such cases. Thus indications for therapy are the presence of diplopia in the *practical field of fixation* (see Chapter 4) and inability to maintain single binocular vision without a conspicuous anomalous head posture. The inability to maintain single binocular vision without a conspicuous head posture not only is cosmetically distressing but also, as mentioned, may cause secondary structural changes in the cervical spine.

Nonsurgical Therapy

Therapy for incomitant paralytic strabismus is aimed at aligning the eyes in positions of gaze in which a deviation exists without disturbing single binocular vision elsewhere in the field of fixation. While surgery is necessary to achieve this goal in most instances, conservative methods should be considered in suitable cases. *Prisms* are most effective in treating comitant and in many instances incomitant paralytic strabismus of small amplitude. When a deviation is less than 10^Δ we have found prismatic correction to be most effective in deleting diplopia. For larger deviations, prisms rarely are tolerated for prolonged periods and surgery becomes unavoidable. In some cases of comitant strabismus, segmental membrane (Fresnel) prisms may be considered and will eliminate diplopia.

Segmental occluding devices that restrict the effect of occlusion or prisms to one position of gaze may also be feasible. When double vision is restricted to downward gaze, segmental occluding devices or segmental membrane prisms that restrict the effect of occlusion or prisms to one

position of gaze occasionally may be feasible. When double vision is restricted to downward gaze, for instance, in cranial nerve IV paresis, and the patient's age, medical condition, or other reasons militate against surgery, occlusion of the lower third of the spectacles lens before the paretic eye with semiopaque adhesive tape is effective and readily accepted by most patients. The same method is useful when double vision is present in lateral gaze in patients with mild cranial nerve VI paresis (Fig. 20–29).

In desperate situations in which single binocular vision cannot possibly be restored by any means, occlusion of one eye, preferably the sound eye, is a last resort to create visual comfort for the patient. Improvement in surgical techniques and, in recent years, the recognition and successful surgical management of mechanical restriction of ocular motility have made it possible to save the majority of patients with paralytic strabismus from permanently wearing a patch.

Several methods have been advocated to prevent secondary contracture of the antagonist of a paretic muscle in lateral rectus paralysis that in some but not all cases takes place and that will present obstacles to later surgical alignment. The antagonistic muscle has been injected with a local anesthetic or with 15% alcohol. A. B. Scott²³⁸ advocated injection of the antagonist of a palsied muscle with botulinum toxin under electromyographic control.

Surgical Therapy

When conservative therapy fails or the deviation is of such magnitude that it may not even be considered, surgery becomes necessary. The timing of an operation depends on the nature of the underlying paralysis. If the paralysis is longstanding, surgery may be performed as soon as the diagnosis is established. If the paralysis is of recent onset, a 6- to 8-month waiting period is mandatory for the condition to be considered stable; spontaneous recovery of function rarely occurs after that length of time. During the waiting period the patient should be evaluated at frequent intervals and visual comfort maintained with prisms or unilateral occlusion. The determination of the *binocular field of fixation* (see p. 447) is of special value in following such patients. Figure 20–30 shows the gradual recovery of a traumatic superior oblique palsy.

The following discussion contains an outline of

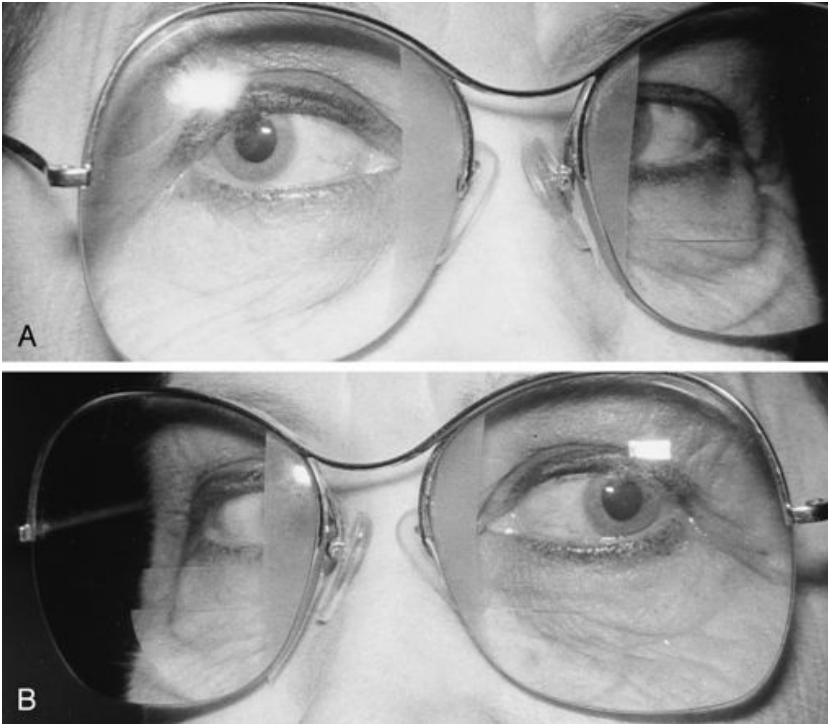

FIGURE 20–29. Sector nasal occlusion in a patient with mild bilateral abducens paresis. Note limitation of abduction of both eyes. The patient fused in the primary position but developed uncrossed diplopia caused by secondary esotropia in lateral gaze. *A*, Nasal sector eliminates diplopia in dextroversion, and *B*, in levoversion.

the surgical management of paralytic strabismus. For dosages and technical details of each operation, the reader is referred to Chapter 26.

PARALYSIS OF RECTUS MUSCLES. The general principle of strabismus surgery—weakening the action of an overacting muscle and strengthening the action of an underacting muscle—also is applicable, with some exceptions, to the management of paralytic strabismus. Resections are indicated only in *pareses* where they may enhance the action of the weak muscle. In *complete paralyses* the effect of muscle resections will only be of a temporary nature.

LATERAL RECTUS MUSCLE. A maximal recession-resection procedure suffices in most instances of incomplete abducens paralysis to restore a useful field of single binocular vision and to eliminate the head turn. The *forced duction test* (see Chapter 26) will determine whether contracture of the medial rectus muscle is present and the *estimation of generated muscle force* (see Chapter 26) whether the paralysis is complete or incomplete. For a complete paralysis of the lateral rectus a resection of that muscle will not only fail to improve the patient but will destroy the anterior ciliary arteries from that muscle. In both children and adults we prefer a *transposition of the full inferior and superior rectus tendons to the insertion of the lateral rectus muscle*, as suggested by Berens and Girard.¹⁹ In older patients we transpose

only the *temporal half* of each vertical rectus muscle, taking care to preserve at least one anterior ciliary artery in that part of the muscle that remains attached to the sclera. Carlson and Jampolsky⁴⁴ also transpose only the temporal aspect of the superior and inferior rectus muscles and apply an adjustable suture to these muscle segments (see also Bechac and coworkers¹⁶). The *Jensen muscle union* (see Chapter 26) is less frequently performed now than only a few years ago since it has been shown that this procedure does not necessarily protect against anterior segment necrosis. Either procedure must be combined with a maximal recession of the medial rectus to be successful, provided contracture of that muscle has been shown to be present with the forced duction test. To preserve part of the blood supply to the anterior segment by avoiding the operation on the medial rectus muscle, injection of the medial rectus with botulinum toxin (see also Chapter 25) has been recommended.^{73, 74, 157, 168, 174, 175, 218, 221,}

^{223, 239} Despite this precaution several cases of anterior segment ischemia have been reported after this procedure.^{104, 134} It may be argued that the ischemia could have occurred from detaching the vertical rectus muscles alone and was unrelated to the injection.^{134, 158}

Whereas normal abduction can never be established by surgery in a complete abducens paralysis and adduction usually becomes restricted after the transposition or Jensen procedures, these opera-

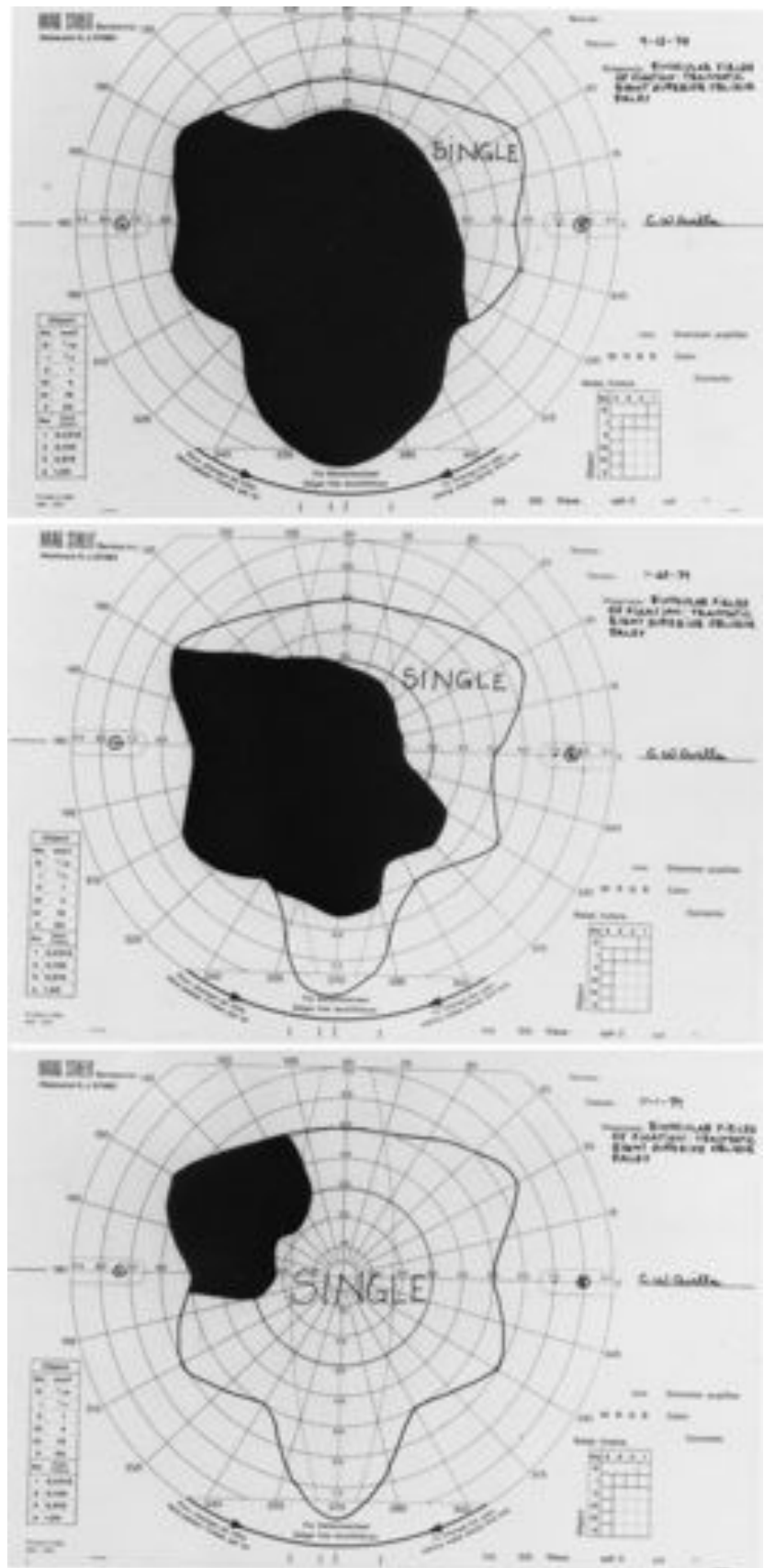


FIGURE 20-30. Progressive enlargement of the field of single binocular vision in a patient recovering from traumatic right superior oblique palsy. A small field of residual vertical diplopia remained 1 year after injury on gaze upward and left as a result of overaction of the ipsilateral inferior oblique muscle.

tions are quite effective in moving the adducted eye into primary position, in restoring a limited field of single binocular vision, and in eliminating or decreasing the head turn. Even a small abduction movement can occasionally be reestablished. This is caused by the springlike action of the transposed vertical muscles upon relaxation of the medial rectus rather than by active innervation of the lateral rectus. In bilateral complete abducens paralysis we operate on both eyes in the same session.

MEDIAL RECTUS MUSCLE. Transposition of the vertical rectus muscles close to the upper and lower border of the medial rectus muscle is indicated.

VERTICAL RECTUS MUSCLES. For paralysis of the superior or inferior rectus muscles, a simple resection-recession operation of the vertical rectus muscles usually is effective. If, in the case of paresis of the superior rectus muscle, the deviation is limited to upward gaze or, in the case of paresis of the inferior rectus, to downward gaze, 4-mm resection of the paretic muscle without recession of its antagonist may suffice.

The question arises whether surgery should be performed on the fixating or nonfixating eye. With rare exceptions, if the horizontal or vertical rectus muscles are paralyzed, we prefer to operate on the paretic eye regardless of whether it is the dominant or nondominant eye. The amount of surgery that is necessary varies, of course, depending on whether the paretic eye (secondary deviation) or the nonparetic eye (primary deviation) habitually fixates.

PARALYSIS OF INFERIOR OBLIQUE MUSCLE.

The generalization to weaken the overacting muscle and strengthen the underacting muscle does not apply to inferior oblique paralysis, the reason being that resection or advancement of the inferior oblique, although technically possible, has consistently yielded unsatisfactory results in our hands. Instead, we recess the superior rectus and resect the inferior rectus muscle of the normal eye. In the presence of marked overaction of the unopposed superior oblique muscle a tenotomy of that muscle has been equally effective in our experience²⁰⁹ and that of others^{102, 245} and may be augmented by recession of the contralateral superior rectus muscle.¹³⁵ This operation eliminates incyclotropia and an existing head tilt and may improve function of the paretic inferior oblique muscle; however, a gradually progressing superior oblique palsy may

develop in the eye operated on and require additional surgical treatment.²⁰⁹

COMPLETE CRANIAL NERVE III PARALYSIS.

The surgical management of a complete cranial nerve III paralysis presents a formidable challenge and the therapeutic possibilities are limited. As may be expected, the sensorimotor outcome of treatment in children is poor.¹⁸⁷ At the very best, the surgeon will succeed in moving the paretic eye into the primary position without restoring adduction, elevation, or depression to a significant degree. Before embarking on what often turns out to be a whole series of operations, a detailed discussion with the patient is necessary in which it must be pointed out that double vision is likely to persist in certain gaze positions and may, in fact, become more bothersome after surgery when the images are closer together. The surgeon must ascertain exactly what the patient expects from the operation. Some patients with a complete cranial nerve III paralysis and ptosis are clearly better off without surgery. This goes especially for older patients! In younger patients most surgeons are tempted to improve the situation. A maximal recession-resection of the horizontal rectus muscles will, at best, create only temporary improvement of the eye position. Eventually, the eye will drift back into an abducted position and a more radical approach will be called for. After trying several procedures, including maximal horizontal surgery with upward transposition of the muscle tendons or transposition of the superior oblique tendon to the insertion of the medial rectus muscle, according to Wiener²⁷⁴ the following operation has given the best results: tenotomy of the lateral rectus and superior oblique muscles combined with a transposition of the vertical rectus muscles to the insertion of the medial rectus muscle. Even though the treated eye will continue to be immobile, it will at least be centered and this operation should be considered especially in patients who fixate with the paralyzed eye and are thus forced to maintain an extreme head turn to the opposite side.

Kaufmann¹²⁹ reported a satisfactory surgical result in two patients who had a combined paralysis of cranial nerves III and IV. The lateral rectus muscle was split, its upper half was transposed to a retroequatorial point near the nasal superior vortex vein, and the lower half to a point near the nasal inferior vortex vein. The horizontal deviation was decreased by 15° to 20°. Other authors

have suggested transposing the lateral rectus muscle to the medial side of the globe,¹²⁰ fixating the globe with strips of fascia lata sutured onto the medial aspect of the globe and the nasal bone periostium,²³⁰ and decreasing surgically the elevation of the fixating eye.¹⁹⁵ Kushner¹⁵⁴ reported satisfactory outcomes in patients with paralysis of the inferior division of the third nerve after tenotomy of the superior oblique, transposition of the superior rectus to the medial rectus, and transposition of the lateral rectus to the insertion of the inferior rectus muscle. Taylor reported improvement after transposing the lateral rectus muscle to the medial portion of the globe.²⁵⁹ Young and coworkers²⁷⁷ suggested cutting the tendon at the medial border of the superior rectus muscle and reinserting it into the sclera 1.0 to 3.5 mm anterior to the medial border of the superior rectus insertion. This operation is combined with recession of the lateral rectus muscle and was reported to improve the exotropia and hypotropia in eight patients thus operated on.

As may be expected, the prognosis for moving the eye at least into primary position by surgery becomes better when the cranial nerve III paralysis is *incomplete* and some recovery of medial rectus function has occurred. Surgery in such cases consists of a maximal recession of the lateral rectus muscle (at least 12 mm) and resection of the medial rectus muscle (at least 7 mm) with upward transposition of the tendons in case of an associated hypotropia. This may restore a small but useful field of single binocular vision even though double vision will persist in up- and downward gaze.

If the eye remains in primary position after surgery, the upper lid may be suspended with an adjustable fascia lata sling in a second operation, unless a significant amount of hypotropia persists. In that case, attempts to elevate the lid are contraindicated, because exposure keratitis will invariably occur.

In certain patients with cranial nerve III palsy, ptosis, exotropia, and aberrant regeneration, the lid position may improve when adduction is attempted because of abnormal yoking between the levator palpebrae on the paralyzed side and the contralateral lateral rectus muscle. Such patients may benefit from having the exotropia corrected by performing surgery on the horizontal recti of the *normal eye*.^{85, 204, 250} This operation will work only if the patient prefers the nonparetic eye for fixation. Postoperatively, the patient must abduct

the fixating eye to bring it into the primary position and this impulse, transmitted to the paretic eye, will, according to Hering's law, elevate the drooping lid simultaneously.

CRANIAL NERVE IV PARALYSIS. Surgical treatment of superior oblique paralysis presents no particular difficulties and is, as a rule, uniquely gratifying to the patient and surgeon. Our surgical methods depend on the classification (see Table 20–5) and are summarized in Table 20–7.²⁰² This approach is similar, though not identical, to that advocated by Knapp and Moore,¹⁴³ Helveston and coworkers (190 patients),¹⁰⁶ Simons and coworkers (123 patients),²⁴⁶ Gräf and coworkers,⁹⁰ and others. No stereotypic mode of treatment exists, and the surgeon must remain flexible because not all patients can be fitted into the classification proposed by Knapp and Moore or its modification by Helveston and coworkers.¹⁰⁸ In patients of class 7 (Knapp) in whom there has been direct trauma to the trochlea, the involved area must be freed by surgical exploration and lysis of adhesions. Whether a recession of the contralateral inferior rectus or of the ipsilateral superior rectus is performed in patients belonging to classes 4 and 5 depends on the outcome of the forced duction test under general anesthesia. If the test is positive on attempts to depress the paralyzed eye, contracture of the superior rectus muscle must be suspected and that muscle is recessed 4 to 5 mm along with weakening the inferior oblique or tucking the superior oblique muscle, or both. Inclusion of the

TABLE 20–7. Surgical Treatment of Superior Oblique Muscle Paralysis

Class	Surgical Treatment
1	Inferior oblique myectomy
2	Superior oblique tuck (8–12 mm); recession of contralateral inferior rectus as second procedure
3	Hypertropia of $\leq 25^\Delta$: inferior oblique myectomy Hypertropia of $> 25^\Delta$: inferior oblique myectomy; superior oblique tuck
4	As in class 3 plus recession of ipsilateral superior rectus or contralateral inferior rectus
5	Superior oblique tuck; recession of ipsilateral superior rectus; or recession of contralateral inferior rectus
6	As in classes 1–5, but bilateral surgery
7	Explore trochlea

From Noorden GK von, Murray E, Wong SY: Superior oblique paralysis. A review of 270 cases. *Arch Ophthalmol* 104:177, 1986.

superior rectus muscle in the operation has resulted in excellent surgical results in such cases.⁹ If the traction test is negative, the contralateral inferior rectus is recessed by a similar amount and may be placed on an adjustable suture in suitable patients.

When exocyclotropia is the only complaint and a vertical deviation is absent, a superior oblique tendon transposition according to Harada and Ito (see Chapter 26) is indicated.

Because of the *laxity of the tendon in congenital paralysis* a large tuck (12 mm or more) can be performed without difficulties. On the other hand, in acquired cases the tendon appears tight at the time of surgery and a tuck of more than 6 to 8 mm may not only be difficult to accomplish but is contraindicated for it may cause a postoperative Brown syndrome with double vision in upward gaze. *Pre- and postoperative rotational forced duction testing of the tightness of the superior oblique tendon*^{93, 214, 215} and, if necessary, surgical revision of the tuck have greatly reduced this complication in our experience.

In *bilateral cases* we operate on both eyes at the same time when the paralysis is of equal severity on both sides. A tuck of both tendons is performed, to which we add a myectomy of the inferior oblique muscles in cases of marked overaction of these muscles. When the paralysis is unequal on both sides we operate first on the more severely involved eye. In a preliminary report Jampolsky¹²⁷ advocated bilateral inferior oblique myectomy combined with 12-mm recessions of both superior rectus muscles to eliminate the chin depression and restore single binocular vision in the reading position.

The effect of surgery according to the approaches outlined in Table 20–7 was evaluated in 112 patients with unilateral and bilateral superior oblique palsies.²⁰² The mean follow-up was 19.8 months (range, 3 to 115 months). A cure, defined as the elimination of the signs or symptoms that caused the patient to seek medical help (diplopia, asthenopia, cosmetically disturbing hypertropia, torticollis), was achieved in 85% of the patients. In the remainder, additional surgery is planned or the patient did not return. It must be noted, however, that a total of 162 operations (1.45 operations per patient) were necessary to achieve a cure. Thus in discussing surgery with the patient it must be mentioned that although the prognosis is good, the probability of having more than one operation

is about 50%. Other authors have reported a lower rate.²⁴⁶

We realize that there are alternative approaches^{106, 246} to the surgical treatment of superior oblique paralysis but feel comfortable with the results achieved with the procedures outlined in Table 20–7.

Congenital absence of the superior oblique muscle is often not suspected until the surgeon is unable to locate the superior oblique tendon. In that case the operation depends on the presence of preoperative inferior oblique muscle overaction.²⁶⁸ If such overaction was present and the hypertropia in the paralyzed field of gaze is less than 25^Δ we myectomize the inferior oblique and recess the ipsilateral superior rectus muscle 3 to 4 mm. If the deviation in the paralyzed field is greater than 25^Δ a recession of the contralateral inferior rectus muscle is added. When there is no preoperative upshoot in adduction we recess the contralateral inferior rectus muscle. If cyclotropia in downward gaze is the only complaint, nasal transposition of the inferior rectus muscle is performed.¹⁸⁸

DOUBLE ELEVATOR AND DOUBLE DEPRESSOR PARALYSES. Not every case requires surgery, which is indicated only when there is hypotropia of the involved eye in primary position or chin elevation or both. The aim of surgery is to restore single binocular vision in primary position. Knapp¹⁴² introduced vertical transposition of the horizontal rectus muscles to the medial and lateral edge of the superior rectus muscle insertion (Knapp procedure; see Chapter 26) for the treatment of this condition. This operation has been successful in our hands and that of others^{41, 130} provided there is no contracture of the inferior rectus muscle. If contracture is present a recession of that muscle becomes also necessary. In cases where it is difficult to determine whether the hypotropia is maintained by a primary inferior rectus tightness alone or by an innervational deficit of the elevator muscle(s) it is best to perform the operation in two stages, beginning with recessing the inferior rectus muscle, after which the situation should be reassessed. The same approach is advocated in older patients to lessen the risk of anterior segment ischemia (see Chapter 26). A complication of surgery is limitation of depression of the eye operated on, with diplopia in downward gaze. In such instances we have performed a recession of the contralateral inferior rectus muscle on an adjustable suture and eliminated the problem. The

long-term results of this procedure for double elevator paralysis have been described as "stable,"³⁵ a description with which we concur.

An analogous approach is used to treat a double depressor paralysis: both horizontal rectus muscles are transposed to the medial and lateral edge of the inferior rectus insertion (inverse Knapp procedure.)⁶⁵

SUPRANUCLEAR GAZE PARALYSIS. An anomalous head posture, especially a face turn in the direction of the gaze palsy, may cause great discomfort to the patient. The general health of the patient permitting, such cases may be considered for surgery on the extraocular muscles. An operative approach similar to that in treating anomalous head posture in manifest congenital nystagmus (see Chapter 23) should be used and we have obtained satisfactory results after unconventionally large recessions of yoke muscle (modified Anderson operation; see p. 523). For instance, in a conjugate palsy to the left with a face turn to the right, we recess the right lateral rectus muscle 12 mm and the left medial rectus muscle 10 mm. This dosage may be modified in cases with a coexisting horizontal strabismus.⁴⁸ Good surgical results have been reported not only in supranuclear but also in internuclear paralyses.³⁴

Alternative Methods

Ophthalmologists have for many years dreamed about and experimented with methods to restore function to or replace a paralyzed muscle with a prosthetic device. Electrical stimulation of a muscle via a subcutaneously implanted radiofrequency receiver⁴⁶ and secondary muscular neurotization of the lateral rectus by implantation of a nerve or neuromuscular pedicle from the adjacent inferior oblique^{5, 12, 92} are but a few alternative treatment methods currently under investigation.^{13, 21} A. B. Scott and coworkers²⁴¹ reported successful implantation of a silicone rubber band along the course of a paralyzed lateral rectus muscle. The band has been in place for 7 years and provides a spring against which the antagonistic medial rectus muscle can pull so that ocular alignment and a 20° field of single binocular vision is restored. Similar success was reported by the same authors with a superior oblique muscle prosthesis. Kolling¹⁴⁶ reported encouraging results in two patients in whom a paralyzed lateral rectus muscle was augmented by an elastic silicone tube that was fixed to the orbital wall.

REFERENCES

- Adelstein F, Cüppers C: Zur Diagnoses des Strabismus paralyticus. *Klin Monatsbl Augenheilkd* 141:335, 1962.
- Adelstein F, Cüppers C: Probleme der operativen Schielbehandlung. *Ber Dtsch Ophthalmol Ges* 69:580, 1969.
- Adler FH: Pathologic physiology of convergent strabismus. Motor aspects of the nonaccommodational type. *Arch Ophthalmol* 33:362, 1945.
- Afifi AK, Bell WE, Menezes AH: Etiology of lateral rectus palsy in infancy and childhood. *J Child Neurol* 7:295, 1992.
- Aichmair H: Muscular neurotisation in surgery of traumatic abducens paresis. *Jpn J Ophthalmol* 21:477, 1977.
- Alvaro M: Simultaneous surgical correction of vertical and horizontal deviations. *Ophthalmologica* 120:191, 1950.
- Ambrose PS, Noorden GK von: Past-pointing in comitant strabismus. *Arch Ophthalmol* 94:1896, 1976.
- Aroichane M, Repka MX: Outcome of sixth nerve palsy or paresis in young children. *J Pediatr Ophthalmol Strabismus* 32:152, 1995.
- Aseff AJ, Muñoz M: Outcome of surgery for superior oblique palsy with contracture of ipsilateral superior rectus treated by superior rectus recession. *Binocular Vision Strabismus Q* 13:177, 1998.
- Bagolini B, Campos EC, Chiesi C: Plagiocephaly causing superior oblique deficiency and ocular torticollis. A new clinical entity. *Arch Ophthalmol* 100:1093, 1982.
- Balkan R, Hoyt CS: Associated neurologic abnormalities in congenital third nerve palsies. *Am J Ophthalmol* 97:315, 1984.
- Baker RS, Smith SD: New muscle growth in denervated extraocular muscle. *Invest Ophthalmol Vis Sci* 28:330, 1987.
- Baker RS, Steed MM: Restoration of function in paralytic strabismus: Alternative methods of therapy. *Binocular Vision Strabismus Q* 5:203, 1990.
- Bárány F: Ein Fall von monokularer Lähmung aller seitlichen Blickbewegungen, bei Intaktheit der vertikalen Blickbewegungen, mit horizontalem Konvergenz- und Divergenznystagmus im Bereich des für die Willkürbewegungen gelähmten Abducens. *Arch Ohr Nase Kehlkopfheilkd* 26:237, 1930.
- Baron Soudet: Scoliose d'origine oculaire. *Rev Otoneuroophthalmol* 24:181, 1952.
- Bechac G, Bes MH, Gajan B, et al: Intérêt de l'opération de Carlson-Jampolsky dans les paralysies totales du VI. *Ophthalmologie* 3:140, 1989.
- Bechac G, Gigaud M, Mathis A: Une étiologie peu commune d'exocyclophorie bilaterale avec pseudo-ectopie maculaire: La stenose de l'aqueduc. *Bull Soc Ophthalmol Fr* 82:1031, 1982.
- Bell JA, Fielder AR, Viney S: Congenital double elevator palsy in identical twins. *J Clin Neuro Ophthalmol* 10:32, 1990.
- Berens C, Girard L: Transplantation of the superior and inferior rectus muscles for paralysis of the lateral rectus muscle. *Am J Ophthalmol* 33:1041, 1950.
- Berlit P: Isolated and combined pareses of cranial nerves III, IV and VI. A retrospective study of 412 patients. *J Neurol Sci* 103:10, 1991.
- Bicas HE: A surgically implanted elastic band to restore paralyzed ocular rotations. *J Pediatr Ophthalmol Strabismus* 28:10, 1991.
- Bielschowsky A: Die Motilitätsstörungen der Augen. In Axenfeld T, Elschnig A, eds: *Graefe-Saemisch's Handbuch der gesamten Augenheilkunde*, ed 2, vol 8. Berlin, Springer-Verlag, 1939.
- Bielschowsky A: *Lectures on Motor Anomalies*. Hanover, NH, Dartmouth College Publications, 1943/1956.

24. Bixenman WW, Noorden GK von: Benign recurrent sixth nerve palsy in childhood. *J Pediatr Ophthalmol Strabismus* 18:29, 1981.
25. Björk A, Kugelberg E: Motor unit activity in the human extraocular muscles. *Electroencephalogr Clin Neurophysiol* 5:271, 1953.
26. Bleik JH, Chedid P, Salame S: Case report: Benign recurrent abducens palsy in children: Another triggering factor: Impetigo. *Binocular Vision Strabismus Q* 13:53, 1998.
27. Boeder P: Cooperative action of extraocular muscle. *Br J Ophthalmol* 46:397, 1962.
28. Boehme G, Schick E: Über die motorische Komponente der exzentrischen Fixation und ihre operative Korrektur. *Klin Monatsbl Augenheilkd* 130:628, 1957.
29. Botelho PJ, Giangiacomo JG: Autosomal-dominant inheritance of congenital superior oblique palsy. *Ophthalmology* 103:1508, 1996.
30. Brackett LE, Demers LM, Mamourian AC, et al: Moebius syndrome in association with hypogonadotropic hypogonadism. *J Endocrinol Invest* 14:599, 1991.
31. Brandt T, Dieterich M: Skew deviation with ocular torsion: A vestibular brainstem sign of topographic diagnostic value. *Ann Neurol* 33:528, 1993.
32. Breinin GM: *The Electrophysiology of Extraocular Muscles*. Toronto, University of Toronto Press, 1962.
33. Brown WB: Isolated inferior oblique paralysis. *Trans Am Ophthalmol Soc* 55:415, 1957.
34. Buckley SA, Elston JS: Surgical treatment of supranuclear and internuclear ocular motility disorders. *Eye* 11:377, 1997.
35. Burke JP, Ruben JB, Scott WE: Vertical transposition of the horizontal recti (Knapp procedure) for the treatment of double elevator palsy: Effectiveness and long-term stability. *Br J Ophthalmol* 76:734, 1992.
36. Burian HM, Cahill JE: Congenital paralysis of medial rectus muscle with unusual synergism of the horizontal muscles. *Trans Am Ophthalmol Soc* 50:87, 1952.
37. Burian HM, Van Allen MW: Cyclic oculomotor paralysis. *Am J Ophthalmol* 55:529, 1963.
38. Burian HM, Rowan PJ, Sullivan MS: Absence of spontaneous head tilt in superior oblique muscle palsy. *Am J Ophthalmol* 79:972, 1975.
39. Burian HM, Van Allen MW, Sexton RR, Baller RS: Substitution phenomena in congenital and acquired supranuclear disorders of eye movement. *Trans Am Acad Ophthalmol Otolaryngol* 69:1105, 1965.
40. Cadera W, Bloom HN, Karlik S, Viirre E: A magnetic resonance imaging study of double elevator palsy. *Can J Ophthalmol* 32:250, 1997.
41. Caldeira JA: Vertical transposition of the horizontal rectus muscle for congenital/early onset "acquired" double elevator palsy: A retrospective long term study of 10 consecutive patients. *Binocular Vision Strabismus Q* 15:29, 2000.
42. Capó H, Guyton DL: Ipsilateral hypertropia after cataract surgery. *Ophthalmology* 103:721, 1996.
43. Capó H, Roth E, Johnson T, et al: Vertical strabismus after cataract surgery. *Ophthalmology* 103:918, 1996.
44. Carlson MR, Jampolsky A: An adjustable transposition procedure for abduction deficiencies. *Am J Ophthalmol* 78:382, 1979.
45. Chavasse FB: *Worth's Squint or the Binocular Reflexes and the Treatment of Strabismus*, ed 7. London, Baillière, Tindall & Cox, 1939.
46. Chen Y, Richards R, Ko W, Finger P: Electrical stimulation of extraocular muscles. In *Proceedings of the Ninth Annual Conference of the IEEE Engineering, Medicine, and Biology Society*, Boston, Nov 13-16, 1947, p 649.
47. Clark RA, Miller JM, Demer JL: Displacement of the medial rectus pulley in superior oblique palsy. *Invest Ophthalmol Vis Sci* 39:207, 1998.
48. Coats DK, Avilla CW, Lee AG, Paysse EA: Etiology and surgical management of horizontal pontine gaze palsy with ipsilateral esotropia. *J Am Assoc Pediatr Ophthalmol Strabismus* 2:293, 1998.
49. Cobbs WH, Schatz HJ, Savino PJ: Nontraumatic bilateral fourth nerve palsies. A dorsal midbrain sign. *Ann Neurol* 8:107, 1980.
50. Cogan DC: *Neurology of the Ocular Muscles*, ed 2. Springfield, IL, Charles C Thomas, 1956, p 89.
51. Courtens W, Vamos E, Hainaut M, Vergauwen P: Moebius syndrome in an infant exposed in utero to benzodiazepines. *J Pediatr* 121:833, 1992.
52. Cruysberg JR, Mtanda AT, Duinkerke-Eerola KU, Huygen PL: Congenital adduction palsy and synergistic divergence: A clinical and electro-oculographic study. *Br J Ophthalmol* 73:68, 1989.
53. Cuignet FLU: Torticolis oculaire. *Receuil Ophtalmol* 1873. Quoted by Bielschowsky A: *Lectures on Motor Anomalies*. Hanover, NH, Dartmouth College Publications, 1943/1956.
54. Cüppers C: Discussion of paper by Boehme G, Schick E: Über die motorische Komponente der exzentrischen Fixation und ihre operative Korrektur. *Klin Monatsbl Augenheilkd* 130:628, 1957.
55. Cüppers C: Some reflections on the possibility of influencing the pathological fixation act. *Ann R Coll Surg Engl* 38:308, 1966.
56. Davis DB, Mandel MR: Posterior peribulbar anesthesia: An alternative to retrobulbar anesthesia. *J Cataract Refract Surg* 12:182, 1986.
57. D'Cruz OF, Swisher CN, Jaradeh S, et al: Moebius syndrome: Evidence for a vascular theory. *J Child Neurol* 3:260, 1993.
58. de Decker W: The fadenoperation. When and how to do it. *Trans Ophthalmol Soc U K* 101:264, 1981.
59. de Faber JTHN, Noorden GK von: Inferior rectus muscle palsy after retrobulbar anesthesia for cataract surgery. *Am J Ophthalmol* 112:209, 1991.
60. Demer JL, Miller JM: Magnetic resonance imaging of the functional anatomy of the superior oblique muscle. *Invest Ophthalmol Vis Sci* 36:906, 1995.
61. Dietrich DE, Slack WJ: Scoliosis secondary to unilateral extraocular muscle paresis (ocular torticollis). *Radiology* 88:538, 1967.
62. Dotti MT, Federico A, Palmeri S, Guazzi GC: Congenital oculo-facial paralysis (Moebius syndrome): Evidence of dominant inheritance in two families. *Acta Neurol* 11:434, 1989.
63. Duke-Elder S, Wybar K: *System of Ophthalmology*, vol 6: *Ocular Motility and Strabismus*. St Louis, Mosby-Year Book, 1973, pp 736 ff.
64. Dunlap EA: Diagnosis and surgery of double elevator underaction. *Memorias VI Congress. Panamericano de Oftalmologia* 3:1154, 1952.
65. Dunlap EA: Vertical displacement of horizontal recti. In *Symposium on Strabismus*. St Louis, Mosby-Year Book, 1971, p 307.
66. Ehrich W: Der Einfluss der Schieloperation auf den Fixationsort des amblyopen Auges. *Klin Monatsbl Augenheilkd* 133:846, 1958.
67. Ellis FD, Helveston EM, eds: Superior oblique palsy. *Int Ophthalmol Clin* 16:127, 1976.
68. Ellis FJ, Stein LA, Guyton DL: Masked bilateral superior oblique muscle paresis. *Ophthalmology* 105:544, 1998.
69. Elsayh NM: Moebius syndrome associated with the mother taking thalidomide during gestation: Case report. *Plast Reconstr Surg* 51:93, 1973.
70. Esslen E, Papst W: Die Bedeutung der Elektromyographie für die Analyse von Motilitätsstörungen der Augen. *Bibl Ophthalmol* 57:1, 1961.

71. Esswein MB, Noorden GK von: Paresis of a vertical rectus muscle after cataract surgery. *Am J Ophthalmol* 116:424, 1993.
72. Fells P, Collin JR: Cyclic oculomotor palsy. *Trans Ophthalmol Soc U K* 99:192, 1979.
73. Fitzsimmons R, Lee JP, Elston J: Treatment of sixth nerve palsy in adults with combined botulinum toxin chemodenervation and surgery. *Ophthalmology* 95:1535, 1988.
74. Fitzsimmons R, Lee J, Elston J: The role of botulinum in the management of sixth nerve palsy. *Eye* 3:391, 1989.
75. Foster J, Pemberton EC: The effect of operative alterations in the heights of the external rectus insertion. *Br J Ophthalmol* 30:88, 1946.
76. Ford CS, Schwartze GM, Weaver RC, Troost BT: Monocular elevation paresis caused by an ipsilateral lesion. *Neurology* 34:1264, 1984.
77. Fox A: Findings in superior oblique palsy. *Br Orthopt J* 38:31, 1981.
78. Franceschetti A: Le diagnostic des paralysies des différents muscles oculaires. *Bull Soc Ophthalmol Fr* 5:471, 1936.
79. François J, Derouck A: Étude electrooculographique des paralysies oculaires. *Acta Ophthalmol* 33:523, 1955.
80. Fujita I, Koyanagi T, Kukita J, et al: Moebius syndrome with central hypoventilation and brainstem calcification: A case report. *Eur J Pediatr* 150:582, 1991.
81. Ghabriel R, Versace P, Kourt G, et al: Möbius syndrome: Features and etiology. *J Pediatr Ophthalmol Strabismus* 35:304, 1998.
82. Gifford H: Congenital abduction deficiency. *Trans Am Acad Ophthalmol Otolaryngol* 29:176, 1924.
83. Glaser J: Myasthenic pseudo-internuclear ophthalmoplegia. *Arch Ophthalmol* 75:363, 1966.
84. Goodman CR, Chabner E, Guyton DL: Should early strabismus surgery be performed for ocular torticollis to prevent facial asymmetry? *J Pediatr Ophthalmol Strabismus* 32:162, 1995.
85. Gopal KSS: Acquired double depressor palsy. *Indian J Ophthalmol* 36:35, 1988.
86. Gottlob I, Catalano RA, Reinecke RD: Surgical management of oculomotor nerve palsy. *Am J Ophthalmol* 111:71, 1991.
87. Gowers WR: *A Manual of the Diseases of the Nervous System*. Philadelphia, P Blakiston & Son, 1888, p 596.
88. Graefe A von: Beiträge zur Physiologie und Pathologie der schiefen Augenmuskeln. *Graefes Arch Clin Exp Ophthalmol* 1:1, 1854.
89. Graefe A von: *Klinische Analyse der Motilitätsstörungen des Auges*. Berlin, H Peters, 1858, p 70.
90. Gräf M, Krzizok T, Kaufmann H: Kombinierte Obliquusoperation mit Ansatzverlagerung bei Strabismus sursoaductorius. *Klin Monatsbl Augenheilkd* 205:329, 1994.
91. Grimmet MR, Lambert SR: Superior rectus muscle overaction after cataract extraction. *Am J Ophthalmol* 114:72, 1992.
92. Grossman MD, Gutman FA, Tucker HM: Extraocular muscle reinnervation by a neuromuscular pedicle. *Invest Ophthalmol Vis Sci* 24(suppl):23, 1983.
93. Guyton D: Exaggerated traction test for the oblique muscles. *Ophthalmology* 88:1035, 1981.
94. Hamed LM: Associated neurologic abnormalities in congenital third nerve palsies. *Am J Ophthalmol* 98:708, 1991.
95. Hamed LM, Lingua RW, Fanous MM, et al: Synergistic divergence: Saccadic velocity analysis and surgical results. *J Pediatr Ophthalmol Strabismus* 29:30, 1992.
96. Hamed LM, Manusco A: Inferior rectus muscle contracture syndrome after retrobulbar anesthesia. *Ophthalmology* 98:1506, 1991.
97. Hamed LM, Maria BL, Quisling RG, Mickle JP: Alternating skew on lateral gaze—neuroanatomic pathway and relationship to superior oblique overaction. *Ophthalmology* 100:281, 1993.
98. Hamilton SR, Lessell S: Recurrent idiopathic lateral rectus muscle palsy in adults. *Am J Ophthalmol* 112:540, 1991.
99. Harms H: Über die Untersuchung von Augenmuskellähmungen. *Graefes Arch Clin Exp Ophthalmol* 144:129, 1942.
100. Hardesty HH: Diagnosis of paretic vertical rotators. *Am J Ophthalmol* 56:811, 1963.
101. Hashimoto N, Sakakihara Y, Miki Y, et al: Moebius syndrome associated with pituitary dwarfism and hypoplastic optic disc. *Acta Paediatr Jpn* 35:144, 1993.
102. Helmholtz H von: *Treatise on Physiological Optics*, vol 3, Translated by Southall JPC. New York, Dover Publications, 1962, chap 29.
103. Helveston EM: A new two-step method for the diagnosis of isolated cyclovertical muscle palsies. *Am J Ophthalmol* 64:914, 1967.
104. Helveston EM: Personal communication, Dec 5, 1994.
105. Helveston E, Bick SE, Ellis FD: Differential intraocular pressure as an indirect measure of generated muscle force. *Ophthalmol Surg* 11:386, 1980.
106. Helveston EM, Fraco JSM, Lipsky SN, et al: Surgical treatment of superior oblique palsy. *Trans Am Ophthalmol Soc* 94:315, 1996.
107. Helveston EM, Giangiaco JD, Ellis FD: Congenital absence of the superior oblique tendon. *Trans Am Ophthalmol Soc* 79:124, 1981.
108. Helveston EM, Krach D, Plager DA, Ellis FD: A new classification of superior oblique palsy based on congenital variations in the tendon. *Ophthalmology* 99:1609, 1992.
109. Hermann JS: Masked bilateral superior oblique paresis. *J Pediatr Ophthalmol Strabismus* 18:43, 1981.
110. Hicks AM: Congenital paralysis of lateral rotators of eyes with paralysis of muscles of face. *Arch Ophthalmol* 30:38, 1943.
111. Hofmann FB: Die Lehre vom Raumsinn. In Axenfeld Th, Elschnig A, eds: *Graefe-Saemisch's Handbuch der gesamten Augenheilkunde*, ed 2, vol 3. Berlin, Springer-Verlag, 1925.
112. Hofmann FB, Bielschowsky A: Die Verwertung der Kopfeigung zur Diagnose der Augenmuskellähmungen aus der Heber und Senkergruppe. *Graefes Arch Clin Exp Ophthalmol* 51:174, 1900.
113. Holmes JM, Droste PJ, Beck RW: The natural history of acute traumatic sixth nerve palsy or paresis. *J Am Assoc Pediatr Ophthalmol Strabismus* 2:265, 1998.
114. Holmes JM, Mutyala S, Maus T, et al: Pediatric third, fourth and sixth nerve palsies: A population based study. *Am J Ophthalmol* 127:388, 1999.
115. Horton CE, Crawford HH, Adamson JE, Ashbell TS: Torticollis. *South Med J* 60:953, 1967.
116. Huber A, Lehner FH: Zur Elektromyographie der Augenmuskeln. *Ophthalmologica* 131:238, 1956.
117. Hugonnier R, Magnard P: Paralysies à bascule du grand oblique. *Bull Soc Ophthalmol Fr* 69:587, 1969.
118. Hunter D, Lam GC, Guyton DL: Inferior oblique muscle injury from local anesthesia for cataract surgery. *Ophthalmology* 102:501, 1995.
119. Jacobi KW: Einige bemerkenswerte Fälle von Fixationswandel nach Schieloperationen. *Klin Monatsbl Augenheilkd* 152:751, 1968.
120. Jacobson DM: Isolated trochlear nerve palsy in patients with multiple sclerosis. *Neurology* 53:877, 1999.
121. Jaensch PA: Paresen der schrägen Heber. *Graefes Arch Clin Exp Ophthalmol* 121:113, 1928.

122. Jampel RS, Fells P: Monocular elevation paresis caused by a central nervous system lesion. *Arch Ophthalmol* 80:45, 1968.
123. Jampolsky A: What can electromyography do for the ophthalmologist? *Invest Ophthalmol* 9:570, 1970.
124. Jampolsky A: Vertical strabismus surgery. In *Transactions of the New Orleans Academy of Ophthalmology*. St Louis, Mosby-Year Book, 1971, p 366.
125. Jampolsky A: Surgical leashes and reverse leashes in strabismus surgical management. In *Symposium on Strabismus: transactions of the New Orleans Academy of Ophthalmology*. St Louis, Mosby-Year Book, 1978, p 244.
126. Jampolsky A: Personal communication, 1978.
127. Jampolsky A: A new surgical procedure for marked bilateral superior oblique palsy: Preliminary report. In Lernerstrand G, ed: *Advances in Strabismology*. Proceedings of the International Strabismological Association, Maasticht, Sept 10–12, 1998. Buren, The Netherlands, Aeolus Press, 1999, p 241.
128. Járegui-Renaud K, Faldon N, Clarke A, et al: Skew deviation of the eyes in normal human subjects induced by semicircular canal stimulation. *Neurosci Lett* 205:135, 1996.
129. Kaufmann H: "Lateralissplitting" bei totaler Okulomotoriusparalyse mit Trochlearisparese. *Fortschr Ophthalmol* 88:314, 1991.
130. Kocak-Altinas AG, Kocak-Midillioglu I, Dabil H, Duman S: Selective management of double elevator palsy by either inferior rectus recession and/or Knapp type transposition. *Binocular Vision Strabismus Q* 15:39, 2000.
131. Kubatko-Zielinska A, Krzystkova KM: Congenital syndromes of oculomotor disturbances—diagnosis and results of surgical treatment (English abstract). *Klin Oczna* 97:142, 1995. [Cited by Spierer and Barak.²⁵¹]
132. Kazarian EL, Flynn JT: Congenital third nerve palsy with amblyopia of the contralateral eye. *J Pediatr Ophthalmol Strabismus* 15:366, 1978.
133. Keane JR: Ocular skew deviation. *Arch Neurol* 32:185, 1975.
134. Keech RV, Morris RJ, Ruben JB, Scott WE: Anterior segment ischemia following vertical muscle transposition and botulinum toxin injection. *Arch Ophthalmol* 108:176, 1990.
135. Khawam E, Menassa J, Jaber A, Farah S: Diagnosis and treatment of isolated inferior oblique muscle palsy: A report of seven cases. *Binocular Vision Strabismus Q* 13:45, 1998.
136. Khawam E, Scott A, Jampolsky A: Acquired superior oblique palsy. Diagnosis and management. *Arch Ophthalmol* 77:761, 1967.
137. King AJ, Stacey E, Stephenson G, Trimble RB: Spontaneous recovery rates for unilateral sixth nerve palsies. *Eye* 9:476, 1995.
138. Kirkham TH, Bird AC, Sanders MD: Divergence paralysis with increased intracranial pressure: An electrooculographic study. *Br J Ophthalmol* 56:776, 1972.
139. Klemm O: Überraschend günstige funktionelle Besserung bei schieloperierten Erwachsenen. In Hollwich F, ed: *Schielen-Pleoptik-Orthoptik-Operation*. Stuttgart, Ferdinand Enke Verlag, 1961, p 179.
140. Klainguti G, Lang J: Diagnostic et traitement chirurgical de la parésie bilatérale de l'oblique supérieur. *Klin Monatsbl Augenheilkd* 206:359, 1995.
141. Knapp P: The surgical treatment of double elevator paralysis. *Trans Am Ophthalm Soc* 67:304, 1969.
142. Knapp P: Diagnosis and surgical treatment of hyperopia. *Am Orthopt J* 21:29, 1971.
143. Knapp P, Moore S: Diagnosis and surgical options in superior oblique surgery. *Int Ophthalmol Clin* 16:137, 1976.
144. Knox DL, Clark DB, Schuster FF: Benign sixth nerve palsies in children. *Pediatrics* 40:560, 1967.
145. Kodsí SR, Younge BR: Acquired oculomotor, trochlear, and abducent cranial nerve palsies in pediatric patients. *Am J Ophthalmol* 114:568, 1992.
146. Kolling GH: Funktioneller Ersatz eines paralytischen M. rectus lateralis durch eine elastische Silikonschlinge. *Z Prakt Augenheilkd* 18:285, 1997.
147. Kommerell G, Mattheus S, Mühlendyck H: Willkürliche Beeinflussbarkeit des einseitigen Strabismus sursoadductorius. *Klin Monatsbl Augenheilkd* 209:171, 1996.
148. Kraft SP, Scott WE: Masked bilateral superior oblique palsy. Clinical features and diagnosis. *J Pediatr Ophthalmol Strabismus* 23:264, 1986.
149. Kraft SP, O'Reilly C, Quigley PL, et al: Cyclotorsion in unilateral and bilateral superior oblique paresis. *J Pediatr Ophthalmol Strabismus* 30:361, 1993.
150. Krewson WE: Ocular torticollis. *Am Orthopt J* 7:151, 1957.
151. Krohel GB, Mansour AM, Petersen WL, Evenchik B: Isolated trochlear palsy secondary to a juvenile pilocytic astrocytoma. *J Clin Neuro Ophthalmol* 1:119, 1982.
152. Kushner BJ: Ocular muscle fibrosis following cataract extraction. *Arch Ophthalmol* 106:18, 1988.
153. Kushner BJ: The diagnosis and treatment of bilateral masked superior oblique palsy. *Am J Ophthalmol* 105:186, 1988.
154. Kushner BJ: Surgical treatment of paralysis of the inferior division of the oculomotor nerve. *Arch Ophthalmol* 117:485, 1999.
155. Lee AG, Haymann LA, Beaver HA, et al: A guide to the evaluation of fourth nerve cranial nerve paralysis. *Strabismus* 6:191, 1998.
156. Lee AG, Onan H, Brazis PW, Prager TC: An imaging guide to the evaluation of third cranial nerve palsies. *Strabismus* 7:153, 1999.
157. Lee J, Harris S, Cohen J, et al: Results of a prospective randomized trial of botulinum toxin therapy in acute unilateral sixth nerve palsy. *J Pediatr Ophthalmol Strabismus* 31:283, 1994.
158. Lee JP, Olver JM: Anterior segment ischemia following vertical muscle transposition and botulinum toxin injection (letter). *Arch Ophthalmol* 109:174, 1991.
159. Legge RH, Hedges TR, Anderson M, Reese PD: Hyperopia following trochlear trauma. *J Pediatr Ophthalmol Strabismus* 29:163, 1992.
160. Leigh RJ, Zee DS: *The Neurology of Eye Movements*. Philadelphia, FA Davis, 1983, p 173.
161. Lengyel D, Zaunbauer W, Keller E, Gottlob I: Möbius syndrome: MRI findings in three cases. *J Pediatr Ophthalmol Strabismus* 37:305, 2000.
162. Lessel S: Supranuclear paralysis of monocular elevation. *Neurology* 25:1134, 1975.
163. Limón de Brown E, Monasterio FO, Feldman MS: Strabismus in plagiocephaly. *J Pediatr Ophthalmol Strabismus* 25:180, 1988.
164. Lipson AH, Webster WS, Brown-Woodman PD, Osborn RA: Moebius syndrome: Animal model-human correlations and evidence for a brainstem vascular etiology. *Teratology* 40:339, 1989.
165. Loewenfeld IE, Thompson HS: Oculomotor paresis with cyclic spasms. A critical review of the literature and a new care. *Surv Ophthalmol* 20:81, 1975.
166. Mackensen G: *Okulographie*. In Hamburger FA, Hollwich F, eds: *Augenmuskellähmungen*, vol 46. Stuttgart, Ferdinand Enke Verlag, 1966.
167. Manners RM, O'Flynn E, Morris RJ: Superior oblique lengthening for acquired superior oblique overaction. *Br J Ophthalmol* 78:280, 1994.
168. McManaway JW, Buckley EG, Brodsky MC: Vertical

- rectus muscle transposition with intraoperative botulinum injection for treatment of chronic sixth nerve palsy. *Graefes Arch Clin Exp Ophthalmol* 228:401, 1990.
169. McNeer KW, Jampolsky A: Double elevator palsy caused by anomalous insertion of the inferior rectus. *Am J Ophthalmol* 59:317, 1965.
 170. Merz M, Wojtowicz S: The Moebius syndrome: Report of an electromyographic examination in two cases. *Am J Ophthalmol* 63:837, 1967.
 171. Metz HS: III nerve palsy: I. Saccadic velocity studies. *Ann Ophthalmol* 5:526, 1973.
 172. Metz HS: Saccadic velocity measurements in internuclear ophthalmoplegia. *Am J Ophthalmol* 81:295, 1976.
 173. Metz HS: Saccadic velocity measurements in strabismus. *Trans Am Ophthalmol Soc* 81:630, 1983.
 174. Metz HS, Dickey CF: Treatment of unilateral acute sixth-nerve palsy with botulinum toxin. *Am J Ophthalmol* 112:381, 1991.
 175. Metz HS, Mazow M: Botulinum toxin treatment of acute sixth and third nerve palsy. *Graefes Arch Clin Exp Ophthalmol* 226:141, 1988.
 176. Metz HS, Yeaple R: Modified periodontal probe for simplified forced duction measurements. *J Pediatr Ophthalmol* 32:257, 1995.
 177. Metz HS, Scott AB, O'Meara DM: Saccadic velocity in infants and children. *Am J Ophthalmol* 72:1130, 1971.
 178. Metz HS, Scott AB, O'Meara D, Stewart HL: Ocular saccades in lateral rectus palsy. *Arch Ophthalmol* 84:453, 1970.
 179. Metz HS, Scott AB, Scott WE: Horizontal saccadic velocities in Duane's syndrome. *Am J Ophthalmol* 80:901, 1975.
 180. Metz HS, Scott WE, Madson E, Scott AB: Saccadic velocities and active force studies in blow-out fractures of the orbit. *Am J Ophthalmol* 78:665, 1974.
 181. Miller MT, Strömland K: The Möbius sequence. *J Am Assoc Pediatr Ophthalmol Strabismus* 3:199, 1999.
 182. Miller N: Solitary oculomotor nerve palsy in childhood. *Am J Ophthalmol* 99:106, 1977.
 183. Mitchell PR, Parks MM: Surgery for bilateral superior oblique palsy. *Ophthalmology* 89:484, 1982.
 184. Möbius PJ: Über angeborene doppelseitige Abducens-Facialis Lähmung. *Münch Med Wochenschr* 35:91, 1888.
 185. Möbius PJ: Diagnostik der Nervenkrankheiten, ed 2. Leipzig, FCW Vogel, 1898, p 69.
 186. Moses RA: Adler's Physiology of the Eye: Clinical Application, ed 5. St Louis, Mosby-Year Book, 1970, p 236.
 187. Mudgil AV, Repka MX: Ophthalmologic outcome after third cranial nerve palsy or paresis in childhood. *J Am Assoc Pediatr Ophthalmol Strabismus* 3:2, 1999.
 188. Mumma JV: Surgical procedure for congenital absence of the superior oblique. *Arch Ophthalmol* 92:221, 1974.
 189. Muñoz M, Capó H, Siatkowski RM: Results of surgery for vertical strabismus following cataract extraction performed under local anesthesia. *Binocular Vision Strabismus Q* 11:275, 1996.
 190. Munoz M, Page LK: Acquired double elevator paralysis on a child with pineocytoma. *Am J Ophthalmol* 118:810, 1994.
 191. Nagel A: Über des Vorkommen von wahren Rollungen um die Gesichtslinie. *Graefes Arch Clin Exp Ophthalmol* 17:243, 1871.
 192. Narita AS, Lee JP: Consecutive inferior oblique underaction in resolving superior oblique palsy. In *Spiritus M*, ed: Transactions of the 23rd Meeting of the European Strabismological Association, Nancy, France, June 1996. Buren, The Netherlands, 1997, p 383.
 193. Neetens A, Janssens M: The superior oblique: A challenging extraocular muscle. *Doc Ophthalmol* 46:295, 1979.
 194. Newman NJ, Lambert SR: Botulinum toxin treatment of supranuclear ocular motility disorder. *Neurology* 42:1391, 1992.
 195. Noonan CP, O'Connor M: Surgical management of third nerve palsy. *Br J Ophthalmol* 79:431, 1995.
 196. Noorden GK von: Atlas of Strabismus, ed 4. St Louis, Mosby-Year Book, 1983.
 197. Noorden GK von, Hansell R: Clinical characteristics and treatment of isolated inferior rectus paralysis. *Ophthalmology* 98:253, 1991.
 198. Noorden GK von, Helveston EM: Influence of eye position on fixation behavior and visual acuity. *Am J Ophthalmol* 70:199, 1970.
 199. Noorden GK von, Maumenee AE: Atlas of Strabismus. St Louis, Mosby-Year Book, 1967.
 200. Noorden GK von, Ruttum M: Torticollis in paralysis of the trochlear nerve. *Am Orthopt J* 33:16, 1983.
 201. Noorden GK von, Awaya S, Romano PE: Past-pointing in paralytic strabismus. *Am J Ophthalmol* 71:27, 1971.
 202. Noorden GK von, Murray E, Wong SY: Superior oblique paralysis. A review of 270 cases. *Arch Ophthalmol* 104:1771, 1986.
 203. Noorden GK von, Tredici TD, Ruttum M: Pseudointernuclear ophthalmoplegia after surgical paresis of the medial rectus muscle. *Am J Ophthalmol* 98:602, 1984.
 204. O'Donnell FE, del Monte M, Guyton DL: Simultaneous correction of blepharoptosis and exotropia in aberrant regeneration of the oculomotor nerve by strabismus surgery. *Ophthalmic Surg* 11:695, 1980.
 205. O'Donnell JJ, Howard RO: Torticollis associated with hiatus hernia (Sandifer's syndrome). *Am J Ophthalmol* 71:1134, 1971.
 206. Özkan A, Aribal ME, Can D, et al: The evaluation of congenital double elevator palsy with magnetic resonance imaging. *Neuro Ophthalmology* 21:69, 1999.
 207. Özkan A, Dayanir V, Karaman ZC, Söylev MF: Double depressor palsy with results of surgery and MRI examination. In *Spiritus M*, ed: Transactions of the 25th Meeting European Strabismological Association, Jerusalem. Lisse, The Netherlands, Aeolus Press, 2000, p 208.
 208. Olivier P, Noorden GK von: Excyclotropia of the nonparetic eye in unilateral superior oblique muscle paralysis. *Am J Ophthalmol* 93:30, 1982.
 209. Olivier P, Noorden GK von: Results of superior oblique tenectomy in inferior oblique paresis. *Arch Ophthalmol* 100:581, 1982.
 210. Ong-Tone L, Pearce WG: Inferior rectus muscle restriction after retrobulbar anesthesia for cataract extraction. *Can J Ophthalmol* 24:162, 1989.
 211. Opper O: Über die motorischen, sensorischen, und sensiblen Nerveneinrichtungen im menschlichen Augenmuskellapparat und ihre sinnesphysiologische Bedeutung. *Graefes Arch Clin Exp Ophthalmol* 171:337, 1967.
 212. Parks MM: Isolated cyclovertical muscle palsy. *Arch Ophthalmol* 60:1027, 1958.
 213. Petrus M, Rhabbour M, Clouzeau J, et al: Association of Moebius syndrome and hypopituitarism due to a midline anomaly. A case report. *Ann Pediatr* 40:376, 1993.
 214. Plager DA: Traction testing in superior oblique palsy. *J Pediatr Ophthalmol Strabismus* 27:136, 1990.
 215. Plager DA: Tendon laxity in superior oblique palsy. *Ophthalmology* 99:1032, 1992.
 216. Reinecke RD, Thompson WE: Childhood recurrent idiopathic paralysis of the lateral rectus. *Ann Ophthalmol* 13:1037, 1981.
 217. Richards BW, Jones FR, Younge BR: Causes and prognosis in 4,278 cases of paralysis of the oculomotor, trochlear, and abducens cranial nerves. *Am J Ophthalmol* 113:489, 1992.
 218. Riordan-Eva P, Lee JP: Management of VIth nerve palsy—avoiding unnecessary surgery. *Eye* 6:386, 1992.

- 218a. Robb RM, Boger WP: Vertical strabismus associated with plagiocephaly. *J Pediatr Ophthalmol Strabismus* 20:58, 1983.
219. Roper-Hall G, Feibel RM: Measurement of the field of binocular single vision in the evaluation of incomitant paralytic strabismus. *Am Orthopt J* 24:77, 1974.
220. Rosenbaum A, Metz HS: Diagnosis of lost or slipped muscles by saccadic velocity measurements. *Am J Ophthalmol* 77:215, 1974.
221. Rosenbaum A, Kushner BJ, Kirschen D: Vertical rectus muscle transposition and botulinum toxin (Oculinum) to the medial rectus muscle in abducens palsy. *Arch Ophthalmol* 107:228, 1989.
222. Rosenbaum A, Meyers JH: New instrument for the quantitative determination of passive forced traction. *Ophthalmology* 18:158, 1980.
223. Rosenbaum A: The use of Oculinum as a surgical adjunct. Presented at the American Academy of Ophthalmology, Las Vegas, Oct 8–12, 1988.
224. Roussat B, Bourreau M, Hayot B, et al: Les paralysies isolées et bénignes du VI nerf crânien chez l'enfant—aspects évolutifs à propos de 9 nouveaux cas. *Ophthalmologie* 3:107, 1989.
225. Ruedemann AD Jr: Scoliosis and vertical ocular muscle balance. *Arch Ophthalmol* 56:389, 1956.
226. Rush JA, Shafrin F: Ocular myasthenia presenting as superior oblique weakness. *J Clin Neuro Ophthalmol* 2:125, 1982.
227. Rush JA, Younge BR: Paralysis of cranial nerves III, IV, and VI: Causes and prognosis in 1,000 cases. *Arch Ophthalmol* 99:76, 1981.
228. Safran AB, Vibert D, Issoua D, Hausler R: Skew deviation after vestibular neuritis. *Am J Ophthalmol* 118:238, 1994.
229. St Charles S, DiMario FJ, Grunnet ML: Möbius sequence: Further in vivo support for the subclavian artery supply disruption sequence. *Am J Genet* 47:289, 1993.
230. Salazar-León JA, Ramírez-Ortiz MA, Salas-Vargas M: The surgical correction of paralytic strabismus using fascia lata. *J Pediatr Ophthalmol Strabismus* 35:27, 1998.
231. Sato M: Magnetic resonance imaging and tendon anomaly associated with congenital superior oblique palsy. *Am J Ophthalmol* 127:379, 1999.
232. Sato M, Yagasaki T, Kora T, Awaya S: Comparison of muscle volume between congenital and acquired superior oblique palsies by magnetic resonance imaging. *Jpn J Ophthalmol* 42:466, 1998.
233. Schiavi C, Bellusci C, Campos EC: Acquired Moebius like syndrome: Case report. In Spiritus M, ed: Transactions of the 25th Meeting of the European Strabismological Association. Lisse, The Netherlands, Aeolus Press, 2000, p 62.
234. Schumacher-Feero LA, Yoo KW, Solari FM, Biglan AW: Third cranial nerve palsy in children. *Am J Ophthalmol* 128:216, 1999.
235. Schultz E: Spontaneous consecutive Brown syndrome following superior oblique palsy. *Strabismus* 1:11, 1993.
236. Schwarz EC, Gerdemann M, Hoffmann R, Hartmann C: Kataraktoperation mit Linsenimplantation. Strabismus und Diplopie als Komplikation. *Ophthalmologie* 10:635, 1999.
237. Scott AB: Active force tests in lateral rectus paralysis. *Arch Ophthalmol* 85:397, 1971.
238. Scott AB: Botulinum toxin injection of eye muscles to correct strabismus. *Trans Am Ophthalmol Soc* 74:734, 1981.
239. Scott AB, Kraft SP: Botulinum toxin injection in the management of lateral rectus paresis. *Ophthalmology* 92:676, 1985.
240. Scott AB, Collins CC, O'Meara DM, Jampolsky A: Paralysis of the lateral rectus muscle (abstract). *Invest Ophthalmol* 8:652, 1969.
241. Scott AB, Miller JM, Collins CC: Eye muscle prosthesis. *J Pediatr Ophthalmol Strabismus* 29:216, 1992.
242. Scott WE: Clinical study of saccadic eye movements. In Symposium on Strabismus: Transactions of the New Orleans Academy of Ophthalmology. St Louis, Mosby-Year Book, 1978, p 65.
243. Scott WE, Kraft SP: Classification and surgical treatment of superior oblique palsies: I. Unilateral superior oblique palsies. In Transactions of the New Orleans Academy of Ophthalmology, New York, Raven Press, 1986, p 15.
244. Scott WE, Kraft SP: Classification and surgical treatment of superior oblique palsies: II. Bilateral superior oblique palsies. In Transactions of the New Orleans Academy of Ophthalmology, New York, Raven Press, 1986, p 265.
245. Scott WE, Nankin SJ: Isolated inferior oblique paresis. *Arch Ophthalmol* 95:1586, 1977.
246. Simons BD, Saunders TG, Siatkowski RM, et al: Outcome of surgical management of superior oblique palsy: A study of 123 cases. *Binocular Vision Strabismus Q* 13:273, 1998.
247. Slee JJ, Smart RD, Viljoen DL: Deletion of chromosome 13 in Moebius syndrome. *J Med Genet* 28:413, 1991.
248. Souza-Diaz C: Surgical management of superior oblique paresis. In Moore S, Mein J, eds: Orthoptics, Past, Present, Future. Miami, Symposia Specialists, 1976, p 379.
249. Spencer F, Harcourt B: A paradoxical pattern of ocular movement associated with acquired superior oblique dysfunction. In Ravault AP, Lenk M, eds: Transactions of the Fifth International Orthoptic Congress, Cannes. Lyon, LIPS, 1983, 1984, p 261.
250. Spielmann A, Spielmann A: Correction d'un ptosis par déplacement horizontal de l'oeil controlatéral dans une paralysie du III. *Bull Soc Ophthalmol Fr* 1:45, 1992.
251. Spierer A, Barak A: Strabismus surgery in children with Möbius syndrome. *J Am Assoc Pediatr Ophthalmol Strabismus*, 4:58, 2000.
252. Stathacopoulos RA, Yee RD, Bateman JB: Vertical saccades in superior oblique palsy. *Invest Ophthalmol Vis Sci* 32:1938, 1991.
253. Steinbach MJ, Smith DR: Spatial localization after strabismus surgery: Evidence for inflow. *Science* 213:1407, 1981.
254. Stephens KF, Reinecke RD: Quantitative forced duction. *Trans Am Acad Ophthalmol Otolaryngol* 71:324, 1967.
255. Sternberg I, Ronen S, Arnon N: Recurrent, isolated, post-febrile abducens nerve palsy. *J Pediatr Ophthalmol Strabismus* 17:323, 1980.
256. Strachan I: An apparatus for measuring forces in strabismus. In Mein J, Stockbridge L, eds: Orthoptics: Past, Present and Future. New York, Stratton Intercontinental, 1975, p 123.
257. Sutcliffe J: Torsion spasms and abnormal postures in children with hiatus hernia, Sandifer's syndrome. *Prog Pediatr Radiol* 2:190, 1969.
258. Swan KC: False projection in comitant strabismus. *Arch Ophthalmol* 73:189, 1965.
259. Taylor JN: Surgical management of oculomotor nerve palsy with lateral rectus transplantation to the medial side of globe. *Aust N Z J Ophthalmol* 17:27, 1989.
260. Tian S, Lennerstrand G: Vertical saccadic velocity and force development in superior oblique paralysis. *Vision Res* 34:1785, 1994.
261. Traboulsi EI, Maumenee IH: Extraocular muscle aplasia in Moebius syndrome. *J Pediatr Ophthalmol Strabismus* 23:12, 1986.
262. Tschermak-Seysenegg A von: An Introduction to Physiological Optics. Translated by Boeder P. Springfield, IL, Charles C Thomas, 1952.

263. Tsaloumas MD, Willshaw HE: Congenital oculomotor palsy: Associated neurological and ophthalmological findings. *Eye* 11:500, 1997.
264. Urist M: Bilateral superior oblique paralysis. *Arch Ophthalmol* 49:382, 1953.
265. Valmaggia C, Zaunbauer W, Gottlob I: Elevation deficit caused by accessory extraocular muscle. *Am J Ophthalmol* 121:444, 1996.
266. Verslype LM, Folk ER, Thoms ML: Recurrent sixth nerve palsy. *Am Orthop J* 40:76, 1990.
267. Volpe NJ, Lessell S: Remitting sixth nerve palsy in skull base tumors. *Arch Ophthalmol* 111:1391, 1993.
268. Wallace DK, Noorden GK von: Clinical characteristics and surgical management of congenital absence of the superior oblique tendon. *Am J Ophthalmol* 118:63, 1994.
269. Warwick R: Representation of the extra-ocular muscles in the oculomotor complex. *J Comp Neurol* 98:449, 1953.
270. Waterhouse WJ, Enzenauer RW, Martyak AP: Successful strabismus surgery in a child with Moebius syndrome. *Ann Ophthalmol* 25:192, 1993.
271. Webb N: The visual system. In Doege TC, Houston TP, eds: *Guides to the Evaluation of Permanent Impairment*, ed 4. Chicago, American Medical Association, 1993, p 209.
272. Werner DB, Savino PJ, Schatz N: Benign recurrent sixth nerve palsies in childhood. *Arch Ophthalmol* 101:607, 1983.
273. Wesley RE, Pollard ZF, McCord CD: Superior oblique paresis after blepharoplasty. *Plast Reconstr Surg* 66:283, 1989.
274. Wiener M: Correction of defect due to third nerve paralysis. *Arch Ophthalmol* 57:597, 1928.
275. Wilson ME, Hoxie J: Facial asymmetry in superior oblique muscle palsy. *J Pediatr Ophthalmol Strabismus* 30:315, 1993.
276. Wolf J: The occurrence of retraction movement of the eyeball together with congenital defects of external ocular muscles. *Arch Ophthalmol* 29:297, 1900.
277. Young TL, Conahan BM, Summers G, Egbrt J: Anterior transposition of the superior oblique tendon in the treatment of oculomotor palsy and its influence on postoperative hypertropia. *J Pediatr Ophthalmol Strabismus* 37:149, 2000.
278. Zee D, Hain TC, Carl JR: Abduction nystagmus in internuclear ophthalmoplegia. *Ann Neurol* 21:383, 1987.
279. Ziffer AJ, Rosenbaum AL, Demer JL, Yee RD: Congenital double elevator palsy: Vertical saccadic velocity utilizing the scleral search coil technique. *J Pediatr Ophthalmol Strabismus* 29:142, 1992.
280. Znajda JP, Krill AE: Congenital medial rectus palsy with simultaneous abduction of the two eyes. *Am J Ophthalmol* 68:1050, 1969.

Special Forms of Strabismus

Special types of strabismus exist that, because of their unusual features, deserve discussion in a separate chapter. Some of these forms are caused by structural anomalies of the extraocular muscles or adjacent tissues. Their management varies according to their etiologic basis, and thus treatment often differs from that of ordinary types of comitant or noncomitant strabismus. For this reason, a discussion on treatment is included in this chapter after the description of the clinical findings for each of these special forms.

Retraction Syndrome (Duane Syndrome)

During the late nineteenth century, several papers were published that drew attention to a syndrome consisting of marked limitation or absence of abduction, restriction of adduction, retraction of the globe, and narrowing of the palpebral fissure on adduction. These manifestations were frequently associated with elevation or depression of the globe in adduction. Heuck¹⁶⁵ was the first to describe retraction of the globe in a patient with severe limitation of ocular motility. Stilling,³⁶³ Türk,³⁷⁷ Bahr,¹⁸ Sinclair,³⁴² Wolff,⁴⁰³ and others provided detailed descriptions of this syndrome, and when Alexander Duane⁹⁶ published his paper in 1905, 54 cases were available to him for analysis. Even though Duane never claimed priority for discovery of this entity, in the United States his

name has become attached to the retraction syndrome. In the European literature the syndrome is referred to, perhaps more appropriately, as the *Stilling-Türk-Duane retraction syndrome*.

Since these early descriptions, literally hundreds of papers dealing with the retraction syndrome have been published, which attests to the fact that this anomaly of ocular motility is by no means rare. The literature has been reviewed by various authors.^{4, 99, 173, 208, 231, 275, 276}

Laterality and Sex Distribution

There is general agreement that Duane syndrome is a more common occurrence in the left eye than in the right eye and also more common in females. Bilateral involvement is less common than unilateral occurrence. Only minor variations among the study results of different authors existed in large recent surveys.^{179, 198, 231, 236, 289, 302, 308, 411} These data are summarized in Table 21–1, which has been modified from a survey of the literature on Duane syndrome by DeRespinis and coworkers⁹⁰

TABLE 21–1. Sex Distribution and Laterality in 835 Patients with Duane Syndrome

Female	Male	Left Eye	Right Eye	Bilateral
58%	42%	59%	23%	18%

Modified from DeRespinis PA, Lapoto AP, Wagner RS, Guo S: Duane's retraction syndrome. *Surv Ophthalmol* 38:257, 1993.

and lists the data from major studies published during the past 90 years. No reasonable explanation has been offered for the preponderance of left-sided laterality and of the increased incidence of Duane syndrome in females.

Etiology

STRUCTURAL ANOMALIES. The etiology of the retraction syndrome has intrigued ophthalmologists for the past 90 years. In the older literature, most authors favored the view that congenital structural anomalies were the cause of the retraction phenomenon. Heuck,¹⁶⁵ while performing surgery on one of his patients, found a posterior insertion of the medial rectus muscle, which he thought to be the cause of retraction of the globe on adduction. Bahr,¹⁸ Apple,⁸ and Bielschowsky²⁷ shared this view, that a posteriorly inserted medial rectus muscle may act as a retractor bulbi.

We have observed a band that originated in the orbital apex and inserted 6 mm behind the medial rectus muscle in a patient with Duane syndrome, type I.²⁶¹ Türk³⁷⁷ believed that fixation of the globe by a nonelastic lateral rectus muscle was the cause of retraction on adduction. Many other authors, who during surgery found a fibrotic nonelastic lateral rectus muscle or restricting fibrous bands beneath the muscle insertion, agreed with this view.^{14, 208, 233, 258, 347}

The abnormal vertical eye movements that frequently occur with adduction were blamed, in the older literature, on oblique overaction. T. Duane and coworkers⁹⁸ believed that compensatory oblique overaction replaces the defective abductive action of the lateral rectus muscle. Parker²⁸⁰ thought that the vertical movement in adduction is caused by overaction of the vertical rectus muscles, which act as adductors if the medial rectus muscle is weak. Scott³³² and Souza-Dias³⁴⁶ offered an entirely different explanation for this phenomenon, one based on co-contraction of the horizontal muscles (see p. 464). As a matter of historical interest, the curious theory of Wolff⁴⁰³ should be mentioned. He blamed elevation or depression in adduction on the attachment of the globe to the optic nerve, which would cause resistance in the plane of retraction and pull the eye in a vertical direction.

Many investigators have reported finding an abnormal lateral rectus muscle during surgery, but only a few histologic reports are available in the literature. Krüger²⁰⁸ reported degenerative changes

in the lateral rectus muscle with an increase of fibrous tissue.

PARADOXICAL INNERVATION. Evidence accumulated from electromyographic studies has indicated that an innervational mechanism rather than anatomical abnormalities may be responsible for most cases of the retraction syndrome. Breinin³⁹ was first to describe paradoxical electrical behavior of the lateral rectus muscle in such patients, that is, absence of electrical activity in this muscle on abduction and active electric potentials on adduction. He evolved the theory, now shared by many others, that this anomalous co-contraction of the medial and lateral rectus muscles is the cause for retraction of the globe on adduction. Paradoxical electromyographic activity of the medial rectus muscle in patients with Duane syndrome, type I has also been reported.³¹⁸ Gross and coworkers¹⁴¹ reported absence of retraction in a patient with Duane syndrome, type II with electromyographically proven co-firing of medial and lateral rectus muscles on attempted adduction. These authors concluded from their findings that co-contraction of opposing muscles alone may not suffice to cause the retraction but that additional mechanical factors may play a role.

Breinin explained the abnormal activity of the lateral rectus muscle on adduction as an abnormally sensitized stretch reflex, a theory that cannot be upheld in view of the findings of Blodi and coworkers,²⁹ who demonstrated co-contraction in an unstretched lateral rectus muscle detached from the globe during surgery. Breinin's findings of *paradoxical innervation* were confirmed and enlarged on by many other investigations^{78, 173, 276, 325, 333} (Fig. 21-1). Strachan and Brown,³⁶⁴ in a series of patients with Duane syndrome, demonstrated a spectrum of abnormal electrical activity in the lateral rectus muscle ranging from paradoxical innervation to subnormal firing in abduction. Abnormal synergistic innervation between the medial rectus muscle and the superior and inferior rectus or oblique muscles also was demonstrated electromyographically, which may explain the vertical deviation in adduction observed in some patients with this condition,^{276, 325} although other explanations have been offered. Narrowing of the palpebral fissure on adduction is usually interpreted as a passive adjustment of the lids to the retracting globe. Other explanations for the eyelid findings include decreased innervation to the levator palpebrae on adduction¹¹⁰ and a reorganization of the central oculomotor pathways.²⁵⁰

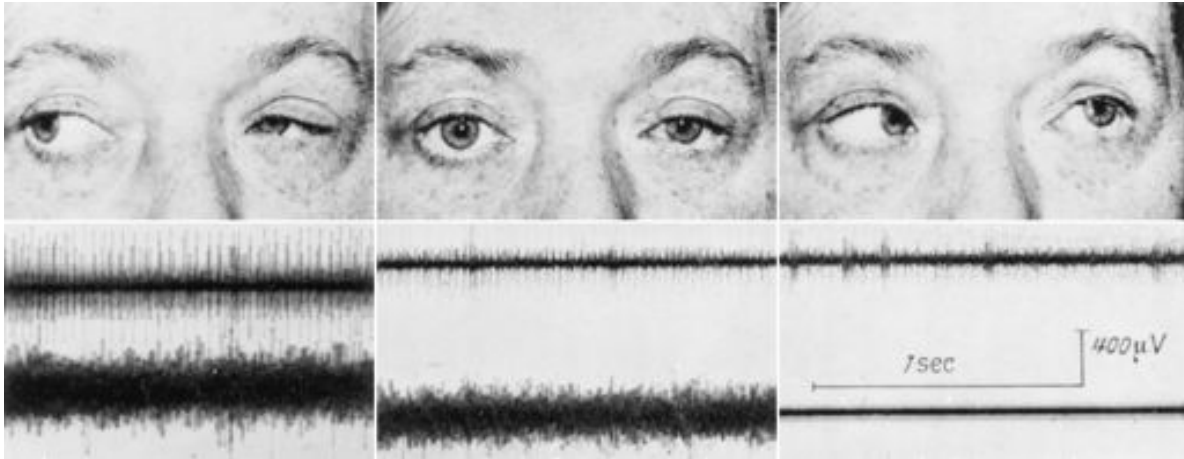


FIGURE 21-1. Simultaneous electromyographic recordings from left lateral rectus (*upper tracing*) and left medial rectus (*lower tracing*) muscles in a patient with Duane syndrome of the left eye. Note maximal firing of lateral rectus motor units in adduction and electric silence on attempted abduction (paradoxical innervation). (From Huber A, Esslen E, Klöti R, Marteret AC: Zum Problem des Duane Syndroms. *Graefes Arch Clin Exp Ophthalmol* 167:169, 1964.)

The currently favored theory is that in most instances the retraction syndrome is an innervational disturbance of brain stem origin rather than an anomaly caused by structural anomalies of the muscles. A case of *acquired bilateral retraction syndrome* in a 23-year-old woman with a brain stem tumor²⁶⁵ and another of a patient in whom co-contraction developed in both horizontal rectus muscles in adduction and downward gaze after a head injury³³³ lend credence to this hypothesis.

Hoyt and Nachtigäller¹⁶⁹ proposed that ocular retraction during adduction, as well as the electromyographic findings of synergistic innervation of medial and lateral rectus muscles, could be explained on the basis of substitute innervation of a paretic lateral rectus muscle by an extra branch from the oculomotor nerve.⁴²

Matteucci²³² described absence of the ipsilateral abducens nerve and hypoplasia of its nucleus in a well-documented case of Duane syndrome. However, he did not discuss innervation of the lateral rectus muscle, nor did he trace the terminal branch of the oculomotor nerve, as has been done in more recent studies.³⁷² More detailed clinicopathologic evidence of central nervous system anomalies in patients with the retraction syndrome was provided by two important studies from the Wilmer Institute at Johns Hopkins Hospital. In a patient with bilateral Duane syndrome, both abducens nuclei and nerves were absent from the brain stem and the lateral rectus muscles were partially innervated by branches from the oculomotor nerves.¹⁶⁷ In a second patient with unilateral Duane syn-

drome, these same findings were limited to the involved side.²⁴⁵ The findings were confirmed by additional reports. Mulhern and coworkers²⁵⁷ described absence of the right abducens nucleus in a patient with Duane syndrome, type III of the right eye and Parsa and coworkers²⁸⁶ described absence of the abducens nerve on magnetic resonance imaging (MRI) in Duane syndrome, type I.

According to Saad and coworkers³¹⁹ the clinical features of Duane syndrome may be explained by a failure to differentiate and to displace the abducens nucleus from the oculomotor nucleus in the human embryo of day 21 to day 26.

Clinicopathologic evidence, the number of patients with acquired retraction syndrome and brain tumor or trauma,^{270, 333} or on the basis of a nonspecific vasculitis,⁶ the frequent association of the gustolacrimal reflex (crocodile tears),^{78, 247, 304} anomalies of the vestibulo-ocular reflex, optokinetic nystagmus,¹³⁶ and auditory evoked responses¹⁸⁶ clearly place the seat of this anomaly in the brain stem.

HEREDITY. Hereditary patterns of Duane syndrome were mentioned by many investigators, and familial occurrence with dominant inheritance patterns^{66, 118, 200, 377, 385, 404} and Duane syndrome in monozygotic twins^{235, 315} have been described. A gene responsible for Duane syndrome and a dominant form of hydrocephalus has been identified and is located close to a gene causing the branchio-oto-renal syndrome.³⁸⁴ Other studies have identified abnormalities in chromosomes in patients with Duane syndrome^{9, 55, 64, 81, 384}

EMBRYOPATHY. In view of the high prevalence of ocular or systemic malformations associated with Duane syndrome, Cross and Pfaffenbach⁷⁹ proposed the intriguing theory that a common teratogenic stimulus at 8 weeks of gestation may be of etiologic significance in sporadic cases of Duane syndrome—a thought that had been expressed earlier by Krüger.²⁰⁸ Duane syndrome has been reported in connection with the fetal alcohol syndrome, which suggests damage to the developing abducens nuclei in the middle of the first gestational trimester.¹⁶⁶ A case of Duane syndrome was reported in a patient with a giant aneurysm of the vertebral basilar arterial junction.¹⁵⁵ The authors speculated that Duane syndrome may be caused by vascular hypofunction during the fourth to fifth week of embryogenesis. Convincing evidence that the etiology of the retraction syndrome may be teratogenic in nature is provided by the finding that it occurs frequently in patients afflicted with the *thalidomide syndrome*.^{10, 243, 244}

At this time it appears that several etiologic factors may be involved in the retraction syndrome, and it is doubtful that a single mechanism is responsible for this disturbance of ocular motility. The reported anatomical changes involving the horizontal rectus muscles imply a peripheral structural etiology in some cases, and such findings cannot be ignored. On the other hand, the electromyographic evidence of paradoxical innervation of the lateral rectus muscle and the clinicopathologic correlations cited above are equally convincing. One must also consider the possibility that some of the anatomical anomalies observed during surgery could be secondary to a primary innervational anomaly. For instance, we have been impressed by the frequent finding of a tight lateral rectus muscle at the time of surgery in Duane syndrome, types I and III.²⁶⁴ The possibility must be entertained that this muscle loses its

elasticity from lack of contraction, which would contribute to the retraction of the globe on attempted adduction. T. Duane and coworkers⁹⁸ reported narrowing of the palpebral fissure and retraction of the globe in abduction following fracture of the medial orbital wall with entrapment of the medial rectus muscle. We have seen retraction on attempted adduction after massive conjunctival scarring following removal of a dermolipoma from the temporal aspect of the bulbar conjunctiva of the left eye (Fig. 21–2). Thus, retraction can be explained on a mechanical basis alone to which an innervational factor may be added in cases of co-contraction.

Clinical Findings and Diagnosis

The retraction syndrome in its classic form is characterized by the following features:

1. Congenital onset (acquired forms are rare)
2. Severe limitation of abduction
3. Slight limitation of adduction
4. Globe retraction and narrowing of the palpebral fissure on adduction
5. Commonly associated elevation or depression in adduction

Owing to the lack of the patient's cooperation the diagnosis may be difficult to make in infants. Retraction, elevation, or depression of the globe on adduction may not be detected until early childhood. We have seen several instances in which *Duane syndrome, type I, was mistaken for essential infantile esotropia*. Resection of the lateral rectus muscle in such patients will increase retraction of the globe on adduction and must be avoided. The differential diagnosis should also include congenital abducens paralysis⁶⁰ even though in such cases the angle of esotropia in primary position is usually much larger than in the retraction syndrome.

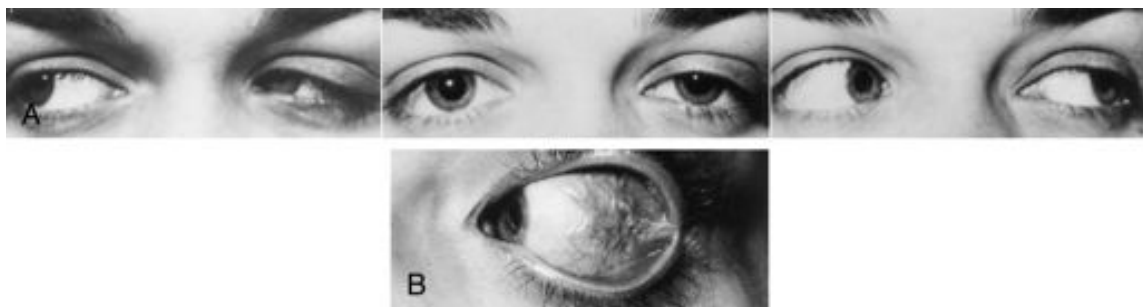

FIGURE 21-2. A, Acquired retraction syndrome of the left eye. B, After removal of conjunctival dermoid with subsequent scarring.

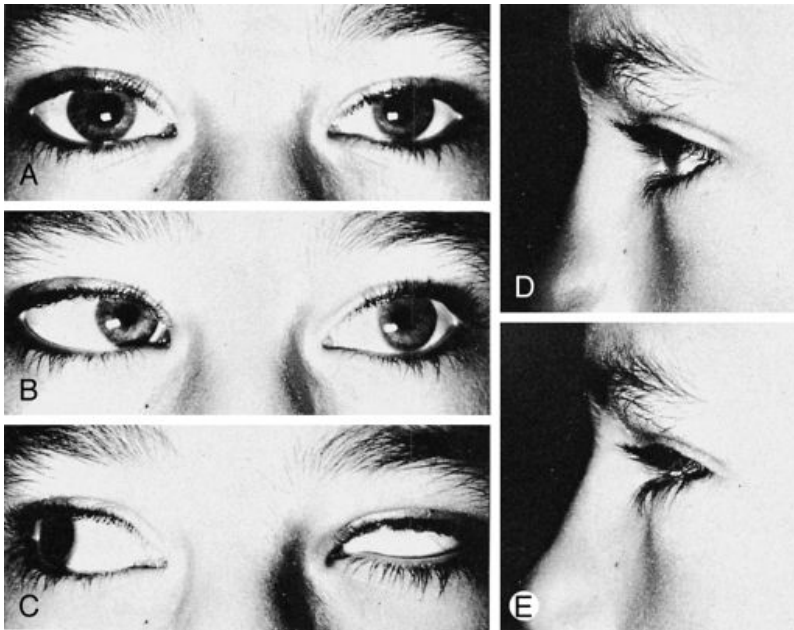


FIGURE 21-3. Duane syndrome, type I, left eye. *A*, No anomaly in primary position. *B*, Limited abduction. *C*, Narrowing of lid fissure and upshoot. *D*, Lateral view of lid fissure with the left eye in primary position. *E*, Retraction of the left eye on adduction. (From Noorden GK von: Atlas of Strabismus, ed 4. St Louis, Mosby-Year Book, 1983.)

Variations of this special form have been described.^{173, 195, 226, 328} The first case of *vertical retraction* was reported by Böhm (1845)³² in a 40-year-old woman who from birth was unable to adduct or abduct her left eye. Abduction of the right eye caused elevation and retraction of the left eye, and on adduction of the right eye the left eye depressed. Brown⁴⁵ reported retraction of both eyes in upward gaze and Khodadoust and von Noorden¹⁹⁵ observed retraction on downward gaze in two siblings. It is likely that the cause of this retraction was fibrosis of the superior or inferior rectus muscles rather than co-contraction. However, retraction in upward gaze has also been reported in a patient with a classic bilateral Duane syndrome, type I.³⁴⁸ Pesando and coworkers²⁸⁸ reported a case of unilateral vertical retraction, and Osher and coworkers²⁶⁹ described acquired retraction of the globe on attempted gaze opposite the field of action of the involved muscles in patients with infiltrative myopathy caused by dysthyroid eye disease, inflammatory myositis, and neoplasms. Weinacht and coworkers³⁹³ showed lateral rectus muscle firing activity during upgaze and downgaze in a rare variant of a vertical retraction syndrome. Huber¹⁷¹ suggested the following useful classification to include most clinical variations in this entity:

Duane I: Marked limitation or complete absence of abduction; normal or only slightly defective adduction; narrowing of the palpebral fissure and retraction on adduction;

widening of the palpebral fissure on attempted abduction (Fig. 21-3)

Duane II: Limitation or absence of adduction with exotropia of the affected eye; normal or slightly limited abduction; narrowing of the palpebral fissure and retraction of the globe on attempted adduction (Fig. 21-4)

Duane III: Combination of limitation or absence of both abduction and adduction; re-

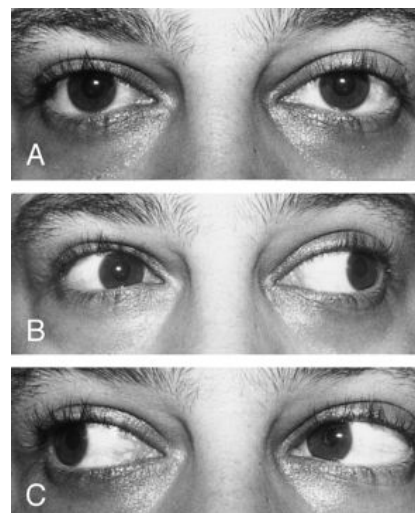


FIGURE 21-4. Duane syndrome, type II, right eye. *A*, 15° exotropia in primary position. *B*, Narrowing of the right lid fissure and limitation of adduction of the right eye in levoversion. *C*, Normal abduction and widening of the lid fissure on dextroversion. (From Noorden GK von: Atlas of Strabismus, ed 4. St Louis, Mosby-Year Book, 1983.)

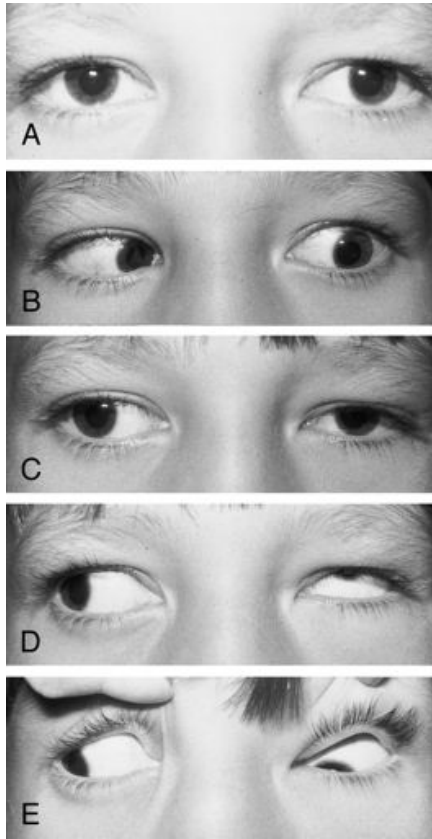


FIGURE 21-5. Duane syndrome, type III, left eye. *A*, Face turn to the right and fused with the head position. *B*, 20° exotropia in primary position; imitation of adduction and abduction of the left eye with widening of the left palpebral fissure on levoversion and narrowing on dextroversion; upshoot of the left eye when attempting to adduct with the right eye elevated and downshoot when attempting to adduct in depression. *C*, Retraction of the globe on attempted adduction (*lower photograph*). (From Noorden GK von: *Atlas of Strabismus*, ed 4. St Louis, Mosby-Year Book, 1983.)

traction of the globe and narrowing of the palpebral fissure on attempted adduction (Fig. 21-5)

Type I is by far the most common (78%), followed in order of frequency by types III (15%) and II (7%), according to data from different authors and compiled by DeRespinis and coworkers.⁹⁰ Not only is Huber's classification the most useful one clinically, but it is supported by electromyographic documentation. Huber found paradoxical innervation in association with all three types of Duane syndrome.¹⁷¹ His work was confirmed by Maruo and coworkers²³¹ who obtained electromyograms in 126 patients with the various types of this disorder. In those with type I the peak of innervation of the lateral rectus muscle occurs on adduction and the minimum on abduction. In those with

type II the lateral rectus muscle fires maximally in abduction and adduction, and type III is characterized by simultaneous electrical activity of both the medial and lateral rectus muscles on adduction and abduction. Clear distinction between the different types is not always possible. For instance, a moderate limitation of abduction may be present in type II and other forms of "mixed" types may occur.

A *bilateral* case of Duane syndrome, type I is shown in Figure 21-6.

In the classic retraction syndrome, strabismus may or may not be present with the eyes in primary position. If strabismus is present, esotropia occurs more frequently than exotropia in patients with Duane syndrome, types I and III, and exotropia is a more frequent occurrence in those with type II.^{85, 232} Many patients adopt a face turn to maintain single binocular vision. Complaints of diplopia are rare, except in the rare, acquired case⁶ and in view of the difficulties encountered in plotting suppression scotomas in such patients it has been suggested that the second image is ignored rather than suppressed.^{193, 268}

Of special interest is the frequently associated *upshoot* and *downshoot of the adducted eye*, which at times causes a cosmetic problem of almost grotesque proportions; namely when the cornea of the adducted eye disappears from view (Figs.

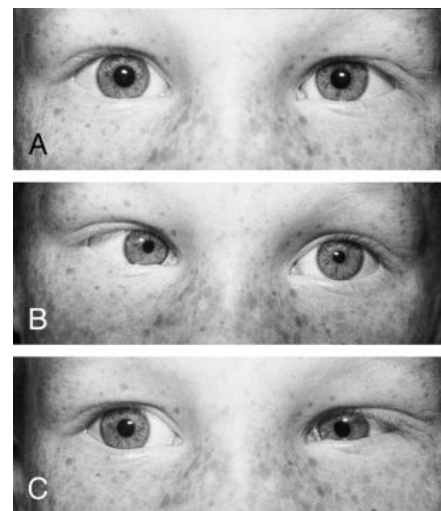


FIGURE 21-6. Bilateral Duane syndrome, type I. *A*, 10° in primary position. *B*, Narrowing of the right palpebral fissure, inability to abduct the left eye, and widening of left palpebral fissure on attempted abduction. *C*, Widening of the palpebral fissure and limitation of abduction of the right eye, narrowing of the left palpebral fissure, and retraction of the left globe on adduction. (From Noorden GK von: *Atlas of Strabismus*, ed 4. St Louis, Mosby-Year Book, 1983.)

21–3C and 21–7A). At first glance such patients appear to have increased overaction of the inferior or superior oblique muscles. Experience has taught us, however, that surgical weakening procedures on these muscles is entirely ineffectual. Scott³³² pointed out that the high muscle tension caused by co-contraction of the horizontal rectus muscles or by structural tightness of the lateral rectus muscle when the medial rectus muscle contracts results in a vertical effect by allowing the muscles to slide over the globe (“bridle” or “leash effect”) when contracting (see also Jampolsky¹⁸⁵). For instance, co-contraction of the medial and lateral rectus muscles, as occurs in adduction with Duane syndrome, type I, will increase the elevating effect of the horizontal muscles of a slightly elevated eye and cause upshoot, and the depressing effect of a slightly depressed eye will cause downshoot. Co-contraction of the horizontal muscles may enhance this effect not only in horizontal gaze but also when the eye elevates or depresses, as illustrated by Scott and Wong³³³ in their electromyographic studies. However, it has been shown by computed tomography (CT) scanning³³⁹ and MRI³⁰ that *it is actually not the muscles that slide over the surface of the globe* (as had been suggested by Scott³³²) *but the globe that slips under the muscles*, because the vertical displacement of the horizontal muscles during ele-

vation and depression in relation to the orbital wall is negligible in most but not in all cases of Duane syndrome.²⁴² It is because the horizontal rectus muscles maintain their vertical position with reference to the orbital walls that elevation of the eyes will move the center of rotation of the globe below the planes of the horizontal rectus muscles and depression will move this center above the muscle planes. This explains the bridle effect that occurs during co-contraction of these muscles when the eye is slightly elevated or depressed.

To control the change of the relationship between the muscle planes and the center of rotation of the globe Scott and Wong³³³ suggested *retro-equatorial fixation* (posterior fixation suture) or a *maximal recession of both horizontal rectus muscles* (see also Souza-Dias³⁴⁶). The results achieved with this surgery suggest that Scott’s and Souza-Dias’s theory is correct since we found posterior fixation sutures to be effective in decreasing the upshoot and downshoot in patients with Duane syndrome, types I and III²⁶⁴ (Fig. 21–7B). However, we have found that the application of posterior fixation may be technically difficult in these patients because of mechanical restriction of adduction. *Recession of both horizontal muscles is equally effective* and technically simpler to perform.^{263, 346} Moreover, it has the added desirable

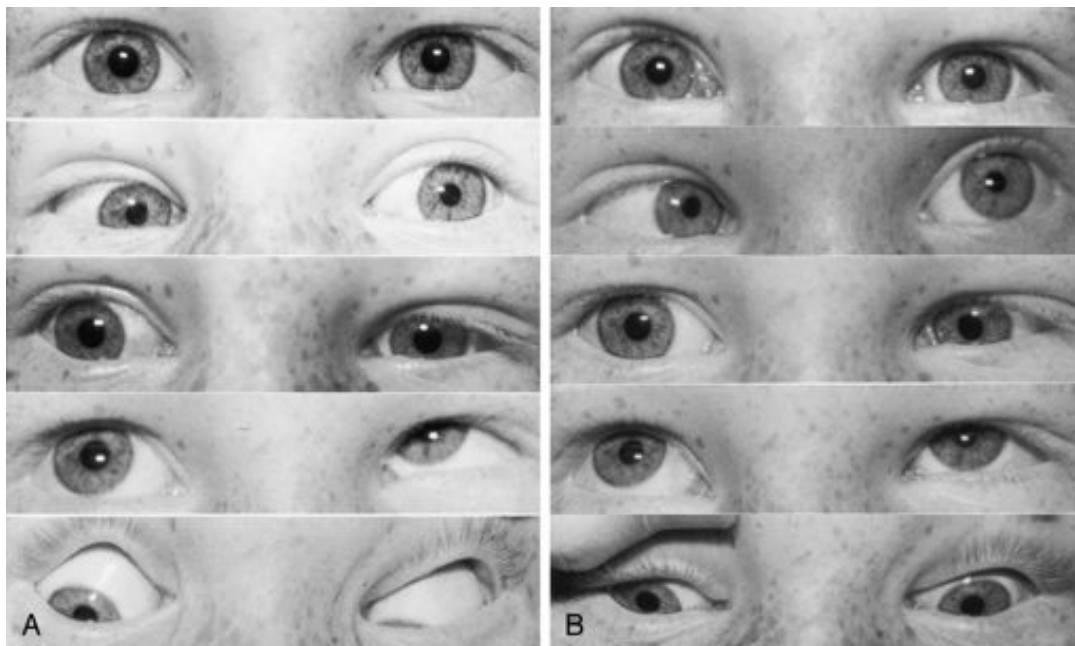


FIGURE 21–7. A, Preoperative findings in bilateral Duane syndrome, type I, of both eyes with upshoot and downshoot of the left adducted eye. Note that this phenomenon occurs only when the fixating right abducted eye is slightly elevated or depressed. B, Postoperative findings after retro-equatorial myopexy of the left medial (14 mm) and lateral rectus (17 mm) muscles. Note significant decrease of upshoot and downshoot of the adducted left eye.

effect of reducing retraction in adduction. It has also been suggested that the lateral rectus tendon be split into a Y configuration that increases the width of insertion and decreases the bridle effect.^{185, 311}

Much emphasis was placed in the past on the high prevalence of amblyopia and anisometropia in patients with Duane syndrome. This concern originated from the original paper of Duane⁹⁶ and a report by Kirkham¹⁹⁹ that amblyopia was present in 40% of his patients. However, more recent studies have shown that the prevalence of anisometropia in Duane syndrome is no higher than in a normal population.^{232, 267, 310, 373}

Another feature of the retraction syndrome that deserves the special attention of the clinician is its frequent association with other ocular lesions and *systemic congenital malformations*. Among the ocular anomalies listed by Sachsenweger^{320, p.283} are dysplasia of the iris stroma, pupillary anomalies, cataracts, heterochromia, persistent hyaloid arteries, choroidal colobomas, distichiasis, crocodile tears, microphthalmos, and many others. Numerous systemic anomalies have been described.^{99, 289, 320} Among these are Goldenhar's syndrome,^{289, 290, 382} facial hemiatrophy,³³⁷ dystrophic defects such as the Klippel-Feil syndrome, arthrogyriposis multiplex congenita,²⁴⁰ cervical spina bifida, cleft palate, sensorineural hearing deficits,^{198, 309} Chiari's type I malformation,^{295, 410} deformities of the external ear, and anomalies of the limbs, feet, and hands.

These findings emphasize that a thorough ocular examination is mandatory in all patients with a retraction syndrome and that systemic malformations, especially hearing defects, must be ruled out by a general physical examination in each case.

Therapy

The results of surgical treatment of the retraction syndrome often have been disappointing. For this reason, *we prefer not to operate when binocular vision is present with the eyes in primary position or if it can be maintained with only a slight head turn*. Surgery is indicated only when there is a significant deviation in primary position or if the face turn is intolerable from a cosmetic or functional point of view. The patient must be informed that there is no surgical procedure that will restore normal ocular excursions in all gaze positions. When esotropia in the primary position causes a significant face turn in Duane syndrome, type I,

we perform a *5-mm recession of the ipsilateral medial rectus muscle* (see also Kaufmann and Milkowitz¹⁹²). To decrease retraction on adduction a recession of the lateral rectus muscle may be added.^{100, 222} The recessions must be asymmetrical to counteract the esotropia in primary position and the face turn.³⁵²

Although these operations cannot be expected to improve motility in abduction in patients with Duane syndrome, type I, they are highly successful in eliminating the anomalous head posture.²⁹⁶ The patient should be informed that this operation is likely to further restrict ocular motility by decreasing adduction. A posterior fixation applied to the contralateral medial rectus muscle^{220, 327, 350} or both horizontal rectus muscles³⁴⁹ is said to improve comitance. We have not been impressed with the results of this combined surgical approach and no longer use it.

Several authors have recommended transposing the vertical rectus muscles to the insertion of the lateral rectus muscle in Duane syndrome, type I. Gobin,¹²⁹ in reporting his results in 67 patients, noted an average improvement of abduction of 20°, but limitation of adduction occurred in most of his patients. Molarte and Rosenbaum²⁴⁶ reported improvement of esotropia, abduction, head turn, and field of single vision. To avoid the complication of a surgically induced vertical strabismus, this procedure may be modified by putting the vertical muscles on adjustable sutures.²¹⁴ Foster¹²⁰ augmented the transposition by fixating the transposed muscles with nonabsorbable sutures 16 mm from the limbus and adjacent to the lateral rectus muscle insertion. Esotropia in primary position and face turn disappeared in most patients and he recorded the same improvement of abduction as Gobin did but, curiously, did not encounter an adduction deficit of the operated eye. One of us (E.C.) has observed fixation of the globe in abduction after the transposition procedure for Duane syndrome, type I.

Clearly, this approach, with or without scleral fixation of the transposed muscles, deserves further study since an isolated recession of the medial rectus muscle has no effect on the diplopia occurring when the involved eye attempts to abduct.

Resection of the lateral rectus muscle in Duane syndrome, type I should be avoided under any circumstances since this may increase retraction of the globe on adduction. In patients with an extreme head turn caused by Duane retraction syndrome, type I, de Decker⁸⁷ recommended a

muscle transposition procedure on both eyes according to Kestenbaum.

For *exotropia* associated with the retraction syndrome, Papst and Stein²⁷⁹ recommended recession of the lateral rectus muscle of the involved eye or recession of the lateral rectus muscle and resection of the medial rectus muscle in the noninvolved eye. This approach has worked well in our hands.

A special therapeutic challenge exists in patients with Duane syndrome, type III (limitation of adduction and abduction), who are esotropic with the involved eye in abduction and exotropic with the involved eye in adduction and who maintain an anomalous head posture. Spielmann and coworkers³⁵⁰ reported good results with a posterior fixation suture, with or without recession of the horizontal rectus muscles of the sound eye in these cases. We mentioned earlier in this chapter the beneficial effect of recession of both horizontal rectus muscles on up- and downshoot of the adducted eye and on the retraction in Duane syndrome.

It is clear from the preceding paragraphs that no rigid rules exist regarding surgical treatment of the retraction syndrome and that an individualized approach taking into account coexisting horizontal or vertical deviations is necessary.²⁰⁶

Brown Syndrome

In 1928 Jaensch described limitation of elevation of the adducted eye after a skiing accident in which the patient's face struck the tip of a ski.¹⁸² The clinical picture resembled a paralysis of the inferior oblique muscle but the forced duction test showed resistance to elevation of the adducted eye. Jaensch suspected a traumatic adhesion between the trochlea and the globe anterior to or at the equator. Such an adhesion would not interfere with depression of the globe but would present an obstacle to elevation in adduction. Thus Jaensch was first to call attention to a pseudoparesis of the inferior oblique muscle as a result of acquired structural anomalies (see also Hass,¹⁵³ and Stein³⁶¹) involving the superior oblique tendon. In 1950 Brown⁴⁵ described an identical anomaly of ocular motility which, unlike the case of Jaensch's patient, occurred on a *congenital* basis. He suspected the existence of a congenitally short superior oblique tendon sheath in a patient who could not elevate the adducted eye and in

whom elevation in adduction was restricted during the forced duction test. During surgery the sheath was isolated from the tendon, and tension on the sheath was demonstrated easily during passive elevation of the globe. When the sheath was severed, tension was no longer present.

Since Brown's original descriptions^{45, 46} in the 1950s, it has become clear, however, that there are many anomalies involving the superior oblique muscle, its tendon and surrounding tissue, or the trochlea that may contribute to a mechanical restriction of elevation of an adducted eye. For this reason the older term "superior tendon sheath syndrome" has been abandoned in favor of *Brown syndrome* although in light of the historical facts the name *Jaensch-Brown syndrome* has also been suggested.²⁵⁵ Brown syndrome consists of consistent and variable features which are listed in Table 21-2. A patient with Brown syndrome is shown in Figure 21-8.

Incidence, Laterality, and Heredity

The incidence of Brown syndrome in a strabismic population is low; in a review of 2583 consecutive strabismus patients, Crosswell and Haldi⁸⁰ encountered only six cases. The syndrome is usually unilateral but may occur in both eyes in about 10% of the cases.^{50, 80, 221, 398} Familial occurrence has been described^{137, 146, 249} and mirror reversal was observed in monozygotic twins.^{117, 191} Caldeira⁵⁶ reviewed the literature on twin studies and reported the syndrome in dizygotic female twins. The syndrome may present in a congenital, acquired, constant, or intermittent form. Despite Brown's original impression that the condition occurs more often in females and in the right eye, subsequent reports have failed to substantiate a sex or laterality predilection.³⁹⁸

TABLE 21-2. Clinical Features of Brown Syndrome

Consistent Features	Variable Features
Absence of elevation in adduction	Mild limitation of elevation from primary position
Normal elevation in abduction	Downshoot in adduction
Forced ductions show severe mechanical restriction on attempts to elevate the adducted eye; no limitations of elevation in abduction	Widening of lid fissure
	Hypotropia in primary position
	Compensatory head posture

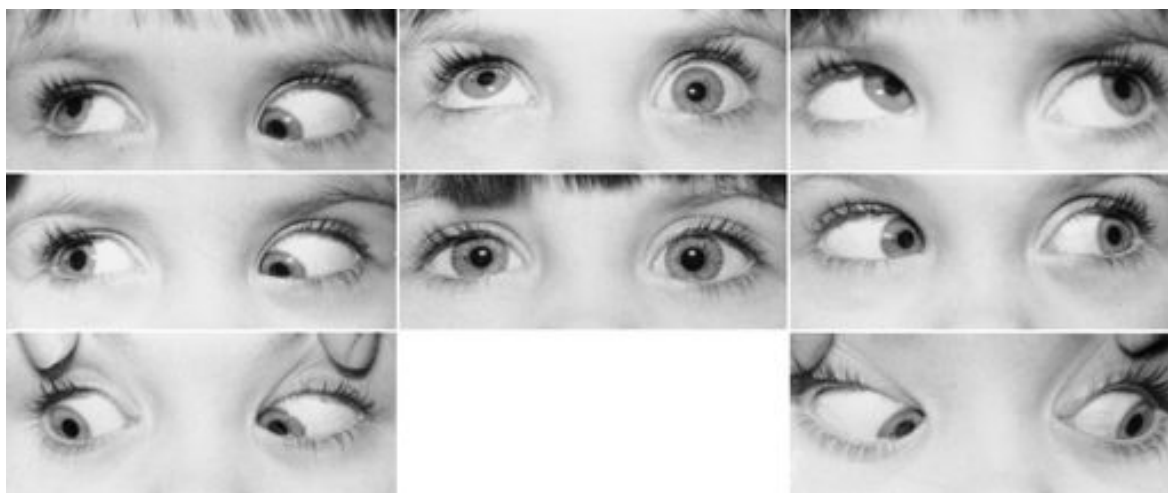

FIGURE 21-8. Brown syndrome of the left eye. Inability to elevate the left eye is most marked in adduction but is also present in primary position. Normal elevation in abduction. A 10° left hypotropia was present in primary position.

Associated Anomalies

Brown syndrome occurs, as a rule, as an isolated anomaly. However, exceptions have been reported, including an association with superior oblique palsy, dissociated vertical deviation,²⁹³ and contralateral inferior oblique overaction.⁶⁸ A patient with Hurler-Scheie syndrome developed an acquired Brown syndrome,³⁴ and other anomalies listed in the comprehensive review on Brown syndrome by Wilson and coworkers³⁹⁸ include crocodile tears, Marcus Gunn synkinetic movements, coloboma of the choroid, and congenital cardiac anomalies. The infrequent occurrence of associated anomalies raises the distinct possibility that these are coincidental findings rather than true associations.

Natural History

Spontaneous remission of an apparently congenital Brown syndrome was reported by several authors.^{3, 48, 74, 139, 188, 221, 391} Spontaneous resolution occurred in 6 of 60 patients and significant improvement in another 6 patients after an average follow-up of 46 months.¹⁸⁸ Even more impressive are the results of a longitudinal long-term study by Gregersen and Rindziunski¹³⁹: of 10 patients with Brown syndrome diagnosed during the first 2 years of life and followed for an average of 13 years, 3 patients had complete recovery of normal ocular motility. The remaining patients had a decrease of the hypotropia and depression of the adducted eye. In this connection, it is of interest that this syndrome is infrequently observed in

adults. Of the 126 patients described by Brown,⁵⁰ only 14 were 13 years of age or older.

Etiology

As has been mentioned above and will be further discussed in the following paragraphs, mechanical limitation of elevation in adduction has more than one cause. For this reason Helveston¹⁵⁸ suggested a *generic* description of the syndrome according to which the inability to elevate the adducted eye is due to a failure to increase the distance between the trochlea and the superior oblique tendon insertion. He further described the complex machinery consisting of muscle, tendon, and trochlea which is especially vulnerable to developmental and acquired defects.¹⁶⁰

ANOMALIES OF TENDON SHEATH. Brown described the mechanism as follows:

The tendon sheath of the superior oblique, according to Whitnall, is fixed to and terminates at the pulley. The effect of the two fixed points, the attachment of the sheath at the pulley and its attachment at the scleral insertion of the fused tendon and sheath, results, if the tendon is short, in restriction of elevation in the nasal field. The linear distance from the pulley to the insertion of the superior oblique muscle increases on adduction of the eye and decreases on abduction. Therefore if the tendon sheath is taut when the eye is in the primary position, adduction will be possible only as the eye is depressed. Normally this sheath acts as a check-ligament for the inferior oblique muscle.⁴⁷

Parks²⁸² observed that the superior oblique tendon does not have a sheath at all and that the term “superior tendon sheath syndrome” introduced by

Brown is a misnomer. Parks reasoned that the tissue surrounding the tendon is actually a sleeve consisting of Tenon's capsule and that this sleeve may have been mistaken by Brown for a sheath.

We do not argue that what has been described by Fink^{115, 116} and by Berke²² as a sheath may not be a sheath after all. However, we cannot agree that this tissue, whatever its nature may be, is altogether blameless for causing restriction, as current authors would have it. Although we no longer use this method, surgical stripping of the sheath or pseudosheath, leaving the tendon proper intact, has relieved the restriction in some cases of Brown syndrome operated on by us. The normalization of the forced duction test after this tissue was dissected was often dramatic. Brown⁵⁰ achieved full correction of the motility defect in 5 of 26 patients operated on in this manner.

Soon after Brown's original description it became apparent, however, that stripping of the peritendinous tissue was not always effective in relieving the restriction of ocular motility.^{50, 284} Ophthalmologists had also become aware that the syndrome occurred in an acquired and intermittent form or resolved with the passage of time. These features are incompatible with a congenital anomaly of the tendon sheath. In 1973, therefore, Brown began to distinguish between a true and a simulated syndrome.⁵⁰ The *true syndrome* includes only those patients who have a congenitally short anterior tendon sheath. A *simulated sheath syndrome* with identical clinical features that includes all acquired cases may be caused by other factors such as anomalies of the tendon itself or of the trochlea.

ANOMALIES OF TENDON OR TROCHLEA.

Thickening of the muscle entering the trochlea, trauma, or inflammatory changes involving the trochlea or the region adjacent to it; developmental structural anomalies of the trochlea; and congenital or iatrogenic shortening of the superior oblique tendon are some of the factors to be considered in the etiology of Brown syndrome.

TIGHT TENDON. Crawford⁷⁶ proposed that the cause of a "true" Brown syndrome is a tight tendon and reported excellent surgical results after cutting the tendon just medial to the superior rectus muscle rather than merely cutting the sheath (see also Jakobi¹⁸¹). Parks²⁸³ made similar observations and the uniformly good results reported after tenectomy of the superior oblique support the current view that most cases of constant congenital

Brown syndrome are caused by an abnormal tightness of the muscle-tendon complex. Spontaneous limitation of elevation in adduction in the wake of an acquired superior oblique paralysis, presumably caused by a fibrotic tendon, has been discussed in Chapter 20.

IMPAIRED SLIPPAGE OF THE TENDON THROUGH THE TROCHLEA.

Girard¹²⁷ reported a patient with Brown syndrome in whom, on repeated attempts to elevate the eye in adduction, sudden release of the restriction occurred and full motility of the globe was restored. He stated that a congenital anomaly of the tendon may have been the cause of the restriction. Similar instances of intermittent Brown syndrome were reported by other authors,^{41, 48, 67, 119, 133, 134, 213, 313, 322} and we have observed patients with Brown syndrome who were unable to elevate the eye from a position of adduction, but who had no restriction of ocular motility when the eye was first elevated in abduction and then, while maintaining the elevation, moved nasalward into adduction. We have seen others who relieved vertical diplopia caused by Brown syndrome by applying *digital pressure* to or massaging the region of the trochlea. Leone and Leone²¹⁹ followed a patient with apparently constant congenital Brown syndrome. After 15 years of observation the patient began to exercise elevation of the adducted eye and was eventually able to do so with an *audible click*. Roper Hall³¹³ reviewed 18 cases of what he termed the *superior oblique click syndrome* (see also Folk et al.¹¹⁹). Obviously, the mechanism of these intermittent forms of Brown syndrome must be an impairment of slippage of the tendon through the trochlea caused by a retrotrochlear thickening of the tendon or anomalies of the trochlea itself.

That impaired slippage of the tendon through the trochlea may also occur on an *acquired* basis was shown by Stein,³⁶¹ who reported a patient in whom typical features of Brown syndrome developed after a blunt injury to the eye. Surgical exploration revealed a blood cyst in the sheath of the superior oblique tendon. After removal of this lesion, function returned to normal. Cysts in the reflected tendon were also observed by Helveston¹⁵⁹ who reported resolution of Brown syndrome after their dissection.

Sandford-Smith³²³ suggested that hypertrophy and constriction of the trochlea and tendon sheath associated with *localized swelling* of the tendon (stenosing tenosynovitis) may cause Brown syndrome, and acquired Brown syndrome, usually

with spontaneous reversal, has been reported in children³⁹¹ and adults^{20, 196, 341} as a manifestation of rheumatoid arthritis or pansinusitis.³²⁶ MRI in such patients shows fibrosis of the superior oblique tendon, apparently thought to be caused by chronic inflammation.³⁷¹

Beck and Hickling²⁰ suggested treating such patients with *local injections of corticosteroids*. Wright and coworkers⁴⁰⁹ reported negative findings on pathologic examination of the superior oblique tendon, trochlea, and superior oblique muscle in a patient with acquired inflammatory Brown syndrome and an audible click on elevating the adducted eye. We have followed several patients with acquired Brown syndrome. Among the more unusual ones were a 43-year-old man with episcleritis who developed a transient inability to elevate the adducted eye.²⁶² Forced duction tests were positive, and spontaneous remission occurred after 2 weeks. Typical Brown syndrome developed in a second patient during her third month of pregnancy. No improvement of her condition occurred during 3 years of observation. Postpartum acquired Brown syndrome has also been reported⁶⁵ and a comparison with the carpal tunnel syndrome comes to mind.

DEVELOPMENTAL ANOMALIES OF THE TROCHLEA. Helveston and coworkers^{158, 161} studied the anatomy and physiology of the human trochlea in cadaver specimens and described a bursa-like structure between the vascular sheath of the tendon and the trochlear saddle. They proposed that excess fluid accumulation or concretion in this bursa-like space could cause limitation of movement through the trochlear tunnel, causing an acquired Brown syndrome. Wilson and coworkers³⁹⁸ suggested that if the telescoping movement of the tendon described by Helveston and his group were interfered with by an intrinsic anomaly of the trochlea or the tendon, Brown syndrome would result.

Sevel,³³⁴ in a developmental study of the extraocular muscles, raised the interesting possibility that persistence of embryonic trabecular connections between the superior oblique tendon and the trochlea may account for Brown syndrome. Under normal circumstances, only fine remnants of these trabeculae remain and act as tethering strands to control and limit excursions of the tendon in the trochlea.³³⁵

ANOMALY OF THE SUPERIOR OBLIQUE MUSCLE. Gradual onset of a pseudo-Brown syndrome

occurred in a 62-year-old man who developed a metastasis from a carcinoma of the prostate to his superior oblique muscle.³³

ANOMALIES OF INFERIOR OBLIQUE MUSCLE AND ADJACENT STRUCTURES. Girard¹²⁷ described a patient with all the features of Brown syndrome in whom dissection of the superior oblique tendon sheath had no effect; however, after a dense fibrous attachment was severed that extended from the insertion of the inferior oblique muscle to the lateral wall of the orbit, all resistance to passive elevation of the globe in adduction disappeared. Zipf and Trokel⁴¹² observed two patients with restricted elevation in adduction following a blow-out fracture of the orbital floor. Surgical exploration revealed incarceration of the inferior orbital tissue in the fracture site.

PARADOXICAL INNERVATION. Analogous to the findings in Duane retraction syndrome is the discovery of Papst and Stein,²⁷⁸ who, in two patients with Brown syndrome, demonstrated paradoxical innervation of the superior oblique muscle on attempts to elevate the eye. Feric-Swiwerth¹¹⁴ reported similar results in one patient in whom simultaneous electromyographic recordings were obtained from the superior and inferior oblique muscles. However, these findings could not be confirmed by Catford and Hart,⁶² who demonstrated electric silence on recording from the superior oblique muscle and maximal activity from the inferior oblique muscle in patients who attempted elevation in adduction. Moreover, if this mechanism would prevail in Brown syndrome, one would expect the forced duction test to become negative with the patient under anesthesia. This is never the case in patients with true Brown syndrome.

POSTOPERATIVE: AFTER SUPERIOR OBLIQUE TUCKING. Girard¹²⁷ and Hervouet and Chevannes¹⁶² each described the appearance of Brown syndrome as a result of their tucking the superior oblique tendon. We have observed this complication in several patients after the tucking operation. Spontaneous improvement occurred in some but not all of them, and persistent diplopia in upward gaze may become a significant problem. Excessive tucking can be avoided by performing a forced duction test at the end of the procedure. The tuck must be undone when there is more than a moderate elastic resistance to elevation of the adducted eye. We believe that another cause of a postopera-

tive Brown syndrome is suturing the tucked tendon back to the sclera. Since we stopped doing this we have no longer encountered this complication.

TRAUMA. As mentioned above direct trauma to the trochlear region can cause restriction of elevation in adduction, often combined with restriction of depression. The “canine tooth syndrome” of Knapp²⁰¹ falls into this category and numerous other cases of traumatic Brown syndrome have been reported.³⁹⁸ Surgical trauma has emerged as another cause of Brown syndrome. We have observed one case after cosmetic blepharoplasty and another patient developed the syndrome after a double-plate Molteno implant.⁹³

SECONDARY TO PARALYSIS OF THE INFERIOR OBLIQUE MUSCLE. There are those who believe that fibrosis of the sheath of the superior oblique tendon is the result of primary paralysis of the inferior oblique muscle.^{274, 380} This concept cannot be upheld in view of the postoperative finding of normal elevation in adduction, of a normal electromyographic innervational pattern of the inferior oblique muscle,^{40, 62} and of normal saccadic velocity in patients with Brown syndrome.²³⁸

Diagnosis and Differential Diagnosis

The clinical manifestations of Brown syndrome are listed in Table 21–2. The direction of a head tilt, if present, and the position of the chin are similar as in paralysis of the inferior oblique muscle: the chin is lifted and the head is tilted toward the involved side. Chin elevation, as a rule, is more pronounced than the head inclination. Diplopia, a frequent complaint of patients with this syndrome, usually can be elicited when the involved eye is adducted. Diplopia in the primary position is often avoided by anomalous head posture. Suppression is rare, and we have observed only one patient who had amblyopia of the involved eye.

The differential diagnosis should include primarily a paralysis of the inferior oblique muscle. The positive forced duction test clearly differentiates Brown syndrome from a paralysis of the inferior oblique muscle. Furthermore, depression of the adducted eye, normal action of the contralateral superior rectus muscles, and a V pattern in upward gaze are features that are frequently found in association with Brown syndrome. On the other hand, in inferior oblique paralysis one may expect

an A pattern because of loss of the abductive action of the paralyzed muscle in upward gaze.²⁵⁵

The ultimate distinction between Brown syndrome and inferior oblique muscle paralysis rests with the outcome of the *forced duction* test. The ophthalmologist should be aware of other causes of restriction of elevation, such as congenital fibrosis of the inferior rectus muscle, endocrine orbitopathy, so-called double elevator paralysis, or fractures of the orbital floor. However, unlike in Brown syndrome, these conditions usually cause restriction of elevation from any gaze position and are not limited to restriction of elevation in adduction. Exceptions to this rule do occur and should be kept in mind; both an orbital floor fracture^{180, 412} and endocrine orbitopathy may occasionally simulate Brown syndrome.^{130, 174}

Therapy

When binocular vision is normal and comfortable with the eye in primary position and without an extreme anomalous head posture, we do not advocate surgery. Such patients may experience diplopia on attempts to elevate the involved eye in adduction, but they will learn to avoid this position of gaze. Downshoot in adduction alone does not present an indication for surgery. On the other hand, when the involved eye is hypotropic in primary position, when there is a significant anomalous head posture or, if traumatic in origin, does not spontaneously resolve, surgery should be considered in an attempt to restore binocular function in primary position. Another indication for surgery exists in the absence of binocularity in patients who habitually fixate with the involved eye and develop an anomalous head posture.

As mentioned, the results of dissecting and stripping the sheath while leaving the tendon intact, as originally advocated by Brown, have been unsatisfactory in the majority of cases. We perform a *complete tenectomy of the superior oblique muscle*,^{265, 353, 357} as advocated by Jacobi¹⁸¹ and by Crawford⁷⁶ and Crawford and coworkers.⁷⁷ The immediate result of this operation is often dramatic: the forced duction test becomes negative, and the eye elevates freely in adduction. However, in some patients the effect of surgery does not become fully apparent until several weeks or months later. In one half of 38 patients treated by us in this manner³⁵³ and followed for more than 1 year, the classic features of a *superior oblique paralysis* developed after tenectomy of the supe-

rior oblique. This problem has, in our hands, responded well to a subsequently performed recession of the contralateral inferior rectus muscle or myectomy or recession of the ipsilateral inferior oblique muscle^{77, 111, 265, 353} but other authors have encountered complications arising from attempts to repair the iatrogenic superior oblique paralysis.³²⁴

In the other half of our patients superior oblique paralysis did not occur, which is the reason why we do not perform a superior oblique tenectomy combined with recession of the inferior oblique muscle at the time of initial surgery, as was advocated by several authors.^{111, 285} In our series there was no loss of sensory function as a result of surgery, which has been mentioned as a surgical complication of tenectomy by Wright and coworkers.⁴⁰⁸

Wright⁴⁰⁶ introduced a *silicone superior oblique tendon expander* to lengthen the tendon rather than cutting it. He reported superior results with this method when compared with tenectomy.⁴⁰⁶⁻⁴⁰⁸ Others have also reported favorable results with the silicone expander technique in Brown syndrome.³⁵⁴ For reasons outlined in Chapter 26 we see no reason to abandon the superior oblique tenectomy, which in our hands has proved to be a very simple, safe, and effective procedure in treating Brown syndrome. In patients with *acquired Brown syndrome* a conservative approach is indicated unless a surgically amenable cause, such as a cyst or trauma to the trochlea, can be identified. As mentioned, spontaneous resolution is not infrequent and corticosteroid injections near the trochlea in patients with juvenile rheumatoid arthritis or other inflammatory conditions in this region are of possible benefit.

Adherence Syndrome

Several investigators have described developmental anomalies of extraocular muscles in which the sheaths of the lateral rectus and inferior oblique muscles and those of the superior rectus and oblique muscles are adherent. Such anomalies are rare, but the ophthalmologist must be aware of their existence, for they may produce perplexing diagnostic problems.

Johnson¹⁸⁷ described several variations of the adherence syndrome. Abnormal fascial connections between the lateral rectus and the inferior oblique muscles will cause pseudoparalysis of the

lateral rectus muscle. After the insertion of the lateral rectus muscle is severed from the sclera, resistance to passive abduction will be apparent during the forced duction test.

Similarly, adherence between the superior rectus muscle and the tendon of the superior oblique muscle may cause pseudoparalysis of the superior rectus muscle. After the lateral rectus or the superior rectus muscle has been temporarily detached from the globe, Johnson recommends lysis of these adhesions. This is accomplished by forcefully rotating the eye medially with forceps for the lateral adherence syndrome or downward for the superior adherence syndrome.

Johnson's description of the adherence syndrome leaves the impression that it occurs relatively often. Though we routinely use the forced duction test before, during, and after surgery, we have never observed a vertical adherence syndrome, and in only two patients have we seen the horizontal form. One of these patients had previous surgery of the lateral rectus muscle with resulting massive scar formation that extended posteriorly and involved both lateral rectus and inferior oblique muscles. In view of the scarcity of additional descriptions of this anomaly after Johnson's initial report and the infrequency with which it is encountered in clinical practice,¹¹⁵ we believe its significance has been overemphasized.

Parks²⁸¹ used the term *adherence syndrome* to describe a complication of myectomy of the inferior oblique muscle that he believed was caused by proliferation of fibrofatty tissue and reattachment of the proximal muscle stump to Tenon's capsule. Patients with this syndrome had hypotropia in primary position, restricted elevation, and a positive traction test. Parks encountered this complication in 13% of patients in whom myectomy was performed at the insertion and in 26% with disinsertions of the inferior oblique muscles. One of us (G.K.v.N.) has performed myectomy of the inferior oblique as the preferred weakening procedure of this muscle for the past 40 years and has encountered this complication in only two instances. Clearly, variations in the surgical technique must be responsible for this difference in prevalence.

Strabismus Fixus

Clinical Findings and Etiology

Strabismus fixus is a rare condition in which one or both eyes are anchored, as a rule, in a position

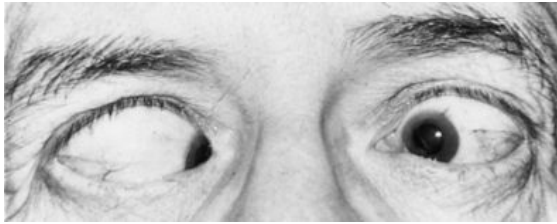

FIGURE 21-9. Convergent strabismus fixus.

of extreme adduction (Fig. 21-9). The involved eye is “fixed” in this position and cannot be moved, and the forced duction test will confirm the immobility of the eye.

Divergent forms of strabismus fixus not accompanied by ptosis or generalized fibrosis of the extraocular muscles are even more unusual¹²⁵ (Fig. 21-10) and enlargement of the nasal field of vision has been described in a case of divergent strabismus fixus.³³⁰ Patients with bilateral strabismus fixus are severely handicapped. One eye usually is preferred for vision, and the immobility of the eyes necessitates an extreme degree of head turn for such patients to get around. Strabismus fixus may occasionally reach bizarre proportions as shown by Case 21-1.

CASE 21-1

A middle-aged man complained that the colored part of his left eye had “gone.” He remembered that the eye had always been turned toward the nose and that the iris had gradually disappeared from view. Examination showed absence of the cornea in the palpebral fissure (Fig. 21-11A) and a CT scan revealed that the eye had rotated inward approximately 135°, almost exposing the optic nerve in the palpebral fissure (Fig. 21-11B). No treatment was advocated.

The condition generally is thought to be congenital and caused by fibrosis, which would explain the loss of elasticity of the medial rectus muscle. Acquired strabismus fixus was described

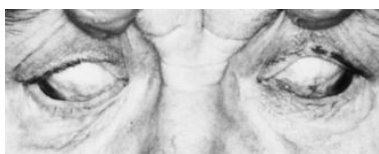

FIGURE 21-10. Divergent strabismus fixus. (From Schmidt D, Reuscher A, Kommerell G: Über das nasale Gesichtsfeld bei Strabismus fixus divergens. Graefes Arch Clin Exp Ophthalmol 183:97, 1971.)

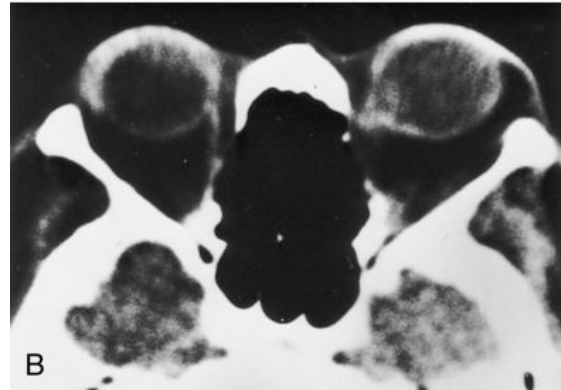
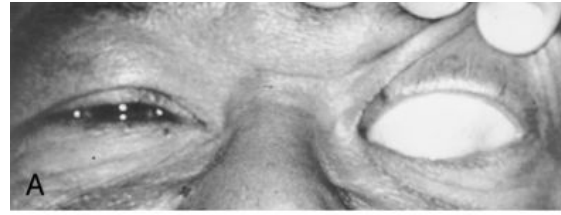


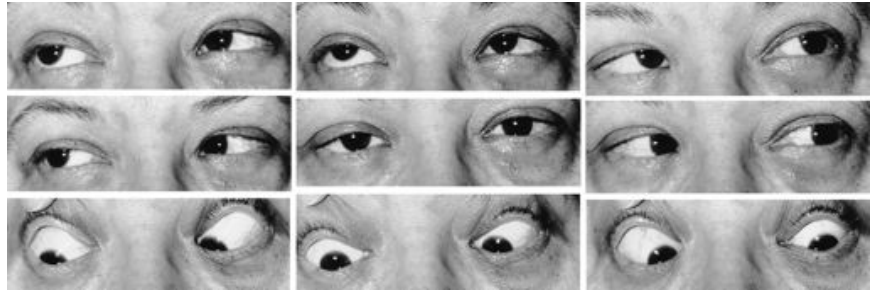FIGURE 21-11. Strabismus fixus with extreme adduction of the left eye. See text for explanation. (Courtesy of Dr. Janet Davis.)

by Villasecca³⁸³ and Martinez.²³⁰ Villasecca postulated that fibrosis of the medial rectus muscle is the consequence of contracture following a lateral rectus paralysis rather than a primary anomaly. Mechanical stretching and torsion of the optic nerve with strangulation of its blood supply has been reported to cause ocular ischemia, optic atrophy, and central artery occlusion in convergent strabismus fixus.²²⁸ Acquired strabismus fixus has also been reported in conjunction with amyloidosis³³⁶ and in patients with high myopia.^{26, 176, 306} An unspecific, progressive fibrosis, myopathy, or myositis is thought to be the cause of myopic strabismus fixus, which usually occurs in a convergent form and may reach extreme proportions.²⁹⁴

Therapy

Treatment is surgical and, for the convergent form of strabismus fixus, consists of complete disinsertion of the medial rectus muscle(s). In addition, resection of the lateral rectus muscles and recession of the conjunctiva and Tenon’s capsule should be carried out. Even though abduction beyond the midline will not become possible after surgery, some cosmetic and functional improvement can be accomplished in this manner. Under optimal conditions, a small field of single binocular vision can be restored by surgically moving the eyes into primary position.

FIGURE 21-12. Case 21-2. Restriction of abduction of the right eye, and elevation in adduction of the left eye in a patient with high myopia. (From Demer JL, Noorden GK von: High myopia as an unusual cause of restrictive motility disturbance. *Surv Ophthalmol* 33:281, 1989.)



Strabismus in High Myopes

Hugonnier and Magnard (1969) were first to direct attention to restrictive motility disturbances in severe myopia which they believed was caused by an unspecific myositis.¹⁷⁶ Since then it has become obvious that progressive strabismus occurring in high myopes may be due to more than one mechanism. One cause is a disproportion between the size of the orbit and the volume of an enlarged or elongated myopic globe. This may cause a generalized restriction of motility in several gaze directions and masquerade as endocrine orbitopathy, as shown by Case 21-2.⁸⁹

CASE 21-2

A 45-year-old woman wore lenticular spectacles for a myopia of OD $-28.00 + 2.50 \times 125^\circ$ and OS $-28.00 + 0.75 \times 165^\circ$, which corrected her visual acuity to 6/15 OD and 6/12 OS. Nine years ago she noted diplopia on tilting her head to the left. A left inferior oblique myectomy was performed elsewhere without relieving her symptoms. She now complains about vertical diplopia in all gaze positions

with an insidious onset. Her motility examination showed comitant left hypertropia of 10^Δ which increased to 16^Δ when looking down and to the left. Abduction was limited OD and elevation in adduction was limited OS (Fig. 21-12). Forced duction testing showed mechanical restriction of ocular motility in all peripheral gaze positions. Because of her ocular motility pattern, the results of the forced duction tests, and periorbital edema, a thyroid evaluation was performed that was essentially negative. Fundus examination showed vertically elongated and tilted optic nerve heads, peripapillary loss of pigmentation, and myopic retinal changes. A B-scan echogram demonstrated elongation of OS with a diffuse posterior, conical staphyloma. CT (Fig. 21-13A) showed marked enlargement and elongation of the globes, which were nearly filling the orbits, and diffuse posterior staphylomas. A coronal view of the orbit (Fig. 21-13B) showed a normal cross-sectional appearance of the extraocular muscles. Surgery consisted of a 4-mm recession of the left inferior rectus muscle, using an adjustable suture anchored to the globe by passage through a residual muscle stump to avoid perforation of the sclera. The patient has remained free of vertical diplopia.

We felt that the restriction of ocular motility was caused by contact between the elongated globes and the orbital walls and apices of the

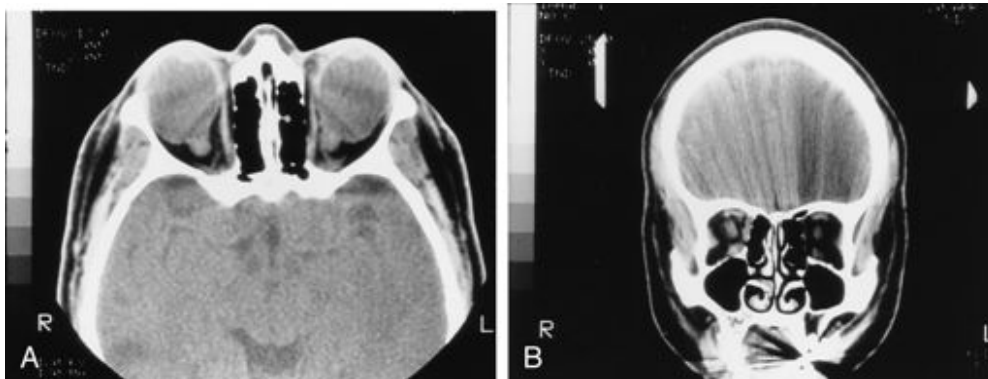


FIGURE 21-13. Case 21-2. A, CT scan shows elongation of the globes which are nearly filling the orbits and partially in contact with the orbital walls. Note posterior staphylomas of both eyes. B, Coronal view of orbit shows normal cross-sectional appearance of the extraocular muscles. (From Demer JL, Noorden GK von: High myopia as an unusual cause of restrictive motility disturbance. *Surv Ophthalmol* 33:281, 1989.)

orbits. Bagolini and coworkers¹⁵ suggested that *compression of the lateral rectus muscle against the lateral orbital wall* by an enlarged myopic globe will cause esotropia. Depending on the degree of esotropia surgery may be indicated to facilitate fundus examination and allow the patient to wear contact lenses. The medial rectus muscle or muscles must be retroplaced maximally (up to 13 mm) and a hang-back suture is used to avoid having to place the suture through the sclera that far posteriorly.

Another form of restrictive strabismus in high myopes has become known as the *heavy eye syndrome*. This syndrome consists of a slow and progressive development of esotropia and hypotropia. A typical case is depicted in Figure 21–14. Since the original description by Bagshaw¹⁶ numerous additional cases have been reported^{13, 16, 73, 154, 205, 216, 317, 368} and the results of neuroimaging studies have become available. Herzau and Ioannakis¹⁶³ noted at the time of operation a downward displacement of the lateral rectus muscle in progressively myopic eyes with the heavy eye syndrome. They postulated that scleral ectasia in these patients causes a downslip of the muscle in relation to the globe. This change of muscle path gives the muscle a depressing effect at the cost of its physiologic action of abduction. Krzizok and coworkers^{209–211} confirmed this change of muscle path with MRI in 33 orbits and noted also that the lateral rectus muscles may not be the only muscle involved; in two patients with exotropia and hypotropia the medial rectus muscle path was displaced

inferiorly. Scan echography showed no differences in muscle size between normal and myopic patients.²⁹¹

To normalize the muscle path Herzau and Ioannakis¹⁶³ recommended adding a supratransposition to a resection of the lateral rectus in combination with a recession of the medial rectus muscle. In several of their cases this operation was augmented with scleral fixation of the transposed muscle with a silicone loop to counteract its tendency to slip back inferiorly (see also Krzizok et al.²¹²). The results of muscle transposition for this condition have been disappointing in the hands of one of us (E.C.).

Fibrosis of the Extraocular Muscles

A rare congenital, familial, or sporadic anomaly involving fibrosis of most or all of the extraocular muscles was described by Heuck in 1879.¹⁶⁵ This condition is characterized by the following features:

1. Downward fixation of one or both eyes
2. Marked ptosis
3. Chin elevation
4. Perverted convergence movements on attempts to look upward or to either side
5. Familial or sporadic occurrence

Histologic examination of excised tissue from the extraocular muscles in patients with this condition reveals total replacement of muscle fibers by

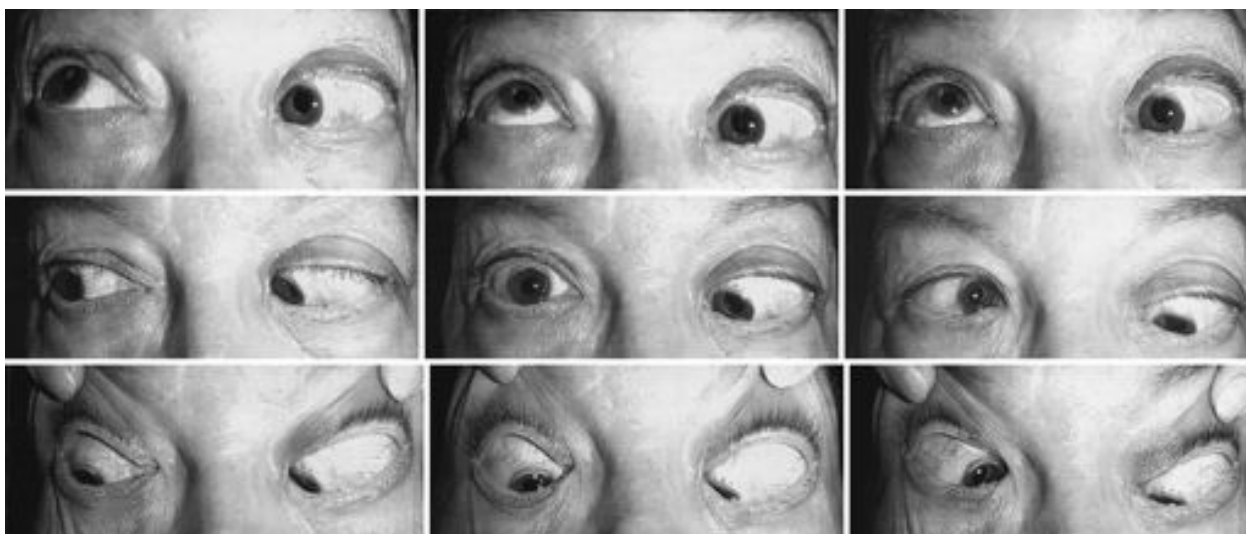

FIGURE 21–14. The “heavy eye syndrome” in a 42-year-old woman with high myopia OS. Note left esotropia and hypotropia with marked limitation of abduction and elevation OS. (Courtesy of Dr. E. M. Helveston, Indianapolis, IN. These digital photographs were transmitted as attached E-mail files from Cuba.)

fibrous elements.^{96, 149, 365} CT shows marked atrophy of the inferior rectus muscle.¹⁷⁷ Assaf¹¹ pointed out that these histologic anomalies may be secondary to an innervational disturbance rather than a primary ocular myopathy as the term *fibrosis syndrome* suggests and raises the possibility that a supranuclear disturbance may be present in these patients. Engle and coworkers¹⁰⁷ described a family with chromosome 12–linked congenital fibrosis of the extraocular muscles and fixation of the eyes in downward gaze. Autopsy findings in one affected member showed absence of the superior division of the oculomotor nerve and its corresponding alpha neurons as well as histologic abnormalities of the levator palpebrae and superior rectus muscles. The other extraocular muscles showed abnormal mitochondrial clumping, indicating that muscles other than those innervated by the superior division of the third cranial nerve are also affected. This report suggests that congenital fibrosis of the extraocular muscles may be caused by an abnormality of the lower motor neuron system.

Familial occurrence has been described by many authors^{106, 305} and other systemic congenital defects may be present in the affected and nonaffected family members.¹⁴⁸ Gillies and coworkers¹²⁶ described a family with dominantly inherited total absence of vertical ocular movements and found a reduction in size of cross sections of the extraoc-

ular muscles on CT scans with the superior rectus muscle particularly involved.

We treated a 21-year-old patient who had generalized fibrosis of the extraocular muscles associated with keratoconus and arthrogyriposis. Her deceased father had a similar condition. The possibility that a *vertical retraction syndrome*¹⁹⁵ may be caused by fibrosis of the vertical rectus muscles has been mentioned (see p. 462). Congenital ocular fibrosis associated with the Prader-Willi syndrome has been reported,¹⁸⁹ as has the association with oculocutaneous albinism, synergistic divergence,²⁷¹ and jaw-winking.⁴⁴

We have been impressed by the high degree of *hypermetropic astigmatism* and *amblyopia* in these patients, an observation also made by Sugawara and coworkers.³⁶⁵ Harley and coworkers¹⁴⁹ reviewed the literature pertaining to ocular fibrosis.

Figure 21–15 shows a family with ptosis and generalized fibrosis of the extraocular muscles. Even though an autosomal dominant pattern of inheritance may be present,^{106, 260} the sporadic form is the most common form encountered in our practice.

In making the differential diagnosis the physician must include orbital floor fracture, endocrine myopathy, Brown syndrome, double elevator palsy, and chronic progressive external ophthalmoplegia, all of which are discussed in this chapter.



FIGURE 21–15. Congenital fibrosis of extraocular muscles. The mother (*left*) had frontalis suspension procedures to both upper lids. Note chin elevation of son and daughter caused by severe ptosis. Motility of the globes was severely restricted in all members of this family. (Courtesy of Dr. Robert M. Feibel, St. Louis, MO.)

Treatment consists of a complete tenotomy to release the tight inferior rectus muscle. The results are never completely satisfactory, and the best a surgeon can hope for is to improve the compensatory head posture. Some patients need ptosis surgery. Since Bell's phenomenon is not present, special care must be taken to avoid postoperative exposure problems. We prefer frontalis suspension of the upper lids with a nonabsorbable suture that can be adjusted postoperatively rather than fascia lata suspension of the lid for these patients. The surgeon should strive for undercorrection of the ptosis and lifting the lids just enough to expose the pupils. Since it is seldom possible to predict the position of the eyes after tenotomy of the inferior rectus muscle, we prefer to perform ptosis surgery as a separate procedure.

Graves' Endocrine Ophthalmopathy

Etiology

Graves' ophthalmopathy is part of a multiorgan autoimmune inflammatory disease that may cause periorbital edema, enlargement of the extraocular muscles, proptosis, lid retraction, optic neuropathy, and secondary increase of intraocular pressure. Limitation of ocular motility, most commonly a restriction of elevation in one or both eyes, is a prominent feature of Graves' disease. A variety of terms are used to describe this condition: *exophthalmic ophthalmoplegia*, *endocrine ophthalmopathy*, *endocrine orbitopathy*, *endocrine myopathy*, *dysthyroid eye disease*, *infiltrative ophthalmopathy*, *dysthyroid myositis*, and *exophthalmic goiter*. This plethora of terms reflects our lack of knowledge of the exact nature of the relation between disturbance of thyroid function and involvement of the extraocular muscles.

It is of historical interest that before reintroduction of the forced duction test by Dunnington and Berke¹⁰¹ in 1943, the opinion prevailed that the limitation of elevation is caused by toxic damage to the elevator muscles, the superior rectus in particular.²²⁹ This view was perpetuated until the mid-1960s,^{132, 320} when it was replaced by the current concept that limitations of ocular motility are caused by the swelling and loss of elasticity of extraocular muscles. Dunnington and Berke¹⁰¹ described the histologic features of myositis (interstitial edema and round cell infiltration) in a group

of patients with exophthalmos and limitation of elevation (see also Kroll and Kuwabara²⁰⁷ and Daicker⁸²). The forced duction test revealed marked resistance on passive elevation. Thus Dunnington and Berke were the first to recognize that pseudoparalysis of the superior rectus muscle in exophthalmic patients is caused by a myopathy and loss of elasticity of the inferior rectus muscle.

Further confirmation of the primary myopathic nature of ocular motility disturbances in patients with Graves' disease has been provided by electromyographic studies.^{172, 225, 241, 331}

Most of the clinical features of the disease can be traced to an overproduction of glycosaminoglycans within the orbit and histologic examination shows an accumulation of this substance in the connective tissue components of the orbital fat and extraocular muscles.⁵⁸ Edema and inflammation of the muscles contribute to their swelling and dysfunction. It has been shown by length-tension curves during surgery that in the early stages of the disease muscle dysfunction is caused by increased tension and reduced elasticity.³³⁸ In the late stage of the disease the muscle fibers are replaced by connective tissue. Environmental and immunogenic factors probably contribute to the development of Graves' ophthalmopathy and the reader is referred to recent review articles^{17, 388} and recent texts^{58, 387} for detailed discussion of current theories.

Diagnosis and Clinical Findings

Graves' ophthalmopathy occurs more commonly in women than in men and usually affects middle-aged persons. The onset of diplopia usually is insidious and related closely to the onset of exophthalmos. Exceptions to this rule occur, however, and Bixenman and von Noorden²⁸ described two patients in whom diplopia and restriction of motility developed practically overnight. We have observed several patients in whom exophthalmos developed after the onset of the motility defect or did not develop at all. Inconspicuous periorbital edema in association with limitation of elevation of one eye may be the first symptom of an endocrine myopathy. *Limitation of elevation is by far the most common defect of ocular motility*, followed in order of frequency by limitation of horizontal and vertical gaze, caused by myopathy of the medial and superior rectus, respectively. The lateral rectus muscle is least commonly involved. Limitation of ocular motility frequently remains

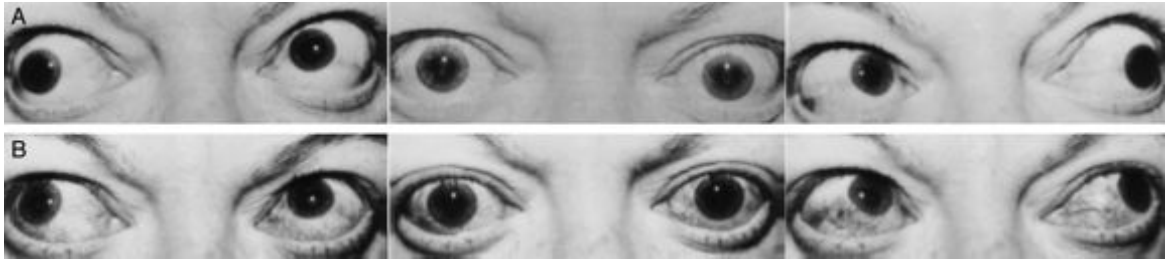


FIGURE 21-16. Graves' ophthalmopathy. *A*, Lid retraction and severe restriction in abduction of either eye caused by myopathy of the inferior rectus muscles. *B*, Normalization of elevation after a 6-mm recession of both inferior rectus muscles. Note improvement of lid retraction showing that this sign was, at least partially, caused by increased effort to elevate the eye.

unilateral or is asymmetrical when myopathy affects both eyes. Saccadic eye movements in euthyroid Graves' disease were found to be less conjugate than in those of control subjects and differences existed also in velocity characteristics of normals and patients with this condition.⁴⁰⁵

Compression of the orbital apex by the enlarged extraocular muscles, especially the medial rectus muscle, may cause *congestion of the optic nerve*, axonal death, and decrease in visual acuity.¹¹³ However, pressure from the swollen muscles is not the only cause of optic neuropathy, which may also occur in the absence of muscle swelling.⁷

Limitation of ocular motility, most commonly a restriction of elevation in one or both eyes and the optic neuropathy, has been shown to correlate with extraocular muscle volume as determined by CT scan.¹⁴⁵ The possibility that initial unilaterality of the condition may be followed by affection of the other eye and renewed diplopia should be pointed out to the patient to avoid disappointment with the initial surgical result at a later date.

An increase in intraocular pressure on upward gaze, suggesting tightness of the inferior rectus muscle, has been used for many years³⁶ as a diagnostic tool in the early stages of the disease. However, the value of this test has been questioned since pressure increase on upward gaze occurred also in normals.³⁵¹

Retraction of the upper lid is one of the many manifestations of Graves' disease. It is usually caused by increased sympathetic innervation, although a shortening of the levator aponeurosis has also been implicated.¹⁴² The effort to elevate the eye in the presence of a tight inferior rectus muscle may contribute substantially to lid retraction (Fig. 21-16).

The diagnosis of endocrine myopathy is confirmed by the *forced duction test*, which reveals restriction of passive movements of the globe, and

by a thorough evaluation by an internist. The frequent association between Graves' disease and myasthenia gravis should be kept in mind. If the restrictive component in a patient with suspected Graves' disease does not adequately explain the ocular motility deficit, an estimation of the generated muscle force and a Tensilon (edrophonium chloride) test are mandatory.⁵³

In the *differential diagnosis* one must consider other causes of restricted globe motility and endocrine ophthalmopathy has been reported to masquerade as a superior oblique paresis²⁵² and Brown syndrome.¹⁷⁵

A *CT scan* is of great value, especially in distinguishing endocrine myopathy from other pathologic changes of the orbit that restrict ocular motility. Trokel and Hilal³⁷⁵ and Patrinely and coworkers²⁸⁷ outlined the variations and differential diagnosis of muscle thickening as seen on CT scans. The dramatic *fusiform swelling of the extraocular muscles* in a patient with endocrine myopathy is shown in Figure 21-17. As can be

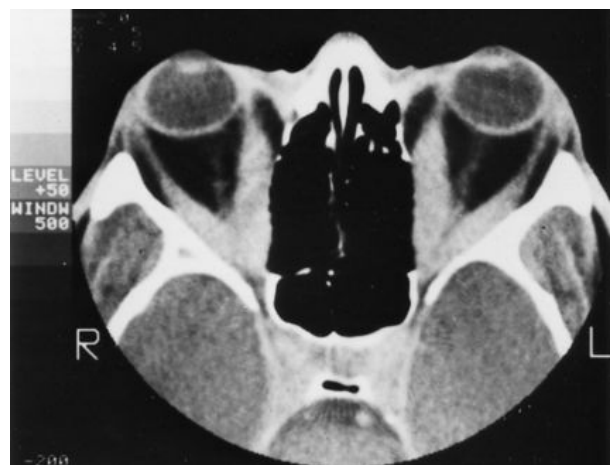

FIGURE 21-17. CT scan in patient with advanced endocrine myopathy causing thickening of the horizontal rectus muscles.

seen by comparing Figures 21–17 and 21–19, the swelling in endocrine myopathy is limited to the *posterior aspects* of the muscle, whereas in ocular myositis it involves the *anterior portions* as well. Considering that the distribution of immunocompetent cells is fairly homogeneous throughout the length of the muscle,²⁰³ the predilection for this posterior site remains a mystery.

The more frequent involvement of the inferior rectus muscle may be related to the anatomy of the lower portion of the orbit. J. E. Miller and coworkers²⁴¹ expressed the view that since the inferior rectus and inferior oblique muscles are the only muscles in direct contact with each other, any inflammatory process would lead to a fibrous union between these two muscles and the ligament of Lockwood. After confirming through surgery the existence of such anomalous connections between these structures, Miller and coworkers further pointed out that a similar inflammatory process may occur in other extraocular muscles but is less likely to cause symptoms since such changes would go unrecognized in symmetrical involvement of yoke muscles.

The relation between the onset of myopathy and thyroid dysfunction needs further clarification. Limitation of ocular motility may occur at any point in the continuum now recognized as Graves' disease.¹⁴⁴ In such patients, evaluation by an internist may reveal hyperthyroidism, euthyroidism, or even hypothyroidism.³⁵ Of 120 patients with Graves' disease 90% had hyperthyroidism, 1% had primary hypothyroidism, 3% had Hashimoto's disease, and 6% were euthyroid.¹⁹ It is not uncommon to find the disease in patients who have had previous transient undiagnosed episodes of hyperthyroidism or in those who had undergone thyroidectomy several years before examination. Thus *the ocular myopathy does not necessarily reflect the state of thyroid activity*. The role of the long-acting thyroid stimulant (LATS) in the pathogenesis of endocrine myopathy is poorly defined at this time.¹⁴⁴

Many otherwise excellent studies by thyroidologists suffer from lack of a thorough ophthalmologic evaluation of ocular motility defects. We believe, for instance, that considerable confusion has been created by failure to differentiate between general limitation of ocular motility in several or all directions of gaze, usually accompanied by marked exophthalmos, in the acute "wet" congestive phase of the disease and the severe restriction of elevation, abduction, or adduction that is a

feature of its more chronic, noncongestive "dry" phase. In the wet phase of the disease, the limitation of eye movement may be caused merely by marked swelling and congestion of the retrobulbar orbital contents. In the dry phase, limited eye movement is caused by actual infiltration and enlargement of the muscles and subsequent loss of elasticity.

Therapy

A discussion of the roles of systemic corticosteroids, immunosuppressive therapy, orbital radiation, or surgical decompression is beyond the scope of this book, and the reader is referred to the pertinent literature.^{58, 123, 135, 151, 387} We shall be concerned here only with treatment of strabismus caused by the myopathy.

Once the diagnosis of endocrine ocular myopathy has been established, it is advisable to await normalization of the endocrine imbalance by medical therapy before considering surgical correction. Spontaneous recovery of restricted ocular motility has been reported,¹⁴³ but is rare in our experience. We prefer to observe such patients for at least 6 months to establish the stationary nature of the disease. On many occasions we have noted that during this observation period other muscles or muscle groups become involved so that a change in the surgical approach became necessary. Prismatic correction of vertical or horizontal deviations may be beneficial during this waiting period or unilateral complete or segmental occlusion be required when the deviation exceeds the amount correctable with prisms.

Other authors have advocated early intervention in patients who are severely disabled on account of their abnormal head position.⁶⁹

Systemic treatment directed at normalization of thyroid function in patients with hyperthyroidism, in our experience, has not been effective in eliminating the restriction of ocular motility. Brown and coworkers⁵¹ reported improvement in ocular motility in some patients following high dosages of corticosteroids. However, patients so treated suffered a severe, acute form of infiltrative Graves' disease, and in their paper these workers made no distinction between the restriction of ocular motility caused by acute orbital congestion and that caused by myopathy. Even though steroids are known to dramatically improve the congestive phase of the disease, they have, in our

experience, no significant effect on the *chronic* form of endocrine myopathy.

Once the deviation has stabilized, surgery becomes the treatment of choice. The aim of surgery is to restore single binocular vision in those gaze positions that are functionally important to the patient. When elevation is limited, a 4- to 7-mm recession of the inferior rectus muscle is indicated.²³ The amount of recession should exceed what is ordinarily recommended for vertical deviations (see Chapter 26). When adjustable sutures are used one should realize that an undereffect in the immediate postoperative phase may be only temporary and that a residual angle of strabismus tends to decrease further with time.¹⁰⁹ Along the same line, it has been noted that overcorrections after initial postoperative alignment developed spontaneously in 5 of 12 patients.¹⁷⁴ For these and other reasons discussed in the following paragraph, a slight undercorrection appears desirable. Adjustable sutures are well suited to deal with the relatively unpredictable results of a conventional recession in this condition but special care must be taken to anchor the sutures well in the sclera since the only two patients one of us (G.K.v.N.) has encountered in whom adjustable sutures became undone (3 and 10 days after surgery) had Graves' ophthalmopathy. Helveston has observed the same complication in this condition.¹⁵⁷

When recessing the inferior rectus muscle in patients with Graves' ophthalmopathy the surgeon must be aware that while this operation in most instances restores single vision in primary position, it may cause a postoperative hypertropia in downward gaze that causes double vision. Depending on the patient's occupational needs, an undercorrection should be strived for. A secretary or accountant, for instance, is better off with a mild residual chin elevation in primary position and fusion in downward gaze than with a normal head posture but diplopia during reading. If this complication is unavoidable, the appropriate surgery to restore fusion in downward gaze must be performed on the fellow eye in a second procedure. Another potential problem the patient should be advised of prior to surgery is asthenopia during near work. Progressive bifocal lenses may no longer work and a conventional bifocal segment may have to be repositioned.

When the inferior rectus muscle is recessed, freeing the muscle completely by sharp dissection from Lockwood's ligament is not always possible

because the extraordinary tightness of the muscle prior to its detachment prevents the necessary elevation of the globe. Postoperative retraction of the lower lid in a patient whose lid fissures are already abnormally wide may create a cosmetic problem. A lateral tarsorrhaphy at a later date may improve the appearance. Occasionally, the markedly depressed position of the globe, swelling of the muscle, and tightness of the tissues will make it technically impossible to insert a muscle hook under the insertion. In such instances, we have performed a complete tenotomy of the muscle at the insertion but obtained undesirable overcorrection in 2 of 19 patients so treated. Several muscle hooks with a groove to guide the tip of a knife during tenotomy have been designed but we have found that if a muscle hook can be inserted at all, a recession or retroplacement on a hang-back suture can also be performed and is preferable to a free tenotomy.

In patients with long-standing depression of the globe, the conjunctiva and Tenon's capsule may shrink. To restore normal ocular motility, we perform a generous recession of the conjunctiva and Tenon's capsule rather than force these back to the original incision during wound closure (see Chapter 26). For limitation of abduction, a similarly large recession of the medial rectus muscle is recommended, and other restrictions of ocular motility associated with an endocrine myopathy should be treated in an analogous manner.

Because of the many variables involved, attempts to create dose-response curves for recessions in Graves' ophthalmopathy have been unsuccessful.³¹ Some surgeons advocate that surgery on these patients be performed under topical anesthesia.³¹ Since it cannot be anticipated how much discomfort will be caused by excessive pull on the muscle hook, we prefer *general anesthesia*. It is of interest, however, that the *oculocardiac reflex* in patients with Graves' ophthalmopathy has been reported to be markedly reduced or absent.^{31, 256}

Injection of the inferior rectus muscle with botulinum toxin (Botox) is discussed in Chapter 25.

Most patients with Graves' ophthalmopathy are severely incapacitated for many months by vertical diplopia. Restoration of single binocular vision, at least in primary position and in downward gaze, often can be accomplished by surgery. The functional results usually are excellent and a source of gratification for both patient and surgeon (see Fig. 21-16B). It must be mentioned, however,

that the results are often only temporary. After various periods of alignment and relief of symptoms, as mentioned earlier, different muscles in the same or fellow eye may become involved and require additional surgery.

Acute Orbital Myositis

Acute orbital myositis belongs to a subgroup of nonspecific orbital pseudotumors, and its etiology remains obscure, although immunologic mechanisms have been postulated.^{52, 253, 343} Symptoms include acute onset of unilateral orbital pain which may increase with eye movements, ptosis, conjunctival injection over the muscle insertion, proptosis, and diplopia.³⁹⁵ Unlike Graves' ophthalmopathy, which shows a predilection for certain tissues and involvement of the posterior part of the muscle belly, inflammatory pseudotumor may involve any or all orbital tissues and the entire length of the muscle. Limitation of ocular motility is a common finding and may consist of restriction of ductions in the field of action of the involved muscle, distinguishing it from Graves' ophthalmopathy in which motility is restricted in the field opposite that of the involved muscle. Weinstein and coworkers³⁹⁵ reported 21 patients with this condition, four with histories of ocular or systemic autoimmune disease. Treatment consists of systemic corticosteroids, supplemented if necessary by radiation therapy. Surgery may occasionally be required in patients with persistent diplopia who may benefit also from a diagnostic botulinum toxin injection to predict the outcome of an operation.²⁴ Stidham and coworkers³⁶² described isolated myositis of the superior oblique muscle. Recurrences have been reported in 50% of the cases²⁴⁸ and have been associated with lack of responses to systemic corticosteroids or nonsteroidal anti-inflammatory agents.²²⁷

With Case 21–3 we describe a typical patient.

CASE 21–3

An 8-year-old boy presented to our emergency room with bilateral lid swelling and proptosis of OS of 8 days' duration. The patient had been using sulfacetamide sodium (Bleph-10) and naphazoline hydrochloride and antazoline phosphate (Vasocon-A) for the previous week without improvement. The patient complained about double vision and pain in OS. The

mother stated that the proptosis had increased over the last 2 days with frequent episodes of nausea and vomiting. The history for trauma was negative and the child had been lethargic and had a low-grade fever for the past week. On examination the uncorrected visual acuity was 6/6 in OU. Exophthalmometry (Hertel) showed 18 mm OD and 21 mm OS. There was decreased retropulsion and pain on retropulsion OS. An exotropia of 30^A and a left hypertropia of 10^A was present at near and distance fixation. There was generalized conjunctival hyperemia, especially over the left medial rectus muscle. OS would not adduct (Fig. 21–18). CT showed swelling of the horizontal rectus muscles OU with maximal swelling of the left medial rectus muscle (Fig. 21–19A). The vertical recti were also involved (Fig. 21–19B). The diagnosis of acute myositis was made and the patient was placed on intravenous dexamethasone (Decadron, 15 mg every 6 hours). Improvement was rapid and dramatic; the exophthalmos, the adduction deficit in the left eye, and the pain subsided within several days.

Cyclic Heterotropia

Clinical Findings and Etiology

A rare but most intriguing form of strabismus apparently depends on a regular clock mechanism that usually follows a 48-hour rhythm; that is, a 24-hour period of normal binocular vision is followed by 24 hours of manifest heterotropia. The first two cases of alternate-day esotropia were described by Böhm in 1845.³² In 1905 Worth⁴⁰⁴ mentioned records in his possession of periodic strabismus that occurred every second day. There was no further mention of this form of strabismus in the literature until the roundtable discussion at the Second Strabismus Symposium of the New Orleans Academy of Ophthalmology in 1958 during which Burian⁵⁴ related a similar case. Since that time, many cases have been reported and are referred to as *circadian*, *periodic*, *alternate-day*, or *clock-mechanism esotropia*.^{5, 49, 54, 63, 75, 121, 156, 254, 307, 314, 329, 399, 400} Costenbader and Mousel⁷⁵ observed only three cases of cyclic heterotropia in 3500 strabismic patients.

In most patients with cyclic heterotropia, certain characteristics are evident. The onset may be in early infancy, but the condition usually becomes apparent during early childhood. On "straight" days no anomalies of binocular vision are observed; heterophorias and refractive errors, if at all present, are slight. However, cyclic esotropia has also been described in a monocular patient

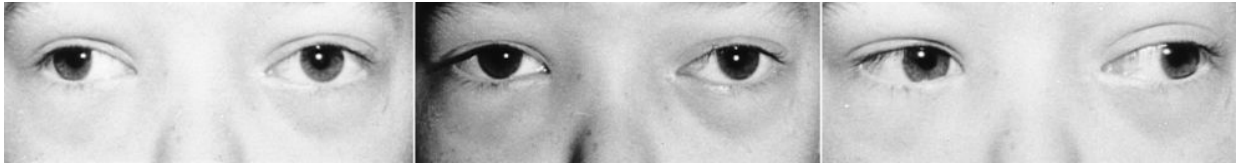

FIGURE 21-18. Case 21-3. Orbital myositis. Note exotropia, left hypertropia, limitation of adduction, and proptosis of the left eye. (Courtesy of Dr. E. Husain, Houston, TX.)

whose seeing eye adducted every second day.³⁰⁸ Thus, the presence of normal binocular function is not a prerequisite of the development of cyclic strabismus. On strabismic days, a large angle esotropia, often as large as 40^Δ to 50^Δ , will appear. These measurements are consistent on subsequent examinations. On days when strabismus is present, sensory anomalies often are found, diplopia is infrequent, and fusional amplitudes determined with the amblyoscope are defective or absent.

The cyclic nature of the strabismus may last from 4 months to several years, after which the

cycle breaks and esotropia becomes constant. A change in the cycle has also been reported after traveling rapidly through different time zones.²³⁹ The 48-hour cycle is encountered most commonly, but 72-hour⁴⁹ and 96-hour cycles⁷⁵ have been reported. Consecutive cyclic esotropia has been reported following surgery for intermittent exotropia, and the only three patients with cyclic esotropia that we have seen and treated each had a history of surgery for intermittent exotropia (see also Muchnik and coworkers²⁵⁴ and Uemura and coworkers³⁷⁹).

In most reported instances cyclic esotropia occurred in childhood, although a sudden onset of this condition has also been reported in adults.^{71, 356, 376} Curiously, in one case cyclic esotropia developed after unioocular traumatic aphakia and was corrected by a secondary intraocular lens implantation.⁷¹

While cyclic strabismus mostly occurs as esotropia, *cyclic exotropia* has also been reported.¹ The most unusual case of cyclic strabismus was reported by Windsor and Berg,³⁹⁹ who observed a cyclic left superior oblique palsy in a 10-year-old boy following an injury to the trochlear region of the left eye. Left hypertropia with vertical diplopia accompanied by a positive Bielschowsky's head tilt test for a left superior oblique palsy was present only on every second day. On alternate days, binocular vision was normal and the head tilt test was negative. After phenobarbital medication was given, the left hypertropia became constant, but when the drug was discontinued, the cycle returned. When the patient was kept awake all night, a spontaneous switch in the cycle occurred from 5 to 6 AM.

The mechanism of this extraordinary form of strabismus is obscure. Pillai and Dhand²⁹² reported cyclic esotropia in association with central nervous system lesions. In one case the condition occurred after removal of a third ventricle astrocytoma, and in the other it developed with the advent of an epileptiform disorder. Cyclic esotropia developed in one instance 1 year after recovery from a traumatic abducens palsy after closed head

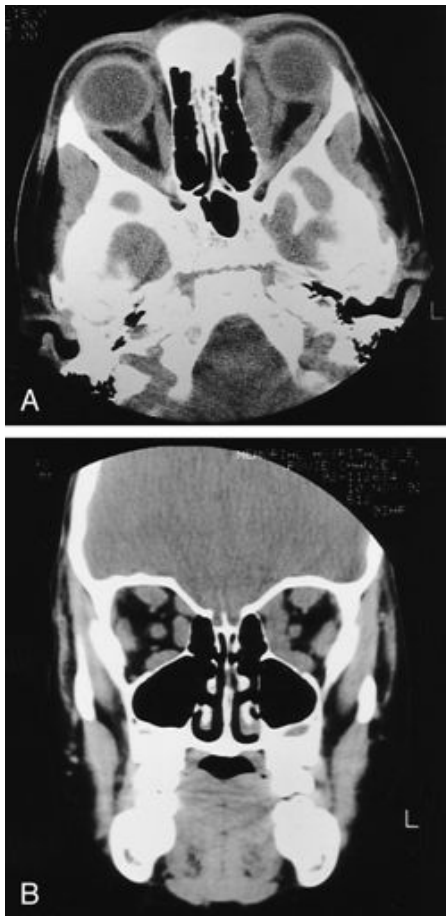

FIGURE 21-19. Case 21-3. Orbital myositis. *A*, CT scan shows proptosis of the left eye and enlargement of all horizontal rectus muscles, especially the left medial rectus, which seems to be pushing the globe anteriorly and laterally. *B*, Coronal section shows that the vertical rectus muscles are also involved.

trauma.¹⁷⁸ In some instances, features possibly related to a clock mechanism elsewhere in the body were noted. Böhm,³² in the first reported case, mentioned that in his patient the strabismus eventually disappeared but recurred whenever the child became upset. Roper Hall and Yapp³¹⁴ observed behavioral changes on the squinting day, and in two of their patients abnormal electroencephalograms showed a change alternating from day to day. One patient experienced frequency of micturition only on the squinting day. Friendly and co-workers¹²¹ monitored psychological and physical functions in a patient with alternate-day esotropia and were unable to detect any concurrent cyclic changes. Richter,³⁰⁷ a world authority on biological clock mechanisms, pointed out that 24- to 96-hour cycles, as found with this entity, are not unique. Other periodic biological phenomena include sweating, salivation, body temperature, and pulse rate; a cyclic pattern occurs with almost every form of abnormal behavior in psychiatric patients. Richter's research with rats and monkeys indicates the presence of a biological clock mechanism that keeps time with extraordinary accuracy and is entirely independent of all internal and external disturbances.

Cyclic strabismus, even though intermittent, differs profoundly from other forms of intermittent strabismus in that a significant latent deviation is absent on the nonsquinting day. Moreover, the abnormality is not associated with factors such as fatigue, accommodation, or disruption of fusion that convert an ordinary intermittent strabismus from its latent to its manifest form. The mystery of cyclic heterotropia is compounded by the fact that some reported patients have strong family histories of manifest strabismus or other anomalies of binocular vision.

Another rare cyclic form of strabismus, observed in association with periodic alternating nystagmus or periodic alternating gaze deviation, is *periodic alternating esotropia*.³⁶⁰ Hamed and Silbiger¹⁴⁷ described this condition as an esotropia maintained in one eye for 1 to 2 minutes while the fellow eye fixates in abduction and the face is turned toward the side of the esotropic eye. This is followed by a phase of normalcy in which the eyes are aligned, after which the previously fixating eye becomes esotropic, the fellow eye fixates in abduction, and the direction of the face turn reverses. The authors reported this phenomenon in a 9-month-old girl with developmental delay and cerebellar atrophy.

Therapy

In considering treatment of cyclic strabismus the ophthalmologist faces two basic questions: Are these patients basically strabismic and, by some unknown mechanism, capable of maintaining normal binocular vision on alternate days? Or do these patients usually have normal binocular vision but develop strabismus on alternate days because of external stress or some unknown psychomotor disorder? The natural history of the disease (the clock mechanism eventually "breaks" and strabismus becomes constant on an everyday basis) and the results of surgical treatment seem to favor the first hypothesis. Surgery based on the full amount of heterotropia as it occurs on the day of squinting has been eminently successful in permanently curing this condition and in reestablishing normal binocular functions. If one were to accept the second hypothesis, one would expect a significant surgical overcorrection to appear on the "straight" days, but this has not been the case in patients who have undergone surgery.

Acquired Motor Fusion Deficiency

Acquired motor fusion deficiency is an infrequent disturbance of both fusional convergence and divergence that occurs after closed head trauma, after a cerebrovascular accident, as a result of intracranial tumors, and after brain surgery.^{12, 182, 183} The first description was by Jaensch in 1935¹⁸³ and damage to the midbrain has been postulated as a cause.

Acquired motor fusion deficiency may be associated with a decreased range of accommodation.^{12, 150, 152, 182, 183, 298, 300, 374, 386} Such patients complain of severe asthenopia, intractable diplopia, and inability to maintain single vision for any length of time. Post-traumatic fusion deficiency may follow surgical correction of paralytic strabismus of traumatic origin. In spite of perfect ocular alignment, diplopia persists and may be crossed at one moment and uncrossed or vertical at another. Examination will reveal marked decreased, or complete absence of, fusional amplitudes, that is, motor fusion. In contrast, sensory fusion and stereopsis are intact during the brief moments that such patients are able to superimpose the double images.¹² It is reasonable to assume that a lesion in the midbrain accounts for this problem.

Acquired motor fusion deficiency after trauma must be distinguished from loss of motor fusion in adult patients caused by a unilateral cataract or uncorrected unilateral aphakia of long standing. In such patients motor fusion has become weakened from lack of binocular sensory input and usually returns once the obstacle to binocular vision has been removed.²⁹⁹ Motor fusion deficiency must also be differentiated from combined convergence and accommodation deficiency (see p. 503) since the impairment is not limited to convergence but affects divergence and sursumvergence as well.

A defect of motor fusion may be mistaken for malingering in a patient who complains of transient diplopia without an identifiable defect of ocular motility and seeks compensation for a work-related accident. Determination of fusional amplitudes with a rotary prism will quickly distinguish between a malingerer in whom motor fusion can be readily elicited and a patient with an organic motor fusion defect with decreased or absent fusional amplitudes. Ophthalmologists must become more aware of this condition, which is frequently overlooked, and recognize it as a legitimate post-traumatic disability.

There is no effective therapy. Prisms are useless because of the constant need for readjustments of the power and the direction of the prism base. Spontaneous improvement has been reported^{152, 224, 234} but is infrequent in our experience. An occluding scleral contact lens may be all one can offer to such patients.

Fracture of the Orbital Floor

Clinical Findings and Etiology

An exhaustive coverage of the subject of orbital fractures would exceed the scope of this book. However, because diplopia is often a prominent manifestation of this injury and its management clearly belongs in the realm of those concerned with ocular motility disorders, a brief discussion of this topic is justified.

The mechanism of orbital floor fractures and their clinical symptomatology have been described sporadically since 1889,²¹⁵ but not until 1957, when Smith and Regan³⁴⁵ published their now classic paper, did the concept of an orbital “blow-out” become recognized. These authors demonstrated in cadavers that posterior impaction of the globe may cause a blow-out of the thin orbital

floor as a result of sudden pressure on the bony area of least resistance. Orbital contents such as fat, fascia, the inferior rectus and oblique muscles, or, in some instances, the entire globe may prolapse into the maxillary antrum,³⁴⁴ or part of these tissues may become incarcerated in a linear crack in the orbital floor.

The concept of a blow-out mechanism has been questioned since orbital floor fractures have been observed after the eye had been enucleated. A second mechanism for orbital floor fractures, which is independent of increased intraorbital pressure, has been proposed and is caused by the buckling effect of a severe blow to the inferior orbital rim (blow-in fracture).^{122, 303} A recent study based on interference holography²¹ has identified several points along the orbital rim that on contact cause deformation of the bony orbit. Regardless of where the stress was applied the maximal deformation occurred on the medial aspect of the orbital floor, which also happens to be the area where most clinically diagnosed fractures occur.

The principal clinical manifestations after a recent fracture of the orbital floor usually are marked swelling and ecchymosis of the lids and periorbital soft tissue. Epistaxis may take place on the affected side. Proptosis commonly occurs during the immediate post-traumatic phase, even though in some patients a large defect of the orbital floor may cause enophthalmos. The presence of subcutaneous emphysema with crepitus is an indication of injury to the medial orbital wall. An associated malar fracture will produce anesthesia of the skin region supplied by the infraorbital nerve. Marked limitation of eye movements, particularly elevation, depression, or both, are common findings (Fig. 21–20); once the swelling of the lid has subsided and the eye can be opened, the patient will complain of diplopia. Limitation of elevation is more likely to be caused by an anterior and of depression by a posterior fracture site (Fig. 21–21).

The forced duction test will demonstrate limitation of passive elevation when the structures surrounding the inferior muscles or the muscles themselves are incarcerated. The clinician must be aware, however, that limitations of passive ductions also may occur from intraorbital hemorrhages or edema,¹ especially in the immediate post-traumatic phase (see below).

Of the various methods of radiologic examination, CT scans with coronal views have emerged as a most accurate technique for demonstrating

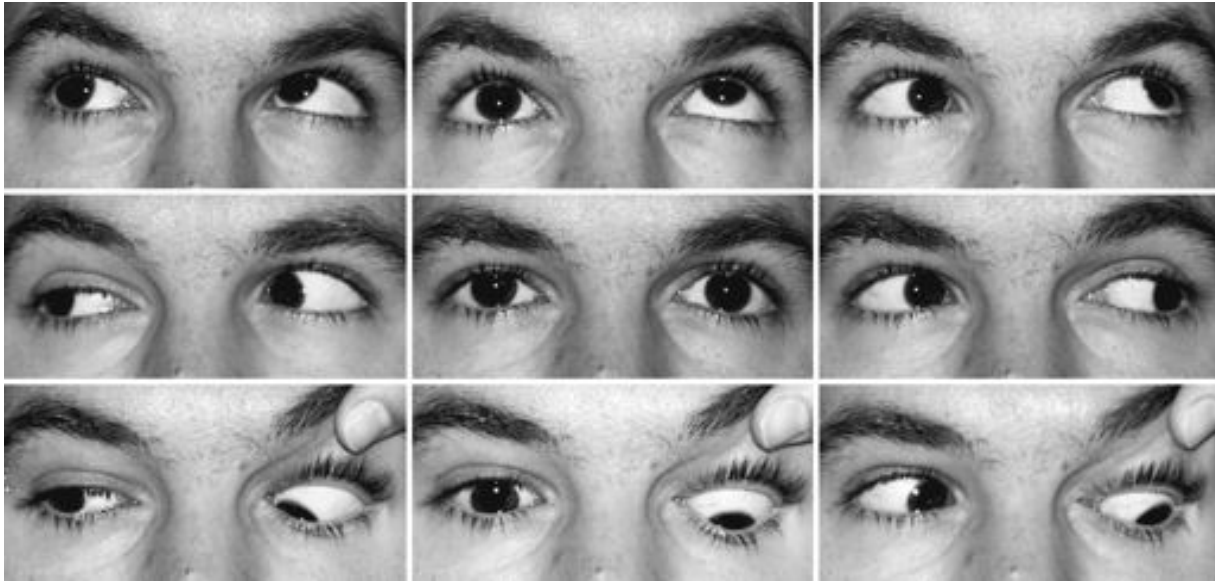


FIGURE 21-20. Orbital floor fracture, right eye. Note limitation of elevation and depression with secondary hypertropia of the left eye on upward gaze and hypotropia on downward gaze.

defects in the bony structure of the orbital floor (Fig. 21-22). If the patient cannot be positioned for CT scans, conventional tomography is advocated. When evaluating cloudiness of the antrum, it is important to differentiate between herniated orbital tissue and hemorrhage associated with the injured maxillary periosteum or mucosa with radiographic clouding (pseudoprolapse)¹⁰³ of the antrum in the presence of an intact orbital floor, as shown in Figure 21-23.

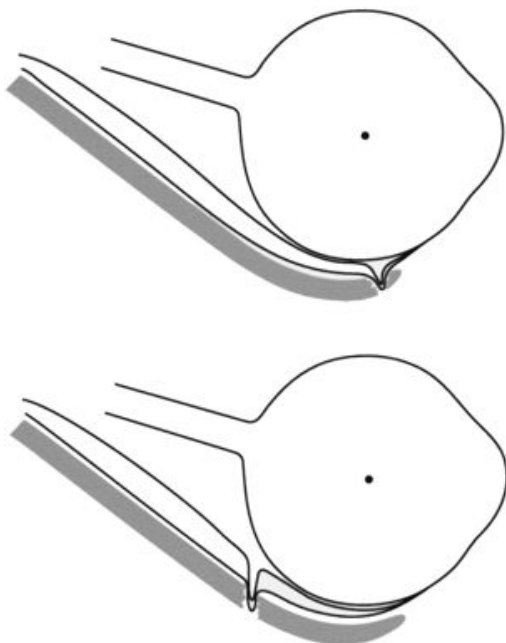


FIGURE 21-21. Above, Fracture site anterior to center of rotation causes limitation of elevation. Below, Fracture site posterior to center of rotation causes limitation of depression.

Serious associated ocular injuries, led in frequency of occurrence by retinal edema and hyphema, were present in 50 of 159 patients evaluated at the Wilmer Institute.¹⁰⁴ Careful ophthalmologic examination is absolutely essential in all patients with orbital injury, and they should never be treated, as sometimes happens, by otolaryngologists or plastic surgeons without ophthalmologic evaluation.

Therapy

In the past, most authors stressed the need for early surgical repair of the orbital floor to prevent

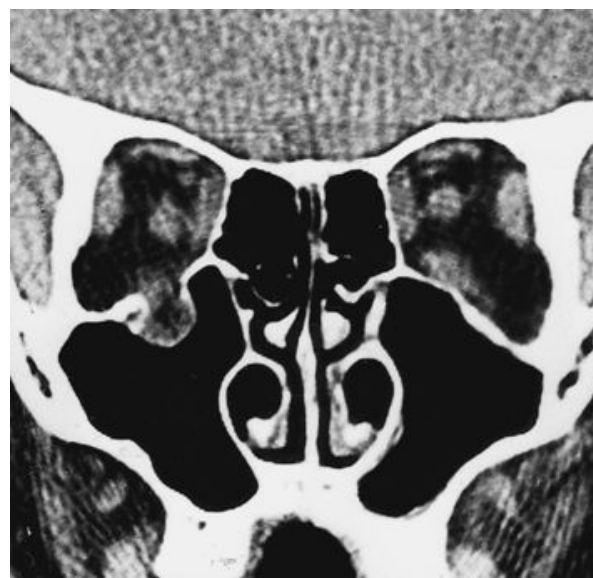

FIGURE 21-22. CT scan of patient depicted in Figure 21-20 shows fracture of the right orbital floor with prolapse of orbital tissue into the antrum.

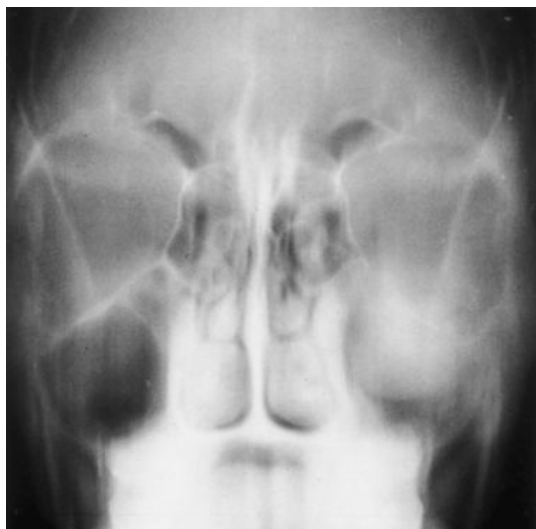

FIGURE 21-23. Polytomography cut showing large balloon-shaped pseudoprolapse of orbital tissues in the left maxillary antrum resulting from hematoma. (From Emery JM, Noorden GK von: Traumatic "pseudoprolapse" of orbital tissues into the maxillary antrum: A diagnostic pitfall. *Trans Am Acad Ophthalmol Otolaryngol* 79:893, 1975.)

late diplopia and enophthalmos and to avoid technical difficulties from scar formation and fibrosis if surgery is delayed. The questions arose as to whether all patients with radiographic evidence of an orbital floor fracture require surgical repair and how soon after the injury such repair should be attempted. Studies of the natural history of orbital floor fractures not surgically treated have shown clearly that not all patients require surgery.^{105, 297} Patients with orbital floor fractures who initially have no diplopia or in whom diplopia disappears within 14 days after injury should not undergo surgery.

The fact that diplopia after orbital injury is not always caused by incarceration of orbital tissues in the fracture site must be taken into consideration. Limitation of eye movement can be caused also by contusion of one or more extraocular muscles or their nerves. Of 40 blow-out fracture patients studied by Wojno, 7 had motility defects consistent with paralysis of one of the extraocular muscles or cranial nerves.⁴⁰¹ Restriction of ocular motility may also occur because of edema or hemorrhage within the orbit. In such cases, alleviation of the limitation of ocular motility and decrease of double vision can be expected soon after injury. Such changes may be subtle at first; therefore we recommend careful charting of diplopia fields in following these patients.

These factors also must be considered when

evaluating the results of the *forced duction test*. A positive test result in the early post-traumatic phase may be unrelated to actual incarceration of tissue. Only several days after the injury, when the initial effects of trauma have subsided, will the forced duction test become more reliable in the diagnosis of a blow-out fracture. When the patient is seen first in the emergency room and the diagnosis of an orbital floor fracture has been confirmed by a CT scan, one of us (E.C.) places a traction suture through the inferior rectus muscle insertion to fixate the eye in a position of elevation for about a week. He has found that surgery may be avoided with this method in many cases.⁵⁹

Surgical repair has been advocated even in the absence of diplopia to prevent development of enophthalmos. Enophthalmos occurs rarely in the immediate post-traumatic phase, and if it does occur, usually signifies a massive defect in the orbital floor that must be repaired without much delay. Measurement of the orbital volume by CT within 20 days after injury may identify those patients at risk for late enophthalmos.³⁹⁶

In most instances enophthalmos does not develop until months after the injury. Its etiology may be unrelated to actual loss of orbital tissue into the maxillary antrum but rather caused by a contusion injury with subsequent shrinkage of the orbital fat tissue, possibly from interference with its blood supply. Clearly, surgical repair of the fracture would not prevent this complication, and Emery and coworkers¹⁰⁵ have shown that the occurrence of enophthalmos is unrelated to whether the fracture was repaired or not. Once it has been established that there is no improvement in a clinically significant defect of ocular motility, the radiographic findings are positive for a fracture, and the results of the forced duction test indicate incarceration of orbital tissue, surgery should be delayed no longer. Exploration of the orbital floor is performed under general anesthesia. The surgical technique that we use has been described and illustrated by Goldberg,¹³⁰ and only a brief summary of the procedure follows.

The infraorbital rim is exposed through a curvilinear incision through the fold of the lower lid. The periosteum is incised slightly below the orbital rim and elevated posteriorly to expose the fracture site. Special care must be exercised not to confuse the infraorbital groove with a fracture line or to mistake the infraorbital nerve for incarcerated tissue. Once the limits of the fracture have been identified, the herniated tissue is gently ex-

traced from the defect in the bony orbital floor. Occasionally, difficulties are encountered in freeing all the incarcerated tissues when using the orbital approach. Should this occur, combined manipulation of the tissue from above and below, through a transoral Caldwell-Luc approach, is recommended. It is advisable therefore to have an otolaryngologist standing by to join the operating team and perform the Caldwell-Luc procedure if this complication occurs. The fractured floor components are elevated and replaced in their normal position. When a large bony defect is encountered, a piece of 0.3 mm Supramid sheath should be sutured to the bone or periosteum to seal the orbital floor and prevent migration or extrusion. The periosteum is closed with 3-0 chromic gut and the skin wound with interrupted 6-0 silk sutures.

The most serious complication after repair of orbital floor fractures is loss of light perception as a result of postoperative orbital hemorrhage, occlusion of the central retinal artery, or damage to the optic nerve during surgery. Less serious postoperative complications include extrusion of the implant, ectropion of the lower lid, and persistent diplopia. The diagnosis and management of these and other complications have been discussed elsewhere.²⁵⁹

As mentioned above, some restriction of ocular motility as a result of tissue swelling is commonly encountered during the immediate postoperative period. If diplopia in primary position or in downward gaze persists for as long as several months after surgery, the defect must be reevaluated for further surgical treatment.

Ocular motility after repair of an orbital floor fracture may be limited because of incomplete liberation of incarcerated tissue (i.e., the fracture may have extended farther posteriorly than was apparent at the time of surgery) or by post-traumatic fibrosis, loss of elasticity, or paralysis of the inferior extraocular muscles. Diplopia in upward gaze usually can be ignored but should be corrected if it occurs in primary position or depression and the patient has a significant chin elevation. If the forced duction test reveals mechanical limitation of elevation, we first recess the ipsilateral inferior rectus and use adjustable sutures in adults. The contralateral superior rectus may be recessed at the same or at a subsequent surgical session to counteract the secondary hypertropia. In the case of a traumatic inferior rectus palsy, depression of the eye will be limited, and resection of the paralyzed muscle combined with recession

of its antagonist is usually effective in eliminating double vision in downward gaze.^{263, 381}

Fracture of the Medial Orbital Wall

A less well-known sequela of orbital trauma is a fracture of the medial orbital wall as an isolated lesion or accompanying a fracture of the floor.^{94, 98, 397} Adduction will be limited and this limitation can reach severe degrees as shown by the tragic Case 21-4.

CASE 21-4

A 26-year-old woman without previous ocular complaints underwent a right ethmoidectomy through a transnasal approach. Upon awakening she noted that she could not see with her OD. Upon examination 10 days after surgery, visual acuity OD was found to be reduced to finger counting at 1 m, her acuity OS was 6/6. OS was in a position of abduction and could not be moved into primary or any other gaze position (Fig. 21-24). The pupil of OD was dilated and fixed. The forced duction test showed that the eye could not be moved at all by passive force. CT showed a large defect of the right medial orbital wall with incarceration of the optic nerve and medial rectus muscle in the ethmoidal sinus (Fig. 21-25). Apparently, the orbit had been entered during the ethmoidectomy and these orbital tissues had been pulled into the ethmoidal sinus. A surgical attempt to free this restriction was unsuccessful. Within a matter of several days of observation visual acuity OD decreased to no light perception. A second attempt by another surgeon to mobilize the eye

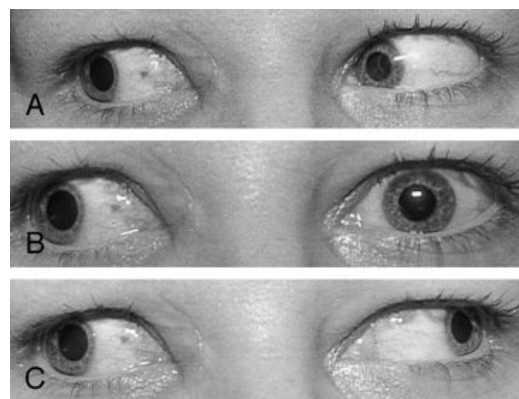


FIGURE 21-24. Case 21-4. Note immobility of the right eye, which is fixed in a position of abduction as the left eye adducts (A), fixates in primary position (B), and abducts (C).

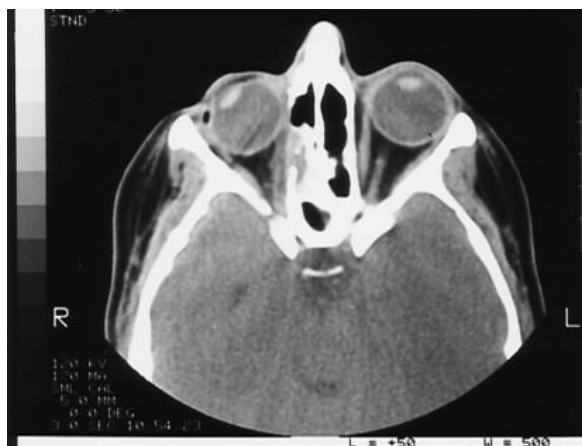

FIGURE 21-25. Case 21-4. Note fracture of the right medial orbital wall with incarceration of the right medial rectus muscle and optic nerve into the fracture site.

about a year later was reported to have caused only temporary improvement. The patient has been fitted with a scleral contact lens.

Several similar cases have been reported.^{61, 102}

Superior Oblique Myokymia

Clinical Findings and Etiology

Episodic nystagmoid intorsion and depression of one eye, accompanied by visual shimmer and oscillopsia, although mentioned by Alexander Duane in 1906⁹⁷ and, more recently, by Clark,⁶⁷ was not sufficiently recognized as a distinct clinical entity until Hoyt and Keane's classic description of *benign superior oblique myokymia*.¹⁶⁸ The onset of this condition is, as a rule, in adulthood, and the symptoms are most annoying to the patient. The diagnosis is often missed by the primary physician, and we have seen several cases diagnosed elsewhere as having a functional disorder. However, careful examination, with the slit lamp if necessary, will reveal high-frequency and low-amplitude torsional and vertical oscillations of the affected eye during an attack. Each episode may last from 20 seconds to up to several minutes, with recurrences at irregular intervals, usually several times each day. In some patients the attacks are precipitated by downward gaze or by physical activity. One of our patients reported episodes of superior oblique myokymia during sexual intercourse and while lifting weights. Duration and frequency of these episodes tend to increase with

time and long-term observation has established the chronicity of the condition.

Superior oblique myokymia is usually benign and in most instances not accompanied by other conditions. However, association with a posterior fossa tumor has been described and the myokymia was the only neurologic sign.^{88, 257} In another instance myokymia developed in a patient with a dural arteriovenous fistula.¹²⁴ Myokymia has also been reported to occur months and years after acquired superior oblique paralysis, perhaps as a manifestation of a *postdenervation phenomenon*.²¹⁷ This possibility is further supported by the results of MRI in two patients which showed the cross-sectional area of the superior oblique muscle to be smaller than normal.²³⁷ On the basis of electromyographic recordings from the ipsilateral superior oblique muscle, a nuclear disorder^{164, 168, 190} or a supranuclear response to peripheral injury of the trochlear nerve has been implicated.²⁰² An analysis of eye movements with the search coil technique taken with electromyographic evidence from other studies led Leigh and coworkers²¹⁸ to propose that myokymia reflects *spontaneous discharge of trochlear neurons that have undergone regenerative changes*. The observation of myokymia developing after superior oblique paralysis²¹⁷ and the MRI findings²³⁷ seem to support this theory.

Therapy

Medical treatment with carbamazepine (Tegretol), phenytoin, clonazepam, baclofen, and propranolol hydrochloride or the topical use of a beta blocker^{25, 221} has been reported to be successful.^{168, 194, 312, 359, 366, 378, 392}

We have been unimpressed with medical treatment in controlling the symptoms on a long-term basis in the five patients we have treated. Similar conclusions were reached in a survey of 16 patients followed at the Wilmer Institute.³⁷ Prolonged use of carbamazepine is not without risks and requires regular monitoring of the blood count. Drowsiness, dizziness, a potential teratogenic effect during pregnancy, and incompatibility with alcohol and barbiturates are but some of the reasons why in our experience most patients, given the alternative, eventually opt for surgery.

Surgical treatment consists of a tenotomy or tenectomy of the superior oblique tendon, usually combined with myectomy of the ipsilateral inferior oblique.^{91, 168, 202, 366, 392} One patient responded

well to a nasal recession of the anterior portion of the superior oblique tendon.²⁰⁴ Microvascular decompression of the trochlear nerve at the root exit zone has also been reported to be successful³²¹ but appears to us as an unnecessarily complex procedure, considering the ease with which surgery on both oblique muscles can be performed.

Several authors have stressed that more than one operation may be necessary,²⁷³ and in one instance a superior oblique myectomy with trochlectomy had to be performed after failure of superior oblique tenectomy to adequately eliminate symptoms.³¹⁶

We are inclined to blame the postoperative recurrences of oscillopsia reported in the literature on an incomplete transection of the tendon and its sheath or on adhesions between the proximal stump of the tendon and the superonasal aspect of the globe. The first complication can be avoided by adequate surgical exposure and meticulous operating technique (see Chapter 26), the second by removing a large segment of the tendon and sheath.

Ocular Myasthenia Gravis

Clinical Findings

Myasthenia gravis is of interest primarily to the neuro-ophthalmologist. Several reviews are available in the recent literature.^{86, 95, 394} Isolated case descriptions can be found in the literature as early as 1672³⁹⁴ but the first detailed report of three patients was that by Erb¹⁰⁸ in 1879 whose name has remained associated with the disease. A brief discussion of ocular myasthenia in this chapter is in order because of the ocular motility disturbances frequently associated with this disease.

Myasthenia is an acquired autoimmune disease, affecting synaptic transmission across the neuromuscular junction in which the number of available acetylcholine receptors is decreased.¹¹² A close relationship exists between myasthenia gravis and hyperplasia of the thymus, and thymectomy is followed occasionally by a dramatic remission of symptoms.^{340, 402}

A pure ocular form of the disease exists, but more frequently other muscles, especially those involved in mastication and breathing, become affected.⁵⁷ The specific characteristics of extraocular muscles, rapid contraction rate, and high firing frequency of the fast twitch fibers (see Chapter 6)

make the extraocular muscles especially vulnerable to the disease. Diplopia and ptosis are the first symptoms in half the cases. The first symptoms may be preceded by an emotional upset, upper respiratory infections, or pregnancy.³⁹⁰ These symptoms may be absent or less pronounced on awakening, then progress dramatically with increased muscular activity. Ptosis is often asymmetrical, may be completely unilateral, and infrequently involves both eyes to the same degree. In most instances the motility disturbances are fleeting, may affect any or all of the extraocular muscles, range from slight paresis to complete gaze paralysis, and may simulate paralyzes of cranial nerves III, IV, and VI. Paresis of upward gaze is an early manifestation of the disease.³⁹⁰ Cogan's lid twitch sign⁷⁰ is a helpful diagnostic sign in the early stages of the disease: after rapidly and repeatedly looking from downward gaze into the primary position, the upper lid(s) will elevate excessively for a brief moment and may twitch several times. Weakness of adduction of either eye and nystagmus of the abducting eye may mimic an internuclear ophthalmoplegia and one of us (G.K.v.N.) had the privilege to examine, together with the late Dr. Frank Walsh, one of the first recognized cases of *pseudo-internuclear ophthalmoplegia* in association with myasthenia that was later published by Glaser.¹²⁸

The disease is more prevalent in women than in men (3:1) although the ocular form affects men more frequently, especially after the age of 40 years.³⁹⁴ As a rule the first symptoms occur between the second and fourth decades of life.^{140, 358} However, Walsh and Hoyt³⁹⁰ have commented that the onset of myasthenia gravis may occur as early as the first year or as late as the seventh decade of life. We have observed children between the ages of 2 and 4 years who developed the disease and occurrence in children younger than that has been described.⁸⁶

Diagnosis

The diagnosis of myasthenia gravis is based on demonstration of easy muscular fatigability and its rapid relief by systemic administration of an anticholinesterase agent such as edrophonium chloride (Tensilon). The improvement of ptosis is often more dramatic than the improvement of ocular motility, which may be subtle and of very short duration. We prefer to administer the Tensilon test with the patient seated before a deviometer while

the strabismus angle is being measured by an orthoptist. Coll and Demer⁷² advocated performing the test while the angle of strabismus is being monitored on a Hess screen, which seems to be an even more accurate method to evaluate ocular motility during the injection.

We use a 10-mg/mL solution of Tensilon intravenously. A second syringe containing 0.5 to 1.0 mg of atropine to counteract side effects should be readily available. Initially, a 1- to 2-mg test dose is given and the patient is observed for the development of hypotension, bradycardia, or arrhythmia. Fortunately, such side effects occur infrequently. The injection is then continued in additional increments of 1 to 2 mg every 60 seconds until a positive response is obtained or the syringe is empty.

If the test result is ambiguous a determination of circulating antiacetylcholine receptor antibodies may be helpful in establishing the diagnosis. These antibodies have been found in up to 87% of patients with the disease.³⁹⁴ Electromyography is useful as an auxiliary diagnostic test since it shows a characteristic myopathic pattern (Fig. 21–26). This test is helpful in differentiating the ocular involvement of myasthenia gravis from a peripheral neurogenic paresis.^{38, 170, 277, 369}

Therapy

Treatment is directed toward providing the patient with symptomatic relief from double vision or obstruction of vision by a drooping upper lid and should be initiated and supervised by a neurologist. In our experience, cholinesterase inhibitors (pyridostigmine bromide, Mestinon) are rarely successful in completely controlling ptosis and diplopia in the ocular form of the disease. Oral corticosteroids are often more effective in alleviating ocular myasthenia. If medical treatment is unsuccessful, the clinician may have to resort to

occluding one eye to eliminate double vision or to keeping the lid(s) elevated by a ptosis crutch.

As a rule, surgery is not indicated for this condition. Exceptions occur, however, in the instance of a myasthenic patient with long-term and stable paresis or paralysis of a particular muscle or muscle group or stable comitant strabismus who does not respond to medical therapy. We have been able to eliminate diplopia by muscle surgery in several such patients after ascertaining the stability of the condition during prolonged periods of observation. Others have also obtained satisfactory results with surgery in selected cases.^{2, 85, 266}

Chronic Progressive External Ophthalmoplegia (Ocular Myopathy of von Graefe)

Clinical Findings and Etiology

Chronic progressive external ophthalmoplegia (CPEO) is a rare and, as its name implies, progressive disorder that affects ocular motility and the function of the levator palpebrae muscle. This condition also belongs in the realm of neuro-ophthalmology, and the reader is referred to the standard texts for detailed information. CPEO was first described by von Graefe¹³⁸ and is characterized by bilateral ptosis and decreasing motility of the eyes in all directions of gaze. Its etiology is still disputed, and there has been extensive discussion as to whether this disease is caused by a central lesion involving the ocular motor nuclei^{43, 84} or by a primary myopathy of the extraocular muscles similar to muscular dystrophy.¹⁹⁷ Histologic evidence has been presented to support both hypotheses. Electromyographic data, on the other hand, clearly indicate a *myopathy of the extraocular muscles*.^{40, 369} The frequent association of chronic progressive external ophthalmoplegia




FIGURE 21–26. Electromyogram from extraocular muscle in myasthenia gravis. Decreased frequency and amplitude of action potentials after prolonged voluntary innervation (*upper tracing*); activation of numerous motor units and increase of discharge frequency after intravenous injection of 10 mg edrophonium chloride (Tensilon) (*lower tracing*). (From Huber A: Die peripheren Augenmuskellähmungen. *Ber Dtsch Ophthalmol Ges* 67:26, 1966.)

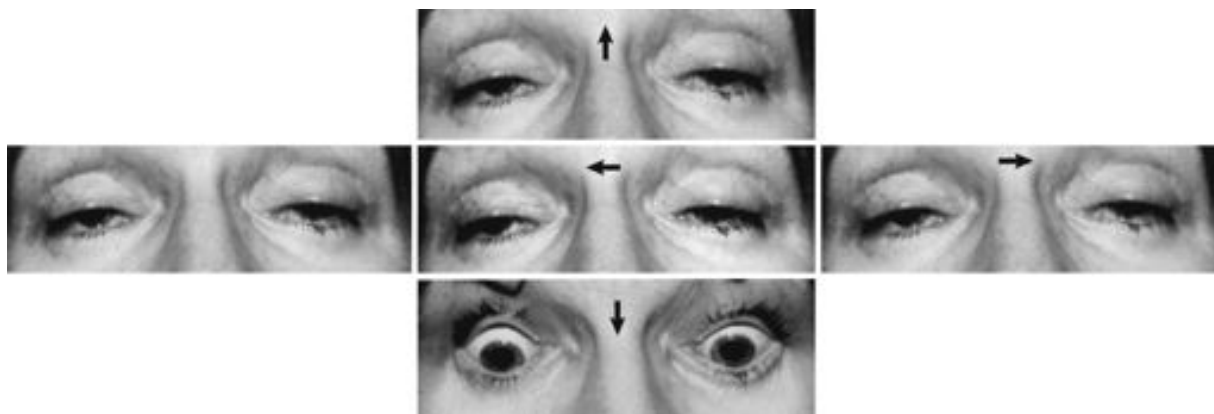

FIGURE 21-27. Endstage of chronic progressive external ophthalmoplegia in a 44-year-old woman. Note bilateral incomplete blepharoptosis and almost complete inability to move the eyes into any position except depression.

with pigmentary and other forms of retinal degeneration has led Thorson and Bell³⁷⁰ to postulate that this disease may be considered abiotrophic. Recent advances in molecular genetics (for a review of the literature, see Wallace et al.³⁸⁹) have identified CPEO as a mitochondrial cytopathy, especially in highly oxidative tissue such as muscle, brain, and heart.

The onset is usually before 30 years of age, and in some cases the disease occurs early in childhood. Both sexes are equally involved, and familial occurrence is frequent.^{390, p.1254} Ptosis, which as a rule is bilateral, is often the first symptom, followed by slowly progressive limitation of ocular motility with a predominant involvement of the elevating muscles (Fig. 21-27). In the extreme case, both eyes may become “frozen.” In the advanced stage, complete ptosis may force the patient’s chin to be maximally elevated to allow vision. In patients with ocular myopathy, unlike those with myasthenia gravis, there are no remissions and anticholinesterase agents have no effect on muscular function. Complaints about diplopia are, curiously, rare, even though a severe disturbance of ocular motility may be present. In addition to involvement of the extraocular and levator muscles, the orbicularis and other facial muscles may become affected, especially those used in mastication. Atrophy of the extraocular muscles, especially a decrease of muscle thickness, can be demonstrated on CT scans.²⁷²

Therapy

In advanced disease a ptosis crutch may help the patient; however, a lid suspension procedure often

becomes necessary. Special care must be taken to protect the cornea during sleep by taping the lids at night. Prisms may be helpful in eliminating diplopia in some patients, and surgical alignment of the eyes has been reported to create satisfactory results.^{355, 367, 389} We have no personal experience with surgery on the extraocular muscles for this condition.

REFERENCES

1. Abe R, Awaya S, Yagasaki T, et al: Two cases of cyclic exotropia. *Folia Ophthalmol Jpn* 44:1439, 1993.
2. Acheson JF, Elston JS, Lee JP, Fells P: Extraocular muscle surgery in myasthenia gravis. *Br J Ophthalmol* 75:232, 1991.
3. Adler FH: Superior oblique tendon sheath syndrome of Brown. *Arch Ophthalmol* 48:264, 1959.
4. Aebli R: Retraction syndrome. *Arch Ophthalmol* 10:602, 1933.
5. Aichmair H: Zyklisches Einwärtsschielen (alternate day squint). *Wien Klin Wochenschr* 89:133, 1977.
6. Akman A, Dayanir V, Sener EC, Sanaç AS: Acquired Duane retraction syndrome. *J Pediatr Ophthalmol Strabismus* 33:267, 1996.
7. Anderson RL, Tweeten JP, Patrinely JR, et al: Dysthyroid optic neuropathy without extraocular muscle involvement. *Ophthalmic Surg Lasers* 20:568, 1989.
8. Apple C: Congenital abducens paralysis. *Am J Ophthalmol* 22:169, 1939.
9. Appukuttan B, Gillanders E, Juo SH, et al: Localization of a gene for Duane retraction syndrome to chromosome 2q31. *Am J Hum Genet* 65:1639, 1999.
10. Arimoto H: Ocular findings of thalidomide embryopathy. *Jpn J Clin Ophthalmol* 33:501, 1979.
11. Assaf AA: Bilateral congenital vertical gaze disorders: Congenital muscle fibrosis or congenital central nervous abnormality? *Neuro Ophthalmol* 17:23, 1997.
12. Avilla CW, Noorden GK von: Posttraumatic fusion deficiency. In Ravault A, Lenk M, eds: *Transactions of the Fifth International Orthoptic Congress*. Lyon, LIPS, 1984, p 143.
13. Aydin P, Kansu T, Sanac AS: High myopia causing bilateral abduction deficiency. *J Clin Neuro Ophthalmol* 12:163, 1992.

14. Axenfeld T, Schürenberg E: Angeborene Retractionsbewegungen. *Klin Monatsbl Augenheilkd* 39:851, 1901.
15. Bagolini B, Tamburrelli C, Dickmann A, Colosimo C: Convergent strabismus fixus in high myopic patients. *Doc Ophthalmol* 74:309, 1990.
16. Bagshaw J: The heavy eye phenomenon: A preliminary report. *Br Orthopt J* 23:75, 1966.
17. Bahn RS, Heufelder AE: Pathogenesis of Graves' ophthalmopathy. *N Engl J Med* 329:1468, 1993.
18. Bahr K: Vorstellung eines Falles von eigenartiger Muskelanomalie eines Auges. *Ber Dtsch Ophthalmol Ges* 25:334, 1896.
19. Bartley GB, Fatourechhi V, Kadrmas EF, et al: Clinical features of Graves' ophthalmopathy in an incidence cohort. *Am J Ophthalmol* 121:284, 1996.
20. Beck M, Hickling P: Treatment of bilateral superior oblique tendon sheath syndrome complicating rheumatoid arthritis. *Br J Ophthalmol* 64:358, 1980.
21. Behrendt A, Rochels R: Zum Entstehungsmechanismus von Orbitabodenfrakturen. *Ophthalmologe* 90:31, 1993.
22. Berke RN: Tenotomy of the superior oblique muscle for hypertropia. *Arch Ophthalmol* 38:605, 1947.
23. Berke RN: Surgical treatment of hypertropia. In *Strabismus. Symposium of the New Orleans Academy of Ophthalmology*. St Louis, Mosby-Year Book, 1962, p 219.
24. Bessant DAR, Lee JP: Management of strabismus due to orbital myositis. *Eye* 9:558, 1995.
25. Bibby K, Deane JS, Farnworth D, Cappin J: Superior oblique myokymia—a topical solution? *Br J Ophthalmol* 78:882, 1994.
26. Bielschowsky A: Das Einwärtsschielen der Myopen. *Ber Dtsch Ophthalmol Ges* 43:245, 1922.
27. Bielschowsky A: Lectures on Motor Anomalies. Hanover, NH, Dartmouth College Publications, 1943/1956.
28. Bixenman WW, Noorden GK von: Benign recurrent VI nerve palsy in childhood. *J Pediatr Ophthalmol Strabismus* 28:29, 1981.
29. Blodi FC, Van Allen MW, Yarbrough JC: Duane syndrome: A brain stem lesion. *Arch Ophthalmol* 72:171, 1964.
30. Bloom JN, Graviss ER, Mardelli PG: A magnetic resonance imaging study of the upshoot-downshoot phenomenon of Duane retraction syndrome. *Am J Ophthalmol* 111:548, 1991.
31. Boergen K-P: Squint operation under topical anesthesia in endocrine orbitopathy. *Strabismus* 1:167, 1993.
32. Böhm L: Schielen und der Sehnenschnitt in seinen Wirkungen auf Stellung und Sehkraft der Augen. Eine Monographie. Berlin, Duncker & Humblot, 1845, p 3.
33. Booth-Mason S, Kyle GM, Rossor M, Bradbury P: Acquired Brown's syndrome: An unusual case. *Br J Ophthalmol* 69:791, 1985.
34. Bradbury JA, Martin L, Strachan IM: Acquired Brown's syndrome associated with Hurler-Scheie's syndrome. *Br J Ophthalmol* 73:305, 1989.
35. Brain R: Pathogenesis and treatment of endocrine exophthalmos. *Lancet* 1:109, 1959.
36. Braley AE: Personal communication, 1956.
37. Brazis PW, Miller NR, Henderer JD, Lee AG: The natural history and results of treatment of superior oblique myokymia. *Arch Ophthalmol* 112:1063, 1994.
38. Breinin GM: Electromyography: A tool in ocular and neurologic diagnosis. I. Myasthenia gravis. *Arch Ophthalmol* 57:161, 1957.
39. Breinin GM: Electromyography: A tool in ocular and neurologic diagnosis. II. Muscle palsies. *Arch Ophthalmol* 57:165, 1957.
40. Breinin GM: New aspects of ophthalmoneurologic diagnosis. *Arch Ophthalmol* 58:375, 1957.
41. Breinin GM: Round table discussion. In *Strabismus. Symposium of the New Orleans Academy of Ophthalmology*. St Louis, Mosby-Year Book, 1962, p 345.
42. Bremer JL: Recurrent branches of abducens nerve in human embryos. *Am J Anat* 28:371, 1921.
43. Brion S, de Recondo J: Ophthalmoplégie nucléaire progressive et hérédodégénérescence spinocérébelleuse: Étude d'un cas anatomo-clinique. *Rev Neurol* 116:383, 1967.
44. Brodsky MC, Pollock SC, Buckley EG: Neural misdirection in congenital ocular fibrosis syndrome: Implications and pathogenesis. *J Pediatr Ophthalmol Strabismus* 26:159, 1989.
45. Brown HW: Congenital structural muscle anomalies. In Allen JH, ed: *Strabismus Ophthalmic Symposium I*. St Louis, Mosby-Year Book, 1950, p 205.
46. Brown HW: Isolated inferior oblique paralysis. Analysis of 97 cases. *Trans Am Ophthalmol Soc* 55:415, 1957.
47. Brown HW: Congenital structural anomalies of the muscles. In Allen JH, ed: *Strabismus Ophthalmic Symposium II*. St Louis, Mosby-Year Book, 1958, p 391.
48. Brown HW: Strabismus in the adult. In *Strabismus. Symposium of the New Orleans Academy of Ophthalmology*. St Louis, Mosby-Year Book, 1962, p 248.
49. Brown H: Round table session 2. In Arruga A, ed: *International Strabismus Symposium*, University of Giessen, Germany, 1966. Basel, S Karger, 1968, p 210.
50. Brown HW: True and simulated superior oblique tendon sheath syndromes. *Doc Ophthalmol* 34:123, 1973.
51. Brown J, Coburn JW, Wigod RI, et al: Adrenal steroid therapy of severe infiltrative ophthalmopathy of Graves' disease. *Am J Med* 34:786, 1963.
52. Bullen CL, Younge BR: Chronic orbital myositis. *Arch Ophthalmol* 100:1749, 1982.
53. Burde RM: Graves' ophthalmopathy and the special problem of concomitant ocular myasthenia gravis. Richard G. Scobee Memorial Lecture. *Am Orthopt J* 40:37, 1990.
54. Burian HM: Round table discussion. In Allen JH, ed: *Strabismus Ophthalmic Symposium II*. St Louis, Mosby-Year Book, 1958, p 488.
55. Calabrese G, Stuppia L, Morizio E, et al: Detection of an insertion deletion of region 8q13-q21.2 in a patient with Duane syndrome: Implications for mapping and cloning a Duane gene. *Eur J Hum Genet* 6:187, 1998.
56. Caldeira JA: Presumptive Brown's syndrome in dizygotic female twins: Case report and review of 30 familial cases in the literature. *Binocular Vision Strabismus Q* 11:23, 1996.
57. Campbell H, Bramwell E: Myasthenia gravis. *Brain* 23:277, 1900.
58. Campbell RJ: Pathology of Graves' ophthalmopathy. In Gorman CA, Waller RR, Dyer JA, eds: *The Eye and the Orbit in Thyroid Disease*. New York, Raven Press, 1984, p 25.
59. Campos EC, Chiesi C: Trazione in elevazione del bulbo oculare nei traumi orbitari con frattura sospetta o accertata del pavimento. *Chir Testa Collo* 2:57, 1985.
60. Caputo AR, Wagner RS, Guo S, Santiago P: Infantile abduction deficit: Duane retraction syndrome or abducens palsy? A study of 234 cases. *Binocular Vision Strabismus Q* 11:213, 1996.
61. Carter K, Lee AG, Tang RA, et al: Neuro-ophthalmologic complications of sinus surgery. *Neuro Ophthalmol* 19:75, 1998.
62. Catford GV, Hart JCD: Superior oblique tendon sheath syndrome. An electromyographic study. *Br J Ophthalmol* 55:155, 1971.
63. Chamberlain W: Cyclic esotropia. *Am Orthopt J* 18:31, 1968.
64. Chew CKS, Foster P, Hurst JA, Salmon J: Duane retrac-

- tion syndrome associated with chromosome 4q27–31 segment deletion. *Am J Ophthalmol* 119:807, 1995.
65. Christiansen SP, Thomas AH: Postpartum Brown's syndrome. *Arch Ophthalmol* 112:23, 1994.
 66. Chung M, Stout JT, Borchert MS: Clinical diversity of hereditary Duane syndrome. *Ophthalmology* 107:500, 2000.
 67. Clark E: A case of apparent intermittent overaction of the left superior oblique muscle. *Br Orthopt J* 23:116, 1966.
 68. Clarke M, Johnson FM, Harcourt B: Left Duane retraction syndrome associated with dissociated vertical divergence (case report). *Br Orthopt J* 45:78, 1988.
 69. Coats D, Paysse EA, Plager DA, Wallace DK: Early strabismus surgery for thyroid ophthalmopathy. *Ophthalmology* 106:324, 1999.
 70. Cogan D: Myasthenia gravis—a review of the disease and a description of lid twitch as characteristic clinical sign. *Arch Ophthalmol* 74:217, 1965.
 71. Cole MD, Hay A, Eagling EM: Cyclic esotropia in a patient with unilateral traumatic aphakia: Case report. *Br J Ophthalmol* 72:305, 1988.
 72. Coll GE, Demer JL: The edrophonium-Hess screen test in the diagnosis of ocular myasthenia gravis. *Am J Ophthalmol* 114:489, 1992.
 73. Cordonnier M, Schakal A, van Nechel C, et al: Severe myopia and restrictive motility disturbance. *Neuro Ophthalmol* 12:97, 1992.
 74. Costenbader FD, Albert DG: Spontaneous regression of pseudoparalysis of the inferior oblique muscle. *Arch Ophthalmol* 59:607, 1958.
 75. Costenbader FD, Mousel DK: Cyclic esotropia. *Arch Ophthalmol* 71:180, 1964.
 76. Crawford JS: Surgical treatment of true Brown's syndrome. *Am J Ophthalmol* 81:289, 1976.
 77. Crawford JS, Orton R, Labow-Daily L: Late results of superior oblique muscle tenotomy in true Brown's syndrome. *Am J Ophthalmol* 89:824, 1980.
 78. Cricchi M: Su di un nuovo caso di sindrome di lacrime di coccodrillo di natura congenita associata alla sindrome di Stilling-Türk-Duane. *Boll Ocul* 41:587, 1962.
 79. Cross HE, Pfaffenbach DD: Duane retraction syndrome and associated congenital malformations. *Am J Ophthalmol* 73:442, 1972.
 80. Crosswell HH, Haldi BA: The superior oblique tendon sheath syndrome. A report of two bilateral cases. *J Pediatr Ophthalmol* 4:8, 1967.
 81. Cullen P, Rodgers CS, Callen DF, et al: Association of familial Duane anomaly and urogenital abnormalities with a bisatellited marker derived from chromosome 22. *Am J Med Genet* 47:925, 1993.
 82. Daicker B: Das gewebliche Substrat der verdickten äusseren Augenmuskeln bei der endokrinen Orbitopathie. *Klin Monatsbl Augenheilkd* 174:843, 1979.
 83. Danis P: Sur les anomalies congénitales de la motilité oculaire d'origine musculaire et en particulier sur le syndrome de Stilling-Türk-Duane. *Ann Ocul* 181:148, 1948.
 84. Daroff RB, Solitaire GB, Pincus JH, Glaser GH: Spongiform encephalopathy with chronic progressive external ophthalmoplegia. Central ophthalmoplegia mimicking ocular myopathy. *Neurology* 16:161, 1966.
 85. Davidson JL, Rosenbaum AL, McCall LC: Strabismus surgery in patients with myasthenia. *J Pediatr Ophthalmol Strabismus* 30:292, 1993.
 86. Davitt BV, Fenton GA, Cruz OA: Childhood myasthenia. *J Pediatr Ophthalmol Strabismus* 37:5, 2000.
 87. Decker W de: Kestenbaum transposition operation for treatment of the Duane I retraction syndrome. *Trans Ophthalmol Soc U K* 100:479, 1980.
 88. Dehaene I, Casselman J: Left superior oblique myokymia and right superior oblique paralysis due to a posterior fossa tumor. *Neuro Ophthalmol* 13:13, 1992.
 89. Demer JL, Noorden GK von: High myopia as an unusual cause of restrictive motility disturbance. *Surv Ophthalmol* 33:281, 1989.
 90. DeRespinis PA, Caputo AR, Wagner RS, Guo S: Duane retraction syndrome. *Surv Ophthalmol* 38:257, 1993.
 91. de Sa LC, Good WV, Hoyt CS: Surgical management of myokymia of the superior oblique muscle. *Am J Ophthalmol* 114:693, 1992.
 92. Doberty EJ, Macy ME, Wang SM, et al: A new extraocular congenital fibrosis syndrome that maps to 16q24.2–q24.3. *Invest Ophthalmol Vis Sci* 40:1687, 1999.
 93. Dobler AA, Sondhi N, Cantor LB, Ku S: Acquired Brown's syndrome after a double-plate Molteno implant. *Am J Ophthalmol* 116:641, 1993.
 94. Dodick JM, Galin MA, Kwitko M: Medial wall fracture of the orbit. *Can J Ophthalmol* 4:377, 1969.
 95. Drachmann DB: Myasthenia gravis. *N Engl J Med* 3330:1787, 1994.
 96. Duane A: Congenital deficiency of abduction associated with impairment of adduction, retraction movements, contraction of the palpebral fissure and oblique movements of the eye. *Arch Ophthalmol* 34:133, 1905.
 97. Duane A: Unilateral rotary nystagmus. *Trans Am Ophthalmol Soc* 11:63, 1906.
 98. Duane TD, Schatz NJ, Caputo AR: Pseudo-Duane retraction syndrome. *Trans Am Ophthalmol Soc* 74:122, 1976.
 99. Duke-Elder S: System of Ophthalmology, vol 3, pt 2: Congenital Deformities. St Louis, Mosby-Year Book, 1963, p 991.
 100. Dunlap E: In discussion of Gobin MH: Surgical management of Duane syndrome. *Br J Ophthalmol* 58:301, 1974.
 101. Dunnington JH, Berke RN: Exophthalmos due to chronic orbital myositis. *Arch Ophthalmol* 30:446, 1943.
 102. Eitzen JP: Strabismus following endoscopic intranasal sinus surgery. *J Pediatr Ophthalmol Strabismus* 28:168, 1991.
 103. Emery JM, Noorden GK von: Traumatic "pseudoprolapse" of orbital tissues into the maxillary antrum: A diagnostic pitfall. *Trans Am Acad Ophthalmol Otolaryngol* 79:893, 1975.
 104. Emery JM, Noorden GK von, Schlernitzauer DA: Management of orbital floor fractures. *Am J Ophthalmol* 74:299, 1972.
 105. Emery JM, Noorden GK von, Schlernitzauer DA: Orbital floor fractures: Long-term follow-up of cases with and without surgical repair. *Trans Am Acad Ophthalmol Otolaryngol* 75:802, 1972.
 106. Engle E: The genetics of strabismus: Duane, Moebius, and fibrosis syndromes. In Traboulsi E, ed: Genetic Diseases of the Eye. A Textbook and Atlas. New York, Oxford University Press, 1998, p 477.
 107. Engle EC, Goumnerov BC, McKeown CA, et al: Oculomotor nerve and muscle abnormalities in congenital fibrosis of the extraocular muscles. *Ann Neurol* 41:314, 1997.
 108. Erb W: Zur Casuistik der bulbären Lähmungen. *Arch Psychiatr Nervenkr* 9:325, 1879.
 109. Esser J: Endokrine orbitopathie. *Ophthalmologie* 91:3, 1994.
 110. Esslen E, Pabst W: Die Bedeutung der Elektromyographie für die Analyse von Motilitätsstörungen der Augen. *Bibl Ophthalmol* 57:100, 1961.
 111. Eustis HS, O'Reilly C, Crawford JS: Management of superior oblique palsy after surgery for true Brown's syndrome. *J Pediatr Ophthalmol Strabismus* 24:10, 1987.
 112. Fambrough DM, Drachman DB, Satyamurti S: Neuro-muscular junction in myasthenia gravis: Decreased acetylcholine receptors. *Science* 182:293, 1973.
 113. Feldon SE, Muramatsu S, Werner JM: Clinical classification of Graves' ophthalmopathy. Identification of risk

- factors for optic neuropathy. *Arch Ophthalmol* 102:1469, 1984.
114. Feric-Swiwerth F: Ein Beitrag zur Kenntnis des Musculus obliquus superior Sehnenscheidensyndroms (Brown's syndrome). In *Orthoptics. Proceedings of the Second International Orthoptic Congress*. Amsterdam, 1972, *Excerpta Medica*.
 115. Fink WH: A study of the anatomical variations in the attachment of the oblique muscles of the eyeball. *Trans Am Acad Ophthalmol Otolaryngol* 51:500, 1947.
 116. Fink WH: The anatomy of the extrinsic muscles of the eye. In Allen JH, ed: *Strabismus Ophthalmic Symposium II*. St Louis, Mosby-Year Book, 1958, p 17.
 117. Finlay A, Powell S: Brown's syndrome in identical twins. *Br Orthopt J* 39:73, 1982.
 118. Fodor F, Martha I, Fodor A: Retraktions-Syndrom in drei Generationen. In Deller M, Weiss JB, eds: *Acta Strabologica*, Lausanne, CERES, 1978, p 85.
 119. Folk E, Miller MT, Mittelman D, Mafee M: Simulated superior oblique tendon sheath syndrome. *Graefes Arch Clin Exp Ophthalmol* 226:410, 1988.
 120. Foster RS: Vertical muscle transposition augmented with lateral fixation. *J Am Assoc Pediatr Ophthalmol Strabismus* 1:20, 1997.
 121. Friendly DS, Manson RA, Albert DG: Cyclic strabismus—a case study. *Doc Ophthalmol* 34:189, 1973.
 122. Fujino T: Experimental "blow-out" fractures of the orbit. *Plast Reconstr Surg* 54:81, 1974.
 123. Garrity JA, Fatourech V, Bergstrahl EJ, et al: Results of transantral orbital decompression in 428 patients with severe Graves' ophthalmopathy. *Am J Ophthalmol* 116:533, 1993.
 124. Geis TC, Newman NJ, Dawson RC: Superior oblique myokymia associated with a dural arteriovenous fistula. *J Clin Neuro Ophthalmol* 16:41, 1996.
 125. Gillies WE, Brooks AMV, Scott M, McKelvie P: A case of divergent strabismus fixus. *Binocular Vision Strabismus Q* 14:40, 1999.
 126. Gillies WE, Harris AJ, Brooks AMV, Rivers MR: Congenital fibrosis of the vertically acting extraocular muscles. *Ophthalmology* 102:607, 1995.
 127. Girard LJ: Pseudoparalysis of the inferior oblique muscle. *South Med J* 49:342, 1956.
 128. Glaser JS: Myasthenic pseudo-internuclear ophthalmoplegia. *Arch Ophthalmol* 75:363, 1966.
 129. Gobin MH: Surgical management of Duane syndrome. *Br J Ophthalmol* 58:301, 1974.
 130. Goldberg M: Surgical repair of orbital blowout fractures. In Milauskas AT, ed: *Blowout Fractures of the Orbit*. Springfield, IL, Charles C Thomas, 1969, p 121.
 131. Goldhammer Y, Smith JL: Acquired intermittent Brown's syndrome. *Neurology* 24:666, 1974.
 132. Goldstein JE: Paresis of the superior rectus muscle associated with thyroid dysfunction. *Arch Ophthalmol* 72:5, 1964.
 133. Goldstein JH: Intermittent superior oblique tendon sheath syndrome. *Am J Ophthalmol* 67:960, 1969.
 134. Goldstein JH, Schneekloth BB, Babb J, et al: Acquired Brown's superior oblique sheath syndrome due to euthyroid Graves' disease ophthalmomyopathy. *Binocular Vision Strabismus Q* 5:93, 1990.
 135. Gorman CA, Waller RR, Dyer JA, eds: *The Eye and the Orbit in Thyroid Disease*. New York, Raven Press, 1984.
 136. Gourdeau A, Miller N, Zee D, Morris J: Central ocular motor abnormalities in Duane retraction syndrome. *Arch Ophthalmol* 99:1809, 1981.
 137. Gowan M, Levy I: Heredity in the superior tendon sheath syndrome. *Br Orthopt J* 25:91, 1968.
 138. Graefe A von: *Verhandlungen ärztlicher Gesellschaften*. Berl Klin Wochenschr 5:126, 1868.
 139. Gregersen E, Rindziunski E: Brown's syndrome—a longitudinal long-term study of spontaneous course. *Acta Ophthalmol Scand* 71:371, 1993.
 140. Grob D, Arsura EL, Brunner NG, Namba T: The course of myasthenia gravis and therapies affecting outcome. *Ann N Y Acad Sci* 505:472, 1987.
 141. Gross SA, Tien DR, Breinin GM: Aberrant innervational pattern in Duane syndrome type II without globe retraction. *Am J Ophthalmol* 117:348, 1994.
 142. Grove AS: Upper eyelid retraction and Graves' disease. *Ophthalmology* 88:499, 1981.
 143. Hales IB, Rundle FF: Ocular changes in Graves' disease: A long-term follow-up study. *Q J Med* 29:113, 1960.
 144. Hall R, Doniach D, Kirkham K, El Kabir D: Ophthalmic Graves' disease. Diagnosis and pathogenesis. *Lancet* 1:375, 1970.
 145. Hallin ES, Feldon SE: Graves' ophthalmopathy: I. Simple CT estimates of extraocular muscle volume. *Br J Ophthalmol* 72:674, 1988.
 146. Hamed LM: Bilateral Brown's syndrome in three siblings. *J Pediatr Ophthalmol Strabismus* 28:306, 1991.
 147. Hamed LM, Silbiger J: Periodic alternating esotropia. *J Pediatr Ophthalmol Strabismus* 29:240, 1992.
 148. Hansen E: Congenital general fibrosis of the extraocular muscles. *Acta Ophthalmol* 46:469, 1968.
 149. Harley RD, Rodrigues MM, Crawford JS: Congenital fibrosis of the extraocular muscles. *Trans Am Ophthalmol Soc* 76:197, 1978.
 150. Harrison RL: Loss of fusional vergence with partial loss of accommodative convergence and accommodation following head injury. *Binocular Vision Strabismus Q* 2:93, 1987.
 151. Hárting F, Koornneef L, Peeters HJ, Gillisen JPA: Decompression surgery in Graves' orbitopathy—a review of 14 years' experience at the Orbita Centrum, Amsterdam. *Dev Ophthalmol* 20:185, 1989.
 152. Hart CT: Disturbances of fusion following head injury. *Proc R Soc Med* 62:704, 1969.
 153. Hass HD: Zur Pseudoparese des Musculus obliquus inferior (traumatisches sheath syndrom). *Klin Monatsbl Augenheilkd* 144:118, 1964.
 154. Hayashi T, Iwashige H, Maruo T: Clinical features and surgery for acquired progressive esotropia associated with severe myopia. *Acta Ophthalmol Scand* 77:66, 1999.
 155. Hedera P, Friedland RP: Duane syndrome with giant aneurysm of the vertebral basilar arterial junction. *J Clin Neuro Ophthalmol* 13:271, 1993.
 156. Helveston EM: Cyclic strabismus. *Am Orthopt J* 23:48, 1973.
 157. Helveston EM: Slipped inferior rectus muscle after adjustable suture. In Lenk-Schäfer M, ed: *Orthoptic Horizons. Transactions of International Orthoptic Congress*, Harrogate, England, June 29–July 2, 1987, p 421.
 158. Helveston EM: Brown's syndrome: Anatomic considerations and pathophysiology. *Am Orthopt J* 43:31, 1993.
 159. Helveston EM: Personal communication, 1994.
 160. Helveston EM: The influence of superior oblique anatomy on function and treatment (Bielschowsky Lecture). *Binocular Vision Strabismus Q* 14:15, 1999.
 161. Helveston EM, Meriam WW, Ellis FD, et al: The trochlea: A study of the anatomy and physiology. *Ophthalmology* 89:124, 1982.
 162. Hervouet F, Chevannes H: Syndrome acquis de la gaine du grand oblique. *Bull Soc Ophtalmol Fr* 63:301, 1963.
 163. Herzau V, Ioannakis K: Zur Pathogenese der Eso- und Hypotropie bei hoher Myopie. *Klin Monatsbl Augenheilkd* 208:33, 1996.
 164. Herzau V, Korner F, Kommerell G, Friedel B: Superior oblique myokymia: A clinical and electromyographical study. In Kommerell G, ed: *Disorders of Ocular Motility*:

- Neuro-physiological and Clinical Aspects. Munich, JF Bergmann, 1978, p 81.
165. Heuck G: Über angeborenen vererbten Beweglichkeitsdefect der Augen. *Klin Monatsbl Augenheilkd* 17:253, 1879.
 166. Holzman AE, Chrousos GA, Kozma C, Traboulsi EI: Duane's retraction syndrome in the fetal alcohol syndrome (letter). *Am J Ophthalmol* 110:565, 1990.
 167. Hotchkiss MG, Miller NR, Clark AW, Green WM: Bilateral Duane's retraction syndrome. A clinical-pathologic case report. *Arch Ophthalmol* 98:870, 1980.
 168. Hoyt WF, Keane JR: Superior oblique myokymia. Report and discussion on five cases of benign intermittent uniocular microtremor. *Arch Ophthalmol* 84:461, 1970.
 169. Hoyt WF, Nachtigäller H: Anomalies of ocular motor nerves: Neuroanatomic correlates of paradoxical innervation in Duane's syndrome and related congenital ocular motor disorder. *Am J Ophthalmol* 60:443, 1965.
 170. Huber A: Die peripheren Augenmuskellähmungen. *Ber Dtsch Ophthalmol Ges* 67:26, 1966.
 171. Huber A: Electrophysiology of the retraction syndrome. *Br J Ophthalmol* 58:293, 1974.
 172. Huber A, Esslen E: Diagnostic des myopathies oculaires a l'aide de l'électromyographie. *Bull Soc Ophtalmol Fr* 80:460, 1967.
 173. Huber A, Esslen E, Klöti R, Martenet AC: Zum Problem des Duane Syndroms. *Graefes Arch Clin Exp Ophthalmol* 167:169, 1964.
 174. Hudson HL, Feldon SE: Late overcorrection of hypotropia in Graves' ophthalmopathy. *Ophthalmology* 99:356, 1992.
 175. Hughes DS, Beck L, Hill R, Plenty J: Dysthyroid eye disease presenting as Brown's syndrome. *Acta Ophthalmol Scand* 70:262, 1992.
 176. Hugonnier R, Magnard P: Les disequilibres oculomoteurs observes en cas de myopie forte. *Ann Ocul* 202:713, 1969.
 177. Hupp SL, Williams JP, Curran JE: Computerized tomography in the diagnosis of the congenital fibrosis syndrome. *J Clin Neuro Ophthalmol* 10:135, 1990.
 178. Hutchison KA, Lambert SR: Cyclic esotropia after a traumatic sixth nerve palsy in a child. *J Am Assoc Pediatr Ophthalmol Strabismus* 2:376, 1998.
 179. Isenberg S, Urist MJ: Clinical observations in 101 consecutive patients with Duane's retraction syndrome. *Am J Ophthalmol* 84:419, 1977.
 180. Jackson OB, Nankin SJ, Scott WE: Traumatic simulated Brown's syndrome: A case report. *J Pediatr Ophthalmol Strabismus* 16:160, 1982.
 181. Jacobi KW: Tenektomie des Obliquus superior bei Sehenscheiden-syndrome (Brown). *Klin Monatsbl Augenheilkd* 160:669, 1972.
 182. Jaensch PA: Paresen der schrägen Heber. *Graefes Arch Ophthalmol* 121:113, 1928.
 183. Jaensch PA: Fusionsstörungen nach Gehirnerschütterung. *Klin Monatsbl Augenheilkd* 94:470, 1935.
 184. Jampolsky A: Surgical leashes and reverse leashes in strabismus surgical management. *Transactions of the New Orleans Academy of Ophthalmology. Symposium on Strabismus. St Louis, Mosby-Year Book*, 1978, p 252.
 185. Jampolsky A, Eisenbaum AM, Parks MM: A study of various surgical approaches to the leash effect in Duane's syndrome. Presented at the American Academy of Ophthalmology, Chicago, Nov 2-7, 1980.
 186. Jay WM, Hoyt CS: Abnormal brain stem auditory-evoked potentials in Stilling-Türk-Duane retraction syndrome. *Am J Ophthalmol* 89:814, 1980.
 187. Johnson LV: Adherence syndrome: Pseudoparalysis of the lateral or superior rectus muscle. *Arch Ophthalmol* 44:870, 1950.
 188. Kaban TJ, Smith K, Orton RB, et al: Natural history of presumed congenital Brown's syndrome. *Arch Ophthalmol* 111:943, 1993.
 189. Kalpakian B, Bateman JB, Sparkes RS, Wood GK: Congenital ocular fibrosis syndrome associated with the Prader-Willi syndrome. *J Pediatr Ophthalmol Strabismus* 23:170, 1986.
 190. Komai K, Mimura O, Uyama J, et al: Neuroophthalmological evaluation of superior oblique myokymia. *J Clin Neuroophthalmol* 12:135, 1992.
 191. Katz NN, Whitmore PV, Beauchamp GR: Brown's syndrome in twins. *J Pediatr Ophthalmol Strabismus* 18:32, 1981.
 192. Kaufmann H, Milkowitz K: Ergebnisse der operativen Behandlung des Retraktionssyndroms von Stilling-Türk-Duane. *Klin Monatsbl Augenheilkd* 204:90, 1994.
 193. Kaufmann H, Kolling G, Hartwig H: Das Retraktionssyndrom von Stilling-Türk-Duane. *Klin Monatsbl Augenheilkd* 178:110, 1981.
 194. Keltner J: The monocular shimmers—your patient isn't deluded. With comments by Miller NM, Gittinger J, Burde R. *Surv Ophthalmol* 27:313, 1983.
 195. Khodadoust AA, Noorden GK von: Bilateral vertical retraction syndrome. *Arch Ophthalmol* 78:606, 1967.
 196. Killian PJ, McClain B, Lawless OJ: Brown's syndrome. An unusual manifestation of rheumatoid arthritis. *Arthritis Rheum* 20:1080, 1977.
 197. Kiloh LG, Nevin S: Progressive dystrophy of the external ocular muscles (ocular myopathy). *Brain* 74:115, 1951.
 198. Kirkham TH: Duane's syndrome and familial perceptive deafness. *Br J Ophthalmol* 53:335, 1969.
 199. Kirkham TH: Anisometropia and amblyopia in Duane's syndrome. *Am J Ophthalmol* 69:774, 1970.
 200. Klein D, Franceschetti A: In Becker PE, ed: *Missbildungen und Krankheiten des Auges, vol 4: Humangenetik*. Stuttgart, Georg Thieme Verlag, 1964, p 50.
 201. Knapp P: Classification and treatment of superior oblique palsy. *Am Orthopt J* 24:18, 1974.
 202. Kommerell G, Schaubele G: Superior oblique myokymia: An electromyographical analysis. *Trans Ophthalmol Soc U K* 100:504, 1980.
 203. Koornneef L, Schmidt ED, Gaag R van der: The orbit: Structure, autoantigens, and pathology. In Wall JR, How J, eds: *Graves' Ophthalmopathy*. Boston, Blackwell Scientific, 1990, p 11.
 204. Kosmorsky GS, Ellis B, Fogt N, Leigh RJ: The treatment of superior oblique myokymia utilizing the Harada-Ito procedure. *J Clin Neuro Ophthalmol* 15:142, 1995.
 205. Kowal L, Troski M, Gilford E: MRI in the heavy eye phenomenon. *Aust N Z J Ophthalmol* 22:125, 1994.
 206. Kraft SP: A surgical approach for Duane's syndrome. *J Pediatr Ophthalmol Strabismus* 25:119, 1988.
 207. Kroll AJ, Kuwabara T: Dysthyroid ocular myopathy. Anatomy, histology, and electron microscopy. *Arch Ophthalmol* 76:244, 1966.
 208. Krüger KE: Beitrag zur Ätiologie des Stilling-Türk-Duane syndroms. *Acta Ophthalmol Scand* 47:415, 1969.
 209. Krzizok T, Schroeder BU: Measurement of recti eye muscle paths by magnetic resonance imaging in highly myopic and normal subjects. *Invest Ophthalmol Vis Sci* 4:2554, 1999.
 210. Krzizok T, Kaufmann H, Traupe H: Kernspintomographische Diagnostik der Motilitätsstörungen bei hoher Myopie zur Planung der Augenmuskeloperationen. *Ophthalmologie* 94:907, 1997.
 211. Krzizok T, Kaufmann H, Traupe H: Elucidation of restrictive motility in high myopia by magnetic resonance imaging. *Arch Ophthalmol* 115:1019, 1997.
 212. Krzizok T, Kaufmann H, Traupe H: New approach to strabismus surgery in high myopia. *Br J Ophthalmol* 81:625, 1997.

213. Labrecque R, Boghen D: Syndrome de Brown's acquis et intermittent. *Can Med Assoc J* 117:498, 1977.
214. Laby DM, Rosenbaum AL: Adjustable vertical rectus muscle transposition surgery. *J Pediatr Ophthalmol Strabismus* 31:75, 1994.
215. Lang W: Traumatic enophthalmos with retention of perfect acuity of vision. *Trans Ophthalmol Soc* 9:41, 1889.
216. Lanthony P: Le syndrome de l'oeil lourd. *Bull Mem Soc Fr Ophtalmol* 96:26, 1985.
217. Lee JP: Superior oblique myokymia. A possible etiologic factor. *Arch Ophthalmol* 102:1178, 1984.
218. Leigh RJ, Tomsak RL, Seidman DSH, Dell'Osso LF: Superior oblique myokymia. Quantitative characteristics of the eye movement in three patients. *Arch Ophthalmol* 109:1710, 1991.
219. Leone CR, Leone RT: Spontaneous cure of congenital Brown's syndrome. *Am J Ophthalmol* 102:542, 1986.
220. Lingua RW, Walonker F: Use of the posterior fixation suture in type 1 Duane's syndrome. *J Ocul Ther Surg* 4:107, 1985.
221. Lowe RF: Bilateral superior oblique tendon sheath syndrome. Occurrence and spontaneous recovery in one of uniocular twins. *Br J Ophthalmol* 53:466, 1969.
222. Lyle TK: Surgical management of congenital musculo-facial anomalies. In *Strabismus '69*. Transactions of the Concilium Europaeum Strabismi Congress, 1970.
223. Lyle TK, Bridgeman GJO: Worth and Chavasse's Squint. *The Binocular Reflexes and the Treatment of Strabismus*, ed 9. London, Baillière, Tindall & Cox, 1959, pp 251-255.
224. MacLellan AV: A case of recovery from traumatic loss of fusion. *Br Orthopt J* 31:102, 1974.
225. Magora A, Chaco J, Zauberman H: An electromyographic investigation of ophthalmoplegia in thyrotoxicosis. *Arch Ophthalmol* 79:170, 1968.
226. Malbran J: Estrabismos y Paralysis. *Clinica y Terapeutica*. Buenos Aires, Editorial Oftalmologia, 1949, p 627.
227. Mannor GE, Ros GE, Mosely IF, Wright JE: Outcome of orbital myositis. Clinical features associated with recurrence. *Ophthalmology* 104:409, 1997.
228. Mansour AM, Wang F, El-Baba F, Henkind P: Ocular complications in strabismus fixus convergens. *Ophthalmologica* 195:161, 1987.
229. Marchesani O: Basedowartige Symptome am Auge. *Graefes Arch Clin Exp Ophthalmol* 152:553, 1952.
230. Martinez L: A case of fixed strabismus. *Am J Ophthalmol* 31:80, 1948.
231. Maruo T, Kusota N, Arimoto H, Kikuchi R: Duane's syndrome. *Jpn J Ophthalmol* 23:453, 1979.
232. Matteucci P: I difetti congeniti di abduzione (congenital abduction deficiency) con particolare riguardo alla patogenesi. *Rassegna Ital Ottalmol* 15:345, 1946.
233. Mayou MS: Presidential address and discussion of squint. *Trans Ophthalmol Soc U K* 54:3, 1934.
234. McLean CJ, Lee JP: Acquired central fusion disruption with spontaneous recovery. *Strabismus* 6:175, 1998.
235. Mehdorn E, Kommerell G: Inherited Duane's syndrome: Mirror-like localization of oculomotor disturbance in monozygotic twins. *J Pediatr Ophthalmol Strabismus* 16:152, 1979.
236. Mehel E, Quéré MA, Lavenant F, Pechereau A: Aspects épidémiologiques et cliniques de syndrome de Stilling-Türk-Duane. *J Fr Ophtalmol* 19:533, 1996.
237. Mehta AM, Demer JL: Magnetic resonance imaging of the superior oblique muscle in superior oblique myokymia. *J Pediatr Ophthalmol Strabismus* 31:378, 1994.
238. Metz HS: Saccadic velocity measurements in patients with Brown's syndrome. *Ann Ophthalmol* 11:636, 1979.
239. Metz HS: Change in the cycle of circadian strabismus. *Am J Ophthalmol* 120:124, 1995.
240. Miller BA, Pollard ZF: Duane's retraction syndrome and arthrogryposis multiplex congenita. *Surv Ophthalmol* 38:395, 1994.
241. Miller JE, Van Heuven W, Ward R: Surgical correction of hypotropias associated with thyroid dysfunction. *Arch Ophthalmol* 74:509, 1965.
242. Miller JM, Demer JL, Rosenbaum AL: Two mechanisms of up-shoots and down-shoots in Duane's syndrome revealed by a new magnetic resonance imaging technique. In Campos EC, ed: *Strabismus and Ocular Motility Disorders*. Proceedings of the Sixth Meeting of the International Strabismological Association, 1990. New York, Macmillan, 1991, p 229.
243. Miller M: Thalidomide embryopathy: A model for the study of congenital incomitant horizontal strabismus. *Trans Am Ophthalmol Soc* 89:6323, 1991.
244. Miller M, Strömland K: Ocular motility in thalidomide embryopathy. *J Pediatr Ophthalmol Strabismus* 28:47, 1991.
245. Miller NR, Kiel SM, Green W, Clark AW: Unilateral Duane's retraction syndrome (type 1). *Arch Ophthalmol* 100:1468, 1982.
246. Molarte AB, Rosenbaum AL: Vertical rectus muscle transposition surgery for Duane's syndrome. *J Pediatr Ophthalmol Strabismus* 27:171, 1990.
247. Molinari A: Krokodilstränen und Retraktionssyndrom. *Klin Monatsbl Augenheilkd* 208:56, 1996.
248. Mombaerts I, Koornneef L: Current status in the treatment of orbital myositis. *Ophthalmology* 104:402, 1997.
249. Moore AT, Walker J, Taylor D: Familial Brown's syndrome. *J Pediatr Ophthalmol Strabismus* 25:202, 1988.
250. Moore LD, Feldon SE, Liu SK: Infrared oculography of Duane's retraction syndrome (type 1). *Arch Ophthalmol* 106:943, 1988.
251. Morrow MJ, Sharpe JA, Ranalli PJ: Superior oblique myokymia associated with a posterior fossa tumor: Oculographic correlation with an idiopathic case. *Neurology* 40:367, 1990.
252. Moster ML, Bosley TM, Slavin ML, Rubin SE: Thyroid ophthalmopathy presenting as superior oblique paresis. *J Clin Neuro Ophthalmol* 12:94, 1992.
253. Mottow-Lippa L, Jacobiec FA, Smith M: Idiopathic inflammatory orbital pseudotumor in childhood. II. Results of diagnostic tests and biopsies. *Ophthalmology* 88:565, 1981.
254. Muchnik RS, Sanfilippo S, Dunlap EA: Cyclic esotropia developing after strabismus surgery. *Arch Ophthalmol* 94:459, 1976.
255. Mühlendyck H: Jaensch-Brown-Syndrom. Ursache und operatives Vorgehen. *Klin Monatsbl Augenheilkd* 208:37, 1996.
256. Mühlendyck H, Braun M: Phenomena of oculocardiac reflex during strabismus surgery. In Kaufmann H, ed: *Transactions of the 20th Meeting of the European Strabismological Association*. Brussels, Gahmig Press, 1992, p 43.
257. Mulhern M, Keohane C, O'Connor G: Bilateral abducens nerve lesions in unilateral type 3 Duane's retraction syndrome. *Br J Ophthalmol* 78:588, 1994.
258. Nawratzki I: A typical retraction syndrome: A case report. *J Pediatr Ophthalmol* 4:32, 1967.
259. Nicholson DH, Guzak SV: Visual loss complicating repair of orbital floor fractures. *Arch Ophthalmol* 86:369, 1971.
260. Noorden GK von: Congenital hereditary ptosis with inferior rectus fibrosis. *Arch Ophthalmol* 83:378, 1970.
261. Noorden GK von: Unpublished observation, 1972.
262. Noorden GK von: *Atlas of Strabismus*, ed 4. St Louis, Mosby-Year Book, 1983, p 166.
263. Noorden GK von: Recession of both horizontal recti

- muscles in Duane's retraction syndrome with elevation and depression of the adducted eye. *Am J Ophthalmol* 114:311, 1992.
264. Noorden GK von, Murray E: Up- and downshoot in Duane's retraction syndrome. *J Pediatr Ophthalmol Strabismus* 23:212, 1986.
 265. Noorden GK von, Oliver P: Superior oblique tenectomy in Brown's syndrome. *Ophthalmology* 89:303, 1982.
 266. Ohtsuki H, Hasebe S, Okano M, Furuse T: Strabismus surgery in ocular myasthenia gravis. *Ophthalmologica* 210:95, 1996.
 267. O'Malley ER, Helveston EM, Ellis FD: Duane's retraction syndrome plus. *J Pediatr Ophthalmol Strabismus* 19:161, 1982.
 268. Orton HP, Burke JP: Sensory adaptations in Duane's retraction syndrome. *Acta Ophthalmol Scand* 73:417, 1995.
 269. Osher R, Schatz NJ, Duane TD: Acquired orbital retraction syndrome. *Arch Ophthalmol* 98:1798, 1980.
 270. Otradovec J: Ein beiderseitiges Duane-Syndrom bei einem Hirnstamm-tumor. *Klin Monatsbl Augenheilkd* 153:686, 1968.
 271. Özkan SB, Kir E: Synergistic divergence in association with congenital extraocular muscle fibrosis. In Lennerstrand G, ed: *Advances in Strabismology. Proceedings of the Eighth Meeting of the International Strabismological Association, Maastricht, The Netherlands, Sept 10-12, 1998*. Buren, The Netherlands, Aeolus Press, 1999, p 150.
 272. Özkan SB, Kir E, Söylev MF, et al: The evaluation of chronic progressive external ophthalmoplegia with computerized tomography. In Lennerstrand G, ed: *Advances in Strabismology. Proceedings of the Eighth Meeting of the International Strabismological Association, Maastricht, The Netherlands, Sept 10-12, 1998*. Buren, The Netherlands, Aeolus Press, 1999, p 154.
 273. Palmer EA, Shults WT: Superior oblique myokymia: Preliminary results of surgical treatment. *J Pediatr Ophthalmol Strabismus* 21:96, 1984.
 274. Palmieri L, Anselmi P: Sulla sindrome della guaina tendinea del grande obliquo. *Riv Otoneurooftalmol* 37:295, 1962.
 275. Papst W: Paralytischer Strabismus infolge paradoxer Innervation. *Ber Dtsch Ophthalmol Ges* 67:84, 1966.
 276. Papst W, Esslen E: Zur Ätiologie der angeborenen Abduzenslähmung. *Klin Monatsbl Augenheilkd* 137:306, 1960.
 277. Papst W, Esslen E: Über die oculare Myasthenie. *Klin Monatsbl Augenheilkd* 139:345, 1961.
 278. Papst W, Stein HJ: Zur Ätiologie des Musculus-obliquus-superior-Sehnenscheiden-Syndroms. *Klin Monatsbl Augenheilkd* 154:506, 1969.
 279. Papst W, Stein HJ: Zur chirurgischen Behandlung der paradoxen Innervation. *Ber Dtsch Ophthalmol Ges* 70:345, 1970.
 280. Parker, cited in Sinclair WW: Abnormal associated movements of the eyelids. *Ophthalmol Rev* 14:307, 1895.
 281. Parks MM: The weakening surgical procedures for eliminating overaction of the inferior oblique muscle. *Am J Ophthalmol* 73:107, 1972.
 282. Parks MM: The superior oblique tendon—33rd Doyne memorial lecture. *Trans Ophthalmol Soc U K* 97:288, 1977.
 283. Parks MM: Surgery for Brown's syndrome. In *Symposium on Strabismus: Transactions of the New Orleans Academy of Ophthalmology*. St Louis, Mosby-Year Book, 1978, p 157.
 284. Parks MM, Brown M: Superior oblique tendon sheath syndrome of Brown. *Am J Ophthalmol* 79:82, 1975.
 285. Parks MM, Eustis HS: Simultaneous superior oblique tenectomy and inferior oblique recession in Brown's syndrome. *Ophthalmology* 94:1043, 1987.
 286. Parsa CF, Grant E, Dillon WP, et al: Absence of the abducens nerve in Duane syndrome verified by magnetic resonance imaging. *Am J Ophthalmol* 125:399, 1998.
 287. Patrinely JR, Osborn AG, Anderson RL, Whiting AS: Computed tomographic features of nonthyroid extraocular muscle enlargement. *Ophthalmology* 96:1038, 1989.
 288. Pesando P, Nuzzi G, Maraini G: Vertical retraction syndrome. *Ophthalmologica* 177:254, 1978.
 289. Pfaffenbach DD, Cross HH, Kearns TP: Congenital anomalies in Duane's retraction syndrome. *Arch Ophthalmol* 88:635, 1972.
 290. Pieroni D: Goldenhar's syndrome associated with bilateral Duane's retraction syndrome. *Am J Ophthalmol* 70:945, 1970.
 291. Pierro L, Zaganelli E, Tavola A, Muraglia M: Extraocular muscle size comparison between normal and myopic eyes using standardized A scale echography. *Ophthalmologica* 21 (suppl 1):22, 1998.
 292. Pillai P, Dhand UK: Cyclic esotropia with central nervous system disease: Report of two cases. *J Pediatr Ophthalmol Strabismus* 24:237, 1987.
 293. Pollard ZF, Booher EL: Masked dissociative hypertropia in Brown's syndrome. *Binocular Vision Strabismus Q* 7:89, 1992.
 294. Prakash P, Gupta NK, Menon V, Chandra M: Myopic strabismus fixus convergens. *Indian J Ophthalmol* 37:24, 1989.
 295. Prats JM, Garaizar C: Duane retraction syndrome associated with Chiari I malformation. *Pediatr Neurol* 10:340, 1994.
 296. Pressman SH, Scott W: Surgical treatment of Duane's syndrome. *Ophthalmology* 93:29, 1986.
 297. Putterman AM, Stevens T, Urist MJ: Nonsurgical management of blow-out fractures of the orbital floor. *Am J Ophthalmol* 77:232, 1974.
 298. Pratt-Johnson JA: Central disruption of fusional amplitude. *Br J Ophthalmol* 57:347, 1973.
 299. Pratt-Johnson JA: Fusion ability lost and regained in visual adults. *Graefes Arch Clin Exp Ophthalmol* 226:111, 1988.
 300. Pratt-Johnson JA, Tillson G: Acquired central disruption of fusional amplitude. *Ophthalmology* 86:2140, 1979.
 301. Pratt-Johnson JA, Tillson G: Intractable diplopia after vision restoration in unilateral cataract. *Am J Ophthalmol* 107:23, 1989.
 302. Raab EL: Clinical features of Duane's syndrome. *J Pediatr Ophthalmol Strabismus* 23:64, 1986.
 303. Rafo GT: Blow-in and blow-out fractures of the orbit: Clinical correlations and proposed mechanisms. *Ophthalmol Surg* 15:114, 1984.
 304. Ramsay J, Taylor D: Congenital crocodile tears: A key to the aetiology of Duane's syndrome. *Br J Ophthalmol* 64:518, 1980.
 305. Reck AC, Manners R, Hatchwell E: Phenotypic heterogeneity may occur in congenital fibrosis of the extraocular muscles. *Br J Ophthalmol* 82:676, 1998.
 306. Remón L, Palomar T, Gabas M, Dominguez M: Acquired convergent fixus associated with high myopia: A case report. *Binocular Vision Strabismus Q* 11:41, 1996.
 307. Richter C: Clock-mechanism esotropia in children. *Alternate day squint*. *Johns Hopkins Med J* 122:218, 1968.
 308. Riordan EP, Vickers SF, McCarty B, Lee JP: Cyclic strabismus without binocular function. *J Pediatr Ophthalmol Strabismus* 30:106, 1993.
 309. Ro A, Chernoff G, MacRae D, et al: Auditory function in Duane's retraction syndrome. *Am J Ophthalmol* 109:75, 1990.
 310. Ro A, Gummeson B, Orton RB, Cadera W: Duane's

- retraction syndrome: Southwestern Ontario experience. *Can J Ophthalmol* 24:200, 1989.
311. Rogers GK, Bremer DL: Surgical treatment of the upshoot and downshoot in Duane's retraction syndrome. *Ophthalmology* 91:1380, 1984.
 312. Roper Hall G, Burde RM: Superior oblique myokymia. *Am Orthopt J* 28:58, 1978.
 313. Roper Hall MJ: The superior oblique click syndrome. In *Orthoptics. Proceedings of the Second International Orthoptic Congress*. Amsterdam, 1972, Excerpta Medica.
 314. Roper Hall MJ, Yapp JMS: Alternate day squint. In *First International Congress of Orthoptists*. St Louis, Mosby-Year Book, 1968, p 262.
 315. Rosenblum AL, Weiss SJ: Monozygotic twins discordant for Duane's retraction syndrome. *J Pediatr Ophthalmol Strabismus* 15:359, 1978.
 316. Ruttum MS, Harris GJ: Superior oblique myectomy and trochlectomy in recurrent superior oblique myokymia. *Graefes Arch Clin Exp Ophthalmol* 226:145, 1988.
 317. Ruttum MS, Lloyd MA, Lewandowski MF: Echography in the diagnosis of restrictive motility caused by severe myopia. *Am J Ophthalmol* 109:350, 1990.
 318. Saad N, Lee JL: Medial rectus electromyographic abnormalities in Duane syndrome. *J Pediatr Ophthalmol* 30:88, 1993.
 319. Saad N, Freeman B, Lee J: The pathogenesis of Duane's syndrome. *Strabismus* 2:137, 1994.
 320. Sachsenweger R: *Augenmuskellähmungen. Ein Handbuch für Ophthalmologen, Neurologen und Internisten*. Leipzig, VEB Georg Thieme, 1966.
 321. Samii M, Rosahl SK, Carvalho GA, Krzizok T: Microvascular decompression for superior oblique myokymia: First experience. Case report. *J Neurosurg* 89:1020, 1998.
 322. Sandford-Smith JH: Intermittent superior oblique tendon sheath syndrome: A case report. *Br J Ophthalmol* 53:412, 1969.
 323. Sandford-Smith JH: Superior oblique tendon sheath syndrome and its relationship to stenosing tenosynovitis. *Br J Ophthalmol* 59:385, 1975.
 324. Santiago AP, Rosenbaum AL: Grave complications after superior oblique tenotomy or tenectomy for Brown syndrome. *J Am Assoc Pediatr Ophthalmol Strabismus* 1:8, 1997.
 325. Sato S: Electromyographic studies on Duane's retraction syndrome. Report I. Qualitative changes of action currents of extraocular muscles in ocular movements. *Acta Soc Ophthalmol Jpn* 63:2028, 1959.
 326. Saunders RA, Stratas BA, Gordon RA, Holgate RC: Acute-onset Brown's syndrome associated with pansinusitis. *Arch Ophthalmol* 108:58, 1990.
 327. Saunders RA, Wilson ME, Bluestein EC, Sinatra RB: Surgery on the normal eye in Duane retraction syndrome. *J Pediatr Ophthalmol Strabismus* 31:162, 1994.
 328. Scassellati-Sforzolini G: Una sindrome molto rara: Difetto congenito monolaterale della elevazione con retrazione del globo. *Riv Otoneurooftalmol* 33:431, 1958.
 329. Schmidt D, Mattheus S: Zyklisches Einwärtsschielen (alternate day squint). *Klin Monatsbl Augenheilkd* 167:835, 1975.
 330. Schmidt D, Reuscher A, Kommerell G: Über das nasale Gesichtsfeld bei Strabismus fixus divergens. *Graefes Arch Clin Exp Ophthalmol* 183:97, 1971.
 331. Schultz RO, Van Allen MW, Blodi FC: Endocrine ophthalmoplegia with an electromyographic study of paretic extraocular muscles. *Arch Ophthalmol* 63:217, 1960.
 332. Scott AB: Upshoot and downshoot. In Souza-Dias C, ed: *Smith-Kettlewell Symposium on Basic Sciences in Strabismus*, Guarujá, Brazil, Oct 16–17, 1976.
 333. Scott AB, Wong GY: Duane's syndrome: An electromyographic study. *Arch Ophthalmol* 87:140, 1972.
 334. Sevel D: Brown's syndrome. A possible etiology explained embryologically. *Ophthalmology* 18:26, 1981.
 335. Sevel D: The origins and insertions of the extraocular muscles: Development, histologic features and clinical significance. *Trans Am Ophthalmol Soc* 84:488, 1986.
 336. Sharma P, Gupta NK, Arora R, Prakash P: Strabismus fixus convergens secondary to amyloidosis. *J Pediatr Ophthalmol Strabismus* 28:236, 1991.
 337. Sharma DC, Parihar PS, Kumawat DC, et al: Duane's retraction syndrome with facial hemiatrophy (a case report). *Postgrad Med* 36:51, 1990.
 338. Simonsz HJ, Kommerell G: Increased muscle tension and reduced elasticity of affected muscles in recent-onset Graves' disease caused primarily by active muscle contraction. *Doc Ophthalmol* 72:215, 1989.
 339. Simonsz HJ, Harting F, de Waal BJ, Verbeeten BWJM: Sideways displacement and curved path of recti eye muscles. *Arch Ophthalmol* 103:124, 1985.
 340. Simpson JA: Myasthenia gravis as an autoimmune disease: Clinical aspects. *Ann N Y Acad Sci* 135:506, 1966.
 341. Sims J: Acquired apparent superior oblique tendon sheath syndrome. *Br Orthopt J* 28:112, 1971.
 342. Sinclair WW: Abnormal associated movements of the eyelids. *Ophthalmol Rev* 14:307, 1895.
 343. Slavin ML, Glaser JS: Idiopathic orbital myositis: A report of six cases. *Arch Ophthalmol* 100:1261, 1982.
 344. Smit TJ, Koornneef L, Zonneveld FW: A total orbital floor fracture with prolapse of the globe into the maxillary sinus manifesting as postenucleation socket syndrome (letter). *Am J Ophthalmol* 110:569, 1990.
 345. Smith B, Regan WF: Blowout fracture of the orbit: Mechanism and correction of internal orbital fracture. *Am J Ophthalmol* 44:733, 1957.
 346. Souza-Dias C: Additional consequences of muscle co-contraction in Duane's syndrome. In Souza-Dias C, ed: *Smith-Kettlewell Symposium on Basic Sciences in Strabismus*, Guarujá, Brazil, Oct 16–17, 1976.
 347. Spaeth EB: Surgical aspects of defection abduction. *Arch Ophthalmol* 49:49, 1953.
 348. Spielmann A: Bilateral vertical retraction syndrome in horizontal Duane's syndrome. *Graefes Arch Clin Exp Ophthalmol* 226:425, 1988.
 349. Spielmann A: *Les strabismes: De l'analyse clinique à la synthèse chirurgicale*, ed 2. Paris, Masson, 1991, p 164.
 350. Spielmann A, Lagrange B, Laurent M: Le syndrome de retraction de Stilling Duane. Etiopathogénie clinique. Régulation motrice par la Faden-operation de Cüppers sur l'oeil sain, associé ou non à la chirurgie de l'oeil atteint. *J Fr Ophtalmol* 8:105, 1976.
 351. Spierer A, Eisenstein Z: The role of increased intraocular pressure on upgaze in the assessment of Graves' ophthalmopathy. *Ophthalmology* 98:1491, 1991.
 352. Sprunger D: Recession of both horizontal rectus muscles in Duane syndrome with globe retraction in primary position. *J Am Assoc Pediatr Ophthalmol Strabismus* 1:31, 1997.
 353. Sprunger DT, Noorden GK von, Helveston EM: Surgical results in Brown syndrome. *J Pediatr Ophthalmol Strabismus* 28:164, 1991.
 354. Stager DR, Parks MM, Stager DR Jr, Pesheva M: Long-term results of silicone expander for moderate and severe Brown syndrome (Brown syndrome "plus"). *J Am Assoc Pediatr Ophthalmol Strabismus* 3:328, 1999.
 355. Stanworth A: Ocular myopathies. *Trans Ophthalmol Soc U K* 83:515, 1963.
 356. Stärk N, Walther C: Cyclische Esotropie bei einem Erwachsenen. *Klin Monatsbl Augenheilkd* 184:553, 1984.
 357. Stark W, Fries U: Die Tenektomie des Musculus obliquus superior zur Behandlung von A-Inkomitanzen und des Brown-Syndroms. *Klin Monatsbl Augenheilkd* 199:337, 1991.

358. Starr MA: Myasthenia gravis. *J Nerv Ment Dis* 39:721, 1962.
359. Staudenmaier C: Superior oblique myokymia: When treatment is necessary. *Can J Ophthalmol* 21:236, 1986.
360. Staudenmaier C, Buncic JR: Periodic alternating gaze deviation with dissociating secondary face turn. *Arch Ophthalmol* 101:202, 1983.
361. Stein R: Posttraumatische intermittierende Pseudoparese des Musculus obliquus inferior. Bemerkungen zum Sehenscheiden-syndrom des Musculus obliquus superior. *Klin Monatsbl Augenheilkd* 47:712, 1965.
362. Stidham DB, Sondhi N, Plager D, Helveston EM: Presumed isolated inflammation of the superior oblique muscle in idiopathic orbital myositis. *Ophthalmology* 105:2216, 1998.
363. Stilling J: Untersuchungen über die Entstehung der Kurzsichtigkeit. Wiesbaden, JF Bergmann, 1887, p 13.
364. Strachan IM, Brown BH: Electromyography of extraocular muscles in Duane's syndrome. *Br J Ophthalmol* 56:594, 1972.
365. Sugawara M, Awaya A, Majima A, et al: General fibrosis syndrome. *Acta Soc Ophthalmol Jpn* 86:657, 1982.
366. Susac JO, Smith JL, Schatz NJ: Superior oblique myokymia. *Arch Neurol* 29:432, 1973.
367. Tarkkanen A, Tommila V: Progressive muscular dystrophy involving the extraocular muscles, with notes concerning operative treatment of the associated divergent squint. *Br J Ophthalmol* 49:102, 1965.
368. Taylor R, Whale K, Raines M: The heavy eye phenomenon: Orthoptic and ophthalmic characteristics. *German J Ophthalmol* 4:252, 1995.
369. Teasdall RD, Sears M: Myasthenia gravis: Electromyographic evidence for myopathy. *Am J Ophthalmol* 54:541, 1962.
370. Thorson JC, Bell WE: Progressive dystrophic external ophthalmoplegia with abiotropic fundus changes. *Arch Ophthalmol* 62:833, 1959.
371. Tien RD, Duberg A, Chu PK, et al: Superior oblique tendon sheath syndrome (Brown syndrome): MR findings (case report). *AJNR Am J Neuroradiol* 11:1210, 1990.
372. Tillack TW, Winer JA: Anomaly of the abducens nerve. *Yale J Biol Med* 34:620, 1962.
373. Tredici TD, Noorden GK von: Are anisometropia and amblyopia common in Duane's syndrome? *J Pediatr Ophthalmol Strabismus* 22:23, 1985.
374. Trimble RB: Loss of accommodation and convergence. *Proc R Soc Med* 70:261, 1977.
375. Trokel SL, Hilal SK: Recognition and differential diagnosis of enlarged extraocular muscles in computed tomography. *Am J Ophthalmol* 87:503, 1979.
376. Troost BT, Abel L, Noreika J, Genovese FM: Acquired cyclic esotropia in an adult. *Am J Ophthalmol* 91:8, 1981.
377. Türk S: Bemerkungen zu einem Falle von Retraction des Auges. *Centralbl Pract Augenheilkd* 23:14, 1899.
378. Tyler TD, Ruiz RS: Propranolol in the treatment of superior oblique myokymia (case report). *Arch Ophthalmol* 108:175, 1990.
379. Uemura Y, Tomita M, Tanaka Y: Consecutive cyclic esotropia. *J Pediatr Ophthalmol* 14:278, 1977.
380. Urist MJ: Discussion of paper by Folk E: Superior oblique tendon sheath syndrome. *Arch Ophthalmol* 57:39, 1957.
381. Van Eeckhoutte L, De Clippeleir L, Apers R, et al: A protocol for extraocular muscle surgery after orbital floor fracture ("blow-out"). *Binocular Vision Strabismus Q* 13:29, 1998.
382. Velez G: Duane's retraction syndrome associated with Goldenhar's syndrome. *Am J Ophthalmol* 70:945, 1970.
383. Villasecca A: Strabismus fixus. *Am J Ophthalmol* 48:51, 1959.
384. Vincent C, Kalatzis V, Compain S, et al: A proposed new contiguous gene syndrome on 8q consists of branchio-oto-renal (BOR) syndrome, Duane syndrome, a dominant form of hydrocephalus and trapeze aplasia: Implications for the mapping of the BOR gene. *Hum Mol Genet* 3:1859, 1994.
385. Waardenburg PJ: Angeborene Bewegungsstörungen und über den diagnostischen Wert des Hess'schen Methode. *Klin Monatsbl Augenheilkd* 66:535, 1921.
386. Wade SL: Loss of fusion following brain damage. *Br Orthopt J* 22:81, 1965.
387. Wall JR, How J, eds: Graves' Ophthalmopathy. Boston, Blackwell Scientific, 1990.
388. Wall JR, Bernard N, Boucher A, et al: Pathogenesis of thyroid-associated ophthalmopathy: An autoimmune disorder of the eye muscle associated with Graves' hyperthyroidism and Hashimoto's thyroiditis. *Clin Immunol Immunopathol* 68:1, 1993.
389. Wallace DK, Sprunger DT, Helveston EM, Ellis FD: Surgical management of strabismus associated with chronic progressive external ophthalmoplegia. *Ophthalmology* 104:695, 1997.
390. Walsh FB, Hoyt WF: *Clinical Neuroophthalmology*, ed 3, vol 2. Baltimore, Williams & Wilkins, 1969.
391. Wang FM, Wertebaker C, Behrens MM, Jacobs JC: Acquired Brown's syndrome in children with juvenile rheumatoid arthritis. *Ophthalmology* 91:23, 1984.
392. Ware CFW: Duane's uniocular micro-tremor or superior oblique myokymia of Hoyt and Keane. *Doc Ophthalmol* 44:173, 1977.
393. Weinacht S, Huber A, Gottlob I: Vertical Duane's retraction syndrome. *Am J Ophthalmol* 122:447, 1996.
394. Weinberg DA, Lessner RL, Vollmer T: Ocular myasthenia: A protean disorder. *Surv Ophthalmol* 39:169, 1994.
395. Weinstein GS, Dresner SC, Slamovitz TL, Kennerdell JS: Acute and subacute orbital myositis. *Am J Ophthalmol* 96:209, 1983.
396. Whitehouse RW, Batterbury M, Jack A, Noble JL: Prediction of enophthalmos by computed tomography after "blow out" orbital fracture. *Br J Ophthalmol* 78:618, 1994.
397. Whyte DK: Blowout fractures of the orbit. *Br J Ophthalmol* 52:721, 1968.
398. Wilson ME, Eustis HS, Parks MM: Brown's syndrome. *Surv Ophthalmol* 34:153, 1989.
399. Windsor CE, Berg EF: Circadian heterotropia. *Am J Ophthalmol* 67:656, 1969.
400. Wittwer K: Zyklisches Einwärtsschielen. *Klin Monatsbl Augenheilkd* 164:824, 1974.
401. Wojno TH: The incidence of extraocular muscle and cranial nerve palsy in orbital floor blow-out fractures. *Ophthalmology* 94:682, 1987.
402. Wolf SM, Rowland LP, Schotland DL, et al: Myasthenia as an autoimmune disease: clinical aspects. *Ann N Y Acad Sci* 135:517, 1966.
403. Wolff J: The occurrence of retraction movements of the eyeball together with congenital defects in the external ocular muscles. *Arch Ophthalmol* 29:297, 1900.
404. Worth CD: *Das Schielen. Ätiologie, Pathologie und Therapie*. German edition translated by Oppenheimer EH. Berlin, Springer-Verlag, 1905, p 14.
405. Wouters RJ, van dem Bosch WA, Lemij HG: Saccadic eye movements in Graves' disease. *Invest Ophthalmol Vis Sci* 39:1544, 1998.
406. Wright KW: Superior oblique silicone expander for Brown's syndrome and superior oblique overaction. *J Pediatr Ophthalmol Strabismus* 28:101, 1991.
407. Wright KW: Brown's syndrome: Diagnosis and management. *Trans Am Ophthalmol Soc* 97:1023, 1999.
408. Wright KW, Min BM, Park C: Comparison of superior

- oblique tendon expander to superior oblique tenotomy for the management of superior oblique overaction and Brown's syndrome. *J Pediatr Ophthalmol Strabismus* 29:92, 1992.
409. Wright KW, Silverstein D, Marrone AC, Smith RE: Acquired inflammatory superior oblique tendon sheath syndrome. *Arch Ophthalmol* 100:1752, 1982.
410. Yamanouchi H, Iwasaki Y, Sugai K, Mukuno K: Duane retraction syndrome associated with Chiari I malformation. *Pediatr Neurol* 9:327, 1993.
411. Zhang F: Clinical features of 201 cases with Duane's retraction syndrome. *Clin Med J (Engl)* 110:789, 1997.
412. Zipf RF, Trokel SL: Simulated superior oblique tendon sheath syndrome following orbital floor fracture. *Am J Ophthalmol* 75:700, 1973.

Anomalies of Convergence and Divergence

In this chapter, the discussion of anomalies of convergence and divergence is based on the premise that both mechanisms are active processes. Although there has never been an argument against convergence being an active force, this does not hold true for the divergence mechanism. Scobee and Green⁴⁹ postulated, for instance, that divergence is a passive form of eye movement elicited by relaxation of convergence, a divergent position of the orbital axes, and the elasticity of orbital tissues. Costenbader,¹⁶ who reviewed the evidence for and against an active divergence mechanism, concluded that divergence is passive and that its anomalies are variances of a divergent position of rest associated with anomalies of convergence. In our view, electromyographic findings and the presence of fusional divergence prove unequivocally that an active divergence mechanism does exist.

It was established from the beginning of the study of fusional eye movements that fusion can be maintained in spite of the presentation before the eyes of prisms base-in of increasing power or image separation by a haploscopic arrangement. Under these conditions the eyes will diverge beyond parallelism of the visual axes. Moreover, patients with esophoria keep their eyes aligned and recover fusion by fusional divergence after temporary dissociation of the eyes. Clearly, under these circumstances, nothing but an active process

could produce divergent eye movements capable of maintaining or recovering fusion.

Electromyographic findings further attest to the active nature of the divergence mechanism. Early support for this concept was supplied by the work of Adler¹ and of Breinin.⁷ Breinin recorded increased activity of the lateral rectus muscle at the breakpoint of fusion in intermittent exotropia. This increase of activity occurred before the inhibition of the medial rectus muscle, just before the eye diverged, and was maintained as long as the eye remained divergent. Tamler and Jampolsky⁵³ argued that to prove unequivocally the existence of active divergence, recordings must be made simultaneously from both lateral rectus muscles during recovery from a fusion-free position or while maintaining fusion during presentation of prisms base-in before the eyes. Using this method, these investigators could demonstrate an increase of electrical activity in both lateral rectus muscles as a patient maintained fusion when prisms base-in were placed before the eyes (Fig. 22-1) and as patients with intermittent esotropia recovered fusion from a fusion-free position (Fig. 22-2). Thus the existence of active fusional divergence has been proved beyond a doubt.

The fact that the location of a divergence center has not been identified should not be interpreted as an argument against active divergence. First, divergence has been produced experimentally in

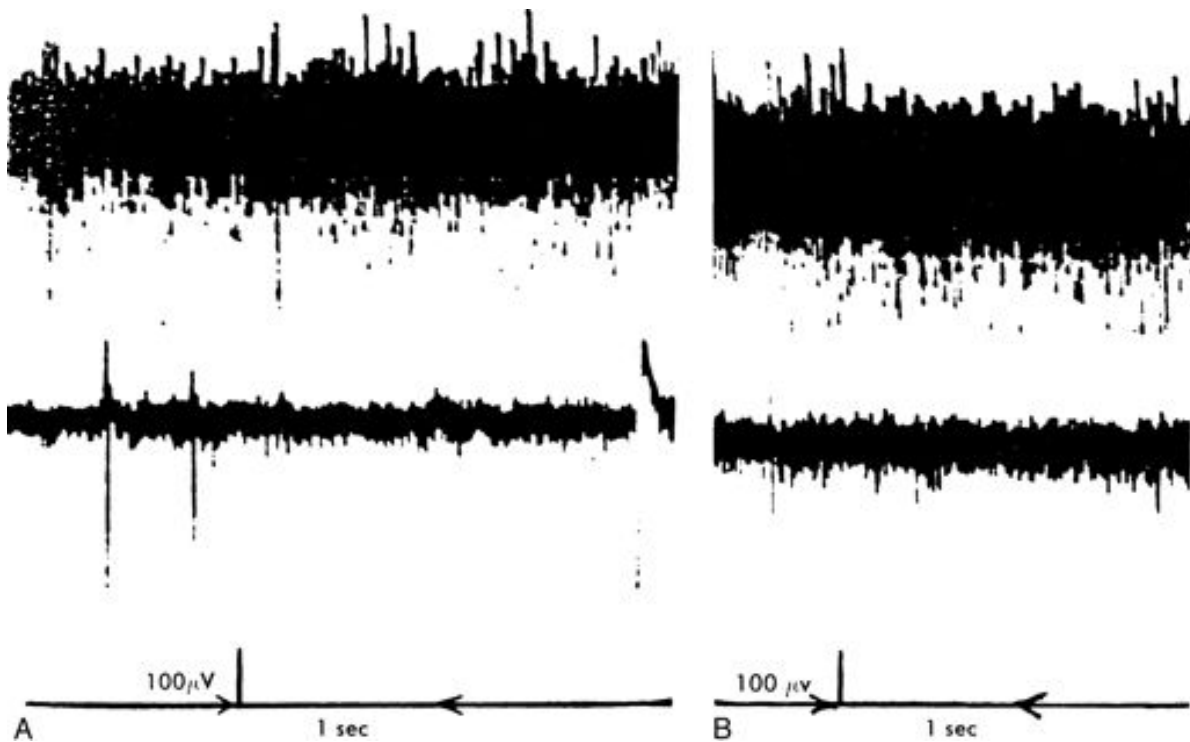


FIGURE 22-1. Active divergence elicited by prisms base-in. *A*, Electromyogram of right lateral rectus muscle (*upper tracing*) and left lateral rectus muscle (*lower tracing*) before introduction of the prism. *B*, Increased activity of both lateral rectus muscles after 18^Δ base-in was added while fusion was maintained. (From Tamler E, Jampolsky A: Is divergence active? An electromyographic study. *Am J Ophthalmol* 63:452, 1967.)

monkeys by means of electrical stimulation of the oculomotor area in the frontal lobe,^{17, 44} which suggests the existence of a supranuclear control mechanism for divergence. Second, the existence of active convergence is universally accepted, even though Warwick⁵⁷ effectively shattered the

concept of Perlia's nucleus acting as a convergence center. Thus the lack of more precise anatomical information regarding the site of a divergence center does not dispose of the physiologic and clinical data that support an active divergence mechanism.

Jampolsky,³⁰ although accepting the fact that divergence is an active mechanism, denied the existence of nonretinal tonic vergence innervations. He rejected the concept of divergence insufficiency and paralysis and accepted only the fusional form of active divergence, that is, that which is elicited by temporal disparity of retinal images. It would exceed the purpose of this chapter to analyze this hypothesis, which is discussed further in Chapter 5, except to say that, in our opinion, a tonic vergence mechanism has not been disproved by the evidence presented. Moreover, one may argue that convergence and divergence paralyzes, as well as convergence nystagmus, are well-recognized entities that cannot be explained solely on the basis of deficient fusional divergence,¹⁴ that accommodation is not necessarily defective in convergence insufficiency, and that experimentally administered ethanol^{6, 15, 45} and barbiturates⁵⁸ have been shown to affect the tonic

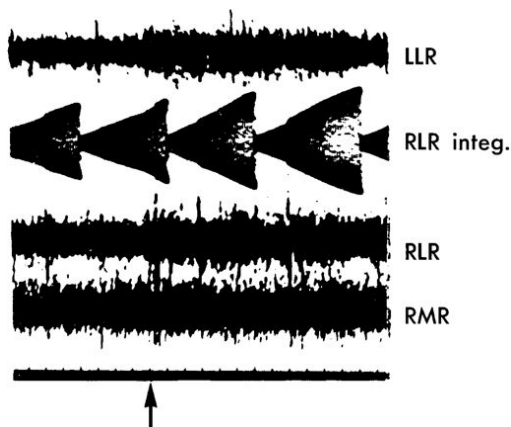


FIGURE 22-2. Electromyogram during fusional divergence movement. As the left eye of a patient with 17D intermittent esotropia is uncovered (*arrow*), there is increased activity of both left and right lateral rectus muscles (LLR, RLR) as the eye makes a fusional divergence eye movement. (From Tamler E, Jampolsky A: Is divergence active? An electromyographic study. *Am J Ophthalmol* 63:452, 1967.)

vergence mechanism. Furthermore, Scott⁵⁰ reported electromyographic findings in a patient with V exotropia that could not have been caused by anything but tonic divergence.

Anomalies of Convergence

Convergence Insufficiency

ETIOLOGY AND CLINICAL FINDINGS. Convergence insufficiency is one of the most common causes of ocular discomfort and, in fact, is the most common cause of muscular asthenopia; therefore it is of considerable clinical significance.

There is frequently an etiologic connection with associated accommodative difficulties. For instance, a convergence insufficiency as a result of disuse of the accommodative convergence mechanism may have been caused by uncorrected high hypermetropia or myopia. Patients with hypermetropia exceeding, say, 5D or 6D, make little or no effort to accommodate, and in those with myopia there is no need to accommodate to obtain clear vision at near fixation. Likewise, a patient with beginning presbyopia may develop convergence insufficiency after wearing a bifocal prescription for the first time. The relief of sustained accommodative effort afforded by the new prescription causes a decrease of accommodative convergence; thus an exophoria that had been controlled by accommodative convergence may become manifest. In other patients without refractive problems the condition may arise without any obvious cause.

Some ophthalmologists consider patients with convergence insufficiency to be neurotic and believe that their problem is something to be dealt with by a psychiatrist. We emphatically reject this generalization.¹¹ The often dramatic subjective improvement after appropriate therapy, noted concurrently with the objective clinical finding of improved near point of convergence and fusional convergence amplitudes, clearly puts this condition on an innervational basis.

In rare instances acquired convergence insufficiency may occur on an organic basis, such as secondary to a subdural hematoma.⁵²

An admirably concise description of the symptoms arising from convergence insufficiency was given by von Graefe, who pointed out as early as 1855^{26, 27} that such patients complain about eye-strain and a sensation of tension in and about the

globes. After brief periods of reading, the letters will blur and run together; crossed diplopia occasionally occurs during near work. Characteristically, one eye will be closed or covered while reading to obtain relief from visual fatigue. Little can be added to this classic description except that ocular headaches are another frequent complaint. Von Graefe thought that convergence insufficiency was myogenic, that is, caused by a congenital weakness of the medial rectus muscles secondary to overaction of the lateral rectus muscle. He recommended prisms base-out to exercise the action of the medial rectus muscles in some patients, prisms base-in to eliminate symptoms in others, or a weakening procedure of the lateral rectus muscles. Except for prisms base-out, which are still used by some, his views on the etiology of convergence insufficiency and therapeutic suggestions have not withstood the test of time.

DIAGNOSIS. The diagnosis of convergence insufficiency is based on the finding of a remote near point of convergence and decreased fusional convergence at near fixation. The reader is referred to Chapter 12 for a discussion of diagnostic methods and the clinically important differentiation between the subjective and objective near point of convergence. Most patients with convergence insufficiency exhibit varying degrees of exophoria at near fixation; however, this disorder also occurs in patients with orthophoria and occasionally even in those with esophoria. The near point of accommodation is normal and corresponds to the age of the patient. However, to identify patients who suffer from a combined insufficiency of convergence and accommodation (see p. 503) and who require a different form of therapy, the near point of accommodation should be determined in each case.⁴¹

Convergence insufficiency seldom becomes a clinical problem until a patient reaches the teenage years. Increased schoolwork and prolonged periods of reading may then exacerbate the characteristic symptoms. The type of patient most often encountered is a high-school, college, or university student who is especially prone to develop symptoms before examinations when special demands are made on the near vision complex during extended periods of studying. Needless to say, symptoms are aggravated by lack of sleep, reduction of general well-being, and anxiety.

THERAPY. Therapy for convergence insufficiency is in the realm of orthoptics. Indeed its treatment

is the most successful application of orthoptics and in most instances provides long-lasting relief from symptoms (see Chapter 24). On occasion, however, especially when convergence insufficiency is associated with a large exophoria at near vision, orthoptic treatment fails and surgery may be indicated. The ophthalmologist must remember that, as a rule, convergence insufficiency is a reversible disorder and that the decision to perform surgery should be made with extreme reluctance and not until all other therapeutic possibilities, including prisms base-in, have been exhausted. If surgery is imperative, we have advocated resection of both medial rectus muscles.⁴⁰ Frequently, a temporary overcorrection follows this procedure, and the patient must be warned to expect double vision for several weeks or even months postoperatively.⁴⁰ Of interest is the fact that the consecutive esotropia usually is greater at distance than at near fixation. If this occurs Fresnel prisms are prescribed as upper segment bifocals to neutralize diplopia. Fortunately, the consecutive esotropia has a tendency to disappear spontaneously. Nemet and Stolovitch³⁹ suggested resecting the upper border and recessing the lower border of the medial rectus muscles to make the operation more effective at near than at distance fixation.

From our experience with patients operated on by a resection of both medial rectus muscles and followed for several years, we observed that exophoria at near fixation tends to recur. In several patients, the deviation gradually increased to the preoperative angle. This recurrence notwithstanding, for unknown reasons patients who have been operated on in this manner usually remain asymptomatic. The efficacy of surgical treatment of intractable convergence insufficiency for relief of asthenopic symptoms was confirmed by Hermann.²⁸

Convergence Insufficiency Associated with Accommodative Insufficiency

First mentioned by Duane,²² systemic convergence insufficiency, associated with subnormal accommodation, was later described by Brown⁸ following diphtheria, mononucleosis, encephalitis, and streptococcal throat infections. Brown pointed out that this type of convergence insufficiency differs radically from the functional type, inasmuch as symptoms are more severe and remissions are few.

Von Noorden and coworkers⁴¹ reported nine

adolescent and young adult patients with a combined insufficiency of accommodation and convergence. These patients did not respond to conventional orthoptic training. Except for one patient in whom symptoms developed suddenly after an automobile accident, all others had a gradual onset over many years, and the complaints were no different from those commonly associated with functional convergence insufficiency. Unlike in simple convergence insufficiency, the near point of accommodation was found to be drastically reduced (Fig. 22-3), and the accommodative convergence/accommodation (AC/A) ratio was extremely low or absent. In five patients, convergence response could not be elicited at all by stimulation of accommodation with minus lenses. With the exception of one case of trauma, the histories of all other patients were unremarkable except for severe febrile illnesses during childhood in two instances. Von Noorden and coworkers⁴¹ assumed that trauma or subclinical viral encephalopathies may be factors in the pathogenesis of this condition. Trimble⁵⁵ reported sudden loss of accommodation and convergence in a 12-year-old boy. A cause was not established.

Such patients are treated by us with plus lenses for reading and prisms base-in. Only the minimal power necessary to achieve comfortable vision should be prescribed. Fresnel membrane prisms and lenses are of value since frequent adjustment of lenses and prisms may be necessary before the optimal correction can be achieved. Miotics are totally ineffective since they increase the exodeviation at near vision, thus adding to the patient's discomfort. Resection of both medial rectus muscles followed by prescription of bifocals may be helpful.⁴⁰

To recognize this syndrome prior to orthoptic therapy, which has been futile in our hands but reported to be effective by others,³⁷ we recommend measuring the near point of accommodation in all patients with convergence insufficiency.

Convergence Paralysis

Parinaud⁴³ was the first to describe convergence paralysis as a condition distinct from convergence insufficiency, whereby diplopia exists only at near fixation, adduction is normal, and the patient is unable to converge. Accommodation may be normal, reduced, or absent, and the pupil may or may not be involved. In some patients the pupillary reflex may be abolished for convergence and re-

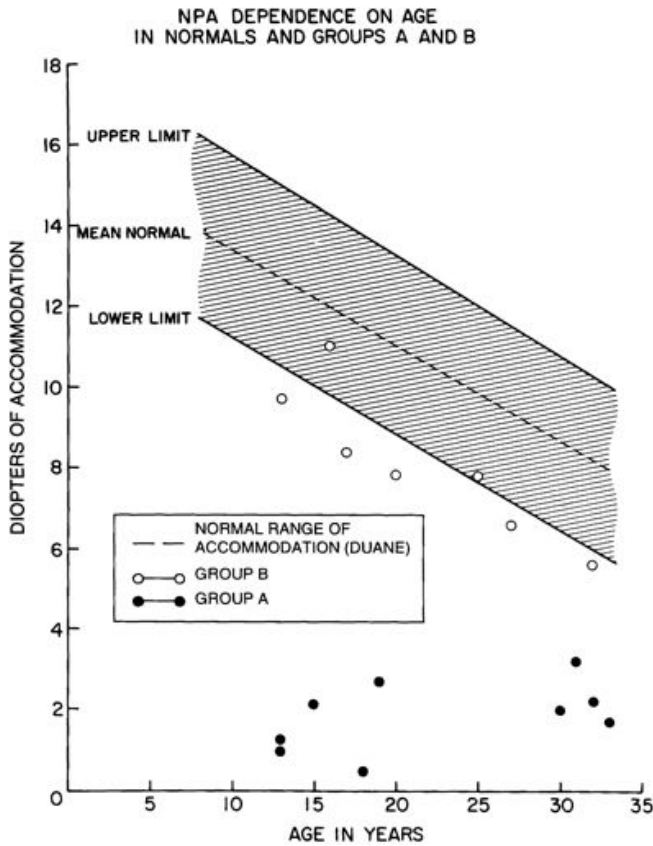


FIGURE 22-3. Near point of accommodation (NPA) in patients with ordinary convergence insufficiency (GROUP A) and combined convergence-accommodation deficiency (GROUP B). The shaded area represents the normal accommodative range established by Duane. (From Noorden GK von, Brown DJ, Parks M: Associated convergence and accommodation insufficiency. *Doc Ophthalmol* 34:393, 1973.)

tained for light (reversed Argyll Robertson pupil). Numerous case reports have followed Parinaud's original description, and the reader is referred to the current texts on neuro-ophthalmology for reviews of the pertinent literature. Bielschowsky³ further analyzed convergence paralysis and its differential diagnosis. He recognized the difficulties involved in differentiating organic from functional disturbances of convergence, that is, distinguishing between the patient's *inability* to converge and his or her *unwillingness* to do so. Convergence paralysis may be easily simulated—intentionally in uncooperative patients and unintentionally in neurotic patients and those with debilitating diseases. To establish whether the patient is unable or unwilling to converge, one must test the fusional convergence with a rotary prism by gradually introducing prisms base-out at a fixation distance of 1 to 2 m. A patient with convergence paralysis will immediately recognize diplopia when prisms are used. The condition is functional when fusional convergence can be elicited with prisms. Bielschowsky³ established the following prerequisites for the diagnosis of convergence paralysis: (1) evidence of intracranial disease, (2) history of sudden onset of crossed diplopia at near fixation, (3) reproducible findings on subsequent examina-

tions, and (4) preservation of accommodation and pupillary reaction on attempts to converge. If internal ophthalmoplegia is associated with convergence paralysis, the presence of an organic lesion of nuclear or supranuclear location is almost certain.

Autopsy findings have shown that convergence paralysis occurs most frequently when lesions are present in the corpora quadrigemina or the third cranial nerve nucleus. The frequent association of convergence paralysis with vertical gaze paralysis (Parinaud's syndrome) further emphasizes that convergence paralysis may be caused by lesions in this location.

Walsh and Hoyt^{56, p.237} listed encephalitis, disseminated sclerosis, and tabes as etiologic factors in convergence paralysis but stated that convergence paralysis occurs most commonly as a result of head injury. Convergence paralysis following mushroom poisoning has also been reported.²⁵ If accommodation is also defective (internal ophthalmoplegia), therapy consists of prisms base-in for near vision in combination with bifocals.

Convergence Spasm

In our experience, convergence spasm occurs almost exclusively in "hysterical" or otherwise neu-

rotic persons. Such patients will exhibit intermittent episodes of sustained maximal convergence associated with accommodative spasm (induced myopia) and miosis. The functional nature of this condition is emphasized by the finding that such patients may have tubular field defects. In some instances, the spasm can be triggered by asking the patient to fixate an object held closely before the eyes. After the fixation object has been removed, the eyes will remain in a convergent position, as demonstrated by Case 22-1.

CASE 22-1

A 28-year-old female school teacher complained of intermittent double vision and blurring. Her visual acuity was 6/6 OU without correction. Refraction revealed emmetropia. Examination of ocular motility showed orthophoria at distance. During the cover and the cover-uncover test at near fixation, the patient's eyes suddenly converged, she complained of diplopia, and her pupils had become miotic. She maintained convergence after removal of the fixation target. Refraction was repeated, and myopia of 6D was now present in each eye. After 12 minutes the eyes returned spontaneously to a normal position. On further questioning the patient complained about a multitude of bizarre symptoms. She was referred to a psychiatrist who diagnosed "hysteria."

Souders⁵¹ reported convergence spasm in two neurotic persons. The clinician should be aware, however, that convergence spasm may have an organic basis, and it has been reported to occur after encephalitis, tabes, labyrinthine fistulas,⁵ trauma,^{20; 56, p.239} Arnold-Chiari malformation, pituitary adenoma, and posterior fossa neurofibroma.¹⁹ Thus patients with spasm of the near reflex should undergo neurologic evaluation to exclude these organic causes.¹⁹ Bielschowsky³ reported convergence spasm with traumatic unilateral depressor paralysis in a patient in whom a spasm of convergence and accommodation occurred after an attempt to overcome the vertical diplopia.

Unless an organic cause can be found, therapy consists of prolonged atropinization of the eyes and plus lenses prescribed as lower segment bifocals. Monocular occlusion may also be considered. This treatment may have to be applied for many months, sometimes for as long as a year, before the convergence spasm subsides and the patient regains visual comfort.

Anomalies of Divergence

Divergence Insufficiency

Divergence insufficiency is regarded as a separate and benign clinical entity to be differentiated from divergence paralysis and bilateral cranial nerve VI paresis. It is characterized by intermittent or constant esotropia at distance fixation with symptomatic uncrossed diplopia in patients who maintain fusion at near. Characteristically, the angle of strabismus is the same in primary position and lateral gaze. Fusional divergence is reduced markedly both at distance and near fixation. Unlike in the case of divergence paralysis, the neurologic findings are normal.

The literature contains relatively few reports dealing with divergence insufficiency.^{12, 29, 38, 42, 46} A distinction between divergence insufficiency and paralysis is by no means an easy task in every case, nor is it always possible. On clinical grounds, however, whenever possible we find it useful to differentiate between a patient with esotropia of sudden onset at distance fixation in the absence of neurologic disease (divergence insufficiency) and one in whom this event is associated with a history of head trauma, hypertensive vascular disease, or other neurologic problems (divergence paralysis). In divergence insufficiency without neurologic signs we first use prisms base-out in the amount required to give the patient comfortable single vision at distance fixation. This prescription usually does not interfere with single binocular vision at near fixation but if it does, upper segment Fresnel prisms are prescribed.

Since divergence insufficiency is a self-limiting condition, the prisms usually can be reduced in power after several weeks or months and eventually be dispensed with. However, if the patient does not respond to prisms, resection of both lateral rectus muscles should be considered^{11, 36} and adjustable sutures are advisable.³⁵

Divergence Paralysis

Divergence paralysis was described first as a clinical entity by Parinaud,⁴³ who observed patients with a sudden onset of homonymous diplopia at distance fixation in whom ductions and versions were normal. Many subsequent cases have been reported.^{10, 21, 24, 32} Among the underlying diseases most frequently cited to be etiologically significant are tabes, encephalitis, disseminating sclerosis,

pseudotumor cerebri,³⁰ poliomyelitis,^{23; 56, p.238} influenza,² vascular lesions involving the vertebro-basilar arterial system,¹⁸ neoplasms,^{9, 34, 36} increased intracranial pressure,^{13, 31, 54} and head trauma,³³ in which divergence paralysis may be associated with papilledema.⁴⁸ Even though the existence of divergence paralysis has been disputed for a long time, many current authors have accepted it.²⁹ Bielschowsky⁴ discussed the difficulties encountered in making the diagnosis of divergence paralysis and pointed out how frequently this condition may be simulated by paresis of one or both lateral rectus muscles. He observed several cases of lateral rectus paresis in which comitance developed rapidly, and within a matter of a few weeks the motility defect became indistinguishable from divergence paralysis. Jampolsky³⁰ expressed the view that divergence paralysis does not exist and that all such patients actually have a bilateral cranial nerve VI paresis. Kirkham and coworkers³¹ reported three patients with increased intracranial pressure and divergence paralysis. The deviation remained unchanged in lateroversion, but the electro-oculographically determined saccadic velocities were significantly reduced in abduction, which attests to weakness of lateral rectus muscle action. After the patients recovered, symptoms of divergence paralysis subsided and saccadic velocities in abduction returned to normal. These authors concluded that cranial nerve VI pareses, caused by increased intracranial pressure, may produce symptoms of divergence paralysis without other evidence of cranial nerve VI palsy and without the need to evoke a specific lesion involving the divergence mechanism. Hence a clear distinction between divergence palsy and lateral rectus muscle paresis may be difficult at times, or even impossible, since one condition may merge with the other.

On the other hand, the evidence from carefully conducted studies of individual cases is sufficiently convincing to consider divergence paralysis as a clinical entity separate from a bilateral cranial nerve VI paresis. Several findings clearly inculcate the divergence mechanism and cannot be explained on the basis of bilateral abducens nerve paresis: (1) fusional divergence is markedly reduced or absent if measured from the fusion-free position at near and distance fixation, (2) the esotropia not only remains unchanged but may even decrease in lateroversion,^{14, 21, 43} and (3) saccadic velocities are only mildly reduced, as a

recent study of 12 patients with the clinical findings of divergence paralysis has shown.³⁵

According to Bielschowsky,⁴ the diagnosis of divergence insufficiency or paralysis is based on the following criteria: (1) there is a sudden onset of uncrossed diplopia at distance fixation, (2) the angle of strabismus remains unchanged or may decrease on lateroversion, (3) when an object is brought nearer to the patient, the two images approach each other and are finally fused when the object is at a distance of 25 to 40 cm from the patient, and (4) the field of fixation is unrestricted. Bielschowsky⁴ also pointed out that divergence paralysis occasionally may be confused with convergence spasm. In both instances the patient will complain of uncrossed diplopia at distance fixation; however, in convergence spasm, fusional divergence is unimpaired and visual acuity at distance is decreased.

REFERENCES

- Adler FH: Pathologic physiology of strabismus. *Arch Ophthalmol* 50:19, 1953.
- Anselmi P: Contributo clinico alla paralisi della divergenza. *Riv Otoneurooftalmol* 39:659, 1964.
- Bielschowsky A: Symptomatology der Störungen im Augenbewegungsapparat. In Bunke O, Foerster O, eds: *Handbuch der Neurologie*, vol 4. Berlin, Springer-Verlag, 1936, p 173 ff.
- Bielschowsky A: Lecture on Motor Anomalies. Hanover, NH, Dartmouth College Publications, 1943/1956, p 152 ff.
- Borries GVT: Konvergenzspasmus und Labyrinthleiden. *Monatsschr Ohrenheilkd* 60:736, 1926; cited in *Zentralbl Ges Ophthalmol* 17:912, 1927.
- Brecher GA, Hartman AP, Leonard DD: Effect of alcohol on binocular vision. *Am J Ophthalmol* 39:44, 1955.
- Breinin GM: The nature of vergence revealed by electromyography. III. Accommodative and fusional vergence. *Arch Ophthalmol* 58:623, 1957.
- Brown HW: Strabismus in the adult. In Haik GM, ed: *Strabismus. Symposium of the New Orleans Academy of Ophthalmology*. St Louis, Mosby-Year Book, 1962, p 259.
- Brown S, Iacuone JJ: Intact sensory fusion in a child with divergence paresis caused by a pontine glioma. *Am J Ophthalmol* 128:528, 1999.
- Bruce GM: Ocular divergence: Its physiology and pathology. *Arch Ophthalmol* 13:639, 1935.
- Burian HM: Anomalies of the convergence and divergence functions and their treatment. In *Symposium on Strabismus. Transactions of the New Orleans Academy of Ophthalmology*. St Louis, Mosby-Year Book, 1971, p 223.
- Burian HM, Brown AW: Unusual adverse effect of prismatic corrections in a child with divergence insufficiency. *Am J Ophthalmol* 74:336, 1972.
- Chamlin M, Davidoff L: Divergence paralysis with increased intracranial pressures (further observations). *Arch Ophthalmol* 46:195, 1951.
- Cogan DG: Convergence nystagmus with notes on a single case of divergence nystagmus. *Arch Ophthalmol* 62:295, 1959.
- Colson ZW: The effect of alcohol on vision. An experimental investigation. *JAMA* 115:1525, 1940.
- Costenbader FD: The physiology and management of di-

- vergent strabismus. In Allen JH, ed: *Strabismic Ophthalmic Symposium I*. St Louis, Mosby-Year Book, 1950, p 351.
17. Crosby EC: Relations of brain centers to normal and abnormal age movements in the horizontal plane. *J Comp Neurol* 99:437, 1953.
 18. Cunningham RD: Divergence paralysis. *Am J Ophthalmol* 74:630, 1972.
 19. Dagi LR, Chrousos GA, Cogan DC: Spasm of the near reflex associated with organic disease. *Am J Ophthalmol* 582:103, 1987.
 20. de Morsier G, Balavione C: Spasmes de la convergence. *Ophthalmologica* 116:248, 1948.
 21. Duane A: A case of divergence paralysis and its bearing upon the theory of squint and heterophoria. *Arch Ophthalmol* 28:261, 1899.
 22. Duane A: Anomalies of the accommodation, clinically considered. *Arch Ophthalmol* 45:124, 1916.
 23. Dunnington JH: Paralysis of divergence with report of cases due to epidemic encephalitis. *Arch Ophthalmol* 52:39, 1923.
 24. Dunphy EB: Paralysis of divergence. *Am J Ophthalmol* 11:298, 1928.
 25. Gilad E, Biger Y: Paralysis of convergence caused by mushroom poisoning. *Am J Ophthalmol* 102:124, 1986.
 26. Graefe A von: Über Myopie in distans nebst Betrachtungen über Sehen jenseits der Grenzen unserer Accommodation. *Graefes Arch Clin Exp Ophthalmol* 2:158, 1855.
 27. Graefe A von: Über musculäre Asthenopie. *Graefes Arch Clin Exp Ophthalmol* 8:314, 1862.
 28. Hermann JS: Surgical therapy for convergence insufficiency. *J Pediatr Ophthalmol* 18:28, 1981.
 29. Jacobsohn DM: Divergence insufficiency revisited: Natural history of idiopathic cases and neurological associations. *Arch Ophthalmol* 118:1237, 2000.
 30. Jampolsky A: Ocular divergence mechanisms. *Trans Am Ophthalmol Soc* 68:730, 1971.
 31. Kirkham TH, Bird AC, Sanders MD: Divergence paralysis with increased intracranial pressure: An electro-oculographic study. *Br J Ophthalmol* 56:776, 1972.
 32. Lebensohn JE: Paralysis of divergence with chorea and with tabes. *Am J Ophthalmol* 9:684, 1926.
 33. Leydhecker W: Divergenzlähmung. *Klin Monatsbl Augenheilkd* 123:83, 1953.
 34. Lippmann O: Paralysis of divergence due to cerebellar tumor. *Arch Ophthalmol* 31:299, 1944.
 35. Lim L, Rosenbaum AL, Demer JL: Saccadic velocity analysis in patients with divergence paralysis. *J Pediatr Ophthalmol Strabismus* 32:76, 1995.
 36. Lyle DJ: Divergence insufficiency. *Arch Ophthalmol* 52:858, 1954.
 37. Mazow ML, France TD: Acute accommodative and convergence insufficiency. *Trans Am Ophthalmol Soc* 87:158, 1989.
 38. Moore S, Harbison JW, Stockbridge L: Divergence insufficiency. *Am Orthopt J* 21:59, 1971.
 39. Nemet P, Stolovitch C: Biased resection of the medial recti: A new surgical approach to convergence insufficiency. *Binocular Vision Strabismus Q* 5:213, 1990.
 40. Noorden GK von: Resection of both medial rectus muscles in organic convergence insufficiency. *Am J Ophthalmol* 81:223, 1976.
 41. Noorden GK von, Brown DJ, Parks M: Associated convergence and accommodation insufficiency. *Doc Ophthalmol* 34:393, 1973.
 42. Oaks LW: Divergence insufficiency as a practical problem. *Arch Ophthalmol* 41:562, 1949.
 43. Parinaud H: Clinique nerveuse: Paralyse des mouvements associés des yeux. *Arch Neurol (Paris)* 5:145, 1883.
 44. Pasik P, Pasik T: Oculomotor functions in monkeys with lesions of the cerebrum and the superior colliculi. In Bender MB, ed: *The Oculomotor System*. New York, Harper & Row, 1964.
 45. Powell WH: Ocular manifestations of alcohol and a consideration of individual variations in seven cases studied. *J Aviat Med* 9:97, 1938.
 46. Prangen AD, Koch FLP: Divergence insufficiency: A clinical study. *Am J Ophthalmol* 21:510, 1938.
 47. Pratt-Johnson JA, Tillson G: Acquired central disruption of fusional amplitude. *Ophthalmology* 86:2140, 1979.
 48. Rutkowsky PC, Burian HM: Divergence paralysis following head trauma. *Am J Ophthalmol* 73:660, 1972.
 49. Scobee RG, Green EL: A center for ocular divergence: Does it exist? *Am J Ophthalmol* 29:422, 1946.
 50. Scott A: V pattern exotropia. Electromyographic study of an unusual case. *Invest Ophthalmol* 12:232, 1973.
 51. Souders BF: Functional ocular deviation. *Am Orthopt J* 19:55, 1969.
 52. Spierer A, Huna R, Rechtman C, Lapidor D: Convergence insufficiency secondary to subdural hematoma. *Am J Ophthalmol* 120:258, 1995.
 53. Tamler E, Jampolsky A: Is divergence active? An electromyographic study. *Am J Ophthalmol* 63:452, 1967.
 54. Terkeli O, Tomaç S, Gürsel E, Hasiripi H: Divergence paralysis and intracranial hypertension due to neurobrucellosis. A case report. *Binocular Vision Strabismus Q* 14:117, 1999.
 55. Trimble RB: Loss of accommodation and convergence. *Proc R Soc Med* 70:261, 1977.
 56. Walsh FB, Hoyt WF: *Clinical Neuro-Ophthalmology*, ed 3, vol 3. Baltimore, Williams & Wilkins, 1969.
 57. Warwick R: Oculomotor organization. In Bender MB, ed: *The Oculomotor System*. New York, Harper & Row, 1964.
 58. Westheimer G, Rashbass C: Barbiturates and eye vergence. *Nature* 191:833, 1961.

Nystagmus

Congenital nystagmus is an involuntary, rhythmic, pendular, or jerky conjugate oscillation of the eyes and occurs in a manifest and a latent form. Because of fundamental differences in their clinical manifestations, waveform, and relationship to strabismus, separate discussions of each type are in order.

The etiology and clinical manifestations of nystagmus are not discussed in detail in this chapter; the reader is referred to the standard texts on neuro-ophthalmology for this information. Other sources are the reports of Goddé-Jolly and Larmande⁷⁴ and of Spielmann¹⁶⁰ to the French Ophthalmological Society, as well as the numerous contributions by Dell'Osso and coworkers referred to throughout this chapter.

We have limited our discussion of the clinical management of nystagmus to what is of concern to the strabismologist. Nystagmus may be *congenital* or *acquired*. We shall deal primarily with the congenital form but will also discuss treatment modes for acquired nystagmus and oscillopsia.

Manifest Congenital Nystagmus

The prevalence of congenital nystagmus in the general population has been estimated to be 1 in 6550.⁹² A curious and unexplained preponderance of men has been noted consistently in the literature.^{4, 28, 74} Common causes of manifest congenital nystagmus are congenital cataracts, congenital glaucoma, aniridia, achromatopsia, Down syndrome,¹⁸¹ and high myopia. The most common

diagnoses in a recently reported study of 152 cases with congenital nystagmus from a pediatric neuro-ophthalmologic practice were optic nerve hypoplasia, Leber's amaurosis, and oculocutaneous albinism.⁷² In our practices, which are almost exclusively dedicated to ocular motility disorders, oculocutaneous albinism is by far the leading cause of manifest congenital nystagmus.

Manifest congenital nystagmus is infrequently observed at birth. Its onset is usually during the first 3 to 4 months of life, but it has been reported to emerge as late as during the teenage years or even in adulthood,⁸⁰ giving cause to question the validity of the prefix "congenital." Sequential electronystagmographic (ENG) recordings in this case have shown that the nystagmus developed at 8 weeks of age and was preceded by square wave jerks 1 week earlier.⁷⁶ Jayalakshmi and coworkers,⁹⁸ in a prospective study of 52 patients with infantile nystagmus, made the interesting observation that congenital nystagmus disappeared in approximately half the patients by 5 years of age. This prevalence decreased to 30% when associated with a neurologic disorder or strabismus or both, but increased to 70% when neither of these conditions was present. We have followed children with congenital nystagmus for a considerably longer period and have gained the impression that nystagmus disappears spontaneously less frequently than is indicated by these studies.

Sensory and Motor Type

Cogan²⁷ has classified congenital nystagmus into two principal types, which he named *sensory defect nystagmus* and *motor defect nystagmus*.

The primary cause of *sensory defect nystagmus* is inadequate image formation on the fovea as a result of anterior visual pathway disease. Inadequate image formation causes a disturbance of the feedback from the fovea that interferes with oculomotor control of the fixation mechanism.

Cogan suggested that oculomotor stabilization depends on the presence of normal sensory afferents. Experimental support for this has been provided by ten Doesschate,¹⁷⁶ who observed the occurrence of pendular nystagmus after the stimulus for fixation was abolished by stabilization of the foveal image. However, attempts to fixate or the "effort to see"⁴² cannot be the only mechanism to trigger congenital nystagmus since nystagmus may continue when the patient wears Fresnel glasses or is in complete darkness, that is, under conditions in which all fixation efforts are abolished.¹⁵⁶

Sensory defect nystagmus is always bilateral and horizontal and often is of the pendular type in which the eyes oscillate with equal velocity in both directions. However, this type of nystagmus assumes a jerky character in extreme positions of gaze. Pure pendular nystagmus occurs infrequently and differentiation of congenital nystagmus into a pendular and a jerky type, as originally proposed by Cogan, is no longer recommended.^{37, 51, 99, 185}

Motor defect nystagmus is a form of congenital nystagmus in which the primary defect is in the efferent mechanism, possibly involving the centers or pathways for conjugate oculomotor control. No ocular abnormalities are present, and the amplitude and frequency may decrease or the nystagmus may disappear completely in one position of gaze, and visual acuity then may improve. This may cause the patient to assume an anomalous head posture to improve visual acuity with the eyes in the position of least nystagmus (null point,⁴ neutral zone,¹⁰³ privileged area¹⁵⁹). In both forms of nystagmus the amplitude may increase considerably on attempts to fixate a visual object. Also, both forms may be associated with *head nodding*.

Eye and head movement recordings do not distinguish between congenital nystagmus and *spasmus nutans*,⁷⁷ a small-amplitude, high-frequency, horizontal nystagmus in one or both eyes that is accompanied by head nodding. An anomalous head posture may be present. *Spasmus nutans*, once thought of as an essentially benign entity, may be associated with optic nerve and chiasm gliomas, empty sella syndrome, or a

porencephalic cyst.¹⁰⁷ Although these anomalies occur infrequently we advise neuroimaging in each new case. A higher prevalence of strabismus and amblyopia in the eye with the greater amplitude of nystagmus has been noted in *spasmus nutans*.¹⁸⁶

Another form of *uniocular nystagmus* occurs in deep amblyopia (Heimann-Bielschowsky phenomenon; see p. 262) or with voluntary nystagmus.¹⁴

Cogan's original classification of sensory and motor defect nystagmus has been challenged by neurologists.^{27, 45, 99} The suggestion that an anomaly in the visual system in a patient with congenital nystagmus establishes a causal relationship has been disputed since both the visual disturbance and nystagmus may be present independent of each other.³⁷ Although it is true that a causal relationship cannot be established in each case, there are numerous instances, perhaps more familiar to ophthalmologists than to neurologists, in which such a relationship seems to be overwhelmingly evident. For example, nystagmus is frequently associated with congenital cataracts and may develop within months after the onset of congenital cataracts in a patient who previously had no nystagmus,¹⁰ or it may disappear after cataract surgery followed by contact lens correction.¹²⁸ Nystagmus also may go into remission in children with congenital aniridia after they are fitted with a pinhole contact lens.^{63, 73, 93} It is difficult to deny a cause-and-effect relationship between the visual disturbance and nystagmus in these instances as well as in patients with motor defect nystagmus whose visual acuity often is clearly dependent on changes in the intensity of nystagmus in different positions of gaze and may improve dramatically when the nystagmus is dampened by convergence. Thus, from a clinical point of view, the differentiation into sensory and motor defect types of nystagmus continues to be useful.

Clinical Characteristics

WAVEFORM. Congenital nystagmus is characterized by a slow drift of the visual target off the fovea, followed by a rapid saccadic correction movement.^{46, 51} *Manifest nystagmus*, unlike *latent nystagmus*, usually occurs with equal amplitude and frequency regardless of whether both eyes are open or one eye is closed¹³³ (Fig. 23–1). However, in the case of manifest nystagmus with a superim-

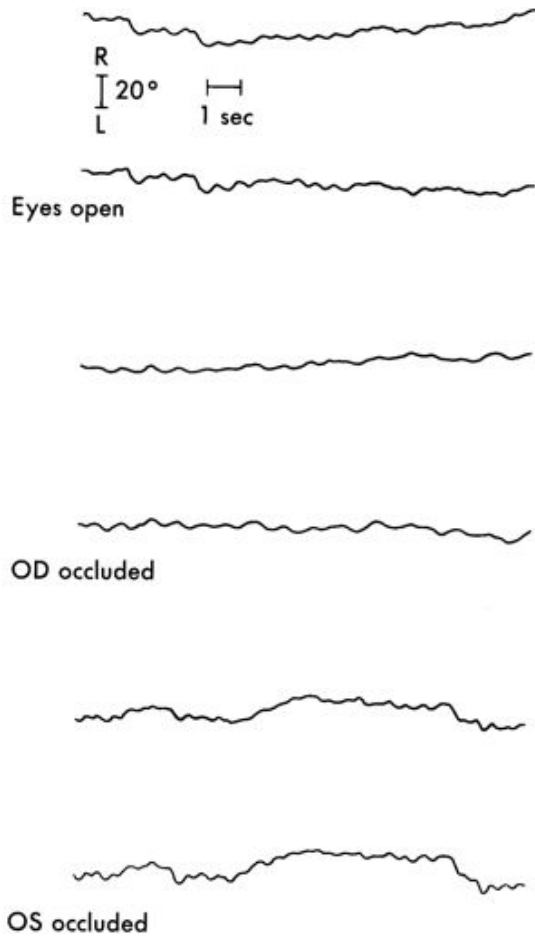


FIGURE 23-1. Binocular electronystagmogram of manifest congenital nystagmus. Mostly pendular waveform and no significant change on covering either eye. (From Noorden GK von, Munoz M, Wong SY: Compensatory mechanisms in congenital nystagmus. *Am J Ophthalmol* 104:387, 1987.)

posed latent nystagmus, the nystagmus intensifies upon occlusion of one eye.¹⁰⁶ The most salient feature distinguishing manifest from latent congenital nystagmus is an increasing-velocity slow phase in manifest nystagmus, whereas in latent nystagmus the slow phase is of decelerated velocity⁵⁴ (Fig. 23-2). Vestibular nystagmus, on the other hand, is characterized by a constant-velocity slow phase.

The distinction between a decreasing- and increasing-velocity slow phase cannot be made by clinical observation but requires ENG registration of eye movements.^{54, 136} Other important distinguishing features of manifest and latent congenital nystagmus are listed in Table 23-1.

VISUAL ACUITY. In most patients with nystagmus, visual acuity is decreased. With sensory defect nystagmus, visual acuity is determined, of course, by the nature of the organic defect. With

the motor defect type, visual acuity is reduced because of the nystagmus and may be as low as 6/60.^{5, 67, 70, 82, 116} To fully evaluate the visual potential of a patient with manifest nystagmus, it is necessary to determine visual acuity not only in the conventional manner by covering either eye but also with both eyes open. Binocular acuity may be higher than monocular acuity when a superimposed latent nystagmus is present. The reverse may be true, however, in some cases; nystagmus decreases on covering either eye, resulting in improved monocular visual acuity.¹³⁷ The motor characteristics of nystagmus, its amplitude, frequency, and velocity, do not always correlate with the level of visual acuity.¹¹⁶ We have observed some patients who, in spite of a coarse, large-amplitude nystagmus, had only a slight reduction in visual acuity and others with a low-amplitude nystagmus who had a severe reduction (see also Handa⁸⁵).

The possibility exists that the constant image sweep across the fovea of both eyes will cause sufficient blurring to produce *visual deprivation amblyopia* similar to bilateral amblyopia caused by uncorrected high hypermetropia. Thus deprivation amblyopia of both eyes may be superimposed on nystagmus and complicate attempts to correlate the motor and sensory behavior.

The fixation distance also may affect the visual acuity of nystagmic patients. Visual acuity at near fixation often is dramatically better than at distance fixation. One should never fail therefore to check visual acuity at near in children with congenital nystagmus. A near acuity of 6/9 is not

TABLE 23-1. Characteristics of Congenital Nystagmus

Manifest	Latent or Manifest-Latent
Biphasic, mostly pendular	Jerking
Increasing-velocity slow phase	Decreasing-velocity slow phase
No change on unilateral occlusion	Increases on unilateral occlusion
Direction independent of fixating eye	Fast phase toward fixating eye
Infrequently associated with infantile esotropia	Nearly always associated with infantile esotropia
Binocular visual acuity same as monocular visual acuity	Binocular visual acuity better than monocular visual acuity.

From Noorden GK von, Munoz M, Wong S: Compensatory mechanisms in congenital nystagmus. *Am J Ophthalmol* 104:387, 1987.




FIGURE 23-2. Binocular nystagmogram in manifest-latent nystagmus (decelerating-velocity slow phase, *above*) and manifest congenital nystagmus (accelerating-velocity slow phase, *below*). (From Noorden GK von, Munoz M, Wong SY: Compensatory mechanisms in congenital nystagmus. *Am J Ophthalmol* 104:387, 1987.)

unusual with a distance acuity of only 6/60. This information is important in assessing the visual potential of a child's ability to function in a regular school environment and has led to the development of several treatment methods to improve visual acuity by inducing convergence artificially.

Improvement of visual acuity at near fixation is thought to be the result of the dampening effect of convergence innervation (see below) on the nystagmic oscillations of the eyes.^{59, 182} Probably, convergence innervation changes the velocity characteristics of the slow and fast phases of nystagmus, which increases the time the image remains on the fovea (foveation time),^{12, 51, 55-57} and thus improves visual acuity. Von Noorden and LaRoche¹³² showed by means of electro-oculography that visual acuity in nystagmic patients improved at near fixation, regardless of whether the nystagmus amplitude or frequency decreased. There is good evidence that the waveform of the nystagmus and the percentage of foveation time per cycle are more important than amplitude and frequency of the nystagmus in determining visual acuity.^{44, 60} The magnification effect of holding reading material very close to the eyes, as patients with nystagmus frequently do, must also be taken into account in explaining the improvement of near vision.

Foveation strategies, as well as waveform analysis in manifest and manifest-latent nystagmus, have been the object of numerous studies by Dell'Osso and coworkers^{49, 53, 64, 94, 155} and Hamed.⁸⁴

OSCILLOPSIA. Unlike in acquired nystagmus, oscillopsia occurs infrequently in congenital nystag-

mus. According to Dell'Osso and Leigh,⁴⁷ well-developed foveation periods create visual stability with suppression of oscillopsia. Bedell and Currie¹¹ raised the possibility that extraretinal signals may be useful in preventing oscillopsia in congenital nystagmus.

ASSOCIATION WITH STRABISMUS. Unlike latent nystagmus, which rarely occurs without essential infantile esotropia, manifest congenital nystagmus is infrequently associated with strabismus. Its prevalence in a group of 408 patients with essential infantile esotropia was only 15%. The high rate of occurrence (40%,⁷⁰ 50%^{74, 83}) reported in earlier studies was probably based on failure to distinguish between manifest nystagmus and latent nystagmus with a manifest phase (manifest-latent nystagmus), a distinction that is not always easy to make on the basis of clinical examination alone.

It has to be noted that manifest congenital nystagmus can be associated with other forms of strabismus as well, for instance with exotropia. This can add problems in the case of surgical correction of the strabismus. A correction of the anomalous head posture may increase the strabismus and a correction of the strabismus may worsen the anomalous head posture if the interrelation between the type of strabismus and the anomalous head posture is not taken into consideration.

Compensatory Mechanisms

Some patients with manifest congenital nystagmus are able to decrease the amplitude or frequency of

the nystagmus by superimposed vergence or version innervation,^{9, 161} known as “dampening” or “blocking.” *Blocking* or *blockage*, as used in the European strabismus literature, has been defined as “an innervational impulse to bring one or both eyes toward a position that can reduce or suppress the innervational impulse causing the nystagmus.”⁷ Since the English word “blocking” does not convey exactly the same meaning as the German *Blockierung* or the French *blocage*, it is preferable to speak of nystagmus compensation or nystagmus dampening, although the term “nystagmus blockage” is commonly used in the American literature.^{50, 121, 129, 131}

The purpose of nystagmus dampening is to improve visual acuity. This improvement is usually reflected by the patient’s ability to recognize smaller letters on a visual acuity chart. In others measurable visual acuity may remain unchanged, but the patient will invariably indicate that visual objects become less blurred and “easier to see” when dampening occurs.

The dampening of nystagmus by active superimposed vergence or version innervation must be distinguished from another as yet unknown mechanism by which nystagmus intensity decreases in certain *intermediate* gaze positions.

DAMPENING BY CONVERGENCE. Adelstein and Cüppers³ suggested that the decrease of the nystagmus by adduction or convergence may be etiologically significant in *causing* esotropia and introduced the term “nystagmus blockage syndrome.” They defined this syndrome as an esotropia with an onset in infancy (often preceded by nystagmus), a pseudoabducens palsy, straightening of the eyes under surgical levels of anesthesia, and the appearance of a coarse manifest nystagmus during the induction phase of anesthesia. A head turn may be elicited by covering either eye, and manifest nystagmus occurs as the fixating eye moves from adduction toward abduction.

The etiologic concept of nystagmus “blockage” and its relationship to infantile esotropia initially became widely accepted in Europe. In fact, many believed that most cases of infantile esotropia could be explained on the basis of this mechanism. However, criticisms ranged from whether the blockage mechanism existed at all¹⁸³ to the demand that the diagnosis of esotropia caused by nystagmus blockage be applied only to patients in whom an inverse relationship between the angle of esotropia and the intensity of nystagmus could

actually be demonstrated.¹⁰⁹ It was also not clear if and how the blockage syndrome defined by Adelstein and Cüppers³ differed from the discordant nystagmus described earlier by Franceschetti and coworkers.⁶⁸ Our current views on this subject, which over the years have changed from those expressed in earlier publications,^{129, 131, 134} as well as in earlier editions of this book, can be summarized as follows.

Since manifest congenital nystagmus occurs infrequently with infantile esotropia and latent or manifest-latent nystagmus is rarely found *without* this condition, most cases diagnosed in the past as having the nystagmus blockage syndrome probably had infantile esotropia associated with latent or manifest-latent congenital nystagmus. In this instance there is no reason to believe that the decreased nystagmus intensity in adduction is actually caused by dampening through superimposed adduction innervation, that is, by a blockage mechanism. In fact, there is evidence to the contrary (see p. 519).

The differentiation of these cases from the true syndrome may, in certain instances, be complicated because patients with manifest congenital nystagmus who develop esotropia from sustained convergence may convert their manifest nystagmus waveform with onset of the esotropia to a manifest-latent nystagmus waveform. Such patients will always show an increase in the magnitude of the nystagmus with abduction of the fixating eye, which is characteristic of manifest-latent but not of manifest congenital nystagmus⁵⁰ (see Fig. 23–8).

These considerations notwithstanding, dampening of *manifest* congenital nystagmus by convergence does occur, although much less frequently than previously assumed, and we accept Adelstein and Cüppers’ concept³ that such patients may become esotropic because of sustained convergence efforts and the resulting hypertonicity of the medial rectus muscles. Case 23–1, which was closely followed by us, illustrates the natural history of this condition and establishes the validity of the etiologic concept.

CASE 23–1

This 2-year-old girl has been under observation since 1 month of age. Her older sister had undergone surgery for esotropia, which had become apparent at 6 months of age. The mother remembered that the sister’s eyes “wiggled” before they crossed.

This child was referred to our clinic because the mother had noted "wiggling" eyes since shortly after birth. We diagnosed a manifest, large-amplitude congenital nystagmus. The ocular examination was entirely normal, and no strabismus was present. The child was seen every 6 weeks, and video recordings were obtained to show the nystagmus and the fact that the eyes were aligned. At 3½ months of age, the mother noted a sudden onset of strabismus and disappearance of the nystagmus. She brought the child to the office a few days later, and we confirmed that an esotropia of 50^Δ had developed and that manifest nystagmus was no longer present unless one eye was covered and the patient was fixating with the uncovered eye in a position of abduction.

With Case 21–3 in mind, we have redefined the nystagmus dampening syndrome as *a condition characterized in its acute form by an esotropia of early onset with a variable angle, changing from orthotropia with manifest nystagmus during periods of visual inattention to esotropia without nystagmus during visual attention.* In other words, the nystagmus intensity is inversely proportional to the angle of the deviation.¹⁰⁹ The esotropia may eventually become constant. Frequently, both eyes are adducted and a head turn may exist toward the side of the fixating eye. There may be an apparent weakness of both lateral rectus muscles, which can be distinguished from a true abducens paresis by means of the doll's head maneuver (see p. 70). Pupillary constriction during the esotropic phase, although denied by others,⁵⁰ occurs frequently in our experience.^{131, 136}

Case 23–2, previously reported,¹³³ shows damp-

ening of a manifest congenital nystagmus by convergence.

CASE 23–2

This 13-year-old boy was noted in early infancy to have apparently manifest nystagmus. A diagnosis of oculocutaneous albinism was made at that time. When he was first examined by us at 6 years of age, the parents related that the boy had been crossing his eyes intermittently for the past year with no improvement after glasses were prescribed. His cycloplegic refraction was +2.50 sph +4.50 cyl × 90 in both eyes. His best corrected visual acuity was 20/200 for far and 20/70 for near with both eyes open. Monocular visual acuity was OD 20/400 and OS 20/200. No head turn was noted. His alignment varied from orthophoria to an esotropia of up to 40^Δ, which he developed in association with increased visual effort. With the appearance of the esotropia the nystagmus disappeared and we made the diagnosis of nystagmus dampening by convergence.

The patient underwent a 4-mm recession of both medial rectus muscles with posterior fixations (OD 12 mm; OS 14 mm). His alignment has remained variable, changing from orthotropia to an esotropia of 20^Δ that develops in association with pupillary constriction whenever his "effort to see" increases. The nystagmus disappears as the esotropia develops (Fig. 23–3). His visual acuity with both eyes open is 20/100 for far and improves to 20/40 for near. His monocular visual acuity is 20/200 in each eye. He has no stereopsis and he suppresses the right eye with Bagolini striated glasses when esotropic.

Dampening of congenital nystagmus by fusional convergence may lead to another interesting

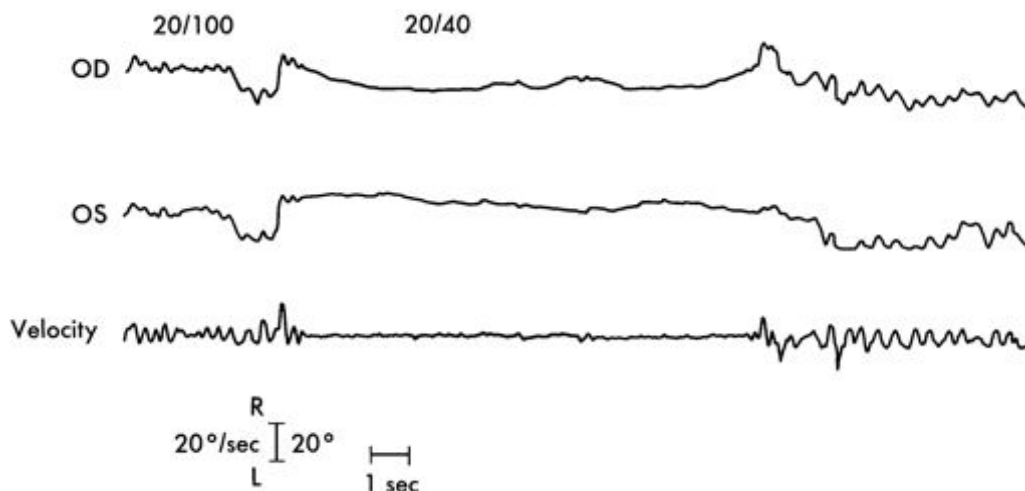


FIGURE 23–3. Case 23–2. Dampening of manifest congenital nystagmus by convergence with improvement of visual acuity during esotropic phase. (From Noorden GK von, Munoz M, Wong SY: Compensatory mechanisms in congenital nystagmus. *Am J Ophthalmol* 104:387, 1987.)

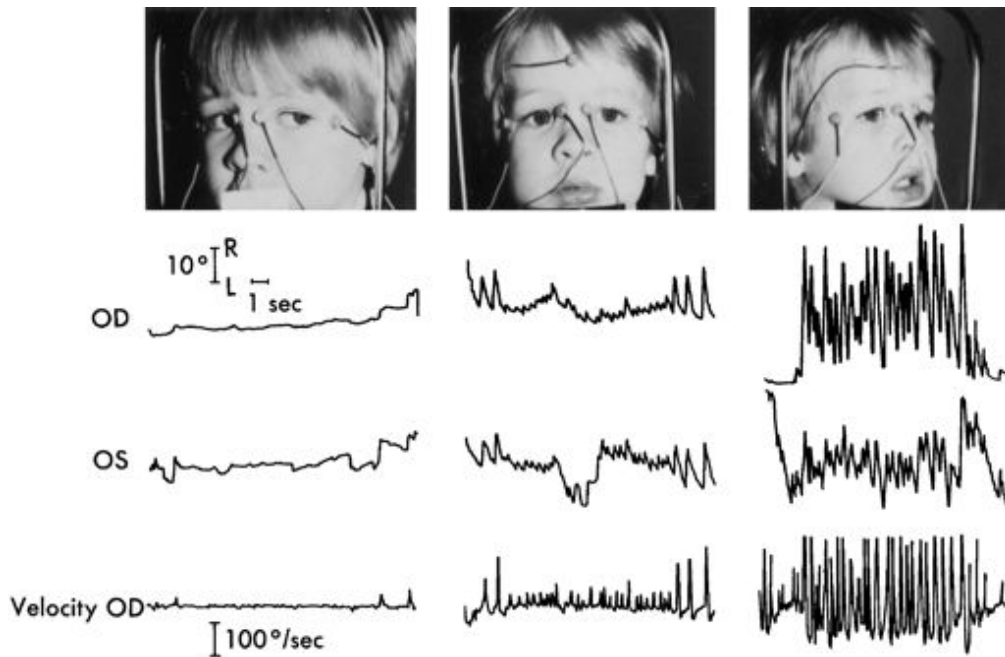


FIGURE 23-4. Dampening of manifest nystagmus with the eyes in levoversion. This patient had a spontaneous head turn to the right. (From Noorden GK von, Munoz M, Wong SY: Compensatory mechanisms in congenital nystagmus. *Am J Ophthalmol* 104:387, 1987.)

clinical picture to which attention was drawn in the same year, independently by Spielmann and Spielmann¹⁷² and by Kommerell and coworkers.¹¹³ These authors described patients with *intermittent exotropia and nystagmus* in whom the nystagmus disappeared when the exophoria was overcome by fusional convergence. Spielmann and Spielmann introduced the term *pseudo-latent nystagmus* for this entity because, just as in true latent nystagmus, the nystagmus is triggered by momentary occlusion of one eye.¹⁷² Kommerell and coworkers surgically undercorrected their patient so that the residual fusional effort to overcome the residual angle sufficed to control the nystagmus.¹¹³

DAMPENING BY VERSIONS. Another dampening strategy used by patients with manifest congenital nystagmus is version innervation. Maintaining the eyes in a peripheral gaze position by sustained innervation of yoke muscles involved in lateral, vertical, or oblique gaze causes dampening of the nystagmus innervation. Bagolini and coworkers⁹ have shown electromyographically that there are patients in whom the rhythmic bursts of electrical discharge of synergistic muscles characteristic of nystagmus are totally masked by the tonic sustained discharge of synergistic muscles during version innervation. Visual acuity usually improves measurably with the eyes in this peripheral gaze position and the patient will assume a

significant anomalous head posture in an effort to gain optimal visual acuity.

Depending on the preferred eye position (null point, neutral zone), the head may be turned to either side, tilted toward one shoulder, or the chin may be elevated or depressed. Figure 23-4 shows the ENG of a patient with a habitual head turn of 40° to the right with dampening of the nystagmus in levoversion, increase of the nystagmus in primary position, and maximal nystagmus with the eyes in dextroversion.

The anomalous head posture may not always be consistent in one direction. The patient shown in Figure 23-5A eventually developed an alternating head turn to the right or left following an Anderson-Kestenbaum operation (see p. 522) for a nystagmus with a null zone in levoversion.¹³³ The ENG now shows two null zones, one 20° to the left in which visual acuity improved to 20/70 and one 20° to the right with a visual acuity of 20/80. With the eyes in primary position nystagmus increased and impaired the visual acuity to a 20/400 level (Fig. 23-5B). This *bidirectional null zone nystagmus*, previously described by Cüppers³⁶ and by Spielmann and Dahan¹⁷⁰ (see also Spielmann¹⁶⁵), must be distinguished from *periodic alternating nystagmus (PAN)*, a cyclic alteration of direction of nystagmus with a concurrent cyclic change in the direction of the head turn.^{1, 104, 146} In bidirectional null zone nystagmus the

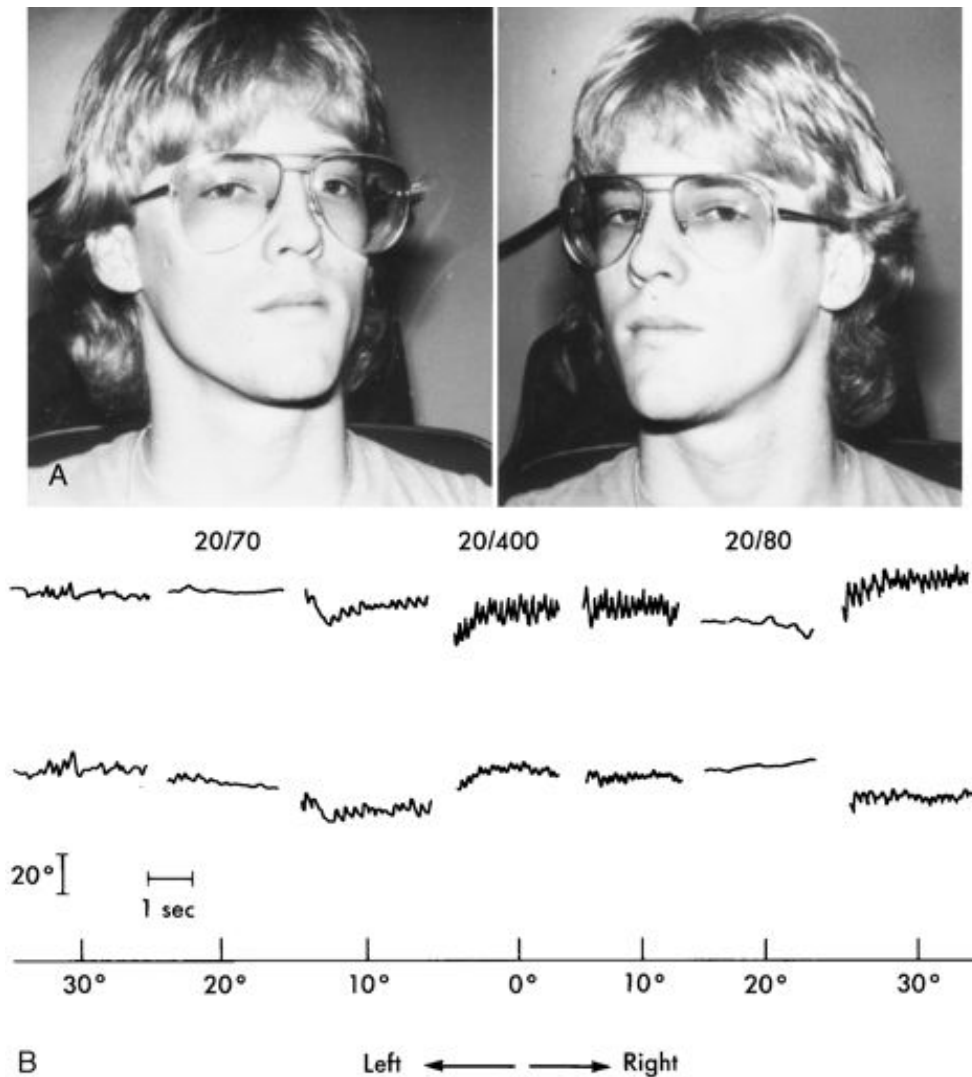


FIGURE 23-5. *A*, Alternating head turn in a patient with bidirectional null zone. *B*, Improvement of visual acuity in 20° levoversion and dextroversion. (From Noorden GK von, Munoz M, Wong SY: Compensatory mechanisms in congenital nystagmus. *Am J Ophthalmol* 104:387, 1987.)

direction of the beat does not change and the change of the head position occurs in a random rather than in a cyclic pattern. This differentiation is important in deciding on the correct surgical procedure for each condition⁷⁸ and because PAN can occur also in congenital nystagmus.¹⁵⁴

Dampening by sustained version innervation in peripheral gaze positions must be distinguished from a decrease or disappearance of the nystagmus and increase of visual acuity in peripheral gaze positions closer to the primary position.⁹ In such patients the anomalous head turn is usually not more than 10° to 15° (Fig. 23-6A), and the nystagmus will increase and visual acuity decrease when the eyes are moved in the same direction beyond the null zone, toward the periphery (Fig. 23-6B). As shown by Bagolini and coworkers,¹⁰ the nystagmus bursts of the horizontal recti mus-

cles in the electromyogram of such patients are not impeded by increased discharge of synergistic muscles as they are during maximal versions; the nystagmus simply disappears when the head is turned (rest point nystagmus). This null zone is an equilibrium between two zones of oculomotor instability, each producing a nystagmus in opposite directions.

Some patients are capable of employing more than one dampening strategy for their nystagmus.^{96, 134, 136} For instance, when the head of the patient depicted in Figure 23-5A was passively straightened, an esotropia developed (Fig. 23-7A) and visual acuity improved from 20/400 in the orthotropic to 20/100 in the esotropic position (Fig. 23-7B). We have also observed that patients with a null point in lateroversion and a compensatory head turn may develop an intermittent esotro-

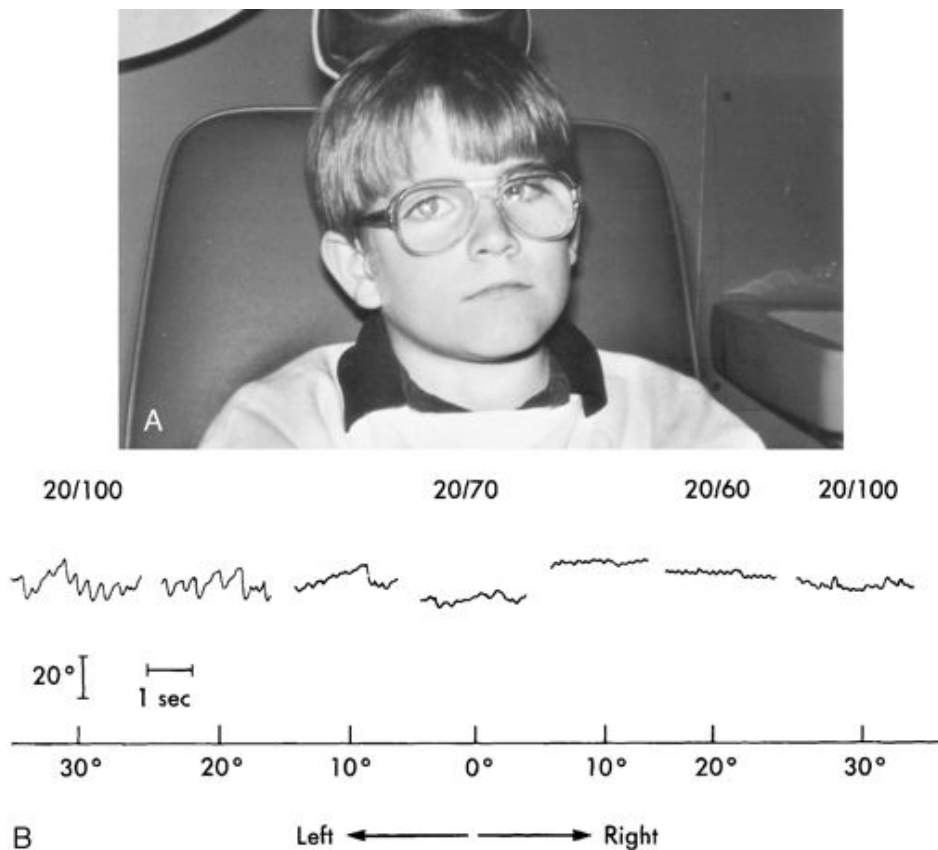


FIGURE 23-6. A, Moderate head turn to the left in a patient with manifest congenital nystagmus. B, The null zone is in 20° dextroversion, and the nystagmus increases and visual acuity decreases in 30° dextroversion. (From Noorden GK von, Munoz M, Wong SY: Compensatory mechanisms in congenital nystagmus. *Am J Ophthalmol* 104:387, 1987.)

pia from dampening by convergence after the head posture had been improved by an Anderson-Kestenbaum operation.¹³⁴ Such patients may require additional surgery for secondary esotropia. This possibility must be kept in mind when discussing the first operation with the patient or parents.

Latent and Manifest-Latent Congenital Nystagmus

Clinical Characteristics

WAVEFORM. Latent nystagmus is evoked by occluding one eye and is decreased or absent with both eyes open. A difference in the quality of retinal images in the two eyes triggers the latent phase of this nystagmus, regardless of whether normal binocular vision or a manifest strabismus is present. An unstable equilibrium of oculomotor coordination,^{111, 179} possibly caused by maldevelopment of monocular or binocular fixation reflexes,^{102, 114, 148} and a centrally generated nasal drift bias related to an impairment of spatial direc-

tionalization are among the factors that have been blamed for its occurrence.^{12, 54} Van Vliet¹⁸⁰ recorded eye movements of patients with latent nystagmus during monocular gaze intention following acoustic stimulation in complete darkness and concluded that it is the intention of “looking with one eye” that triggers the latent nystagmus (see also Dell’Osso and coworkers⁴⁸). Kommerell and Zee¹¹² reported two unusual cases of infantile esotropia and latent nystagmus in which the patients were able to suppress their nystagmus at will.

Characteristically, the amplitude of latent nystagmus decreases in adduction and increases in abduction, the fast phase always beating toward the side of the fixating eye (Fig. 23-8).

As mentioned, the salient feature distinguishing between latent and manifest nystagmus is a decreasing-velocity slow phase in the latent and manifest-latent and an increasing-velocity slow phase in the manifest form (see Fig. 23-2). The principal differences between manifest and latent nystagmus are summarized in Table 23-1.

In 1931 Sorsby¹⁵⁷ cited several studies according to which latent nystagmus becomes mani-

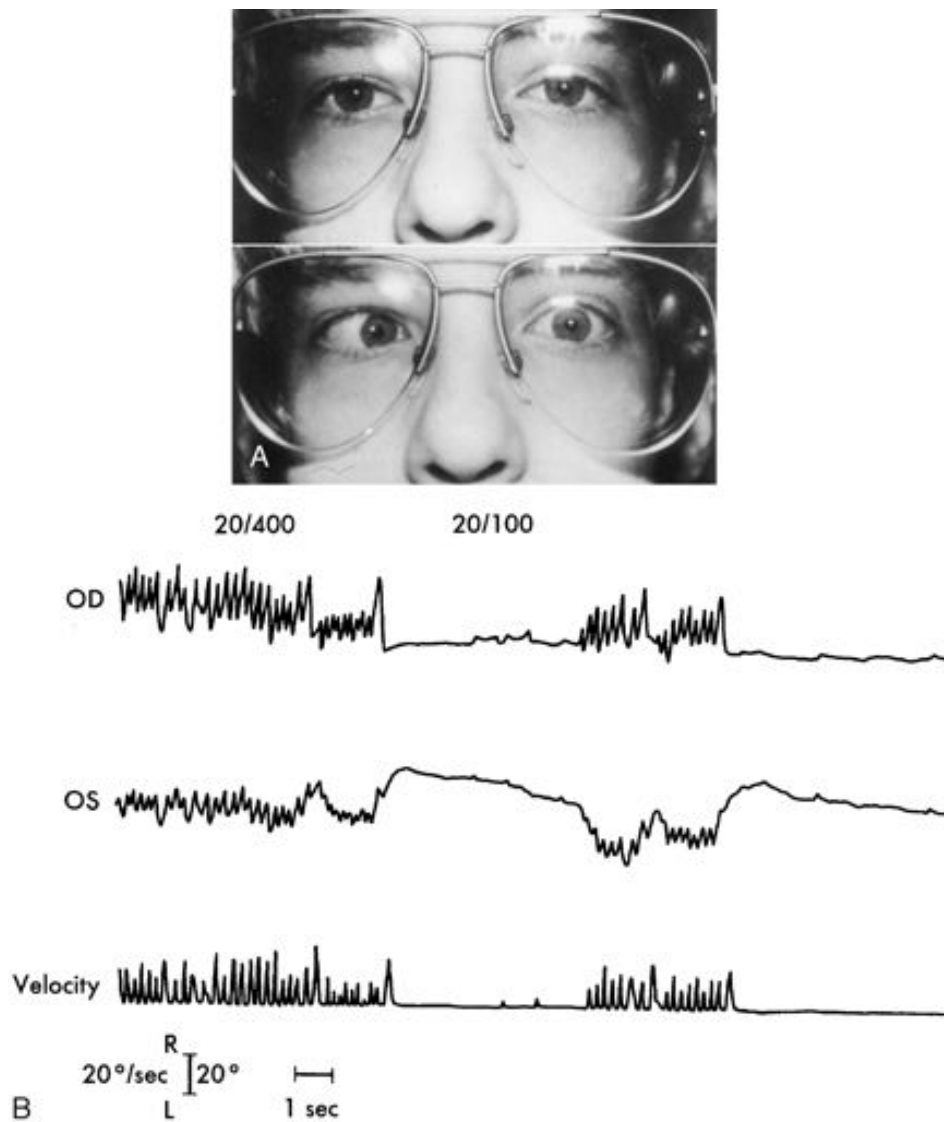


FIGURE 23-7. A, When the head of the patient shown in Figure 23-5, A, was passively straightened, an esotropia developed and both pupils constricted. B, Electronystagmogram shows disappearance of the nystagmus and an improvement of visual acuity concurrent with the development of esotropia. (From Noorden GK von, Munoz M, Wong SY: Compensatory mechanisms in congenital nystagmus. *Am J Ophthalmol* 104:387, 1987.)

fest in peripheral gaze positions and may be present with both eyes open. In 1979 Dell'Osso and coworkers⁵⁴ noted that many patients with apparently latent nystagmus actually have nystagmus with both eyes open and that true latent nystagmus occurs infrequently. The nystagmus with both eyes open is of lower intensity than when either eye is covered and may be difficult or impossible to detect without ENG (Fig. 23-9). However, in some patients the manifest phase of latent nystagmus is clearly visible on clinical examination. In this instance a clear distinction between latent and manifest nystagmus becomes difficult, if not impossible, without ENG. As mentioned previously, many patients with esotropia who were

classified in the past as having manifest nystagmus actually had latent nystagmus with a manifest phase.

To distinguish latent nystagmus with a manifest phase from true latent nystagmus, Dell'Osso and coworkers⁵⁴ used the oxymoronic term *manifest-latent nystagmus*. Kestenbaum¹⁰⁶ had earlier used a similar term (manifested latent nystagmus) when he referred to latent nystagmus manifested by blindness in one eye or by strabismic suppression. Despite its ambiguity, the term manifest-latent nystagmus as opposed to manifest nystagmus has become accepted. However, *the difference between latent and manifest-latent nystagmus is only a quantitative one; their waveforms and other*

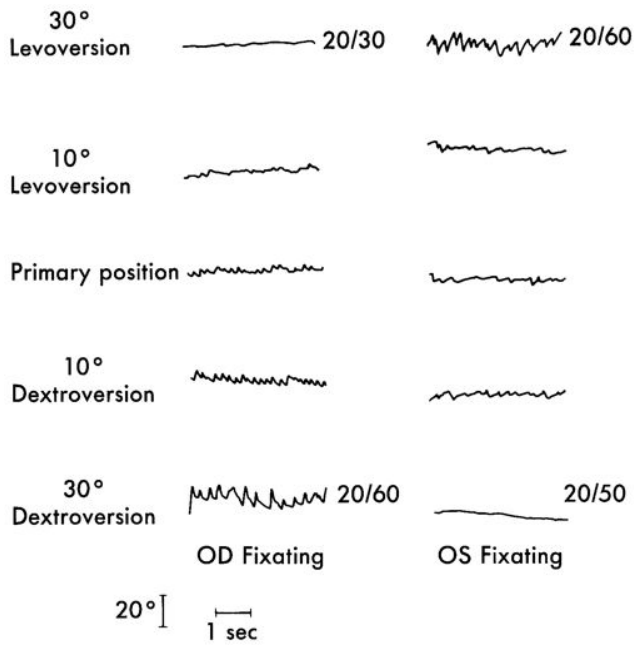


FIGURE 23-8. Monocular electronystagmogram of manifest-latent nystagmus in different gaze positions. Note increase of jerky nystagmus in abduction with fast phase beating toward the side of the fixating eye and improvement of visual acuity with decrease of nystagmus in adduction. (From Noorden GK von, Munoz M, Wong SY: Compensatory mechanisms in congenital nystagmus. *Am J Ophthalmol* 104:387, 1987.)

clinical characteristics are identical, with the exception that in true latent nystagmus there is no nystagmus with both eyes open. As latent, manifest-latent, and manifest nystagmus are all congenital, we prefer to speak of latent and manifest-latent congenital nystagmus as opposed to manifest congenital nystagmus.

In addition to these clearly defined types of nystagmus, mixed forms of congenital nystagmus have been identified.⁴³ These consist of a pendular oscillation superimposed on a decreasing-velocity slow phase jerking nystagmus, and of manifest nystagmus with a superimposed latent compo-

nent.¹⁰⁶ Some patients with manifest nystagmus who develop esotropia may convert from manifest-latent nystagmus while they are esotropic and back to manifest nystagmus when the eyes are aligned.⁵⁰ According to Dell’Osso,⁴³ 80% of congenital nystagmus belongs to manifest, 15% to manifest-latent, and 5% to the mixed variety.

DIFFERENTIATION FROM MANIFEST CONGENITAL NYSTAGMUS. As mentioned previously, it is often difficult or impossible to separate manifest-latent from manifest congenital nystagmus without the advantage of ENG. Yet the pediatric

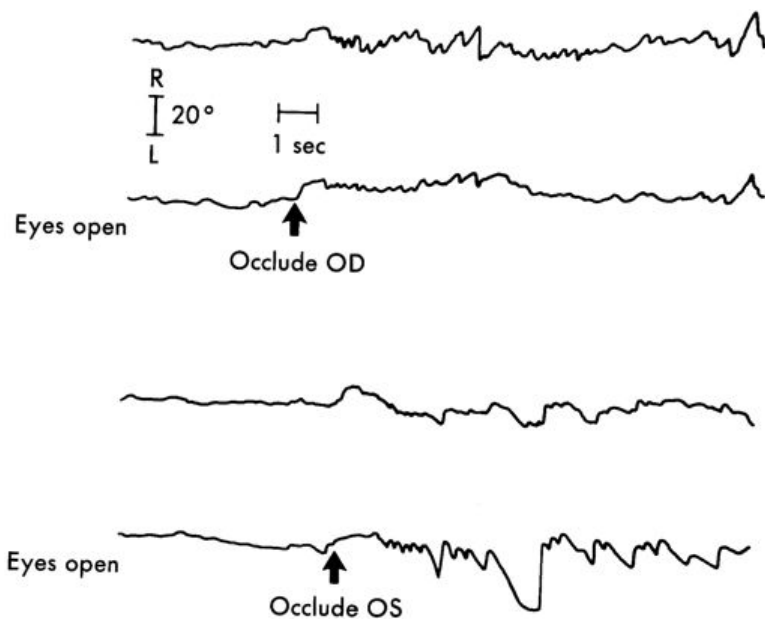


FIGURE 23-9. Binocular nystagmogram of manifest-latent nystagmus. Note that nystagmus does not completely disappear when both eyes are open and increases upon occluding either eye. The manifest phase of the nystagmus escaped careful clinical examination in this patient. (From Noorden GK von, Munoz M, Wong SY: Compensatory mechanisms in congenital nystagmus. *Am J Ophthalmol* 104:387, 1987.)

ophthalmologist is forced to make a diagnosis and surgical decision in the case of a large angle infantile esotropia associated with nystagmus and often accompanied by a severe anomaly of the head position long before a child is old enough to cooperate with ENG. We have found several clinical signs helpful, although by no means as reliable as ENG, to distinguish between manifest and latent or manifest-latent nystagmus in esotropic infants.

A jerking nystagmus that increases markedly upon covering either eye and as the fixating eye moves from adduction into a position of abduction belongs to the *latent or manifest-latent* variety. Such patients should be treated like those with infantile esotropia without nystagmus. Conversely, a variable angle of infantile esotropia, increasing and decreasing inversely proportional with the nystagmus intensity (nystagmus compensation syndrome), in a patient whose nystagmus may be pendular in certain gaze positions, jerking in others, and that does not vary significantly upon covering either eye, is consistent with *manifest nystagmus*.

VISUAL ACUITY. Despite the differences between latent, manifest-latent, and manifest nystagmus, they share one common characteristic: the nystagmus may decrease or even disappear in certain gaze positions and, unless the nystagmus is of the sensory type, visual acuity will improve in this position. The correlation between visual acuity and nystagmus intensity in different gaze positions in a patient with manifest-latent nystagmus is shown in Figure 23–8. Special test methods are required to determine the visual acuity of each eye in patients with latent or manifest-latent nystagmus without evoking or increasing the nystagmus. Such patients commonly may have 6/6 vision with both eyes open and less than 6/60 with either eye occluded. We perform this test by holding a +6.00D to +8.00D sph lens before one eye while the other eye is being tested. The power of this “occluding” lens must be sufficient to blur the test chart but not high enough to completely eliminate formation of images on the retina, since this may elicit nystagmus. Other methods to test visual acuity of each eye while the fellow eye is open include the use of polarized glasses and a polarized projection system (American Optical Vectographic Project-O-Chart Slide), the B-VAT (Mentor) projection device, and other methods of image separation such as the phase difference haploscope.⁷

Finally, true nystagmus must be differentiated from nystagmoid movements in amblyopic eyes. The nystagmoid movements in amblyopic eyes differ from those of congenital nystagmus in that the movements are irregular and searching in character rather than following a regular pendular, jerky, or mixed pattern.¹²⁴

LATENT OR MANIFEST-LATENT NYSTAGMUS AND STRABISMUS.

In contradistinction to manifest congenital nystagmus, which is infrequently associated with esotropia, *patients with latent or manifest-latent congenital nystagmus usually have strabismus*. Dell’Osso⁴³ stated categorically that the presence of strabismus is essential to the diagnosis of latent or manifest-latent nystagmus. Although we have observed and recorded latent nystagmus in several patients who had no strabismus and no history of such, we agree that this is not a common finding.

Ciancia^{22–26} described a group of patients with infantile esotropia, latent nystagmus, a head turn toward the side of the adducting eye, and limited abduction of both eyes. These findings occurred in nearly one third of his patients with infantile esotropia, and the combination of infantile esotropia with latent or manifest-latent nystagmus has become known as the *Ciancia syndrome* (see Chapter 16).

Lang¹⁷ found congenital nystagmus, mostly of the latent type, in as many as 50% of his patients with congenital esotropia. Neither Ciancia nor Lang used ENG to distinguish between manifest-latent and manifest nystagmus. We have diagnosed latent nystagmus without the benefit of ENG in 41 (10%) and manifest nystagmus in 62 (15%) of 409 consecutive children with infantile esotropia treated at our institution during a 10-year period.¹³⁰ If we assume that all those patients with a diagnosis of manifest nystagmus actually had manifest-latent nystagmus, the prevalence of 25% in our population with infantile esotropia is similar to that reported by Ciancia but still much lower than that observed by Lang.

No electromyographic data are available to prove whether the nystagmus in patients with latent or manifest-latent nystagmus is actively dampened by a superimposed adduction innervation, similar to the compensation of manifest congenital nystagmus by convergence or maximal version innervation, or whether adduction represents merely a null zone in which nystagmus innervation ceases. However, one observation not in

accord with a mechanism of active innervational dampening by maximal adduction is that the decrease of nystagmus is not limited to extreme adduction but actually begins before the eye moving from abduction toward adduction reaches the primary position (see Fig. 23–8). If any dampening mechanism is invoked in latent or manifest-latent congenital nystagmus, it is that of binocular visual input, which markedly reduces or even abolishes a nystagmus that occurs when either eye is closed¹⁶¹ (see Fig. 23–9).

It is unknown whether there is a relationship in latent or manifest-latent congenital nystagmus between improved visual acuity in sustained adduction and the esotropia, analogous to the esotropia in the dampening of manifest nystagmus by convergence. Theoretically, such a mechanism is feasible, although no one has, to our knowledge, observed the evolution of esotropia in a patient with manifest-latent congenital nystagmus who initially was orthotropic. It has been shown, however,⁷⁸ that nystagmus dampening by convergence is not limited to manifest nystagmus but occurs also in some (but not all) patients with manifest-latent nystagmus during an increase in visual demands. This finding awaits further substantiation since the recordings presented show a combination of manifest and manifest-latent nystagmus.

Another possible etiologic relationship between infantile esotropia and latent or manifest-latent nystagmus that is unrelated to visual acuity changes in different gaze positions has been proposed by Kommerell,^{109, 110} Kommerell and Mehdorn,¹¹¹ Tyachsen and Lisberger,¹⁷⁸ and Spielmann.¹⁶³ These authors postulated that latent nystagmus is caused by a *persistent asymmetry of the optokinetic and pursuit systems* (Chapter 16) from early binocular disruption. The nasally directed vector of the smooth pursuit system is said to drive the slow phase of the latent nystagmus when the visual input becomes imbalanced (occlusion) in favor of one eye.¹¹⁰ The commonly reported association between unilateral blindness from infancy and latent or manifest-latent nystagmus in the healthy eye that favors a position of adduction is of interest in this connection.^{88, 91, 163} Since no *consistent* correlation between optokinetic asymmetry, infantile esotropia, and latent nystagmus has been established and until it can, this explanation must remain in the realm of hypothesis.

At this time we must conclude that although most patients with latent or manifest-latent con-

genital nystagmus also have infantile esotropia, a causal relationship between these two conditions, although possible, cannot be proved.

A syndrome described independently in 1971 by Ciancia²⁵ and by Haase⁸³ consists of early acquired unilateral severe visual loss or enucleation, esotropia, manifest-latent nystagmus, a preferred fixation preference in adduction, apparently limited abduction, and a face turn toward the side of the fixating eye. Several authors^{85, 91, 115, 161, 163} have subsequently contributed to defining this interesting entity, for which Spielmann¹⁶⁷ coined the term *visuo-motor syndrome of functional monophthalmos*. Among the causes listed by various authors for the unilateral visual impairment are microphthalmos, unilateral congenital cataract, toxoplasma chorioretinitis, high unilateral myopia, persistent hyperplastic primary vitreous, total retinal detachment, retinal folds, or ruptured globe during infancy. Typically, the nystagmus is least pronounced or absent in adduction where visual acuity is optimal, and its intensity increases as the fixating eye abducts. However, the opposite has also been observed where fixation preference was in abduction.⁸³ Ciancia²⁵ felt that the nystagmus in these cases represents the abnormal persistence of a normal prenatal feature, and Spielmann¹⁶³ proposed that unequal visual inputs interfered with normal binocular connections. In view of the frequent finding of a positive family history for strabismus in these cases¹¹⁵ Kushner suggested a genetic predisposition for strabismus in such patients and proposed that the latent nystagmus becomes manifest by the unilateral occlusion effect of the non-seeing or enucleated eye.¹¹⁵ Surgical treatment of the face turn in these cases is most effective and is discussed in the following paragraphs.

Treatment

Treatment of nystagmus is aimed at stabilizing the eyes to improve visual acuity, to decrease oscillopsia, or, in the case of a null zone in a secondary or tertiary gaze position with compensatory head posture, to shift the null zone toward the primary position. In most instances such treatment is limited to patients with manifest nystagmus. However, those with manifest-latent nystagmus and a head turn toward the side of the fixating eye may also benefit from therapy.

Therapy to decrease the nystagmus intensity is worth considering in patients with a motor-type

nystagmus, congenital or acquired. There should be some evidence before instituting therapy that improved stabilization of the eyes will have a beneficial effect on visual acuity or oscillopsia.

Medical Treatment

DRUGS. Systemic treatment in the form of alcohol,¹³⁸ tranquilizers,¹¹⁹ phenobarbital,^{71, 118} and baclofen¹⁸⁴ has been advocated to treat congenital nystagmus, and improvement of visual acuity has been reported in some instances. However, because of their side effects, prolonged treatment with any of these medications has not become popular. Crone and coworkers³⁵ injected *botulinum toxin, type A* in the horizontal recti muscles of patients with acquired nystagmus. Helveston and Pogrebniak⁸⁹ injected botulinum A toxin (Oculinum) into the retrobulbar space of two patients with acquired nystagmus and severe oscillopsia and reduced visual acuity. Nystagmus and visual acuity improved after the injection, but the injection had to be repeated at intervals of 1 to 3 months. Other authors have confirmed the beneficial though only temporary effect of this treatment.^{20, 120, 145, 149} Side effects such as symptomatic diplopia may limit the utilization of this form of treatment.¹⁷⁷

Botulinum toxin has been injected into the medial rectus muscle of patients with latent nystagmus.¹²³ This treatment either improved temporarily the face turn toward the fixating eye and convinced the patient of the necessity of surgery, or decreased a latent nystagmus that may have become manifest because of loss of visual acuity of one eye.

GLASSES AND CONTACT LENSES. Every effort should be made to correct any underlying refractive errors. We have observed on many occasions a dramatic decrease of the nystagmus once a patient's refractive error was corrected. Retinoscopy may be difficult to perform accurately when the nystagmus amplitude is large and should be performed with the eyes in the null zone if such is present. Contact lenses are helpful, especially in high myopes. Contact lenses have the optical advantage of moving synchronously with the eyes so that the visual axis coincides with the optical center of the lens at all times. Good results from treating nystagmic children with soft contact lenses have been reported.¹²⁵ In addition to the improvement in visual acuity, there is some kind

of tactile feedback from the contact lens that decreases the nystagmus and to which Dell'Osso and coworkers⁵⁸ have drawn attention.

MINUS LENSES. Overcorrection with minus lenses stimulates accommodative convergence and may improve visual acuity at distance fixation by nystagmus dampening.⁴²

PRISMS. Prisms are used for two purposes in the treatment of nystagmus: (1) to improve visual acuity and (2) to eliminate an anomalous head posture. In the first instance, prisms base-out are prescribed to stimulate fusional convergence, which may be effective in decreasing the amplitude of nystagmus and thus improving visual acuity.^{5, 126} Dell'Osso and coworkers⁵¹ pointed out that the dampening of nystagmus elicited by prisms base-out allows "clear vision at a glance," removing the necessity for increased visual concentration and thereby avoiding intensification of the nystagmus resulting from that heightened fixation.

Normal binocular vision is a prerequisite of the use of prisms base-out since fusional convergence in response to prism-induced temporal retinal disparity cannot be expected in patients without fusion. In spite of strong advocacy for this therapy by a few authors, there is a conspicuous paucity of well-documented studies in the literature regarding long-term success. We have found this treatment effective in only a few isolated instances. In many patients the disadvantages of prisms outweighed the modest visual benefit gained.

The second application of prisms may be in the preoperative evaluation or nonsurgical therapy of a patient with head turn resulting from concordant nystagmus. The prisms are inserted with the base opposite the preferred direction of gaze. For instance, with a head turn to the left, the null zone is in dextroversion, and a prism base-in before the right eye and base-out before the left eye will correct the head turn. Likewise, a compensatory chin elevation caused by a null zone in deorsumversion will be improved with prisms base-up before each eye. A combination of vertical and horizontal prisms is advocated by Godd -Jolly and Larmande^{74, p.668} when the null zone is in an oblique position of gaze. Thus the results of surgery for head turn in nystagmus can be reasonably well predicted on the basis of the patient's response to prisms, and a postoperative residual head turn may be alleviated further with prisms.^{3; 74, p.673} The optical disadvantages of prisms of suf-

ficient power to eliminate even a moderate head turn of, say, 20° are significant. For this reason we have been disappointed with the effectiveness of long-term prismatic therapy of compensatory head postures in patients with congenital nystagmus. In the long-term treatment of compensatory head postures we have found surgery on the extraocular muscles to be the most effective therapy.

OTHER FORMS OF TREATMENT. *Acupuncture*, consisting of the insertion of needles into the sternocleidomastoid muscle, has been shown to improve foveation characteristics in congenital nystagmus on a temporary basis.¹⁷ *Biofeedback* has been mentioned as a treatment for nystagmus. These putative therapies must be considered placebos until proved otherwise with randomized controlled trials.^{65, 144}

Surgical Treatment

Surgical treatment directed at *manifest* congenital nystagmus may be considered for two different reasons: (1) to eliminate a compensatory head posture that may be cosmetically disturbing or that may cause neck strain or other physical discomfort by shifting the null point from a peripheral gaze position to the primary position or (2) to decrease nystagmus amplitude, or for both reasons. Surgery directed at *manifest-latent* nystagmus is rarely indicated, but it has been reported that strabismus surgery may convert manifest-latent nystagmus to latent nystagmus, causing improvement of binocular visual acuity.¹⁸⁷

SHIFTING THE NULL POINT. When considering shifting the null point surgically, it is easy to remember that *the eyes should always be shifted in the direction of the anomalous head posture*, that is, to the left when there is a head turn to the left, down when the chin is depressed, or to the left around the visual axis in the case of a head tilt toward the left shoulder. A head turn or tilt of less than 15° to 20° is rarely of cosmetic or functional significance, but for a larger anomalous head posture a surgical indication may exist.

Before deciding which surgical approach is the most appropriate, one should ascertain beyond doubt by repeated examinations that the direction of the null zone and thus of the head turn is consistent. We have had several patients referred to us for nystagmus surgery in whom the null zone (and the head turn) changed directions (PAN or bidirectional null point nystagmus) during re-

peated office examinations. For obvious reasons, a Kestenbaum operation or one of its modifications is contraindicated in such patients and a different surgical approach becomes necessary for PAN.

FACE TURN. Among the various compensatory head postures caused by nystagmus, a face turn to the right or left is most commonly encountered, and several surgical approaches have been advocated to shift the null zone of nystagmus into the primary position. Kestenbaum¹⁰⁵ is credited with being the first to report the surgical technique that now bears his name. For a face turn to the left, he recessed the right lateral rectus muscle and resected the right medial rectus muscle, and in a second operation, he recessed the left medial rectus muscle and resected the left lateral rectus muscle. Kestenbaum advocated performing an equal amount of surgery (5 mm) on all four rectus muscles. Anderson,⁴ who reported his method in the same year as Kestenbaum and thus should share the credit for originating this type of procedure, recessed the yoke muscles in each eye 4 to 5 mm. For instance, for a face turn to the left, he recessed the right lateral and left medial rectus muscles. Since publication of these two classic papers, numerous modifications of horizontal rectus operations have been reported, and, following the same principle, the vertical rectus or oblique muscles have been operated on for chin depression, chin elevation, and head tilt to either shoulder.

Most current authors recommend an operation on all four rectus muscles for a compensatory face turn, provided the nystagmus is not associated with strabismus. The amount of surgery to be performed is not agreed on by various authors. Cooper and Sandall³² determine the degree of face turn, double this figure to convert it to prism diopters, and then perform an appropriate amount of recession and resection. Parks,¹⁴⁰ taking into account that the effects of a recession and resection may differ, depending on whether it is performed on a medial or lateral rectus muscle, and that an equal amount of recession and resection do not give the same results, arrived at the following recommendations, which we have found to be useful: 5-mm recession of the medial rectus muscle, 6-mm resection of the medial rectus muscle, 7-mm recession of the lateral rectus muscle, and 8-mm resection of the lateral rectus muscle. Thus in a patient with a face turn to the left and a conjugate deviation of the eyes to the right, the following operation is performed: 7-mm recession

of the right lateral rectus muscle, 6-mm resection of the right medial rectus muscle, 5-mm recession of the left medial rectus muscle, and 8-mm resection of the left lateral rectus muscle. Calhoun and Harley¹⁸ perform an additional 2-mm recession and resection on each muscle, and Pratt-Johnson¹⁴² recommends 10-mm recessions and resections. Spielmann¹⁵⁸⁻¹⁶⁰ adds posterior fixation sutures to the recessions in such cases and has contributed many other valuable modifications to nystagmus surgery, especially when the nystagmus is associated with strabismus.

It seems reasonable to adjust the amount of surgery to the degree of face turn rather than use a rigid dosage scheme for all patients. We have used the dosage scheme suggested by Parks¹⁴⁰ if the face turn does not exceed 30° and add 1 to 2 mm to each recession and resection in larger-degree face turns. In the presence of strabismus the dosage of surgery performed on each muscle operation must be modified to correct the strabismus in addition to the face turn.

In the case of amblyopia, surgery should be confined to the fixating eye and followed, if necessary, by a second operation on the nonfixating eye. The compensatory face turn in patients with *unilateral visual loss* early in life (see above) who develop manifest-latent nystagmus with a face turn toward the side of the seeing eye responds well to moving that eye from adduction toward the primary position by recessing the medial and resecting the lateral rectus muscles. Surgery on the non-seeing eye in such cases will have no effect on the face turn.

The results of surgery directed at shifting the position of the eyes, and thus eliminating the face turn, have been satisfactory. A return of the anomalous head posture has been reported,^{16, 18, 62} but most authors agree that the null zone can be shifted successfully toward the primary position.^{2, 13, 16, 33, 46, 61, 95, 108, 139, 142, 143, 150, 152, 159} Certainly, that has also been our experience.¹⁶ Of 18 patients, 12 had a normal head position, 2 had a residual but cosmetically satisfactory head position between 5° and 15°, and 4 had a residual head turn in excess of 15° after an average follow-up of 52 months. Our surgical results were less predictable with a coexisting manifest strabismus. Overcorrection with reversal of the face turn to the opposite side is, as a rule, temporary and will disappear with time.

It is amazing that the Kestenbaum-Anderson procedure with its rather unconventional and un-

equal amounts of surgery on all four rectus muscles does not compromise binocular functions in those with intact binocular vision before surgery.³⁴ Except for the occasional complaint of temporary diplopia during the immediate postoperative phase, we have not seen a permanently disabling misalignment of the eyes after the Kestenbaum-Anderson operation in a formerly fusing patient.

When maximal recessions and resections have been performed on all four horizontal rectus muscles, the choice of what to do next in case of an undercorrection or recurrence of a face turn is not an easy one. To avoid this dilemma, we have for the last several years used an *enhanced Anderson operation* in lieu of the Kestenbaum procedure. This modification was advocated by de Decker³⁹ and consists of recessing yoke muscles as much as 10 to 12 mm, rather than the 4 to 5 mm suggested by Anderson.⁴ Since a recession is more effective when performed on the medial than on the lateral rectus muscle, the medial rectus is recessed 2 mm less than the lateral rectus muscle. For example, in the absence of strabismus and a face turn to the left, the right lateral rectus muscle is recessed 12 mm and the left medial rectus muscle is recessed 10 mm. The amount of surgery may be modified to correct an underlying horizontal strabismus. The limitation of dextroversion after this operation is not greater than the limitation of lateroversion seen after a Kestenbaum operation on all four rectus muscles. The medium-term results with this modification have been excellent, and the advantage of having two "spare" horizontal rectus muscles available if additional surgery is needed in the future should not be underestimated.

In a study of the effect of large recessions of all four horizontal muscles to decrease nystagmus amplitude in certain types of manifest congenital nystagmus (see below), one of us (G.K.v.N.) reported that this surgery also had a beneficial effect on *alternating face turn* in a patient with *periodic alternating nystagmus*.¹³⁶ Other authors confirmed this observation in a subsequent study of five patients with PAN and noted also a modest improvement of postoperative visual acuity.⁷⁹ After further study this operation may well emerge as a safe and effective treatment for a condition previously thought to be untreatable.

CHIN ELEVATION OR DEPRESSION. A null zone with the eyes in depression or elevation will cause chin elevation or depression. This type of compensatory head posture occurs much less fre-

quently than a face turn. For chin elevation of 25° or more, Parks¹⁴⁰ recommended a 4-mm resection of both superior rectus muscles and a 4-mm recession of both inferior rectus muscles, and for chin depression of at least 25°, a 4-mm recession of both superior rectus muscles and a 4-mm resection of both inferior rectus muscles. When chin elevation or depression is less than 25°, the operation is limited to a 4-mm recession of both depressors or elevators without resection of their antagonists. In our experience the dosage of surgery must be increased to at least 5 to 6 mm or even more to be successful. This has also been the conclusion of other authors.⁹⁷

It has also been suggested to treat chin elevation with bilateral recessions of the inferior rectus muscles combined with bilateral recession of the superior oblique muscles.^{75, 141} Chin depression has been treated with bilateral recessions of the superior rectus muscles combined with a bilateral anterior transposition of the inferior oblique muscles.¹⁴⁷ Both procedures harbor the potential complication of iatrogenic cyclotropia and it has yet to be shown that they are more effective than surgery on the two pairs of vertical rectus muscles. For these reasons we prefer the classic approach outlined in the preceding paragraph.

Schiavi and coworkers¹⁵¹ used the same strategies employed for treatment of congenital nystagmus with a null zone in a vertical or horizontal gaze position to treat patients with *supranuclear gaze palsies* and those with *acquired nystagmus and oscillopsia* that improved or was eliminated in a gaze position other than the primary position. Spielmann¹⁶⁶ has used a similar approach successfully.

HEAD TILT. A special surgical challenge exists in patients with a head tilt toward either shoulder that is unrelated to paralysis of one of the cyclovertical muscles. Such head tilts often, but not always, correspond to the null zone of the nystagmus.¹³⁵ Visual acuity is, as a rule, optimal with the head in its abnormal position and decreases when the head is passively straightened. The nystagmus may be of such small amplitude that it may be difficult to detect on clinical examination. Fundus examination with a direct ophthalmoscope containing a fixation target (see p. 264) may demonstrate micronystagmus in such cases with decreased intensity in the habitual head position.

Conrad and de Decker^{30, 31} and de Decker and Conrad,⁴¹ in following Kestenbaum's principle to rotate the head in the direction of the abnormal

head posture, suggested rotating both eyes around the sagittal axis toward the shoulder to which the head is tilted. This is accomplished by operating on the insertions of all four oblique muscles. To maintain alignment of the visual horizon, which will be slanted after this operation, the patient is forced to straighten the head. For instance, if a patient has a head tilt to the right shoulder, the right eye is surgically excycloducted and the left eye incycloducted. This is accomplished in the right eye by recessing the anterior and retropositioning the posterior aspect of the superior oblique tendon and advancing the anterior and anteropositioning the posterior aspect of the inferior oblique tendon. In the left eye the anterior portion of the superior oblique tendon is advanced and the posterior edge anteropositioned and the anterior part of the inferior oblique insertion is recessed and its posterior portion retroplaced. This rather complicated operation has been reported to induce a cyclorotation of the globes of 10° to 15°.

A simpler approach, also suggested by de Decker,⁴⁰ consists of vertical transposition of the horizontal rectus muscles. For example, to cause excycloduction of the right eye the right medial rectus muscle is transposed downward and the right lateral rectus muscle upward. Spielmann¹⁶² advocated slanting the insertions of all four rectus muscles. With a head turn to the right, for instance, the right eye is excycloducted by recessing the temporal part of the superior rectus, the inferior part of the lateral, the nasal part of the inferior, and the superior part of the medial rectus insertions. In the left eye the slanting occurs in the opposite direction; for instance, the nasal edge of the superior rectus is recessed, and so on. Special care must be taken to preserve sufficient blood supply to the anterior segment through that part of the tendon that remains attached to the insertion.

We prefer to transpose the vertical rectus muscles horizontally in such cases.¹³⁵ For example, with a head tilt to the right the right eye is excyclotorted and the left eye incyclotorted. This is accomplished by transposing the right superior rectus muscle nasally, the right inferior rectus muscle temporally, the left superior rectus muscle temporally, and the left inferior rectus muscle nasally. The muscle insertions are transposed one full muscle width, and the nasal and temporal aspects of the tendon are reinserted at the same distance from the limbus as was measured prior to their disinsertion. Surgery is always performed

on both eyes when no fixation preference exists, but it works equally well¹³⁵ when performed on the fixating eye in patients who do have such a preference. The usual precautions regarding the blood supply to the anterior segment are in order. In adult patients, when previous surgery has been performed on the horizontal rectus muscles, it would be our choice to transpose the horizontal muscles vertically, as advocated by de Decker,⁴⁰ rather than operate on the vertical rectus muscles. Healthy children seem to tolerate the procedure well, but a waiting period of at least 6 months between horizontal and vertical muscle surgery is advisable. Case 23-3, previously published,¹³⁵ illustrates the effectiveness of horizontal transposition of the vertical rectus muscles.

CASE 23-3

A 9-year-old boy presented with a history of nystagmus since infancy. He presented with neck strain and a head tilt of 25° to the right shoulder (Fig. 23-10A). With the head in this position his best corrected binocularly tested visual acuity was 6/12, which decreased to 6/15 when straightening the head passively, and decreased further to 6/60 when the head was tilted to the left shoulder. His refractive error was OD +5.50D sph; OS +6.00D sph. Orthotropia was present at near and distance fixation and the child had 120° of arc stereopsis with the TNO random-dot test. A manifest nystagmus with low amplitude and high frequency was present

and noted to decrease when the head was tilted to the right. To rotate the eyes in the direction of the head tilt we transposed the insertion of the right superior rectus muscle nasally, of the right inferior rectus muscle temporally, of the left superior rectus muscle temporally, and of the left inferior rectus muscle nasally. Postoperatively, the head position normalized (Fig. 23-10B) and visual acuity improved to 6/12. Postoperative fundus photographs show the surgically induced excyclotorsion of the right eye and incyclotorsion of the left eye (Fig. 23-11). The child has been followed for 3 years and the postoperative improvement has persisted.

We prefer to delay surgery for an anomalous head posture caused by manifest nystagmus until a child is at least 4 years old. Repeated visits and evaluations are advisable to establish the direction, constancy, and degree of the anomalous head posture. Some of this information is often difficult to obtain reliably in younger children.

NYSTAGMUS DAMPENING (BLOCKAGE) SYNDROME. Indications for surgery exist when the esodeviation is constant. Of various surgical approaches, we have found a recession of both medial rectus muscles, which may be combined with posterior fixation sutures, to be more effective than the recession-resection operation originally advocated by Adelstein and Cüppers.³ In comparing the surgical results in these patients with a group of essential infantile esotropes without nystagmus who had also undergone surgery, we found more undercorrections and, especially, overcorrec-




FIGURE 23-10. Case 23-3. Preoperative (A) and postoperative (B) head posture. (From Noorden GK von, Jenkins R, Rosenbaum A: Horizontal transposition of the vertical rectus muscles for treatment of ocular torticollis. *J Pediatr Ophthalmol Strabismus* 30:8, 1993.)

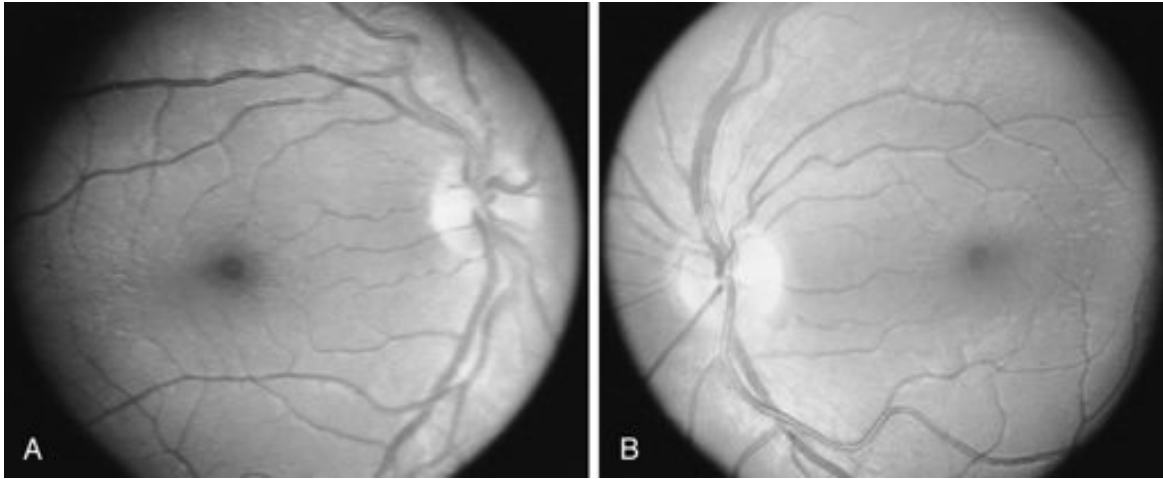


FIGURE 23-11. Case 23-3. Surgically induced excycloduction of the right eye (A) and incycloduction of the left eye (B). (From Noorden GK von, Jenkins R, Rosenbaum A: Horizontal transposition of the vertical rectus muscles for treatment of ocular torticollis. *J Pediatr Ophthalmol Strabismus* 30:8, 1993.)

tions and a higher prevalence of reoperations in patients with the nystagmus dampening syndrome.¹³⁴

DECREASING NYSTAGMUS INTENSITY. Attempts have been made since the beginning of the twentieth century to decrease nystagmus by stabilizing the eyes surgically. Of historical interest only are methods that use fixation of the lateral rectus muscles to the periosteum of the lateral orbital wall²⁹ (see also Friede,⁶⁹ Harada and co-workers⁸⁷) and the complex muscle transposition procedures of Blatt.¹⁵ Keeney and Roseman¹⁰¹ suggested a tenotomy of all four vertical recti to decrease oscillopsia in acquired vertical nystagmus. A device featuring electronically controlled motor-driven prisms oscillates the visual environment in lockstep with the nystagmus and caused a decrease of oscillopsia and an increase of visual acuity in four out of five patients with acquired pendular nystagmus.¹⁷⁵

ARTIFICIAL DIVERGENCE. Several authors have proposed stabilizing the eyes by surgically induced convergence innervation.^{19, 36, 100, 188} First, prisms of up to 40^Δ base-out are prescribed, which induces artificial divergence. If the resulting exodeviation is overcome by fusional convergence, and visual acuity improves under the nystagmus-dampening influence of convergence innervation, an artificial exodeviation is then created by recessing the medial rectus muscle and resecting the lateral rectus muscle of one eye. The convergence effort necessary to keep the eyes aligned after surgery is said to decrease the nystagmus and to improve visual acuity.

This approach has been endorsed by Spielmann^{160, 168, 170} who, with Lavlan,¹⁷¹ has published what is thus far the most extensive study, comprising 75 cases with surgically induced artificial divergence. Spielmann prefers 5- to 12-mm recessions of the medial rectus muscles. A preoperative prism adaptation test determines the amount of surgery, which is calculated according to the power of the prism base-out that is necessary to dampen the nystagmus at distance fixation without inducing diplopia. Postoperative visual acuity improved from one to three lines in 26% of the cases. Nine patients developed a consecutive exotropia, and hypermetropia appeared to be a predisposing factor for this complication.

It must be emphasized that this operation should be considered only in patients with an intact vergence system, normal fusion, and otherwise normal binocular functions. If this advice is ignored, consecutive exotropia and diplopia will result from artificial divergence. This treatment has recently been proposed for patients with manifest nystagmus secondary to achromatopsia to improve visual acuity at distance.⁸⁶ Because of the impaired fusional capabilities of such patients with low vision, the risk of postoperative diplopia is increased.

We consider artificial divergence surgery only if prismatically (base-out prisms) induced nystagmus dampening improves visual acuity at distance fixation. We have found only a few cases that have met this criterion, but one of us (E.C.) has used artificial divergence surgery successfully for the last 12 years to treat alternating head turn, secondary to a bidirectional null nystagmus.^{19, 21}

MAXIMAL RECESSON OF ALL HORIZONTAL RECTUS MUSCLES. Weakening the function of all horizontal rectus muscles by applying posterior fixation sutures behind the equator to decrease horizontal nystagmus has been advocated,^{6, 12} but the results have been disappointing in our experience and that of Spielmann.¹⁵⁸ More effective are unconventionally large (10 to 12 mm) recessions of all four horizontal rectus muscles. This approach was first reported and documented by ENG in 1960 by Bietti and Bagolini.¹³ However, it did not gain much popularity, probably because its publication in a rather obscure journal failed to attract the attention of strabismologists. The operation was then independently described and resurrected in 1986 by Emma Limon of Mexico.¹²¹ It was mentioned and illustrated by a case report in the fourth edition (1990) of this book, and despite the initially sceptical reception of this operation by leading strabismologists,⁶⁶ subsequent reports have confirmed its value.^{8, 38, 81, 90, 122, 133, 164, 169}

Certain precautions with regard to the indications are in order. Although the cosmetic improvement is unquestionable and the rate of patient satisfaction uniformly high, the patient must clearly understand that surgery will not eliminate the nystagmus but will only decrease its amplitude. Although many patients report that they can see better after surgery, and some have acuity improvement of two or more lines on the Snellen chart,³⁸ this improvement is not always reflected in improved measurable visual acuity. If such occurs at all, as a rule it is of modest degree and limited to near vision. The amelioration of visual acuity is often described by the patient as a decrease in the time it takes to recognize an object, for instance reading a sign from a moving automobile. This suggested to us that the operation prolongs foveation time and thus the recognition time. That this is indeed so has been proved experimentally by Sprunger and coworkers.¹⁷³

Contrary to our initial concern that such unconventionally large recessions may cause significant limitations of ocular motility, this is not the case because the weakening effect of one muscle is balanced by similarly weakening the action of its opponent: the balance of forces remains undisturbed. The minimal restriction of motility in adduction and abduction we have observed after surgery in some but not all patients was of no functional significance.

However, 4 of 21 patients operated on by us with equal amounts of recession (10 to 12 mm)

on medial and lateral rectus muscles eventually developed a consecutive exotropia. This complication responded well to a 3-mm advancement of the medial rectus muscles, which confirms the commonly held view that a recession is more effective when performed on the medial rectus than on the lateral rectus muscle. After this experience (confirmed by Helveston, personal communication, 1994) we now advocate that the medial rectus muscle be recessed 2 mm less than the lateral rectus muscle. In the presence of strabismus or a face turn, the amount of recession performed on each horizontal rectus muscle may be varied to decrease nystagmus amplitude in addition to aligning the eyes or shifting the null zone.

Case 23-4 shows the beneficial effect of maximal rectus recessions in one of our patients.

CASE 23-4

A 16-year-old girl presented with complaints of poor vision and cosmetic embarrassment caused by her nystagmus. She had been diagnosed elsewhere as having oculocutaneous albinism. On examination her best corrected visual acuity at distance fixation was OD 6/60, OS 6/30, and OU 6/30. Her near vision was OU 6/15. She was orthotropic at near and distance fixation and had no stereopsis on the TNO test. Her fundi were lightly pigmented. She had a manifest, largely pendular nystagmus (Fig. 23-12A). In January 1987 she underwent a 10-mm recession of all four horizontal rectus muscles. Visual acuity at distance 18 months later had improved to OD 6/30, to OS 6/21, and at near to 6/12. An ENG performed before and 6 years after surgery showed marked decrease of the nystagmus in all gaze positions (Fig. 23-12B). Her distance visual acuity remained unchanged during several years of postoperative observation but her near vision improved further to 6/9. This patient had noted a marked improvement in her ability to function visually (seeing the blackboard, shooting) and was delighted with the cosmetic improvement since her nystagmus was now only barely noticeable. She has remained orthotropic and except for a minimal limitation of adduction in both eyes the excursions of her eyes were virtually unchanged by the operation (Fig. 23-13).

The therapeutic potential of this operation in patients with PAN has been mentioned earlier.

Dell'Osso and coworkers⁵² reported improvement of nystagmus in one achiasmatic Belgian sheepdog after performing a tenotomy of all four horizontal rectus muscles, followed by their immediate reattachment at the original scleral posi-

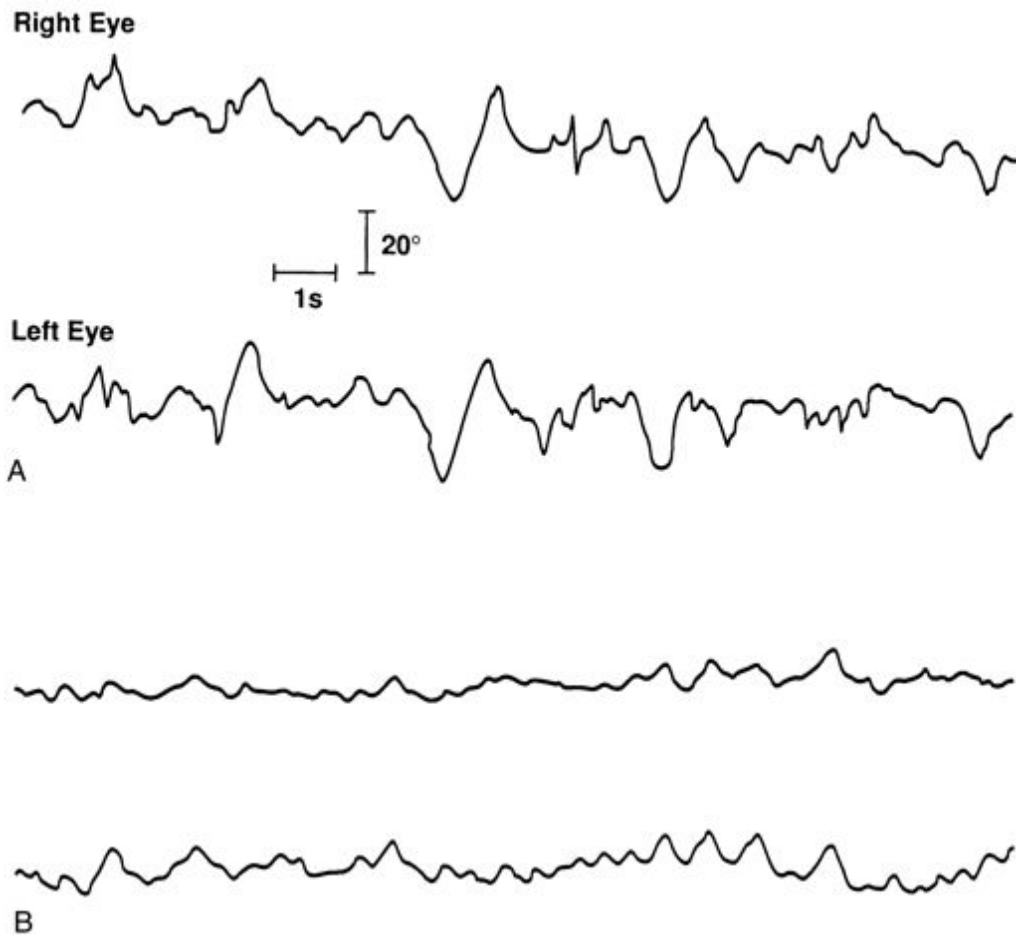


FIGURE 23-12. Case 23-4. Monocular electronystagmograms before (A) and 6 years after (B) 10-mm recessions of the horizontal recti in both eyes. Note improvement of nystagmus.

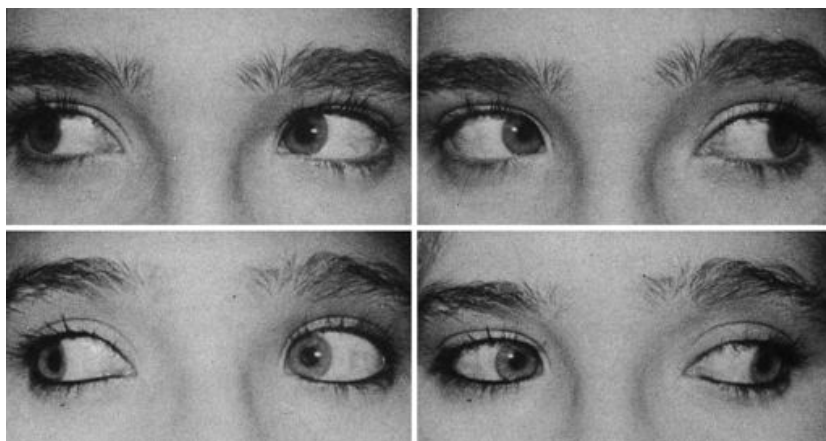


FIGURE 23-13. Case 23-4. Preoperative (above) and postoperative (below) lateroversion. Note minimal limitation of adduction and no effect on abduction despite unconventionally large recessions of all horizontal rectus muscles.

tions. This singularly odd operation, which has a null effect on eye muscle force and eye position, presumably works by interrupting proprioceptive afference from the extraocular muscles. Dell'Osso has suggested that this approach be used also in humans in lieu of recessing the muscles maximally, but no data have been presented to show the benefits of this approach at the time this edition was prepared.

REFERENCES

- Abadi RV, Pascal E: Periodic alternating nystagmus in humans with albinism. *Invest Ophthalmol Vis Sci* 35:4080, 1994.
- Abadi RV, Whittle J: Surgery and compensatory head postures in congenital nystagmus. *Arch Ophthalmol* 110:632, 1992.
- Adelstein FE, Cüppers C: Zum Problem der echten und der scheinbaren Abducenslähmung (das sogenannte "Blockierungssyndrom"). In *Augenmuskellähmungen*. Bücherei Augenarzt 46:271, 1966.
- Anderson JR: Causes and treatment of congenital eccentric nystagmus. *Br J Ophthalmol* 37:267, 1953.
- Arruga A: Aplicaciones de los prismas membranosos en terapeutica estrabologica. *Arch Soc Esp Oftalmol* 31:381-402, 1971.
- Arruga A: Posterior suture of rectus muscles in retinal detachment with nystagmus: A preliminary report. *J Pediatr Ophthalmol* 11:36, 1974.
- Arruga A: ESA terminology. In Arruga A, Bérard PV, Campos E, et al, eds: *Strabismus Terminology*. Lausanne, European Strabismological Association, 1985.
- Attila H, Erkam N, Isikcelik Y: Surgical treatment in nystagmus. *Eye* 13:11, 1999.
- Bagolini B, Campos E, Fonda S, et al: Active blockage and rest position nystagmus. Electromyographic demonstration of two types of ocular induced head-turn. *Doc Ophthalmol* 62:149, 1986.
- Bagolini B, Penne A, Zanasi MR: Ocular nystagmus: Some interpretational aspects and methods of treatment. *Int Ophthalmol* 6:37, 1983.
- Bedell HE, Currie DC: Extraretinal signals for congenital nystagmus. *Invest Ophthalmol Vis Sci* 34:2325, 1993.
- Bedell HE, Flom MC: Bilateral oculomotor abnormalities in strabismic amblyopes: Evidence for a common central mechanism. *Doc Ophthalmol* 59:309, 1985.
- Bietti GB, Bagolini B: Traitement médicochirurgical du nystagmus. *Annee Ther Clin Ophthalmol* 11:268, 1960.
- Blair CJ, Goldberg MF, Noorden GK von: Voluntary nystagmus: Electro-oculographic findings in four cases. *Arch Ophthalmol* 77:349-354, 1967.
- Blatt N: Kreuzung der geraden Augenmuskeln als Methode der Nystagmusoperation. *Ber Dtsch Ophthalmol Ges* 63:393, 1960.
- Bleik J, Noorden GK von: Surgical treatment of compensatory head posture in asymmetric gaze nystagmus. *Saudi J Ophthalmol* 6:15, 1992.
- Blekher T, Yamada T, Yee RD, Abel LA: Effects of acupuncture on foveation characteristics in congenital nystagmus. *Br J Ophthalmol* 82:115, 1998.
- Calhoun JH, Harley RD: Surgery for abnormal head position in congenital nystagmus. *Trans Am Ophthalmol Soc* 71:70, 1973.
- Campos EC, Schiavi C: L'intervento di "divergenza artificiale" nella terapia chirurgica del torcicollo da nistagmo. In *Proceedings of the Fourth National Congress of Pediatric Ophthalmology*. Florence, OIC Medical Press, 1987, p 101.
- Carruthers J: The treatment of congenital nystagmus with Botox. *J Pediatr Ophthalmol Strabismus* 32:306, 1995.
- Chiesi C, Schiavi C, Campos EC: Esperienze personali con la moderna chirurgia del nistagmo. *Boll Ocul* 70 (suppl 4):357, 1991.
- Ciancia AO: La esotropia en el lactante, diagnóstico y tratamiento. *Arch Chil Oftalmol* 19:117, 1962.
- Ciancia AO: La esotropia con limitación bilateral de la abducción en el lactante. *Arch Oftalmol B Aires* 37:207, 1962.
- Ciancia AO: Management of esodeviations under the age of two. *Int Ophthalmol Clin* 6:503, 1966.
- Ciancia AO: Early esotropia. *Int Ophthalmol Clin* 4:81-87, 1971.
- Ciancia AO, Melek N, Garcia H: Los movimientos de sacudida, fijación y persecución en los estrabismos no paralyticos. *Rev Arch Oftalmol B Aires* 51:73, 1976.
- Cogan DG: Nystagmus. In Haik GH, ed: *Strabismus*. Symposium of the New Orleans Academy of Ophthalmology. St Louis, Mosby-Year Book, 1962, p 119.
- Cogan DG: Congenital nystagmus. *Can J Ophthalmol* 2:4, 1967.
- Colburn EJ: Fixation of the external rectus muscle in nystagmus and paralysis. *Am J Ophthalmol* 23:85, 1906.
- Conrad HG, Decker W de: "Rotatorischer Kestenbaum"—Umlagerungschirurgie bei Kopfwangshaltung zur Schuler. *Klin Monatsbl Augenheilkd* 173:681, 1978.
- Conrad HG, Decker W de: Torsional Kestenbaum procedure: Evolution of a surgical concept. In Reinecke RD, ed: *Strabismus II*. Orlando, FL, Grune & Stratton, 1982, p 301.
- Cooper EL, Sandall GS: Surgical treatment of congenital nystagmus. *Arch Ophthalmol* 81:473, 1969.
- Crone RA: The operative treatment of nystagmus. *Ophthalmologica* 163:15, 1971.
- Crone RA: Orthophorisation. Die binokulare Augenstellung nach Kestenbaumscher Operation. *Klin Monatsbl Augenheilkd* 175:348, 1979.
- Crone RA, de Long PT, Notermans G: Behandlung des Nystagmus durch Injektion von Botulintoxin in die Augenmuskeln. *Klin Monatsbl Augenheilkd* 184:216, 1984.
- Cüppers C: Probleme der operativen Therapie des okulären Nystagmus. *Klin Monatsbl Augenheilkd* 159:145, 1971.
- Daroff RB: Summary of clinical presentations. In Lennerstrand G, Bach-y-Rita P, eds: *Basic Mechanisms of Ocular Motility and Their Clinical Implications*. New York, Pergamon Press, 1975, p 441.
- Davis PL, Baker RS, Piccione RJ: Large recession nystagmus surgery in albinos: Effect on acuity. *J Pediatr Ophthalmol Strabismus* 34:279, 1997.
- Decker W de: Kestenbaum transposition in nystagmus therapy. Transposition in horizontal and torsional plane. *Bull Soc Belge Ophthalmol* 221-222:107, 1987.
- Decker W de: Rotatorischer Kestenbaum an geraden Augenmuskeln. *Z Prakt Augenheilkd* 11:111, 1990.
- Decker W de, Conrad HG: Torsionale Umlagerung, Rüstzeug bei komplettem frühkindlichen Schielsyndrom. *Klin Monatsbl Augenheilkd* 193:615, 1988.
- Dell'Osso LF: Improving visual acuity in congenital nystagmus. In Smith JL, Glaser J, eds: *Neuroophthalmology*, vol 7. St Louis, Mosby-Year Book, 1973, p 98.
- Dell'Osso LF: Congenital, latent or manifest latent nystagmus. Similarities, difference and relation to strabismus. *Jpn J Ophthalmol* 29:351, 1985.
- Dell'Osso LF, Daroff RB: Congenital nystagmus waveforms and foveation strategy. *Doc Ophthalmol* 39:155, 1975.

45. Dell'Osso LF, Daroff RB: Achromatopsia and congenital nystagmus. *J Clin Neuro Ophthalmol* 3:152, 1983.
46. Dell'Osso LF, Flynn JT: Congenital nystagmus surgery: A quantitative evaluation of the effects. *Arch Ophthalmol* 97:462, 1979.
47. Dell'Osso LF, Leigh RJ: Ocular motor stability of foveation periods. *Neuro Ophthalmol* 12:303, 1992.
48. Dell'Osso LF, Abel A, Daroff RB: Latent/manifest latent nystagmus reversal using an ocular prosthesis. *Invest Ophthalmol Vis Sci* 28:1973, 1987.
49. Dell'Osso LF, Averbuch-Heller L, Leigh RJ: Oscillopsia suppression and foveation-period variation in congenital, latent, and acquired nystagmus. *Neuro Ophthalmol* 18:163, 1997.
50. Dell'Osso LF, Ellenberger C, Abel LA, Flynn JT: The nystagmus blockage syndrome. *Invest Ophthalmol Vis Sci* 24:1580, 1983.
51. Dell'Osso LF, Flynn JT, Daroff RB: Hereditary congenital nystagmus. *Arch Ophthalmol* 92:366, 1974.
52. Dell'Osso LF, Hertle RW, Williams RW, Jacobs JB: A new surgery for congenital nystagmus: Effects of tenotomy of an achiasmatic canine and the role of extraocular proprioception. *J Am Assoc Pediatr Ophthalmol Strabismus* 3:166, 1999.
53. Dell'Osso LF, Leigh RJ, Sheth NV, Daroff RB: Two types of foveation strategy in "latent" nystagmus. *Neuro Ophthalmol* 15:167, 1995.
54. Dell'Osso LF, Schmidt D, Daroff R: Latent, manifest latent, and congenital nystagmus. *Arch Ophthalmol* 97:1877, 1979.
55. Dell'Osso LF, Steen J van der, Steinman RM, Collewijn H: Foveation dynamics in congenital nystagmus—I: Fixation. *Doc Ophthalmol* 79:1, 1992.
56. Dell'Osso LF, Steen J van der, Steinman RM, Collewijn H: Foveation dynamics in congenital nystagmus—II: Smooth pursuit. *Doc Ophthalmol* 79:25, 1992.
57. Dell'Osso LF, Steen J van der, Steinman RM, Collewijn H: Foveation dynamics in congenital nystagmus—III: Vestibulo-ocular reflex. *Doc Ophthalmol* 79:51, 1992.
58. Dell'Osso LF, Traccis S, Abel LA, Erzurum SI: Contact lenses and congenital nystagmus. *Invest Clin Vis Sci* 3:229, 1988.
59. Dickinson CM: The elucidation and use of the effect of near fixation in congenital nystagmus. *Ophthalmic Physiol Opt* 6:303, 1986.
60. Dickinson CM, Abadi RV: The influence of nystagmoid oscillation on contrast sensitivity in normal observers. *Vision Res* 25:1089, 1985.
61. Dorn V, Celic M: Electronystagmographische Beurteilung der operativen Ergebnisse in der Nystagmusbehandlung. *Klin Monatsbl Augenheilkd* 181:114, 1982.
62. Dunlap E: Discussion of paper by Schlossman A: Nystagmus with strabismus: Surgical management. *Trans Am Acad Ophthalmol* 76:1479, 1972.
63. Enoch JM, Wilson GE: Remission of nystagmus following fitting contact lenses to an infant with aniridia. *Am J Ophthalmol* 66:333, 1968.
64. Erhul DM, Dell'Osso LF, Jacobs JB: Characteristics of foveating and defoveating fast phases in latent nystagmus. *Invest Ophthalmol Vis Sci* 39:1751, 1998.
65. Evans BJW, Evans BV, Jordahl-Moroz JJ, Nabee M: Randomized double-masked placebo-controlled trial of a treatment for congenital nystagmus. *Vision Res* 38:2193, 1998.
66. Flynn JT, Scott WE, Kushner BJ, et al: Large rectus muscle recessions for the treatment of congenital nystagmus (letter). *Am J Ophthalmol* 109:1636, 1991.
67. Forssman B: A study of congenital nystagmus. *Acta Otolaryngol* 57:427, 1964.
68. Franceschetti A, Monnier M, Dieterle P: Analyse du nystagmus congénital par la méthode electronystagmographique (ENG). *Bull Schweiz Akad Med Wiss* 8:403, 1952.
69. Friede R: Zur operativen Behandlung des Nystagmus gravis nebst Bemerkungen zur Extraktion der kongenitalen Kataract. *Klin Monatsbl Augenheilkd* 128:431, 1956.
70. Gamble RG: The visual prognosis for children with congenital nystagmus. A statistical study. *Trans Am Ophthalmol Soc* 32:485, 1934.
71. Gay AJ, Newman N, Stroud MH: Vestibular studies on a case of congenital nystagmus. *Lancet* 2:694, 1969.
72. Gelbart SS, Hoyt CS: Congenital nystagmus: A clinical perspective in infancy. *Graefes Arch Clin Exp Ophthalmol* 226:178, 1988.
73. Girard L, Camp RN, Lamb VR, et al: Iris corneal contact lenses. *Am J Ophthalmol* 52:264, 1961.
74. Goddé-Jolly D, Larmande A: Nystagmus congénital. In *Les nystagmus*, vol 1. Paris, Masson, 1973.
75. Gonzales C, Chaudhry NA: Use of the Pierse procedure to treat congenital upbeat nystagmus with a chin-up head position. *J Pediatr Ophthalmol Strabismus* 36:158, 1999.
76. Gottlob I: Infantile nystagmus. Development documented by eye movement recordings. *Invest Ophthalmol Vis Sci* 38:767, 1997.
77. Gottlob I, Zubcov A, Catalano RA, et al: Signs distinguishing spasmus nutans (with and without central nervous system lesions) from infantile nystagmus. *Ophthalmology* 97:1166, 1990.
78. Gradstein L, Goldstein HP, Wizov SS, et al: Relationship among visual acuity demands, convergence, and nystagmus in patients with manifest/latent nystagmus. *J Am Assoc Pediatr Ophthalmol Strabismus* 2:218, 1998.
79. Gradstein L, Reinecke RD, Wizov SS, Goldstein H: Congenital periodic alternating nystagmus. *Ophthalmology* 104:918, 1997.
80. Gresty MA, Bronstein AM, Page NG, Rudge P: Congenital-type nystagmus emerging in later life. *Neurology* 41:653, 1991.
81. Guerra R, Campos EC: Modern surgery for nystagmus. *New Trends Ophthalmol* 7:31, 1992.
82. Haase W: Zur Diagnose und Therapie des Nystagmusblockierungssyndroms (elektromyographische Untersuchungen). *Klin Monatsbl Augenheilkd* 157:500, 1970.
83. Haase W: Zur operativen Therapie bei der Kopffehlhaltung infolge Nystagmus bei Monophthalmos. *Klin Monatsbl Augenheilkd* 158:35, 1971.
84. Hamed LM: Congenital nystagmus: In search of simplicity on the other side of complexity. *J Am Assoc Pediatr Ophthalmol Strabismus* 3:67, 1999.
85. Handa K: Studies on visual acuity and the nystagmus. II. Studies on factors with which nystagmus influences visual acuity and on relationships between nystagmus and EEG. *Acta Soc Ophthalmol Jpn* 75:69, 1971.
86. Happe W, Mühlendyck H: Surgical dampening of nystagmus in patients with achromatopsia. *Strabismus* 3:127, 1995.
87. Harada M, Ishikawa S, Ozawa T: Studies on nystagmus. I. Surgical treatment of horizontal nystagmus (in Japanese). *Acta Soc Ophthalmol Jpn* 65:320, 1961.
88. Harcourt B, Spencer F: Manifest latent nystagmus affecting patients with uniocular congenital blindness. In Gregersen E, ed: *Transactions of the 14th Meeting of the European Strabismological Association*, Copenhagen, May 18–20, 1984, p 259.
89. Helveston EM, Pogrebniak AE: Treatment of acquired nystagmus with botulinum A toxin. *Am J Ophthalmol* 106:584, 1988.
90. Helveston EM, Ellis FD, Plager DA: Large recession of the horizontal rectus muscles for treatment of nystagmus. *Ophthalmology* 98:1302, 1991.

91. Helveston EM, Pinchoff B, Ellis FD, Miller K: Unilateral esotropia after enucleation in infancy. *Am J Ophthalmol* 100:96, 1985.
92. Hemmes GD: Hereditary nystagmus (abstract). Doctoral thesis, Utrecht. *Am J Ophthalmol* 10:149, 1927.
93. Hermann JS, Koberman JJ: Prophylaxis of amblyopia in aniridia: The role of pinhole contact lenses. *J Pediatr Ophthalmol* 5:48, 1968.
94. Hertle RW, Dell'Osso LF: Clinical and ocular motor analysis of congenital nystagmus in infancy. *J Am Assoc Pediatr Ophthalmol Strabismus* 3:70, 1999.
95. Hugonnier R, Etienne R: Le traitement chirurgical du nystagmus congénital. *Bull Soc Fr Ophtalmol* 2:299, 1956.
96. Isenberg SJ, Yee RD: The ETHAN syndrome. *Ann Ophthalmol* 18:358, 1986.
97. Jarzebinska-Vecerova M, Happe W, Mühlendyck H: Vertical shifting operations in patients with congenital nystagmus and vertical torticollis. In Kaufmann H, ed: *Transactions of the 21st Meeting of the European Strabismological Association*, Salzburg. Giessen, Germany, Gahmig Press, 1993, p 375.
98. Jayalakshmi P, Scott TFM, Tucker SH, Schaffer DB: Infantile nystagmus: A prospective study of spasmus nutans, congenital nystagmus, and unclassified nystagmus of infancy. *J Pediatr* 77:177, 1970.
99. Jung R, Kornhuber HH: Results of electronystagmography in man: The value of optokinetic, vestibular, and spontaneous nystagmus for neurologic diagnosis and research. In Bender MB, ed: *The Oculomotor System*. New York, Harper & Row, 1964, p 428.
100. Kaufmann H, Kolling G: Operative Therapie bei Nystagmuspatienten mit Binokularfunktionen mit und ohne Kopfwangshaltung. *Ber Dtsch Ophthalmol Ges* 78:815, 1981.
101. Keeney AH, Roseman E: Acquired, vertical illusory movements of the environment. *Am J Ophthalmol* 61:1188, 1966.
102. Keiner GBJ: Physiology and pathology of the optomotor reflexes. *Am J Ophthalmol* 42:233, 1956.
103. Keiner GB, Roelofs CO: In Niihof M, ed: *Optomotor Reflexes and Nystagmus*, vol 1. La Haye, 1955, p 224. Cited in Goddé-Jolly D, Larmande A: *Nystagmus congénital*. In *Les nystagmus*, vol 1. Paris, Masson, 1973.
104. Kestenbaum A: Periodisch umschlagender Nystagmus. *Klin Monatsbl Augenheilkd* 84:552, 1930.
105. Kestenbaum A: Nouvelle opération du nystagmus. *Bull Soc Ophthalmol Fr* 6:599, 1953.
106. Kestenbaum A: *Clinical Methods of Neuroophthalmologic Examination*. New York, Grune & Stratton, 1961.
107. King RA, Nelson LB, Wagner RS: Spasmus nutans. *Arch Ophthalmol* 104:1501, 1986.
108. Kommerell G: Nystagmusoperationen zur Korrektur verschiedener Kopfwangshaltungen. *Klin Monatsbl Augenheilkd* 164:172, 1974.
109. Kommerell G: Beziehungen zwischen Strabismus und Nystagmus. In Kommerell G, ed: *Disorders of Ocular Motility: Neurophysiological and Clinical Aspects*. Munich, JF Bergmann, 1978, p 367.
110. Kommerell G: The pathophysiology of infantile strabismus. In Kaufmann H, ed: *Transactions of the 16th Meeting of the European Strabismological Association*, Giessen, Germany, Sept 18–20, 1987, p 47.
111. Kommerell G, Mehdorn E: Is an optokinetic defect the cause of congenital and latent nystagmus? In Lennersstrand G, Zee D, Keller EL, eds: *Functional Basis of Ocular Motility Disorders*. Elmsford, NY, Pergamon Press, 1982, p 159.
112. Kommerell G, Zee DS: Latent nystagmus. Release and suppression at will. *Invest Ophthalmol Vis Sci* 34:1785, 1993.
113. Kommerell G, Gusek G, Gilles U: Kongenitaler Nystagmus und intermittierende Exotropie. Nystagmuschemung durch fusionale Konvergenz. *Klin Monatsbl Augenheilkd* 200:210, 1992.
114. Kornhuber HH: Über Begleitschielen und latenten Nystagmus aus neurologischer Sicht, Nr. 102. In *Verein Rheinisch-Westfälischer Augenärzte*. Balve, Germany, Verlag Zimmermann, 1961, p 45.
115. Kushner BJ: Infantile uniocular blindness with bilateral nystagmus. A syndrome. *Arch Ophthalmol* 113:1298, 1995.
116. Lafon C: La vision des nystagmiques. *Ann Ocul* 151:4, 1914.
117. Lang J: Der kongenitale oder frühkindliche Strabismus. *Ophthalmologica* 154:201, 1967.
118. Larmande P, Pautrizel B: Traitement du nystagmus congénital par le 5-hydroxy-tryptophane. *Nouv Presse Med* 10:38, 1981.
119. Lee JP: Surgical management of nystagmus. *Eye* 2:44, 1988.
120. Leigh RJ, Tomsak RL, Grant MP, et al: Effectiveness of botulinum toxin administered to abolish acquired nystagmus. *Ann Neurol* 32:633, 1992.
121. Limon E: Surgical treatment of nystagmus. Presented at the First Congress on Practical Management of Nystagmus and Strabismus, General Hospital, Dr. Manuel Gea Gonzalez, Mexico City, Nov 5–7, 1986.
122. Limon de Brown E, Bernadeli Corvera J: Metodo debilitante para el tratamiento del nistagmo. *Rev Mex Oftalmol* 63:65, 1989.
123. Liu C, Grestly M, Lee J: Management of symptomatic latent nystagmus. *Eye* 7:550, 1993.
124. Mackensen G: Das Fixationverhalten amblyopischer Augen. *Graefes Arch Clin Exp Ophthalmol* 159:200, 1957.
125. Matsubayashi K, Fukushima M, Tabuchi A: Application of soft contact lenses for children with congenital nystagmus. *Neuro Ophthalmol* 12:47, 1991.
126. Metzger EL: Correction of congenital nystagmus. *Am J Ophthalmol* 33:1796, 1950.
127. Mühlendyck H: Diagnosis of convergent strabismus and its treatment with Cüppers fadenoperation. In Moore S, Mein J, eds: *Orthoptics: Past, Present, Future*. New York, Grune & Stratton, 1976, p 143.
128. Noorden GK von: Oculomotor effects on vision: Clinical aspects. In Lennersstrand G, Bach-y-Rita P, eds: *Basic Mechanisms of Ocular Motility and Their Clinical Implications*. New York, Pergamon Press, 1975.
129. Noorden GK von: The nystagmus compensation (blockage) syndrome. *Am J Ophthalmol* 82:283, 1976.
130. Noorden GK von: A reassessment of infantile esotropia (Jackson Memorial Lecture). *Am J Ophthalmol* 105:1, 1988.
131. Noorden GK von, Avilla CW: Nystagmus blockage syndrome: Revisited. In Reinecke RD, ed: *Strabismus II*. New York, Grune & Stratton, 1984.
132. Noorden GK von, LaRoche R: Visual acuity and motor characteristics in congenital nystagmus. *Am J Ophthalmol* 95:748, 1983.
133. Noorden GK von, Sprunger DT: Large rectus muscle recession for the treatment of congenital nystagmus. *Arch Ophthalmol* 109:221, 1991.
134. Noorden GK von, Wong SY: Surgical results in nystagmus blockage syndrome. *Ophthalmology* 93:1028, 1986.
135. Noorden GK von, Jenkins R, Rosenbaum A: Horizontal transposition of the vertical rectus muscles for treatment of ocular torticollis. *J Pediatr Ophthalmol Strabismus* 30:8–14, 1993.
136. Noorden GK von, Munoz M, Wong SY: Compensatory mechanisms in congenital nystagmus. *Am J Ophthalmol* 104:387, 1987.

137. Norn MS: Congenital idiopathic nystagmus. Incidence and occupational prognosis. *Acta Ophthalmol* 42:889, 1964.
138. Ohm J: Augenzittern der Bergeleute und Verwandtes. Berlin, Springer-Verlag, 1916. Cited by Bietti GB, Bagolini B: Traitement medicochirurgical du nystagmus. *Annee Ther Clin Ophthalmol* 11:268, 1960.
139. Ohmi E, Fujita J, Tuboi T, et al: Electrophysiological analysis of congenital nystagmus before and after Anderson's surgery. In Reinecke RD, ed: *Strabismus*. Proceedings of the Third Meeting of the International Strabismological Association. New York, Grune & Stratton, 1978, p 159.
140. Parks MM: Congenital nystagmus surgery. *Am Orthopt J* 23:35, 1973.
141. Pierser D: Operation on the vertical muscles in cases of nystagmus. *Br J Ophthalmol* 43:230, 1959.
142. Pratt-Johnson JA: Results of surgery to modify the null-zone position in congenital nystagmus. *Can J Ophthalmol* 26:219, 1991.
143. Raab-Sternberg A: Anderson-Kestenbaum operation for asymmetrical gaze nystagmus. *Br J Ophthalmol* 47:339, 1963.
144. Reinecke RD: Costenbader Lecture. Idiopathic infantile nystagmus: Diagnosis and management. *J Am Assoc Pediatr Ophthalmol Strabismus* 1:67, 1997.
145. Repka MX, Savino PJ, Reinecke R: Treatment of acquired nystagmus with botulinum neurotoxin. *Arch Ophthalmol* 112:1320, 1994.
146. Robb RM: Periodic alternation of null point in congenital nystagmus. Association with alternating gaze deviation and esotropia. *Arch Ophthalmol* 87:169, 1972.
147. Roberts EL, Saunders RA, Wilson ME: Surgery for vertical head position in null point nystagmus. *J Pediatr Ophthalmol Strabismus* 33:219, 1996.
148. Roelofs CO: Nystagmus latens. *Graefes Arch Clin Exp Ophthalmol* 98:401, 1928.
149. Ruben ST, Lee JP, O'Neil D, et al: The use of botulinum toxin for treatment of acquired nystagmus and oscillopsia. *Ophthalmology* 101:783, 1994.
150. Sandall GS: Surgical treatment of congenital nystagmus in patients with singular binocular vision. *Ann Ophthalmol* 8:227, 1977.
151. Schiavi C, Scorolli L, Campos EC: Surgical management of anomalous head posture due to supranuclear gaze palsies and acquired nystagmus. In Spiritus M, ed: *Transactions of the 23rd Meeting of the European Strabismological Association*. Buren, The Netherlands, Aeolus Press, 1996, p 229.
152. Schlossman A: Nystagmus with strabismus: Surgical management. *Trans Am Acad Ophthalmol Otolaryngol* 76:1479, 1972.
153. Sendler S, Shallo-Hoffmann J, Mühlendyck H: Die artifizielle Divergenz-Operation beim kongenitalen Nystagmus. *Fortschr Ophthalmol* 87:85, 1990.
154. Shallo-Hoffmann J, Faldon M, Tusa RJ: The incidence and waveform characteristics of periodic alternating nystagmus in congenital nystagmus. *Invest Ophthalmol Vis Sci* 40:2546, 1999.
155. Sheth NV, Dell'Osso LF, Leigh RJ, et al: The effects of afferent stimulation on congenital nystagmus foveation periods. *Vision Res* 35:2371, 1995.
156. Shibasaki H, Yamashita H, Motomura S: Suppression of congenital nystagmus. *J Neurol Neurosurg Psychiatry* 41:1078, 1978.
157. Sorsby A: Latent nystagmus. *Br J Ophthalmol* 15:1, 1931.
158. Spielmann A: The surgical treatment of nystagmus: Cüppers Fadenoperation. *Monatsbl Ophthalmol* 2:157, 1978.
159. Spielmann A: Congenital nystagmus; clinical types and their surgical treatment. *Ophthalmologica* 182:65, 1981.
160. Spielmann A: Le traitement chirurgical dans les strabisme avec nystagmus. In Bérard FV, ed: *Sur la chirurgie du strabisme*. Paris, Masson, 1984, p 413.
161. Spielmann A: Nystagmus congénital essentiel et nystagmus congénital manifeste. *J Fr Orthopt* 18:12, 1986.
162. Spielmann A: The "oblique" Kestenbaum procedure revisited. In Lenk-Schafer M, ed: *Orthoptic Horizons*. Transactions of the Sixth International Orthoptic Congress, Harrogate, UK, June 29–July 2, 1987, p 433.
163. Spielmann A: Adduction, latent nystagmus, infantile strabismus and the opto-motor syndrome of congenital uni-ocular organic amblyopia. In Kaufmann H, ed: *Transactions of the 16th Meeting of the European Strabismological Association*, Giessen, Germany, Sept 18–20, 1987, p 291.
164. Spielmann A: Nystagmus and strabismus. *Curr Opin Ophthalmol* 4:25, 1993.
165. Spielmann A: Nystagmus congénitaux mal connus: Le nystagmus congénital pseudo-latent et le nystagmus congénital bi-directional avec double torticolis. Importance du blocage en convergence. *J Fr Orthopt* 28:75, 1996.
166. Spielmann A: Oscillopsia and nystagmus surgery. In Spiritus M, ed: *Transactions of the 24th Meeting of the European Strabismological Association*. Buren, The Netherlands, Aeolus Press, 1998, p 300.
167. Spielmann A: Personal communication, 2000.
168. Spielmann A: Clinical rationale for manifest congenital nystagmus surgery. *J Am Assoc Pediatr Ophthalmol Strabismus* 4:67, 2000.
169. Spielmann A, Bourron-Madignier M: Récession des 4 muscles droits horizontaux dans les nystagmus congénitaux. *Bull Soc Ophtalmol Fr* 11:991, 1993.
170. Spielmann A, Dahan A: Double torticolis and surgical artificial divergence in nystagmus. In Nemet P, Weiss JB, eds: *Acta Strasologica*, Proceedings of the International Symposium on Strabismus and Amblyopia, Tel Aviv. Paris, CERES, 1985, p 187.
171. Spielmann A, Lavlan J: La mise en divergence artificielle dans les nystagmus congénitaux. A propos de 120 cas. *Bull Soc Fr Ophtalmol* 93:571, 1993.
172. Spielmann A, Spielmann AC: Pseudo-latent nystagmus: Congenital nystagmus with exophoria. In Kaufmann H, ed: *Transactions of the 20th Meeting of the European Strabismological Association*, Brussels. Giessen, Germany, Gahmig Press, 1992, p 77.
173. Sprunger DT, Fahad B, Helveston EM: Recognition time after four muscle recession for nystagmus. *Am Orthopt J* 47:122, 1997.
174. Sradj N: Über die Bedeutung okular bedingter Zwangshaltungen und die Möglichkeit ihrer Messung mit dem Torticollometer. *Klin Monatsbl Augenheilkd* 165:823, 1974.
175. Stahl JS, Lehmkuhle M, Wo K, et al: Prospect for treating acquired pendular nystagmus with servo-controlled optics. *Invest Ophthalmol Vis Sci* 41:1084, 2000.
176. Doesschate J: Amblyopic nystagmus induced in non-amblyopic observers. *Ophthalmologica* 124:361, 1952.
177. Tomsak RL, Remler BF, Averbuch-Heller L, et al: Unsatisfactory treatment of acquired nystagmus with retrobulbar injection of botulinum toxin. *Am J Ophthalmol* 119:489, 1995.
178. Tychsen L, Lisberger SG: Maldevelopment of visual motion processing in humans who had strabismus with onset in infancy. *J Neurosci* 6:2495, 1986.
179. van der Hoeve J: Nystagmus latent. *Ann Ocul* 154:738, 1917.
180. van Vliet AGH: Of the central mechanism of latent nystagmus. *Acta Ophthalmol Scand* 51:772, 1973.

181. Wagner RS, Caputo AR, Reynolds RD: Nystagmus in Down's syndrome. *Ophthalmology* 97:1439, 1990.
182. Walsh FB, Hoyt UF: *Clinical Neuroophthalmology*, vol 1. Baltimore, Williams & Wilkins, 1969, p 280.
183. Weiss JG: Le "blocage" existe-t-il? *J Fr Ophtalmol* 12:715, 1975.
184. Yee RD, Baloh RW, Honrubia V: Effect of baclofen on congenital nystagmus. In Lennerstrand G, Zee DS, Keller EL, eds: *Functional Basis of Ocular Motility Disorders*. Oxford, Pergamon Press, 1982, p 151.
185. Yee RD, Wong EK, Baloh RW, Honrubia V: A study of congenital nystagmus waveforms. *Neurology* 26:326, 1976.
186. Young TL, Weis JR, Summers CG, Egbert JE: The association of strabismus, amblyopia, and refractive errors in spasmus nutans. *Ophthalmology* 104:112, 1997.
187. Zubcov AA, Reinecke RD, Gottlob I, et al: Treatment of manifest latent nystagmus. *Am J Ophthalmol* 110:160, 1990.
188. Zubcov AA, Stark N, Weber A, et al: Improvement of visual acuity after surgery for nystagmus. *Ophthalmology* 100:1488, 1993.

P A R T

four

Principles of Therapy

Principles of Nonsurgical Treatment

If definitive knowledge of the etiology of all forms of neuromuscular anomalies of the eyes were available, rational methods of treatment could be implemented. However, the etiology of many forms of strabismus is still unclear. Nevertheless, careful analysis of each has provided sufficient material to form the basis of useful empirical principles from which the necessary therapeutic guidelines can be constructed.

Optical Treatment

Refractive Correction

SPECTACLES. Corrective lenses fulfill a twofold purpose in the treatment of neuromuscular anomalies of the eyes: (1) they create a sharp retinal image that in young children is essential as a stimulus for the use of the eyes and for fusion, and (2) they assist in producing the proper balance between accommodation and convergence (see Chapter 5).

The first basic step of any form of treatment therefore is the prescription of proper glasses, that is, optical correction that fills the individual's needs. These needs vary with the nature of the abnormality and with the age of the patient. The details of refractive correction applicable to the different forms of heterophoria are discussed in Chapters 16 and 17. Only the guiding principles are discussed here.

Generally speaking, the trend is to prescribe

the *full* amount of the refractive error measured in cycloplegia, which we discussed in Chapter 16. The practice of routinely reducing the measured amount of hypermetropic refraction by 1D or so is wrong, and neither is the reduction of a high minus correction reasonable, especially in young children. Young children normally will accept the correct glasses. If the mother reports that the child refuses to wear the glasses, in all probability it is not the fault of the patient. In most instances the ophthalmologist will find that the original refraction was incorrect, and a change of lenses will readily change the patient's attitude. If the refraction obtained during the initial examination is found to have been accurate, the child should then be questioned in detail about why the glasses are disliked. One often hears that they "hurt behind the ears," or "pinch the nose," or that the frames are uncomfortable in some other way, and an adjustment generally will take care of the matter.

When hypermetropia is corrected for the first time, some children may be unable to relax accommodation while wearing their glasses and will experience blurring of distance vision. Atropinization of both eyes for 3 to 4 days usually suffices to relax accommodation and to facilitate acceptance of the correcting lenses. Failure to relax accommodation is not the only reason why some children of school age do not accept glasses. Vanity or worries about being conspicuous are other common causes. When glasses are prescribed in hypermetropic children with refractive accommo-

dative esotropia it is necessary to explain this indication carefully to the parents who may otherwise not understand why spectacles are needed in the presence of normal vision or when the child can see as well with as without glasses.

Several general considerations apply with regard to the age of the child. Although the full refractive correction should be prescribed from infancy through the preschool age regardless of the effect on distance vision, this situation changes in older children in whom distance acuity becomes essential in all activities, particularly in the increasingly competitive school environment. The refractive correction must provide optimal visual acuity, and to insist on a correction that blurs distance vision is wrong. The child may rightly refuse to wear glasses. It is better by far to wear a correction of +3.0D sph in both eyes than it is to hide or conveniently “lose” a pair of spectacles with +3.50D sph that may control the deviation only slightly more effectively.

The question remains whether spectacles should be prescribed for infants. Glasses can be worn by babes in arms, and every skilled optician can provide harness frames for infants. One is sometimes surprised to find that a hypermetropic correction may have an unexpectedly favorable effect on infantile esotropia, and the fact that purely refractive accommodative esotropia may have its onset in infancy should always be borne in mind (see Chapter 16). Unless the patient has an abnormally high accommodative convergence/accommodation (AC/A) ratio, we do not correct hypermetropic refractive errors of less than +2.00D sph in esotropic infants.

UNDERCORRECTIONS AND OVERCORRECTIONS. Undercorrection of a hypermetropic refractive error may cause a decrease in a consecutive exodeviation, and such treatment usually is well tolerated by children. The degree of tolerance depends, of course, on the available accommodative range and thus on the age of the patient. Patients who are treated in this manner, especially school-age children, need to be examined for the development of refractive asthenopia, in which case the refractive error should be fully prescribed even if this increases the consecutive exodeviation. Undercorrection of a myopic refractive error to decrease the angle of strabismus (e.g., in accommodative esotropia) is rarely tolerated well. On the other hand, a full correction of myopia can at times eliminate esotropia, when the far point

without optical correction is extremely close to the patient. Slight overcorrection of a myopic refractive error occasionally is helpful in controlling intermittent exodeviation (see Chapter 17). For a discussion of the use of optical overcorrection or undercorrection in the treatment of amblyopia (penalization), see page 550.

Finally, in certain instances, optical blurring by undercorrection or overcorrection of a refractive error may be used for cosmetic reasons to switch fixation preference, as illustrated in Case 24-1.

CASE 24-1

This patient was a 10-year-old girl with a cosmetically unacceptable right hypertropia who had undergone disinsertion of both inferior oblique muscles. Her best corrected visual acuity was OU 6/6, the right eye being emmetropic and the left eye requiring a -1.75 sph correction. With the left eye corrected with a contact lens, the patient demonstrated a strong fixation preference for that eye, and a 22^Δ hypertropia was present on the right (Fig. 24-1A). Without correction she fixated with the right eye and the right hypertropia measured 9^Δ, which was cosmetically inconspicuous (Fig. 24-1B). Because the patient was asymptomatic and had alternating suppression in all fields of gaze and because her

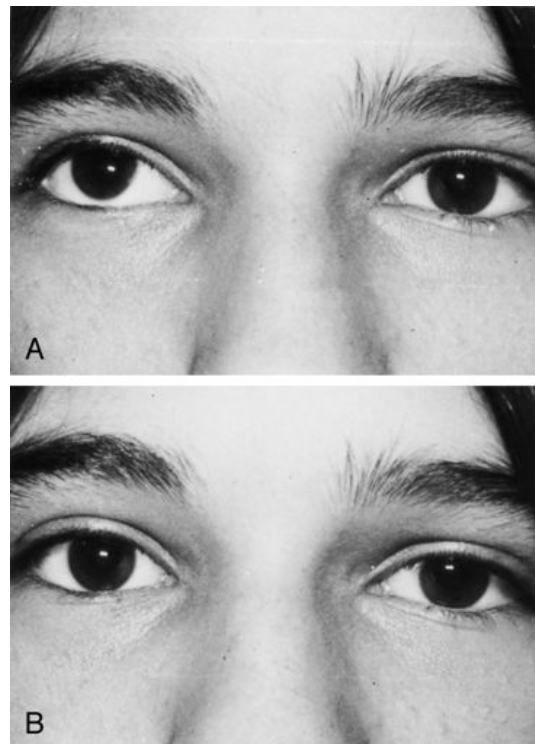

FIGURE 24-1. A, Right hypertropia with the left eye fixating. B, Marked improvement of vertical deviation with the right eye fixating.

parents were opposed to further surgery, we discontinued the contact lens to reduce the deviation. Two years later the patient continued to fixate with the right eye, her myopia had not increased, and the strabismus had remained cosmetically acceptable.

The application of the same principle in controlling *asymmetrical dissociated deviations* has been mentioned in Chapter 18.

BIFOCALS. Bifocals are extremely valuable in the treatment of nonrefractive accommodative esotropia in a patient with a high AC/A ratio (see Chapters 5 and 16). They assist in keeping a child's eyes aligned in the all-important near vision range and commonly bring about remarkable improvement of binocular cooperation. Bifocals should not be prescribed at random, however, but on the basis of accurate measurements and provided certain criteria are met.

Their use should be restricted to a patient who after wearing full cycloplegic correction has a small angle esotropia or, preferably, orthotropia at distance fixation with a residual esotropia at near fixation *that can be converted to orthotropia or esophoria by means of additional plus lenses*. Contraindications to treatment with bifocals are the presence of amblyopia and the mere reduction but not complete elimination of esotropia at near fixation with the addition of plus lenses. Far too often bifocals are prescribed that decrease the esotropia at near fixation from, for example, 40^Δ to 20^Δ. Clearly, nothing is gained by the use of bifocals in such patients, because the incomplete reduction of the near deviation does not improve binocular function. Parental acceptance of bifocal therapy for their child can be greatly enhanced by having the patient perform the Lang two-pencil stereotest (see Chapter 15) while looking first through the upper and then through the lower segment. Performance with this test is often spectacularly improved when the patient looks through the bifocals. We know of no better method to convince parents of the functional benefit derived from this therapy and to ensure full parental cooperation.

We determine the power of bifocals by adding plus lenses to a clip-on frame attached to the patient's spectacles (see Fig. 12–16), starting with +1.00D sph and increasing the power in steps of +0.5D sph up to +3.00D sph and then measuring the angle each time stronger lenses are placed before the eyes.³⁵ In most patients with a high

AC/A ratio, a stepwise decrease of the angle at near fixation will be noted as the lens power is increased until a point is reached at which the esotropia becomes sufficiently small to be overcome by fusional divergence. Only the minimal lens power that converts an esotropia to an esophoria is prescribed because (1) excessive relaxation of accommodation, to which Breinin and coworkers³² have objected, is prevented, and (2) some of the burden of keeping the eyes straight is put on the patient, which is the goal of all forms of nonsurgical treatment of comitant heterotropia.

One may argue that when measuring with additional plus lenses a patient will not relax accommodation immediately and that bifocals need to be worn for some time before their full effect on the near deviation can be assessed. If this were so, one would expect further reduction of the near deviation after the patient had worn bifocals for several weeks. To clarify this point, we¹⁵² compared measurements taken during the first examination at near fixation through +3.00 sph lenses with those obtained after bifocals had been worn for 5 to 15 weeks. With rare exceptions, the near deviation had remained the same or increased, which shows that prescription of bifocals on the basis of measurements made during the initial examination is justified. In patients whose response to bifocals is doubtful, a trial with Press-On lenses (Optical Science Co.) is often helpful before ordering the final prescription. In emmetropic patients, plano lenses to which the bifocal segments can be attached are prescribed.

The success of bifocal therapy depends largely on the proper bifocal segment. Experience has taught us that small segments, such as those used in presbyopic prescriptions, are essentially useless in children. We prefer a straight-top bifocal in which the separation line between the distance and near segments bisects the pupil or touches the lower border of the pupil when the child looks straight ahead (Fig. 24–2A). Improperly placed bifocals (Fig. 24–2B) are of no functional benefit to the patient. Since many opticians do not understand the purpose of bifocals in children and place the segments in a position appropriate for the correction of presbyopia but inappropriate for correction of an esotropia at near fixation, we attach written instructions for proper fitting to the prescription. We do not favor the use of *progressive lenses* as a substitute for bifocals since one cannot be certain that the patient uses the maximal power of the lens for near vision to relax accommodation (see Chapter 16).

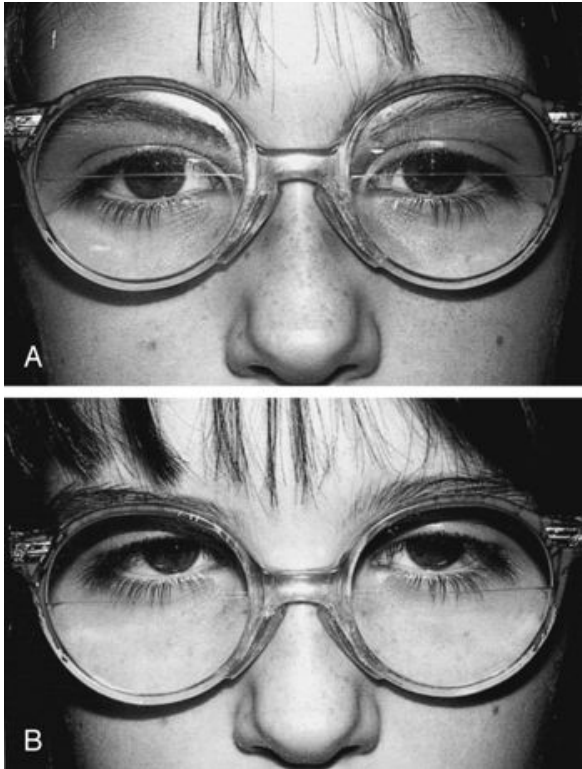


FIGURE 24-2. Correct (A) and incorrect (B) placement of bifocal segments for the treatment of accommodative convergence excess.

Bifocals may cause fusional amplitudes to develop spontaneously in many patients, after which the bifocals may be reduced step by step and eventually discontinued.^{123, 152} We attempt to wean the patient from the bifocal segment by 10 years of age. We have determined that in patients who are being treated with bifocals the deviation may decrease to the point where bifocals can be discontinued, or the child may become dependent on bifocals, or ocular function may deteriorate in spite of maximal bifocal correction.¹⁵² Patients with a high AC/A ratio and those receiving supportive orthoptic therapy fared best with bifocals. If a patient still depends on bifocals to maintain fusion during the early teenage years or if fusional control of the near deviation is no longer possible, we recess both medial rectus muscles.

We have become aware of an interesting association between bifocal wear in childhood and an *abnormally low near point of accommodation*.¹⁴⁸ Prospective studies must decide whether this finding is the expression of a bifocal-induced accommodative insufficiency or a primary hypoaccommodative state that may, in fact, be the cause of the increased esodeviation at near fixation (hypoaccommodative esotropia of Costenbader; see Chapter 16).

During the course of bifocal treatment, cycloplegic refraction must be repeated semiannually and the distance and near correction adjusted if the refractive error has changed. The aim should be to provide the very maximal hypermetropic spectacles correction and to reduce the bifocal power by the amount of lens power if additional plus correction can be added to the prescription.

A special problem is a myopic patient with a high AC/A ratio whose binocular vision is normal until the myopia is corrected for the first time. Before correction, these patients were in a hypoaccommodative state. With the myopia corrected, normal accommodative innervation is then required to clear the retinal images at near fixation, causing an esodeviation. Albert and Hiles⁷ observed that such patients became especially dependent on their bifocals and instead recommend miotic treatment.

Prisms

The history of prismatic correction in the treatment of neuromuscular anomalies of the eyes is interesting. The increasing store of knowledge and the interest in the study of refractive anomalies and heterophorias in the United States in the last third of the nineteenth century and the first third of the twentieth century brought about widespread use of prismatic corrections in spectacles lenses. Currently, the prescription of prisms has become a less common practice. Guibor⁸⁵ recommended their use to reduce the deviation, develop fusional amplitudes in comitant heterotropias, and avoid contracture of the antagonist in paralytic strabismus (see Chapter 20). In Europe, prisms were used in the treatment of strabismus during the nineteenth century by Krecke,¹⁰⁵ Donders,⁶⁶ von Graefe,⁸¹ and Javal.^{97, p.75} In 1930, Sattler¹⁸⁹ revived interest in prisms, but his method of treating strabismus had few followers. In the late 1950s the application of prisms again became popular, especially in Europe. There were advocates of prismatic treatment of eccentric fixation in amblyopia, anomalous retinal correspondence, comitant deviations, nystagmus, and paralytic strabismus, but prisms are now rarely used for these purposes.

TYPES OF PRISMS. The past lack of enthusiasm for prismatic therapy may be attributed partially to the many disadvantages inherent to conventional glass prisms of high power. Their excessive weight, disturbing reflections and aberrations, and

cosmetically unsatisfactory appearance, together with the prohibitive cost associated with frequent necessary changes of correction, have limited the use of prisms. These disadvantages were largely overcome when Fresnel membrane prisms became available.* The great advantage of membrane prisms, which are simply pasted to the back surface of spectacles lenses, is their immediate availability in powers up to 30^Δ, minimal distortion effects, ready changeability, lightness in weight, and acceptable cosmetic appearance.^{95, 102, 196} Yet membrane prisms also have the undesirable effect of reducing visual acuity, particularly if their power is high. We find them useful for diagnostic purposes and when the patient needs a prismatic correction for reduced periods of time and particularly when the prism power has to be frequently modified.

INDICATIONS. Prismatic therapy may be considered to maintain single, comfortable binocular vision in the presence of motor imbalance of the eyes. The role of prisms in the therapy of heterophoria, horizontal and vertical heterotropia, anomalies of the vergence system, nystagmus, paralytic strabismus, and consecutive strabismus with diplopia is discussed in the appropriate chapters of this book.

A second indication for prismatic therapy—the modification of sensory anomalies—has not become established in our therapeutic armamentarium and is primarily of historical interest. Sattler¹⁸⁹ was the first to advocate the use of prisms in treating sensory anomalies, and he reported significantly improved functional results in a group of patients in whom prismatic correction preceded surgery. Bagolini^{15, 16} reintroduced the use of prisms in our time and believes that correction or overcorrection of a residual angle of esotropia after surgery may restore normal retinal correspondence (see also Maraini and Pasino¹²⁸ and Welge-Lüssen and Bock²²³). Pigassou and Garipuy¹⁶⁵ stressed the value of creating “sensory orthophoria” by first overcorrecting and then neutralizing the deviation before surgery, and they reported spectacular results with respect to restoration of normal binocular functions with this method (see also de Beir,²⁶ Deller and Brack,⁶² and Flemming and coworkers⁷³).

Many authors have claimed that *prismatic*

overcorrection (changing an esotropia to an exotropia) creates especially favorable conditions for spontaneous restoration of normal retinal correspondence and that this effect is similar to that created by surgical overcorrection.^{4, 5, 11, 59, 95} The rationale for preoperative treatment of anomalous retinal correspondence with prisms raises the question of whether better functional results are obtained than if surgical treatment only is used. The beneficial effect of surgical alignment on the normalization of retinal correspondence is well-known, and there are no studies that establish that preoperative prismatic therapy improves the functional results of surgery. For this reason, the prismatic treatment of sensorial anomalies has been largely abandoned.

The *prism adaptation test* used by some to determine the dosage of surgery is discussed in Chapter 26.

The interested reader is referred to a comprehensive review of the optical principles of prisms and current prismotherapy by Véronneau-Trautman.²¹⁶

Pharmacologic Treatment

Miotics

Javal^{97, p.79} was one of the first to use miotics (physostigmine, pilocarpine) in the treatment of strabismus. He clearly recognized the disturbed relationship between accommodation and accommodative convergence in certain forms of esotropia and the therapeutic possibility of activating accommodation without convergence by peripherally acting drugs such as physostigmine and pilocarpine. However, not until 1949, when Abraham¹⁻³ published the first of his many papers on the use of miotics, did the use of parasympathomimetic and anticholinesterase drugs become established as adjuncts to the medical treatment of strabismus. Since then, several reviews have been published.^{79, 116}

ACTION. The pharmacologic action of miotics is twofold. They cause constriction of the pupil and act on the ciliary muscle, either indirectly by facilitating neuromuscular transmission in the case of cholinesterase inhibitors,¹⁸² or directly by causing an accommodative spasm in the case of parasympathomimetics.¹ Ripps and coworkers¹⁸³ have shown that drug-induced miosis with its resultant increase in depth of focus does not affect the

*The Fresnel Prism and Lens Co., 7975 N. Hayden Road, Suite A-106, Scottsdale, AZ, 85258-32342. Website: www.fresnelprism.com

accommodative requirements or the AC/A ratio. Thus the therapeutic effect of miotics is based on the facilitation of accommodation; the accommodative effort is reduced, and less accommodative convergence occurs (see Chapter 5). The value of such therapy in accommodative esotropia is obvious, but the use of miotics in this condition has steadily declined in recent years.

We prefer echothiophate iodide in 0.03% solution, starting with 1 drop per day in each eye in the morning. The minimal dosage required to produce the desired effects should be titrated, starting with a weak solution and using stronger concentrations if the patient fails to respond. Haddad and Rivera⁸⁷ showed that a 0.03% echothiophate iodide solution was as effective as a 0.125% solution in controlling accommodative esotropia.

INDICATIONS. Numerous studies have demonstrated the effectiveness of miotics in refractive and nonrefractive accommodative esotropia.^{87, 128} It goes without saying that miotics will not eliminate the basic innervational problem; however, they may change esotropia to esophoria at near fixation, thereby creating conditions favorable for the development of fusional amplitudes. *Miotics should not be used unless some degree of binocularity can be achieved*; a slight reduction in the angle of esotropia is of no benefit to the patient with respect to restoring normal binocular function. We have discussed the use of miotics in Chapters 16 and 17, and our indications for this form of therapy are summarized only briefly here.

DIAGNOSTIC TRIAL. A diagnostic trial with miotics may occasionally be indicated in esotropic infants to differentiate between nonaccommodative and accommodative esotropia (see Chapter 16). A significant reduction of the deviation at near fixation under the influence of miotics will readily identify those patients who can be expected to benefit from a correction of their hypermetropic refractive error in the case of refractive accommodative esotropia or from prescription of a bifocal segment in the case of nonrefractive accommodative esotropia (high AC/A ratio; see Chapter 16). Failure to respond to miotics is a consistent feature of nonaccommodative esotropia. We rarely use miotics for this purpose and prefer a trial with glasses instead.

THERAPY OF ACCOMMODATIVE ESOTROPIA. Despite our preference for bifocals over miotics in the long-range therapy of esotropia with a

high AC/A ratio (Chapter 16), we on rare occasions use miotics in children who will not tolerate glasses or are unlikely to wear glasses for the entire day while participating in extended athletic activities or while in summer camp. Whether a physician elects to treat accommodative esotropia with bifocals or with miotics is a matter of preference rather than a decision based on the proven advantages of one method over the other.^{25, 32, 101}

POSTOPERATIVE. Miotics may be helpful in restoring fusion in patients able to fuse who have a consecutive esotropia after surgery for an intermittent exodeviation (see Chapter 17).

AMBLYOPIA. Miotics in the amblyopic eye, in combination with atropinization of the sound eye, have been advocated for the treatment of amblyopia by Knapp and Capobianco¹⁰³ and are discussed later under *Penalization*.

SIDE EFFECTS. There are systemic and local side effects of miotics. The more potent anticholinesterase drugs, such as echothiophate iodide, lower the cholinesterase in the red blood cells, and several weeks will pass after discontinuing the drug before blood cholinesterase reaches its pretreatment level.^{69, 70} Although a temporary reduction in the blood cholinesterase level usually is well tolerated, a potential risk exists when children receiving miotic therapy are given a general anesthetic. Since cholinesterase is required for hydrolysis of succinylcholine, a drug used by some anesthesiologists to facilitate intubation, such patients may develop prolonged respiratory paralysis. It follows that the use of succinylcholine should be avoided in patients treated with echothiophate iodide within 6 weeks before surgery.

Shallowing of the anterior chamber,⁶¹ angle closure glaucoma,⁹⁹ and cardiac arrest⁹² in patients on echothiophate therapy, and lens opacities in a patient on fluorophosphate eye drops,⁹¹ are rare complications of miotic therapy (see also Kinyon¹⁰⁰ and Shaffer and Hetherington¹⁹⁹).

Transient blurring of vision, generalized darkening of the field of vision, and development of iris cysts are among the most common ocular reactions to miotics. The incidence of iris cysts along the pupillary margin reported by different authors ranges from 20% to 50% of all children treated with miotics, and such cysts may appear from 2 to 40 weeks after the beginning of therapy.^{2, 100, 144} Phenylephrine 2.5% used in combination with diisopropyl fluorophosphate (DFP) or echothiophate iodide prevents formation of iris

cysts.^{3,56} As a rule, iris cysts regress spontaneously after therapy is discontinued, and in our experience and that of Miller¹⁴⁷ they are less common when echthiophate iodide is used than when other miotics are employed. The cataractogenic effect of miotic therapy occasionally observed in adults does not seem to pose a risk in children treated with cholinesterase inhibitors.^{17, 134}

Atropine

As early as 1866, Laurence and Moon¹¹² noted that paralysis of accommodation as a result of atropinization may cause strabismus to disappear in young children. Similar observations were reported by Javal,^{97, p.75} and by Hansell and Reber.⁸⁹ Guibor⁸⁴ became an ardent advocate of atropine treatment of children with accommodative esotropia. He suggested that esotropic children be treated with atropine for at least 6 months before considering surgery to “suppress the accommodative-convergence mechanism and to stimulate divergence indirectly.” This form of treatment has found few adherents, although Réthy¹⁷⁹ recommended atropine in combination with overcorrection of a hypermetropic refractive error (see Chapter 16) for treatment of accommodative esotropia. The use of atropine in the treatment of amblyopia is discussed on page 550.

Chemodenervation

The possibility of weakening an extraocular muscle by neurotoxic agents as an alternative to surgical weakening has been explored.¹⁹³ A. B. Scott introduced the use of diluted botulinum A toxin (Oculinum, Berkeley, CA) for this purpose.¹⁹²⁻¹⁹⁴ The use of botulinum toxin is discussed in Chapter 25.

Orthoptics

The goal of orthoptic treatment is to give the patient secure, comfortable binocular vision. In the broader sense, all nonsurgical treatment is considered orthoptic treatment. In the last analysis the aim of prescribing glasses, prismatic correction, and the use of miotics is to help the patient achieve this goal. In the narrower sense, orthoptic treatment is used to combat suppression, amblyopia, and anomalous retinal correspondence and to enhance development of fusional amplitudes and

improve stereopsis. The orthoptist cannot be expected to permanently remove the underlying deviation. In successful cases, orthoptic treatment enables transformation of heterotropia into heterophoria by allowing patients to fuse a manifest deviation; however, the latent deviation is not changed.

All treatment is the responsibility of the physician. Certainly, refraction and prescription of glasses are in the physician’s province, as is treatment with prisms and miotics; however, many ophthalmologists refer their patients to a competent orthoptist for treatment and binocular training. Nevertheless, the supervision and direction of such treatment remains at all times the sole responsibility of the ophthalmologist. Frequent conferences with the orthoptist about the patient’s treatment are necessary.

Only the principles of orthoptic treatment are discussed here; the reader is referred to the orthoptic literature for details of these procedures.

Applications

CONVERGENCE INSUFFICIENCY. Treatment of convergence insufficiency is one of the most effective and gratifying endeavors of the orthoptist. Indeed, orthoptics is the only method by which such patients with severe muscular asthenopia will find relief. In the advanced stage, suppression must be treated first. After suppression has been eliminated, the patient is told to converge on an approaching object, such as a pencil or a light, while a red filter is placed over one eye. Another method consists of making the patient aware of physiologic diplopia of a distant object while fixating on a target at near. The near target is then removed, and convergence is sustained for increasing periods by voluntary effort while diplopia is maintained at distance. These exercises are followed by training of fusional convergence with prisms base-out and by treatment with the major amblyoscope. Prisms base-out also may be used during reading, and fusion exercises with prisms of increasing power can be continued on a home therapy basis. Many patients in whom symptoms recur will resume these exercises on their own.

FUSION TRAINING. Training of fusional amplitudes may enable the patient to cope better and live more comfortably with a symptomatic heterophoria than would otherwise be the case. The targets on the major amblyoscope are set at an

angle at which the patient can fuse, and the arms of the instrument are diverged (for training of divergence amplitudes) or converged (for convergence amplitudes) until diplopia occurs. This treatment may be supplemented by prism exercises that the patient may carry out at home according to instructions given by the orthoptist.

ANTISUPPRESSION TRAINING. As pointed out in Chapter 13, suppression is the patient's defense against diplopia. This adaptive mechanism may be considered a blessing in certain patients when restoration of binocular function remains unattainable. In others, suppression presents an obstacle to functional cure that must be overcome. Orthoptic treatment is aimed at making the patient conscious of physiologic diplopia in heterophoria and of diplopia in heterotropia. Once diplopia can be elicited, the patient is taught vergence control or, if the deviation is sufficiently large, surgical alignment is considered. Antisuppression therapy is aimed at bringing the image formed on the suppressed retinal area back into consciousness. Several therapeutic approaches are used. One consists of forcing the suppressed area to be used concurrently with the corresponding area of the dominant eye by means of differential stimulation. This can be accomplished by placing a red filter over the dominant eye and having the patient trace with a red pencil or select red beads for a necklace. The variety of such exercises is limited only by the ingenuity of the therapist. It is important of course that the color of the filter and of the object match so that perception of the red objects with the eye on which the filter is worn is totally extinguished. Another approach to the treatment of suppression involves stimulation of the retina of the deviated eye by moving the visual target on the major amblyoscope back and forth across the suppression scotoma (macular massage) or by rapidly alternating visual stimulation of both maculas. The patient also can be taught awareness of physiologic diplopia by using a bar reader or the Tibbs diplopia trainer. There is no question that suppression can be effectively eliminated by orthoptic methods. *The question is whether patients thus treated gain a better functional result than others who receive passive treatment, such as alternating occlusion, or no treatment at all.*

ANOMALOUS RETINAL CORRESPONDENCE. Orthoptic treatment of anomalous retinal correspondence is no longer practiced. The methods that were in use are only of historical and theoretic

interest. They were based on the principle that if the image of the fixation point is moved with the amblyoscope over the retina of the deviated eye, anomalous localization of the double image may suddenly be replaced by normal localization. This instability of anomalous retinal correspondence is made use of in orthoptic training in the technique known as "retinal massage." Normal retinal correspondence is elicited by moving the image of an object over the macula of the deviated eye or by stimulating the two foveas using the major amblyoscope. Monocular diplopia frequently occurs during this training and is made use of in a treatment procedure described by Walraven.²¹⁹ In later years, instruments and treatment methods came into use by which such training could be performed under casual conditions of seeing, for which the somewhat awkward expression "in free space" has come into use.^{9, 27, 52, 53, 159, 161-164}

The benefits of anomalous retinal correspondence in preserving most advantages of normal binocular vision in the presence of a manifest ocular deviation have been discussed in Chapter 13. In view of these benefits, *we do not advocate orthoptic treatment of anomalous retinal correspondence.* Such treatment may actually cause harm and, therefore, be inappropriate. Quéré and coworkers¹⁷³ have reported cases with intractable diplopia following intensive prismatic and orthoptic treatment of anomalous retinal correspondence.

Indications and Contraindications

The activities of an orthoptist are twofold. They are (1) to obtain a complete diagnostic evaluation of a patient with a neuromuscular anomaly of the eyes and (2) to carry out orthoptic training. Although the diagnostic workup performed by a competent orthoptist is indisputably of great value to the clinician, this does not necessarily hold true for orthoptic therapy. The views expressed on this matter range from almost total therapeutic nihilism by those willing to settle for a cosmetically acceptable result to an almost religious zeal by others who aim for the elimination of sensory anomalies and restoration of binocular vision in each patient and at any price. The value of treatment of amblyopia and of orthoptic training in improving deficient fusional amplitudes or convergence insufficiency is well established. However, the extent to which suppression should be treated orthoptically in the preoperative and postoperative phases is not



FIGURE 24-3. Copy of the original manuscript of Thabit Ibn Qurrah in ancient Arabic, containing the first description of amblyopia therapy (*lower left-hand page, underlined*). (Courtesy of M. Z. Wafai, M.D., Damascus, Syria.)

clear at this time, nor has the type of patient who should be considered for such therapy been unequivocally defined. Most studies published by orthoptists and ophthalmologists who have attempted to evaluate the results of orthoptic therapy, of suppression, or anomalous retinal correspondence do not stand up under critical scrutiny. Indeed, a truly scientific validation of orthoptic treatment has never been published. Thus the value of orthoptic training is variously assessed by different ophthalmologists and in different countries, and such assessment is based on clinical impressions rather than on solid evidence. A comprehensive, well-designed prospective collaborative study of the various forms and methods of orthoptic treatment is needed to determine the value of such training and to define the type of patients who may benefit from it. Such a study could show that orthoptic therapy is not worthwhile, in which case it should no longer be practiced. On the other hand, if the value of orthoptic training can be unequivocally established and shown to be superior to other forms of therapy, orthoptics may have the comeback that it perhaps deserves.^{37, 145}

Treatment of Amblyopia

HISTORICAL REMARKS. The history of the treatment of amblyopia is a fascinating one that vividly demonstrates how pathophysiologic concepts influence the handling of a disease. The French naturalist and botanist Comte de Buffon³⁴ (1707–1788) is often credited with having introduced patching of the fixating eye for amblyopia. However, occlusion treatment was actually described much earlier by Thabit Ibn Qurrah,¹⁷⁵ whose date of birth is not known but who died in AD 900. This scientist from Mesopotamia wrote that strabismus “should be treated by patching the normal eye. Once you do that, the visual power will go in its entirety to the deviated eye and vision will return to normal in that eye. You should not release the normal eye until the vision in the strabismic eye has completely returned to normal”* (Fig. 24–3).

While we may find it difficult to agree with our colleague from ancient times when he goes on to write that “such patients must also be purged, should bathe every second day and be

*Translation courtesy of M. Z. Wafai, M.D., Damascus, Syria.

made to sneeze by putting the juice of olive leaves into the nose,” there is no argument that his principle of amblyopia therapy has remained virtually unchanged for more than a millennium!

Despite these early recommendations, amblyopia was not treated until much later. Indeed, treatment was rejected for many years during which amblyopia was thought of as a congenital, hereditary anomaly. This view was defended as late as 1927 by Uthoff²¹³ and Poulard,¹⁶⁸ who wrote in 1921 that in young children “le strabisme n’est pas la cause, mais la conséquence de l’amblyopie.” In 1935 S. Gifford⁷⁸ reported from Chicago that he had been unable to obtain cooperation for prolonged occlusion treatment for most cases of amblyopia and that even in those who cooperated the results of therapy were disappointing.

With the birth of the concept of amblyopia as a sensory adaptation to strabismus as opposed to a congenital defect, patching was resumed and has since remained the mainstay of amblyopia treatment. That patching was by no means successful in all cases, especially in older children, became evident from the work of Sattler,¹⁸⁸ who deserves credit for having reintroduced occlusion treatment. Attempts were made to supplement this passive amblyopia treatment with active stimulation of the amblyopic eye. Electric and chemical stimulation were tried without much success, and visual exercises to train the acuity of the amblyopic eye were suggested.^{54, 64, 127, 198} However, all these attempts were essentially unsystematic until Bangerter^{18–20} introduced planned exercises for the amblyopic eye. No type of treatment exists for bilateral visual deprivation amblyopia other than timely elimination of the visual obstacle and proper optical correction. Hopefully, some day pharmacologic treatment (see Chapter 14) will become available for this condition.⁴¹

OCCLUSION TREATMENT. Before discussing the various treatment modalities for amblyopia, the importance of establishing a reliable baseline visual acuity measurement must be stressed. The learning effect of repeated visual testing, the parents’ attitude,¹⁵⁶ and the potentially confounding influence of nonspecific pretreatment procedures such as spectacles correction and repeated visual acuity or contrast sensitivity testing^{119, 135} have to be taken into account.

METHODS OF OCCLUSION. In occlusion therapy the fixating eye is prevented from taking

part in the act of vision so that the patient is forced to use the amblyopic eye. In addition, occlusion removes the inhibitory stimuli to the amblyopic eye that arise from stimulation of the fixating eye (see Chapter 14). Patching the fixating eye may appear to be a simple procedure, and in many cases it is. Nevertheless, in the practical application of this simple treatment method, several questions and difficulties must be discussed.

Eyes can be occluded in various ways. Occluders that attach in some fashion to the spectacles can be worn by the patient; however, children have an amazing ability to peek over their glasses or sideways through small spaces between the spectacles frame and the skin, especially on the nasal side. Most children will simply take their glasses off when unobserved, and for this reason, we rarely use this method of occlusion. A more effective type of occluder is a piece of material that fastens directly to the skin. Numerous occluders are available commercially or can be readily fashioned by a parent. We favor the paper-thin hypoallergenic and semiporous eye patches available from several manufacturers (Fig. 24–4).

Problems may arise in children with sensitive skin, in which case the skin may be treated with tincture of benzoin before the occluder is applied. This medication not only forms a protective layer on the skin but also increases adhesiveness of the patch so that the child is less likely to remove it. It is even more effective to treat the skin with protective dressing wipes that are ordinarily used to protect the abdominal skin underneath colos-

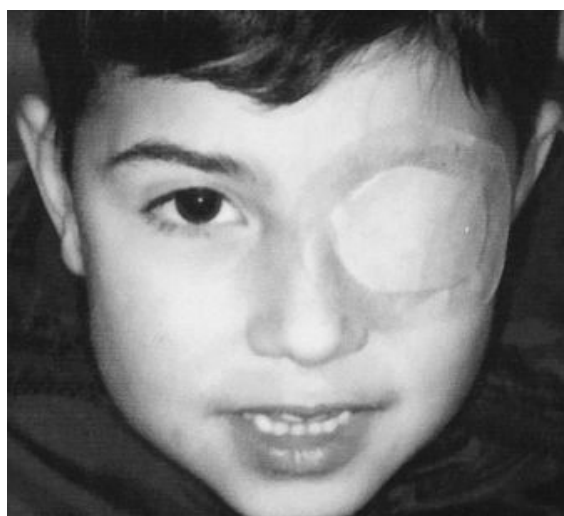

FIGURE 24–4. Use of eye patch in the treatment of amblyopia.

tomy appliances.* When treated in this manner, most patients with sensitive skin will tolerate a patch. In the case of total lack of compliance because of persistent skin problems, extended-wear *occluding soft contact lenses* may be used as a substitute for a patch.^{72, 209, 212}

As a rule, the fixating eye should be occluded completely and constantly during all waking hours. Occlusion of the sound eye for an hour or so a day as practiced by some is rarely beneficial. Bangerter and Steidele²³ recommended that semi-transparent membranes (Bangerter foils†) of increasing density be attached to the back of a spectacles lens. The acuity of the dominant eye is gradually reduced, and the child becomes accustomed to the occluding device. This method has been particularly recommended because of its potential in tapering off treatment by reducing the density of the filters.¹¹¹

In checking vision in an eye from which a patch has just been removed, one should allow several minutes after removal before proceeding with testing. Unless the opportunity is given for the eye to adapt to light and to recover from the mechanical effect of the patch, visual acuity is likely to be reduced, which may lead to wrong conclusions.

AGE AT OCCLUSION. Once amblyopia is diagnosed occlusion treatment should commence without delay. The age at which therapy is begun is directly related to the effectiveness of therapy—the younger the child at initiation of treatment, the more rapid the response. Once children reach the age of 6 to 7 years improvement of vision becomes slow and compliance with wearing a patch often becomes a major problem. However, treatment may still be successful at that age and even older provided compliance is good.¹⁶⁰

PREVENTION OF OCCLUSION AMBLYOPIA. Once occlusion therapy has been instituted, the child must be reexamined at frequent intervals for several reasons. Problems that may arise when occlusion is first attempted will have to be discussed with the parents. Also, in children who are old enough to permit a reliable determination of fixation behavior, it is of interest to determine whether such treatment has brought about any change of fixation. Most important, however, the

visual acuity of the fixating eye must be carefully monitored during occlusion therapy. Children up to 5 years of age may develop amblyopia in the occluded eye, at times complicated by eccentric fixation,^{36, 140, 142} and the formerly amblyopic eye may become the dominant eye (*occlusion amblyopia*). This phenomenon, which has been well documented in the literature, is usually reversible,^{36, 55, 90, 125, 142, 158, 215} even though irreversible amblyopia in the formerly fixating eye following uncontrolled unilateral occlusion during early infancy has been reported.^{14, 143} Several cases are on record where the formerly fixating eye became amblyopic under the influence of occlusion, and amblyopia persisted in the nonfixating eye.^{120, 205}

The precise age range during which the human visual system is sensitive to unilateral visual deprivation has yet to be defined, and the susceptibility to occlusion amblyopia varies among patients. This *period of susceptibility* to monocular occlusion was investigated in 407 children, whose ages ranged between 21 months and 12 years, to collect data on the sensitive period for strabismic amblyopia.⁷¹ The susceptibility, although high during infancy, was about null at 12 years, having decreased, as expected, with age. Parents should be alerted to the risk of occlusion amblyopia and be asked not to miss their appointments once occlusion therapy has started and to report to the ophthalmologist if the previously deviated eye continues to maintain fixation once the patch is removed.

In an effort to *prevent occlusion amblyopia*, we alternate occlusion of the sound eye with occlusion of the amblyopic eye. During the first year of life the sound eye is patched for 3 days, followed by patching of the amblyopic eye for 1 day (3:1 rhythm). During the second year of life, the occlusion period of the sound eye can be extended to 4 days, followed by 1 day of occlusion of the amblyopic eye. In 3- to 4-year-old children, the occlusion period of the fixating eye can be further lengthened, provided the physician monitors visual acuity of both eyes at frequent intervals. The same principle applies in younger children. If 3:1 or 4:1 occlusion fails to bring about improvement, the period of occlusion of the sound eye may be lengthened and visual acuity, fixation preference, or both are checked at intervals not to exceed 4 weeks.

Rapidly acquired transient occlusion amblyopia may be a good prognostic sign, indicating that the visual function of an amblyopic eye is still in a highly plastic state and therefore recoverable. In such children, judicious use of alternating occlu-

*United Skin Prep made in the United States by Smith & Nephew United, Largo, FL, 34643 and available in medical supply stores.

†The Fresnel Prism and Lens Co., Inc., 7975 N. Hayden Road, Suite A-106, Scottsdale, AZ 85258-3242. Website: www.fresnelprism.com

sion usually restores normal vision and central fixation in each eye.

FULL-TIME VS. PART-TIME OCCLUSION. In the prevention of occlusion amblyopia there is definite value in occluding the amblyopic eye at regular intervals rather than leaving both eyes exposed. The dominant eye is actively reinforced when the amblyopic eye is occluded, and also the amblyopiogenic factors that become active when both eyes are open (see Chapter 14) are prevented from reversing gains made by the therapy. It is for the same reason that we prefer to use constant (full-time) occlusion, from morning to night, when treating amblyopia rather than limiting occlusion to several hours (part-time) during each day. While some beneficial effect may be obtained even from part-time occlusion, the duration of treatment is unnecessarily prolonged because each time the patch is removed the inhibitory process that causes the amblyopia is being reactivated. Indeed, the effect of, say, half-day occlusion can be likened to walking toward a certain goal by taking three steps forward, two steps backward, and so on. Eventually, the goal will be reached but it will take much longer to get there than by walking directly toward it. During this prolonged treatment the child will become increasingly bored and annoyed with the patch. Part-time occlusion, in our opinion, has only one valid place: together with other methods (alternating penalization) it is an effective tool to maintain a good treatment result until the child has reached an age at which recurrence of amblyopia is no longer a problem.

EFFECT OF OCCLUSION ON THE ANGLE OF STRABISMUS. It has been suggested that occlusion may have an effect on a preexisting esodeviation.¹⁶⁶ Holbach and coworkers⁹³ examined whether occlusion therapy carries the risk of changing the ocular alignment and were unable to confirm this view. These negative findings should not distract from the fact that unilateral occlusion may occasionally trigger a manifest esotropia (acute esotropia) in a patient who had formerly been orthotropic or had only intermittent esotropia. If this possibility is adequately explained to the parents, they nearly always will take this risk and agree to occlusion therapy.

DURATION OF TREATMENT. The time required for treatment varies from patient to patient and is shorter the younger the child.^{76, 77, 126, 141, 157, 215} If therapy is at all successful, improvement at first is quite rapid but slows once a certain level of acuity has been reached. Extremely low vision

when treatment is begun does not necessarily mean treatment will be prolonged. Occlusion treatment should be continued until the vision of the amblyopic eye and its fellow eye becomes equalized or until there is no further improvement in spite of good compliance after at least 3 months of constant patching. In addition to isoacuity of the eyes, other criteria have been proposed to define a cure of amblyopia that protects against relapse. These are equal reading ability with each eye and a switch of fixation by an almost invisible 1.0 Bangerter foil¹¹¹ (p. 547) and the presence of free and spontaneous alternation of fixation and isoaccommodation.⁴³

COMPLIANCE WITH TREATMENT. A major cause of nonresponsiveness to treatment can be the lack of compliance.^{121, 129, 156} A coin-sized occlusion dose monitor was developed to measure compliance objectively by recording differences in the temperature between the front and the back of the device which is glued to the front of the patch.²⁰⁶ When the patch is on the eye, the temperature at the back of the monitor is higher than at the front. The data are collected for a week and read out on a computer. Although the parents knew that a recording was being made, compliance was mediocre in many cases. In another study compliance was evaluated statistically in a group of 961 children followed for 10 years in seven orthoptic clinics in Great Britain.²⁰⁷ An overall compliance of 51% was found. Although objective parameters were difficult to establish, a good correlation existed between lack of compliance and social deprivation.²⁴

PREVENTION OF RECURRENCES. Once the vision of the amblyopic eye has been improved to the level of the fixating eye, the patient must be followed closely. Amblyopia tends to recur until children have reached 8 to 10 years of age or even older because of the persistence of inhibitory effects from the fixating eye, and it may be necessary to resume occlusion.^{74, 82, 195} Risk factors for recurrence have been identified and include deep amblyopia prior to therapy, a combination of strabismus and anisometropia,¹¹⁷ or a hypermetropic anisometropia in excess of 1.5D.¹¹⁸ However, in most instances the visual result can be maintained by reducing the level of visual acuity of the sound eye slightly below that of the amblyopic eye. This can be accomplished by overcorrecting or undercorrecting the refractive error of the dominant eye, by using Bangerter's precalibrated occlusion foils (see p. 547), or by fully occluding the

sound eye for several hours during the day while the child watches television or performs home exercises.^{43, 88, 123, 165, 236} Such training occasionally may be effective even in children who have failed to respond to conventional occlusion therapy and can be carried out at home under parental supervision.^{64, 127, 198} A most effective form of “maintenance” therapy aimed at maintaining a good visual result in children whose visual acuity has been equalized by occlusion treatment and who are at risk of having a recurrence of amblyopia is alternating penalization.¹⁴⁷

AMBLYOPIA IN UNILATERAL HIGH MYOPIA. A special problem arises when amblyopia is associated with unilateral high myopia. Strabismus is not always present in these patients, and the amblyopia frequently remains undetected until such children have reached school age. Using the conventional method of full correction of the refractive error followed by occlusion of the sound eye, Rosenthal and von Noorden¹⁸⁵ (see also Pollard and Manley¹⁶⁷) reported significant improvement in visual acuity and binocular vision in 7 (24%) of 29 patients so treated. The degree of improvement of visual acuity could be correlated with the age at which therapy was carried out, with milder degrees of amblyopia, and with unilateral myopia of less than $-15D$. The presence or absence of strabismus did not influence the therapeutic results. Jampolsky and coworkers⁹⁶ reported less favorable therapeutic results in patients with unilateral high hypermetropia. Awaya¹³ supported the opposite, namely that anisohypermetropia responds to treatment better than anisomyopia. In our experience no significant difference exists in the treatment results of anisohypermetropic and anisomyopic amblyopes.¹²

AMBLYOPIA AND LATENT NYSTAGMUS. The literature contains several warnings against the use of occlusion therapy in patients with latent nystagmus,^{67, 115, 124} the implication being that occlusion of the sound eye exacerbates the nystagmus and thus decreases rather than enhances the function of the amblyopic eye. We cannot support this view after having shown that a significant improvement of visual acuity can be obtained despite latent nystagmus by full-time patching of the sound eye.¹⁵¹ Simonsz²⁰⁴ described oscillopsia after occlusion of the better eye in such cases. Oscillopsia improved and disappeared eventually. These findings emphasize the need for full-time rather than hourly occlusion in the presence of latent nystagmus.²⁰⁵ Other authors have recom-

mended a combination of occlusion of the sound eye with topical application of 1% cyclopentolate hydrochloride^{224, 225} or 1% atropine sulfate³⁸ to the eyes. This treatment is based on the observation that cycloplegic drugs tend to decrease the amplitude, velocity, and, to a lesser degree, the frequency of latent nystagmus.^{224, 225} On the basis of our findings¹⁵¹ we concluded that conventional occlusion treatment should be given preference over the more complex combined treatment with occlusion and cycloplegics.

ECCENTRIC FIXATION. When the high incidence of eccentric fixation in amblyopes became known following development of the visuscope (see Chapter 14), many investigators voiced the opinion that after 2 years of age occlusion of the sound eye is contraindicated in amblyopes with eccentric fixation because it may reinforce anomalous fixation behavior.^{8, 21, 22, 50, 59, 136} These and other authors reasoned that the amblyopic eye should be occluded to break up abnormal fixation behavior (inverse occlusion). However, others reported that occlusion of the sound eye (direct occlusion) is effective until 5 years of age, regardless of fixation behavior.^{65, 180, 187, 197} To settle this controversy, a collaborative study was performed independently, using the same criteria, at the Wilmer Institute, Baltimore, and at the University Eye Clinic in Tübingen, Germany, in which the effects of direct and inverse occlusion were compared in 181 patients with eccentric fixation.^{126, 141} This study showed conventional occlusion of the sound eye to be the most effective method, particularly in younger children (see also Parks and Friendly¹⁵⁷). On the other hand, inverse occlusion usually did not normalize fixation behavior and in some cases actually intensified the amblyopia. We now use inverse occlusion only during the initial phase of therapy of eccentric fixation in children older than 5 years of age so that the patient will become accustomed to wearing a patch for a few days before switching the occluder to the sound eye. Steady peripheral eccentric fixation in a child older than 4 years is in our experience an unfavorable prognostic sign.

ORGANIC AMBLYOPIA. The fact that functional (reversible) amblyopia may be superimposed on an organic defect of the fovea and may improve after occlusion treatment^{31, 107-109, 210, 227} has been mentioned (see p. 253).

OCCCLUSION AND TIMING OF SURGERY. Although views to the contrary have been voiced,^{110, 220} most strabismologists would agree

that the treatment of amblyopia should precede surgical alignment in patients with infantile esotropia.¹⁴⁶ First, and as mentioned before, the earlier treatment of amblyopia is done, the briefer the treatment time and the better the results. Surgery may delay treatment and thus prolong treatment time. Second, by far the most common postoperative result in infantile esotropia is small angle esotropia or microtropia (Chapter 16). The monitoring of visual acuity differences in the two eyes is essential to prevent occlusion amblyopia but becomes difficult in infants or small children once the angle has been reduced surgically or the patient has a residual microtropia. Third, surgical alignment fosters complacency among less well-educated parents who may feel that once the eyes are “straight,” all problems are over and close postoperative observation and patching become superfluous.^{42, 45} Finally, since normal visual acuity in both eyes is a prerequisite of stable fusion, it is reasonable to assume that in those cases with postoperative subnormal binocular vision or microtropia, fusion is easier to maintain when visual acuity is equal in both eyes than when one eye is amblyopic. These comments should not gainsay the observation that visual acuity may in some instances spontaneously improve after surgical alignment of a deeply amblyopic eye with eccentric fixation (see p. 264). For this reason, we occasionally perform surgery in older children with deep amblyopia, eccentric fixation, and a large angle esotropia before commencing with occlusion treatment.

Early surgery does not protect against the development of amblyopia. On the contrary, the prevalence of amblyopia in long-standing untreated infantile esotropia has been reported to be lower than in patients operated on early.¹³⁶

Red Filter Treatment

In treating amblyopia associated with eccentric fixation, Brinker and Katz³³ advocated total occlusion of the sound eye and application of a red filter that excludes wavelengths shorter than 640 nm (Kodak gelatin Wratten filter No. 92) on the spectacles frame before the amblyopic eye. The rationale behind this treatment is explained by Brinker and Katz on the basis that predominantly rod-populated areas of the retina are used for eccentric fixation. The red light is ineffective in stimulating this area because of the reduced number of cones as compared with those in the fovea.

Thus a suitable red filter motivates the patient to use the fovea and inhibits use of the eccentric fixation area. Once fixation has become parafoveal or central, the red filter is removed, and occlusion of the sound eye is continued until visual acuity of the amblyopic eye becomes normal. The method has been effective in improving fixation behavior in some patients with eccentric fixation.^{33, 56, 127, 142, 176} It is, however, an unusual child that will put up with wearing such a conspicuous device for any length of time and it is for this reason that we no longer use this treatment. A blue filter has been suggested with similar reasoning to stimulate the parafoveal areas of the amblyopic eye, which appeared to be depressed when tested with visual evoked response.¹³¹ Encouraging results were reported, which need further verification.

Prisms

In the past, attempts have been made to treat strabismic amblyopia with prisms in combination with occlusion or as an isolated mode of therapy.^{10, 30, 63, 114, 137, 164, 186} No convincing data have ever been reported to establish the advantage of these methods over conventional occlusion. We do not advocate the use of prisms in the treatment of amblyopia.

Penalization

In view of the difficulties encountered with occlusion therapy in some children and the occasional complication of occlusion amblyopia, alternative methods for the treatment of amblyopia have been explored. The use of atropine in the fixating eye in an attempt to blur vision and compel the amblyopic eye to fixate at near was probably first advocated in 1903 by Worth^{226, p.502} and later by Peter,¹⁵⁸ Chavasse,^{50, p.502} Guibor,⁸⁴ Lowe,¹²² and many others. Knapp and Capobianco¹⁰³ combined atropinization of the fixating eye with miotics (DFP) instilled at bedtime in the amblyopic eye of hypermetropic children who refused to tolerate complete occlusion. According to these authors, these drugs will cause the patient to prefer the amblyopic eye for near fixation while the sound eye continues to fixate at distance (see also Foley-Nolan et al.,⁷⁵ Johnson and Antuna,⁹⁸ Wallace²¹⁸).

Pfandl¹⁵⁹ observed that esotropic patients who have unilateral mild myopia may use the myopic eye for near fixation and the emmetropic eye for

distance fixation and that this alternating fixation behavior prevents development of anomalous retinal correspondence. He therefore advocated the addition of a plus lens to one eye, forcing the patient to use that eye for near fixation and the fellow eye for distance fixation. This therapy has become popular under the odd term *penalization*.²²² The principle of penalization is to decrease near vision of the fixating eye, that is, to “penalize” it (as if it had committed a crime!) by atropinization^{168, 169} or to decrease distance vision of the fixating eye by optical overcorrection and atropinization.¹⁷² The amblyopic eye is overcorrected with lenses ranging from +1.00D sph to +3.00D sph.^{28, 29, 49, 63, 86, 184, 222} This treatment forces the patient to develop alternation between the amblyopic eye for near fixation and the sound eye for distance fixation. When amblyopia is cured, alternation is reinforced, and the therapeutic results are maintained by *alternating penalization* with two pairs of glasses containing +3.00D sph overcorrection for the right or left eye.^{147, 174}

Even though current advocates of penalization cite excellent results,^{177, 178} and some use it even in preference to occlusion treatment,¹⁵⁴ we have not been convinced of its advantages over conventional amblyopia therapy. In the first place, the inhibitory influence originating from stimulating the sound eye (see Chapter 14) is not totally excluded by merely blurring its vision. Second, except in moderate or high hypermetropia, atropinization does not sufficiently decrease visual acuity of the sound eye so that the patient prefers the amblyopic eye for fixation. Moreover, in our experience, if penalization by optical overcorrection of the fixating eye is used, the child will simply take the glasses off to gain better vision. However, atropinization of the sound eye combined with removal of the corrective lens has been useful in our hands in treating hypermetropic children with amblyopia, as illustrated by Case 24–3.

CASE 24–3

A 4-year-old hyperactive girl with a history of infantile esotropia had worn glasses for a year. Amblyopia of the left eye had been diagnosed elsewhere, and attempts to occlude the right eye were unsuccessful because of a total lack of cooperation.

December 21, 1971

Best corrected visual acuity: OD 6/12
OS 3/60

Refraction:

OD +6.00D sph +2.00D cyl ax 75°

OS +6.00D sph +2.00D cyl ax 95°

Fixation: OS eccentric; nasal disk

Ocular deviation: 30^A esotropia at distance; 60^A esotropia at near

Treatment: removal of correcting lens and atropinization OD; full correction OS

February 16, 1972

Visual acuity: OD 6/12
OS 6/60

May 5, 1972

Visual acuity: OD 6/12
OS 6/30

August 2, 1972

Visual acuity: OD 6/12
OS 6/9

The patient still preferred the right eye for distance and near fixation. Fixation in the left eye was central and unsteady. At this point, it was decided to perform a recession-resection operation on the left eye to align the eyes. The patient had maintained good vision in the left eye and had an esotropia of 5^A at near and distance fixation when last seen 12 months after surgery.

The superiority of occlusion therapy notwithstanding, penalization (especially at near and in hypermetropic patients) in its “total” form has been in our hands a useful alternative to occlusion therapy in patients with milder forms of amblyopia and central fixation. We have used this method with moderate success in patients who would not or could not tolerate a conventional patch (see also Gregerson and coworkers⁸³) and advocate slight optical blurring of the fixating eye in children wearing glasses or alternating penalization to prevent recurrence of amblyopia.^{147, 150} Penalization is also useful to induce a patient to switch fixation to the fellow eye when differences in the size of the deviation depend on which eye is fixating (see Fig. 24–1).

Repka and coworkers¹⁷⁸ determined the minimal amount of plus spherical lens power necessary to switch fixation preference from the sound to the amblyopic eye by using a Reichert vectographic slide (American Optical Co.) with alternately polarized letters. This subjective test for a switch of fixation does not take into account that fixation with the normal eye may continue even though its vision is artificially reduced to a level lower than that of the amblyopic eye.⁴³

In the presence of a sizable strabismus, the power of the penalizing lens should be based on the switch of fixation. In the case of microstrabis-

mus, a prism is placed before the eye to be penalized. The direction of the prism is irrelevant. The minimal power of the penalizing lens that eliminates a noticeable movement in the direction of the apex of the prism in the fellow eye is prescribed.⁴⁶

Penalization does not, as claimed by Quéré¹⁷² as one of its advantages, prevent occlusion amblyopia. Worth²²⁶ reported two cases of amblyopia developing in atropinized eyes. We have confirmed this observation¹⁴⁴ and additional cases have been reported.^{106, 154}

Penalization has also been claimed to improve binocular functions¹⁷² because with this method a position is said to exist in subjective space at a certain distance from the patient where both eyes see equally well. This assumption is based on geometric calculations, has never been validated, and the parameters employed for defining the binocular outcome (Worth four dots, Titmus stereo fly, and Randot Circles stereo test)²⁰³ are questionable. On the other hand, the same group²⁰² found equally good results in the binocular outcome with penalization and with part-time occlusion. At this time no convincing data have been presented that show a beneficial effect of penalization on binocular functions.

Drugs

Attempts have been made to treat suppression and amblyopia pharmacologically. While modest and mostly temporary gains of visual acuity have been reported after levodopa or similar agents used in the treatment of parkinsonism^{43, 44, 47, 48, 113, 133} (see p. 257), it is too early to predict whether pharmacologic treatment of amblyopia will become an accepted mode of therapy.

Pleoptics

Since its early beginning, therapy for amblyopia has been limited to occlusion of the sound eye to which miscellaneous exercises were added to enforce use of the amblyopic eye.¹⁸⁰ Most of these exercises are now of historical interest only. The results were disappointing in older children with eccentric fixation, a condition thought for many years to be unamenable to any form of therapy. Comberg,⁵⁴ in 1936, introduced an apparatus designed specifically to stimulate the macula in eccentric fixators, but his method never became popular and was soon forgotten. In the 1940s, Bangerter¹⁸

began systematic active therapy of amblyopia with eccentric fixation using a method for which he coined the term *pleoptics* (Gr. *pleion*, more; *optikos*, eyesight). The following discussion of pleoptics is limited to its principles, and the reader is referred to other publications in which this method is described in detail.^{19, 57, 58, 67, 94, 120, 139, 171, 180, 190}

The principle of Bangerter's method¹⁹ was to dazzle the eccentrically fixating retinal area with bright lights while protecting the fovea with a disk projected onto the fundus, followed by intermittent stimulation of the macula with flashes of light. This treatment is administered under direct observation of the fundus by the therapist, using a modification of the Gullstrand ophthalmoscope (pleoptophor) and is continued until the central scotoma diminishes and fixation becomes central. For use in combination with the dazzling method, Bangerter invented numerous instruments to train deficient oculomanual coordination, separation difficulties, and fusional amplitudes.

Cüppers^{57, 58} used a different approach to treat eccentric fixation, the principles of which are based on attempts to reestablish, at least temporarily, the physiologic superiority of the fovea over the retinal periphery. This is done by an ingenious application of afterimages elicited by a modified ophthalmoscope (euthyscope) that contains projectable black disks of different sizes. While the fovea is protected with a black mark, the retinal periphery, including the area used for eccentric fixation, is dazzled with bright light. A negative afterimage is thus provoked and enhanced by flickering room illumination. The clear spot in the center of the afterimage corresponds to the position of the fovea, which has momentarily regained its functional superiority over the eccentrically fixating area. This treatment is complemented by fixation exercises using Haidinger's brushes (coordinator) or a combination of Haidinger's brushes and afterimages. Cüppers held the view that eccentric fixation is maintained by a shift of the principal visual direction from the fovea to the eccentric fixation area (see Chapter 14), and his method is aimed at reestablishing the principal foveal visual direction. In Chapter 14, we discuss our reasons for rejecting this view of the pathogenesis of eccentric fixation.

A wave of enthusiasm followed introduction of pleoptics, spreading throughout the ophthalmic literature, and numerous reports have attested to its value in treating amblyopia with central and eccentric fixation.^{20, 57, 58, 60} However, it soon be-

came apparent that pleoptic treatment should be limited to older and more cooperative children and that considerable time and effort were required before appreciable results were noted. In Europe this led to the establishment of *Sehschulen* (“vision schools”) to which children were admitted (and readmitted) for several weeks or even months of daily therapy sessions. Eventually, studies were published that questioned the long-term effectiveness of pleoptic therapy, its superiority over conventional occlusion treatment, and its practicality from a socioeconomic point of view.^{74, 149, 181, 191, 217} The enthusiasm of most ophthalmologists and orthoptists for pleoptics has waned and, fortunately, so has the prevalence of eccentric fixation and deep amblyopia in older children for whom this method was originally designed. It is encouraging that most patients are now referred to the ophthalmologist at an age before eccentric fixation is firmly established and when conventional occlusion treatment alone is effective.

Although the practical importance of pleoptics has faded and, with some exceptions,^{104, 211} pleoptics is no longer practiced, the principles of pleoptic treatment should not be forgotten. This method is the only one available for older amblyopic patients who lose their good eye and whose amblyopic eye does not recover vision spontaneously. Bangerter and Cüppers deserve credit for rejuvenating interest in the therapy of amblyopia, for advancing our knowledge of its pathophysiology, and for introducing new diagnostic methods.

CAM Treatment

Campbell and coworkers,⁴⁰ in 1978, proposed a new treatment for amblyopia, the main feature of which was 7 minutes of stimulation of the amblyopic eye by slowly rotating, high-contrast, square wave gratings of different spatial frequencies (CAMbridge stimulator). The sound eye remained open between the weekly treatment sessions and was patched only during the brief period of stimulation. The rationale for this treatment was based on the assumption that rotating gratings provide stimulation specific for the spatial orientation of visual cortical neurons. In spite of encouraging results reported by the originators of this therapy and by other authors, the value of this treatment has not been confirmed by subsequent studies (for review, see Mehdorn and coworkers¹³⁰).

Other Types of Treatment

Over the years various alternative approaches have been suggested for the treatment of amblyopia.⁴³ In essence, none of these has been proved with a controlled study to be equal or superior to classic occlusion therapy. Among these methods are occlusive sectors that selectively mask portions of the spectacles lenses worn by the patient and the use of biofeedback. Unfortunately, these treatments have become quite fashionable in some parts of the world, particularly among therapists who are not surgeons. The inherent risk of these procedures is that children who would benefit from conventional treatment lose the opportunity to have their amblyopia eliminated.

Rationale for Treatment

Finally, a brief comment with respect to the *rationale of all amblyopia treatment* is in order. Are our efforts warranted to treat amblyopia energetically in childhood only to have visual acuity decrease in many instances once treatment is discontinued? What happens to the untreated adult amblyope? Most people will function adequately despite amblyopia, even though the lack of stereopsis may constitute a handicap in persons with certain occupations. However, an important health hazard exists in that the sound eye could become diseased or injured. In case of trauma, the normal eye is injured more frequently than the amblyopic one.

Even though it is well known that spontaneous recovery of amblyopia is possible in adulthood after loss of the good eye,^{68, 88, 214} such recovery by no means occurs in every instance.

It is often said that once amblyopia has been improved, vision will always remain available in that eye if vision is lost in the sound eye, even if the amblyopic eye is allowed to deteriorate after treatment. Yet it is not known to what extent recovery depends on previous attempts to improve vision, at least temporarily, in amblyopic eyes during childhood. Until such information becomes available, we have the obligation to treat amblyopia by the most appropriate means until the best possible visual result is reached and also to maintain this result by supportive therapy to prevent a recurrence.

In the recent wave of conducting “scientifically correct” clinical research, the need for controlled studies to establish the validity of amblyopia treat-

ment has been voiced, and the value of preschool visual screening has been questioned.²⁰⁸ Considering that the age at which treatment is begun is of the essence in determining its outcome, withholding treatment in a control group just to prove the obvious and to satisfy the statisticians raises serious ethical questions (see also Simons and Preslan²⁰¹). If we can accept without a controlled study that aspirin is an effective analgesic and that cataract extraction improves vision, we should also be able to accept that occlusion therapy for amblyopia is effective.

REFERENCES

1. Abraham SV: The use of miotics in the treatment of convergent strabismus and anisometropia: A preliminary report. *Am J Ophthalmol* 32:233, 1949.
2. Abraham SV: Intraepithelial cysts of the iris. Their production in young persons and possible significance. *Am J Ophthalmol* 37:327, 1954.
3. Abraham SV: The use of an echothiophate-phenylephrine formulation (echophenylene-B3) in the treatment of convergent strabismus and amblyopia with special emphasis on iris cysts. *J Pediatr Ophthalmol* 1:68, 1964.
4. Adelstein FE, Cüppers C: Probleme der operativen Schielbehandlung. *Ber Zusammenkunft Dtsch Ophthalmol Ges* 69:580, 1969.
5. Adelstein FE, Cüppers C: La traitement de la correspondance rétinienne anormale à l'aide de prismes. *Ann Ocul* 203:445, 1970.
6. Adler FH: Foveal fixation. *Am J Ophthalmol* 56:483, 1963.
7. Albert DG, Hiles DA: Myopia, bifocals, and accommodation. *Am Orthopt J* 19:59, 1969.
8. Arruga A: Effect of occlusion of amblyopic eye on amblyopia and eccentric fixation. *Trans Ophthalmol Soc U K* 82:45, 1962.
9. Aulhorn E: Phasendifferenz-Haploskopie: Eine neue Methode zur Trennung der optischen Eindrücke beider Augen. *Klin Monatsbl Augenheilkd* 148:540, 1966.
10. Aust W: The use of prisms in pre- and post-operative treatment. In Fells P, ed: *The First Congress of the International Strabismological Association*. St Louis, Mosby-Year Book, 1971, p 255.
11. Aust W, Welge-Lüssen L: Effect of prolonged use of prisms on the operative results of strabismus. *Ann Ophthalmol* 3:571, 1971.
12. Avilla C, Noorden GK von: Clinical observations in anisotropic amblyopia. In Lenk-Schäfer M, ed: *Orthoptic Horizons. Transactions of the Sixth International Orthoptic Congress*, Harrogate, UK, 1987, p 113.
13. Awaya S: Management of hypermetropia. *Jpn J Ophthalmol* 135:70, 1973.
14. Awaya S, Miyake Y, Imaizumi Y, et al: Amblyopia in man, suggestive of stimulus deprivation amblyopia. *Jpn J Ophthalmol* 17:69, 1973.
15. Bagolini B: Diagnostic et possibilité de traitement de l'état sensoriel du strabisme concomitant avec des instruments peu dissociants (test des verres striés et barre de filtres). *Ann Ocul* 194:236, 1961.
16. Bagolini B: Postsurgical treatment of convergent strabismus, with a critical evaluation of various tests. *Int Ophthalmol Clin* 6:633, 1966.
17. Baldone JA, Clark WB: Absence of lenticular changes from cholinesterase inhibitors in 205 eyes of children. *J Pediatr Ophthalmol Strabismus* 6:81, 1969.
18. Bangerter A: Behandlung der Amblyopie. *Ophthalmologica* 111:220, 1946.
19. Bangerter A: *Amblyopiebehandlung*, ed 2. Basel, S Karger, 1955.
20. Bangerter A: Orthoptische Behandlung des Begleitschiels, vol 1: Pleoptik (Monokulare Orthoptik). In *Acta 18th Concilium Ophthalmologica Belgium*. Amsterdam, Excerpta Medica, 1958, p 105.
21. Bangerter A: Die Okklusion in der Pleoptik und Orthoptik. *Klin Monatsbl Augenheilkd* 136:305, 1960.
22. Bangerter A: The purpose of pleoptics. *Ophthalmologica* 158:334, 1969.
23. Bangerter A, Steidele M: Wann-Was? Amblyopiebehandlung in der Praxis. St Gall, Switzerland, Pleoptik und Orthoptik-Schule.
24. Beardsell R, Clarke S, Hill M: Outcome of occlusion treatment for amblyopia. *J Pediatr Ophthalmol Strabismus* 36:19, 1999.
25. Bedrossian H, Krewson WE: Isofluorophate versus glasses in evaluating the accommodative element in esotropia. *Arch Ophthalmol* 76:186, 1966.
26. Beir O de: Correspondance anormale et prismes. *Bull Soc Belge Ophtalmol* 159:691, 1971.
27. Bérard PV, Carlotti P, Payan-Papera: Les traitements orthoptiques dans l'espace des correspondances rétinienne anormales. *Bull Soc Ophtalmol Fr* 65:750, 1965.
28. Berrondo P: Contribution à l'étude du traitement de l'amblyopie fonctionnelle par changement de dominance oculaire. *Bull Soc Ophtalmol Fr* 67:569, 1967.
29. Bongrand M: Le traitement de l'amblyopie fonctionnelle par la pénalisation optique. Techniques et résultats. *J Fr Orthopt* 3:45, 1971.
30. Brack B: Penalisation and prism. New results obtained with the method of treating squint amblyopia with eccentric fixation. In Moore S, Meine J, Stockbridge L, eds: *Orthoptics: Past, Present and Future*. New York, Stratton Intercontinental, 1975, p 99.
31. Bradford GM, Kutschke PJ, Scott WE: Results of amblyopia therapy in eyes with unilateral structural anomalies. *Ophthalmology* 99:1616, 1992.
32. Breinin GM, Chin NB, Ripps H: A rationale for therapy of accommodative strabismus. *Am J Ophthalmol* 61:1030, 1966.
33. Brinker WR, Katz SL: New and practical treatment of eccentric fixation. *Am J Ophthalmol* 55:1033, 1963.
34. Buffon M de: Dissertation sur la cause du strabisme ou des yeux louches. *Hist Acad R Sci* 1743, p 231.
35. Burian HM: Use of bifocal spectacles in the treatment of accommodative esotropia. *Br Orthopt J* 13:3, 1956.
36. Burian HM: Occlusion amblyopia and the development of eccentric fixation in occluded eyes. *Am J Ophthalmol* 62:853, 1966.
37. Burian HM: Orthoptics and orthoptists in 1972. *Am Orthopt J* 23:43, 1973.
38. Calcutt C, Crook W: The treatment of amblyopia in patients with latent nystagmus. *Br Orthopt J* 29:70, 1972.
39. Callahan WP, Berry D: The value of visual stimulation during constant and direct occlusion. *Am Orthopt J* 18:73, 1968.
40. Campbell FW, Hess RF, Watson PG, Banks R: Preliminary results of a physiologically based treatment of amblyopia. *Br J Ophthalmol* 62:748, 1978.
41. Campos EC: Rational approach to amblyopia in congenital cataracts. *Eur J Implant Ref Surg* 2:257, 1990.
42. Campos EC: Timing of amblyopia therapy (letter). *Ophthalmology* 101:1157, 1994.
43. Campos EC: Amblyopia. *Surv Ophthalmol* 40:23, 1995.
44. Campos EC: Future directions in the treatment of amblyopia. *Lancet* 349:1190, 1997.
45. Campos EC: Eradicating amblyopia before surgery. *J Pediatr Ophthalmol Strabismus* 35:6, 1998.

46. Campos EC, Leyman IA: Optical penalization in the prevention and treatment of amblyopia. *Am Orthopt J* 30:102, 1980.
47. Campos EC, Bolzani R, Schiavi C, et al: Cytidine-5'-diphosphocholine enhances the effect of part-time occlusion in amblyopia. *Doc Ophthalmol* 93:247, 1997.
48. Campos EC, Schiavi C, Benedetti P, et al: Effect of citicoline on visual acuity in amblyopia: Preliminary results. *Graefes Arch Clin Exp Ophthalmol* 233:307, 1995.
49. Catros A, Garrec A: Unsere Erfahrungen mit der Penalisation in der Behandlung der funktionellen Amblyopie. *Klin Monatsbl Augenheilkd* 161:156, 1972.
50. Chavasse FB: *Worth's Squint or the Binocular Reflexes and the Treatment of Strabismus*. London, Baillière, Tindall & Cox, 1939.
51. Chin NB, Gold AA, Breinin GM: Iris cysts and miotics. *Arch Ophthalmol* 71:611, 1964.
52. Ciancia AO, Melek N: A new treatment for anomalous retinal correspondence in intermittent exotropia. In Fells P, ed: *The First Congress of the International Strabismological Association*. St Louis, Mosby-Year Book, 1971, p 106.
53. Clayette-Hugonnier S: Les procédés de traitement de la correspondance rétinienne anormale par la travail dans l'espace. *Doc Ophthalmol* 23:448, 1967.
54. Comberg W: Ein Gerät zur Uebung des zentralen Sehens bei funktioneller Schwachsichtigkeit. *Ber Dtsch Ophthalmol Ges* 51:441, 1936.
55. Costenbader FD: Round table discussion. In Allen JH, ed: *Strabismus Ophthalmic Symposium II*. St Louis, Mosby-Year Book, 1958, p 484.
56. Cowle JB, Kunst JH, Philpotts AM: Trial with red filter in the treatment of eccentric fixation. *Br J Ophthalmol* 51:165, 1967.
57. Cüppers C: *Moderne Schielbehandlung*. *Klin Monatsbl Augenheilkd* 129:579, 1956.
58. Cüppers C: Grenzen und Möglichkeiten der pleoptischen Therapie. In Hollwich F, ed: *Schielen, Pleoptik, Orthoptik, Operation*. Bücherei Augenarzt 38:1, 1961.
59. Cüppers C: Some reflections on the possibility of influencing the pathological fixation act. *Ann R Coll Surg Engl* 38:308, 1966.
60. Cüppers C, Flynn JT, Vereecken E: Ergebnisse der pleoptischen Therapie unter besonderer Berücksichtigung der Dauerresultate. *Doc Ophthalmol* 23:547, 1967.
61. Decker JH: Shallowing of the anterior chamber following the use of echothiophate (Phospholine) iodide. *J Pediatr Ophthalmol* 9:16, 1972.
62. Deller M, Brack B: Erste Bilanz der modernen Schielbehandlung. *Klin Monatsbl Augenheilkd* 155:712, 1969.
63. Deller M, Brack B: Nouveau procédé de traitement de l'amblyopie strabique à fixation excentrique. *Ophthalmologica* 160:152, 1969.
64. Dobson M: *The Amblyopia Reader. A System of Eye Sight Development*. London, Rembrandt Photographers, 1936.
65. Doden W, Kotowski H: Resultate und Probleme der Frühbehandlung des unilateralen Strabismus convergens. *Ber Dtsch Ophthalmol Ges* 65:475, 1964.
66. Donders FC: *Die Anomalien der Refraction und Accommodation des Auges*, ed 2. Vienna, W Braumüller, 1888, pp 112, 114.
67. Duke-Elder S, Wybar K: *System of ophthalmology*, vol 6: *Ocular Motility and Strabismus*. St Louis, Mosby-Year Book, 1973, p 433.
68. El Mallah MK, Chakravarthy U, Hart P-M: Amblyopia: Is visual loss permanent? *Br J Ophthalmol* 84:952, 2000.
69. Ellis PP: Systemic effects of locally applied anticholinesterase agents. *Invest Ophthalmol Vis Sci* 51:146, 1966.
70. Ellis PP, Esterdahl M: Echothiophate iodide therapy in children: Effect on blood cholinesterase levels. *Arch Ophthalmol* 77:598, 1967.
71. Epelbaum M, Milleret C, Buisseret P, Dufer JL: The sensitive period for strabismic amblyopia in humans. *Ophthalmology* 100:323, 1993.
72. Eustis H, Chamberlain D: Treatment for amblyopia: Results using occlusive contact lens. *J Pediatr Ophthalmol Strabismus* 33:319, 1996.
73. Flemming A, Pigassou R, Garipuy J: Adaptation of a method of prismatic overcorrection for treating strabismus in children one and two years old. *J Pediatr Ophthalmol* 10:154, 1973.
74. Fletcher MC, Silverman SJ, Boyd J, Callaway M: Biostatistical studies: Comparison of the management of suppression amblyopia by conventional patching, intensive hospital pleoptics, and intermittent office pleoptics. *Am Orthopt J* 19:40, 1969.
75. Foley-Nolan A, McCann A, O'Keefe M: Atropine penalisation versus occlusion as the primary treatment for amblyopia. *Br J Ophthalmol* 81:54, 1997.
76. François J, Goes F, James M: Resultats statistiques du traitement de l'amblyopie strabique. *Bull Soc Belge Ophthalmol* 151:351, 1969.
77. Fulton AB, Mayer DL: Esotropic children with amblyopia: Effects of patching on acuity. *Graefes Arch Clin Exp Ophthalmol* 226:309, 1988.
78. Gifford SR: Some notes on the treatment of strabismus. *Br J Ophthalmol* 19:148, 1935.
79. Goldstein JH: The role of miotics in strabismus. *Surv Ophthalmol* 13:31, 1968.
80. Gould A, Fishkoff D, Galin MA: Active visual stimulation: A method of treatment of amblyopia in the older patient. *Am Orthopt J* 20:39, 1970.
81. Graefe A von: Über musculäre Asthenopie. *Graefes Arch Clin Exp Ophthalmol* 8:314, 1862.
82. Gregersen E, Rindziunski E: "Conventional" occlusion in the treatment of squint amblyopia. *Acta Ophthalmol Scand* 43:462, 1965.
83. Gregersen E, Pontoppidan M, Rindziunski E: Optic and drug penalization and favouring in the treatment of squint amblyopia. *Acta Ophthalmol Scand* 52:60, 1974.
84. Guibor GP: The use of atropine in the treatment of motor defects. In Allen JH, ed: *Strabismus Ophthalmic Symposium I*. St Louis, Mosby-Year Book, 1950, p 316.
85. Guibor GP: Some uses of ophthalmic prisms. In Allen JH, ed: *Strabismus Ophthalmic Symposium II*. St Louis, Mosby-Year Book, 1958, p 244.
86. Haase W: Optische Penalisation als therapeutisches Hilfsmittel beim frühkindlichen Strabismus. *Adv Ophthalmol* 35:26, 1978.
87. Haddad HM, Rivera H: Echophenylene-B3 and Phospholine (echothiophate) iodide 0.03% in the management of esotropia. *J Pediatr Ophthalmol* 4:24, 1967.
88. Hamed LM, Glaser JS, Schatz NJ: Improvement of vision in the amblyopic eye following visual loss in the contralateral normal eye: A report of three cases. *Binocular Vision Strabismus Q* 6:97, 1991.
89. Hansell H, Reber M: *The Ocular Muscles. A Practical Handbook on the Muscular Anomalies of the Eye*, ed 2. Philadelphia, P Blakiston's Son, 1912, pp 176 hr ff.
90. Hardesty HH: Occlusion amblyopia. Report of a case. *Arch Ophthalmol* 62:314, 1959.
91. Harrison R: Bilateral lens opacities associated with use of di-isopropyl fluorophosphate eye drops. *Am J Ophthalmol* 50:153, 1960.
- 91a. Hill K, Stromberg A: Echothiophate iodide in the management of esotropia. *Am J Ophthalmol* 53:88, 1962.
92. Hiscox PEA, McCulloch C: Cardiac arrest occurring in a patient on echothiophate iodide therapy. *Am J Ophthalmol* 60:425, 1965.

93. Holbach HT, Noorden GK von, Avilla CW: Changes in esotropia after occlusion therapy in patients with strabismic amblyopia. *J Pediatr Ophthalmol Strabismus* 28:6, 1991.
94. Hugonnier R, Clayette-Hugonnier S: Strabismus, heterophoria, ocular motor paralysis. Clinical ocular motor imbalance. Translated and edited by Véronneau-Troutman S. St Louis, Mosby-Year Book, 1969, p 483.
95. Jampolsky A, Flom M, Thorson JC: Membrane fresnel prisms: A new therapeutic device. In Fells P, ed: *The First Congress of the International Strabismological Association*. St Louis, Mosby-Year Book, 1971, p 183.
96. Jampolsky A, Flom BC, Weymouth FW, Moses LE: Unequal corrected visual acuity as related to anisometropia. *Arch Ophthalmol* 54:893, 1955.
97. Javal E: *Manuel théorique et pratique du strabisme*. Paris, g. Masson, 1896.
98. Johnson DS, Antuna J: Atropine and miotics for treatment of amblyopia. *Am J Ophthalmol* 60:889, 1965.
99. Jones DEP, Watson DM: Angle closure glaucoma precipitated by the use of phospholine iodide for esotropia in a child. *Br J Ophthalmol* 51:783, 1967.
100. Kinyon GE: Anticholinesterase eye drops: Need for caution. *N Engl J Med* 280:53, 1969.
101. Knapp P: The clinical management of accommodative esotropia. *Am Orthopt J* 17:8, 1967.
102. Knapp P: The use of membrane prisms. *Trans Am Acad Ophthalmol Otolaryngol* 79:718, 1975.
103. Knapp P, Capobianco NM: Use of miotics in esotropia. *Am Orthopt J* 6:40, 1956.
104. Koskela PU, Mikkola T, Laatikainen L: Permanent results of pleoptic treatment. *Acta Ophthalmol Scand* 69:39, 1991.
105. Krecke FWC: Brillen voor scheelzienden. *Ned Lancet* 3:1047, 1847.
106. Kubota N, Usui C: The development of occlusion amblyopia following atropine therapy for strabismic amblyopia. *Acta Soc Ophthalmol Jpn* 97:763, 1993.
107. Kushner BJ: Functional amblyopia associated with organic disease. *Am J Ophthalmol* 91:39, 1981.
108. Kushner BJ: Functional amblyopia associated with abnormalities of the optic nerve. *Arch Ophthalmol* 102:683, 1984.
109. Kushner BJ: Successful treatment of functional amblyopia associated with juvenile glaucoma. *Graefes Arch Clin Exp Ophthalmol* 226:150, 1988.
110. Lam G, Repka M, Guyton DL: Timing of amblyopia relative to strabismus surgery. *Ophthalmology* 100:17-51, 1993.
111. Lang J: An efficient treatment and new criteria for cure of strabismic amblyopia: Reading and Bangerter foils. *Binocular Vision Strabismus Q* 14:9, 1999.
112. Laurence JZ, Moon RC: *A Handy Book of Ophthalmic Surgery for the Use of Practitioners*. Philadelphia, HC Lea, 1866, p 67.
113. Leguire LE, Rogers GL, Walson PD, et al: Occlusion and levodopa-carbidopa treatment for childhood amblyopia. *J Am Assoc Pediatr Ophthalmol Strabismus* 2:257, 1998.
114. Lenk M: Das monokulare Fixationsprisma nach Prof. Cüppers. *Augenarzt* 7:212, 1973.
115. Leonardi E, Lischette P: Considerazioni sugli inconvenienti e controindicazioni dell'occlusione nella terapia dell'ambliopia. *Boll Ocul* 51:329, 1975.
116. Letson RD: The use of drugs in the management of strabismus. *Surv Ophthalmol* 14:428, 1970.
117. Levartovsky S, Oliver M, Gottesman N, Shimshoni M: Factors affecting long term results of successfully treated amblyopia: Initial visual acuity and type of amblyopia. *Br J Ophthalmol* 79:225, 1995.
118. Levartovsky S, Oliver M, Gottesman N, Shimshoni M: Long-term effect of hypermetropic anisometropia on the visual acuity of treated amblyopic eyes. *Br J Ophthalmol* 82:55, 1998.
119. Levi DM, Polat U, Hu YS: Improvement in Vernier acuity in adults with amblyopia. Practice makes better. *Invest Ophthalmol Vis Sci* 38:1493, 1997.
120. Links A: Theory of pleoptics. *Int Ophthalmol Clin* 1:747, 1961.
121. Lithander J, Sjöstrand J: Anisometropic and strabismic amblyopia in the age group 2 years and above: A prospective study of the results of treatment. *Br J Ophthalmol* 75:111, 1991.
122. Lowe RF: The use of atropine in the treatment of amblyopia ex anopsia. *Med J Aust* 50:725, 1963.
123. Ludwig IH, Parks MM, Jetson PP: Long-term results of bifocal therapy for accommodative esotropia. *J Pediatr Ophthalmol Strabismus* 26:264, 1989.
124. Lyle KT, Bridgeman GJO: Worth and Chavasse squint, ed 9. London, Tindall & Cox, 1959, p 51.
125. Mackensen G: *Theorie und Praxis der Schielbehandlung*. *Klin Monatsbl Augenheilkd* 152:731, 1968.
126. Mackensen G, Kröner B, Postic G, Kelok W: Untersuchungen zum Problem der exzentrischen Fixation. *Doc Ophthalmol* 23:228, 1967.
127. Malik SRK, Gupta AK, Choudry S: The red filter treatment of eccentric fixation. *Am J Ophthalmol* 67:586, 1969.
128. Maraini G, Pasino L: Development of normal binocular vision in early convergent strabismus after orthophoria. *Br J Ophthalmol* 49:154, 1965.
129. Mazow ML, Chuang A, Vital MC, Prager T: Outcome study in amblyopia: Treatment and practice pattern variations. *J Am Assoc Pediatr Ophthalmol Strabismus* 4:1, 2000.
130. Mehdorn E, Mattheus S, Schuppe A, et al: Treatment for amblyopia with rotating gratings and subsequent occlusion: A controlled study. *Int Ophthalmol* 3:161, 1981.
131. Metzler U, Ham O, Flores V, et al: Blue filter amblyopia treatment protocol for strabismic amblyopia: A prospective comparative study of 50 cases. *Binocular Vision Strabismus Q* 13:241, 1998.
132. Miller JE: A comparison of miotics in accommodative esotropia. *Am J Ophthalmol* 49:1350, 1960.
133. Mohan K, Dhankar V, Sharma V: Visual acuity after levodopa administration in amblyopia. *J Pediatr Ophthalmol Strabismus* 38:61, 2001.
134. Morton WR, Drance SM, Fairclough M: Prospective study of the effect of echthiophate iodide on the lens. *Am J Ophthalmol* 68:1003, 1969.
135. Moseley MJ, Fielder AR, Irwin M, et al: Effectiveness of occlusion therapy in ametropic amblyopia: A pilot study. *Br J Ophthalmol* 81:956, 1997.
136. Murray ADN, Calcutt C: The incidence of amblyopia in longstanding untreated infantile esotropia. In Campos EL, ed: *Strabismus and Ocular Motility Disorders*. Houndmills, UK, Macmillan 1990, p 45.
137. Nawratzki I, Oliver M: Eccentric fixation managed with inverse prism. *Am J Ophthalmol* 71:549, 1971.
138. Nemetz UR: Zur Frage der Okklusionsbehandlung bei Amblyopie. *Acta Ophthalmol Scand* 32:351, 1954.
139. Noorden GK von: Treatment of squint amblyopia, with the after-image method. *Am J Ophthalmol* 47:809, 1959.
140. Noorden GK von: Prophylaxis of amblyopia. *J Pediatr Ophthalmol Strabismus* 1:35, 1964.
141. Noorden GK von: Occlusion therapy in amblyopia, with eccentric fixation. *Arch Ophthalmol* 73:776, 1965.
142. Noorden GK von: The etiology and pathogenesis of fixation anomalies in strabismus. *Trans Am Ophthalmol Soc* 67:688, 1969.
143. Noorden GK von: Experimental amblyopia in monkeys.

- Further behavioral and clinical correlations. *Invest Ophthalmol Vis Sci* 12:721, 1973.
144. Noorden GK von: Amblyopia caused by unilateral atropinization. *Ophthalmology* 88:131, 1981.
 145. Noorden GK von: Störungen des Binokularsehens und ihre Behandlung. *Fortschr Ophthalmol* 80:387, 1983.
 146. Noorden GK von: Treatment of amblyopia and surgical outcome (letter). *J Pediatr Ophthalmol Strabismus* 35:5, 1998.
 147. Noorden GK von, Attiah F: Alternating penalization in the prevention of amblyopia recurrence. *Am J Ophthalmol* 102:473, 1986.
 148. Noorden GK von, Jenkins RH: Accommodative amplitude in children wearing bifocals. In Lennerstrand G, ed: *Update on Strabismus and Pediatric Ophthalmology*. Boca Raton, FL, CRC Press, 1995, p 201.
 149. Noorden GK von, Lipsius RMC: Experiences with pleoptics in 58 patients with strabismic amblyopia. *Am J Ophthalmol* 58:41, 1964.
 150. Noorden GK von, Milam J: Penalization in the treatment of amblyopia: Preliminary experiences. *Am J Ophthalmol* 88:511, 1979.
 151. Noorden GK von, Avilla C, Sidikaro Y, LaRoche R: Latent nystagmus and strabismic amblyopia. *Am J Ophthalmol* 103:87, 1987.
 152. Noorden GK von, Morris J, Edelman P: Efficacy of bifocals in the treatment of accommodative esotropia. *Am J Ophthalmol* 85:829, 1978.
 153. Noorden GK von, Springer F, Romano P, Parks M: Home therapy for amblyopia. *Am Orthopt J* 20:46, 1970.
 154. North RV, Kelly ME: Atropine occlusion in the treatment of strabismic amblyopia and its effect upon the non-amblyopic eye. *Ophthalmic Physiol Opt* 11:113, 1991.
 155. Oppel O: Über die soziale Bedeutung und die Behandlung des Begleitschielens sowie der einseitigen Schielamblyopie. *Med Welt* 35:1709, 1963.
 156. Paliaga GP: Major review: Controversies in functional amblyopia. *Binocular Vision Strabismus Q* 12:155, 1997.
 157. Parks MM, Friendly DS: Treatment of eccentric fixation in children under 4 years of age. *Am J Ophthalmol* 61:395, 1966.
 158. Peter LC: *The Extra-Ocular Muscles. A Clinical Study of Normal and Abnormal Ocular Motility*, ed 2. Philadelphia, Lea & Febiger, 1936, p 194.
 159. Pfandl E: Ein neuer Weg zur Verhinderung der Ausbildung einer anomalen retinalen Korrespondenz beim Strabismus convergens concomitans. In *Acta of the 17th Concilium Ophthalmologica Belgium*. Brussels, Imprimerie Médicale et Scientifique, 1959, p 202.
 160. Piantanida A, Vergani D: Successful occlusion therapy in compliant amblyopic elderly children. In *Spiritus M*, ed: *Transactions of the 25th Meeting of the European Strabismological Association*, Jerusalem, September 1999. Lisse, The Netherlands, Aeolus Press, 2000, p 41.
 161. Pigassou R: Prisms in strabismus. *Int Ophthalmol Clin* 6:519, 1966.
 162. Pigassou R: Examination of binocular vision in polarized light. In Arruga A, ed: *International Strabismus Symposium*, University of Giessen, Germany, 1966. Basel, S Karger, 1968, p 240.
 163. Pigassou R, Garipuy J: Traitement du strabisme dans l'espace libre. *Arch Ophtalmol (Paris)* 26:445, 1966.
 164. Pigassou R, Garipuy J: Traitement de la fixation excentrique strabique par le port d'un prisme et l'occlusion. *Bull Mem Soc Fr Ophtalmol* 79:367, 1966.
 165. Pigassou R, Garipuy J: Les différents modes d'action des prismes dans la vision. Leurs applications. *Bull Soc Ophtalmol Fr* 66:934, 1966.
 166. Pine L, Shipmann S: The influence of occlusion therapy on esodeviations. *Am Orthopt J* 32:61, 1982.
 167. Pollard ZF, Manley D: Long-term results in the treatment of unilateral high myopia with amblyopia. *Am J Ophthalmol* 78:397, 1972.
 168. Poulard M: Amblyopie par strabisme. *Ann Ocul* 158:95, 1921.
 169. Pouliquen P: Début du traitement de l'amblyopie. *Bull Soc Ophtalmol Fr* 59:82, 1959.
 170. Pouliquen P: Surcorrection optique et angle strabique. *Bull Soc Ophtalmol Fr* 64:742, 1964.
 171. Priestly BS: Pleoptic instruments and methods. *Int Ophthalmol Clin* 1:787, 1961.
 172. Quéré MA: Die Methoden der Penalisation in der Behandlung des Strabismus convergens. *Klin Monatsbl Augenheilkd* 161:140, 1972.
 173. Quéré MA, Lavenant G, Péchereau A, et al: Les diplopies incoercibles post-thérapeutiques. *J Fr Orthopt* 25:191, 1993.
 174. Quéré MA, Rossazza C, Delplace MP: Les techniques de pénalisation a la période préorthoptique du strabisme convergent. *Bull Soc Ophtalmol Fr* 69:365, 1969.
 175. Qurrah, Thabit Ibn: *Vision and Perception*. Translated and edited by Wafai MZ, Riyadh, Saudi Arabia, Obiekan Publishing House, 1991.
 176. Ratiu E, Reiter E: Results obtained with the red filter method in the treatment of amblyopia with eccentric fixation. *J Pediatr Ophthalmol* 3:28, 1966.
 177. Repka MX, Ray JM: The efficacy of optical and pharmacological penalization. *Ophthalmology* 100:769, 1993.
 178. Repka MX, Gallin PF, Scholz RT, Guyton D: Determination of optical penalization by vectographic fixation reversal. *Ophthalmology* 92:1584, 1985.
 179. Réthy I: Stabilized accommodative factor in esotropia. *Int Ophthalmol Clin* 11:27, 1971.
 180. Revell MJ: *Strabismus. A History of Orthoptic Techniques*. London, Barrie & Jenkins, 1971, pp 180 hr ff.
 181. Richter S: Erfahrungsbericht über pleoptische und orthoptische Behandlungsmethoden. *Klin Monatsbl Augenheilkd* 137:155, 1960.
 182. Ripps H, Breinin GM, Baum JL: Accommodation in the cat. *Trans Am Ophthalmol Soc* 59:176, 1961.
 183. Ripps H, Chin NB, Siegel IM, Breinin GM: The effect of pupil size on accommodation, convergence, and the AC/A ratio. *Invest Ophthalmol* 1:127, 1962.
 184. Ron A, Nawratzki K: Penalization treatment of amblyopia: A follow-up study of 2 years in older children. *J Pediatr Ophthalmol Strabismus* 19:137, 1982.
 185. Rosenthal R, Noorden GK von: Clinical findings and therapy in unilateral high myopia associated with amblyopia. *Am J Ophthalmol* 71:873, 1971.
 186. Rubin W: Reverse prism and calibrated occlusion in the treatment of small angle deviations. *Am J Ophthalmol* 59:271, 1965.
 187. Sachsenweger R, Walther R: Möglichkeiten, Grenzen und Ergebnisse der Amblyopieprophylaxe und Frühbehandlung bei schielenden Kindern. *Klin Monatsbl Augenheilkd* 144:230, 1964.
 188. Sattler CH: Erfahrungen über die Beseitigung der Amblyopie und die Wiederherstellung des binokularen Sehaktes bei Schielenden. *Z Augenheilkd* 63:19, 1927.
 189. Sattler CH: Prismenbrillen zur Frühbehandlung des konkomittierenden Schielens. *Klin Monatsbl Augenheilkd* 84:813, 1930.
 190. Schlossman A: Prognosis, management, and results of pleoptic treatment. *Int Ophthalmol Clin* 1:829, 1961.
 191. Schmidt D, Stapp M: Über die Wirkung der Euthyskop und Okklusionsbehandlung beim Konvergenzschielens. *Klin Monatsbl Augenheilkd* 171:105, 1977.
 192. Scott AB: Botulinum toxin injection into extraocular muscles as an alternative to strabismus surgery. *Ophthalmology* 87:1044, 1980.

193. Scott AB: Botulinum toxin injection of the eye muscles to correct strabismus. *Trans Am Ophthalmol Soc* 79:734, 1981.
194. Scott AB, Rosenbaum A, Collins CC: Pharmacologic weakening of extraocular muscles. *Invest Ophthalmol Vis Sci* 12:924, 1973.
195. Scott WB, Dickey CF: Stability of visual acuity in amblyopic patients. *Graefes Arch Clin Exp Ophthalmol* 226:154, 1988.
196. Scott WE: Office use of prisms. In *Symposium on Strabismus: Transactions of the New Orleans Academy of Ophthalmology*. St Louis, Mosby-Year Book, 1978, p 91.
197. Scully JP: Early intensive occlusion in strabismus with noncentral fixation. Preliminary results. *BMJ* 2:1610, 1961.
198. Sédan J: *Post cure de l'amblyope rééduqué*. Paris, Masson, 1956.
199. Shaffer RN, Hetherington J: Anticholinesterase drugs and cataracts. *Trans Am Ophthalmol Soc* 64:204, 1966.
200. Simon JW, Parks MM, Price EC: Severe visual loss resulting from occlusion therapy for amblyopia. *J Pediatr Ophthalmol Strabismus* 24:244, 1987.
201. Simons K, Preslan M: Natural history of amblyopia untreated owing to lack of compliance. *Br J Ophthalmol* 83:582, 1999.
202. Simons K, Gotzler KC, Vitale S: Penalization versus part-time occlusion and binocular outcome in treatment of strabismic amblyopia. *Ophthalmology* 104:2156, 1997.
203. Simons K, Stein L, Sener EC, et al: Full-time atropine, intermittent atropine, and optical penalization and binocular outcome in treatment of strabismic amblyopia. *Ophthalmology* 104:2143, 1997.
204. Simonsz HJ: The effect of prolonged monocular occlusion on latent nystagmus in the treatment of amblyopia. *Doc Ophthalmol* 72:375, 1989.
205. Simonsz HJ, Kommerell G: Effect of prolonged monocular occlusion on latent nystagmus. *Neuro Ophthalmol* 12:185, 1992.
206. Simonsz HJ, Polling JR, Voorn R, et al: Electronic monitoring of treatment in patching for amblyopia. *Strabismus* 7:113, 1999.
207. Smith LK, Thompson JR, Woodruff G, Hiscox F: Factors affecting treatment compliance in amblyopia. *J Pediatr Ophthalmol Strabismus* 32:98, 1995.
208. Snowdon SK, Stewart-Brown SL: Preschool vision screening: Results of a systematic review. York, England, Centre for Reviews and Dissemination, 1997 (CDR Report 9).
209. Sprague Eustis H, Chamberlain D: Treatment for amblyopia: Results using occlusive contact lens. *J Pediatr Ophthalmol Strabismus* 33:319, 1996.
210. Summers CG, Romig L, Lavoie JD: Unexpected good results after therapy for anisometropic amblyopia associated with unilateral peripapillary myelinated nerve fibers. *J Pediatr Ophthalmol Strabismus* 28:134, 1991.
211. Timmerman G: The results of penalization therapy. *Doc Ophthalmol* 42:385, 1977.
212. Tsubota K, Yamada M: Treatment of amblyopia by extended-wear occlusion soft contact lenses. *Ophthalmologica* 208:214, 1994.
213. Uhthoff W: Zur "Schiel-Amblyopie." *Klin Monatsbl Augenheilkd* 78:453, 1927.
214. Vereecken EP, Brabant P: Prognosis for vision in amblyopia after loss of the good eye. *Arch Ophthalmol* 102:220, 1984.
215. Verheyden C, Dralands L, d'Horne M, Malfiet O: Résultats du traitement de l'amblyopie strabique. *Bull Soc Belge Ophtalmol* 151:380, 1969.
216. Véronneau-Troutman S: *Prisms in the Medical and Surgical Management of Strabismus*. St Louis, Mosby-Year Book, 1994.
217. Véronneau-Troutman S, Dayanoff S, Stohler T: Conventional occlusion versus pleoptics in the treatment of amblyopia. *Am J Ophthalmol* 78:117, 1974.
218. Wallace DK: Visual acuity after cycloplegia in children: Implications for atropine penalization. *J Am Assoc Pediatr Ophthalmol Strabismus* 3:241, 1999.
219. Walraven F: Cited by Kramer ME: *Clinical Orthoptics: Diagnosis and Treatment*. St Louis, Mosby-Year Book, 1949, p 349.
220. Weakley DR, Holland DR: Effect of ongoing treatment of amblyopia on surgical outcome in esotropia. *J Pediatr Ophthalmol Strabismus* 34:275, 1997.
221. Weiss JB: Amblyopie à fixation excentrique et occlusion. *Arch Ophtalmol (Paris)* 23:176, 1963.
222. Weiss JB, Bourrie F: La pénalisation de l'oeil dominant. *Ann Ocul* 201:827, 1968.
223. Welge-Lüssen L, Bock D: Erfahrungen mit der Prismenbehandlung bei kleinem Schielwinkel. *Klin Monatsbl Augenheilkd* 157:60, 1971.
224. Windsor E: Modification of latent nystagmus. part 2. *Arch Ophthalmol* 80:352, 1968.
225. Windsor E, Burian HM, Milogevic B: Modification of latent nystagmus. pt 1. *Arch Ophthalmol* 80:657, 1968.
226. Worth C: *Squint: Its Causes, Pathology and Treatment*. London, J. Bale, Sons & Danielson, 1903.
227. Yang LLH, Lambert SR: Reappraisal of occlusion therapy for severe structural abnormalities of the optic disc and macula. *J Pediatr Ophthalmol Strabismus* 32:37, 1995.

Chemodeneration of Extraocular Muscles—Botulinum Toxin

The idea of substituting surgery with less invasive methods has been one of the dreams of strabismologists. Despite the success achieved with surgery in the treatment of strabismus, there are some disadvantages. In most instances the operation is performed on normal muscles and there are the risks of tissue scarring and infection or the unknown effects of changing the dynamics of muscle function by shortening the muscle or changing its insertion. Various attempts have been made over the years to change extraocular muscle activity by means other than surgery. Alcohol or anesthetic substances have been injected intramuscularly⁵² but these experiments were not pursued or published since it soon became apparent that the effect of injected anesthetics fades out too rapidly to be effective. In the early 1970s Alan B. Scott of San Francisco began experimenting with chemodeneration of the extraocular muscles in an attempt to find a viable alternative to surgery. He established, first in animal experiments and then in clinical trials, that injection with botulinum toxin type A (Botox, Allergan) is the most effective method to paralyze a muscle temporarily. He also showed that the dreaded systemic side effects of this powerful neurotoxin can be ignored provided a highly diluted solution is used. This was the beginning of pharmacologic treatment of strabismus in our time.^{51, 58} Among numerous contributors to this rapidly developing field, the names

of A. B. Scott, McNeer, Magoon, Lee and Elston, Campos and coworkers, and Lennerstrand and coworkers have become connected with increasing the scope of applications of Botox and with the collection of clinical data on its effectiveness in various forms of strabismus.

Mechanisms of Action

Botox treatment for strabismus is based on the property of this toxin, a competitor of acetylcholinesterase at the neuromuscular junction, to cause a flaccid paralysis of the injected muscle. This effect is temporary, because reinnervation takes place within 40 to 60 days and the injected muscle regains its contractile power. Spencer and McNeer⁶⁰ showed histologic changes in injected medial rectus muscles of adult rhesus monkeys. These changes were most apparent in the orbital, singly innervated muscle fibers, which in the acute stage exhibited denervation-like hypertrophy with dispersion of the central mitochondria toward the periphery of the fibers. There was also obliteration of the capillary network as a secondary response to disuse. Neuromuscular junctions were still present on all fibers, although evidence of sprouting was apparent. In the long term (42 to 56 days) the muscle fibers appeared normal and the vasculature had recovered. In another study it was shown that

Botox produces a gradient of denervation in a given muscle, which is dose-dependent.⁶ Even repeated injections of Botox do not appear to cause irreversible muscle atrophy or other degenerative changes.⁵ Finally, injection of Botox has been shown to induce temporary changes in the diameter of myofibers in the orbital layer of the superior rectus muscles of rabbits: the diameter was first reduced and eventually increased at 5 weeks after injection, compared to that in the control eyes. In contrast, no change in the diameter of muscle fibers was found in the intermediate layer zone.⁴⁴

The effect of Botox in *paralytic strabismus* is easily understood. In this condition the strabismus is caused by overaction of the unopposed antagonist of a paralyzed muscle and is reversed by creating a temporary paralysis of that muscle. This avoids contracture of the chemodenervated muscle until such time that the function of the paralyzed muscle returns. In the interim this treatment may provide the patient with a useful zone of single binocular vision and avoid a compensatory and, in the case of a complete paralysis, often excessively abnormal and uncomfortable head posture. Acheson and coworkers² showed a dissociated effect of Botox in patients treated for a chronic lateral rectus muscle deficit. They found that the ocular realignment caused by Botox can persist after saccadic function has been restored. They interpret this finding with the hypothesis that Botox may have a more profound and long-lasting effect on the orbital singly innervated fibers. These fibers are active tonically at rest to hold gaze, whereas there is a relative sparing of the additional motor units recruited during fast eye movements.

The effect of Botox in *comitant strabismus* is less clearly understood. Even though repeated injections are required in most patients there are conditions, such as essential infantile esotropia, in which the ocular realignment may persist even after the effect of chemodenervation has worn off. It has been suggested that the temporary paralysis induced by Botox favors activation of its antagonist.⁵² As an example, the unopposed lateral rectus muscle of a patient with esotropia becomes tight by creating a temporary paralysis of the medial rectus muscle. After the effect of Botox has worn off, a balance would be reached between the action of the excessively innervated medial rectus and the tightened lateral rectus and the effect of the injection may become permanent.^{32, 52} This hypothesis has, to our knowledge, not been verified.

Injection Technique

The original approach developed by A. B. Scott consisted of injecting an extraocular muscle under electromyographic (EMG) control. This is tolerated in adults, but requires sedation with ketamine hydrochloride (Ketalar) in children because muscle activity has to be preserved for EMG recording.^{51, 57} Injections must often be repeated more than once. In infants this necessitates repetition of sedation and usage of an operating facility, which causes both ethical and economical problems. Moreover, many pediatric anesthesiologists dislike the use of ketamine hydrochloride in children because of its side effects.

In adults, an electrode is placed on the forehead of the patient and an eye speculum is inserted after use of a local anesthetic. The conjunctival site of the needle perforation is further anesthetized by application of a cotton swab soaked with 4% carbocaine. A specially designed needle electrode connected to a regular syringe containing Botox as well as to the EMG apparatus is used for the injection. Only the tip of the needle is not insulated. The needle is inserted transconjunctivally into the muscle (Fig. 25-1A), close to its insertion, and then moved forward tangentially. The patient is then asked to move the eye in the direction of action of the muscle to be injected (Fig. 25-1B). If the needle has been placed correctly an EMG signal appears on the monitor and an auditory response is obtained as well. At this point Botox is injected into the muscle. The whole procedure takes 1 to 2 minutes for an experienced person.

When Botox is used in children the above approach is not possible. A. B. Scott injected the substance under EMG control and sedation as stated above. McNeer and coworkers³⁹⁻⁴¹ use inhalation anesthesia (nitrous oxide and ethrane) and obtain recordings from the injected muscle within the first few minutes of insufflation. Campos and coworkers,^{11, 48, 50} when injecting Botox in patients younger than 5 to 6 years old, prefer halothane (Fluothane) or sevoflurane insufflation anesthesia. The conjunctiva is opened, the muscle is engaged on a muscle hook, and Botox is injected into the muscle under direct visualization and without the aid of EMG. This ensures adequate penetration and distribution of the substance in the muscle. It also reduces the spread of Botox to adjacent extraocular muscles and prevents blepharoptosis. Botox is diluted in 4 mL of a 0.9% solution of

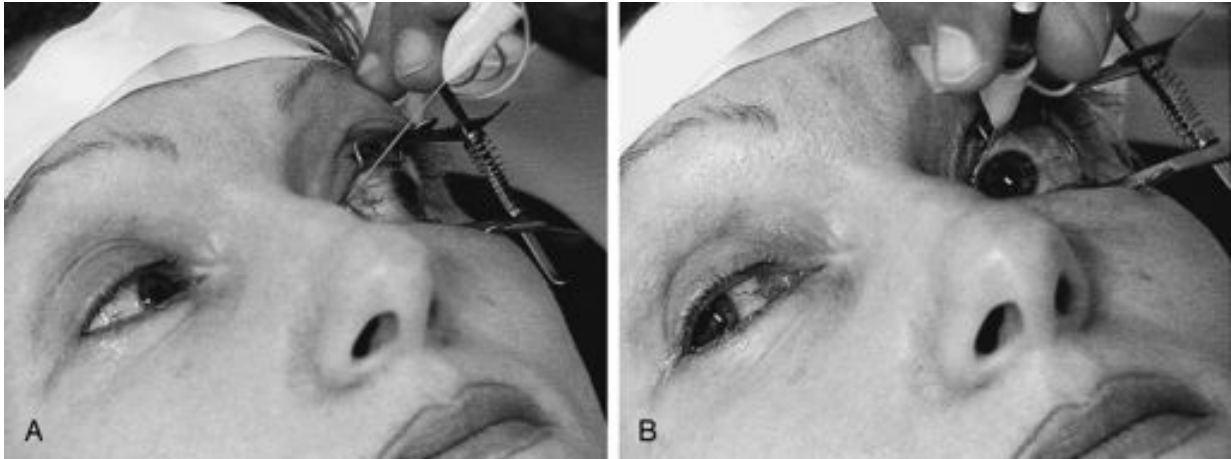


FIGURE 25-1. A, A needle electrode is inserted transconjunctivally into the medial rectus muscle. B, While the patient adducts the eye the ophthalmologist listens for the auditory response of the amplifier to confirm correct placement of the needle prior to injection.

NaCl so that 0.1 mL equals 2.5 units. Most authors have employed 1.5 to 2.5 units per muscle in children, but Campos and coworkers inject 3 units into each muscle.

Indications

Botox in Infantile Esotropia

In the past, Botox was injected into only one medial rectus muscle. The result was a paralytic exotropia, which made alternating fixation impossible and created the risk of developing amblyopia in the injected eye. An analysis of the literature of this approach reveals conflicting results.^{4, 16, 32, 38, 54} The patient groups injected were quite heterogeneous and the age of the patients at injection time varied over a wide range. Moreover, attempts to correlate the dosage of Botox injection with the effect obtained produced variable results.

Considering that the effect of muscle surgery is fairly predictable in most patients with essential infantile esotropia, the variable outcomes after Botox and, in particular, the frequent need for repeated injections did not generate enough enthusiasm among most pediatric ophthalmologists to employ chemodeneration as a primary therapy in this condition. Its usefulness as a secondary therapy after surgical overcorrection or undercorrection has been suggested but long-term follow-up studies establishing the value of this therapy are still lacking.^{10-12, 39, 62}

More recently, surgeons have injected both medial rectus muscles at the same session, and the results have become more encouraging than after

single-muscle injection.^{4, 20, 27, 40, 41, 45, 46} However, the data are still difficult to compare because different types of strabismus were included in many of the studies. Patients with essential infantile esotropia of 30^Δ to 40^Δ were considered together with others who had an esotropia of 20^Δ and the patients' ages at the time of treatment varied over a wide range.^{41, 45} Some patients were injected at an age of less than 12 months and others between the ages of 12 and 24 months.^{38, 40, 41, 45}

In 1989 Campos and coworkers began injecting both medial rectus muscles in patients with essential infantile esotropia and alternating fixation between 5 and 8 months of age and obtained stable correction of the strabismus in 53 (88%) of 60 cases after an average follow-up of 10 years.^{9, 11, 13, 48, 50} Other authors replicated this approach and followed essentially the same scheme of treatment.^{15, 20, 31, 61} The stability of results obtained with only one injection could be due to several factors: First, Botox injection was performed presumably before a contracture of the medial rectus muscles could develop and before the establishment of sensorimotor sequelae of strabismus (anomalous disjunctive movements).⁸ Both of these factors are capable of decreasing or nullifying the effect of surgery. The fact that recurrences or undercorrections or both, are common in patients treated after the age of 8 months, even after injection of both medial rectus muscles, seems to be in favor of this possibility. Second, Botox injection under direct visualization under anesthesia allows for more accurate control of the injection site and for more Botox reaching the muscle, thus causing a greater effect.

Campos and coworkers evaluated visual acuity and the binocular sensory functions in 21 of their 60 patients and found normal visual acuity in each eye. However, stereopsis as tested with the TNO test was not present in a single instance. In essence, normal binocularity was never achieved, but anomalous binocular vision or subnormal binocular vision was always present. This result is comparable to that after surgery in terms of ocular alignment and binocular functions⁴³ (see Chapter 16).

In conclusion, Botox offers some advantages and some disadvantages when compared to surgery in the treatment of infantile esotropia.²³ Its limitations are related to the difficulties involved in gaining access to patients with infantile esotropia that early in life, to the frequent need of repeated injections unless treatment is begun prior to the age of 8 months, and to lack of precision in the dose-response relationship. Many studies published during the last 5 years, especially those in which bilateral injections were used, are encouraging. However, until the stability of alignment after one injection reported by Campos and coworkers can be confirmed by additional studies employing the same strict criteria, the use of Botox in infantile esotropia cannot be unequivocally advocated at this time.

Botox in Other Forms of Comitant Strabismus

Attempts have been made to employ Botox in adult *exotropia*.²⁵ Repeated injections are obviously necessary. We are convinced that surgery is preferable, yet in selected cases this option may be offered to the patient.

Botox has been employed in *normosensorial late-onset esotropia*. Campos and coworkers obtained favorable results with one injection in both medial rectus muscles, shortly after the onset of this condition.^{9, 48, 50} These results have been confirmed.¹⁵

The use of Botox has also been suggested as a preoperative diagnostic tool in adult patients by simulating a surgical result and predicting the postoperative diplopia.^{30, 63} We feel that prismatic correction of the preoperative angle of strabismus or of a local anesthetic injected into a muscle can be used with the same purpose without inducing long-term effects, which may require a delay of surgery.

Botox is useful in *sensory exotropia* following

a traumatic cataract and monolateral aphakia, provided that useful visual acuity is achieved.^{3, 21, 49} After successful cataract surgery and lens implantation the fusional amplitudes of such patients are insufficient to overcome the exodeviation and diplopia is present. However, after injection of Botox into the lateral rectus muscle the sensory exotropia may disappear and the patient regains sufficient fusional amplitudes to control whatever exodeviation remains after recovery of lateral rectus muscle function.

Botox in Paralytic Strabismus

A logical expansion of Botox indications has been its use in muscle deficits due to lesions to the corresponding nerve or its fibers, that is, in recently acquired paralyzes of neurologic origin. Injection of Botox into the medial rectus of patients with *sixth cranial nerve paralysis* is used by many clinicians, if the deficit is of recent origin.^{12, 16, 17, 19, 26, 35, 56} The iatrogenic paralysis induced with Botox counterbalances the original paralysis of the antagonist muscle. The recovery periods of the original paralysis and the iatrogenic paralysis are approximately matched and 80% of the patients do not require surgery. It is well known that the majority of acquired sixth nerve paralyzes recover spontaneously but a contracture of the antagonist muscle may remain and cause a permanent esotropia with diplopia. Botox appears to prevent this contracture.⁵⁶ This view has been challenged by Lee and coworkers.³³ They found equal recovery rates in patients with unilateral abducens palsy, whether treated or not treated with Botox, and concluded that there is no evidence that Botox prevents the contracture of the medial rectus muscle. Be this as it may, Botox injection improves the quality of life for the patient during the recovery period by providing a useful field of binocular single vision in or near the primary position. For this reason we feel that its use is still warranted in suitable patients. Caution is advised, however, not to increase the field of diplopia with Botox in patients with incomplete abducens paralysis who are able to maintain single binocular vision with a moderate head turn.

Botox may also be useful in patients with *multiple sclerosis*, who may recover spontaneously from a sixth nerve paralysis or paresis but suffer from diplopia during the active phase of the disease.

An interesting application is the injection of

Botox into the medial rectus of patients who have to undergo a *transposition procedure* for a complete abducens paralysis.¹⁸ Botox injection 15 to 20 days before surgery eliminates the need of combining the transposition procedure with a recession of the hyperactive antagonistic medial rectus muscle, even in the presence of contracture, revealed by positive forced ductions. This approach is of particular interest in elderly patients, who are at risk of developing anterior segment ischemia after multiple muscle procedures. We have used it for the last 10 years but in one case the iatrogenic medial rectus muscle paralysis persisted for 1 year, with troublesome exotropia and diplopia.

Botox has also been suggested to temporarily weaken the ipsilateral inferior oblique muscle in *acquired fourth nerve paralysis*.^{26, 35} We have found it impossible to inject the inferior oblique muscles under EMG control and a closed sky technique without spreading Botox to the adjacent inferior rectus muscle, although others have been successful in doing this.³⁶ At this time it remains doubtful that this application of Botox will gain a firm place in the management of trochlear paralysis.

Botox in Endocrine Ophthalmopathy and Other Ocular Motility Disturbances

There are some other, ancillary indications for Botox deserving mention. Botox works well if injected into tight muscles in *endocrine myopathy* in the florid stage, that is, when the muscles become imbibed with mucopolysaccharides.^{37, 53} It is of no use in this condition once the fibrosis stage is reached.

Botox has also been used to treat strabismus after surgery for *retinal detachment* when vision in the eye operated on is low and corrective muscle surgery appears risky.^{34, 55} Botox injections have to be repeated periodically in this condition. Considering the altered anatomy of these globes after extensive surgery the risk of perforation with repeated injections is probably higher than with surgery and we do not advocate this treatment.

The use of Botox in *Duane's syndrome*, proposed by White and Lee,⁶⁴ seems not warranted because of the temporary effect of Botox on a fibrotic muscle.

Botox in Nystagmus

Botox has been used successfully in acquired nystagmus with *oscillopsia*. Retrobulbar injections or injections in the horizontal rectus muscles have been proposed.^{14, 22, 35, 47} The treatment has to be repeated periodically and only one eye can be injected at a time, as there is a risk of losing binocular vision after injection. Some but not all patients benefit from this treatment. No rational indications for Botox exist in congenital nystagmus, in spite of some reports in the literature to the contrary.

Other Ophthalmologic Indications

One of the most effective applications of Botox is the injection of both upper and lower lids in patients with *essential blepharospasm*. Although the injection must be repeated every 3 to 6 months the overall patient satisfaction and the extent of rehabilitation in this debilitating condition is impressive and gratifying.

Botox is also effective in spastic entropion, where it has to be used chronically. The injection of Botox in the *levator palpebrae superioris* has been suggested for inducing a long-lasting ptosis in patients with corneal pathologic conditions who otherwise require prolonged use of a bandage. Yet a persisting hypotropia following this procedure has been described.²⁴

Neurologists use Botox for movement disorders, such as oculofacial spasms and spastic torticollis.¹² Other indications include spastic dysphonia, esophageal spasm, bladder sphincter spasm, spastic paralysis, hyperhidrosis, and the removal of facial wrinkles.

Alternatives to Botox for Chemodenervation

Botox is probably not the ideal substance for chemodenervation.¹ As a biological substance its action cannot be precisely predicted since its toxicity varies in different lots. Moreover, repeated injections may induce immunoreactions, which can decrease the efficacy of treatment.^{29, 59} This problem is more relevant to movement disorders than to strabismus. Still, when using repeated injections in infantile esotropia, as suggested by various authors, one has to consider this alternative.

Ideally, synthetic substances interfering with

muscle function are preferable. Breinin and co-workers have experimented with the calcium channel blocker cadmium and diltiazem.^{7, 28} Since this approach seems to be quite rational, it is unfortunate that these studies have not been continued. Antibiotics such as doxorubicin, used against immunoreactions, have also been suggested as an alternative to Botox.⁴² Doxorubicin induces a localized necrosis and causes a destruction of the injected muscle with some skin reaction. Perhaps one day its use may be considered for movement disorders in which Botox treatment is chronic, whereas one single injection could solve the problem permanently. Whether this approach, if properly modified, could also be applied to some strabismus forms remains to be seen.

REFERENCES

1. Abbasoglu OE, Sener EC, Sanac AS: Factors influencing success and dose-effect relation of botulinum A treatment. *Eye* 10:385, 1996.
2. Acheson JF, Bentley CR, Shallo-Hoffmann J, Gresty MA: Dissociated effects of botulinum toxin chemodenervation on ocular deviation and saccade dynamics in chronic lateral rectus palsy. *Br J Ophthalmol* 82:67, 1998.
3. Bernstein JM, Lee JP: Botulinum toxin: An alternative to surgery in symptomatic exodeviations. *Br J Orthopt J* 47:31, 1990.
4. Biglan AW, Burnstein RA, Rogers GL, Saunders RA: Management of strabismus with botulinum A toxin. *Ophthalmology* 96:935, 1989.
5. Borodic GE, Ferrante R: Effects of repeated botulinum toxin injections on orbicularis oculi muscle. *J Clin Neuro Ophthalmol* 12:121, 1992.
6. Borodic GE, Ferrante R, Pearce LB, Smith K: Histologic assessment of dose-related diffusion and muscle fiber response after therapeutic botulinum A toxin injections. *Mov Disord* 9:31, 1994.
7. Breinin GM, Sadvnikoff N, Pfeffer R, et al: Cadmium reduces extraocular muscle contractility in vitro and in vivo. *Invest Ophthalmol Vis Sci* 26:1639, 1985.
8. Campos EC: Sensory and sensori-motor adaptations in strabismus: Their role in space perception. *Acta Psychol (Amst)* 63:281, 1986.
9. Campos EC: New indications for botulinum toxin A in strabismus and in medical treatment of amblyopia. Editorial review. *Curr Opin Ophthalmol* 4:34, 1992.
10. Campos EC: Indicazioni e aspettative nel trattamento con tossina botulinica. *Boll Ocul* 75 (suppl 4):73, 1992.
11. Campos EC: Pharmacological treatment of strabismus. In Lennerstrand G, Ygge J, eds: *Advances in Strabismus Research: Basic and Clinical Aspects*. Wenner Gren International Series, London, Portland Press, 78:167, 2000.
12. Campos EC, Schiavi C, Schoenhuber R, Guerra R: La tossina botulinica come terapia del blefarospasmo essenziale e come alternativa alla chirurgia dello strabismo. *Boll Soc Med Chir Modena* 88:213, 1988.
13. Campos EC, Schiavi C, Scorolli L: Botulinum toxin A in essential infantile esotropia. In Louly N, ed: *Transactions of the Eighth International Orthoptic Congress, Kyoto, Japan, 1995*, p 229.
14. Crone RA, de Long PTVM, Notermans G: Behandlung des Nystagmus durch Injektion von Botulintoxin in die Augenmuskeln. *Klin Monatsbl Augenheilkd* 184:216, 1984.
15. Dawson EL, Marshman WE, Adams GGW: The role of botulinum toxin A in acute-onset esotropia. *Ophthalmology* 106:1727, 1999.
16. Elston JS: The use of botulinum toxin A in the treatment of strabismus. *Trans Ophthalmol Soc U K* 104:208, 1985.
17. Elston JS, Lee JP, Powell C, et al: The treatment of strabismus in adults with botulinum toxin A. *Br J Ophthalmol* 69:718, 1985.
18. Fitzsimons R, Lee JP, Elston JS: Treatment of sixth nerve palsy in adults with combined botulinum toxin chemodenervation and surgery. *Ophthalmology* 95:1535, 1988.
19. Fitzsimons R, Lee JP, Elston JS: The role of botulinum toxin management of sixth nerve palsy. *Eye* 3:391, 1989.
20. Gomez de Liano R, Rodriguez JM, Ogaliar C, Zato MA: Inyeccion bimedial de toxine botulinica. *Acta Estrabologica* 19:71, 1991.
21. Hakin KN, Lee JP: Binocular diplopia in unilateral aphakia: The role of botulinum toxin. *Eye* 5:447, 1991.
22. Helveston EM, Pogrebiank AE: Treatment of acquired nystagmus with botulinum A toxin. *Am J Ophthalmol* 106:584, 1988.
23. Helveston EM, Ellis FD, Plager DA, Miller KK: Early surgery for essential infantile esotropia. *J Pediatr Ophthalmol Strabismus* 27:115, 1990.
24. Heyworth PLO, Lee JP: Persisting hypotropias following protective ptosis induced by botulinum toxin. *Eye* 8:511, 1994.
25. Horgan SE, Lee JP, Bunce C: The long-term use of botulinum toxin for adult strabismus. *J Pediatr Ophthalmol Strabismus* 35:9, 1998.
26. Huber A: Anwendung von Botulinustoxin in der Ophthalmologie. *Klin Monatsbl Augenheilkd* 210:289, 1999.
27. Ing MR: Botulinum alignment for congenital esotropia. *Ophthalmology* 100:318, 1993.
28. Jacoby J, Kahn DN, Pavlica MR, et al: Diltiazem reduces the contractility of extraocular muscles in vitro and in vivo. *Invest Ophthalmol Vis Sci* 31:569, 1990.
29. Jankovic J, Schwartz K: Response and immunoresistance to botulinum toxin injections. *Neurology* 45:1743, 1995.
30. Ketley MJ, Powell CM, Lee JP, Elston J: Botulinum toxin adaptation test: The use of botulinum toxin in the investigation of the sensory state in strabismus. In Lenk-Schaefer M, ed: *Orthoptic Horizons. Transactions of the sixth International Orthoptic Congress, 1987, Harrogate, U K*, p 289.
31. Lavenant F, Pecherau A, Quéré MA: Toxine botulique et ésoptropies congénitales. Injection de toxine botulique dans les droits internes dans les ésoptropies congénitales. *Ophthalmologie* 10:302, 1996.
32. Lee J, Elston J, Vickers S, et al: Botulinum toxin therapy for squint. *Eye* 2:24, 1988.
33. Lee JP, Harris S, Cohen J, et al: Results of a prospective randomised trial of botulinum toxin therapy in acute sixth nerve palsy. *J Pediatr Ophthalmol Strabismus* 31:283, 1994.
34. Lee JP, Page B, Lipton J: Treatment of strabismus after retinal detachment surgery with botulinum neurotoxin A. *Eye* 5:451, 1991.
35. Lennerstrand G, Nordbo OA, Tian S, et al: Treatment of strabismus and nystagmus with botulinum toxin A. *Acta Ophthalmol Scand* 76:27, 1998.
36. Lozano-Pratt A, Estanol B: Treatment of acute paralysis of the fourth cranial nerve by botulinum toxin A chemodenervation. *Binocular Vision Strabismus Q* 9:155, 1994.
37. Lyons CJ, Vickers SF, Lee JP: Botulinum toxin therapy in dysthyroid strabismus. *Eye* 4:535, 1990.
38. Magoon EH: Chemodenervation of strabismic children: A 2 to 5 years follow-up study compared with shorter follow-up. *Ophthalmology* 96:931, 1989.
39. McNeer KW: An investigation of the clinical use of botulinum toxin A as a postoperative adjustment procedure in

- the therapy of strabismus. *J Pediatr Ophthalmol Strabismus* 27:3, 1990.
40. McNeer KW, Spencer RF, Tucker MG: Observations on bilateral simultaneous botulinum toxin injection in infantile esotropia. *J Pediatr Ophthalmol Strabismus* 31:214, 1994.
 41. McNeer KW, Tucker MG, Spencer RF: Botulinum toxin management of essential infantile esotropia in children. *Arch Ophthalmol* 115:1411, 1997.
 42. Nguyen LT, McLoon LK, Wirtschafter JD: Doxorubicin chemomyectomy is enhanced when performed two days following bupivacaine injections: The effect coincides with the peak of muscle satellite cell division. *Invest Ophthalmol Vis Sci* 39:203, 1998.
 43. Norcia AM, McNeer KW, Tucker MG, et al: Development of binocular motion processing following Oculinum injection in infantile esotropia. *Invest Ophthalmol Vis Sci* 33:870, 1992.
 44. Ohtsuki H, Hasebe S, Okano M, Furuse T: Morphological changes in the orbital surface layer muscle of the rabbit eye produced by botulinum toxin. *Ophthalmologica* 212:212, 1998.
 45. Rayner SA, Hollick EJ, Lee JP: Botulinum toxin in childhood strabismus. *Strabismus* 7:103, 1999.
 46. Robert PY, Jeaneau-Bellego E, Bertin P, Adenis JP: Intérêt de l'injection tardive de toxine botulique dans l'esotropie de l'enfant en première intention. *J Fr Ophtalmol* 21:508, 1998.
 47. Ruben ST, Lee JP, O'Neill D, et al: The use of botulinum toxin for treatment of acquired nystagmus and oscillopsia. *Ophthalmology* 101:783, 1994.
 48. Schiavi C, Benedetti P, Campos EC: Botulinum toxin in essential infantile esotropia and in Lang's normosensorial strabismus. In Kaufmann H, ed: *Transactions of the 20th Meeting of the European Strabismological Association, Brussels, 1992*, p 179.
 49. Schiavi C, Schoenhuber R, Campos EC: Risultati personali di 6 anni di uso della tossina botulinica nella terapia dello strabismo e delle distonie oculo-facciali. *Atti Soc Oftalmol Lombarda* 45:453, 1990.
 50. Schiavi C, Scorolli L, Campos EC: Long term follow-up of botulinum toxin treatment in essential infantile esotropia and in late-onset normosensorial esotropia. In Spiritus M, ed: *Transactions of the 22nd Meeting of the European Strabismological Association, Cambridge, UK. The Hague, Aeolus Press, 1995*, p 159.
 51. Scott AB: Botulinum toxin injection into extraocular muscles as an alternative to strabismus surgery. *Ophthalmology* 87:1044, 1980.
 52. Scott AB: Botulinum toxin injection of eye muscles to correct strabismus. *Trans Am Ophthalmol Soc* 79:734, 1981.
 53. Scott AB: Botulinum injection treatment for endocrine orbital myopathy. *Doc Ophthalmol* 58:141, 1984.
 54. Scott AB: Botulinum injection treatment of congenital esotropia. In Lenk-Schaefer M, ed: *Transactions of the 6th International Orthoptic Congress, 1987, Harrogate, U K*, p 294.
 55. Scott AB: Botulinum treatment of strabismus following retinal detachment surgery. *Arch Ophthalmol* 108:509, 1990.
 56. Scott AB, Kraft SP: Botulinum toxin injection in the management of lateral rectus paresis. *Ophthalmology* 92:676, 1985.
 57. Scott AB, Magoon E, Stager D, McNeer K: Botulinum treatment of strabismus in children. *Trans Am Ophthalmol Soc* 87:1, 1989.
 58. Scott AB, Rosenbaum AL, Collins CC: Pharmacologic weakening of extraocular muscles. *Invest Ophthalmol* 12:924, 1973.
 59. Siatowski RM, Tyutyunikov A, Biglan AW: Serum antibody production to botulinum A toxin. *Ophthalmology* 100:1861, 1993.
 60. Spencer RF, McNeer KW: Botulinum toxin paralysis of adult monkey extraocular muscle. Structural alterations in orbital, singly innervated muscle fibers. *Arch Ophthalmol* 105:1703, 1987.
 61. Spielmann A: La toxine botulique dans les strabismes précoces. Expérience personnelle. *Société Ophtalmologie Est de la France, April 1, 1995. Bull Soc Fr Ophtalmol* 96:142, 1996.
 62. Tejedor J, Rodriguez JM: Retreatment of children after surgery for acquired esotropia: Reoperation versus botulinum injection. *Br J Ophthalmol* 82:110, 1998.
 63. Watkins SE, Lee JP: The pre-operative predictive value of botulinum toxin A. In Tillson G, ed: *Advances in amblyopia and strabismus. In Transactions of the Seventh International Orthoptic Congress, Nuremberg, 1991*, p 189.
 64. White JES, Lee JP: The role of botulinum toxin A injections in the management of patients with Duane's retraction syndrome. In Tillson G, ed: *Advances in Amblyopia and Strabismus. Transactions of the Seventh International Orthoptic Congress, Nuremberg, 1991*, p 341.

Principles of Surgical Treatment

The primary goal of strabismus surgery is to eliminate the relative deviation of the visual axes. Surgery is performed for functional reasons, to create comfortable single binocular vision, or, if this cannot be accomplished, to reestablish a normal facial configuration by aligning the eyes. The term “cosmetic surgery” in connection with operations for strabismus in adults should be avoided since this description is not only incorrect but may also be unacceptable to some insurance carriers and managed care providers. *Cosmetic surgery* is defined as surgery performed to improve the appearance of a *normal* person. Since strabismus is an *abnormal* sensory and motor state of the eyes, its surgical correction falls under the category of *reconstructive surgery*, the goal of which is to eliminate a disease, abnormality, or defect.^{4, 105, 262} The term cosmetic surgery is also a misnomer in view of the fact that in many instances functional visual benefits may be expected from correcting strabismus in adults.^{142, 146, 226, 244, 254, 303}

Whatever the indication, the effect of an operation is mechanical, since the position of the globe in the orbit is changed, thus altering the effectiveness of extraocular muscle contraction. Surgical procedures cannot *directly* affect the innervation reaching the eyes. This can happen only *indirectly* when innervational and sensory factors adjust to the newly created anatomical and mechanical conditions that have created a new stimulus situation.

The purpose of surgery should be to correct the static angle of strabismus. Operations to change

the dynamic angle as defined by us (see p. 180) invariably lead to undesirable results. In paralytic strabismus only those patients in whom the deviation interferes with comfortable single binocular vision in the *practical field of fixation* (see Chapter 4) should be considered for surgical treatment.

History and General Comments

The earliest reference to strabismus surgery can be found in the early eighteenth century in the writings of an itinerant English oculist named John Taylor. “Chevalier” Taylor, as he called himself, traveled through continental Europe to lecture and perform eye surgery.¹⁴ He left a trail of deteriorating sight and blindness behind him and has been called the greatest charlatan of all oculists who ever lived. His self-glorification and shameless publicity stunts would have made even the most aggressive advertising of contemporary “laser surgeons” appear to be exercises in modesty. According to an eyewitness, Le Cat, who later wrote a book about Taylor, strabismus surgery consisted of excising a piece of conjunctiva from the lower fornix.^{113, p. 166} Taylor claimed that by excising some of its nerve supply an overacting muscle was weakened. After surgery the eye not operated on was bandaged and great was the awe and admiration of the spectators when the eye operated on straightened out and remained straight

. . . until several days later when the bandage was removed and the squint returned. But by that time Taylor had moved on to the next town and not before collecting a sizable surgical fee. Le Cat, who knew about the nerve supply to the extraocular muscles, expressed his doubts about the effectiveness of this operation in an unusually dramatic and macabre fashion. Once after an excellent lunch he had a covered dessert dish served to Taylor. When the cover was removed it revealed a human head in which the nerves to the extraocular muscles had been carefully dissected.^{113, p. 167} It was obvious that none of the nerves could have been reached with Taylor's technique and the embarrassed surgeon left town, his local reputation shattered. Despite his unscrupulousness Taylor deserves credit for being the first to mention in his writings that myotomy of a muscle may cure strabismus. However, none of his contemporaries witnessed that Taylor had actually performed this operation himself.

It was not until a century later, on October 26, 1839, at 3 PM to be exact,^{114, p. 322} that Johann Friedrich Dieffenbach, a general surgeon from Berlin and professor at the famous Charité, corrected strabismus by performing a myotomy of a medial rectus muscle in a 7-year-old esotropic child. Dieffenbach was a popular and famous surgeon in his day to whom medicine owes numerous innovations. Many consider him the father of orthopedic and plastic surgery. When he walked through the streets of Berlin the street urchins greeted him with this ditty:

Wer kennt nicht Doktor Dieffenbach,
den Doktor der Doktoren?
Er schneidet Arm und Beine ab,
macht neue Nas' und Ohren*

It is highly probable that the rationale for this operation evolved from successfully treating club-foot with weakening of the Achilles tendon or torticollis with a myotomy of the sternocleidomastoid muscle. Dieffenbach had a considerable personal experience with both operations.²³⁵ Dieffenbach published this case only a few days later, on November 13, 1839,⁵⁶ and mentioned in his report that Louis Stromeyer, another German surgeon, had performed this operation on a cadaver.

It so happened that a Belgian ophthalmologist, Florent Cunier, who had also become aware of Stromeyer's report, performed a myotomy of the

lateral rectus muscle in a patient with exotropia only 3 days after Dieffenbach's feat.^{114, p. 335} Actually, Cunier's report of his operation in the *Annales d' Oculistique* preceded Dieffenbach's publication in the *Medizinische Zeitung* by 2 weeks. Not surprisingly, an ardent and ugly dispute evolved when Cunier challenged Dieffenbach's priority. This disagreeable situation was further aggravated when the prestigious and substantial (6000 gold francs!) Montyon Prize of the Royal Academy of Science (Paris) was shared by Stromeyer for first suggesting the operation and performing it in cadavers and by Dieffenbach for being the first to perform it successfully in a patient.^{114, p. 335}

Dieffenbach's publication in 1839 secured him priority as the father of strabismus surgery, but he may not have been the first to treat esotropia with a myotomy of the medial rectus muscle. In fact, it is quite likely that he was preceded by William Gibson of Baltimore, a noted general surgeon and professor at the University of Maryland. In the sixth edition of his textbook, *The Institutes and Practice of Surgery* (1841),⁸³ Gibson reported that he had performed this operation in four patients in 1818, that is, 21 years before Dieffenbach. However, because the results were disappointing (three undercorrections, one overcorrection), Gibson abandoned this procedure. He graciously stated that he did not intend to question Dieffenbach's glory as the originator of the myotomy but regretted not having persisted and operated on a larger number of patients.

The news of a surgical cure of strabismus spread through Europe and America with telegraphic speed. Only 2 years after his first publication Dieffenbach had done 1200 cases.^{114, p. 324} Ether anesthesia was not discovered until 1846 and several helpers were needed during the operation, one surgeon and two or three assistants whose task it was to immobilize the sitting patient and to pry the lids open. In 1839 only eight such operations had been performed at the Royal Westminster Eye Hospital, but in 1840 over 400 procedures were done, more than 365 of them in less than 7 months by a single surgeon.²²² The French ophthalmologist Fleussu wrote that "never has an operation been accepted with similar enthusiasm as the operation for strabismus. Surgeons snatched patients from each other or chased them like game whose meat would be suited to feed and fatten one's own reputation."^{73, 235}

The operation was performed in the United

*Who does not know Dr. Dieffenbach,/The doctors' doctor?/
He cuts off arms and legs,/Makes new noses and ears.

States soon after it became popular in Europe and England. A treatise on strabismus surgery was published in 1842 by James Bolton of Virginia²² with illustrations of instruments that look not all that much different from those we are using today.

We became aware of one of the first and perhaps most colorful descriptions of muscle surgery in those days in Stephens's fascinating diary of his 1841 expedition to Yucatan.²⁷⁸ Stephens was accompanied on this trip by a Dr. Cabot of Boston who performed this procedure on a 14-year-old boy, and Stephens outlined the operation as follows: "The cure discovered is the cutting of the contracted muscle, by means of which the eye falls immediately into its proper place. This muscle lies under the surface; and, as it is necessary to pass through a membrane of the eye, the cutting cannot be done with a broadaxe or a handsaw." Stephens then went on to describe the operation performed by Dr. Cabot in a "stout lad of about 19 or 20":

As soon as the doctor began to cut the muscle, however, our strapping patient gave signs of restlessness; and all at once, with an actual bellow, he jerked his head on one side, carried away the doctor's hook, and shut his eye upon it with a sort of lockjaw grip, as if determined it should never be drawn out. How my hook got out I have no idea; fortunately, the doctor let his go, or the lad's eye would have been scratched out. As it was, there he sat with the bandage slipped above one eye, and the other closed upon the hook, the handle of which stood out straight. Probably at that moment he would have been willing to sacrifice pride of personal appearance, keep his squint, and go through life with his eye shut, the hook in it, and the handle sticking out; but the instrument was too valuable to be lost. And it was interesting and instructive to notice the difference between the equanimity of one who had a hook in his eye, and that of lookers-on who had not. All the spectators upbraided him with his cowardice and want of heart, and after a round of reproof to which he could make no answer, he opened his eye and let out the hook. But he had made a bad business of it. A few seconds longer, and the operation would have been completed. As it was, the whole work had to be repeated. As the muscle was again lifted under the knife, I thought I saw a glare in the eyeball that gave token of another fling of the head, but the lad was fairly browbeaten into quiet; and, to the great satisfaction of all, with a double share of blackness and blood, and with very little sympathy from anyone, but with his eye straight, he descended from the table. Outside he was received with a loud shout by the boys, and we never heard of him again.

But, as one may have expected, the initial excitement with this operation soon wore off. In many cases the outcome was a huge overcorrection which Dieffenbach treated by myotomizing

the lateral rectus and passing a suture through its tendon, which was then fastened to the opposite side of the nose. This traction suture was called "Fadenoperation" and it is unfortunate that this term was usurped in our time to describe a completely different procedure, the retroequatorial myopexy. Although there were patients with good results, presumably from spontaneous scleral reattachment of the distal muscle segment further posteriorly, Laqueur¹⁴⁹ observed in 1908 that "after the initial reports of 1842 the publications about strabismus decreased progressively and concerned mostly efforts to reverse the effect of surgery," and Javal¹²⁹ spoke of the "slaughter" of extraocular muscles that had taken place.

The early phase of strabismus surgery had ended and even though Critchett reported advancement of a rectus muscle in 1855, it was not until 1857 when a new era of strabismus surgery began with publication of Albrecht von Graefe's classic monographs on strabismus surgery.^{92, 93} Von Graefe, who is considered by most as one of the fathers of modern ophthalmology (the other three being Helmholtz, Donders, and Bowman) defined the indications for tenotomy, improved the technique, and added controlled recession and resection and advancement of a muscle to the surgical armamentarium. His younger nephew and disciple, Alfred K. Graefe, is rarely mentioned in this connection but made similarly important contributions to the surgical treatment of paralytic strabismus.^{91, 295}

In our time, *free tenotomies* (or myectomies) of the rectus muscles have been replaced by recessions and have but sunk into oblivion. An exception is tenotomy of the inferior rectus muscle, which is used in rare cases of severe endocrine ophthalmopathy or congenital fibrosis. In both conditions the tightness of the muscle may be so pronounced that it is technically impossible to pass sutures through its tendon at the insertion. Tenotomies of the superior oblique muscle and myectomies of the inferior oblique muscles are being performed to this day.

Choice of Operation

When the need for surgery has been established, the muscle or muscles to be operated on must be determined. Only two procedures can affect the action of an extraocular muscle and thereby alter the position of the eyes. The action of a muscle

can be weakened or the action of the antagonist muscle strengthened; the two procedures can also be combined. We emphasize that we are speaking of weakening or strengthening the action of a muscle rather than of the muscle itself since most of the currently used surgical procedures do only just that.

Motility Analysis

VERSIONS. An important criterion for choosing the appropriate surgical procedure is based on the study of versions. In most patients with comitant heterotropia, abnormalities of rotations are present. In esotropes, for instance, adduction may be excessive and abduction deficient. In exotropes, abduction may be excessive and adduction deficient, or both conditions may coexist. Surgical procedures on extraocular muscles should normalize the excursions of the eyes and if successful should reduce the deviation automatically.

For example, if movement of the globe is excessive in a particular direction, the action of that muscle should be weakened. If movement is deficient, strengthening the action of the appropriate muscle is indicated. Thus in a patient with esotropia, excessive adduction, and normal abduction, we perform a maximal recession of the medial rectus muscle and only a nominal resection of its antagonist. On the other hand, if deficient abduction is a prominent clinical feature, maximal resection of the lateral rectus muscle is combined with a small recession of the medial rectus muscle. If movement is excessive in one direction and deficient in the opposite direction, a maximal weakening procedure on one muscle may be combined with a maximal strengthening procedure on the antagonist. When the rotations are neither excessive nor deficient, the emphasis should be placed on strengthening rather than on weakening the muscle action.

Weakening the action of a normally functioning muscle tends to restrict movement of the globe in the direction of action of that muscle. Large resections may cause retraction of the globe with narrowing of the palpebral fissure and large recessions may widen the palpebral fissure.

DIAGNOSTIC POSITIONS. The results of careful measurements in the diagnostic positions of gaze (see Chapter 12) also must be considered. Increases or decreases of the deviation in the various positions of gaze are important guidelines in se-

lecting the appropriate procedure. This is especially true in exotropes in whom measurements in lateral gaze may indicate a smaller angle of strabismus than in primary position. The amount of recession of the lateral rectus muscles needs to be modified accordingly to avoid overcorrections.

The degree of change in the horizontal deviation with the eyes in elevation and depression provides information regarding the presence or absence of an alphabetic pattern (see Chapter 19), which may influence the choice of operation. When a vertical deviation is present, measurements in the nine diagnostic positions are essential for determining the muscle or muscles involved and, therefore, in choosing the appropriate surgical procedure.

Regardless of its usefulness, the prism cover test in the diagnostic positions does not replace the study of versions. The two tests do not necessarily elicit the same information. For example, an increase of deviation in dextroversion as measured with the prism cover test in a patient with esotropia may be the result of excess adduction in the left eye or limitation of abduction in the right eye. Even if the measurement is performed with either eye fixating, results will remain the same in both situations; the prism cover test does not pinpoint the cause of the anomalous muscle actions in this situation.

FORCED DUCTION TEST. In general, the surgical procedure to be performed should be decided on during the preoperative examinations, and the surgical plan should not be changed when the patient is on the operating table and general anesthesia has caused modification of the deviation. When performing the forced duction test on a patient who has been given a general anesthetic, the surgeon must be aware that succinylcholine, a short-acting, depolarizing muscle relaxant used during endotracheal intubation, causes sustained contraction of extraocular muscles. This effect may last for as long as 20 minutes and may interfere with accurate interpretation of the forced duction test. A nondepolarizing muscle relaxant, which does not alter the forced duction test, is suggested as an alternative drug.⁷⁷

Modification of the original surgical plan is indicated when the forced duction test (see Chapter 20) reveals mechanical obstacles not anticipated preoperatively or when congenital anomalies or structural changes from previous surgery are found on exposure of the muscle that were not

evident on clinical examination. The surgeon must then change the original plan and remove the restrictions. It follows that the forced duction test must be used at the beginning and end of each surgical procedure and at various stages of the operation.

For instance, limitation of abduction in an infant with esotropia may be caused by weakness of the action of the lateral rectus muscle or by contracture of the medial rectus muscles or of the conjunctiva and Tenon's capsule. In both instances the results of clinical examination will be similar, yet surgical management will differ. In the first instance, the emphasis of the operation should be placed on strengthening the action of the lateral rectus muscle; in the second case, this operation will cause narrowing of the palpebral fissure and little improvement of abduction unless the contracted medial rectus muscle or conjunctiva is first recessed. Another example for application of the forced duction test is the patient in whom a muscle transposition procedure for paralytic horizontal strabismus or a double elevator or depressor paralysis is contemplated. This procedure is successful only if mechanical restriction in the field opposite that of the paretic muscle is eliminated first (see Chapter 20).

Likewise, the position of the eyes after completion of surgery and while the patient is still anesthetized varies considerably between esotropia and exotropia, even though the eyes may be perfectly aligned once the patient is awake.^{204, 205} These findings should be considered by those who attach significance, regarding the amount of surgery to be performed, to the eye position while the patient is anesthetized.^{6, 23, 177, 230, 242, 243} As a rule, we have found that assessment of the angle of strabismus under this circumstance is without value except in patients in whom strabismus is purely restrictive. In such instances, the eye position is the same under general anesthesia as during the waking state. This information, in conjunction with the forced duction test, is of diagnostic value.

NEAR POINT OF CONVERGENCE. At one time much attention was given to the near point of convergence in determining the proper surgical procedure for esotropia. The concept was that action of the medial rectus muscles should not be weakened if the near point of convergence is remote, an opinion that in turn was based on the erroneous idea that ocular deviations are caused by inadequate strength of the muscles. Actually,

with few exceptions the medial rectus muscles are always able to contract sufficiently to cause maximal convergence of the eyes. The missing factor in convergence insufficiency is the nervous impulse to converge. This impulse arises in an area of the brain that is spatially separate from the area subserving the lateroversion movements. These movements are normal in spite of convergence insufficiency, and convergence may be normal, excessive, or defective even though lateroversions are normal. To be sure, if the medial rectus muscles are recessed unduly far behind their original insertion, a mechanical paresis is created, and convergence and lateroversion will be affected. On the other hand, properly executed operations will alter the relative position of the eyes, regardless of the type of procedure, and thus change the starting position of convergence and divergence movements. Changes in the near point of convergence then will depend on whether the patient exerts the same convergence impulse as before the operation. If so, the near point should be farther away than it was preoperatively in esotropes and closer in exotropes; however, this is not necessarily true because of postoperative adjustments of innervation.

Symmetrical vs. Asymmetrical Operations

Some ophthalmologists place much emphasis on the need for symmetrical operations; that is, the same type of operation (recession or resection) should be done on homonymous muscles of the two eyes. Behind this thought is the belief that asymmetrical procedures (recession of one muscle, resection of the antagonist) often result in an incomitance, although this is by no means always true. However, routine symmetrical operations are just as wrong as the exclusive use of any one type of procedure.

An ophthalmologist who routinely does symmetrical procedures is automatically assuming that all patients have a symmetrical abnormality, a premise that is contrary to the facts. In our opinion, surgery must be planned on an individual basis. Clearly, an incomitance should not be created where one did not exist, but symmetrical operations should not be performed when asymmetry is the primary anomaly. We therefore recommend symmetrizing rather than symmetrical operations; that is, symmetry should be main-

tained when it exists and restored when it does not exist.

Comitance is desirable, of course, from a functional standpoint. Recession-resection operations are apt to create incomitance, which can be remedied by operating on the fellow eye. A truly functionally harmful incomitance, however, must be defined. It is doubtful whether incomitance in extreme positions of gaze is of major significance, since the eyes rarely if ever move that far during casual conditions of seeing (see Chapter 4). There is no doubt, however, that postoperative incomitance in primary position is functionally detrimental. Such an incomitance is reflected in a change in deviation in primary position with either eye fixating. This may be termed a *primary* and *secondary deviation*, but after muscle surgery, it may be referred to also as a *differential angle of squint*.

Asymmetrical operations on the yoke muscles of the two eyes also may be performed if the deviation toward one side is significantly greater than toward the other. For example, for an esotropia that is 15^A or more in levoversion than in dextroversion, one may recess the right medial rectus muscle and resect the left lateral rectus muscle. Such procedures have proved useful in our hands by reducing the deviation in primary position and equalizing or reducing the deviation in dextroversion and levoversion.

Amount of Operation

The results of strabismus surgery are not precisely predictable in terms of prism diopters correction per millimeter of recession or resection. So-called dose-response curves or tables, derived from retrospective analysis of surgical outcomes and listing the amounts of recession and resections even in fractions of millimeters, can be found throughout the strabismus literature and give the impression of accurate predictability of the surgical effect. We have found such data rather useless because of the common experience that an identical surgical procedure, performed by the same surgeon on several patients with apparently similar conditions, may give different results in each patient. At best, dose-response curves or tables may serve as very general guidelines for the less experienced surgeon. We have included our surgical dosages for the various forms of strabismus in the appropriate sections of this book, being fully aware, however, of the limitations of such information.

The variability of surgical results depends on

numerous and only partially known factors. The sensory state of the patient, the operative technique, the manner in which the muscle is exposed, how thoroughly it is freed, its stiffness, whether the check ligaments are severed, the placement of the sutures, the occurrence of intra- and postoperative bleeding, the tendency to form adhesions and scarring, the state of conjunctival elasticity, and the anatomical variations of muscle insertions are just some of the variables that may influence the effect of the operation. Even though it may eventually be possible to standardize most of these aspects, additional factors, as yet unknown, may exist and influence the surgical result. *Each surgeon must establish through periodic review of the surgical outcomes the approximate effectiveness of the procedure he or she routinely employs for a certain condition and modify the accustomed dosage whenever so dictated by this learning experience.*

Despite the foregoing, there are certain empirical rules that are helpful in determining the amount of surgery to perform in each patient. Assuming that the identical operative technique was used in each case, the larger the deviation and the more abnormal the rotation, the greater the effect will be following a given amount of surgery. In older children and adults in whom presumably secondary anatomical changes of muscles and fascia have taken place, more extensive operations are required than in younger children with a comparable amount of deviation.

After publication of David Robinson's classic paper on quantitative analysis of extraocular muscle cooperation in strabismus (1975),²⁴⁰ efforts began to use the aid of a *computer* to determine the type and dosage of surgery. Initially, these computer predictions were of little value to the practicing ophthalmologist, but recent work in this direction has become more promising. The reason for this is that many of the variables listed above that determine the surgical outcome are now being incorporated into the calculating process. Some of these previously neglected factors are the mechanical influence of orbital structures and geometry, muscle and connective tissue mechanics, stability of the muscle paths, the muscle pulleys, and innervation. The differences between a preoperative computer simulation of a surgical procedure and its actual outcome are becoming increasingly smaller.^{165, 261} There is reason to predict that the computer will play some practical, clinical role in the future in deciding on the amount and type of

surgery in complex strabismus cases of *innervational origin*. For strabismus of *mechanical cause*, such computer predictions have been disappointing.

The recent emphasis on performing surgery for esotropia during infancy has brought new awareness of the fact that the globe has not reached adult size during infancy (see Chapter 3, Table 3–2). For this reason, a certain amount of recession or resection is more effective in terms of reducing the tangency between muscle and globe than when growth of the eye is completed.^{1, 147}

Weakening the action of a muscle (recession) is more effective in reducing the deviation than is strengthening its action. Relatively larger amounts of resection therefore are required to produce an effect comparable to that achieved by recession of the antagonist.

The *sensory state* also must be considered. If the patient has a good functional potential for binocular vision, the surgeon should aim for complete alignment of the eyes. In those patients with deep-seated anomalous retinal correspondence and without a functional potential, less extensive surgery is required, since a cosmetically acceptable residual angle is desirable and will enable the patient to maintain single vision and peripheral fusion by means of anomalous retinal correspondence.

Intractable *deep amblyopia* causes a major problem when one is determining the appropriate amount of surgery to be performed. The amount done under ordinary circumstances may be insufficient and the eye may revert to its original position. In other patients the deviation will be overcorrected. When deep amblyopia is present, therefore, the patient should be informed of the relative unpredictability of the operation and the possibility of more than one operation must be mentioned.

In view of the foregoing, it is obviously impossible to provide for each strabismic condition a recipe by which one can predict the correction to be obtained from a specific amount of recession or resection. Nevertheless, on the basis of clinical experience and with the surgical technique that we use, the following guidelines have been found useful. A minimal amount of combined resection-recession in one eye can be expected to correct 20^Δ to 25^Δ, and a maximal resection-recession procedure may correct 40^Δ to 60^Δ of esodeviation or exodeviation. A minimal recession of both medial or both lateral rectus muscles corrects 15^Δ to

20^Δ, and a maximal recession of these muscles corrects up to 50^Δ of an esodeviation or exodeviation. The minimal and maximal amounts of recession and resection for each muscle are discussed elsewhere in this book in connection with specific conditions. The amount of surgery must be distributed between the muscles according to our concept of symmetrizing their action, as outlined in the preceding discussion, and according to the size of the deviation.

Prism Adaptation Test

It has been observed that the eyes of some patients may return to the preoperative angle after surgical correction on the basis of anomalous retinal correspondence or of anomalous fusional movements (see Chapter 11) or that the preoperative angle of strabismus may increase or reestablish itself after neutralization with prisms. Such patients are said to be “eating up” the prismatic correction. On the basis of these observations some authors advocate deliberate surgical overcorrection when the angle increases significantly after prismatic compensation. Indeed, the preoperative use of prisms to predict the amount of surgery has been advocated since the 1960s.^{7, 8, 110, 116, 124, 295} Improved surgical results were reported when the increase of the deviation under the influence of correcting prisms (prism adaptation) was taken into account when determining the surgical dosage. A multicenter, prospective, and randomized study was published in 1990²²⁹ that reported the efficacy of prism adaptation in the surgical management of acquired esotropia. This study showed that the success rate in patients whose angle increased under the influence of prisms base-out was higher (see also Ohtsuki and coworkers²⁰⁵) after augmented surgery (89%) than when conventional surgery was performed (79%). In a 1-year outcome study of the original patient group, prism responders operated on for the adapted esotropic angle had a satisfactory motor outcome more often (90%) than those operated on for the entry angle (75%).²³⁷ However, Greenwald,⁹⁴ using a different statistical approach, found that the overall motor success rate for the study’s adaptation group was only 75% vs. 74% in the conventionally managed group.

There remain additional questions regarding the prism adaptation study in terms of the nosologic homogeneity of the study group and the influence of the sensorial state of patients undergoing prism adaptation. Moreover, there are no clear directions

as to how much the surgical dosage needs to be augmented when prisms are “eaten up.” No due consideration has been given to the fact that children tend to compensate for stronger prisms than adults, which may affect the long-term outcome of surgery augmented on the basis of prism adaptation. These considerations, as well as the cost of prismatic spectacles in patients who ordinarily do not wear glasses, the general lack of compliance with wearing prismatic spectacles at home, and the necessity for repeated patient visits during which the prismatic power must be adjusted, are reasons why we have not adopted the prism adaptation procedure to determine the dosage of surgery.

Operations to Weaken the Action of a Muscle

As mentioned elsewhere in this chapter, recessions reduce the deviation more per millimeter than do resections of the same amount. Recessions do not disrupt the action of an overacting muscle, but if a muscle does not overact preoperatively or if it is recessed too far, its action may indeed be unduly weakened.

Excessive weakening of the action of a muscle usually is attributed to the loss of rotational force or torque. Torque acts on the tangential point of the muscle, which, in the case of the medial rectus muscle, lies 6.27 mm in front of the equator when the globe is in primary position. The rotational force is most effective when it is applied tangentially. When the muscle is recessed, thus altering its tangential point, the direction of the applied force changes and the muscle loses some of its mechanical effect. Adelstein and Cüppers¹ have shown that the effect of a recession on the arc of contact depends on the diameter of the globe, which varies in patients of different age groups. Moreover, normal variations in the distance between the limbus and insertion of a muscle may add an additional variable to the effect of a standard recession procedure.¹⁰⁹

Beisner¹⁰ developed a formula by which the loss of torque with various degrees of recession can be determined. He found that this loss, though real, is less than generally assumed. From the family of curves derived by Beisner, one can see that an 8-mm recession of a medial rectus muscle reduces the torque by only 1.5% in primary position and by 10% with 10° adduction. Beisner believes that the loss of torque is a secondary reac-

tion and that the primary cause of postoperative underaction is loss of contractile force caused by shortening of the muscle. This physiologic relationship between muscle force and muscle length is known to exist.

Beisner's conclusions are well founded, but in addition to torque and muscle length reduction, a third factor must be considered. Not only has the insertion been set back in the operation but the muscle is no longer quite in situ, since many of the dampening and supporting structures have been severed. Their removal indubitably adds to the effect of surgery.

RECESSION OF HORIZONTAL RECTUS MUSCLES.

Recession of the *medial rectus muscles* for esotropia should be restricted to a maximum of 8 mm. Larger recessions are likely to disturb the balance between opposing muscle forces: the unopposed lateral rectus becomes tight and pulls the eye toward abduction. This effect is sometimes desirable, for instance, when shifting the null position in congenital nystagmus from a peripheral gaze position to the primary position (Chapter 23). However, if both the medial and lateral recti are recessed as much as 12 mm, the balance between the opposing muscle forces remains undisturbed and the resulting motility deficit in lateral gaze is clinically negligible.

If both medial rectus muscles are operated on, they are often recessed the same amount; however, this is not mandatory, and again consideration should be given to the individual problem. If adduction in one eye is significantly more excessive than that in the fellow eye, one may recess the medial rectus of that eye, say, 6 mm, and recess only 3 mm in the other eye. As a rule, a recession of the medial rectus muscle is more effective than the same amount of recession performed on a lateral rectus muscle. Recessions of the *vertical rectus muscles* are more effective than when they are performed on the horizontal rectus muscles.

Recessions of both *lateral rectus muscles* of less than 5 mm are of little use in the treatment of exotropia. Unilateral or bilateral lateral rectus muscle recessions of 6 to 8 mm generally are required. In adults with exodeviations exceeding 70°, we recess the lateral rectus muscle as much as 10 to 12 mm behind its insertion and have never had more than moderate restriction of abduction develop postoperatively. One must remember that even though this puts the insertion behind the

anatomical equator of the eye, the lateral rectus muscle will remain in contact with the globe behind the equator (*functional equator*) and thus continue to exert rotational force on contraction. This is the reason this operation has a greater effect when performed on the medial than on the lateral rectus muscle.

In patients with long-standing strabismus who have a large and especially fixed angle with contracture of the conjunctiva and Tenon's capsule, the effect of recessing a rectus muscle can be augmented by recessing these tissues as well (see p. 616).

RECESSION OF VERTICAL RECTUS MUSCLES.

Surgery on the vertical rectus muscles has become a routine procedure in our time and is very effective and free of complications, provided certain precautions are taken and the amount of surgery is not excessive. Great care must be taken in dissecting the inferior rectus muscle from all its fascial attachments to Lockwood's ligament, since direct fibrous connections exist between the muscle and the tarsus of the lower lid. Failure to meticulously dissect these connections causes ptosis of the lower lid with resection or retraction of the lower lid when a recession of the inferior rectus muscle is performed. According to Jampolsky,¹²⁸ recession of the lower lid can be avoided by reattaching the capsulopalpebral head of the recessed inferior rectus to that muscle 15 mm from the limbus. This approach has been modified by others.^{144, 212, 270} We have been unsuccessful in consistently avoiding lower lid retraction using these or other methods to reattach the capsulopalpebral head.

The anatomical connections between the levator palpebrae and the superior rectus muscle are less critical in operating on the latter muscle. Relatively large amounts of recession (e.g., 8 to 9 mm for dissociated vertical deviations) or resection of the superior rectus muscle are tolerated well without causing changes of the upper lid position.

Since surgery on the vertical recti is more effective in terms of millimeters recession or resection per prism diopter correction and more predictable than surgery on the horizontal recti, we infrequently recess or resect the vertical recti more than 5 mm except in dissociated vertical deviations, endocrine ophthalmopathy, or fibrosis of an extraocular muscle.

SLANTING OF THE RECTUS MUSCLES. Fink⁷¹ mentioned that "some surgeons" tenotomize the

nasal fibers of the superior rectus muscle or advance the superior border and recess the inferior border of the medial rectus muscle to treat ex-cyclotropia. However, he provided no details or case reports to prove the effectiveness of this procedure. Lyle¹⁵⁰ reported, paradoxically, that advancing the temporal and recessing the medial borders of the inferior rectus muscle reduces ex-cyclotropia when, in fact, it should have increased it. Spielmann²⁶⁸ introduced slanting of the rectus muscle insertions to treat cyclotropia or a head tilt caused by congenital nystagmus with a neutral zone in a tertiary position. For instance, by recessing only the nasal portion of the right superior rectus, the inferior portion of the right medial, the temporal portion of the right inferior, and the superior portion of the right lateral rectus muscles, the right eye is incycloducted by approximately 10°. The same operation performed on the left eye will produce an excycloduction of the same amount. We can confirm the effectiveness of this operation but have abandoned it for simpler approaches, such as a horizontal transposition of the vertical¹⁹⁷ or vertical transposition of the horizontal rectus muscle.⁵³

Nemet and Stolovitch¹⁸² suggested resecting the upper border and recessing the lower border of the medial rectus muscles in convergence insufficiency to make the operation more effective at near than at distance fixation.

POSTERIOR FIXATION SUTURE. Cüppers,⁴⁹ in 1974, popularized a new operation termed *Fadenoperation*. A similar, though not identical, operation was actually described earlier by Peter²²⁰ in 1941, but it found little resonance at that time. With this operation, the action of a rectus muscle is selectively weakened in its primary field of action without disturbing the balance between agonist and antagonist in other positions of gaze. This is accomplished by suturing the muscle to the sclera behind the equator and thus creating a new insertion, posterior to the anatomical insertion (Fig. 26-1).

The word *faden* is German for "thread" or "suture" and is derived from the use of sutures to attach the muscle to the sclera. But sutures are used for most types of muscle surgery and hence the term Fadenoperation is rather nonspecific. Moreover, it had been used previously in the older German literature to describe traction sutures used to pull an eye operated on temporarily into an overcorrected position.^{45, 57} We suggested, there-

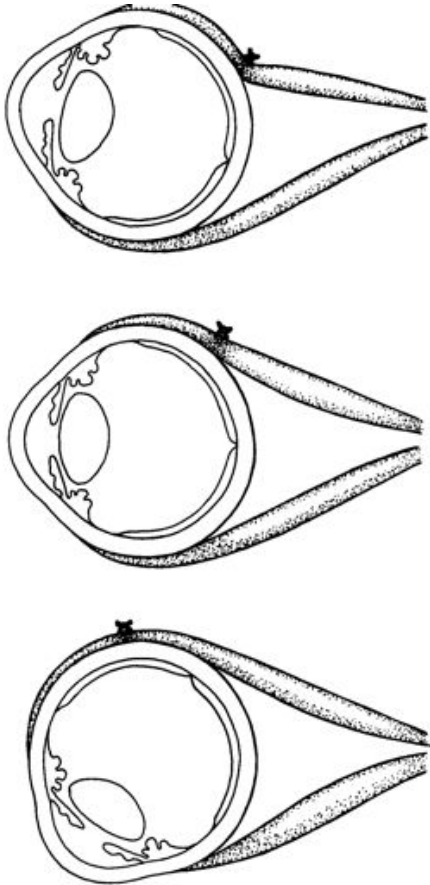


FIGURE 26-1. Posterior fixation of the superior rectus muscle weakens the effect of contraction of that muscle in elevation. With this operation the balance between the superior rectus muscle and the opposing inferior rectus muscle remains undisturbed in primary position and depression. (From von Noorden GK. Posterior fixation suture in strabismus surgery. In symposium on strabismus transactions of the New Orleans Academy of Ophthalmology. St Louis, Mosby-Year Book, 1976.

fore, that this operation be designated *posterior fixation suture* or *retropexy of an extraocular muscle*.¹⁸⁹ Even more precise, though considered by some as too ponderous, is *retroequatorial myopexy*. In view of these more descriptive and precise terms there is no justification for adopting “Fadenoperation” into the English language as has unfortunately become customary in the contemporary literature.

There are several mechanisms that may contribute to the effectiveness of this operation:

1. The ability of a rectus muscle to rotate the eye depends on the leverage existing between the center of rotation (CR) and the line of pull of the muscle at the tangential point (Pt) (Fig. 26-2A). By suturing the muscle behind the equator, the length of the moment arm (m) of this lever system is decreased and more muscle force (+ + +)

is now required to rotate the globe the same amount (Fig. 26-2B). The further retroequatorially the muscle is fixated, the greater the muscle force must be to maintain the same rotational effect on the globe. This classic explanation of the torque exerted by a rectus muscle has been challenged by Clark and coworkers³⁹ who, in 1999, demonstrated by axial magnetic resonance imaging (MRI), that a significant change in torque of a retroequatorially fixated horizontal rectus muscle actually does not occur. In fact, the angular displacement from tangency is much less than one would predict geometrically. They point out that the classic “arc of contact” concept on which the geometry shown in Figure 26-2 is based may have to be changed since it does not consider the nonlinear paths of the rectus muscles caused by pulleys and during muscle contraction.

2. Since the innervational requirement of a posteriorly fixated muscle for a given rotation of the globe increases and since there is equal innervation of yoke muscles (Hering’s law; see p. 64), the operation increases innervation to the yoke muscle of the fellow eye. For instance, by performing this operation on the superior rectus muscle of the nonparetic eye in a patient with an elevator paresis, the innervational requirements to elevate the eye operated on increase. Increased innervation will also flow to the

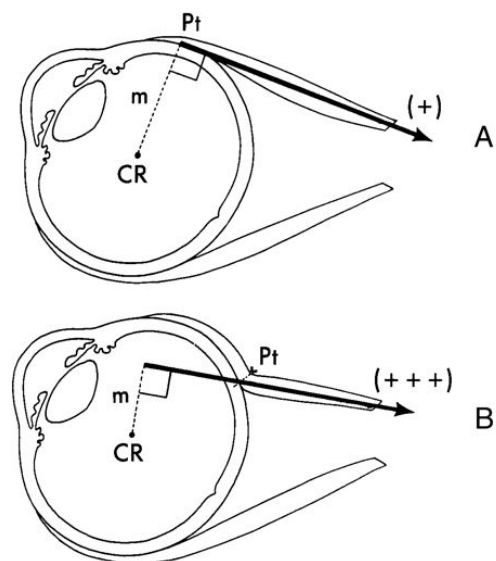


FIGURE 26-2. Mechanical effect of retroequatorial muscle fixation. For explanation, see text.

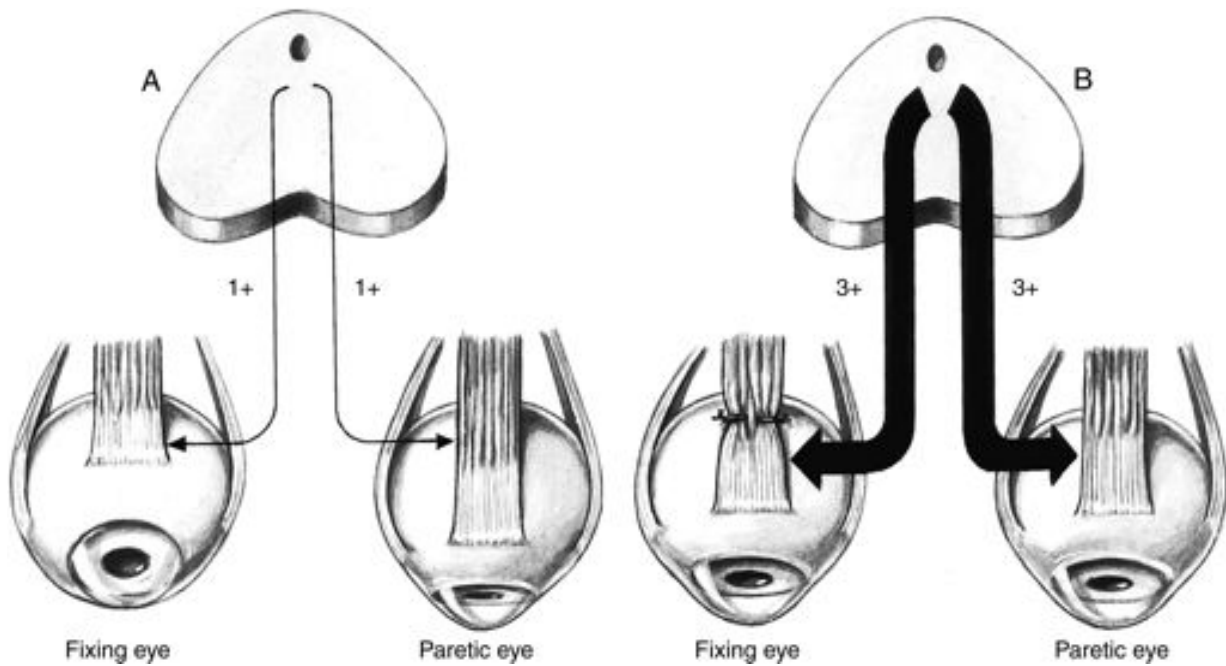


FIGURE 26-3. The innervation required to elevate the fixating nonparetic eye is insufficient to elevate the paretic eye in a patient with elevator paresis of the left eye, *A*, A posterior fixation of the superior rectus muscle of the fixating right eye increases the innervation requirement to elevate that eye. *B*, According to Hering's law of equal innervation, increased innervation will flow also to the yoke muscle in the fellow eye and elevation of the paretic eye improves.

paretic elevators of the fellow eye and improve their elevating force (Fig. 26-3). This principle is, of course, only applicable to patients who habitually fixate with their nonparetic eye.

3. A mechanical restriction occurs from a "reverse leash effect"¹²⁶ (Chapter 20), which is caused by the retroequatorially fixated and shortened medial rectus muscle pushing against the retrobulbar tissues as the eye adducts.^{198, 213} This restriction of adduction can be demonstrated with the forced duction test and may cause a jerk nystagmus of the abducted fellow eye so that the clinical picture resembles that of an internuclear paralysis.¹⁹⁸ Clark and coworkers³⁹ have provided further information on the nature of mechanical restriction of ocular rotation following posterior fixation. They suggested that the restriction that also occurs, though to a lesser degree, in abduction after posterior fixation of the lateral rectus muscle occurs because the *muscle pulley is deformed and stretched behind the suture*.
4. During the operation the muscle is considerably stretched, which causes its elongation proximal to the myopexy.

5. Since the segment of the muscle between its anatomical and new insertions is functionally inactivated, the contractile elements of the muscle are shortened and the effectiveness of a muscle contraction is decreased.

The posterior fixation suture has found a definitive place in our surgical armamentarium.^{12, 28, 49, 50, 54, 179, 189, 190, 193, 196, 269} In our experience the operation is most effective when performed on the medial rectus, less effective on the vertical rectus, and least effective on the lateral rectus muscle. We use it frequently in the treatment of incomitant strabismus in patients who are orthotropic in primary position but have diplopia in a peripheral position of gaze. For instance, a patient with a mild right abducens paresis will have single binocular vision in primary position and levoversion but experience uncrossed diplopia in dextroversion. A posterior fixation suture applied to the left medial rectus muscles will cause slight limitation of adduction of that eye without compromising normal binocular vision in primary position. This adduction limitation offsets the limitation of abduction, and single binocular vision will be present in all gaze positions. In other words, a paresis is treated by causing a slight and clinically insignificant paresis of the yoke muscle. Other applications

include nystagmus dampening by convergence (nystagmus blockages syndrome), and *esotropia with a variable angle*.

It was originally thought that the operation has no effect on the position of the eyes in primary position. Although this still holds true in patients who are orthotropic in primary position, posterior fixation of the medial rectus muscles will reduce esotropia in primary position by decreasing the effectiveness of an increased adduction innervation. If a significant deviation exists in the primary position and further weakening of muscle action is desired in the field of action of a medial rectus muscle, the operation may be combined with a muscle recession. We have also recommended this operation as a viable alternative to marginal myotomies of the medial recti in patients with a *persistent esotropia* in spite of previously performed maximal recession of the medial recti and resections of the lateral recti.¹⁹³ Klainguti¹³⁶ pointed out that a desirable cyclorotational effect can be obtained by placing the posterior fixation sutures obliquely into the inferior rectus muscle; fixating the nasal aspect of the muscle closer to the limbus than the temporal one reduced excyclotropia, especially in downward gaze.

Since a conventional posterior fixation suture is not adjustable, A. B. Scott²⁵³ suggested resecting a muscle before recessing it by an amount equal or greater than the resection and then placing it on a hang-back adjustable suture. This alternative to a posterior fixation should be kept in mind if for some reason retroequatorial suture placement is technically difficult or for other reasons (e.g., scleral thinning) is inadvisable (see also Bock and coworkers²⁰).

WEAKENING THE ACTION OF THE INFERIOR OBLIQUE MUSCLE. Weakening the action of the inferior oblique muscle can be achieved in many ways: the muscle may be myotomized, disinserted, denervated, anteriorly tranposed, extirpated, lengthened by marginal myotomy, recessed, or myectomized at its origin or through a conjunctival incision in the temporal inferior quadrant between its insertion and the inferior rectus muscle. With the exception of a myotomy or myectomy near the origin of the muscle—a technique that has been largely abandoned—all other procedures are currently in use, each strabismus surgeon championing one or the other favorite approach.^{43, 48, 63, 86–88, 216, 218, 276}

MYECTOMY. Having tried most of these methods, each of which has its advantages and disad-

vantages, over the years, the senior author has found that a *myectomy* through a conjunctival incision in the inferior temporal quadrant, as illustrated in Figure 26–11, consistently gave the most predictable results. This procedure is effective, fast, technically simple, and intra- or postoperative complications are exceedingly infrequent in our experience (see also Mulvihill and coworker¹⁷³). For these reasons the myectomy has evolved for one of us (GKvN) as the procedure of choice for weakening the action of the inferior oblique muscle. Once the presence of a significant increased elevation in adduction has been determined, a myectomy of the inferior oblique muscle may reduce the hyperdeviation in its field of action and also may reduce significantly a hyperdeviation in primary position. Moreover, if the action of the antagonistic superior oblique muscle has been impeded by a tight inferior oblique muscle, the function of the superior oblique muscle may improve after an inferior oblique weakening procedure. The average reduction of a hyperdeviation by inferior oblique myectomy in the field of action of that muscle in primary position and in the field of action of a paretic superior oblique muscle is 11.5^Δ and this effect increases with the size of the preoperative deviation.²⁸⁴ Weakening the action of the inferior oblique muscle tends to reduce or even eliminate excyclotropia, which is invariably present when this muscle overacts. Because of its abductive effect, a weakening procedure performed on the inferior oblique muscle alters the horizontal position of the eyes in upward gaze (see Chapter 19). The effect of this procedure on the horizontal position of the eyes in primary position is negligible.²⁷⁴ An overcorrection following surgery on this muscle is rare but tends to occur when a weakening operation is performed on a normally acting muscle or when the upshoot in adduction is only minimal.

In our experience, as well as that of others,²³¹ a unilateral inferior oblique weakening procedure should be performed only after it is clearly established that elevation of the adducted fellow eye is normal. If this point is overlooked, hypertropia of the eye not operated on invariably will occur postoperatively.

The *adherence syndrome* described by Parks²¹⁷ in 13% of myectomies performed at the insertion and in 2% of disinsertions of the muscle consists of a hypotropia greater in abduction than adduction and restricted elevation with a positive forced duction test. It is caused by a reattachment of the

muscle into “fatty Tenon’s tissue” and “proliferation of the fibrofatty tissue in the inferior temporal area extending up and attaching to the insertion and capsule of the inferior rectus muscle.”²¹⁷ In performing myectomies of the inferior oblique in the inferior temporal quadrant for the past 40 years, the senior author has encountered this complication only once

RECESSION. Many strabismologists (including the junior author) prefer to recess rather than myectomize this muscle. It has been argued that this operation is reversible in case of an overeffect and causes less bleeding and swelling. As mentioned above, an overcorrection has not been a problem for the senior author, provided this operation was not performed on a normally acting inferior oblique muscle. The ability to modulate the effect of surgery in asymmetrical cases of increased elevation in adduction is a good reason why recession is preferred by some. Interestingly, limitation of elevation in abduction of the eye operated on with secondary upshoot in adduction of the contralateral eye has been reported as a complication not only of anteriorization but also of recession of the inferior oblique muscle.¹⁴² A recession of only the *anterior* part of the inferior oblique insertion decreases the excycloduction effect of that muscle and an advancement increases it.⁴¹ Likewise, recession of its *posterior* aspect will decrease elevation in adduction without having an incyclorotatory effect.

ANTERIORIZATION. Transposing the insertion of the inferior oblique muscle to a position lateral to the insertion of the inferior rectus muscle^{65, 272, 273, 276} has gained some popularity in recent years. However, this procedure is not without its problems as it may produce changes in the palpebral fissure^{145a} or a limitation of elevation in abduction with secondary contralateral upshoot in adduction that may require additional surgery.^{145, 169, 277} Mims and Wood¹⁷⁰ suggested that this complication can be avoided by attaching the posterior fibers of the inferior oblique muscle not more than 2 mm lateral to the inferior rectus insertion site. In comparing the results of myectomy vs. anterior positioning, one group of authors found the latter procedure more effective.²⁹ On the other hand, such differences were not noted in other studies of a much larger patient group.^{35, 172} In view of the efficacy, lack of complications, and ease with which myectomy or recessions are performed, we see no reason to abandon either of these proce-

dures in favor of anteriorization of the inferior oblique muscle.

WEAKENING THE ACTION OF THE SUPERIOR OBLIQUE MUSCLE. As in the case of surgery on the inferior oblique muscle, numerous surgical procedures have been used to weaken the action of the superior oblique muscle. The tendon may be recessed, lengthened with silicone expander, severed, or a piece excised. The loose tissue surrounding the tendon may be left intact or severed along with the tendon. Over the years, each of these procedures has found its strong proponents. The impression has been created that by including or excluding the sheath (which some authors believe is not a true sheath but rather a reflection of Tenon’s capsule; see p. 467) in the operation, or by performing the tenotomy closer to or farther away from the trochlea, the surgical effect can be modified. In our experience, this has not been so. Once the continuity of the tendon has been completely disrupted, the effect will be the same regardless of where the tenotomy is done or whether the sheath, or whatever one may choose to call it, is sectioned or left intact. For this reason, and after having tried all procedures, we prefer to perform a *tenectomy* (including the sheath) midway between the insertion and the trochlea in the upper nasal quadrant or a recession.

TENECTOMY. As is true with weakening procedures on the inferior oblique muscle, it is difficult to predict precisely the amount of correction in terms of prism diopters achieved by tenectomy of the superior oblique muscle. Nevertheless, the operation is extremely effective in reducing the vertical deviation in downward gaze, an A pattern (see Chapter 19), or an incyclotropia. Overcorrections rarely occur, but if they do, they may cause severe functional problems in downward gaze. To avoid overcorrections, perform tenectomy only in those patients in whom a significantly increased elevation in adduction can be demonstrated unequivocally before surgery. The exception to this rule is a tenectomy in a patient with Brown syndrome.

RECESSION. In patients with milder yet functionally significant increased depression in adduction, we prefer, because of its reversibility, to recess the tendon, as proposed by Caldeira.^{30, 31} It is of interest, however, that a comparison of surgical results in patients treated with tenotomy or recession of the superior oblique tendon showed both procedures to be equally effective.²⁷

Recession of the *anterior* aspect of the superior oblique tendon decreases incycloduction and an advancement increases it.⁴¹ A tenotomy of the posterior fibers selectively weakens the vertical action of the muscle without altering its cycloducting effect. This procedure has been successfully employed to collapse an A-pattern with mild to moderate overaction of the superior oblique muscles.^{259, 288}

As an alternative to recession of tenectomy of the superior oblique muscles, Mombaerts and coworkers¹⁷¹ have advocated *surgical luxation of the tendon out of the trochlea* or of the trochlea and tendon and reported encouraging results in acquired Brown syndrome and apparent superior oblique overaction. This approach must await further studies to assess its value in comparison with other superior oblique muscle weakening procedures currently in use.

SILICONE EXPANDER. Rather than recessing the tendon, Wright³⁰⁵ introduced a *silicone expander* to lengthen it. He reported superior results with this method in Brown syndrome (see p. 471) when compared with tenectomy.^{307, 308} Other authors have also reported favorable results with the silicone expander technique in Brown syndrome²⁷⁵ as well as in superior oblique overaction with an A-pattern.^{224, 256} However, this operation is not without its problems.²⁹⁸ We had occasion to reoperate on several patients for extrusion of the implant. Moreover, the expander does not always protect against a subsequent symptomatic superior oblique paralysis.²²⁴ Mechanically, the lengthening of a tendon with an expander is not much different from performing a large recession of the tendon and the latter is a much simpler procedure. We prefer recession or a tenectomy rather than implanting foreign material near the superior aspect of the globe, an area that in our surgical experience is particularly prone to form adhesions and postoperative reaction.

MARGINAL MYOTOMY. Unlike a recession or posterior fixation suture, which reduces the action of a muscle by decreasing its rotational force on the globe, the marginal myotomy entails actual weakening of the muscle by reducing the number of contractile elements without changing its arc of contact with the globe. This procedure is effective in further reducing the action of an already maximally recessed rectus muscle or one that cannot be recessed because of extremely thin sclera, an implant, explant, or an encircling tube placed

directly behind its insertion during prior retinal surgery.¹⁰⁷ A review of 18 patients with persistent esotropia after maximal recession of the medial rectus muscle, in whom we performed a marginal myotomy of these muscles as a second procedure, showed a mean improvement of 9^Δ at distance and of 21^Δ at near fixation after a follow-up of 3 years.⁶⁸ The wide range indicates that the results of marginal myotomies are rather unpredictable.

A disadvantage of marginal myotomy is its irreversibility. In the case of a patient with persistent esotropia after maximal recession of both the medial rectus muscle and resection of both lateral rectus muscles, we found that application of posterior fixation sutures to the medial rectus muscles was an effective alternative procedure to marginal myotomy of the medial rectus muscles.¹⁹³

Operations to Strengthen the Action of a Muscle

To enhance the action of a muscle, one may shorten its length by tucking or resecting a portion of the tendon or, in the case of the rectus muscles, by advancing the line of insertion toward the limbus. A combined resection and advancement of a muscle is the most commonly performed operation to enhance muscle action. In terms of prism diopters of correction per millimeter of resection, a single resection usually is less effective than a single recession. Advancements, which have been rather neglected in recent years, are effective in increasing and stabilizing the results of a resection. Excessive resection may mechanically restrict movement of the globe in the opposite direction and therefore must be avoided.

HORIZONTAL RECTUS MUSCLES. The minimal amount of resection performed on the medial rectus muscle is 4 mm, and the maximal amount rarely exceeds 7 or 8 mm. We infrequently resect the lateral rectus muscle less than 4 mm or more than 10 mm. When more correction is desired, the muscle is advanced toward the cornea.

VERTICAL RECTUS MUSCLES. In strengthening procedures, as in weakening operations, the relationship of the vertical rectus muscles to the lid structures must be taken into account. We rarely resect the vertical rectus muscles less than 2 mm or more than 5 mm. As mentioned, in terms of prism diopter correction per millimeter of surgery, a resection of the vertical rectus muscle is more

effective than a comparable procedure on the horizontal rectus muscles.

INFERIOR OBLIQUE MUSCLE. Many technical problems occur with the operation to strengthen the action of the inferior oblique muscle. Resection of the inferior oblique muscle at its insertion and advancement, in particular, must be performed with great care to avoid injury to adjacent structures such as the fovea.⁴¹ Moreover, in our experience, this procedure is notoriously ineffective in improving ocular motility in the field of action of this muscle. For this reason, we prefer to weaken the action of the superior rectus muscle in the fellow eye or, in the case of inferior oblique paralysis, to perform a tenectomy of the ipsilateral superior oblique muscle.²⁰⁸

SUPERIOR OBLIQUE MUSCLE. A tuck of the superior oblique tendon is effective in improving depression of the adducted eye and in counteracting excyclotropia. One complication of this operation is temporary inability to elevate the adducted eye, similar to Brown syndrome (see Chapter 21). Even though this overeffect normally subsides after several months, we observed permanent restriction of ocular motility in upward gaze in several instances. The length of tendon included in the tuck ranges from 6 to 12 mm and the decision of how much to tuck depends not only on the degree of hypotropia of the adducted eye but also on the tendon's tightness. As a rule, we perform larger tucks in congenital superior oblique paralysis than in acquired superior oblique paralysis where the tendon is often tight. The tightness of the tendon must be ascertained by the rotational duction test (see p. 423) and determines the size of the muscle tuck. By keeping these points in mind, a postoperative limitation of elevation in adduction (iatrogenic Brown syndrome) can usually be avoided.

Combined Recession-Resection Operation

Weakening of an agonist combined with strengthening the action of the antagonist in the same operative session adds greatly to the effectiveness of each procedure and tends to stabilize the surgical result. Clinical experience supports the concept that each resection operation reduces the amount of contracture that normally occurs in the recessed antagonist. Thus a resection is often added not so

much on its own account but rather as a means to ensure the effectiveness of the recession.²⁸¹

The amount of this surgery depends, as always, on the individual case, and one should determine whether a recession supported by a resection or a resection supported by a recession is the more appropriate approach. The answer is determined from the behavior of the rotations and from measurements of the deviation.

In comitant strabismus, we usually do not perform more than a 5-mm recession of a medial rectus muscle combined with an 8- to 10-mm resection of a lateral rectus muscle for esotropia and an 8-mm recession of a lateral rectus muscle combined with a 7-mm resection of the medial rectus muscle for exotropia (for an exception, see p. 573). When a combined operation of the vertical rectus muscles is indicated, we usually recess one vertical rectus muscle 3 mm and resect its antagonist 4 mm. Combined procedures may also be performed on the oblique muscles (e.g., tucking of the superior oblique and a myectomy of the antagonistic inferior oblique muscle) but are indicated only if the hypertropia in the paretic field of gaze exceeds 25^Δ (see p. 449).

Single vs. Multiple Procedures

Many exposures to general anesthesia clearly should be avoided, and the eyes should be aligned with a minimum of operations. With this in mind, it is appropriate to operate on more than one set of muscles during one surgical session, and in large deviations we also operate on all four horizontal muscles in the two eyes.

We maximally recess both medial rectus muscles and resect one lateral rectus muscle to correct esodeviations exceeding 50^Δ and operate on all horizontal rectus muscles if the deviation exceeds 75^Δ. Likewise, a recession of both lateral rectus muscles combined with resection of one medial rectus muscle may be considered for an exodeviation of more than 50^Δ, and all four horizontal muscles can be operated on if the deviation measures more than 75^Δ.

When small incomitant vertical deviations along with comitant horizontal deviations are present, it is undesirable to attempt to correct both deviations at the same time. A relatively small deviation in one direction often is influenced by the surgical correction of the deviation in the other

direction. It is wise therefore to permit some time to elapse between procedures to determine the effect of the correction of the horizontal deviation on the vertical deviation. Small comitant vertical deviations associated with horizontal deviations respond well to vertical transpositions of the horizontal rectus muscles at the time of their recession or resection (see p. 612).

For a large vertical deviation, which may be the cause of the horizontal deviation by impeding binocularity, an attempt should be made first to correct the vertical deviation. If the vertical deviation is smaller than the horizontal deviation, the horizontal deviation is corrected first. Additional operative procedures depend on the outcome of the initial operation.

The presence of an A or V pattern with increased elevation or depression in adduction alters the rule for correcting horizontal and vertical deviations in separate operations. In such cases, we combine horizontal and oblique muscle surgery in one procedure, as described in Chapter 19.

Preparation of Patient and Parents for Surgery

A great deal of unnecessary fear and bewilderment can be avoided by appropriate psychological preparation of the parents and patient. The strabismus surgeon must realize that the first mention of surgery to the parents of a strabismic child may cause considerable anxiety, and the subject should be approached gently and in anticipation of the parents' possible reactions, preferably with the child outside the examination area. The operation should be explained briefly (without going into unnecessary details) to dispel fears and the astonishingly frequent notion that the eye is temporarily removed from the orbit during surgery or that surgery is performed with laser beams. We often sense a mild disappointment when we explain that there is no need for lasers. The parents also should be told how much, if any, postoperative discomfort can be expected. One should make a point of mentioning which eye is to be operated on, but qualify this by saying that plans sometimes have to be altered during the operation. In the case of alternating strabismus with equal visual acuity and essentially normal versions, for which it really does not matter which eye is operated on, the surgeon should make a choice *before* surgery and inform the patient or parents accordingly. Nothing

is more difficult to explain to a patient or the parents why, in some conditions, it makes no difference on which eye the surgery is performed, or why the right eye was operated on when the surgeon had previously mentioned it would be the left eye! Just in case unusual findings at the time of surgery, such as extensive scarring from previous operations, unexpected anatomical anomalies, or absence of a muscle, necessitate a change of plans, it is prudent to obtain permission to operate on either eye before surgery.

Finally, it is a grave mistake to be overconfident in predicting the outcome of strabismus surgery. The late Dr. Alan C. Woods, when questioned by an anxious mother about whether he could guarantee the result of strabismus surgery on her child, replied, "Madam, in order to do that I would have to be God or a damned fool, and I am neither." The possibility of an overcorrection or undercorrection and the need for more than one operation should be mentioned. If this is adequately explained, most parents will maintain confidence in the surgeon rather than question his or her ability if another operation becomes necessary.

Anesthesia

General Anesthesia

The globe and its adnexa can be completely anesthetized locally, so that operations on the extraocular muscles can be performed painlessly. Every adult should be informed of this possibility and given the choice between local and general anesthesia. Children and apprehensive or nervous adult patients should be given a general anesthetic. We always use general anesthesia for patients who undergo reoperations, surgery on the inferior rectus muscle for endocrine ophthalmopathy, or surgery on the muscles of both eyes.

Most hospitals in which eye surgery is performed have an anesthesiologist available, which relieves the ophthalmologist of a serious responsibility. The surgeon should abide by the suggestions and rules of the anesthesiologist, who should also be acquainted with the patient and suggest the choice of anesthetic. However, the ophthalmologist must be aware of the details of the anesthesia. In most hospitals the anesthesiologist will insist on intubating the patient, even the youngest infant.

Needless to say, a patient undergoing elective

surgery must be in good health. A physical examination before the operation is mandatory and in children is best performed by their pediatrician. It has been recommended that at least 1 month be allowed between the last upper respiratory infection and the date of surgery since intra-anesthetic pulmonary dysfunction has been observed when this rule was violated.¹⁵⁷

As mentioned on page 570, the position of the eyes during surgical levels of anesthesia is different from that during the waking stage in most patients with strabismus of nonmechanical origin. In esotropes in particular, the eyes appear to be less esotropic or even exotropic when innervation of the extraocular muscles is suspended. The inexperienced surgeon is easily intimidated by this observation and will perform less surgery than originally intended. This will produce an undercorrection, of course, and reoperation will become necessary.

Local Anesthesia

To obtain *akinesia* of the lid, we inject 2 mL of 1% lidocaine over the condyloid process of the mandible, according to the method of O'Brien.

Local anesthesia is then induced with several drops of 0.5% proparacaine hydrochloride (Ophthaine), followed by an injection of 1% lidocaine underneath Tenon's capsule in the quadrant in which surgery is performed. The sub-Tenon's space is entered with the injection needle 3 mm behind the limbus, anterior to the muscle insertion. The injected solution will rapidly spread, ballooning conjunctiva and Tenon's capsule into all four quadrants. A retrobulbar injection is rarely necessary. If the tissue is handled gently and excess traction of the muscle is avoided, the patient will tolerate muscle surgery under local anesthesia very well. However, for surgery on the oblique muscles and when applying posterior fixation sutures, we insist on general anesthesia to avoid the pain associated with excessive pulling on the muscle. The same applies to the patient with endocrine orbitopathy.

Instruments, Sutures, Needles

The complete instrument set that we use in strabismus surgery is shown in Figure 26-4. Although

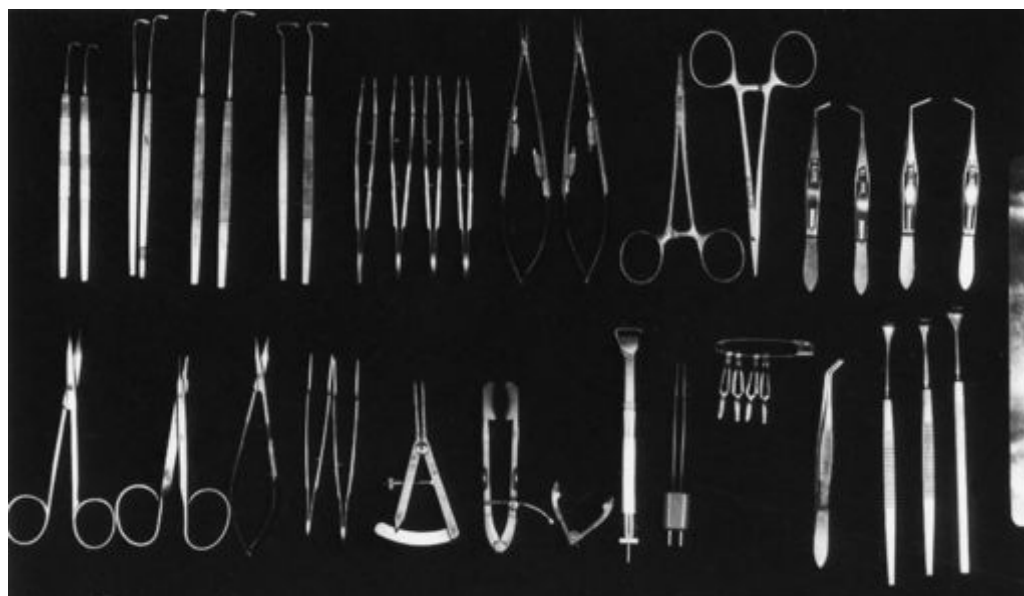


FIGURE 26-4. Instruments for strabismus surgery. *Upper row from left to right:* Stevens tenotomy hooks (2); Graefe muscle hooks No. 1 (2); Graefe muscle hooks No. 3 (2); Jameson muscle hooks (2); Castroviejo suturing forceps 0.3 (2); Castroviejo suturing forceps 0.5 (2); Castroviejo needle holders, heavy model (2); mosquito hemostats (2); Jameson resection clamps, right and left, child size (2); Jameson resection clamps, right and left, adult size (2). *Lower row from left to right:* Stevens tenotomy scissors, curved (1); Stevens tenotomy scissors, short blades, straight (1); Wescott tenotomy scissors, blunt point (1); smooth tying forceps (2); Castroviejo caliper (1); Lester-Burch speculum (1); Sauer infant speculum (1); Burch tendon tucker, modified by von Noorden (1)¹⁹²; wet field cautery forceps (1); serrefines (4); Nugent utility forceps (1); Desmarres lid retractors, sizes 1, 2, 3 (3); malleable neurosurgical retractor (1).

not all of these instruments are routinely used for each procedure, we like to have the complete set available for each operation. For the control of minor bleeding we use Visi-Sorb Absorbent Sticks.* Unlike Q-Tips, which after each application leave numerous irritating cotton fibers behind, or Weck sponges, which are too soft for applying pressure on a capillary bleeding site, we have found these cellulose sticks especially suitable for muscle surgery.

For all recessions and resections, we use 6-0 coated Vicryl (polyglactin 910) suture with an S-14 spatula needle. Vicryl is a synthetic, absorbable suture that has practically eliminated acute allergic suture reactions or formation of postoperative granulomas. However, this suture has some tissue drag; therefore it is somewhat difficult for the inexperienced surgeon to tie snugly to the sclera. Vicryl (7-0) on a GS-9 needle is used for conjunctiva closure.

Some surgeons prefer nonabsorbable sutures such as silk, Dacron (polyethylene terephthalate fiber), nylon, or Mersilene for recession or resection operations. However, unless the knot is buried under the muscle, as advocated by Reinecke,²³⁴ such sutures remain visible through thin conjunctiva for many years; for this reason, we have stopped using them.

Attempts have been made to reattach muscle to sclera by means other than suturing and thus to avoid the risks of perforation and intraocular infection. Various tissue glues have been experimented with and Spierer and coworkers²⁷¹ showed that fibrin sealant was effective in reattaching extraocular muscles in rabbits, provided a muscle recession was large. With small recessions the contractile strength of the muscle exceeded the holding power of the glue. Clearly, this research is still in its exploratory stage and its importance has also been diminished by the much increased safety of muscle surgery and the development of spatula needles. Unlike curved cutting and reversed cutting needles, these needles have a flat back, a thin profile, a sharp tip, and a cutting edge only at the sides. In our opinion, they are preferable to all other needles for strabismus surgery. The improved control of passage of the needle through the superficial lamellae of even the thinnest sclera minimizes trauma and the danger of perforation.

The needle must be passed through the sclera in such a manner that it remains visible through the scleral lamellae at all times. We prefer the same type of needle for traction sutures.

Surgical Techniques

Few ophthalmologic operations have so many variations as surgery of the extraocular muscles. Methods of exposing muscle, passing or tying the suture, and measuring the amounts of recession or resection differ with each surgeon. It follows that a specified number of millimeters of muscle recession or resection will have a different effect on a deviation in the hands of one surgeon than in those of another surgeon. A surgeon's technique is determined largely by training. With growing experience and exposure to other methods a surgeon is likely to modify procedures and eventually develop an individualized technique. In the following discussion, only those techniques are discussed to which the authors of this book have become accustomed, without implying that our methods are better than the many others in use but not described in this book. We reviewed the surgical techniques of 17 North American strabismus surgeons and found vast differences in their technique of reattaching the muscle to the sclera.¹⁸⁷ Several texts dealing with extraocular muscle surgery are available to which the reader is referred for a description of methods other than those discussed here.^{32, 106, 218, 245, 304}

We do not believe that strabismus surgery must be routinely performed under the operating microscope but believe that surgical loupes and optimal illumination, enhanced, if necessary, by a fiberoptic headlight worn by the surgeon, are indispensable aids to optimal surgical technique.

Preparation of the Eye

The periorbital skin is scrubbed for 3 minutes with hexachlorophene (pHisoHex) after which the skin and the upper and lower fornices are thoroughly rinsed with normal saline. The periorbital skin is then dried with a sterile towel and painted with povidone-iodine (Betadine). Isenberg and coworkers¹¹⁹ advocated rinsing the ocular surfaces with a half-strength povidone-iodine solution routinely for strabismus surgery after having shown an antibacterial effect of this preparation. There is also some evidence that this procedure may decrease

*VISITEC, 7575 Commerce Court, Sarasota, FL 34243-3218 and Waterloo Road Industrial Estate, Bidford-on-Avon, Warwickshire B504JH, England.

the prevalence of bacterial endophthalmitis,^{266, 267} although additional data based on a randomized prospective study are lacking to further substantiate this claim.

Fixation of the Globe

During general anesthesia the eye may rotate inconspicuously around its anteroposterior axis. Unless recognized by the surgeon, this malorientation of the globe may lead to an incision at the wrong place and even to surgery on the wrong muscle. For orientation and for improved exposure, we prefer fixation sutures that permit rotation and fixation of the globe into any desired position during the procedure. These sutures (6-0 Mersilene on an S-14 needle) are inserted through the conjunctiva and superficial sclera close to the limbus in the 12- and 6-o'clock positions for surgery on horizontal muscles and in the 9- and 3-o'clock positions for surgery on vertical rectus muscles. For surgery on the inferior oblique muscle, only one suture is inserted close to the limbus in the inferotemporal quadrant. Before inserting the fixation sutures, the surgeon must verify the position of the eye by looking for prominent landmarks such as the insertion of the rectus muscles, which normally can be identified through overlying conjunctiva and Tenon's capsule, or the positions of the semilunar fold and caruncle.

Conjunctival Incision and Exposure of a Rectus Muscle

Various techniques for exposing the rectus muscles have been described, most of which consist of direct or indirect transconjunctival incisions anterior or posterior to the muscle insertion or in the fornix.²¹⁵ Each of these methods has advantages and disadvantages, but in our opinion, they are somewhat less than ideal. An ideal technique should be technically simple and minimally traumatic, provide quick access to the muscle, and achieve an optimal cosmetic result soon after surgery. These criteria are met by the *limbal conjunctival incision*, which probably was used as early as von Graefe's time but was reintroduced by Cortes (1962)⁴⁶ in South America, by Massin and Hudelo (1962)¹⁵⁵ and de Decker (1967)⁵² in Europe, and by von Noorden (1968–1969)^{184, 185} in the United States. Zugsmith³⁰⁹ had suggested earlier (1959) the use of this incision for surgery on the inferior oblique muscle.

By using this incision, we found that the normal anatomical relationship between Tenon's capsule and conjunctiva remains undisturbed and that Tenon's capsule is not traumatized. The limbal conjunctival incision not only provides easy, quick access to the muscle but causes minimal redness and prevents adhesions, leading to an optimal cosmetic and functional result. Another advantage of using this incision is that conjunctival recession or adjustable sutures can be performed with ease and that surgical exposure during muscle transpositions is better than through a fornix-based incision.

The various steps of the limbal conjunctival incision are illustrated in Figure 26–5 in which exposure of the right medial rectus muscle is used as an example. The surgeon sits at the right temporal side of the patient's head and the assistant at the opposite side. All illustrations used in this chapter to demonstrate surgical techniques show the eye as viewed by the surgeon.

After insertion of the lid speculum, two 6-0 Mersilene sutures are placed with spatula needles through the episclera and the limbus in the 6- and 12-o'clock positions, and the eye is rotated temporally to expose the site of the operation (Fig. 26–5A). Conjunctiva and Tenon's capsule are united into a single layer close to the limbus. Thus a conjunctival incision in the limbal area provides direct access to Tenon's space. The conjoined layer is grasped close to the limbus, and a small radial incision is made through these layers perpendicular to the limbus down to the sclera (Fig. 26–5B). The combined layer of conjunctiva and Tenon's capsule is undermined by spreading the blades of spring-action blunt Wescott scissors (Fig. 26–5C) and is then severed from the limbus (Fig. 26–5D). At this point, slight bleeding from the perilimbal capillaries may be encountered but is easily controlled by pressure with absorbent sponges or an application with the wet field cautery.

The second radial incision is then made (Fig. 26–5E). The radial incisions are 3 to 4 mm in length, but may be extended 5 mm or more when a large recession or a posterior fixation suture is planned. The curved tenotomy scissors are then inserted into the upper and lower nasal quadrant, and the blades are spread gently only once to separate Tenon's capsule from the episclera (Fig. 26–5F and G). Care must be taken not to advance the scissors directly toward the muscle insertion to avoid injury to muscle fibers, which could cause

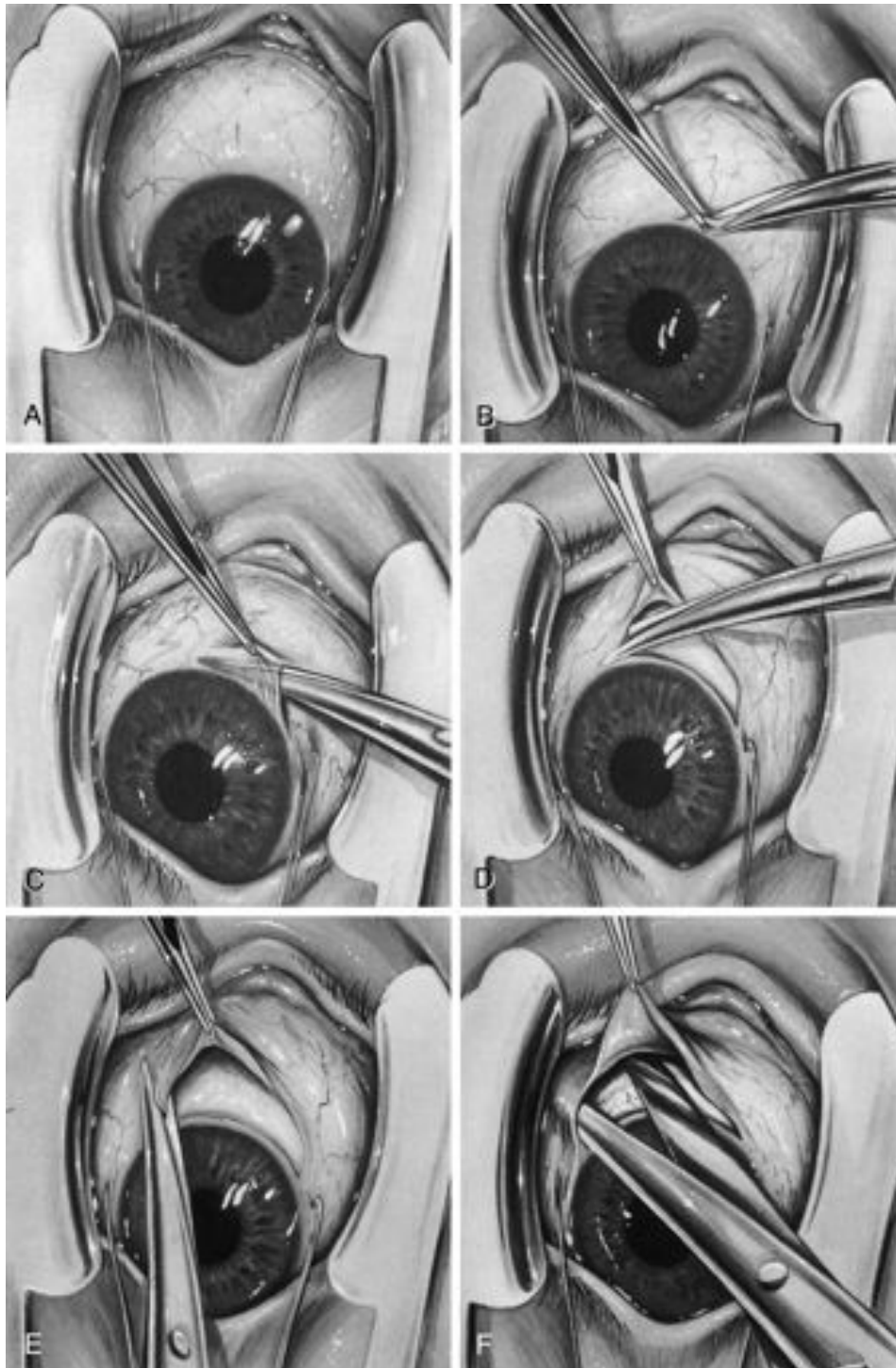


FIGURE 26-5. Conjunctival incision, muscle exposure, and wound closure. For explanation, see text. (From von Noorden GK: Extraocular muscles. In Beyer-Machule CK, von Noorden GK, eds: Lids, Orbits, Extraocular Muscles, Vol 1. In Heilmann K, Paton D, eds: Atlas of Ophthalmic Surgery. New York, Thieme-Stratton, 1985.)

Illustration continued on following page

bleeding. The conjunctival flap is then retracted, with forceps or a Graefe muscle hook No. 3 and a Jameson muscle hook is then inserted with its tip pointing away from the insertion (Fig. 26-5H).

The muscle is engaged by rotating the hook 180° (arrow in Fig. 26-5H) and exposed by

applying traction to the handle of the hook (Fig 26-5I). The assistant exposes the muscle and its inferior and superior fascial connections (falci-form folds of Guérin) by lifting conjunctiva and Tenon's capsule with two Graefe hooks No. 3 (Fig. 26-5J). The inferior border of the muscle is

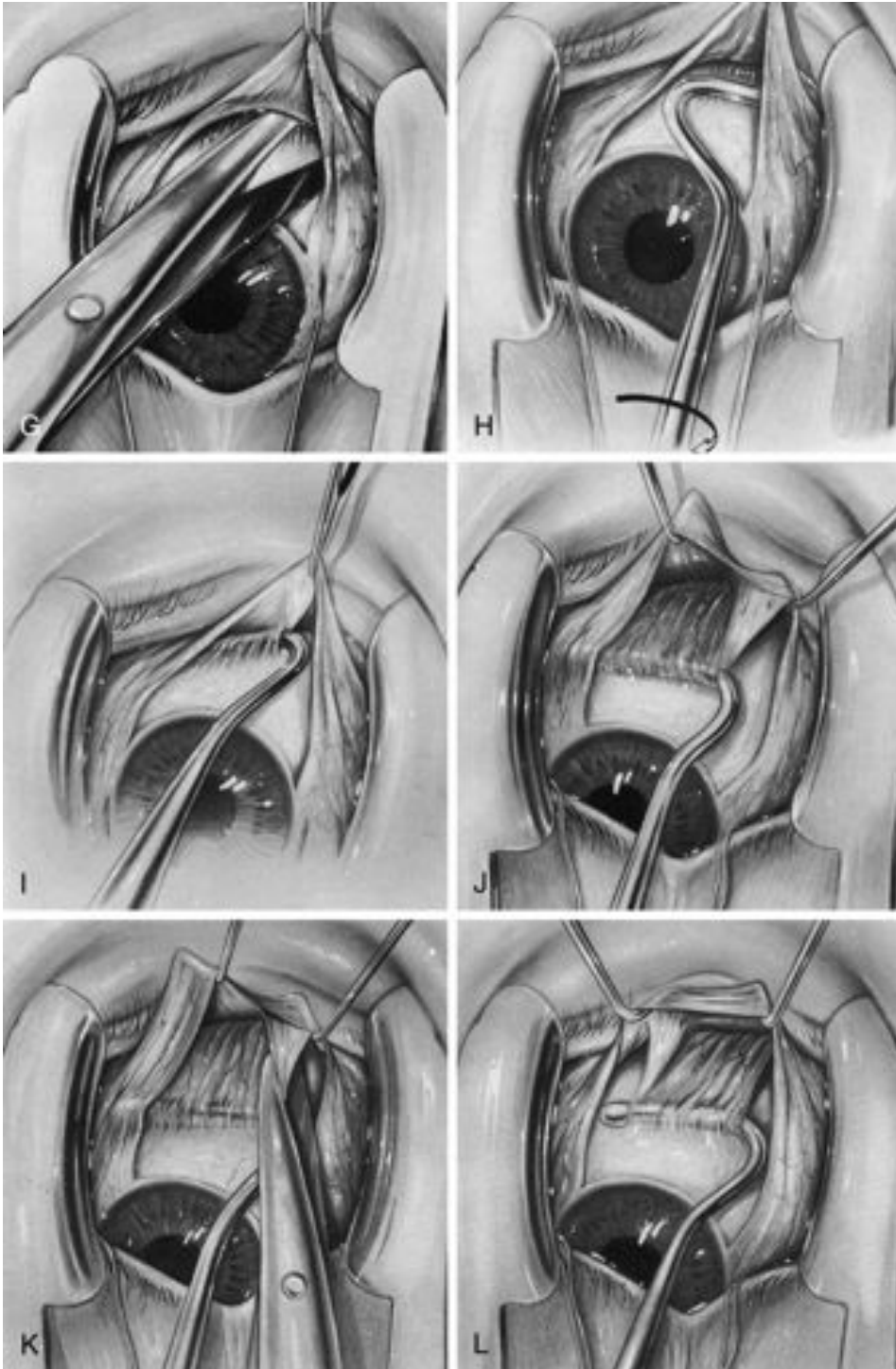


FIGURE 26-5 *Continued.* For legend, see p. 585.

freed by sharp dissection (Fig. 26-5K), after which the superior border is similarly exposed (Fig. 26-5L) and freed by dissection (not shown).

When one exposes the *lateral rectus muscle*, especially if this muscle has previously been operated on, it is advisable to pass the tip of the muscle hook under the muscle insertion from above to avoid accidental engagement of muscle fibers from the inferior oblique muscle.¹⁰⁸ Failure to rec-

ognize this potential complication results in post-operative hypertropia or deficiency of vertical rotation.¹⁷⁶

After completion of the procedure the wound is closed with two 7-0 Vicryl sutures on a GS-9 needle passed through the edges of the flap, limbal conjunctiva, and episclera (Fig. 26-5M and N). These sutures should be cut short to avoid irritation. If the perpendicular incisions are larger than

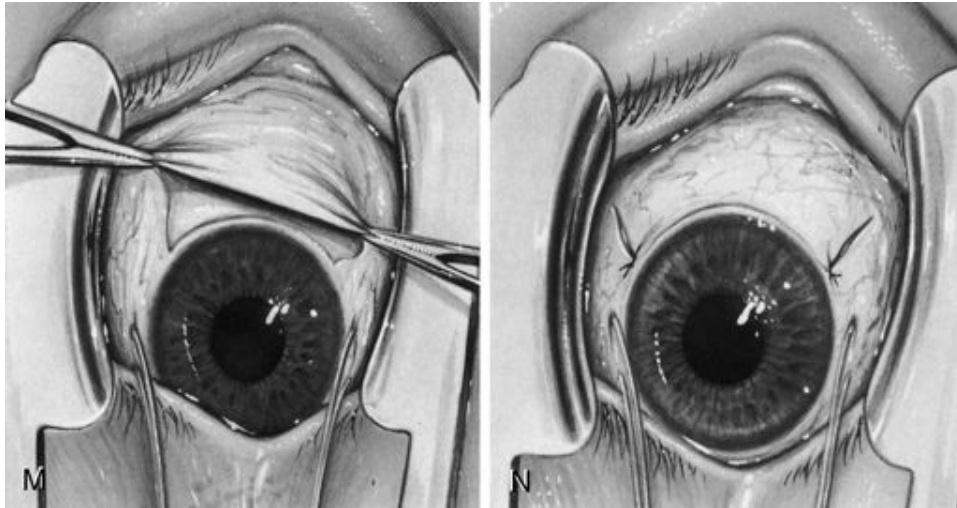


FIGURE 26-5 *Continued.* For legend, see p. 585.

4 or 5 mm, they may be closed with one additional suture. While the wound is being closed, it is important not to leave a conjunctival ridge near the limbus, since this is cosmetically unsatisfactory and causes interruption of the tear film that in turn may produce a corneal dellen.

Occasional difficulties may be encountered in identifying the wound edges, and special care must be taken not to grasp and suture Tenon's capsule, which may prolapse spontaneously from under the conjunctiva during the operation, especially after the tissue has been excessively manipulated. To distinguish between conjunctiva and Tenon's capsule, it is helpful to remember that, unlike conjunctiva, Tenon's capsule is an avascular structure. For the less experienced surgeon we recommend placement of a small suture knot at each edge of the conjunctival flap to identify the corners at the conclusion of the operation.

Recession of a Rectus Muscle

After exposure of the rectus muscle, as shown in the preceding discussion, the surgeon must determine whether the muscle is completely engaged by passing a second hook repeatedly from above and from below or, in the case of the vertical rectus muscle, nasally and temporally under the insertion. During a recession operation, we always cut the check ligaments, although some surgeons believe that this does not enhance the effect of surgery.⁸⁰ During surgery on the superior rectus muscle, accidental inclusion of the superior oblique tendon on the muscle hook must be avoided. When recessing the inferior rectus muscle, one should take special care to dissect the

intermuscular membrane and all fascial attachments between the inferior rectus muscle and Lockwood's ligament as far posterior as possible to prevent postoperative changes in the position of the lower lid. When isolating the inferior rectus muscle, one should remember that the nerve supply to the inferior oblique enters this muscle just as it passes the lateral border of the inferior rectus muscle, 12 mm posterior to the inferior rectus insertion.

After the muscle has been thus prepared, two single-armed sutures are inserted and locked to the lower and upper edges of the muscle close to the insertion (Fig. 26-6A-D). As mentioned earlier, we prefer a 6-0 coated Vicryl suture with spatula needles for all recession operations. Care is taken to include all anterior ciliary arteries in the suture lock. Serrefines are clamped to the armed end and the free end of each suture for later identification. The surgeon then applies tension to the muscle hook and the sutures (Fig. 26-6E) while the muscle tendon is dissected from the sclera using curved Stevens tenotomy scissors (Fig. 26-6F). Bleeding from the capillaries on the muscle stump is controlled by applying pressure or using wet field cautery. While the stump of the insertion remaining on the sclera is grasped with a forceps, the assistant places one prong of the preset caliper next to the forceps and indents the sclera with the other end (Fig. 26-6G) to provide a mark to identify the site of reinsertion. Keech and coworkers¹³⁵ pointed out that the insertion site may be displaced anteriorly more than 1 mm during disinsertion of the muscle and while pulling on it with a fixation forceps to stabilize the globe during determination of the reattachment site. This

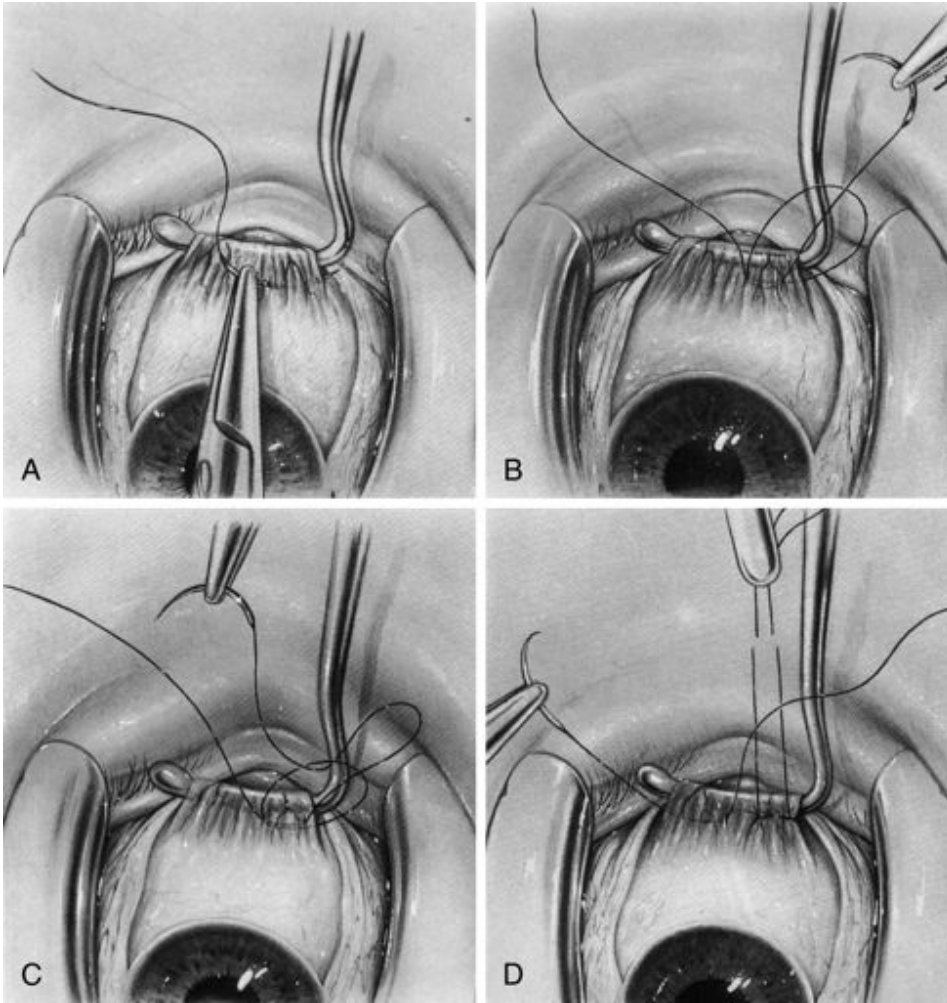


FIGURE 26-6. Recession of the right medial rectus muscle. For explanation, see text. (From von Noorden GK: Extraocular muscles. In Beyer-Machule CK, von Noorden GK, eds: *Lids, Orbits, Extraocular Muscles*, Vol 1. In Heilmann K, Paton D, eds: *Atlas of Ophthalmic Surgery*. New York, Thieme-Stratton, 1985.)

factor needs to be considered if the insertion site is used as a point of reference. The needles are then inserted through the sclera, entering the tissue at the mark and emerging slightly lateral and parallel to the limbus (Fig. 26-6H and I). The needle should be visible at all times while passing through superficial scleral lamellae, and deep passage, especially perforation, must be avoided. The sutures are then tied and cut, and the new insertion is carefully inspected before closing the wound (Fig. 26-6J).

Some authors prefer to hang back the muscle routinely on a suture loop from the original insertion rather than suture it to the sclera.^{64, 85, 167, 238, 236} This technique is used by us only in patients with very thin scleras, those with scleral explants after retinal surgery, or when there are mechanical restrictions that prevent adequate exposure of the

scleral reattachment site. In most other situations we feel more secure knowing that the muscle is exactly where we put it with sutures. The possibility exists that a suture-suspended muscle may move toward its old insertion once the eye is returned to primary position at the end of the operation. Interestingly, the histologic examination of loop-recessed extraocular muscles revealed that the sutures eventually become replaced by a pseudotendon that resembles real tendon.⁶⁴

Resection of a Rectus Muscle

Resection of a rectus muscle is illustrated using the right lateral rectus as an example. The surgeon faces the left side of the patient's head; the assistant is on the opposite side.

After being exposed and placed on a muscle

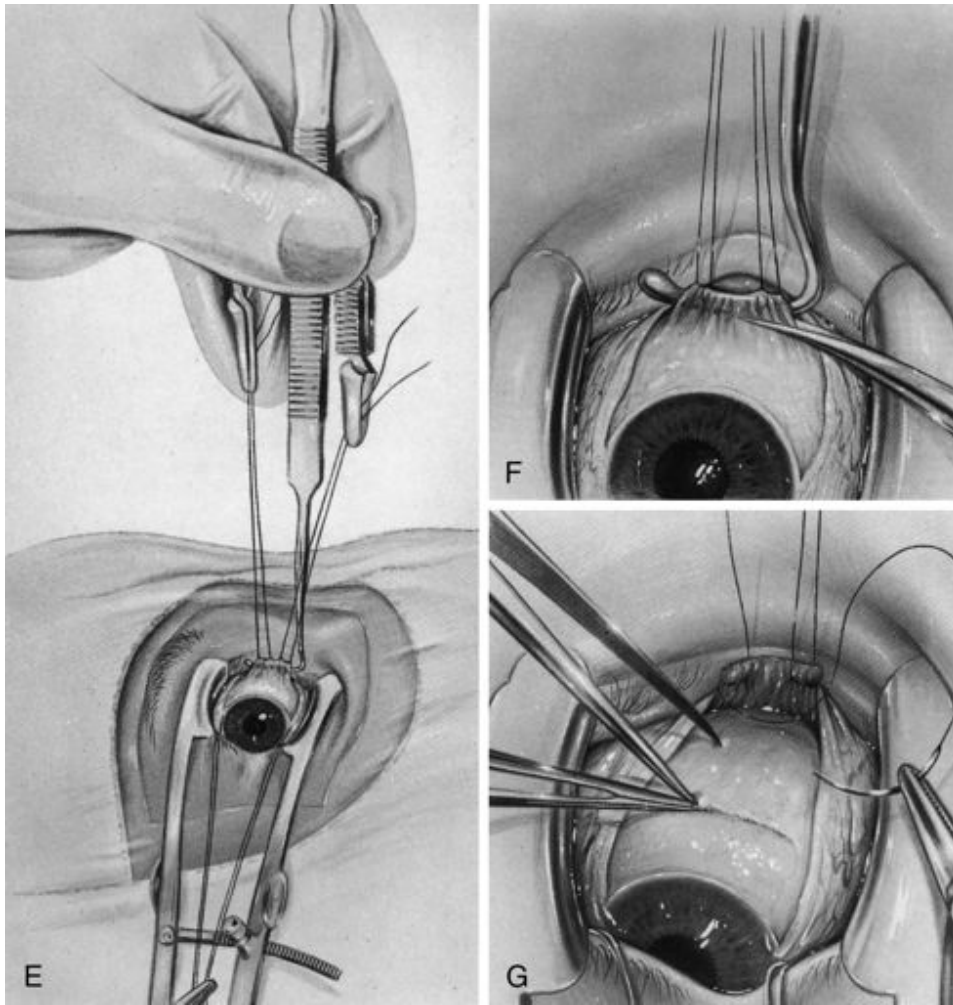


FIGURE 26-6 *Continued.* For legend, see p. 588.

Illustration continued on following page

hook (see Fig. 26-5), the rectus muscle is freed as far as necessary to apply the resection clamp. Fascial structures are left intact as much as possible since their presence may add materially to the effect of the operation. A Jameson resection clamp is then placed on the muscle with its smooth side toward the underside of the muscle belly (Fig. 26-7A). The clamp is placed so that its posterior edge corresponds with the amount of muscle that is to be shortened, as determined with a caliper (Fig. 26-7B). One should not pull excessively on the muscle when making this measurement, since the amount of resection is calculated by the amount of the unstretched muscle.

A common error of inexperienced surgeons during this step of the operation may result in resecting more of the muscle than intended. This occurs when the tendon is plicated as the muscle hook pulls the eye toward the surgeon (Fig. 26-7C). Since this folded part is not included in the

caliper measurement, an additional 2 to 3 mm of muscle may thus be unintentionally resected.

After the clamp has been applied and locked, the muscle is severed from the sclera with curved tenotomy scissors at its point of insertion and any footplates or other connections of the tendon to the sclera are removed at that time (Fig. 26-7D). Wet field cautery is used to control bleeding of the muscle stump. Two double-armed 6-0 coated Vicryl sutures are then placed through the stump, one needle of each suture being placed close to the center of the insertion and the other through the corresponding end (Fig. 26-7E-G).

The sutures are then carried through the muscle, which is lifted by the clamp, and the needles are placed through the underside of the belly as closely as possible to the posterior edge of the blade of the clamp (Fig. 26-7H). The central sutures are placed close to the middle of the muscle belly and the outer sutures at the corresponding

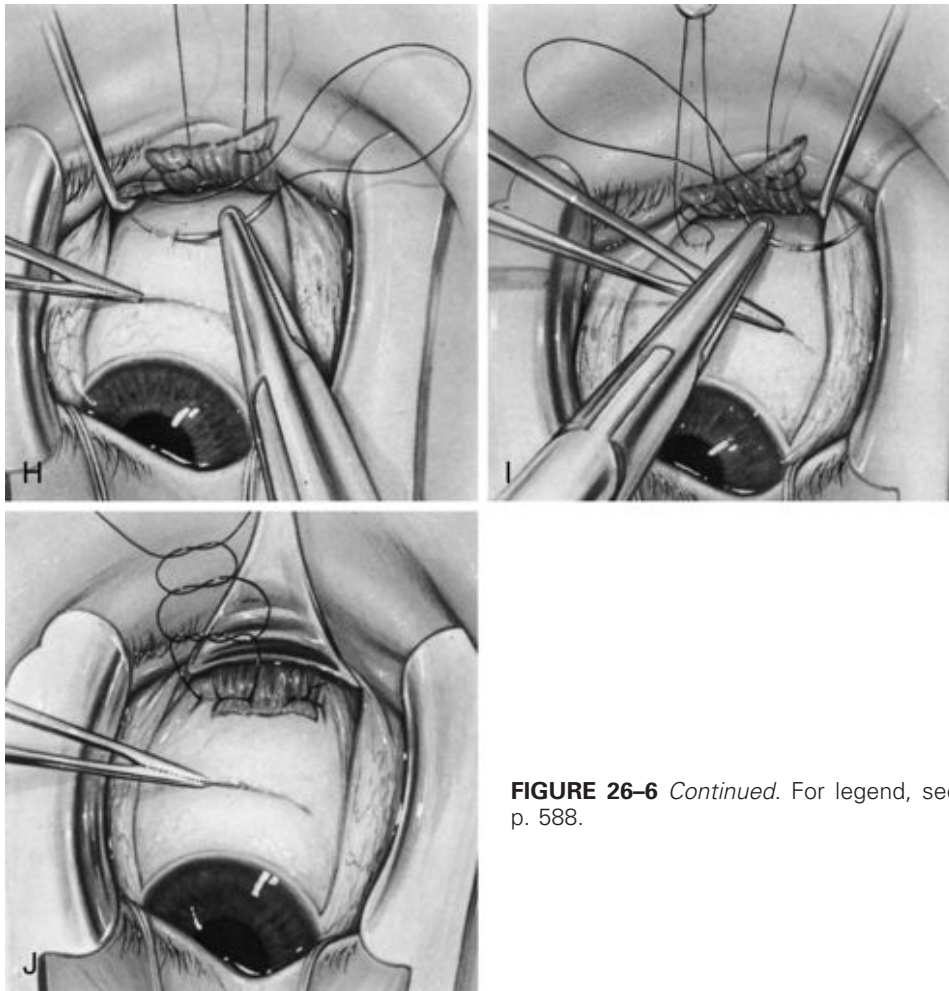


FIGURE 26-6 Continued. For legend, see p. 588.

edge of the muscle. As the needle emerges on the other side of the clamp, the assistant grasps it with an angled utility forceps (Fig. 26-7I). Each pair of sutures is placed in a serrefine, which is removed only when the suture is being used again, to prevent confusion between the four suture ends (Fig. 26-7J). The assistant then takes hold of the muscle clamp and pulls the muscle forward toward its old insertion while the surgeon ties each suture with a triple knot (Fig. 26-7K). The clamp is loosened slightly, then refastened to grasp the muscle at its end. The muscle is crushed with an angled hemostat (Fig. 26-7L). The muscle segment anterior to the sutures is then removed with scissors (Fig. 26-7M). The muscle is inspected (Fig. 26-7N) and any bleeding at this time is controlled with wet field cautery, after which the wound is closed at the limbus (Fig. 26-7O).

The *spring-back balance test* introduced by Jampolsky¹²⁵ may prevent overcorrections from excessive resection of a muscle and is used by us routinely during surgery. After completion of the resection and before closure of the conjunctiva the

globe is grasped at the limbus with two forceps in the same manner as during the forced duction test. The eye is rocked back and forth several times in the desired plane and then quickly released. The final position of the globe and the velocity of the spring-back are noted. If, for instance, the lateral rectus muscle has been resected too much, the eye will come to rest in a position of abduction. The surgeon is then well advised to recess the previously resected muscle to avoid an overcorrection that will certainly occur if the test result is ignored.

If additional strengthening is desirable, the muscle may be advanced 1 or 2 mm toward the limbus, in which case the muscle should be severed from the sclera as closely as possible to avoid adhesion between the old insertion and the underside of the muscle belly. The benefits derived from an advancement procedure are based on lengthening the arc of contact between the muscle and globe, thus increasing the rotational force of the contracting muscle. This effect will be neutralized if the muscle becomes reattached to its old insertion.

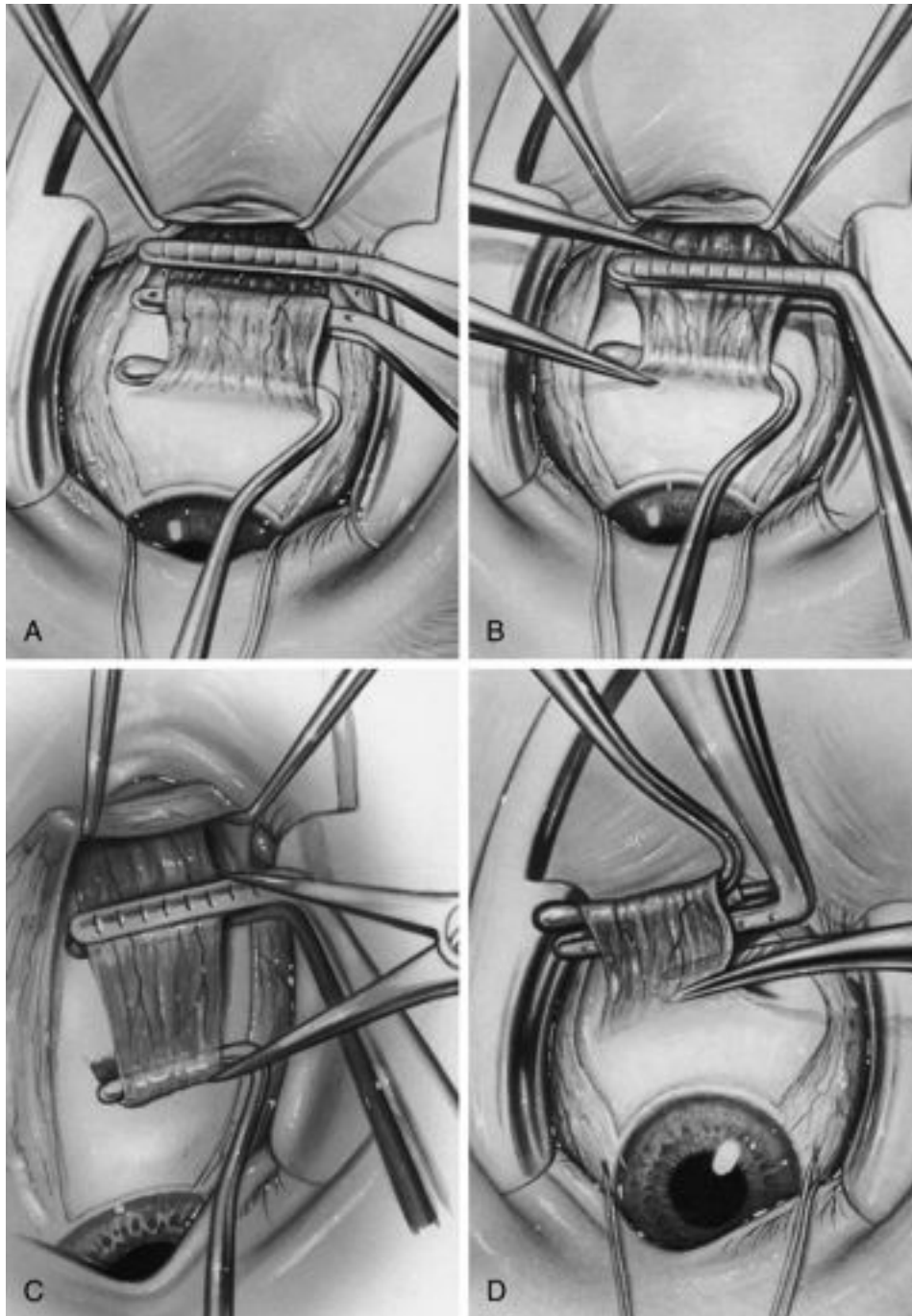


FIGURE 26-7. Resection of the right lateral rectus muscle. For explanation, see text. (Modified from von Noorden GK: Extraocular muscles. In Beyer-Machule CK, von Noorden GK, eds: Lids, Orbits, Extraocular Muscles, Vol 1. In Heilmann K, Paton D, eds: Atlas of Ophthalmic Surgery. New York, Thieme-Stratton, 1985.)

Illustration continued on following page

Adjustable Sutures

Interest has been revived in reattaching a recessed or resected muscle to the sclera in such a manner that the effect of surgery can be augmented or decreased during the postoperative period by pulling on or loosening the sutures, which are then retied under topical anesthesia. This technique was

described as early as 1885 in the United States²²⁸ and at one time was in vogue in Europe.¹⁰¹ It has been modified and again made popular in our time by Jampolsky.¹²⁷ This approach is based on the assumption that the position of the eye at the end of surgery, hours after surgery or on the first postoperative day, when such adjustments can be made, reflects its position after the postoperative

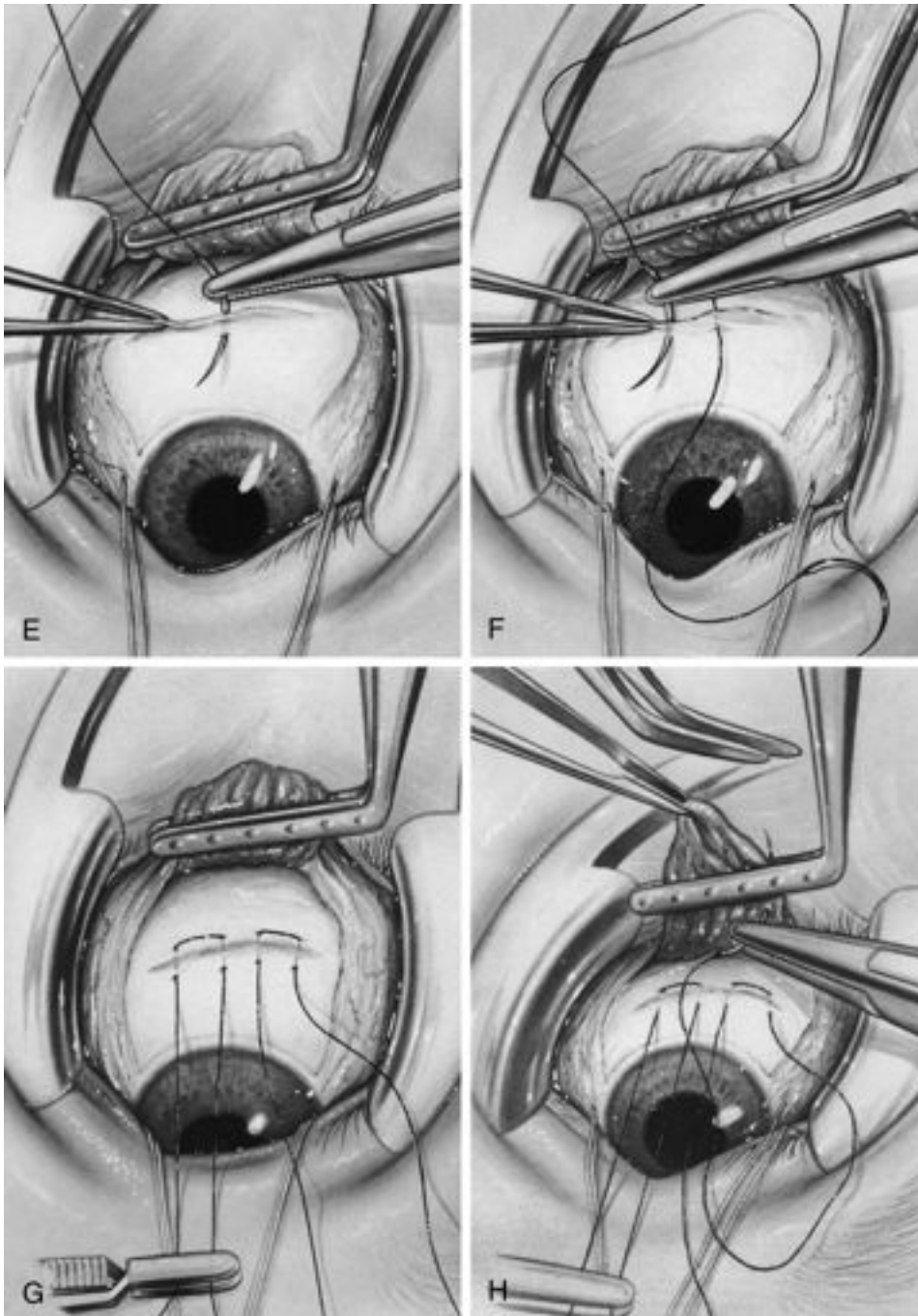


FIGURE 26-7 Continued. For legend, see p. 591.

tissue reaction, photophobia, and ocular discomfort have subsided. This assumption remains unproven. Except for large undercorrections and overcorrections, which tend to persist throughout the postoperative phase, we have not found the immediate postoperative position of the globe to be of much help in assessing the final result of surgery. In fact, in one study the operative result 6 weeks after surgery differed from that 24 hours after surgery in 28 (40%) of 70 patients.²⁰⁷ In another study, major and significant changes in

ocular alignment occurred between the first day and 6 weeks after surgery.³⁴ Although the direction and magnitude of such changes were unpredictable, most patients showed recurrences in the direction of the preoperative deviation.³⁴

Postoperative suture adjustments in children are often difficult, and sedation or even general anesthesia may be required. For these reasons, we do not use adjustable sutures in children. However, we have found them to be of value in patients in whom multiple previous operations or restrictive

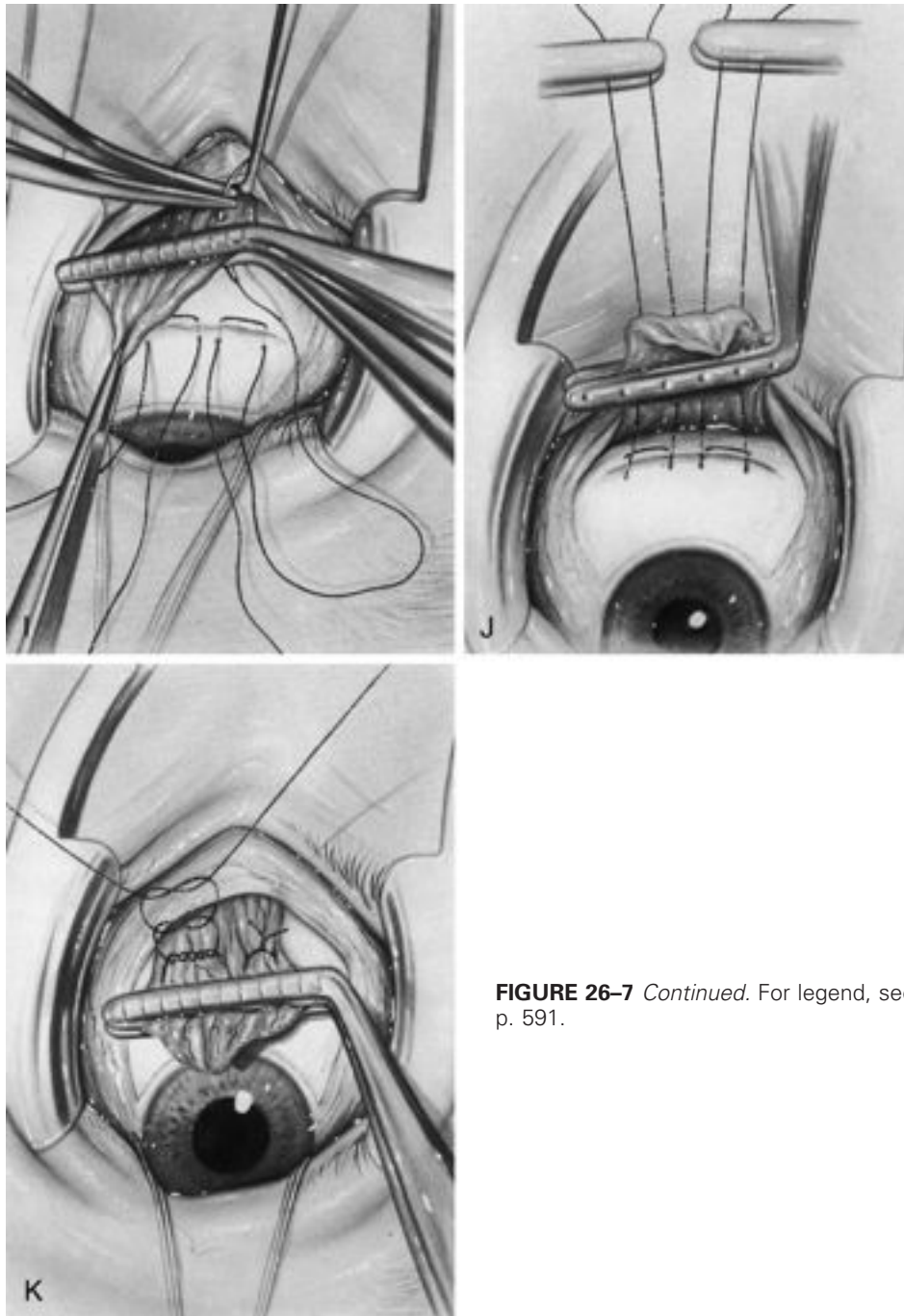


FIGURE 26-7 *Continued.* For legend, see p. 591.

forms of strabismus (scarring, contracture) have added a substantial factor of unpredictability to the outcome of the operation. Another indication for their use exists in paralytic strabismus with a good potential for restoration of single binocular vision. Wisnicki and coworkers²⁹⁹ reported that the use of adjustable sutures reduced the frequency of reoperations in their patients.

The adjustable suture technique in recession of the right medial rectus muscle is shown as an example. A double-armed 6-0 coated Vicryl suture is passed and tied through the center of the tendon

and then passed and locked through its upper and lower edges (Fig. 26-8A-C). The muscle has been severed from the sclera, and the sutures have been inserted through the scleral muscle stump (Fig. 26-8D). The muscle has been allowed to recede a desired amount. Moving the sutures back and forth several times (*arrows*) widens the scleral tunnel created by the sutures and facilitates suture adjustment the following day.

The sutures are tied, first with a single knot, then with a bowknot (Fig. 26-8E). The conjunctiva has been closed with two interrupted 7-0

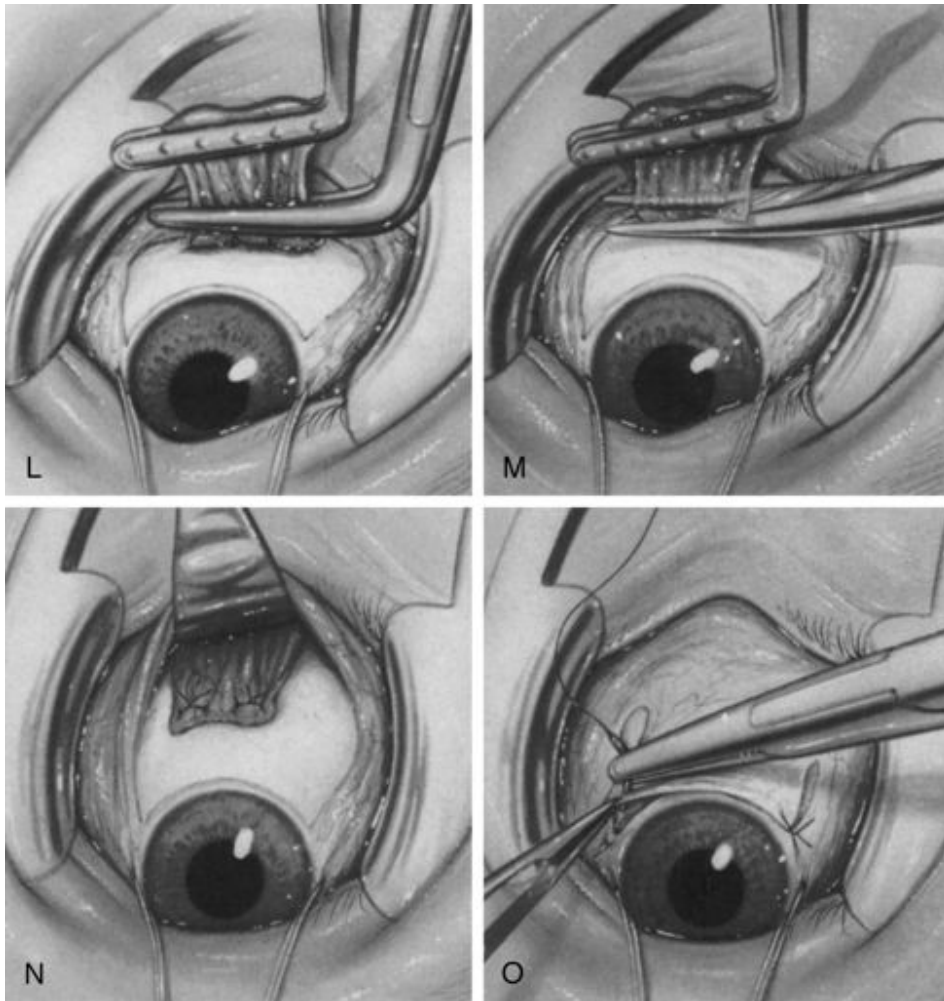


FIGURE 26-7 *Continued.* For legend, see p. 591.

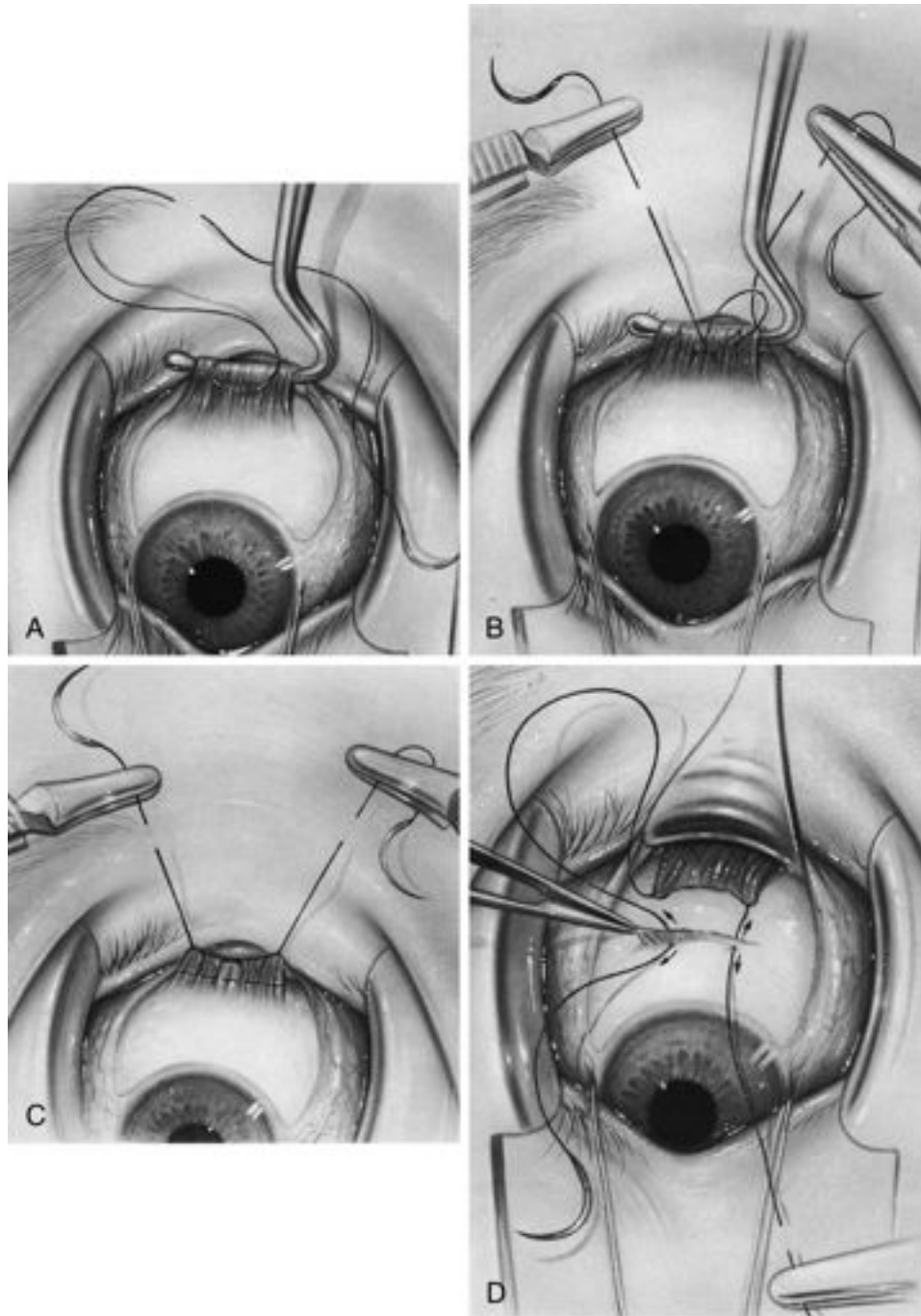


FIGURE 26-8. Adjustable suture. For explanation, see text. (Modified from von Noorden GK: Extraocular muscles. In Beyer-Machule CK, von Noorden GK, eds: *Lids, Orbits, Extraocular Muscles*, Vol 1. In Heilmann K, Paton D, eds: *Atlas of Ophthalmic Surgery*. New York, Thieme-Stratton, 1985.)

Vicryl stitches (Fig. 26-8F), using a bare scleral closure technique. The end of the suture that will open the bowknot is left long for later identification. A traction suture (5-0 Mersilene) may be inserted through the superficial sclera between the limbus and the old tendon insertion to facilitate exposure by rotating the globe during suture adjustment (not shown).

If the eye is in a satisfactory position postoperatively and no adjustment is necessary, the suture

bow must be opened and a third knot added to secure the knot. The bowknot is removed (not shown in this figure) by cutting the loop and pulling out the now disconnected suture fragment that has been previously identified by leaving its end long. The remaining double knot is tightened and a third double knot is added before the remaining two sutures are cut. The conjunctiva is left in its recessed position.

For suture adjustment on the first postoperative

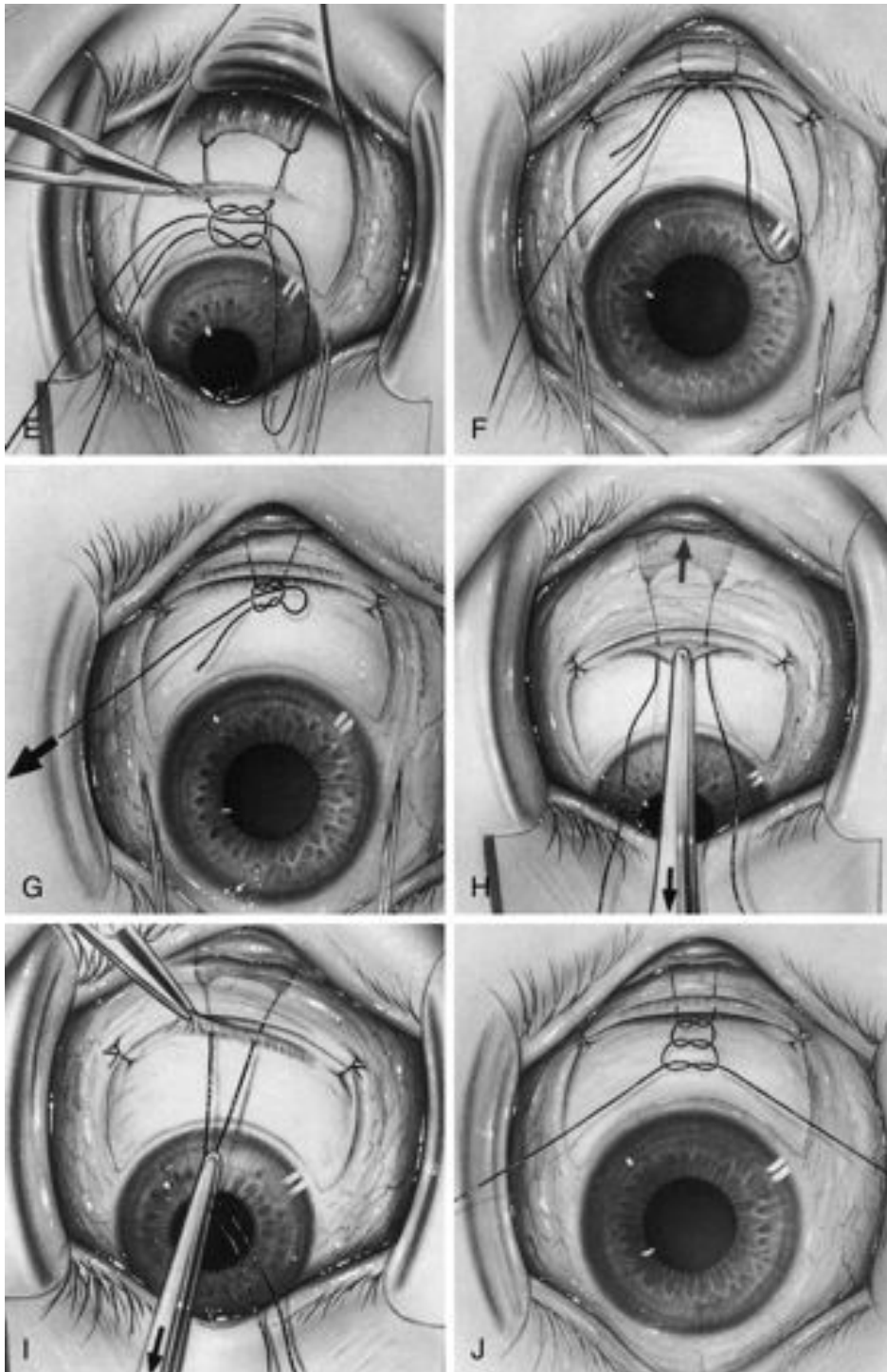


FIGURE 26-8 *Continued.* For legend, see p. 595.
Illustration continued on following page

day, the knot is opened by pulling on the long end of the suture after the conjunctiva has been locally anesthetized (Fig. 26-8G). To allow the muscle to slide posteriorly, the globe is fixed with forceps (or traction suture) while the patient looks in the direction of the field of action of the recessed muscle (Fig. 26-8H). To move the muscle toward the original insertion, it is pulled forward by

means of the sutures while the patient is asked to look in the direction of the pull (Fig. 26-8I). After adjustment is completed, the sutures are permanently tied with a triple surgical knot (Fig. 26-8J) and in a few days the knot will be covered by conjunctiva (Fig. 26-8K).

When there is no conjunctival scarring or contracture of conjunctiva or Tenon's capsule, this

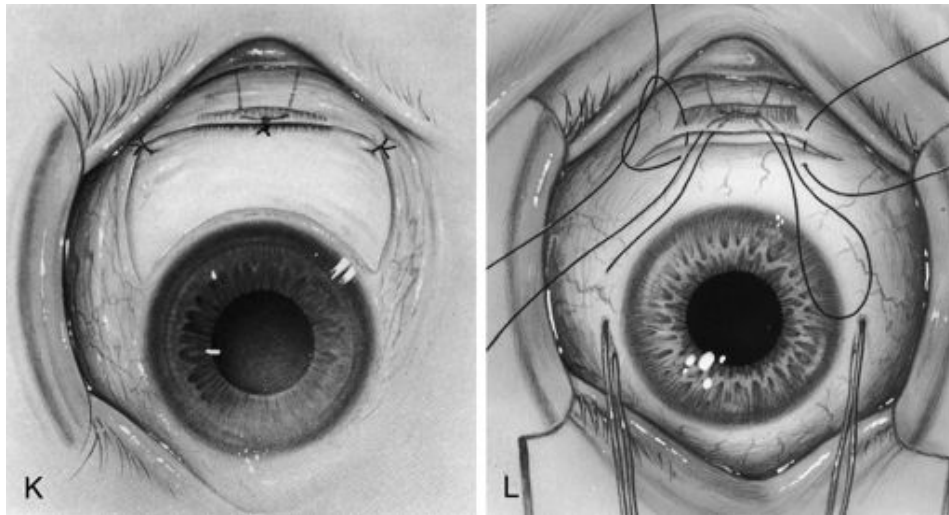


FIGURE 26-8 Continued. For legend, see p. 595.

technique may be modified by making the initial incision directly anterior to the muscle insertion. The wound is then closed with two interrupted stitches (6-0 Vicryl [polyglactin 910]), leaving a central gap through which the suture can be adjusted and tied (Fig. 26-8L). The postoperative cosmetic appearance, especially when operating on the horizontal recti, is better than after bare scleral closure. When the adjustment is made, advancing a muscle is easier to accomplish than additional recession since a muscle rapidly adheres to its new insertion. It is easier to break the muscle from the sclera by actively pulling it forward than by allowing it to slide back. When using adjustable sutures for resections, therefore, it is recommended that 3 mm be added to the desired amount of resection and that the muscle be recessed 3 mm at the same time so that both a surgical undereffect and overeffect can be corrected.

Pulling on the muscle usually is accompanied by a dull ache despite topical anesthesia, and the patient should be advised of this beforehand.

Not all adults are good candidates for suture adjustment. We have found that anxious patients or those who cooperate poorly during tonometry or the forced duction test in the office may be uncooperative during suture adjustment and even require sedation, which defeats the very purpose of this procedure. Patients in whom *bradycardia* or other cardiac dysrhythmias develop on traction of any extraocular muscle during surgery should be excluded from this type of procedure since similar problems may occur during suture adjustment.^{118, 293}

No convincing data are available to show that strabismus surgery using adjustable sutures is superior to conventional methods. However, there is no question that the possibility of correcting or at least decreasing a large overcorrection or undercorrection on the first postoperative day is reassuring both to the surgeon and the patient.

Marginal Myotomy of a Rectus Muscle

Of the many techniques used to lengthen a muscle, the marginal myotomy of von Blaskovics and Kreiker¹⁷ has emerged as the most effective. The reason for the less beneficial results of the other methods, such as the tenotomy after O'Connor²⁰⁰ or Verhoeff,²⁸⁹ is that unless the central fiber bundles of the muscle are sectioned, only insignificant amounts of lengthening of the insertion are obtained.^{107, 140} Hemostasis is obtained by briefly crushing the tissue to be cut with a mosquito hemostat (Fig. 26-9A), after which the myotomy is performed, with at least 70% of the width of the muscle being sectioned from above and below (Fig. 26-9B). If available, we prefer to do the myectomy by using battery-driven thermocautery (not shown), which prevents hemorrhage from the muscle section. After completion of the myectomies, the muscle has been lengthened (Fig. 26-9C). It is important to first make an incision distal to the insertion, followed by a second incision through the muscle or tendon proximal to the insertion. Distortion of the muscle or tendon occurs when the proximal incision is first made, which causes difficulties in gauging the length

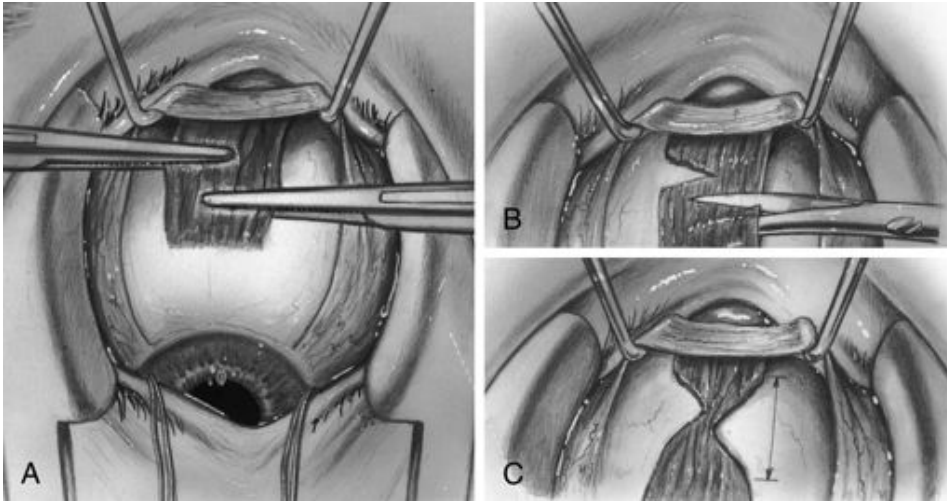


FIGURE 26-9. Marginal myotomy of the right medial rectus muscle. For explanation, see text.

of the second incision. Reoperations following marginal myotomies are difficult and should be avoided if at all possible.

Myectomy of the Inferior Oblique Muscle

We shall discuss only the technique of myectomy in the lower temporal quadrant, a procedure that in our hands has given the best results. The operation is illustrated using the right inferior oblique muscle as an example. Positions of the surgeon and assistant are shown in Figure 26-10.

The eye is elevated in adduction with a traction suture passed through conjunctiva and episclera near the limbus in the inferotemporal quadrant (Fig. 26-11A). A two-step incision is then made, first through the conjunctiva and then through Tenon's capsule close to the fornix but on the bulbar side of the conjunctiva to stay clear of the more heavily vascularized tissue in the fornix (Fig. 26-11B). Bleeding from conjunctival capillaries, which obscures the operative field and thus interferes with direct visualization of the inferior oblique muscle, can be avoided by opening conjunctiva and Tenon's capsule with battery-driven thermocautery (not shown).

The scissors blades are placed in the incision and spread, exposing the sclera (Fig. 26-11C). Care must be taken to avoid injuring the inferotemporal vortex vein, usually located in this region, with the tip of the hook. The wound edges are then retracted with a Desmarres lid speculum to expose the muscle. The muscle can be seen as a salmon-pink, flat structure lying in a pocket of Tenon's capsule (Fig. 26-11D). Great emphasis

is placed on adequate exposure, because many surgeons make the mistake of searching blindly for the muscle with a sharp instrument and thereby run the risk of causing considerable tissue damage or injury to the muscle.

After being exposed, the muscle is engaged under direct visualization on a short Graefe hook (Fig. 26-11E). Closed scissors blades are then placed under the muscle, and Tenon's capsule is perforated by spreading the scissors blades (Fig. 26-11F). Muscle hooks are placed under the muscle, which is then stretched (Fig. 26-11G). The muscle is clamped with two hemostats approximately 8 mm apart (Fig. 26-11H) and the myectomy is performed by excising the muscle segment between the clamps. One should not cut the mus-

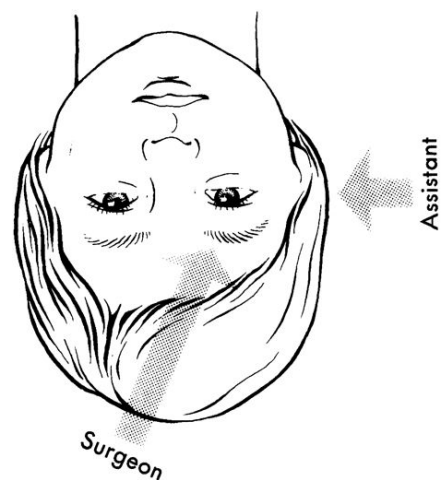


FIGURE 26-10. Position of surgeon and assistant for myectomy of the right inferior oblique muscle. (From von Noorden GK: Extraocular muscles. In Beyer-Machule CK, von Noorden GK, eds: Lids, Orbits, Extraocular Muscles, Vol 1. In Heilmann K, Paton D, eds: Atlas of Ophthalmic Surgery. New York, Thieme-Stratton, 1985.)

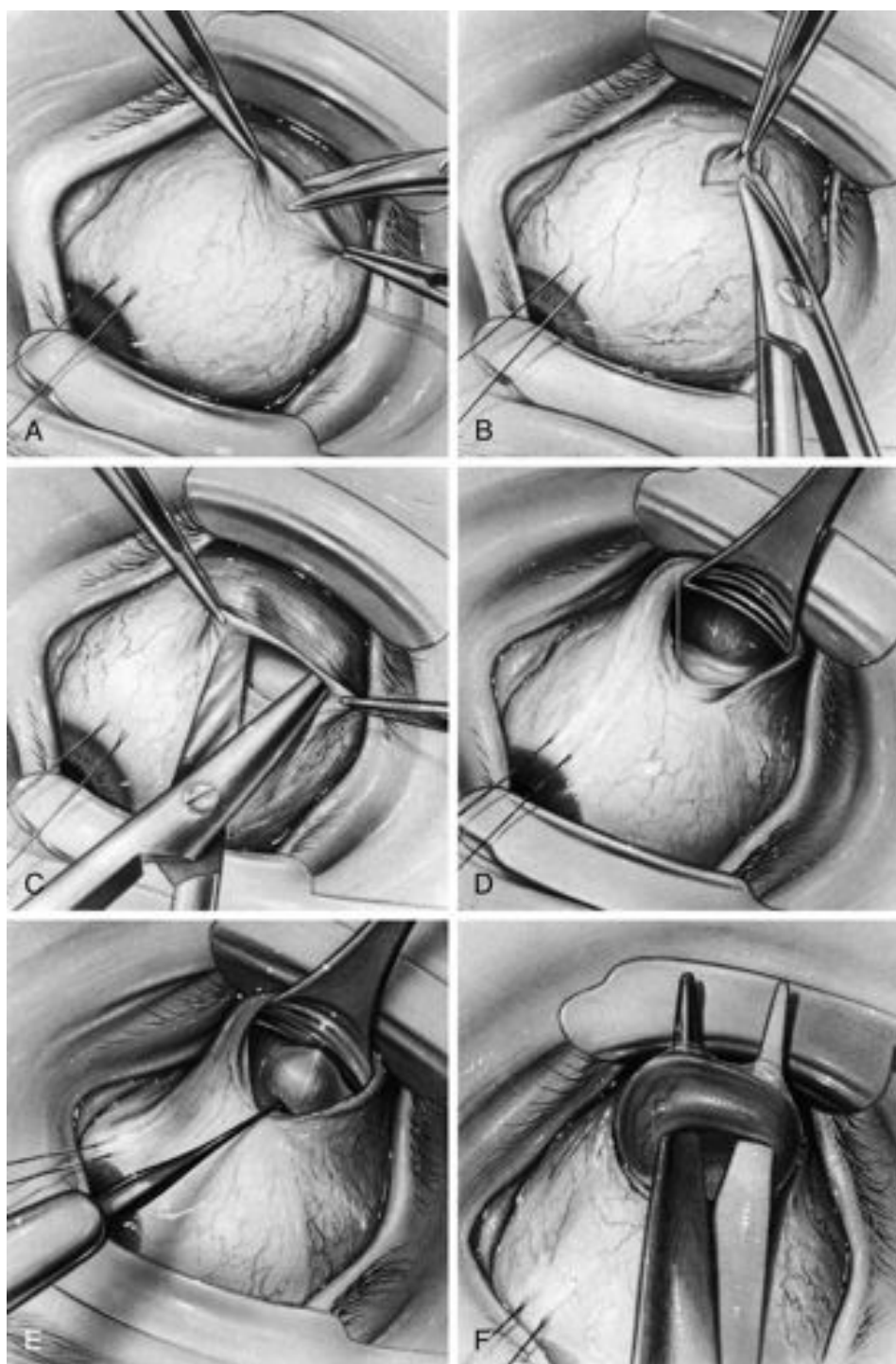


FIGURE 26-11. Myectomy of the right inferior oblique muscle. For explanation, see text. (From von Noorden GK: Extraocular muscles. In Beyer-Machule CK, von Noorden GK, eds: *Lids, Orbits, Extraocular Muscles*, Vol 1. In Heilmann K, Paton D, eds: *Atlas of Ophthalmic Surgery*. New York, Thieme-Stratton, 1985.)

cle flush with the clamp but should leave a stump for subsequent thorough cauterization (Fig. 26-11) to prevent postoperative hemorrhage or reattachment of the muscle segment(s) to the sclera or Tenon's capsule.

The effect of a myectomy can be severely lim-

ited if the surgeon leaves even a few strands of intact muscle. It is absolutely essential at this point to ensure that all the muscle fibers have been cut, and the sectioned muscle should be examined to determine whether the muscle sheath is intact posteriorly. The posterior aspect of the muscle may

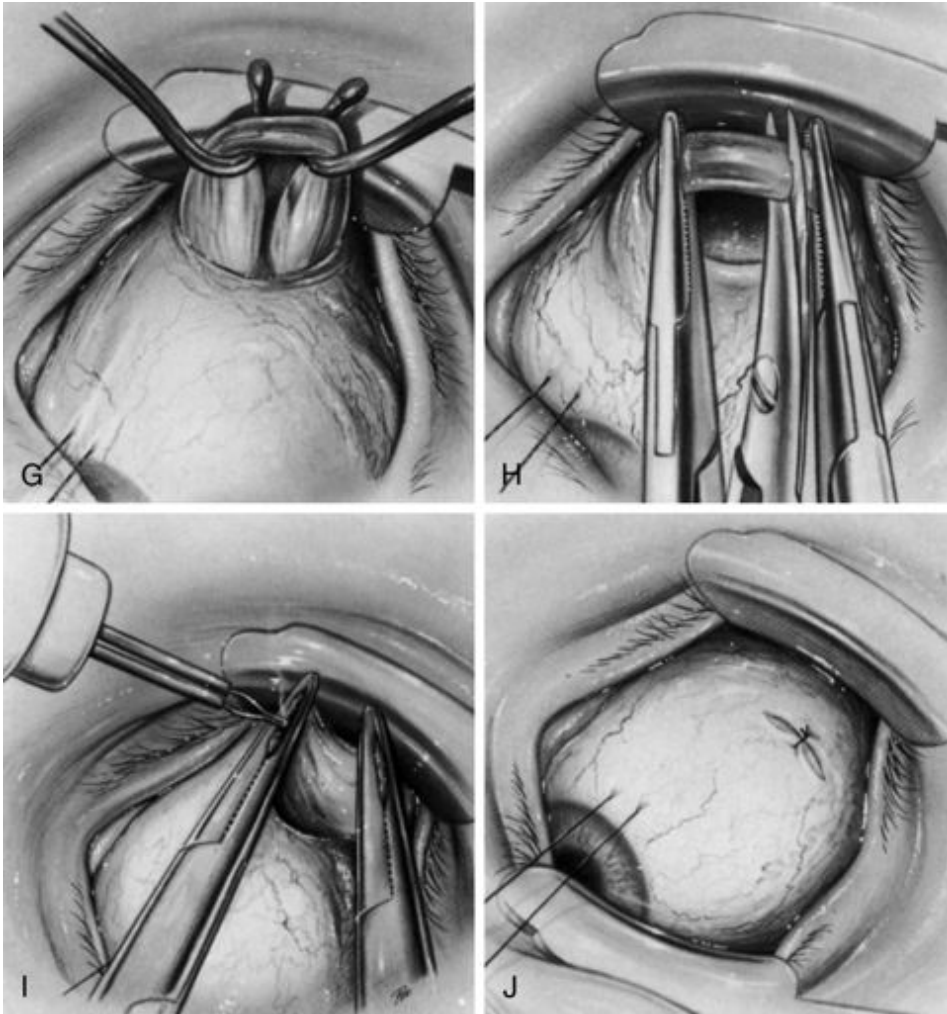


FIGURE 26-11 Continued. For legend, see p. 599.

have slipped off the Graefe hook during its exposure, and the surgeon must search for any missed muscle fibers that must be cut or for an anomalous posterior insertion of the muscle, which is not uncommon.²⁶ Cadaver studies have shown that multiple insertions occurred in 17% and a bifid insertion in 8% of 100 eyes examined.⁵¹

The conjunctiva may be closed with one or two interrupted 7-0 Vicryl sutures (Fig. 26-11J), or closure may be omitted, because sufficient coaptation of the wound edges occurs without suture the moment the eye is released from the traction suture. The eye is now grasped with forceps close to the limbus and rotated several times to spread the muscle stumps as far from each other as possible (not shown).

Inadvertent sectioning of the inferior rectus muscle rather than the inferior oblique muscle is a rare complication that can be avoided by fixation of the globe in an adducted and elevated position

and by exposing the muscle under direct visualization. Also, the flat inferior rectus muscle differs considerably in appearance from the more oval inferior oblique muscle, the fibers of which run perpendicular to those of the inferior rectus muscle. Before proceeding with the myectomy of the inferior oblique muscle, the less experienced surgeon is advised to identify the inferior rectus muscle by placing a muscle hook under its insertion.

Recession of the Inferior Oblique Muscle

For a recession of the right inferior oblique muscle the surgeon and assistant are positioned as shown in Figure 26-10. The eye is elevated and maintained in adduction by means of a traction suture passed through conjunctiva and superficial scleral lamellae near the limbus in the inferotemporal quadrant (Fig. 26-12A) The conjunctiva is opened

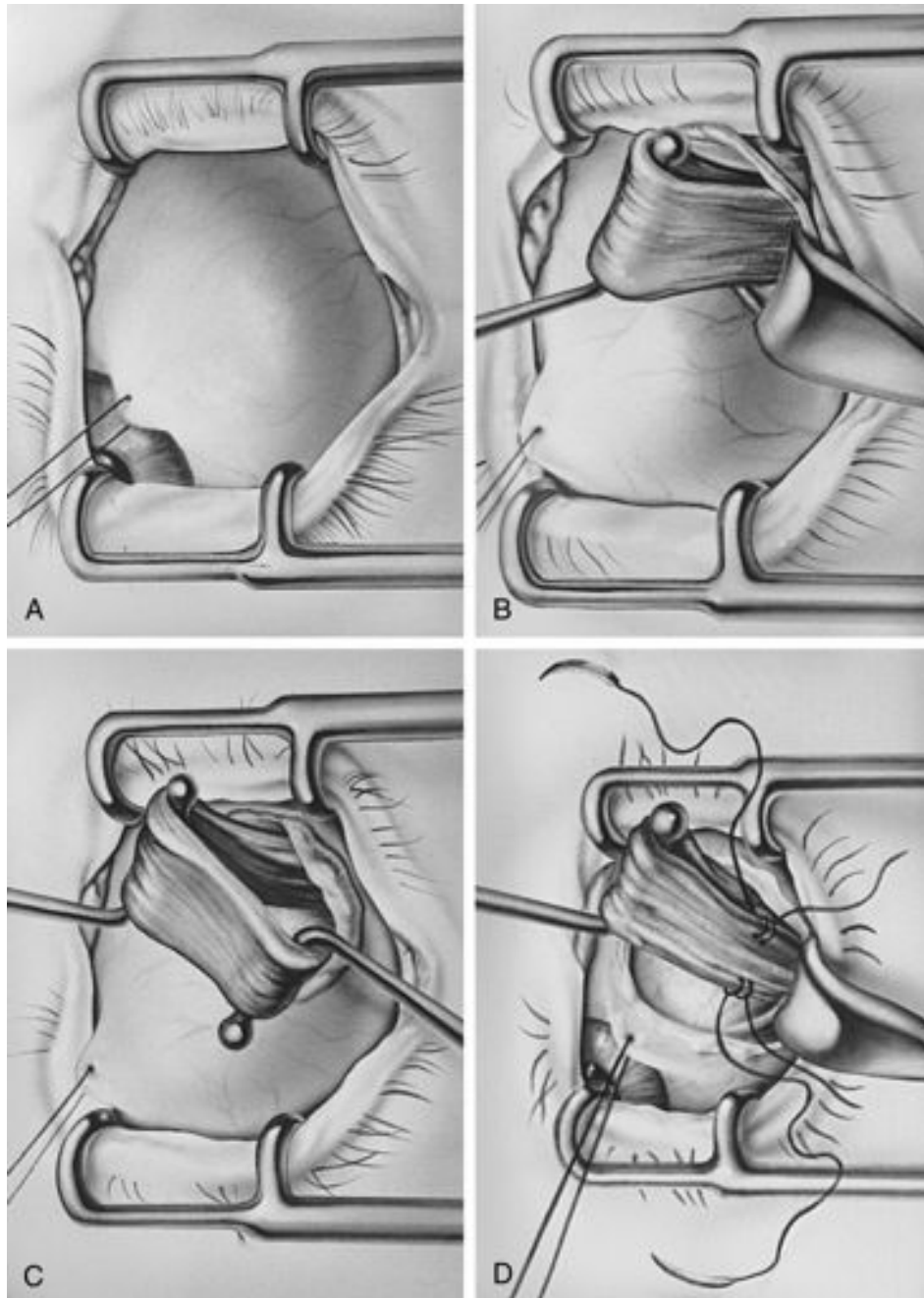


FIGURE 26-12. Recession of the right inferior oblique muscle. For explanation, see text.

as for a myectomy in the inferior temporal quadrant so as to expose the inferior oblique muscle, which is engaged with a hook under direct visualization (Fig. 26-12B). Care is taken to check with two muscle hooks that all the fibers, particularly the posterior ones, are engaged and that a triangle of bare sclera is visible between the hooks (Fig. 26-12C). As mentioned earlier, anomalies of the insertion of this muscle are not uncommon and must be searched for since recessing only part of a multiple insertion may account for a persistent muscle overaction. A double-armed suture of Vi-

cryl 6-0 is passed through the muscle as close as possible to its insertion and is locked and tied at the edges of the muscle (Fig. 26-12D). The amount of recession is measured from the position of the suture with a caliper (Fig. 26-12E) and an indentation is made into the sclera with the caliper to mark the point of reinsertion. The amount of recession ranges from 5 to 10 mm, depending on the degree of overaction. The muscle is detached from the sclera with scissors (Fig. 26-12F) and reinserted to the sclera at the predetermined site (Fig. 26-12G).

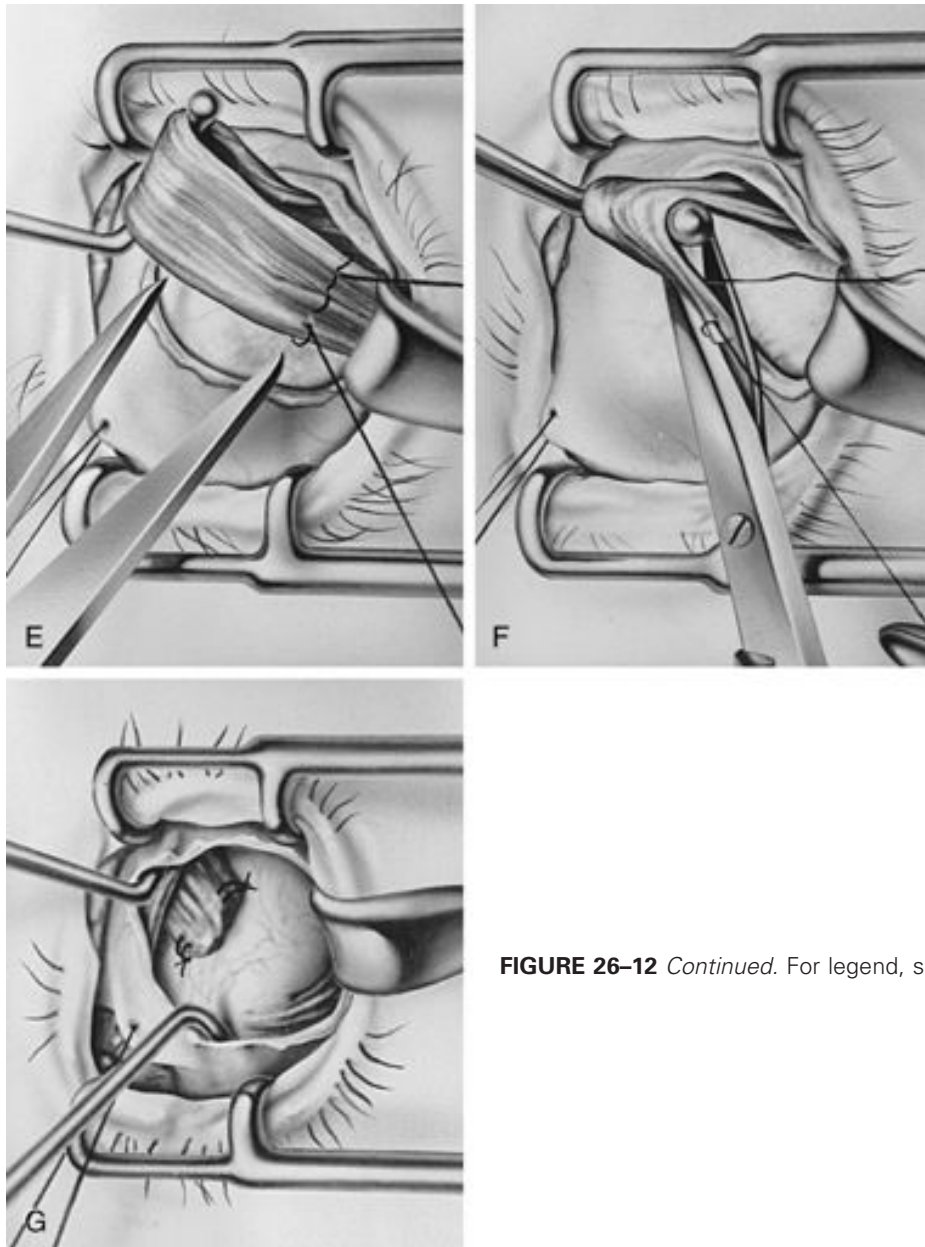


FIGURE 26-12 *Continued.* For legend, see p. 601.

Tenectomy of the Superior Oblique Muscle

Improved techniques for exposure and isolation of the superior oblique tendon under direct visualization, as advocated by Parks and Helveston,²¹⁹ have practically eliminated all complications previously incurred with tenectomy of the superior oblique muscle, such as injury to the medial horn of the levator muscle with subsequent ptosis, injury to the superior rectus muscle, or perforation of the orbital septum with prolapse of orbital fat. The operation is illustrated using tenectomy of the right superior oblique as an example and the positions of the surgeon and assistant are shown in

Figure 26-13. We prefer to perform this procedure while standing.

Figure 26-14A shows exposure of the superior oblique tendon. The incision is made through the conjunctiva and Tenon's capsule between the medial and superior rectus muscles, 4 to 5 mm behind the limbus. As during opening of the conjunctiva and Tenon's capsule for a myectomy of the inferior oblique, thermocautery may be used to gain access to the sclera (not shown). The wound is gently spread with the tips of blunt tenotomy scissors (Fig. 26-14B).

One muscle hook engages the superior rectus muscle, and the eye is turned downward and outward by applying traction on the muscle hook,

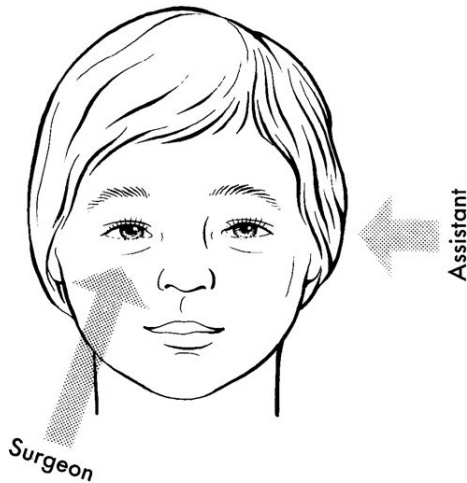


FIGURE 26-13. Position of surgeon and assistant for tenectomy of the right superior oblique muscle. (From von Noorden GK: Extraocular muscles. In Beyer-Machule CK, von Noorden GK, eds: *Lids, Orbits, Extraocular Muscles*, Vol 1. In Heilmann K, Paton D, eds: *Atlas of Ophthalmic Surgery*. New York, Thieme-Stratton, 1985.)

held by the assistant (Fig. 26-14C). The upper edge of the wound is retracted upward. Rather than using a forceps or a third muscle hook, as advocated by Parks and Helveston,²¹⁹ we use a small Desmarres lid retractor, which provides atraumatic exposure (Fig. 26-14D). The tendon of the superior oblique can be seen as a glistening white band lying in a pocket of Tenon's capsule. Visualization of the tendon is facilitated if the surgeon wears a headlight. A small Graefe hook is used to engage the tendon and pull it forward (Fig. 26-14E). Scissors blades are then spread to isolate the tendon (Fig. 26-14F and G).

The tissue surrounding the tendon is incised to identify the tendon proper, the glistening appearance of which reminds us of mother-of-pearl (Fig. 26-14H). This step of the operation is always recommended for the less experienced surgeon since strands of Tenon's capsule may be mistaken for the tendon. If an isolated tenotomy is to be performed, the tendon is pulled from the sheath at this point and cut (not shown). To remove a piece of tendon, including its sheath, the tendon is spread between two hemostats and clamped (Fig. 26-14I), after which a section is removed with scissors (Fig. 26-14J and K). The tendon has a gritty consistency that is different from other tissue and should be easily recognized by the surgeon when cutting through this structure. The wound is now closed with one stitch of 7-0 Vicryl (Fig. 26-14L), after which the muscle hook is removed.

Recession of the Superior Oblique Muscle

Recession of the superior oblique muscle is shown for the right eye. The positions of surgeon and assistant are depicted in Figure 26-13. The superior oblique tendon has been exposed in the upper temporal quadrant, as for a tuck. In Figure 26-15A the conjunctiva has been opened, close to the temporal border of the superior rectus, and bare sclera and the superior oblique tendon insertion are visible. A hook, inserted under the superior rectus muscle insertion and held by an assistant, has depressed the globe toward the 6-o'clock position. A small Desmarres retractor provides good exposure of the operating field above. Two single-armed sutures have been inserted and locked to the anterior and posterior part of the tendon insertion. After the tendon has been detached with scissors (Fig. 26-15B) the sclera is marked with a caliper, nasal to the superior rectus muscle and as equidistant from the limbus as the original insertion. The tendon is resutured to the sclera at the new insertion (Fig. 26-15C).

Tucking of the Superior Oblique Muscle

Tucking of the superior oblique muscle is illustrated using a tuck of the right superior oblique tendon as an example. The surgeon sits at the right side of the patient's head, the assistant at the opposite side (Fig. 26-16). The right eye has been rotated downward with two traction sutures inserted near the limbus through conjunctiva and episclera.

An incision is made through conjunctiva and Tenon's capsule with scissors (Fig. 26-17A) or thermocautery (not shown). Stevens tenotomy scissors have been introduced into the wound, and the blades are spread only slightly to avoid injury to the temporal border of the superior rectus muscle (Fig. 26-17B). A muscle hook has been placed under the superior rectus insertion (Fig. 26-17C). By applying traction to the hook the eye is rotated further downward. The posterior wound edge is pulled upward with a small Desmarres retractor. The temporal border of the superior rectus is lifted with a Graefe muscle hook No. 1 and the superior oblique tendon is exposed with a sweeping motion of a second Graefe hook No. 1 (Fig. 26-17D). A Burch tendon tucker or its von Noorden modification¹⁹² has been introduced beneath the superior

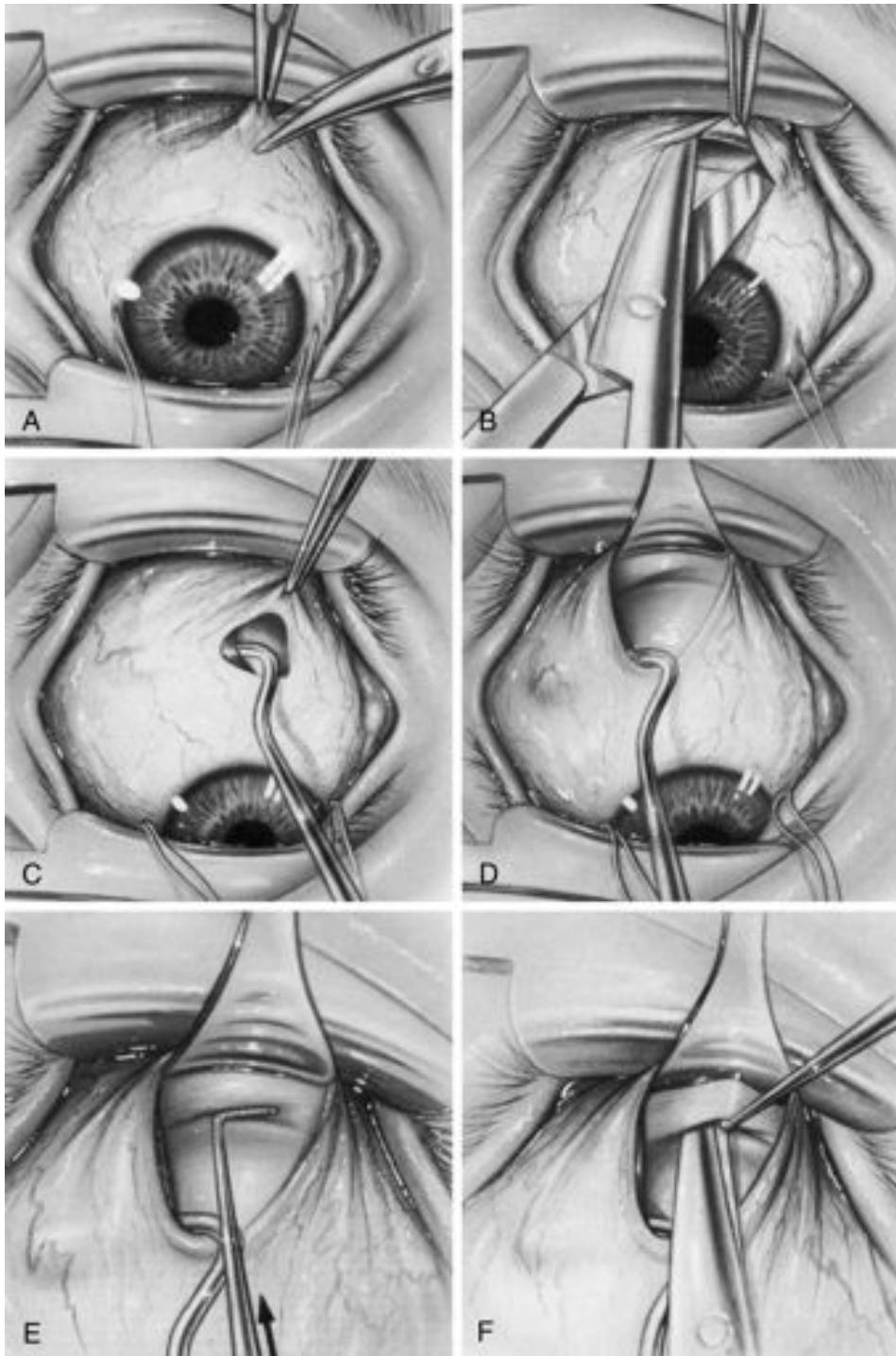


FIGURE 26-14. Tenectomy of the right superior oblique muscle. For explanation, see pp. 602 and 603. (From von Noorden GK: Extraocular muscles. In Beyer-Machule CK, von Noorden GK, eds: Lids, Orbits, Extraocular Muscles, Vol 1. In Heilmann K, Paton D, eds: Atlas of Ophthalmic Surgery. New York, Thieme-Stratton, 1985.)

Illustration continued on following page

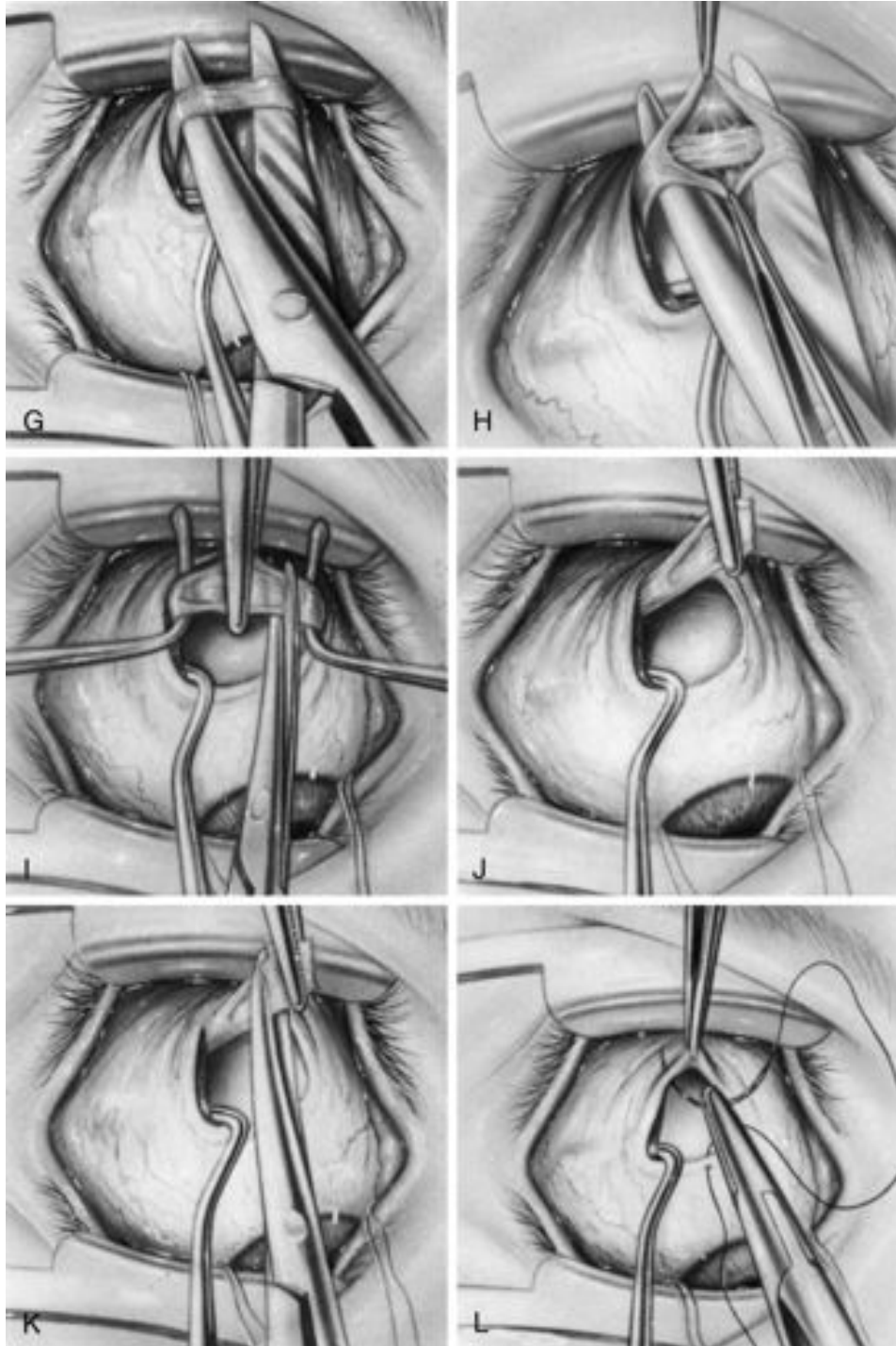


FIGURE 26-14. *Continued.* For legend, see p. 604.

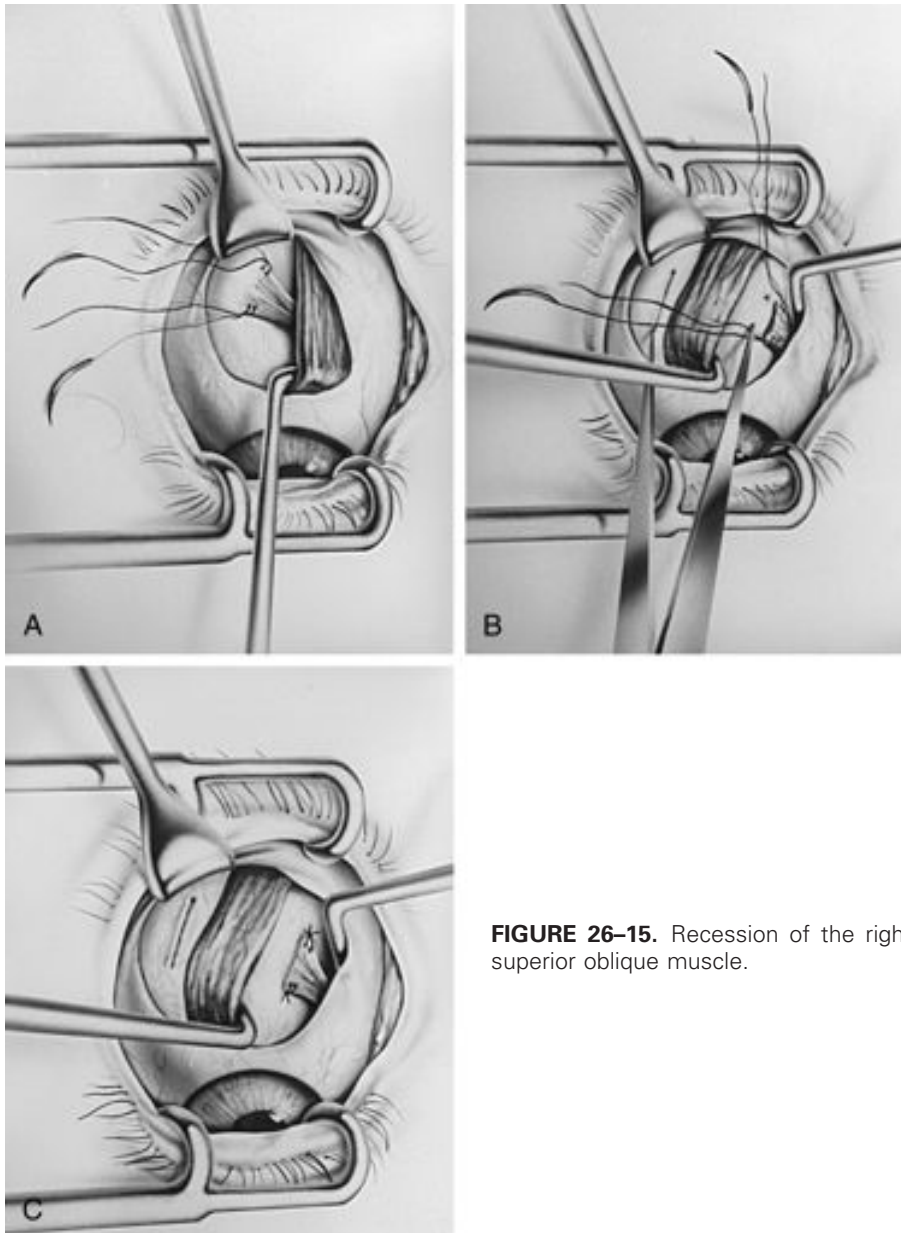


FIGURE 26-15. Recession of the right superior oblique muscle.

oblique tendon. The folded tendon is drawn into the tucker by turning the screw at the tip of the instrument (screw not shown) (Fig. 26-17E). After achieving the desired amount of tucking, which is determined by tightness or slacking of the tendon (usually between 6 and 12 mm), the cuff of the instrument (*large arrow*) is brought forward, thus closing the blades of the instrument (Fig. 26-17F). The tuck is fastened beneath the instrument with two 5-0 nonabsorbable sutures, after which the tucker is removed (Fig. 26-17G and H). We do not fasten the tucked portion of the tendon to the

sclera as this maneuver may inadvertently pull the tendon anteriorly and thus decrease the vertical effect of the operation and also contribute to post-operative limitation of elevation (pseudo-Brown syndrome). Forced ductions are now performed to determine the degree of restriction when elevating the adducted eye. Mild elastic restriction is desirable and should result in a good effect from the operation. Severe restriction necessitates undoing the tuck and tucking a lesser portion of the tendon. The wound is then closed with one interrupted stitch of 7-0 Vicryl.

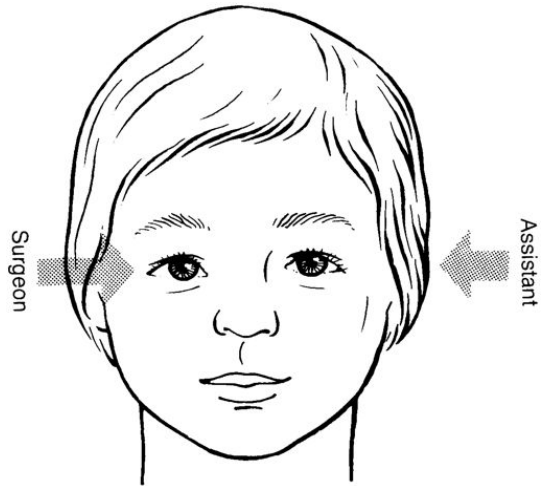


FIGURE 26-16. Position of surgeon and assistant for tucking of the right superior oblique tendon. (From von Noorden GK: Extraocular muscles. In Beyer-Machule CK, von Noorden GK, eds: Lids, Orbits, Extraocular Muscles, Vol 1. In Heilmann K, Paton D, eds: Atlas of Ophthalmic Surgery. New York, Thieme-Stratton, 1985.)

Anterior and Lateral Displacement of the Superior Oblique Tendon for Excyclotropia (Harada-Ito Procedure)

Jackson¹²¹ suggested recession and lateral displacement of the superior rectus tendon to counter-

act excyclotropia in patients with paresis of the superior oblique muscle. We have found the operation described by Harada and Ito¹⁰⁰ to be effective. This procedure involves anterior and lateral displacement of the anterior portion of the superior oblique, thereby increasing the incycloduction ef-

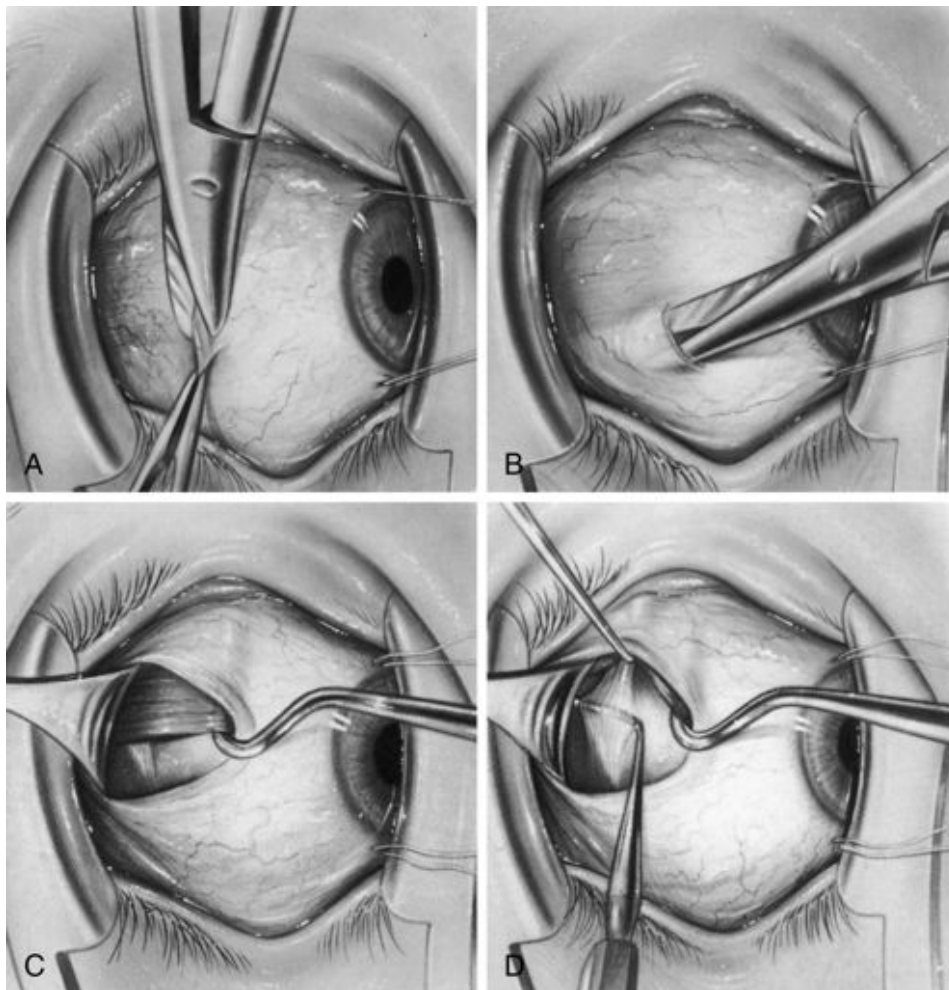


FIGURE 26-17. Tucking of the right superior oblique tendon. For explanation, see text, p. 603. (From von Noorden GK: Extraocular muscles. In Beyer-Machule CK, von Noorden GK, eds: Lids, Orbits, Extraocular Muscles, Vol 1. In Heilmann K, Paton D, eds: Atlas of Ophthalmic Surgery. New York, Thieme-Stratton, 1985.)

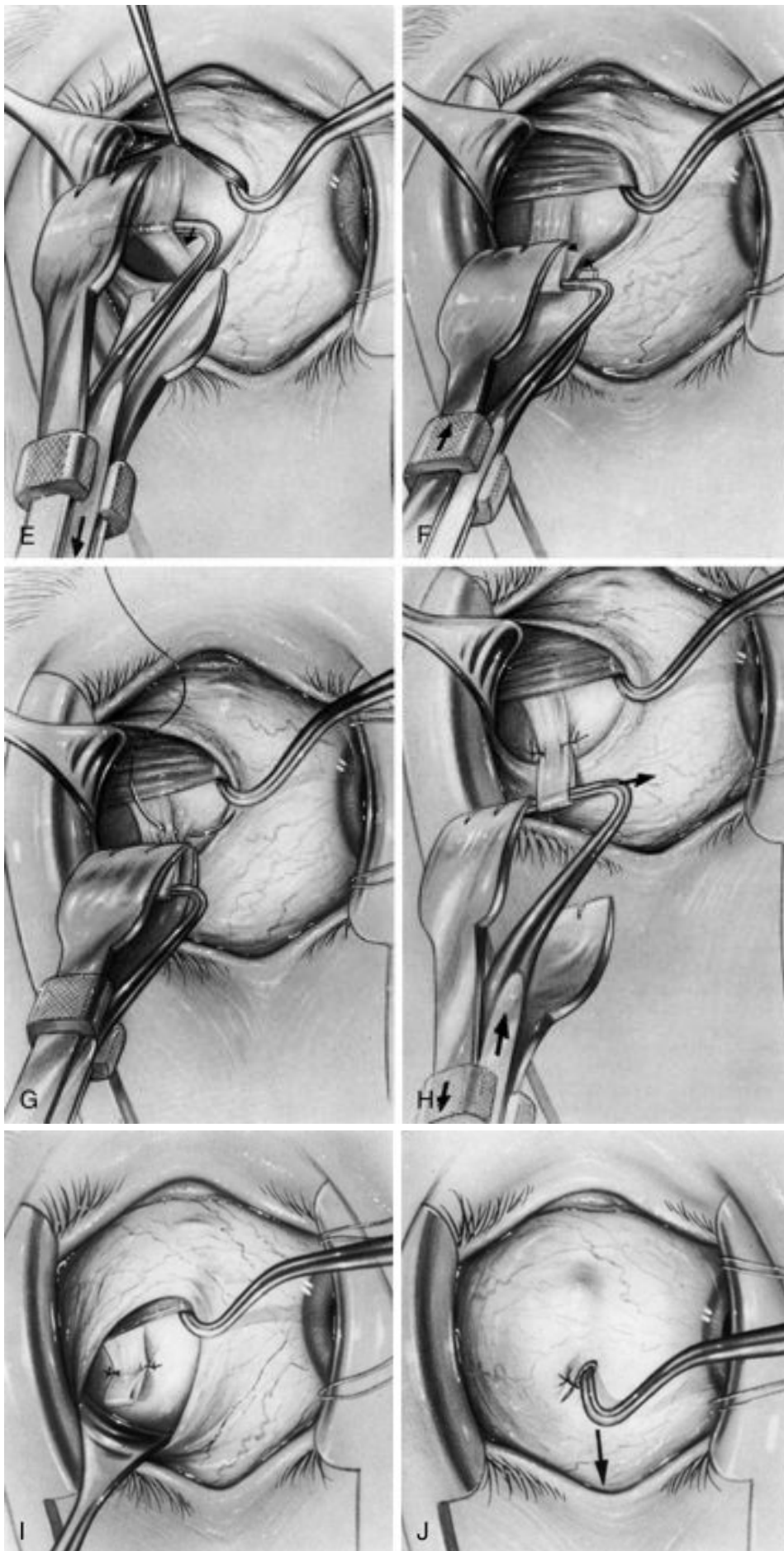


FIGURE 26-17 *Continued.* For legend, see p. 607.

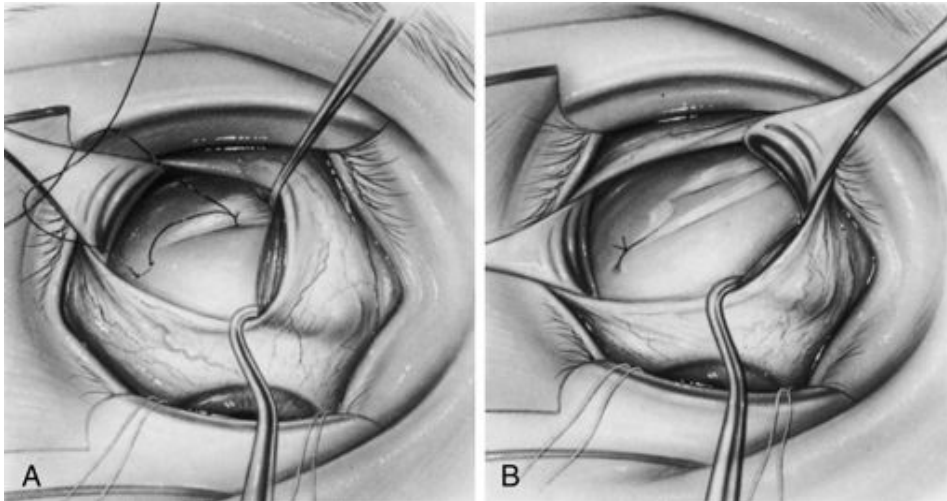


FIGURE 26-18. Harada-Ito operation (right superior oblique tendon). For explanation, see text. (From von Noorden GK: Extraocular muscles. In Beyer-Machule CK, von Noorden GK, eds: Lids, Orbits, Extraocular Muscles, Vol 1. In Heilmann K, Paton D, eds: Atlas of Ophthalmic Surgery. New York, Thieme-Stratton, 1985.)

fect between 9° and 15° in downward gaze.^{143, 191} The operation is illustrated using the right superior oblique tendon as an example.

The lateral aspect of the superior oblique tendon is exposed as for the tucking procedure. A nonabsorbable 5-0 single-armed suture is passed on a spatula needle through the anterior portion of the tendon, 3 mm nasal to its insertion (Fig. 26-18A). The suture is tied firmly with a triple knot. The needle is then passed through superficial scleral lamellae, 3 mm temporally and anterior to the insertion. By tying the suture over its scleral fixation, the anterior portion of the tendon is pulled laterally and anteriorly (Fig. 26-18B). The conjunctiva is closed with one or two interrupted 7-0 absorbable sutures, and the muscle hook is removed.

Fells⁷⁰ has modified this operation by splitting the tendon at its insertion and transposing the anterior half anteriorly and laterally, and Metz and Lerner¹⁶³ advocated the use of an adjustable suture for this procedure (see also Ohmi and coworkers²⁰⁴).

Using the procedure described by Harada and Ito we have noted that the effect of the operation tends to diminish in the course of time¹⁹¹. The same has been observed by other authors.^{11, 175, 286} Thus, if adjustable sutures are used at all, *a slight overcorrection on the first postoperative day should not be reversed by a suture adjustment*. Indeed, such initial overeffects are common and do not unfavorably influence the final outcome.¹⁹⁴ In reviewing our results with the Harada-Ito proce-

dures in nine patients we found that the reduction of the excyclotropia in primary position ranged from 8° to 25° , and in downward gaze, from 12° to 30° .¹⁹⁴

Posterior Fixation Suture

As an example of posterior fixation suture, posterior fixation of the right superior rectus muscle is used to explain the procedure. A limbal conjunctival incision is made to expose the muscle, and the two incisions perpendicular to the limbus are extended approximately 6 to 8 mm posteriorly. The superior rectus has been secured with two single-armed 6-0 Vicryl sutures (see Fig. 26-6A-D), severed from the globe (see Fig. 26-6E and F), and is held in a Jameson muscle clamp (Fig. 26-19A).

For maximal depression of the globe, two additional traction sutures may be inserted through the sclera at the site of the old insertion (Fig. 26-19B). A Schepens speculum or a similarly shaped retractor (malleable brain retractor, Charles microretinal retractor) is used to expose the sclera retroequatorially while marking the sites of the posterior fixation with calipers (Fig. 26-19C). A curved Scott ruler (not shown) should be used for marking posterior fixation sites exceeding 9 mm since the caliper, measuring the chord rather than the arc, becomes inaccurate beyond this distance.³⁸ For longer arc measurements the amount of inaccuracy depends on axial length. The Scott ruler can introduce significant measuring errors when measuring

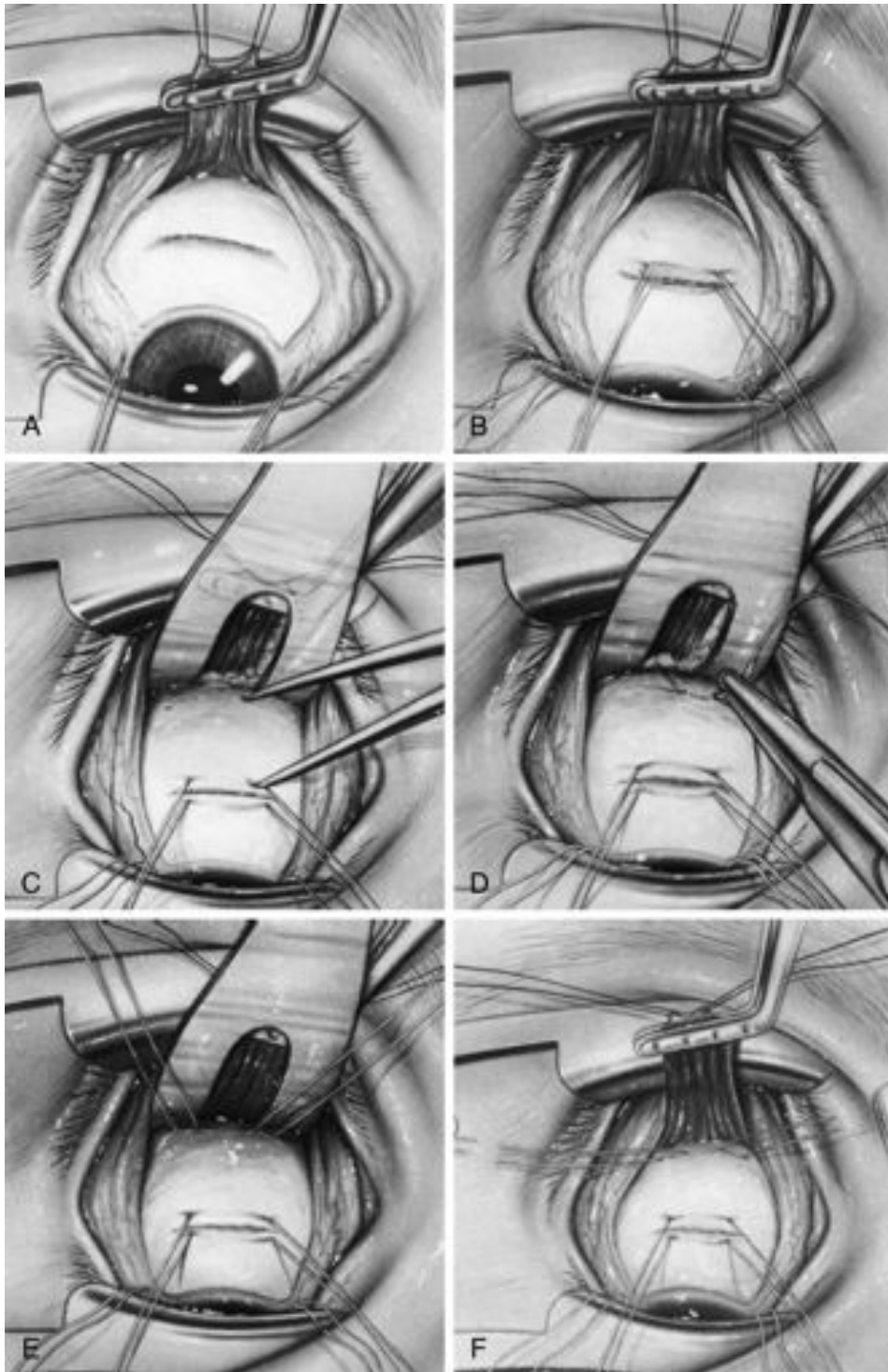


FIGURE 26-19. Posterior fixation of the right superior rectus muscle. For explanation, see text. (From von Noorden GK: Extraocular muscles. In Beyer-Machule CK, von Noorden GK, eds: Lids, Orbits, Extraocular Muscles, Vol 1. In Heilmann K, Paton D, eds: Atlas of Ophthalmic Surgery. New York, Thieme-Stratton, 1985.)

Illustration continued on following page

arc length as small as 12 mm in small eyes and 14 mm in large eyes.

The sutures (5-0 Dacron with a D-1 8-mm needle) are placed 14 mm posterior to the nasal and temporal edges of the superior rectus (Fig.

26-19D). The surgeon must avoid injury to the superior vortex veins (not shown) with the retractor. Both sutures are now in place (Fig. 26-19E) and the speculum has been removed (Fig. 26-19F). The muscle is brought downward (Fig. 26-

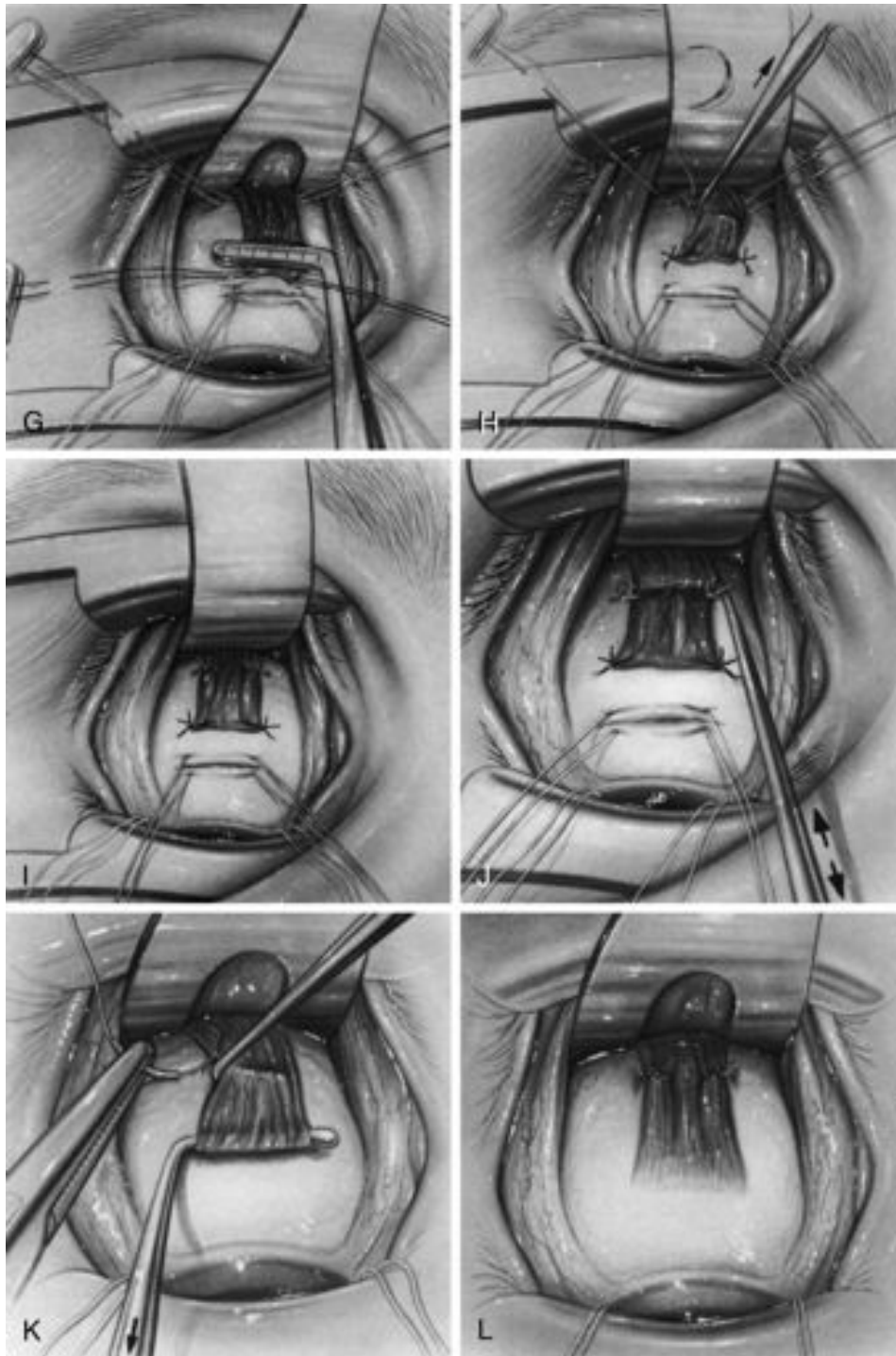


FIGURE 26-19 Continued

19F and G) and reattached to the sclera 4 mm behind its original insertion (Fig. 26-19H). The temporal suture is passed through the muscle from underneath, incorporating one third of the muscle, while the assistant lifts the edge of the muscle and pulls it laterally (arrow) with a Graefe hook No. 1 (Fig. 26-19H). Both sutures, fixating the lateral one third of the muscles, have been tied and cut

(Fig. 26-19I). Firm fixation of the muscle is tested with a muscle hook (Fig. 26-19J), after which the wound is closed in the usual fashion (see Fig. 26-5N). When the incisions are gaping, two interrupted sutures are used on each side for closure. When there is no deviation in primary position, the operation is performed without recession as shown in Figure 26-19K and L.

TABLE 26-1. Recommended Distances of Posterior Fixation

Muscle	Distance Behind Insertion (mm)
Medial rectus	12-15
Lateral rectus	13-16
Superior rectus	11-16
Inferior rectus	11-12

From von Noorden GK: Posterior fixation suture in strabismus surgery. In Symposium on Strabismus: Transactions of the New Orleans Academy of Ophthalmology. St Louis, Mosby-Year Book, 1978.

The recommended minimal and maximal distances of posterior fixation are shown in Table 26-1.


Muscle Transposition Procedures

HORIZONTAL AND VERTICAL RECTUS MUSCLES IN THE TREATMENT OF A AND V PATTERNS. The indications and effects of raising and lowering the insertion of the horizontal rectus muscle or nasal or temporal transposition of the vertical rectus muscles are discussed in Chapter 19. Exposure and surgical technique do not differ from the performance of a recession or resection of the rectus muscles; however, the limbal incision should be extended toward the direction in which one plans to move the insertion to gain better exposure, and the muscle should be reinserted parallel to the limbus. The effect may be modified by shifting the insertion between one-half and one full muscle width.

VERTICAL RECTUS MUSCLES IN THE TREATMENT OF HORIZONTAL STRABISMUS. Tempo-

ral transposition of the vertical rectus muscles for esotropia and nasal transposition for exotropia were also recommended by Nawratzki and Benezra¹⁸¹ for horizontal deviations, when maximal surgery on the horizontal muscles fails to completely align the eyes or if the surgeon is reluctant, for some reason, to operate on the fellow eye. Provided there are no mechanical restrictions, we can confirm the effectiveness of this procedure. However, we recommend only partial transposition of the tendon if previous surgery has been performed on the horizontal recti. Great care must be taken to leave viable anterior ciliary vessels in the part of the muscle segment that remains attached to the globe to prevent anterior segment ischemia. In children a full tendon-width transposition may be performed regardless of whether the horizontal rectus muscles have been previously operated on.

VERTICAL RECTUS MUSCLES IN THE TREATMENT OF CYCLODEVIATIONS. Horizontal transposition of one or both vertical rectus muscles corrects cyclotropia (see p. 391) or may be used to induce a cyclodeviation to treat a compensatory head tilt to one shoulder in patients with a nystagmus null zone in a tertiary gaze position (see p. 524). Figure 26-20 shows the direction in which the vertical rectus muscles must be transposed to cause incycloduction or excycloduction of each eye. We perform a full tendon transposition and reattach the nasal and temporal border of each muscle in accordance with their preoperatively measured distance from the limbus. Figure 26-21 shows the direction of the transpositions to cause incycloduction of the right eye. This operation will correct (or induce) a cyclodeviation of 11° (range, 8° to 12°) when performed on both vertical rectus muscles.



RSR → nas. LSR → temp. RSR → temp. LSR → nas.
 RIR → temp. LIR → nas. RIR → nas. LIR → temp.

FIGURE 26-20. The cyclotorsional effect of horizontal transposition of the vertical rectus muscles. For explanation, see text. RSR, right superior rectus; LSR, left superior rectus; RIR, right inferior rectus; LIR, left inferior rectus; nas., nasalward; temp., templeward.

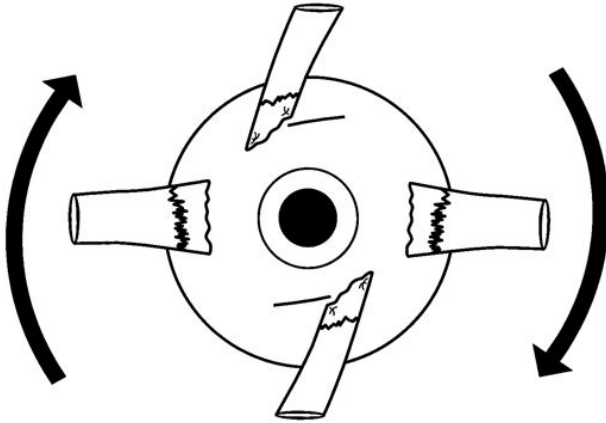


FIGURE 26–21. Position of reattached vertical rectus muscle tendons to produce incycloduction of the right eye.

HORIZONTAL RECTUS MUSCLES IN THE TREATMENT OF CYCLODEVIATIONS.

This procedure, introduced by de Decker,⁵³ may be used for the indications outlined in the preceding paragraph as an alternative to horizontal transposition of the vertical rectus muscles in adults who have had previous surgery on the horizontal rectus muscles.

HORIZONTAL RECTUS MUSCLES IN THE TREATMENT OF VERTICAL STRABISMUS.

Vertical transposition of the horizontal rectus muscles in the treatment of comitant vertical strabismus was introduced by Foster and Pemberton,⁷⁵ who lowered or raised the lateral rectus muscle to treat hypertropia or hypotropia. Alvaro³ advocated lowering or raising the insertions of both horizontal rectus muscles and combining this procedure with recession or resection to achieve simultaneous correction of vertical and horizontal deviations. This technique has found acceptance among many ophthalmic surgeons,^{136, 160, 200, 202, 214} and we found it effective in reducing the hyperdeviation from 8^Δ to 13^Δ when the muscles are transposed by one muscle width. To lower an eye, the insertions are lowered; to raise an eye, they are raised.

HORIZONTAL OR VERTICAL RECTUS MUSCLES IN PARALYTIC STRABISMUS.

Resection of a paralyzed muscle does little to improve its function unless the paralysis is incomplete. Some temporary mechanical advantage may be gained by combining resection of a completely paralyzed muscle with recession of its antagonist; however, rotation of the globe into the field of action of the paralyzed muscle cannot be restored and the eye tends to return to its preoperative position. However,

muscle transposition procedures may restore some degree of motility to the eye in the field of gaze of the paralyzed muscle.

Jackson¹²¹ and Hummelsheim¹¹⁵ are both credited with being the originators of muscle transposition for paralytic strabismus, and most techniques subsequently used^{111, 200, 130, 137} are derived from the procedure of Hummelsheim, in which the lateral part of the superior and inferior rectus muscles is transposed to the lateral rectus insertion for abducens paralysis. The numerous modifications of this procedure, all of which are based on the same principle, were reviewed by Helveston¹⁰⁴ and Metz.^{161, 162}

The question has been debated whether innervational adjustment takes place so that the transposed muscle can carry out coordinated movements in different directions from its original field of action^{19, 20} or whether the effect of muscle transpositions is merely mechanical.²⁸⁷ We favor the view that muscle transpositions have only a mechanical effect, which was substantiated by EMG studies of Metz and Scott.¹⁶⁴

Before considering a muscle transposition, the surgeon must determine that ocular motility is not impeded by mechanical factors by using the forced duction test (see p. 423). Such restrictions must be removed first, usually by maximal recession of the contracted antagonist of the paretic muscle and, if necessary, by conjunctival recession. *We state categorically that a muscle transposition should never be performed unless passive movement of the eye is unrestricted in the paretic field of gaze.*

Many of the muscle transposition procedures in use, especially those performed in combination with resection of the paretic muscle and recession of its antagonist, have the disadvantage that the integrity of the insertion of more than two rectus muscles is disturbed. Although many adult patients tolerate well such interference with the blood supply from the anterior ciliary arteries, we have seen in consultation several patients in whom ischemic anterior segment necrosis (see p. 620) occurred after surgery on three or four rectus muscles in one session. The severity of this complication is such that transposition of the entire tendon should be considered only if at least one rectus muscle insertion is intact and has not been previously operated on. Otherwise, partial transposition should be considered.

For *double elevator or double depressor paralysis*, we transpose the insertion of the horizontal

rectus muscle to that of the superior rectus or inferior rectus muscle, as suggested by Knapp.¹³⁷ The operation illustrating transpositions of the horizontal recti in a patient with double elevator paralysis of the right eye is shown in Figure 26–22. The horizontal recti have been exposed with a limbal incision between the 4- and 8-o'clock positions and secured with two single-armed su-

tures (6-0 Vicryl), after which the muscles are severed from the globe by sharp dissection (Fig. 26–22A). The lateral rectus is transposed to the temporal edge of the superior rectus muscle (Fig. 26–22B). Both horizontal recti are shown in their final position (Fig. 26–22C), after which the conjunctiva is closed near the limbus with two stitches at the 4- and 8-o'clock positions (not shown). The

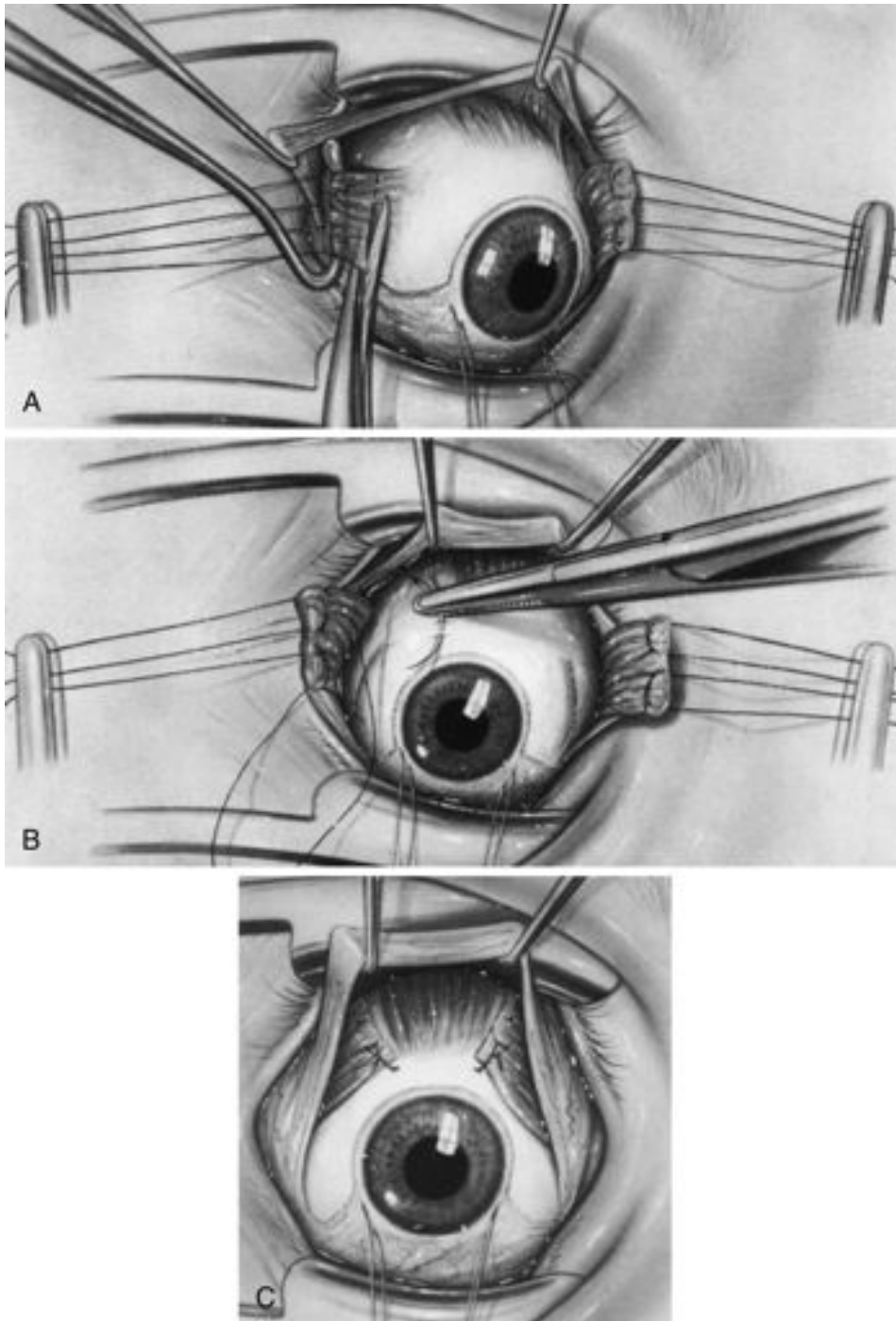


FIGURE 26–22. Transposition of horizontal rectus muscles to insertion of the right superior rectus according to Knapp. For explanation, see text. (From von Noorden GK: Extraocular muscles. In Beyer-Machule CK, von Noorden GK, eds: *Lids, Orbits, Extraocular Muscles*, Vol 1. In Heilmann K, Paton D, eds: *Atlas of Ophthalmic Surgery*. New York, Thieme-Stratton, 1985.)

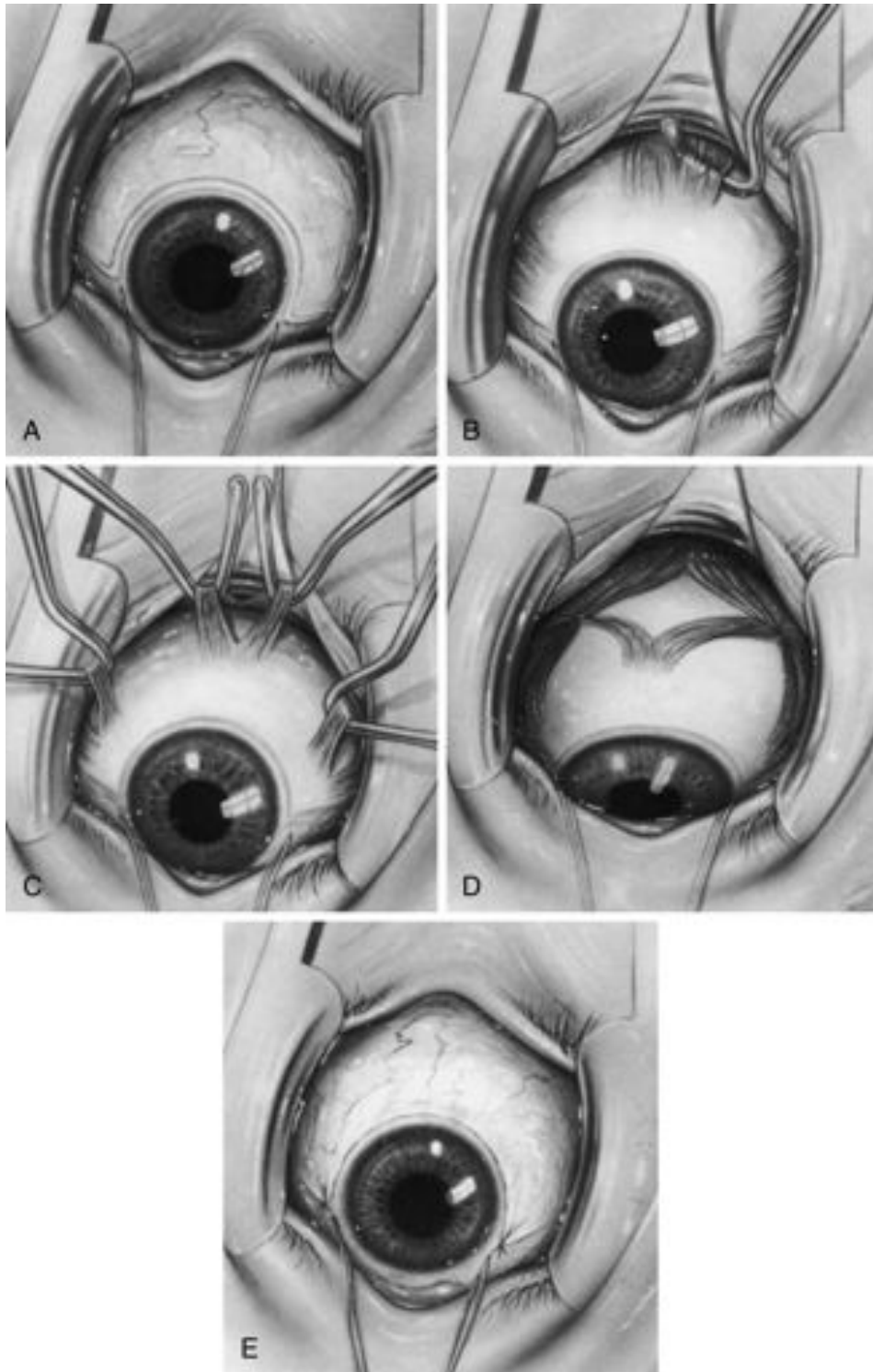


FIGURE 26-23. Muscle union according to Jensen. For explanation, see p. 616. (From von Noorden GK: Extraocular muscles. In Beyer-Machule CK, von Noorden GK, eds: Lids, Orbits, Extraocular Muscles, Vol 1. In Heilmann K, Paton D, eds: Atlas of Ophthalmic Surgery. New York, Thieme-Stratton, 1985.)

improved ocular motility in the vertical field of gaze to be obtained with this method is most satisfactory, and horizontal gaze is restricted little, if any.

For cranial nerve VI *paralysis*, we use a full

tendon-width transposition of the vertical rectus muscles to the insertion of the lateral rectus muscle or the procedure described by Jensen,¹³⁰ combined with a 6- or 7-mm recession of the medial rectus muscle. To enhance the effect of lateral

transposition of the vertical rectus muscles, Foster⁷⁵ suggested fixation of one fourth of each muscle to the sclera 16 mm posterior to the limbus with a nonabsorbable 5-0 Dacron suture. The rationale for this approach is based on recent findings with MRI that showed very little retroequatorial lateral displacement of a transposed vertical rectus muscle.¹⁶⁶ This stability of the posterior muscle path is thought to be the effect of musculo-orbital tissue connections (muscle pulleys).

The *Jensen procedure* is illustrated in Figure 26–23 using the right eye as an example. The surgeon has to move around to work on both vertical recti and the lateral rectus and for better mobility should stand during this operation. The right eye is rotated medially by means of traction sutures inserted through episclera near the limbus at the 1- and 5-o'clock positions and a partial peritomy has been performed (Fig. 26–23A). When combining the operation with a recession of the medial rectus, a total peritomy is required to gain access to all rectus muscles. The superior, lateral, and inferior recti have been exposed, and the tendon of the lateral rectus is split in its center with a muscle hook (Fig. 26–23B). The tendons of the lateral, inferior, and superior recti have also been split (Fig. 26–23C). At least one branch of the anterior ciliary vessel should remain in the nasal segment of each of the vertical recti that are not incorporated in the muscle union.¹⁸⁷ The temporal half of the superior and the superior half of the lateral rectus muscles have been loosely tied with a nonabsorbable suture (5-0 Mersilene) over the equator, and a similar muscle union has been completed between the temporal half of the inferior and the inferior half of the lateral rectus

(Fig. 26–23D). The conjunctiva is closed with two stitches at the limbus (Fig. 26–23E).

Our results with respect to moving the paretic eye from a position of extreme adduction into primary position and restoring abduction from 5° to 10° have been satisfactory in most instances (Fig. 26–24) (see also Frueh and Henderson⁸¹). An overcorrection during the immediate postoperative period frequently occurs but this is usually a transient phenomenon that disappears spontaneously and therefore need not be of concern to the surgeon. Selezinka and coworkers²⁵⁷ reported an average reduction of 40^A esotropia in primary position and an average postoperative abduction of 18° in 16 eyes with sixth nerve paralysis after medial rectus recession combined with a rectus muscle union according to Jensen.

Jensen developed this operation to protect the patient against anterior segment ischemia but, unfortunately, this protection is not 100%. The senior author, after having encountered anterior segment ischemia following the Jensen procedure combined with recession of the ipsilateral rectus muscle in an elderly lady,¹⁸⁸ no longer uses this operation in older persons. Similar results can be obtained and complications avoided by doing a “partial Knapp” instead, that is, *by transposing only the temporal halves of the superior and inferior rectus muscles to the insertion of the lateral rectus muscle, while taking very special care to leave at least one intact anterior ciliary artery in each of the nasal muscle stumps*. This is one situation in which the operating microscope may become indispensable during eye muscle surgery.

SUPERIOR OBLIQUE TENDON IN CRANIAL NERVE III PARALYSIS. Transposition of the supe-

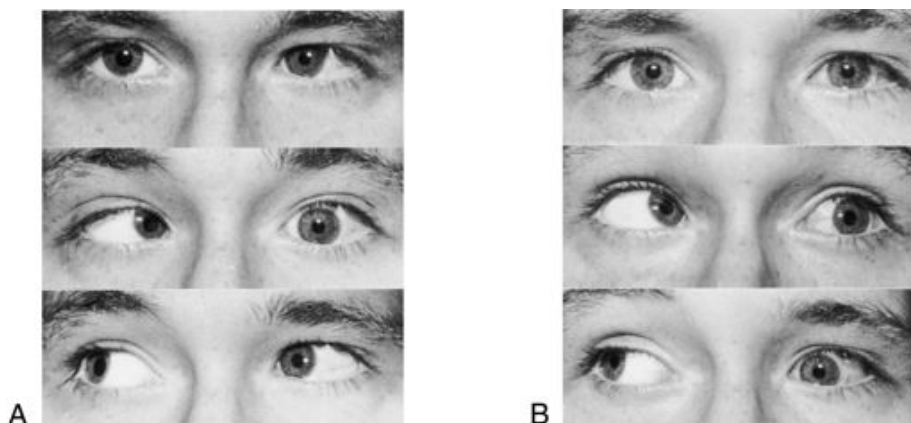


FIGURE 26–24. Improvement of ocular deviation in primary position and levoversion after Jensen procedure and medial rectus recession for a left sixth cranial nerve paralysis. *A*, Preoperatively. *B*, Postoperatively.

rior oblique tendon was suggested first by Dransart,⁶⁰ who sutured the resected tendon to the upper part of the lateral rectus insertion in the case of traumatic disinsertion of the tendon. Jackson,¹²⁰ Wiener,²⁹⁶ and Peter²²¹ described a technique by which the tendon is removed from the trochlea, resected, and reattached to the sclera near the insertion of the medial rectus muscle in cases of oculomotor paralysis. The effect is mechanical; the resected tendon pulls the eye from abduction toward the primary position. The superior oblique tendon is exposed under direct visualization and engaged with a muscle hook, as described earlier in this chapter. A small closed mosquito hemostat is then slid along the tendon until its tip enters the pulley of the trochlea. Opening the hemostat fractures the pulley, and the tendon can be disengaged. The tendon is shortened at least 10 or 12 mm and then sutured to the sclera near the upper border of the medial rectus muscle. This operation is combined with extensive recession (10 to 12 mm) of the lateral rectus muscle and maximal resection of the medial rectus muscle.

Some ophthalmologists have observed that adduction is improved after this procedure,^{47, 106} but in our experience this has not always been the case. Our approach to a complete oculomotor paralysis is outlined on page 448.

Recession of Conjunctiva and Tenon's Capsule

The elasticity of the conjunctiva and Tenon's capsule may be impaired severely if an eye has been deviated in one position for a long time or if scars have formed from previous operations. This factor must be considered in the etiology of mechanically restricted ocular motility. In such patients, forced closure of the conjunctiva after weakening the action of a muscle will counteract the effect of muscle surgery. Considering for how long conjunctival recession and baring of the sclera have been used in the surgical treatment of pterygium,²¹ it is surprising that this technique was seldom used in strabismus surgery until it was popularized by Cole and Cole⁴⁰ in 1962. These authors showed that a bare scleral closure after strabismus surgery is effective in eliminating mechanical restrictions of conjunctiva and Tenon's capsule, that it is uncomplicated, and that reepithelialization occurs in a short time. For obvious reasons the limbal conjunctival approach is especially suitable in muscle surgery if a conjunctival recession is planned at

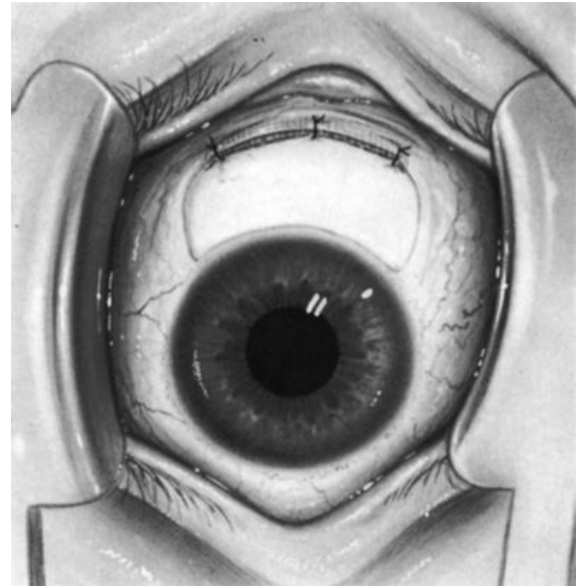


FIGURE 26–25. Bare sclera closure. For explanation, see text. (From von Noorden GK: Extraocular muscles. In Beyer-Machule CK, Noorden GK von, eds: *Lids Orbits, Extraocular Muscles*, Vol 1. In Heilmann K, Paton D, eds: *Atlas of Ophthalmic Surgery*. New York, Thieme-Stratton, 1985, p 218.)

the end of the operation. The conjunctiva is recessed to a point slightly anterior to the new muscle insertion and fastened to the sclera with interrupted 7-0 Vicryl sutures to prevent prolapse of Tenon's capsule (Fig. 26–25) and to act as a barrier against re-formation of scar tissue. Excess conjunctiva should be excised to achieve a neat closure without leaving an unsightly mass of elevated tissue. We do not routinely use conjunctival recessions but limit their use (1) to patients in whom one or both eyes have remained in a position of extreme adduction, abduction, or depression for a long time and in whom conjunctival tightness must be respected, (2) to those with extensive conjunctival scarring, and (3) to patients whose previously negative traction test after surgical reattachment of a muscle becomes positive after conjunctival closure.

Traction Sutures

If adhesion formation that might counteract the effect of the operation is anticipated, traction sutures may be used to hold the globe in an overcorrected position for several days after surgery. This technique is as old as the beginning of muscle surgery, was used as early as 1848 by Dieffenbach,⁵⁸ was mentioned by von Graefe⁹² and by Gruening,⁹⁷ and was revived by Martinez,¹⁵⁴ Vil-

laseca,²⁹² and Callahan.³³ Traction sutures are indicated after surgery for large angle unilateral deviations in adults in whom prior surgery was unsuccessful, leaving massive scar formation. For instance, in the treatment of a large unilateral esodeviation, two 5-0 Mersilene sutures on a spatula needle are placed through episclera near the limbus at the 12- and 6-o'clock positions. The needles are then cut off and each suture is re-threaded through a skin needle. This needle is passed through the lateral conjunctival fornix to emerge through the skin over the orbital rim. By tying the sutures over a rubber peg, one can rotate the eye into extreme abduction. The sutures are left in place for 7 to 10 days. Care must be taken to insert the sutures so that they do not override and erode the cornea. Some surgeons pass the sutures through the insertions of the rectus muscle for better anchoring, but in our experience this provides less of a fulcrum to rotate the eye.

Use of Plastic Materials

In the prevention of adhesions and preservation of muscle function after isolation from scar tissue during reoperations, plastic sheaths¹³⁸ or sleeves^{61, 62} were once popular and said to enhance the management of persistent strabismus. We no longer use these materials and have relied instead on reducing trauma to the muscle by using painstakingly gentle surgical manipulation of the tissues and reducing adhesions by meticulously cleaning the sclera.

Complications

Surgical Complications

Hemorrhages during surgery may result from cutting a conjunctival vessel or from accidentally cutting into the muscle during exposure. Sometimes the scleral muscle stump hemorrhages after the muscle has been disinserted. An intraconjunctival or intramuscular hematoma occasionally may develop. Control of bleeding is essential before continuing with the operation, since organization of the clot and subsequent scarring will inevitably result and unfavorably influence the surgical result. Cauterized tissue promotes scar formation; therefore, electrocautery should be used sparingly and only if a bleeding vessel can be directly identified. We have found wet field cautery especially

useful in muscle surgery, since it keeps tissue coagulation to a minimum. Most hemorrhages, particularly from a capillary bed, respond well to brief pressure with a cellulose sponge that may be soaked with a drop or two of 1:10,000 epinephrine; however, permission must be obtained from the anesthesiologist to use this drug. The conjunctival incision must never be closed until all hemorrhages have been controlled. Most hemorrhages can be prevented by delicate handling of the tissue and by including the marginal vessels of the extraocular muscles in the sutures.

One of the most distressing complications during strabismus surgery is the *loss of a muscle* because of inadvertent transection during surgery or as a result of direct trauma, breaking of the sutures, slippage from the muscle clamp, spontaneous disintegration while exerting pull on the muscle hook ("snapped muscle"),¹⁸⁰ or slippage and contracture of the muscle belly within the muscle capsule, which remains attached to the sclera.^{180, 223} The last complication usually involves the medial rectus muscle and occurs during the postoperative phase. It must be suspected when a large overcorrection with incomitance suddenly develops after initial alignment. Muscle slippage is caused by superficial suture placement that does not incorporate the entire thickness of the tendon. Neural imaging is indispensable in locating the slipped muscle prior to attempts to retrieve and reattach it.

When the muscle snaps or is lost during the operation, the surgeon, above all, must remain calm. Under bright illumination (headlight or microscope, if necessary), with the help of additional assistants and optimal exposure with malleable retractors, the area in which the muscle loss is suspected should be gently explored by hand-over-hand grasping of Tenon's capsule, to which posterior fibers of the muscle are usually attached. The direction of exploration should occur in the direction of the muscle, that is, in the case of the medial rectus muscle, along the medial orbital wall, rather than toward the posterior pole where the muscle will rarely be found and injury to the optic nerve is a risk.¹⁵² Irrigation of the operative field with balanced salt solution may cause the pink color of the muscle to contrast with the whitish color of Tenon's capsule and thus help identification of even a few remaining muscle fibers. These should be immediately secured with a suture. Rather than making later identification of the muscle difficult or even impossible by un-

necessarily traumatizing the tissues, the inexperienced surgeon is well advised to call for consultation or to close the wound and refer the patient immediately to an expert surgeon for reexploration. Neural imaging, especially computed tomography (CT) or MRI, may then be helpful in identifying the location of the muscle and in deciding whether further exploration should be attempted or, in the case of a lost medial rectus muscle retracted too far posteriorly, whether a nasal transposition of the vertical rectus muscles should be performed at this time. In our experience, a muscle can be reattached and will function normally even many months after it was lost during surgery. If the muscle was irretrievably lost, Brown recommended resecting and suturing Tenon's capsule to the muscle stump,²⁵ but we consider a muscle transposition to be the more effective procedure.

Inadvertent *perforation* of choroid or retina may occur when the needle is passed too deeply through the sclera. This complication probably is more common than generally realized^{37, 90, 132, 147, 160, 178, 260} but its occurrence has markedly declined since cutting needles have been replaced by spatula needles. The prevalence of chorioretinal perforation after conventional muscle surgery has recently been reported to range from 0.4%¹⁸³ to 1.5%¹⁵ on the basis of individual studies of large patient groups. A survey conducted by Simon and coworkers²⁶⁰ among²⁸⁵ members of the American Association of Pediatric Ophthalmology and Strabismus showed a prevalence of scleral perforation, as defined to include known retinal damage, in only 0.13% of 553,565 cases. An unusually high prevalence of 15.5% of chorioretinal scarring was reported to occur after posterior fixation sutures at the site of the scleral anchorage.² This figure contrasts with a prevalence of only 7% after this operation at Moorfields Eye Hospital.¹⁵¹

One must consider the possibility that not all pigmented lesions at muscle reinsertion sites are caused by perforation but may be the result of local tissue reaction to the suture material. In any case, retinal detachment endophthalmitis^{9, 90, 102, 247} and phthisis bulbi⁵ have been reported as infrequent but extremely serious complications of inadvertent perforation. Thus whenever perforation occurs during surgery, the retina should be examined immediately and the patient placed on systemic antibiotics and referred to a retinal specialist on the following day. Most retinologists will opt for observation without treatment. Such patients should be monitored closely during the immediate

postoperative phase with slit-lamp and fundus examinations for signs of intraocular inflammation and infection. We routinely check postoperative patients with a retinoscope for a bright fundus reflex.

A *scleral wound* made during dissection of the muscle insertion from the globe should be securely sutured and surrounded with diathermy or cryotherapy. The retina should be examined at the time of surgery and at close intervals during the postoperative period. Preventive measures include avoiding excessive pull on the muscle hook, which may force the sclera between the scissors blades when the muscle is being dissected from the globe, and exercising extreme care in patients with thin sclera, such as high myopes.

Transient mydriasis of the eye operated on may occur after detachment of a rectus or oblique muscle and is probably caused by release of neurotransmitters from tissue damage.¹²³ It disappears soon after surgery and is without clinical significance.

Complications of Anesthesia

Complications arising from anesthesia during muscle surgery are, fortunately, extremely rare, even though anesthesia is never entirely without danger. However minimal the risk may be, the possibility that severe and at times life-threatening situations can suddenly develop during the operation or the recovery period should never be ignored. The ophthalmic surgeon must keep abreast of modern methods of cardiac resuscitation and be able to assist the anesthesiologist in the management of *cardiac arrest*. The incidence of mortality during general anesthesia for strabismus surgery is not known exactly. Gartner and Billet⁸² conducted a survey among 557 North American ophthalmologists and reported a total of 72 deaths during the 10-year period between 1946 and 1956. Over half of these deaths occurred in patients under 7 years of age. A similar survey conducted in Germany by Knobloch and Lorenz,¹³⁹ who polled 324 ophthalmologists, revealed 60 deaths, 56 of which occurred during general anesthesia. These authors estimated that the number of operations on which this figure is based was approximately 300,000. J. Cooper and coworkers⁴⁴ estimated the mortality rate to be 1.1 per 10,000 cases, which indicates that more people die as a result of tooth extraction (17.42 per 10,000) than as a result of strabismus surgery.

In addition to cardiac arrest and asphyxia from other causes, hereditary or idiopathic *malignant hyperthermia* is cited as another life-threatening complication of general anesthesia.^{16, 24, 265} A careful history and constant monitoring of the rectal temperature during strabismus surgery have become routine in most operating rooms so that this problem may be detected early during the procedure. For details regarding the pathophysiology, diagnosis, and treatment of this fulminant hypermetabolic crisis, the reader is referred to the excellent reviews by Gronert⁹⁵ and by Marmor,¹⁵³ as well as the special bulletin issued by the American Society of Anesthesiologists.²⁸² We have encountered malignant hyperthermia on only four occasions and not once since we banned the use of succinylcholine in our operating room during strabismus surgery. In each instance, the alert pediatric anesthesiologist noted trismus during the induction phase and anesthesia was stopped before the surgery began. Creatinine phosphokinase (CPK) levels were abnormally high in these children. They were eventually readmitted, treated preoperatively and before induction with intravenous dantrolene, and tolerated anesthesia without further complications.

When taking the patient's history, the surgeon must always search for information with respect to unusual reactions to an anesthetic agent by members of the patient's family, since there are several other genetic conditions, such as *hepatic porphyria* and *suxamethonium sensitivity*, that cause severe complications during and after general anesthesia.⁸⁹ A less harmful complication is *bradycardia* caused by vagal stimulation, which results from pulling on the muscles, especially the medial rectus muscle. This oculocardiac reflex is a transient phenomenon and the surgeon must immediately stop any operative manipulation of the eye. The cardiac rhythm is usually restored after the pull on the muscle is relaxed, but intravenous injection of atropine is usually given by the anesthesiologist at this point. Injection of atropine is recommended prophylactically in all patients who are to undergo muscle surgery, and an additional dose is administered when the reflex is elicited during surgery.

Milot and coworkers¹⁶⁸ applied a standardized traction force to all extraocular muscles during surgery and reported no difference in the sensitivity of a particular muscle to stretching. However, they noted that quick traction was more likely to elicit the oculocardiac reflex than slow, progres-

sive traction. As mentioned above, patients in whom the oculocardiac reflex can be elicited during surgery become poor candidates for adjustable sutures. There is consensus among anesthesiologists that electrocardiographic monitoring is important during all types of eye surgery to detect potentially dangerous cardiac rhythm disturbances.¹⁵⁸

Postoperative Complications

Postoperative vomiting used to be a most unpleasant sequela of muscle surgery but is rarely a problem now since it can be controlled effectively with droperidol (Inapsine) administered intravenously (0.075 mg/kg) during induction of anesthesia.⁶⁷

Infections following strabismus surgery are rare but endophthalmitis is the most dreaded complication after strabismus surgery and nearly always results in phthisis bulbi and blindness. Knobloch and Lorenz¹³⁹ reported 87 cases following approximately 300,000 strabismus operations performed in Germany. A higher incidence (1:30,000) was reported by Ing¹¹⁷ in his survey of 63 North American strabismologists. From these reports the role of inadvertent scleral perforations in the etiology of endophthalmitis is not clear. Most studies^{90, 102, 260, 287} indicate that intraocular infections following muscle surgery can be related directly to scleral perforation. Such complications can be prevented by good surgical technique and by routine use of spatula needles during muscle surgery.

Orbital cellulitis is rarely mentioned in the literature. Only eight cases have been reported^{98, 112, 186, 199, 294, 297} but it might be safely assumed that this severe and potentially life-threatening complication occurs far more frequently than indicated in the literature. Ing¹¹⁷ reported an incidence of orbital cellulitis and subconjunctival abscess after strabismus surgery of 1 in 1900 cases. In the two patients reported by us, the infection developed on the second and third postoperative days, respectively, accompanied by the characteristic clinical signs of orbital infection, that is, proptosis, swelling of the eyelids, chemosis, and restriction of ocular motility. Both patients responded well to massive intravenous and topical antibiotic treatment and recovered completely. CT is indicated to exclude abscesses that may require draining. Since most surgeons discharge patients who have had extraocular muscle surgery either on the day of surgery or on the first postoperative day, it

is important to recognize that this complication may occur.

A most unusual complication of muscle surgery is a localized *suture abscess*, which one must assume to be caused by contaminated suture material. We have seen this complication only once and, as one would perhaps expect, in the child of a colleague and close associate. Rapid localized swelling and erythema developed over the insertion of the medial rectus muscle 7 days after a resection operation. The abscess was incised and pus drained from the wound; the organism was later identified as *Staphylococcus aureus*. Healing was uncomplicated, but subsequent formation of adhesions in the area of the abscess caused mechanical restriction of ocular motility, and reoperation became necessary.

Suture reactions used to be common but have become virtually extinct since the introduction of synthetic absorbable sutures. They occurred either as an acute allergic reaction between 24 hours and 7 days after surgery or as a delayed foreign body reaction 6 to 8 weeks later. During the acute stage the patient complained of ocular discomfort and itching and marked chemosis; hyperemia of the conjunctiva and swelling of the lids also may be present. The reaction could be so fulminating that retractors were necessary to open the lids.

Granulomas have become equally rare. They occur from 2 to 4 weeks after surgery and represent a nonallergic foreign body reaction to the suture material, cotton fibers, glove powder, or an eyelash buried in the wound. Characteristically, a localized, elevated, slightly hyperemic mass will appear over the muscle insertion and at times will form a pedicle type of attachment to the sclera. Treatment consists of topically applied corticosteroid drops, and excision of the granuloma occasionally may become necessary.

Anterior segment ischemia is a more serious complication of muscle surgery, caused by disinsertion of three or four rectus muscles with the inevitable disruption of blood supply to the anterior segment from the anterior ciliary arteries. Several cases are on record in which the patients developed anterior segment ischemia after surgery on just two opposing rectus muscles.^{66, 232, 248, 263} A survey conducted among the membership of the American Association of Pediatric Ophthalmology and Strabismus (1984) showed an estimated incidence of less than 1 case for each 13,000 procedures.⁷⁸ Within 24 hours after surgery, microcystic epithelial edema and marked thickening of the

cornea may develop. Prominent folds occur in Descemet's membrane, and nonpigmented keratic precipitates and a mild cellular aqueous humor reaction are usually present. Segmental iris atrophy,²⁸⁰ a fixed and distorted pupil, and cataract formation are late sequelae of this complication. Treatment consists of intensive systemic and topical administration of corticosteroids, and one patient was successfully treated with hyperbaric oxygen.²⁶³ However, there is no evidence that visual outcome or the speed of resolution is influenced by such treatment.²⁵⁰ Severe functional impairment of the eye and even phthisis bulbi have been reported.^{84, 104}

Apparently the tolerance to a reduction of blood supply to the anterior segment is higher in children than in adults⁸⁴ but exceptions do occur. Anterior segment ischemia occurred in a child with retinopathy of prematurity after surgery on the horizontal recti⁶⁶ and in a healthy 10-year-old after a Jensen procedure combined with recession of the ipsilateral medial rectus muscle.¹⁸ Anterior segment ischemia has been observed in older patients in whom the Hummelsheim procedure or one of its modifications was combined with surgery on one or both horizontal rectus muscles.^{69, 74, 84, 250, 279} It has been described in a leukemic patient after surgery on the two horizontal rectus muscles¹²² and in a 66-year-old woman after the Jensen procedure combined with a medial rectus recession.¹⁸⁸ Saunders and Sandall²⁴⁹ reported anterior segment ischemia following full tendon transposition of the superior and inferior rectus muscles 9 and 20 years after ipsilateral horizontal rectus muscle surgery. Although fluorescent iris angiography appeared to be a promising method to determine when collateral circulation developed after muscle surgery,^{103, 210, 211, 245} the "safe" interval after which the second procedure can be planned is unknown and subject to wide individual variations. The probable mechanism of redistribution of blood flow to the anterior segment after disinserting the muscles is via the long posterior ciliary arteries. Routine preoperative angiograms are not recommended. As a general rule, we advise waiting at least 6 months in adult patients after surgery on both horizontal rectus muscles before operating on the vertical recti.

Several methods have been reported for preservation of the anterior ciliary vessels during muscle surgery.^{79, 141, 159, 246} These range from microdissection of the vessels from the muscle under the operating microscope or loupes to a modified

tucking operation during which the muscle with its vessels is plicated rather than detached from the sclera and resected. Contrary to what one may expect, the vessels in the tucked muscle have been reported to remain patent postoperatively, at least in monkeys.³⁰⁶ It is not certain whether the anterior ciliary arteries continue to function after these manipulations in humans. These dissection procedures are time-consuming and technically difficult, especially in the age group at risk for anterior segment ischemia. Moreover, it has been reported that this complication can occur despite the use of blood vessel-sparing surgical techniques.¹⁷⁴

Fishman and coworkers⁷² observed in cynomolgus monkeys that a fornix conjunctival incision may provide partial protection against anterior segment ischemia by preserving the perilimbal circulation. Whether the same holds true for humans remains to be established. For additional discussion and literature references on anterior segment ischemia, the reader is referred to a recent review article.²⁵⁰

A harmless and rare complication is an *amputation neuroma* that may develop at the site of the old insertion after tenotomy of a muscle as many as 4 to 8 years after muscle surgery.^{300, 301}

Conjunctival cysts develop when small sections of conjunctival epithelium become buried in the wound during closure. The cyst is filled with clear fluid and can be evacuated with a needle puncture under local anesthesia. If the cyst recurs, excision becomes necessary.

Corneal dellen (plural of the German: *Delle*, a small depression) are caused by interruption of the corneal tear film and local dehydration of the cornea. This benign complication occurs in the postoperative phase, especially when the limbal incision is used, and must be distinguished from marginal corneal ulcers. Dellen usually respond well to a firm bandage applied to the eye for 24 to 48 hours. They can be prevented by smooth closure of the limbal wound and resection of excess conjunctiva to prevent tissue elevation near the limbus. Scharwey and coworkers²⁵¹ reported a decreased prevalence of corneal dellen if plication of a muscle is used rather than a resection.

A *scleral delle* after strabismus surgery consisted of a dark, translucent scleral patch that disappeared after hydration and reappeared on dehydration and was managed by covering the bare sclera with a conjunctival flap.²⁵⁸

A more serious complication involving the sclera is *necrotizing scleritis*.²⁰¹ It occurs infre-

quently after strabismus surgery and seems to affect mostly patients with autoimmune vasculitic systemic disease.^{133, 156, 201} We have observed it only once, 1 month after strabismus surgery in a 60-year-old woman without detectable autoimmune disease.⁹⁶ Inflammation was controlled with topical and systemic corticosteroids and ibuprofen, and good visual acuity was preserved. Interestingly, the patient developed a *transient myopia* of the involved eye which had not been previously described in connection with necrotizing scleritis. Since there was no axial elongation of the eye on ultrasonography we presume that the anterior segment inflammation produced a transient increase in the refractive index of the lens.

Changes in the *refractive error* (mostly astigmatism) have been reported after surgery on the extraocular muscles^{55, 59, 227, 232, 264, 283} and are thought to be caused by the effects of a temporary imbalance of muscle forces on the corneal curvature.²⁸⁵ One study reported no changes in the corneal topography after routine strabismus surgery²²⁷ but others have described such changes^{99, 148, 251} Nearly all anomalies of corneal topography return to normal after 3 months, but in rare cases an induced astigmatism may persist.²⁵² *The practical significance of these findings is that refraction and, if necessary, a change of glasses should be delayed until 3 to 4 months after surgery on the rectus muscles.*

Diplopia often occurs when a patient with comitant heterotropia undergoes extraocular muscle surgery and the position of the deviated eye is changed so that the fixated object may no longer fall into the area of the suppression scotoma. Provided there is any vision at all in the eye operated on, such a patient will have postoperative diplopia lasting from a few minutes to a day, a week, or a lifetime. How long it persists depends on the ability of the patient to suppress or to ignore the second image. Since this ability decreases with age, constant diplopia is more common in adults. Although young children as a rule respond readily to the new position of the eye with newly formed suppression, a surprising number actually see double immediately after strabismus surgery. Unlike adults, however, children are rarely distressed by diplopia.

Persistent postoperative diplopia is rare, probably because most patients remain slightly undercorrected after strabismus surgery, and the area of suppression extends from the retinal periphery to the fovea in most forms of horizontal strabismus

and some forms of vertical strabismus. Nevertheless, the danger of persistent, distressing, postoperative diplopia must be pointed out to all adults who desire correction of the deviation. It is then up to the patient to assume the risk. To assess this risk preoperatively and to give the patient a chance to experience diplopia, we fully or nearly fully correct the deviation with prisms placed in a trial frame or fitover frame in front of the glasses. Even if diplopia can be elicited in this way, this does not prove that it will be present after surgery; however, the possibility exists, and the patient at least has been shown what double vision means.

The attitude of a patient with insufferable postoperative diplopia depends on his or her personality. A stolid person will adjust and in time may learn to disregard the second image, though it may not actually be suppressed. More often, the patient knows that the second image should not be there, continually looks for it, and becomes increasingly distressed and hampered in his or her activities. Insufferable postoperative diplopia occurs not only in patients with normal visual acuity in the deviated eye but also occasionally in patients with a deeply amblyopic eye that has been operated on. The second image is then dim, of course, but may cause considerable annoyance to the patient.

Problems arise when treating persistent postoperative diplopia, especially if the eyes are nearly aligned and the images are close together. If this situation can be corrected with prisms, they may be prescribed, or an additional operation may be performed. Some form of occlusion therapy is a final resort when prisms fail or the deviation is too small for reoperation to be considered. Patients who underwent surgery for cosmetic reasons in the first place usually decline the use of a conspicuous occluding device. Occluder contact lenses with a painted iris and pupil are acceptable to some.

Overcorrections

Overcorrections happen in the hands of all surgeons, even the most experienced. They may occur in the immediate postoperative phase or months or even years after surgery. Overcorrections may be accompanied by gross incomitance and inability to move the eye in the field of action of a weakened muscle and may occur in patients in whom the action of the muscle operated on appears perfectly normal.

Marked overcorrection can be attributed to ex-

cessive weakening of the action of a muscle or excessive strengthening of its antagonist. Should one note on the day after surgery that a previously esotropic eye is exotropic and that the patient cannot adduct that eye even to the midline, partial or complete disinsertion of the medial rectus muscle must be suspected. Immediate exploration is then indicated, since with the passage of time, location of a disinserted and retracted muscle becomes increasingly difficult. In all other situations, it is advisable to wait at least 6 weeks or longer before considering reoperation. In planning surgery for overcorrection, one should use the *forced duction test* to determine whether the overcorrection is caused by excessive recession or an excessive resection. The test will be negative if excessive recession has been done. If the muscle has been excessively resected, restriction will be noted on attempts to move the eye in the direction opposite the field of action of the resected muscle, in which case the resected muscle should be recessed.

Cooper⁴² suggested that “undoing what was done” is not always the best way to overcome overcorrections. He suggested that the surgical decision be based on the result of the examination, as in other cases of strabismus, and not on the fact that the patient had prior surgery. Thus a patient who has undergone bimedial recession and is left with a divergence excess type of exodeviation is a much better candidate for recession of both lateral rectus muscles than for advancement of the previously recessed medial rectus muscles. With the exception of overcorrections caused by obvious mechanical obstacles, we have adhered to what has become known among North American strabismologists as “Cooper’s law” and find that overcorrections no longer present the problems they once did. The reader is referred to Chapters 16 and 17 for a discussion of the clinical management of overcorrected esodeviations and exodeviations.

Postoperative Care

Length of Hospitalization and Postoperative Checkups

The length of hospitalization for strabismus surgery in recent years has been drastically reduced in most medical centers of this hemisphere. The length of hospital stay is now determined primar-

ily by the time it takes for the effect of general anesthesia to dissipate rather than by concern for the success of the operation. Most patients will be able to leave the hospital in the afternoon if surgery is performed in the morning. For nearly 40 years we have performed muscle surgery on an outpatient basis without a single untoward incident. Laboratory and physical examinations are completed on the day before admission. The patient reports directly to the outpatient surgical suite on the morning of surgery and is discharged from the recovery room on the same day.

It is important to guard against postoperative complications and all patients are examined 24 hours after surgery. We look for large, unexpected overcorrections and external or intraocular infections. The brightness of the retinoscopic light reflex is noted and in older children or adults biomicroscopy is performed. Endophthalmitis may occur after an initial normal examination and not until 3 to 4 days after surgery.²³³ Therefore the parents are instructed to return with the child immediately or, when from out of town, to the local ophthalmologist in case of increasing redness of the eye(s), swelling of the eyelids, lethargy, or fever. Adult patients are alerted to watch for dimming of vision in the eye operated on. One week after surgery we again reexamine our patients or, in the case of out-of-towners, have the examination performed by the local ophthalmologist. The final postoperative evaluation, including a complete motility analysis, is done 6 weeks after surgery, at which time the new position of the affected eye usually is stable.

Dressing

In some foreign clinics, it is still customary to bandage both eyes for several days even though muscle surgery was performed on only one eye. We are strongly opposed to binocular dressings, since they not only have no effect on the outcome of the operation but also are most distressing to the patient, especially a young child. Even with the best of care, every surgical hospital admission is emotionally upsetting to the patient, and a binocular dressing contributes further to the feeling of isolation and distress. After routine procedures, we do not even apply a dressing to the eye or eyes operated on, and it is our clinical impression that there is less redness, edema, and irritation than when the eye is patched. However, after complicated reoperations, we apply a mild pres-

sure dressing to the eye operated on for 24 hours to control postoperative edema. The eye is also patched when adjustable sutures are used to avoid inadvertent pulling on the sutures.

Medication

Most North American strabismus surgeons prefer to treat the eye operated on with an ointment containing corticosteroids and antibiotics for several days after surgery¹⁸⁷ (see also Chipont and Hermosa³⁶). No controlled studies are available to support the rationale for such therapy, but from clinical experience it appears to some that there is less secretion from the wound and more rapid whitening of the eye if steroids are used for a few days. It is quite possible that the mechanical lubricating effect of the ointment rather than its pharmacologic action may account for this effect.

Corticosteroid-induced glaucoma has been reported in an adult patient who noted a sudden decrease of vision 3 days after strabismus surgery.³⁵ Infants and young children are unlikely to report such changes in visual acuity, yet marked intraocular pressure increases after topical corticosteroids are known to occur in this age group.²⁰³ Routine strabismus surgery does not affect the blood-aqueous barrier¹³⁴ and in view of the foregoing it appears increasingly doubtful whether postoperative corticosteroids should be prescribed at all.

No ointment is used when adjustable sutures are employed. Medication for postoperative pain is rarely required, since most patients experience only a mild foreign body sensation and some soreness on moving the affected eye after muscle surgery.

Whether a postoperative course of oral antibiotics is indicated is highly debatable. Considering the current litigious climate in the United States, it is perhaps not surprising that many surgeons have switched over in recent years from no medication to treating their patients with oral antibiotics.²¹⁸ According to a survey conducted by Ing¹¹⁷ among North American strabismologists, there is no evidence that either preoperative or postoperative topical or oral antibiotics prevent cellulitis or endophthalmitis after muscle surgery.

REFERENCES

1. Adelstein FE, Cüppers C: Probleme der operativen Schielbehandlung. *Ber Dtsch Ophthalmol Ges* 69:580, 1969.

2. Alio JL, Faci A: Fundus changes following faden operation. *Arch Ophthalmol* 102:211, 1984.
3. Alvaro ME: Simultaneous surgical correction of vertical and horizontal deviations. *Ophthalmologica* 120:191, 1950.
4. Anderson RL, Holds JB: Does anyone know how to differentiate a "functional" defect from a cosmetic one? *Arch Ophthalmol* 108:1685, 1990.
5. Apple DJ, Jones GR, Reidy JJ, Loftfield K: Ocular perforation and phthisis bulbi secondary to strabismus surgery. *J Pediatr Ophthalmol Strabismus* 22:184, 1985.
6. Apt L, Isenberg S: Eye position of strabismus patients under general anesthesia. *Am J Ophthalmol* 84:574, 1977.
7. Aust W, Welge-Lüssen L: Prä- und postoperative Schielwinkel-Änderungen nach längerem präoperativen prismatischen Schielwinkelausgleich. *Klin Monatsbl Augenheilkd* 155:494, 1969.
8. Bagolini B: Anomales Binokularsehen und dessen Konsequenzen für die Schieloperation. In Herzau V, ed: *Pathophysiologie des Sehens*. Stuttgart, Ferdinand Enke Verlag, 1984, p 233.
9. Basmadjian G, LaSelle P, Dumas J: Retinal detachment after strabismus surgery. *Am J Ophthalmol* 79:305, 1975.
10. Beisner DH: Reduction of ocular torque by medial rectus recession. *Arch Ophthalmol* 13:85, 1971.
11. Bérard PV: La technique de Harada et Ito dans le traitement des cyclotropies isolées. *Bull Soc Ophthalmol Fr* 77:341, 1977.
12. Bérard PV, Quéré MA, Roth A, et al.: *Chirurgie des strabismes*. Paris, Masson, 1984, p 269.
13. Berens C, Cole HG, Chamichian S, Enos MV: Retroplacement of the inferior oblique at its scleral insertion. *Am J Ophthalmol* 35:217, 1952.
14. Berg F: The Chevalier Taylor and his operation. *Br J Ophthalmol* 51:667, 1967.
15. Berger RW, Haase W: Complications in strabismus surgery. *Strabismus* 5:67, 1997.
16. Bergman JA: Idiopathic malignant hyperthermia. *Arch Ophthalmol* 93:232, 1975.
17. Blaskovics L von, Kreiker A: *Eingriffe am Auge*. Stuttgart, Ferdinand Enke Verlag, 1945, p 3.
18. Bleik JH, Cherfan GM: Anterior segment ischemia after the Jensen procedure in a 10-year-old patient. *Am J Ophthalmol* 119:524, 1995.
19. Bloomgarden CI, Jampel R: Adaptation following transpositions of the extraocular muscles in the *Macaca mulatta*. *Am J Ophthalmol* 56:250, 1963.
20. Bock CJ, Buckley E, Freedman S: Combined resection and recession of a single rectus muscle for the treatment of incomitant strabismus. *J Am Assoc Pediatr Ophthalmol Strabismus* 3:263, 1999.
21. Boeckmann EJ: The operative treatment of pterygium. *JAMA* 28:97, 1897.
22. Bolton J: *A Treatise on Strabismus with a Description of New Instruments Designed to Improve the Operation for Its Cure, in Simplicity, Ease and Safety*. Richmond, VA, PD Bernard, 1842.
23. Börner R: Zur Änderung der Augenstellung in Narkose unter besonderer Berücksichtigung des Strabismus comitans. *Klin Monatsbl Augenheilkd* 142:373, 1963.
24. Britt BA: Recent advances in malignant hyperthermia. *Anesth Analg* 51:841, 1972.
25. Brown HW: Complications in surgery of the extraocular muscles. In Fasanella RM, ed: *Management of Complications in Eye Surgery*. Philadelphia, WB Saunders, 1957.
26. Brown HW: Complications of the surgical management of strabismus. In Haik GM, ed: *Strabismus*. Symposium of the New Orleans Academy of Ophthalmology. St Louis, Mosby-Year Book, 1962.
27. Buckley EG, Flynn JT: Superior oblique recession versus tenotomy: A comparison of surgical results. *J Pediatr Ophthalmol Strabismus* 20:112, 1983.
28. Buckley EG, Meekins BB: Fadenoperation for the management of complicated incomitant vertical strabismus. *Am J Ophthalmol* 105:304, 1988.
29. Byung-Moo M, Ju-Hee P, Seung-Young K, Seong-Bok L: Comparison of inferior oblique muscle weakening by anterior transposition or myectomy: A prospective study of 20 cases. *Br J Ophthalmol* 83:206, 1999.
30. Caldeira JA: Graduated recession of the superior oblique muscle. *Br J Ophthalmol* 59:553, 1975.
31. Caldeira JA: Bilateral recession of the superior oblique in "A" pattern tropias. *J Pediatr Ophthalmol Strabismus* 15:306, 1978.
32. Calhoun JH, Nelson LB, Harley RD: *Atlas of Pediatric Ophthalmic Surgery*. Philadelphia, WB Saunders, 1987.
33. Callahan A: The arrangement of the conjunctiva in surgery for oculomotor paralysis and strabismus. *Arch Ophthalmol* 66:241, 1961.
34. Cassin B, Serianni N, Romano P: The change in ocular alignment between the first day and six weeks following eye muscle surgery. *Am Orthopt J* 36:99, 1986.
35. Chimonidou E, Chatzistefanou K, Theodossiadis G: Treatment of inferior oblique muscle overaction with myectomy or with anterior transposition. *Eur J Ophthalmol* 6:11, 1996.
36. Chipont E, Garcia-Hermosa P: Use of steroids after strabismus surgery. *J Pediatr Ophthalmol Strabismus* 37:176, 2000.
37. Cibis GW: Incidence of inadvertent perforation in strabismus surgery. *Ophthalmic Surg* 23:360, 1992.
39. Clark RA, Isenberg SJ, Rosenbaum AL, Demer JL: Posterior fixation sutures: A revised mechanical explanation for the fadenoperation based on rectus extraocular muscle pulleys. *Am J Ophthalmol* 128:702, 1999.
38. Clark RA, Rosenbaum AL: Instrument-induced measurement errors during strabismus surgery. *J Am Assoc Pediatr Ophthalmol Strabismus* 3:18, 1999.
40. Cole JG, Cole HG: Recession of the conjunctiva in complicated eye muscle operations. *Am J Ophthalmol* 53:618, 1962.
41. Conrad HG, Decker W de: Torsional Kestenbaum procedure: Evolution of a surgical concept. In Reinecke R D, ed: *Strabismus II*. Orlando, FL, Grune & Stratton, 1984, p 301.
42. Cooper EL: The surgical management of secondary exotropia. *Trans Am Acad Ophthalmol Otolaryngol* 65:595, 1961.
43. Cooper EL, Sandall GS: Recession versus free myotomy at the insertion of the inferior oblique muscle. Comparative analysis of the surgical correction of overaction of the inferior oblique. *J Pediatr Ophthalmol Strabismus* 6:6, 1969.
44. Cooper J, Medow N, Dibble C: Mortality rate in strabismus surgery. *J Am Optom Assoc* 52:391, 1982.
45. Correspondenzen: *Aerztl Intelligenz Bl* 7:71, 1855.
46. Cortés VM: Nueva incisión conjuntival para la operación de estrabismo. *Arch Chil Oftalmol* 14:54, 1962.
47. Costenbader FD: Round table discussion. In Allen JH, ed: *Strabismus Ophthalmic Symposium II*. St Louis, Mosby-Year Book, 1958, p 502.
48. Costenbader FD, Kertesz E: Relaxing procedures of the inferior oblique, a comparative study. *Am J Ophthalmol* 57:276, 1964.
49. Cüppers C: The so-called "Fadenoperation" (surgical correction by well defined changes in the arc of contact). In Fells P, ed: *Second Congress of the International Strabismological Association*. Marseilles, Diffusion Générale de Librairie, 1976, p 395.

50. Cüppers C, Thomas C: "L'opération du fil" sur un oeil pour la traitement de ptosis de l'autre oeil par la provocation d'une impulsion d'élévation sur cet autre oeil. *Bull Mem Soc Fr Ophthalmol* 87:318, 1975.
51. De Angelis D, Makar I, Kraft SP: Anatomic variations of the inferior oblique muscle: A potential cause of failed inferior oblique weakening surgery. *Am J Ophthalmol* 126: 485, 1999.
52. Decker W de: Bindehauteröffnung am Limbus. *Klin Monatsbl Augenheilkd* 151:76, 1967.
53. Decker W de: Rotatorischer Kestenbaum an den geraden Augenmuskeln. *Z Prakt Augenheilkd* 11:11, 1990.
54. Decker W de, Conrad HG: Fadenoperation bei komplizierten Augenmuskelerkrankungen und nichtakkommodativem Konvergenzexzess. *Klin Monatsbl Augenheilkd* 167: 217, 1975.
55. Denis D, Bardot J, Volot F, et al. Effects of strabismus surgery on refraction in children. *Ophthalmologica* 209:136, 1995.
56. Dieffenbach JF: Ueber die Heilung des angeborenen Schielens mittels Durchschneidung des inneren geraden Augenmuskels. *Med Z.* 46:227, 1839.
57. Dieffenbach JF: Vorläufige Bemerkungen über die Operation des Schielens. *Wochenschr Ges Heilkd* 27:424, 1840.
58. Dieffenbach JF: Die Operation des Schielens. In *Die operative Chirurgie*, vol 2. Leipzig, FA Brockhaus, 1848, p 164.
59. Dottan SA, Hoffman P, Oliver MD: Astigmatism after strabismus surgery. *Ophthalmic Surg* 19:128, 1988.
60. Dransart HN: De la suppléance du muscle grand oblique par le muscle droit externe et par la muscle droit inferieur. *Rev Gen Ophtalmol* 26:229, 1907.
61. Dunlap EA: Plastic implants in muscle surgery: A study of the possible use of plastic material in the management of extraocular motility restrictions. *Trans Am Ophthalmol Soc* 65:393, 1967.
62. Dunlap EA: The use of plastic sleeves in muscle surgery (clinical applications of certain experimental studies in animals). *Trans Am-Acad Ophthalmol Otolaryngol* 73:91, 1969.
63. Dyer JA: Tenotomy of the inferior oblique muscle at its scleral insertion. *Arch Ophthalmol* 68:176, 1962.
64. Elder MJ, Dempster AG, Molteno ACB: A clinicopathological study of loop recessions in strabismus. *Aust NZJ Ophthalmol* 20:115, 1992.
65. Elliott RL, Nankin SJ: Anterior transposition of the inferior oblique. *J Pediatr Ophthalmol Strabismus* 18:35, 1981.
66. Elsas FJ, Witherspoon CD: Anterior segment ischemia after strabismus surgery in a child. *Am J Ophthalmol* 103:833, 1987.
67. Eustis S, Lerman J, Smith DR.: Effect of droperidol pretreatment on post-anesthetic vomiting in children undergoing strabismus surgery: The minimum effective dose. *J Pediatr Ophthalmol Strabismus* 24:165, 1987.
68. Faber JTHN de, Noorden GK von: Medial rectus muscle marginal myotomies for persistent esotropia. *Am J Ophthalmol* 112:702, 1991.
69. Fells P: Vertical rectus muscle transplantation to restore abduction. In Mein J, Bierlaagh JJM, Brummelkamp-Dons TEA, eds: *Orthoptics: Proceedings of the Second International Orthoptic Congress*. Amsterdam, Excerpta Medica, 1972.
70. Fells P: Management of paralytic strabismus. *Br J Ophthalmol* 58:255, 1974.
71. Fink WH: *Surgery of the Oblique Muscles of the Eye*. St Louis, Mosby-Year Book, 1951, p 296.
72. Fishman PH, Repka MX, Green WR, et al: A primate model of anterior segment ischemia after strabismus surgery—the role of the conjunctival circulation. *Ophthalmology* 97:456, 1990.
73. Fleussu, cited by Remky H: Die Frühzeit der operativen Schielbehandlung (1839–184). Presented at the Seventh Meeting of the Julius Hirschberg Society, Vienna, Nov 4–7, 1993.
74. Forbes SB: Muscle transplantation for external rectus paralysis: Report of a case with unusual complications. *Am J Ophthalmol* 48:248, 1959.
75. Foster SR: Vertical muscle transposition augmented with lateral fixation. *J Am Assoc Pediatr Ophthalmol Strabismus* 1:20, 1997.
76. Foster J, Pemberton EC: The effect of operative alterations in the height of the external rectus insertion. *Br J Ophthalmol* 30:88, 1946.
77. France NK, France TD, Woodburn JD, Burbank D: Succinylcholine alteration of the forced duction test. *Ophthalmology* 87:1282, 1980.
78. France TD, Simon JW: Anterior segment ischemia syndrome following muscle surgery: The AAPOS experience. *J Pediatr Ophthalmol Strabismus* 23:87, 1986.
79. Freedman HL, Waltman DD, Patterson JH: Preservation of anterior ciliary vessels during strabismus surgery: A nonmicroscopic technique. *J Pediatr Ophthalmol Strabismus* 29:38, 1992.
80. Friendly DS, Parelhoff ES, McKeown CA: Effect of severing the check ligaments and intermuscular membranes on medial rectus recessions in infantile esotropia. *Ophthalmology* 100:945, 1993.
81. Frueh BR, Henderson JW: Rectus muscle union in sixth nerve paralysis. *Arch Ophthalmol* 85:191, 1971.
82. Gartner S, Billet E: A study on mortality rates during general anesthesia for ophthalmic surgery. *Am J Ophthalmol* 45:847, 1958.
83. Gibson W: *The Institutes and Practice of Surgery*, ed 6. Philadelphia, E Parker, 1841, p 375.
84. Girard LJ, Beltranena F: Early and late complications of extensive muscle surgery. *Arch Ophthalmol* 64:576, 1960.
85. Gobin MH: Recession of the medial rectus muscle with a loop. *Ophthalmologica* 156:25, 1968.
86. Gonzales C: Denervation of the inferior oblique: Current status and long-term results. *Trans Am Acad Ophthalmol Otolaryngol* 81:899, 1970.
87. Gonzales C: Denervation of the inferior oblique procedure (as a weakening surgical procedure). *Trans Am Acad Ophthalmol Otolaryngol* 78:816, 1974.
88. Gonzales C, Klein B: Myectomy and anterior transposition of the inferior oblique muscle: A new surgical procedure and its results in 49 operations. *Binocular Vision Strabismus* 8:249, 1993.
89. Gordon H: In discussion of Zsigmond EK, Starkweather WH, Duboff GS, Flynn KA: Abnormal creatine-phosphokinase isoenzyme pattern in families with malignant hyperthermia. *Anesth Analg* 51:837, 1972.
90. Gottlieb F, Castro JL.: Perforation of the globe during strabismus surgery. *Arch Ophthalmol* 84:151, 1970.
92. Graefe A von: Kurzer Bericht aus den Berliner Kliniken. *Dtsch Klin* 16:547, 1853.
93. Graefe A von: Beiträge zur Lehre vom Schielen und von der Schiel-Operation. *Arch Ophthalmol* 3:177, 1857.
91. Graefe A [Ifred K]: Die Indikationsstellung bei operativer Behandlung der paralytisch bedingten Deviation des Auges. *Graefes Arch Clin Exp Ophthalmol* 33:179, 1887.
94. Greenwald MJ: Prism adaptation study (letter). *Ophthalmology* 103:1725, 1996.
95. Gronert G: Malignant hyperthermia. *Anesthesiology* 53:395, 1980.
96. Gross SA, Noorden GK von, Jones DB: Necrotizing scleritis and transient myopia following strabismus surgery. *Ophthalmic Surg* 24:839, 1993.
97. Gruening E: On the operative treatment of divergent strabismus. *Trans Am Ophthalmol Soc* 6:165, 1891.

98. Haase CG.: Tenotomia musculi recti externi; phlegmonöse Entzündung des Orbitalzellgewebes mit Ausgang in Atrophia nervi optici. *Arch Augenheilkd* 9:442, 1880.
99. Hainsworth DP, Bierly JR, Schmeisser ET, Baker RS: Corneal topographic changes after extraocular muscle surgery. *J Am Assoc Pediatr Ophthalmol Strabismus* 3:80, 1999.
100. Harada M, Ito Y: Surgical correction of cyclotropia. *Jpn J Ophthalmol* 8:88, 1964.
101. Harms H.: Ein Vorlagerungsverfahren mit nachträglicher Dosierungsmöglichkeit. *Klin Monatsbl Augenheilkd* 104:729, 1940.
102. Havener WH, Kimball OP: Scleral perforation during strabismus surgery. *Am J Ophthalmol* 50:807, 1960.
103. Hayreh SS, Scott W: Fluorescein iris angiography. II. Disturbances in iris circulation following operation on the various recti. *Arch Ophthalmol* 96:1390, 1978.
104. Helveston EM: Muscle transposition procedures. *Surv Ophthalmol* 16:92, 1971.
105. Helveston EM: The value of strabismus surgery. *Ophthalmic Surg* 21:311, 1990.
106. Helveston EM: Surgical Management of Strabismus. An Atlas of Strabismus Surgery, ed 4. St Louis, Mosby-Year Book, 1993.
107. Helveston EM, Alcorn DM, Ellis FD.: Inferior oblique inclusion after lateral rectus surgery. *Graefes Arch Clin Exp Ophthalmol* 226:102, 1988.
108. Helveston EM, Cofield DD.: Indications for marginal myotomy and technique. *Am J Ophthalmol* 70:574, 1970.
109. Helveston EM, Patterson JH, Ellis FD, Weber JC: En bloc recession of the medial recti for concomitant esotropia. In Symposium on Strabismus: Transactions of the New Orleans Academy of Ophthalmology. St Louis, Mosby-Year Book 1978, p. 230.
110. Herzau V, Schoser G: Zum Wert des Prismenadaptations-tests bei der Dosierung einer Schieloperation. *Ophthalmologie* 90:11, 1993.
111. Hildreth HR: The tendon-transplanting operation. *Am J Ophthalmol* 36:1267, 1953.
112. Holt EE: Orbital cellulitis, the inflammation spreading to the temporal region, thence to the neck, obstructing deglutition, extending to the brain, and producing death. With remarks upon the same and brief reports of five other cases. *Trans Am Ophthalmol* 6:295, 1892.
113. Hirschberg J: The History of Ophthalmology, vol 4: The Renaissance of Ophthalmology in the Eighteenth Century, pt 2. Translated by Blodi FC. Bonn, JP Wayenbourgh Verlag, 1984.
114. Hirschberg J: The History of Ophthalmology, vol 5: The Renaissance of Ophthalmology in the Eighteenth Century pt 3. The First Part of the Nineteenth Century, pt 1. Translated by Blodi FC. Bonn, JP Wayenbourgh Verlag, 1985.
115. Hummelsheim E: Weitere Erfahrungen mit partieller Sehnenüberpflanzung an den Augenmuskeln. *Arch Augenheilkd* 62:71, 1908–1909.
116. Iacobucci I, Beyst-Martonyi J: The use of press-on prisms in the preoperative evaluation of adults with strabismus. *Am Orthopt J* 28:68, 1978.
117. Ing MR: Infection following strabismus surgery. *Ophthalmic Surg* 22:41, 1991.
118. Isenberg SJ, Blochman B: Oculocardiac reflex during postoperative muscle adjustment. *Am J Ophthalmol* 94:422, 1982.
119. Isenberg SJ, Apt L, Yoshimori R, Khwarg S: Chemical preparation of the eye in ophthalmic surgery. *Arch Ophthalmol* 103:1340, 1985.
120. Jackson E: Operation on the tendon of the superior rectus muscle for paresis of the superior oblique. *Ophthalmol Rev* 22:61, 1903.
121. Jackson; E: Woods System of Ophthalmic Operations, vol 1, p 741. Cited by Wiener M: Correction of defect due to third nerve paralysis. *Arch Ophthalmol* 57:597, 1928.
122. Jacobs DS, Vastine DW, Urist MJ: Anterior segment ischemia and sector iris atrophy after strabismus surgery in a patient with chronic lymphocytic leukemia. *Ophthalmol Surg* 7:42, 1976.
123. James CB, Elston JS: Effect of squint surgery on pupillary diameter. *Br J Ophthalmol* 79:991, 1995.
124. Jampolsky AA: Simplified Approach to Strabismic Diagnosis. In Symposium on Strabismus. St Louis Mosby-Year Book, 1971, p 34.
125. Jampolsky A: Spring-back balance test in strabismus surgery. In Symposium on Strabismus: Transactions of the New Orleans Academy of Ophthalmology. St Louis, Mosby-Year Book, 1978 p 104.
126. Jampolsky A: Surgical leashes and reverse leashes in strabismus surgical management. In Symposium on Strabismus: Transactions of the New Orleans Academy of Ophthalmology. St Louis, Mosby-Year Book, 1978, p 244.
127. Jampolsky A: Adjustable strabismus surgical procedures. In Symposium on Strabismus: Transactions of the New Orleans Academy of Ophthalmology. St Louis, Mosby-Year Book, 1978, p 321.
128. Jampolsky A: Management of vertical strabismus. In Pediatric Ophthalmology and Strabismus: Transactions of the New Orleans Academy of Ophthalmology. New York, Raven Press, 1986, p 150.
129. Javal E: Manuel du strabisme. Paris, Masson, 1896, p 368.
130. Jensen CDF: Rectus muscle union: A new operation for paralysis of the rectus muscle. *Trans Pacific Coast Ophthalmol Soc* 45:359, 1964.
131. Jones ST: Treatment of hypertropia by vertical displacement of horizontal recti. *Am Orthopt J* 27:107, 1977.
132. Kaluzny J, Ralcewic H, Perlikiewicz-Kikielowa A: Obwod dna oka po operacji zeza. *Klin Oczna* 467:557, 1977.
133. Kaufman LM, Folk ER, Miller MT, Tessler HH: Necrotizing scleritis following strabismus surgery for thyroid ophthalmopathy. *J Pediatr Ophthalmol Strabismus* 26:236, 1989.
134. Kazli FA, Diestelhorst M, Esser P, Rüssmann W: Blut-Kammerwasser-Schranken-Störung nach Augenmuskeloperationen bei Kindern. *Ophthalmologie* 93:325, 1996.
135. Keech RV, Scott WE, Baker JD: The medial rectus muscle insertion site in infantile esotropia. *Am J Ophthalmol* 109:79, 1990.
136. Klainguti G: La myopexie rétroéquatoriale oblique. *Klin Monatsbl Augenheilkd* 208:348, 1996.
137. Knapp P: The surgical treatment of double-elevator paralysis. *Trans Am Ophthalmol Soc* 67:304, 1969.
138. Knapp P: The increased certainty and the increased correction of the bare sclera closure with bimedial recession. In Moore S, Mein J, Stockbridge L, eds: Orthoptics: Past, Present, Future. Transactions of the Third International Orthoptic Congress. New York, Stratton Intercontinental, 1976.
139. Knoblock R, Lorenz A: Über ernste Komplikationen nach Schieloperationen. *Klin Monatsbl Augenheilkd* 141:348, 1962.
140. Koczek S, Heyde E, Helveston EM: Quantifying the marginal myotomy *Am J Ophthalmol* 70:204, 1970.
141. Kowal L, Troski M: Prevention of anterior segment ischaemia. In Kaufmann H, ed: Transactions of the 20th Meeting of the European Strabismological Association. Brussels, Gahmig Press, 1992, p 291.
142. Kraft SP: Outcome criteria in strabismus surgery. *Can J Ophthalmol* 33:237, 1998.

143. Kushner BJ: Surgery with respect to cyclotropia. *Ocul Ther Surg* 2:44, 1981.
144. Kushner BJ: A surgical procedure to minimize lower-eyelid retraction with inferior rectus recession. *Arch Ophthalmol* 110:1011, 1992.
145. Kushner BJ: Restriction of elevation in adduction after inferior oblique anteriorization. *J Am Assoc Pediatr Ophthalmol Strabismus* 1:55, 1997.
- 145a. Kushner BJ: The effect of anterior transposition of the inferior oblique muscle on the palpebral fissure. *Arch Ophthalmol* 118:1542, 2000.
146. Kushner BJ, Morton G: Postoperative binocularity in adults with long-standing strabismus. *Ophthalmology* 99:316, 1992.
147. Kushner BJ, Lucchese NJ, Morton GV: Variation in axial length and anatomical landmarks in strabismic patients. *Ophthalmology* 98:400, 1991.
148. Kwito S, Sawusch MR, McDonnell PJ, et al. Effect of extraocular muscle surgery on corneal topography. *Arch Ophthalmol* 109:873, 1991.
149. Laqueur L: Die Schieloperation von A.v. Graefe. *Graefes Arch Clin Exp Ophthalmol* 68:461, 190.
150. Lyle K: Torsional diplopia due to cyclotropia and its surgical treatment. *Trans Am Acad Ophthalmol Otolaryngol* 68:387, 1964.
151. Lyons CJ, Fells P, Lee JP, McIntyre A: Chorioretinal scarring following the Faden operation. A retrospective study of 100 procedures. *Eye* 3:401, 1989.
152. MacEwen CJ, Lee JP, Fells P: Aetiology and management of the "detached" rectus muscle. *Br J Ophthalmol* 76:131, 1992.
153. Marmor M: Malignant hyperthermia. *Surv Ophthalmol* 28:117, 1983.
154. Martinez L: A case of fixed strabismus. *Am J Ophthalmol* 31:80, 1948.
155. Massin M, Hudelo J: L'incision de la conjunctive au limbe dans les opérations pour strabisme et pour décollement de rétine. *Ann Ocul* 195:995, 1962.
156. Maza MS de la, Foster S: Necrotizing scleritis after ocular surgery. *Ophthalmology* 98:1720, 1991.
157. McGill WA, Coveler LA, Epstein BS: Subacute upper respiratory infection in small children. *Anesth Analg* 58:331, 1979.
158. McGoldrich KE: Anesthesia and the eye. In Barash PG, Cullen BR, Stoelting RK, eds: *Clinical Anesthesia*. Philadelphia, JB Lippincott, 1989, p 1055.
159. McKeown CA, Lamber HM, Shore JW: Preservation of the anterior ciliary vessels during extraocular muscle surgery. *Ophthalmology* 96:498, 1989.
160. McLean JM, Galin MA, Baras I: Retinal perforation during strabismus surgery. *Am J Ophthalmol* 50:1167, 1960.
161. Metz HS: The use of vertical offsets with horizontal strabismus surgery. *Ophthalmology* 95:1094, 1988.
162. Metz HS: Muscle transposition surgery (20th Annual Frank Costenbader Lecture). *J Pediatr Ophthalmol Strabismus* 30:346, 1993.
163. Metz HS, Lerner H: The adjustable Harada-Ito procedure. *Arch Ophthalmol* 99:624, 1981.
164. Metz HS, Scott AB: Innervational plasticity of the oculomotor system. *Arch Ophthalmol* 84:86, 1970.
165. Miller JM: Biomechanical models of strabismus. In Lernerstrand G, Ygge J, eds: *Wenner-Gren International Series*. vol 78: *Advances in Strabismus Research: Basic and Clinical Aspect*. London, Portland Press, In press.
166. Miller JM, Demer JL, Rosenbaum AL: Effect of transposition surgery on rectus muscle path by magnetic resonance imaging. *Ophthalmology* 475:100, 1993.
167. Mills PV, Hper TJ, Duff GR: Loop recession of the recti muscles. *Eye* 1:59, 1987.
168. Milot J, Jacob JL, Blanc VF, Hardy JF: The oculocardial reflex in strabismus surgery. *Can J Ophthalmol* 18:314, 1983.
169. Mims JL, Woods RC: Bilateral anterior transposition of the inferior oblique muscles. *Arch Ophthalmol* 107:41, 1989.
170. Mims JL, Wood RC: Antielevation syndrome after bilateral anterior transposition of the inferior oblique muscles: Incidence and prevention. *J Am Assoc Pediatr Ophthalmol Strabismus* 3:333, 1999.
171. Mombaerts I, Koorneef L, Everhard-Halm YS, et al: Superior oblique luxation and trochlear luxation as new concepts in superior oblique muscle weakening surgery. *Am J Ophthalmol* 120:83, 1995.
172. Mullough DH, Strominger MB: Comparison of anterior transposition and recession of the inferior oblique muscle in unilateral superior oblique paresis. *Am Assoc Pediatr Ophthalmol Strabismus* 2:340, 1998.
173. Mulvihill A, Murphy M, Lew JP: Disinsertion of the inferior oblique muscle for treatment of superior oblique paresis. *J Pediatr Ophthalmol Strabismus* 37:279, 2000.
174. Murdock TJ, Mills MD: Anterior segment ischemia after strabismus surgery with microvascular dissection. *J Am Assoc Pediatr Ophthalmol Strabismus* 4:56, 2000.
175. Mitchell PR, Parks MM: Surgery for bilateral superior oblique palsy. *Ophthalmology* 89:484, 1982.
176. Moen C, March I: Inferior oblique syndrome: An under-recognized complication of strabismus surgery. *Eye* 2:970, 1998.
177. Møller PM: Influence of anesthesia and premedication on the squint angle. *Acta Ophthalmol Scand* 36:499, 1958.
178. Morris RJ, Rosen PH, Fells P: Incidence of inadvertent globe perforation during strabismus surgery. *Br J Ophthalmol* 74:490, 1990.
179. Mühlendyck H: Diagnosis of convergent strabismus with nystagmus and its treatment with Cüppers Fadenoperation. In Moore S, Mein J, Stockbridge L, eds: *Orthoptics: Past, Present, Future*. Transactions of the Third International Orthoptic Congress. New York, Stratton International, 1976, p 143.
180. Murray ADN: Slipped and lost muscles and other tales unexpected (Philip Knapp Lecture). *J Am Assoc Pediatr Ophthalmol Strabismus* 2:133, 1998.
181. Nawratzki I, Benezra D: Transposition of vertical recti for residual tropias. *Ann Ophthalmol* 8:1245, 1976.
182. Nemet P, Stolovitch C: Biased resection of the medial recti: A new surgical approach to convergence insufficiency. *Binocular Vision Strabismus*. 5:213, 1990.
183. Noel LP, Bloom JN, Clarke WN, Bawazeer A: Retinal perforation in strabismus surgery. *J Pediatr Ophthalmol Strabismus* 34:115, 1997.
184. Noorden GK von: The limbal approach to surgery of the rectus muscles. *Arch Ophthalmol* 80:94, 1968.
185. Noorden GK von: Modification of the limbal approach to surgery of the rectus muscles. *Arch Ophthalmol* 82:349, 1969.
186. Noorden GK von: Orbital cellulitis following extraocular muscle surgery. *Am J Ophthalmol* 74:627, 1972.
187. Noorden GK von: Extraocular muscle surgery. In *Highlights in Ophthalmology*, vol 14. Panama, Clinica Boyd Institute of Ophthalmology, 1972-73 p 63.
188. Noorden GK von: Anterior segment ischemia following the Jensen procedure. *Arch Ophthalmol* 94:845, 1976.
189. Noorden GK von: Posterior fixation suture in strabismus surgery. In *Symposium on Strabismus: Transactions of the New Orleans Academy of Ophthalmology*. St Louis, Mosby-Year Book, 1978, p 307.
190. Noorden GK von: Indications of the posterior fixation operation in strabismus. *Ophthalmology* 85:512, 1978.
191. Noorden GK von: Clinical observations in cyclodeviations. *Ophthalmology* 86:1451, 1979.

192. Noorden GK von: A modified Burch tendon tucker for use in children. *Ophthalmic Surg* 11:525, 1980.
193. Noorden GK von: An alternative to marginal myotomy. *Am J Ophthalmol*. 94:285, 1982.
194. Noorden GK von: Extraocular muscles. In Beyer-Machule CK, Noorden GK von, eds: *Lids, Orbits, Extraocular Muscles*, vol 1: *Atlas of Ophthalmic Surgery*. Heilmann K, Paton D, eds. New York, Thieme-Stratton, 1985, p 211.
195. Noorden GK von, Esswein MB: Unpublished observations, 1994.
196. Noorden GK von, Murray EM: Up- and downshoot in Duane's retraction syndrome. *J Pediatr Ophthalmol Strabismus* 23:212, 1986.
197. Noorden GK von, Jenkins RH, Rosenbaum AL: Horizontal transposition of the vertical rectus muscles for treatment of ocular torticollis. *J Pediatr Ophthalmol Strabismus* 30:8, 1993.
198. Noorden GK von, Tredici TD, Ruttum M: Pseudo-internuclear ophthalmoplegia after surgical paresis of the medial rectus muscle. *Am J Ophthalmol* 98:602, 1984.
199. O'Brien CS, Leinfelder PJ: Unilateral exophthalmos: Etiologic and diagnostic studies in 82 consecutive cases. *Am J Ophthalmol* 18:123, 1935.
200. O'Connor R: Transplantation of ocular muscles. *Am J Ophthalmol* 4:838, 1921.
201. O'Donoghue E, Lightman S, Tuft S, Watson P: Surgically induced necrotising sclerokeratitis (SINS)—precipitating factors and response to treatment. *Br J Ophthalmol* 76:17, 1992.
202. O'Neill JF: Surgical management of small angle hyperopia by vertical displacement of the horizontal rectus muscles. *Am Orthopt J* 28:32, 1978.
203. Ohji M, Kinoshita S, Ohmi E, Kuwayama Y: Marked intraocular pressure response to instillation of corticosteroids in children. *Am J Ophthalmol* 112:450, 1991.
204. Ohmi E, Ogi K, Kani K: Eye position and electromyographic observation of squint eyes under general anesthesia. *Ophthalmologica* 178:166, 1979.
205. Ohmi E, Oguri K, Yoshiya I, Kitamura S: Eye position of squinting eyes during general anesthesia. *Acta Soc Ophthalmol Jpn* 79:540, 1975.
206. Ohtsuki H, Hasebe S, Tadokoro Y, et al: Preoperative prism correction in patients with acquired esotropia. *Graefes Arch Clin Exp Ophthalmol* 231:71, 1993.
207. Olivier P, N'Guyen D: Ocular alignment variations after strabismus surgery. In Ravault AP, Lenk M, eds: *Transactions of the Fifth International Orthoptic Congress*. Lyon, LIPS, 1984, p 523.
208. Olivier P, Noorden GK von: Results of superior oblique tenectomy in inferior oblique paresis. *Arch Ophthalmol* 100:581, 1982.
209. Olmstead JMD, Margutti M, Yanagisawa K: Adaptation to transposition of eye muscles. *Am J Physiol* 116:245, 1936.
210. Olver JM, Lee JP: The effects of strabismus surgery on anterior segment circulation. *Eye* 3:318, 1989.
211. Olver JM, Lee JP: Recovery of anterior segment circulation after strabismus surgery in adult patients. *Ophthalmology* 99:305, 1992.
212. Pacheco EM, Guyton DL, Repka MX: Changes in eyelid position accompanying vertical rectus muscle surgery and prevention of lower lid retraction with adjustable surgery. *J Pediatr Ophthalmol Strabismus* 29:265, 1992.
213. Paliaga GP, Braga M: Passive limitation of adduction after Cüppers's "Fadenoperation" on medial recti. *Br J Ophthalmol* 73:633, 1989.
214. Paque JT, Mumma JV: Vertical offsets of the horizontal recti. *J Pediatr Ophthalmol Strabismus* 15:205, 1978.
215. Parks MM: Fornix incision for horizontal rectus muscle surgery. *Am J Ophthalmol* 65:907, 1968.
216. Parks MM: The weakening surgical procedures for eliminating overaction of the inferior oblique muscle. *Am J Ophthalmol* 73:107, 1972.
217. Parks MM: The overacting inferior oblique muscle. *Am J Ophthalmol* 77:787, 1974.
218. Parks MM: *Atlas of Strabismus Surgery*. Philadelphia, Harper & Row, 1983.
219. Parks MM, Helveston EM: Direct visualization of the superior oblique tendon. *Arch Ophthalmol* 84:491, 1970.
220. Peter L: *The Extraocular Muscles*. Philadelphia, Lea & Febiger, 1941, p 324.
221. Peter LC: The use of the superior oblique as an internal rotator in third-nerve paralysis. *Am J Ophthalmol* 17:297, 1934.
222. Philips S: *Ophthalmic Operations*. London, Baillière, Tindall & Cox, 1950, p 121.
223. Plager DA, Parks MM: Recognition and repair of the "lost" rectus muscle. *Ophthalmology* 97:131, 1990.
224. Pollard Z, Greenberg MF: Results and complications in 66 cases using a silicone tendon expander on overacting superior obliques with A pattern anisotropias. *Binocular Vision Strabismus Q* 15:113, 2000.
225. Prakash R, Verma D, Menon V: Anterior segment ischemia following extraocular muscle surgery. *Jpn J Ophthalmol* 30:251, 1986.
226. Pratt-Johnson J: Fusion ability lost and regained in visual adults. *Graefes Arch Clin Exp Ophthalmol* 226:111, 1988.
227. Preslan MW, Cioffi G, Min YI: Refractive error changes following strabismus surgery. *J Pediatr Ophthalmol Strabismus* 29:300, 1992.
228. Prince AE: The pulley modification of limiting tenotomy and advancement of the rectus operation. With a report of a case of section and one of exsection of the rectus. *Med Rec* 28:44, 1885.
229. Prism Adaptation Study Research Group: Efficacy of prism adaptation in the surgical management of acquired esotropia. *Arch Ophthalmol* 108:1248, 1990.
230. Quéré MA, Pechereau A, Calvez B, Clergeau B: Le signe de l'anesthésie dans les ésootropes fonctionnelles. Etude statistique de 318 cas. *Bull Mem Soc Fr Ophthalmol* 92:308, 1980.
231. Raab EL, Costenbader FD: Contralateral inferior oblique overaction following unilateral weakening surgery. In Mein J, Bierlaagh JJM, Brummelkamp-Dons TEA, eds: *Orthoptics. Proceedings of the Second International Orthoptic Congress*. Amsterdam, Excerpta Medica, 1972.
232. Raizman M, Beck RW: Iris ischemia following surgery on two rectus muscles (letter). *Arch Ophthalmol* 103:1783, 1985.
233. Recchia FM, Baupal CR, Sivalingam A, et al: Endophthalmitis after pediatric strabismus surgery. *Arch Ophthalmol* 118:939, 2000.
234. Reinecke RD: The figure-of-eight suture for eye muscle surgery. *Ophthalmol Dig* 34:22, 1972.
235. Remky H: Die Frühzeit der operativen Schielbehandlung (1839–1841). Presented at the Seventh Meeting of the Julius Hirschberg Society, Vienna, Nov 4–7, 1993.
236. Repka MX, Guyton DL: Comparison of hang-back medial rectus recession with conventional recession. *Ophthalmology* 96:782, 1988.
237. Repka MX, Connet JE, Scott WE: The one-year surgical outcome after prism adaptation for the management of acquired esotropia. *Ophthalmology* 103:922, 1996.
238. Repka MX, Fishman PJ, Guyton DL: The site of reattachment of the extraocular muscles following hang-back recession. *J Pediatr Ophthalmol Strabismus* 27: 286, 1990.
239. Reynolds RD, Nelson LB, Greenwald M: Large refractive change after strabismus surgery (letter). *Am J Ophthalmol* 111:371, 1991.

240. Robinson D: A quantitative analysis of extraocular muscle cooperation and squint. *Invest Ophthalmol. Vis Sci* 14: 801, 1975.
241. Romano P: Routine antibiotic coverage in eye muscle surgery (letter). *Binocular Vision Strabismus* 4:152, 1989.
242. Romano P, Gabriel L.: Intraoperative adjustment of eye muscle surgery. Correction based on eye position during general anesthesia. *Arch Ophthalmol* 103:351, 1985.
243. Romano PE, Gabriel L, Bennett WL, Snyder BM: Stage I intraoperative adjustment of eye muscle surgery under general anesthesia: Consideration of graduated adjustment. *Graefes Arch Clin Exp Ophthalmol* 226:235, 1988.
244. Rosenbaum AL: The goal of adult strabismus surgery is not cosmetic (letter). *Arch Ophthalmol* 117:250, 1999.
245. Rosenbaum AL, Santiago AP, eds: *Clinical Strabismus Management. Principles and Surgical Management*. Philadelphia, WB Saunders, 1999.
246. Roth A: Gefäßschonung bei Schieloperationen. *Klin Monatsbl Augenheilkd* 195:161, 1989.
247. Salamon SM, Friberg TR, Luxenburg MN: Endophthalmitis after strabismus surgery. *Am J Ophthalmol* 93:39, 1982.
248. Saunders R, Phillips MS: Anterior segment ischemia after three rectus muscle surgery. *Ophthalmology* 95:533, 1988.
249. Saunders RA, Sandall GS: Anterior segment ischemia syndrome following rectus muscle transposition. *Am J Ophthalmol* 93:34, 1982.
250. Saunders RA, Bluestein EC, Wilson ME, Berland JE: Anterior segment ischemia after strabismus surgery. *Surv Ophthalmol* 38:456, 1994.
251. Scharway K, Gräf M, Becker R, Kaufmann H: Heilungsverlauf und Komplikationen nach Augenmuskeloperationen. *Ophthalmologie* 97:22, 2000.
252. Schworm HD, Ullrich S, Häing C, et al: Does strabismus surgery induce significant changes of corneal topography? *Strabismus* 5:81, 1997.
253. Scott AB: Posterior fixation: Adjustable and without posterior sutures. In Lennerstrand G, ed: *Update on Strabismus and Pediatric Ophthalmology*. Boca Raton, FL, CRC Press, 1994, p 399.
254. Scott W, Lee W, Kutschke P: Adult strabismus. *J Pediatr Ophthalmol Strabismus* 32:348, 1995.
255. Scott WE, Thalacker A: Preoperative prism adaptation in acquired esotropia. *Ophthalmologica* 189:49, 1984.
256. Seawright AA, Gole GA: Results of treatment of superior oblique overaction by silicone tendon-expander techniques. *J Pediatr Ophthalmol Strabismus* 35:33, 1998.
257. Selezinka W, Sandall GS, Henderson JW: Rectus muscle union in sixth nerve paralysis, Jensen rectus muscle union. *Arch Ophthalmol* 92:882, 1974.
258. Sharma P, Arya AV, Prakash P: Scleral dellen in strabismus surgery. *Acta Ophthalmol* 68:493, 1990.
259. Shin GS, Elliot RL, Rosenbaum AL: Posterior superior oblique tenotomy at the scleral insertion for collapse of A-pattern strabismus. *J Pediatr Ophthalmol Strabismus* 33:211, 1996.
260. Simon JW, Lininger LL, Scheraga JL: Recognized scleral perforation during eye muscle surgery: Incidence and sequelae. *J Pediatr Ophthalmol Strabismus* 29:273, 1992.
261. Simonsz HJ: Predictive clinical value of strabismus computer models. In Lennerstrand G, Ygge J, eds: *Wenner Gren International Series, vol 78: Advances in Strabismus Research: Basic and Clinical Aspects*. London, Portland Press, 2000, p 195.
262. Small RG: Functional vs cosmetic ophthalmologic defects (letter). *Arch Ophthalmol* 109:1194, 1991.
263. Smet MD de, Carruthers J, Lepawsky M: Anterior segment ischemia treated with hyperbaric oxygen. *Can J Ophthalmol* 22:381, 1987.
264. Snir M, Nissenkorn I, Buckman G, et al: Postoperative refractive changes in children with congenital esotropia: A preliminary study. *Ophthalmic Surg* 20:57, 1989.
265. Snow JC: Malignant hyperthermia during anesthesia and surgery. *Arch Ophthalmol* 84:407, 1970.
266. Soliyzki SE, Awner S, Reynolds JD: Perioperative care of the strabismus patient. *J Pediatr Ophthalmol Strabismus* 34:1256, 1997.
267. Speaker MG, Menikoff JA: Prophylaxis of endophthalmitis with topical povidone-iodine. *Ophthalmology* 98:1769, 1991.
268. Spielmann A: The "oblique Kestenbaum" procedure revisited (sloped recessions of the recti). In Lenk-Schäfer M, ed: *Orthoptic Horizons. Transactions of the Sixth International Orthoptic Congress, Harrogate, UK, 1987*, p 433.
269. Spielmann A, Laulan J: Protocole opératoire tire de l'analyse statistique: Fadenopération et chirurgie classique dans les ésootropies. *Bull Soc Ophtalmol Fr* 79:8, 1979.
270. Spielmann A, Spielmann AC: Association of fixed suspension of the capsulo-palpebral head of the inferior rectus with semi-adjustable recession of the inferior rectus muscle to minimize recession complications. In Kaufmann H, ed: *Transactions of the 21st Meeting of the European Strabismological Association, Giessen, 1993*. Gahmig Press, p 175.
271. Spierer A, Barequet I, Rosner M, et al: Reattachment of extraocular muscles using fibrin glue in a rabbit model. *Invest Ophthalmol Vis Sci* 38:543, 1997.
272. Stager DR: The effect of anterior transposition of the inferior oblique muscle. *Am J Ophthalmol* 117:274, 1994.
273. Stager DR: The neovascular bundle of the inferior oblique muscle as the ancillary origin of that muscle. *J Am Assoc Pediatr Ophthalmol Strabismus* 4:216, 1997.
274. Stager DR, Parks MM: Inferior oblique weakening procedures. Effect on primary position horizontal alignment. *Arch Ophthalmol* 90:15, 1973.
275. Stager DR, Parks MM, Stager DR Jr, Pesheva M: Long-term results of silicone expander for moderate and severe Brown syndrome (Brown syndrome "plus"). *J Am Assoc Pediatr Ophthalmol Strabismus* 3:328, 1999.
276. Stager DR, Weakley DR, Stager D: Anterior transposition of the inferior oblique—atomic assessment of the neurovascular bundle. *Arch Ophthalmol* 110:360, 1992.
277. Stein LA, Ellis FJ: Apparent contralateral inferior oblique muscle overaction after unilateral inferior oblique muscle weakening procedures. *J Am Assoc Pediatr Ophthalmol Strabismus* 1:2, 1997.
278. Stephens JL: *Incidents of Travel in Yucatan*, vol 1. New York, Dover Publications, 1963, p 61. Republication of work first published by Harper & Brothers, 1843.
279. Stromeyer L: Beiträge zur operativen Orthopädie oder Erfahrungen über die subcutane Durchschneidung verkürzter Muskeln und deren Sehnen. Hanover, Helwigsche Hof-Buchhandlung, 1838.
280. Stucchi C, Bianchi G: Dépigmentation en secteur de l'iris consécutive à des transplantations musculaires. *Ophthalmologica* 133:231, 1957.
281. Swan K: Problems of exotropia. *J Pediatr Ophthalmol Strabismus* 2:25, 1965.
282. Technical bulletin for malignant hyperthermia. *ASA Newsletter*, November 1982, p 5.
283. Thompson WE, Reinecke RD: The changes in refractive status following routine strabismus surgery. *J Pediatr Ophthalmol Strabismus* 17:372, 1980.
284. Toosi SH, Noorden GK von: Effect of isolated inferior oblique myectomy in management of superior oblique palsy. *Am J Ophthalmol* 88:602, 1979.
285. Trajer AD, Hudec M, Nikolić V: Biomechanische Analyse und Erklärung der Krümmungsveränderung der

- Hornhaut nach dem operativen Eingriff an den geraden Augenmuskeln. *Verh Anat Ges* 70:505, 1976.
286. Troia RN, Nelson LB, Calhoun JH, Harley RD: Surgical correction of exocycloptopia. *Am Orthopt J* 35:63, 1985.
 287. Uniat LM, Olk JR, Kenneally CZ, Windsor CH: Endophthalmitis after strabismus surgery with a good visual result. *Ophthalmic Surg* 19:42, 1988.
 288. Vempali YMR, Lee JP: Results of superior oblique posterior tenotomy. *J Am Assoc Pediatr Ophthalmol Strabismus* 2:147, 1998.
 289. Verhoeff FH: Transposition of the extraocular muscles. *Am J Ophthalmol* 25:227, 1942.
 290. Vila-Coro A: Metodos personal para la tratamiento operatorio del estrabismo. Barcelona, Talleres Graficos, 1927, p 1.
 291. Vila-Coro AA: Vascular microdissection in strabismus surgery. *Arch Ophthalmol* 108:1034, 1990.
 292. Villaseca A: Strabismus fixus. *Am J Ophthalmol* 48:751, 1959.
 293. Vrabec MP, Preslan MW, Kushner B: Oculocardiac reflex during manipulation of adjustable sutures after strabismus surgery. *Can J Ophthalmol* 104:61, 1987.
 294. Weakley DR: Orbital cellulitis complicating strabismus surgery: A case report and review of the literature. *Ann Ophthalmol* 23:454, 1991.
 295. Weidlich R: Der Beitrag Alfred K. Graefes zur operativen Behandlung des Schielens im ausgehenden 19. Jahrhundert. *Klin Monatsbl Augenheilkd* 208:66, 1996.
 296. Wiener M: Correction of defect due to third nerve paralysis. *Arch Ophthalmol* 57:597, 1928.
 297. Wilson ME, Paul OT: Orbital cellulitis following strabismus surgery. *Ophthalmic Surg* 18:92, 1987.
 298. Wilson ME, Sinatra AB, Saunders RA: Downgaze restriction after placement of the superior tendon spacer for Brown syndrome. *J Pediatr Ophthalmol Strabismus* 32:29, 1995.
 299. Wisnicki HJ, Repka MX, Guyton GL: Reoperation rate in adjustable strabismus surgery. *J Pediatr Ophthalmol Strabismus* 25:112, 1988.
 300. Wolter JR: Amputation neuroma after strabismus surgery. *J Pediatr Ophthalmol Strabismus* 4:33, 1967.
 301. Wolter JR, Benz CA: Bilateral amputation neuromas of eye muscles. *Am J Ophthalmol* 57:287, 1964.
 302. Wood CA: *The American Encyclopedia and Dictionary of Ophthalmology*. Chicago, Cleveland Press, 1914, p 3964.
 303. Wortham E, Greenwald M: Expanded binocular peripheral visual fields following surgery for esotropia. *J Pediatr Ophthalmol Strabismus* 26:109, 1989.
 304. Wright K: *Color Atlas of Strabismus Surgery*. Philadelphia, JB Lippincott, 1991.
 305. Wright K: Superior oblique silicone expander for Brown's syndrome and superior oblique overaction. *J Pediatr Ophthalmol Strabismus* 28:101, 1991.
 306. Wright K, Lanier AN: Effect of a modified rectus tuck anterior chamber circulation in monkeys. *J Pediatr Ophthalmol Strabismus* 28:77, 1991.
 307. Wright KW: Brown's syndrome: Diagnosis and management. *Trans Am Ophthalmol Soc* 97:1023, 1999.
 308. Wright KW, Min BM, Park C: Comparison of superior oblique tendon expander to superior oblique tenotomy for the management of superior oblique overaction and Brown's syndrome. *J Pediatr Ophthalmol Strabismus* 29:92, 1992.
 309. Zugsmith GS: A new approach to surgery of the inferior oblique muscle. *Am J Ophthalmol* 47:667, 1959.